Science Advisory Board

Environmental Protection Agency

I have read the latest version of the IRIS assessment on ERA and ETB and I continue to disagree with several of their conclusions. I have provided detailed explanations of these in my previous comments both in 2016 and 2017, but will summarize briefly here. I will be recused from the SAB discussion because of these previous comments.

The kidney effects associated with TBA and ETBE are entirely explainable by α_{2U}globulin nephropathy, chronic progressive nephropathy (CPN) and corticomedullary mineralization, none of which are relevant to humans. The IRIS assessment continues to insist that the findings of supportive inflammation and so-called urothelial (transitional cell) hyperplasia are independent of either α_{2U}globulin nephropathy or CPN. However, both of these are the consequence of long term CPN, as was indicated in the original National Toxicology Program report on TBA. Furthermore, we have recently demonstrated that the finding is not urothelial nor hyperplasia, but rather it is a finding related to vesicular formation and collapse of the lining of the renal papillae, and is distinct from the true kidney pelvis urothelium (Souza et al., Toxicologic Pathology, 2018). It is found only in the higher grades of CPN. Gordon Hard and I have just completed a review of the slides from the NTP short and long term studies (sponsored by Lyondell Bassel). We confirm that all of the criteria of α_{2U}globulin nephropathy and CPN are met and that there are no other kidney toxicity findings. Thus, none of the kidney findings, non-cancer or cancer endpoints related to TBA and ETBE, are relevant to humans.

Thus, although the non-kidney effects in rats and mice of these chemicals were at higher doses than the kidney findings, the non-kidney findings are what should be used for the overall risk assessment for non-cancer endpoints. Most notably, this should include the liver findings which are related to PPARα activation. This is a finding that could occur at high exposures in humans.

In addition, the statement that the liver tumors related to ETBE are relevant to humans is incorrect. There is more than sufficient evidence that these are secondary to the PPARα activation, which is a mode of action of rodent liver tumorigenesis that is not relevant to humans. The finding of non-relevance has been described in detail in Corton et al., Critical Reviews in Toxicology, 44:1-49, 2014, and in the recent Corton et al., Archives in Toxicology, 92: 83-2018. It should be noted that Dr. Corton is on a research team for EPA, and he and his colleagues present convincing arguments for the non-relevance of the PPARα related tumors for humans. The metabolic effects can be relevant, but not the tumors. In addition, the thyroid follicular tumors in mice are not relevant to humans although the specific mode of action has not been delineated in the model. It should be noted that findings in the male mice is of borderline statistical significance and within the historical controls this leaves this as a single finding of a single tumor in a single species and in a single sex. Furthermore, these are benign. Rodent thyroid follicular tumors are not relevant to humans as they are all directly or indirectly related to activation of TSH with stimulation of thyroid follicular cell proliferation and ultimately tumors. This mechanism, regardless of how it is produced, is not relevant to tumor as there is no evidence that hypothyroidism leading to increased TSH is related to human thyroid cancer.

The animal initiation-promotion model that is described in the IRIS document also is not valid. The study with five DNA reactive carcinogens followed by the test chemical has not been validated, has enormous variability with background rates, and with no indication in the publications that the ETBE treatment is outside the range of historical controls. In summary, there is no carcinogenic activity in rats or mice with ETBE or TBA that is relevant to human cancer risk. Thus, it should not be classified as being related to human cancer. For non-cancer endpoints, I would strongly recommend the use of liver toxicity data to set the standard, as the PPAR activation metabolic effects can occur in humans, but it is not relevant to human cancer.

Lastly, I raise concerns about systematic review as used in this assessment. It is helpful in identifying publications, but one has to have the scientific experience and scientific expertise to understand them: to understand the kidney findings, the understand PPARα activation and its non-relevance to human cancer, to understand the limitations of the initiation-promotion experiments, etc. The IRIS assessment showed a lack of understanding of these issues and presented a highly biased evaluation.

I hope that the SAB will take a firm stand against this scientifically unsound report from the IRIS program. It is clear that there was considerable concern in the review in the CAAC that raised considerable doubt from the IRIS report.

Attached are my previous comments to the EPA docket regarding ETBE and TBA.

Sincerely yours.

Samuel M. Cohen, M.D., Ph.D.
Professor, Department of Pathology and Microbiology
Havlik-Wall Professor of Oncology
University of Nebraska Medical Center
983135 Nebraska Medical Center
Omaha, NE 68198-3135
(402) 559-6388
(402) 559-8330 (F)

Comments to the Docket for the EPA/SAB/CAAC Report on the EPA/IRIS Assessment of Tertiary Butyl Alcohol (TBA) and Ethyl Tertiary Butyl Ether (ETBE)

Samuel M. Cohen, M.D., Ph.D.
Department of Pathology & Microbiology
University of Nebraska Medical Center
Omaha, NE 68198-3135

Following are my comments regarding the recently published EPA/SAB/CAAC evaluation of the IRIS assessment on TBA and ETBE. It is noteworthy that there was a general lack of consensus regarding the overall assessment of both of these chemicals, especially regarding the kidney changes produced by both chemicals, the liver changes related to ETBE, and the thyroid changes related to TBA. I have written extensive details regarding each of these issues in previous comments to the docket following the June, 2016 and the June, 2017 presentations by EPA/IRIS related to these chemicals. As indicated in all of these comments, the major issue is the lack of pathology expertise on the team of scientists involved with the IRIS assessment and its peer review. It should also be noted that the CAAC does not have a pathologist, which significantly affects the CAAC's ability to deal with these issues. The CAAC comments regarding other aspects of the assessment, particularly PBPK modeling, reflects the level of expertise in these areas represented on the CAAC. In contrast, the lack of pathology expertise is clearly reflected in the comments of the CAAC dealing with the kidney, liver, and thyroid. Given the frequent indication by myself and several other reviewers at the 2016 and 2017 presentations that pathology expertise was required, the lack of such expertise in every aspect of the TBA and ETBE evaluation is troublesome.

It is clear in the CAAC report that at least some of the members understand the major gaps in the IRIS assessment of TBA and ETBE, thus leading to the lack of consensus by the panel. EPA/IRIS has made their assessments much more complicated than necessary by ignoring the extensive evaluations by the NTP, 2 Pathology Working Groups (PWGs), and extensive publications and expertise available.

I will not describe again in detail the difficulties of the IRIS assessments regarding kidney, liver, and thyroid pathology, except to highlight specific issues.

The IRIS assessment and several individuals on the CAAC continue to have difficulty accepting that chronic progressive nephropathy (CPN) is a distinct disease entity that has numerous manifestations. I refer them to the INHAND report on the urinary tract (Frazier et al., 2012) that is the current standard for nomenclature of toxicologic pathology, and the numerous publications over the past 20 years regarding this issue, several of which were included in my previous comments. The continued reliance of EPA IRIS on transitional cell (urothelial cell) hyperplasia of the kidney pelvis as a separate entity caused by TBA and ETBE reflects a complete lack of knowledge of the pathology and histology of the rat kidney. The so-called hyperplasia is a manifestation of high grade CPN, is not urothelial and is likely not a proliferative lesion. Dr. Gordon Hard, myself, and colleagues have recently published a detailed evaluation contrasting the lining of the rat renal papilla epithelium with the true kidney pelvis (Souza et al., in press). These are two separate, distinct epithelia. The lesion of the lining of the renal papilla that was seen with TBA and ETBE is characteristic of high grade CPN (does not usually occur with low grade). I am attaching a copy of the recently published article for the information of

the CAAC and the IRIS scientists. Similarly, the kidney weight and inflammation that are also separated by the IRIS assessment are parts of CPN as well as can be manifestations of α_{2u}-globulin nephropathy. (By the way, it is α_{2u}-globulin, not $\alpha_{2\mu}$-globulin, which is a different protein.)

The insistence of the IRIS scientists on utilizing the 1991 criteria of EPA for α_{2u}-globulin, and the CAAC suggestion to use the 1999 IARC criteria for α_{2u}-globulin ignores the considerable progress that has been made in our understanding of α_{2u}-globulin nephropathy over the past 20 years. Specific criteria are listed in the INHAND document (Frazier et al., 2012) and the numerous publications on the subject over the past 20 years. A rat does not have to have all of the criteria to have α_{2u}-globulin nephropathy. Similarly, publications regarding aspects of CPN have also been published and are largely ignored by the IRIS scientists. Most importantly, regardless of whether the IRIS scientists accept the so-called urothelial (transitional cell) hyperplasia as part of CPN or not, the reality is that this lesion does not occur in humans, so extrapolation of a risk assessment to humans is completely inappropriate.

The IRIS assessment and statements by some of the CAAC at the meeting in June 2017 suggest a reliance on the publications by Melnick et al. (2012; 2013) regarding CPN. To begin with, Dr. Melnick is not a pathologist. Secondly, all of the points that were made by Melnick and his associates regarding CPN have been discussed in detail in a publication by Hard et al. (2013), which is nearly entirely ignored in the IRIS document. Also, the detailed evaluations of the Pathology Working Groups (PWGs) on TBA (Hard et al., 2011) and ETBE (Cohen et al., 2011) were ignored by the IRIS assessments. The IRIS program needs to consult with scientists in

other divisions of EPA on how to deal with PWG reports. PWGs are convened as a gathering of experts to address complicated pathology issues such as seen with the kidney in the TBA and EBTE evaluations. This raises an issue regarding the process for systematic review and utilization of papers which I will discuss later.

To summarize, there were numerous changes reported in the kidney of rats treated with TBA or ETBE including various manifestations of α_{2u}-globulin nephropathy, chronic progressive nephropathy, and cortico-medullary calcification. All of the findings in the kidney can be attributed to these entities. Furthermore, this was stated explicitly in the National Toxicology Program (NTP) document reporting the findings on the TBA assays, including a specific statement that the transitional cell hyperplasia was part of CPN. I do not understand why the IRIS scientists ignore this statement in the NTP document, particularly since it is further corroborated by the PWGs and an extensive literature on these issues.

It was suggested in the document that some members of the CAAC believe like I do, that the kidney changes, both non-cancer and cancer, are inappropriate for a risk assessment of these chemicals. The more appropriate non-cancer endpoint for these chemicals is the liver hypertrophy that was seen at high doses. The reference dose should be based on this finding for both chemicals, since it is related to potential toxicity that could occur in humans, for which there is extensive literature available with regard to its implications for humans.

The second major issue that is dealt with in the documents on these chemicals is the liver changes, particularly the liver tumors seen with ETBE. Again, I refer the reader to the previous comments that I have made on this subject. To summarize, the changes are clearly due to

centrilobular hypertrophy, which is likely due to CAR/PXR and PPARα activation. The IRIS assessment argues that the early changes of centrilobular hypertrophy are not related to the induction of the tumors because the centrilobular hypertrophy does not persist to the end of the experiment. However, again this is a complete misunderstanding of the usual pathologic findings associated with centrilobular hypertrophy. As discussed by Maronpot et al. (2010), centrilobular hypertrophy rarely persists to the end of a long term carcinogenicity study, even in instances where the mode of action clearly is related to the PPARα or CAR/PXR activation. Most importantly, the metabolic effects associated with PPARα activation and CAR/PXR activation can occur in humans, but the carcinogenicity related to these is not relevant to humans. That is because in rodents these receptor activations are related to an increase in hepatocellular proliferation which does not occur in humans (Elcombe et al., 2014; Klaunig et al., 2003; Corton et al., 2014; 2017). The evidence strongly suggests for ETBE that CAR/PXR and PPARα activation is the critical key event. There is an extensive literature on this subject which was summarized nicely in a recent publications (Corton et al., 2014; 2017; Elcombe et al., 2014) clearly showing that this is not relevant to human carcinogenesis. PPARα activators are widely used in human medicine for treatment of hypertriglyceridemia, for which there is no epidemiologic evidence for an increased risk of liver cancer or other types of tumors (Klaunig et al., 2003; Corton et al., 2014; 2017). Similarly, the epidemiology for CAR/PXR activators, particularly phenobarbital, shows no increased risk of cancer in humans, even at doses that approximate those used in the rodent bioassay (Elcombe et al., 2014).

Analysis of the liver tumors with respect to mode of action and human relevance shows that there is more than ample evidence to support this mode of action and lack of human relevance,

in contrast to the statements made by the IRIS assessment and by certain members of the CAAC. Rather than utilizing a recently suggested evaluation of carcinogenicity based on the ten characteristics of cancer, I again implore the IRIS scientists to utilize the mode of action/human relevance framework. This was developed originally by a panel of scientists supported by EPA and Health Canada and it is a framework widely used in other branches of the EPA and numerous other regulatory agencies. The ten characteristics of cancer referred to by IRIS are related to cancer, and are not directly applicable to carcinogenesis itself. (Dr. Robert Weinberg, one of the original authors of the 10 features on cancer (Hanahan and Weinberg, 2000; 2011) concurs that it is inappropriate to apply them to carcinogenesis, personal communication.) The use of the mode of action/human relevance framework provides a transparent, disciplined evaluation of the literature regarding the carcinogenicity (or any toxicity) of a given chemical and an evaluation of its human relevance.

For the liver tumors related to ETBE, the key events are activation of CAR/PXR and PPARα followed by increased hepatocellular proliferation, followed by proliferative lesions such as foci, then adenomas, and potentially carcinoma. There is strong evidence that these key events occur in rats treated with ETBE, although route of administration appears to be critical. The differences in results related to different routes of administration are likely secondary to differences in kinetics and metabolism. Given the strength of the evidence, one can confidently conclude that the centrilobular hypertrophy is a toxic endpoint occurring only at high doses but could be relevant to humans and should be used for the non-cancer evaluation. The liver tumors are not relevant to humans. Furthermore, this is another instance of a single target organ in a single sex in a single species, which certainly at most provides limited evidence of

carcinogenicity in humans, even with a lack of knowledge of mode of action. With information available for mode of action and human relevance, one can confidently conclude that there is no cancer risk to humans related to ETBE.

With respect to the thyroid in the TBA-treated animals, again we are faced with a single tumor site in a single sex in a single species. Since the kidney tumors in the rats are clearly not relevant to humans, it leaves an assessment only of thyroid tumors in female mice. Importantly, the lesions that were produced were only hyperplasia and adenomas, not carcinomas. Furthermore, the incidence was only slightly increased with a P value < 0.05. Since thyroid tumors in the mice are considered a common tumor (defined by Haseman (1983) as background incidences > 1%), the more appropriate statistic is $p < .01$. This was established originally by Haseman (1983) at the NTP to avoid the large variability in incidences in controls related to common tumors and to avoid false positive interpretations. Significance at $p < 0.01$ is widely used in safety assessment of pharmaceuticals and is part of the ICH guidelines (used by the FDA in the United States) (FDA, 2001) and it is also in the current OECD guidelines for interpretation of carcinogenicity testing (OECD, 2014). Based on the use of $p < 0.01$, there actually is no statistically significant increase in thyroid tumors, so we are left with no tumors to evaluate for a carcinogenic endpoint in TBA-treated rodents.

In summary, the kidney toxicity seen in TBA and ETBE-treated rats is secondary to α_{2u}-globulin nephropathy and CPN and are not relevant to humans. This leaves hepatocellular centrilobular hypertrophy as the non-cancer toxic endpoint for risk assessment. The kidney tumors in TBA-treated rats are not relevant to humans. The thyroid tumors in TBA-treated mice are

statistically not significant utilizing the current guidelines for interpretation of carcinogenicity tests of a statistically significant difference of $p < 0.01$. The liver tumors related to ETBE are secondary to a known mode of action that is not relevant to humans. Thus, there is no cancer risk to humans based on the rodent bioassays.

I would also like to briefly address the issue of systematic review. There is undoubtedly progress in the IRIS program in the development of the process of systematic review. However, I am still troubled by two important aspects of literature review. One is an evaluation of the quality of the publications being evaluated, and secondly, having the expertise in the reader to be able to understand the information being presented in the publications. The reliance of the IRIS scientists on the Melnick et al. papers for an evaluation of CPN clearly indicates that there is a strong bias regarding evaluation of the literature by the IRIS scientists. The lack of knowledge regarding kidney and liver pathology and mode of action analysis for toxic endpoints, including cancer, is glaringly evident in the documents. I am pleased to see that at least some of the scientists on the CAAC disagree with the EPA IRIS assessment and raise considerable question as to the interpretation. However, going forward, for the IRIS program to have credibility regarding systematic review, they are going to have to demonstrate that they have the capability of evaluating quality of publications and demonstrate an understanding of what is written in the publications, including pursuing literature on the issues that are raised that may not be specific to the chemical under consideration.

As has become widely recognized, there is a crisis in academic science related to reproducibility (Begley and Ellis, 2012; Lithgow et al., 2017; Baker, 2016; DeKant, 2017). This is reflected in the

numerous publications that have significant methodologic problems. These need to be recognized by the scientists evaluating these publications, taking the quality of the studies into account in the overall weight of evidence. For example, to evaluate α_{2u}-globulin, CPN, CAR/PXR and PPARα activation, the scientists reading the publications on TBA and ETBE need to be aware of the literature on these subjects to be able to address the issues as they review the studies on TBA and ETBE.

Lastly, I have recently been appointed to the EPA Science Advisory Board (SAB). I have been notified that when TBA and ETBE come before the SAB for evaluation, that I will need to recuse myself because I have made public statements regarding these chemicals. If that is a criterion for recusement, then I believe that similar criteria need to be applied to membership on the CAAC. I wonder, therefore, why someone like John Budroe who was involved with the California evaluation is allowed to serve on the CAAC panel.

In summary, TBA and ETBE are two of the simplest substances for which IRIS will evaluate. The literature is relatively succinct, the issues are well-defined, and there is significant literature to support the conclusions that I have presented above indicating that there is no human cancer risk for these chemicals. If the IRIS is unable to adequately assess these two chemicals, there will be significant challenges for them to evaluate other chemicals with much more complex issues. The IRIS program cannot be expected to have in house all of the scientific expertise needed to evaluate all issues involved with a given chemical. It is incumbent on them to reach out for appropriate expertise, elsewhere in EPA, at other government agencies, and in academia and in industry. For example, in dealing with PPARα and liver changes, they have

readily available Dr. Christopher Corton at the EPA, and for liver pathology, there is Dr. Robert Maronpot, formerly of the National Toxicology Program, readily available in Research Triangle Park. With regard to kidney, there are numerous experts that could address these issues and assist the IRIS scientists in making a thorough evaluation of the issues. For instruction on use of the mode of action/human relevance framework, there are several scientists in other divisions of EPA and former EPA scientists that are well versed in its use and application. I implore the IRIS scientists to seek the necessary expertise that they need in addressing the issues raised in the various assessments.

REFERENCES

1. Baker, M. (2016). 1,500 scientists lift the lid on reproducibility. Nature 533(7604): 452-454.
2. Begley, C. G. and L. M. Ellis (2012). Drug development: Raise standards for preclinical cancer research. Nature 483(7391): 531-533.
3. Cohen, S. M. (2017) Comments to the Docket regarding the EPA IRIS Assessment on ETBE.
4. Cohen, S. M. (2017) Comments to the Docket regarding the EPA IRIS Assessment on Tertiary-butyl alcohol (TBA).
5. Cohen, S.M.; Hard, G.C., Regan, K.S., Seely, J.C., Bruner, R.H. (2011) Pathology working group review of selected histopathologic changes in the kidneys of rats assigned to toxicology and carcinogenicity studies of ethyl tertiary butyl ether (ETBE): Japan Bioassay Research Center studies no.: 0065 and 0691 [Unpublished report] (pp. 1-30). Research Triangle Park, NC: Research Pathology Associates under contract to Lyondell Chemical Company.
6. Corton, J. C., Cunningham, M. L., Hummer, B. T., Lau, C., Meek, B., Peters, J. M., Popp, J. A., Rhomberg, L., Seed, J., Klaunig, J. E. (2014). Mode of action framework analysis for receptor-mediated toxicity: The peroxisome proliferator-activated receptor alpha (PPARalpha) as a case study. Crit. Rev. Toxicol. 44(1): 1-49.
7. Corton, J. C., Peters, J. M., Klaunig, J. E. (2017). The PPARα-dependent rodent liver tumor response is not relevant to humans: addressing misconceptions. Archives of Toxicology 92(1): 83-119.
8. DeKant, W. (2017) Toxicology and the reproducibility crisis: Scientific publishing, hazard assessment and risk characterization. Toxicology Letters 263: 76-77.

9. Elcombe, C. R., Peffer, R. C., Wolf, D. C., Bailey, J., Bars, R., Bell, D., Cattley, R. C., Ferguson, S. S., Geter, D. ,Goetz, A., Goodman, J. I., Hester, S., Jacobs, A., Omiecinski, C. J., Schoeny, R., Xie, W., Lake, B. G. (2014). Mode of action and human relevance analysis for nuclear receptor-mediated liver toxicity: A case study with phenobarbital as a model constitutive androstane receptor (CAR) activator. Crit. Rev. Toxicol. 44(1): 64-82.
10. FDA (2001) Guidance for Industry: Statistical Aspects of the Design, Analysis, and Interpretation of Chronic Rodent Carcinogenicity Studies of Pharmaceuticals. Rockville, MD: U.S. Dept. of Health and Human Services, Center for Drug Evaluation and Research, p. 1 – 47.
11. Frazier, K. S., Seely, J. C., Hard, G. C., Betton, G., Burnett, R., Nakatsuji, S., Nishikawa, A., Durchfeld-Meyer, B., Bube, A. (2012). Proliferative and nonproliferative lesions of the rat and mouse urinary system. Toxicol. Pathol. 40(4 Suppl): 14S-86S.
12. Hanahan, D. and R. A. Weinberg (2000). The Hallmarks of Cancer. Cell 100(1): 57-70.
13. Hanahan, D. and R. A. Weinberg (2011). Hallmarks of cancer: the next generation. Cell 144(5): 646-674.
14. Hard, G. C., Bruner, R. H., Cohen, S. M., Pletcher, J. M., Regan, K. S. (2011). Renal histopathology in toxicity and carcinogenicity studies with tert-butyl alcohol administered in drinking water to F344 rats: a pathology working group review and re-evaluation. Regul. Toxicol. Pharmacol. 59(3): 430-436
15. Haseman, J. K. (1983). A reexamination of false-positive rates for carcinogenesis studies. Fundam Appl Toxicol 3(4): 334-339.
16. Klaunig, J. E., Babich, M. A., Baetcke, K. P., Cook, J. C., Corton, J. C., David, R. M., DeLuca, J. G., Lai, D. Y., McKee, R. H., Peters, J. M., Roberts, R. A., Fenner-Crisp, P. A. (2003). PPARalpha agonist-induced rodent tumors: modes of action and human relevance. Crit. Rev. Toxicol. 33(6): 655-780.
17. Lithgow, G. J., Driscoll, M., Phillips, P. (2017). A long journey to reproducible results. Nature 548(7668): 387-388.
18. Maronpot, R. R., Yoshizawa, K., Nyska, A., Harada, T., Flake, G., Mueller, G., Singh, B., Ward, J. M. (2010). Hepatic enzyme induction: histopathology. Toxicol. Pathol. 38(5): 776-795.
19. Melnick, R. L., Burns, K. M., Ward, J. M., Huff, J. (2012). Chemically exacerbated chronic progressive nephropathy not associated with renal tubular tumor induction in rats: an evaluation based on 60 carcinogenicity studies by the national toxicology program. Toxicol. Sci. 128(2): 346-356.
20. Melnick, R. L., Ward, J. M., Huff, J. (2013). War on Carcinogens: Industry Disputes Human Relevance of Chemicals Causing Cancer in Laboratory Animals Based on Unproven Hypotheses, Using Kidney Tumors as an Example. Int. J. Occup. Environ. Health 19(4): 255-260.
21. OECD (2014), Guidance Document 116 on the Conduct and Design of Chronic Toxicity and Carcinogenicity Studies, Supporting Test Guidelines 451, 452 and 453: Second edition, OECD Publishing, Paris. http://dx.doi.org/10.1787/9789264221475-en.
22. Souza, N.P., Hard, G.C., Arnold, L.L., Foster, K.W., Pennington, K. L., and Cohen, S. M. Epithelium lining the renal papilla in rats with normal kidney or with chronic progressive nephropathy (CPN) is not urothelium, and CPN-associated papilla lesions are not hyperplasia. Toxicol. Pathol., in press.

ATTACHMENTS:

2016 TBA Comments

2017 TBA Comments

2017 ETBE Comments

2018 Souza et al., Toxicologic Pathology, in press.

Comments to the Docket for the EPA IRIS on *tert*-butyl Alcohol

Samuel M. Cohen, MD, PhD,

Department of Pathology & Microbiology,

University of Nebraska Medical Center

Following is a summary of the comments that I made at the IRIS Public Science Meeting held on June 30, 2016 on *tert*-butyl alcohol (TBA). Most of my comments regard the male rat kidney issue, but I will also provide a few comments regarding the mouse thyroid.

With respect to the rat kidney, it is my impression that the report needs to be completely redrafted, and the input of a pathologist in the evaluation is essential. That became apparent during the discussion at the Public Meeting.

TBA produces an increased incidence of renal cell tumors (mostly adenomas) along with an increased incidence of atypical tubular hyperplasia (ATH), the precursor of the adenomas. There is substantial evidence supporting modes of action for these tumors as α_{2u}-globulin nephropathy combined with enhanced chronic progressive nephropathy (CPN). The evidence supporting these two modes of action is robust. In addition, evaluation for alternative modes of action provide ample evidence to exclude other possibilities. Both modes of action (α_{2u}-globulin and CPN) are not relevant to humans, therefore, the male rat kidney tumors detected following administration of TBA are not relevant to human cancer risk assessment.

Both α_{2u}-globulin and CPN increase renal tubular cell death, either by exfoliation (in the case of α_{2u}-globulin) or necrosis (in the case of CPN) followed by regenerative proliferation. I presented a diagram illustrating the key events for these modes of action, as follows:

Modes of Action

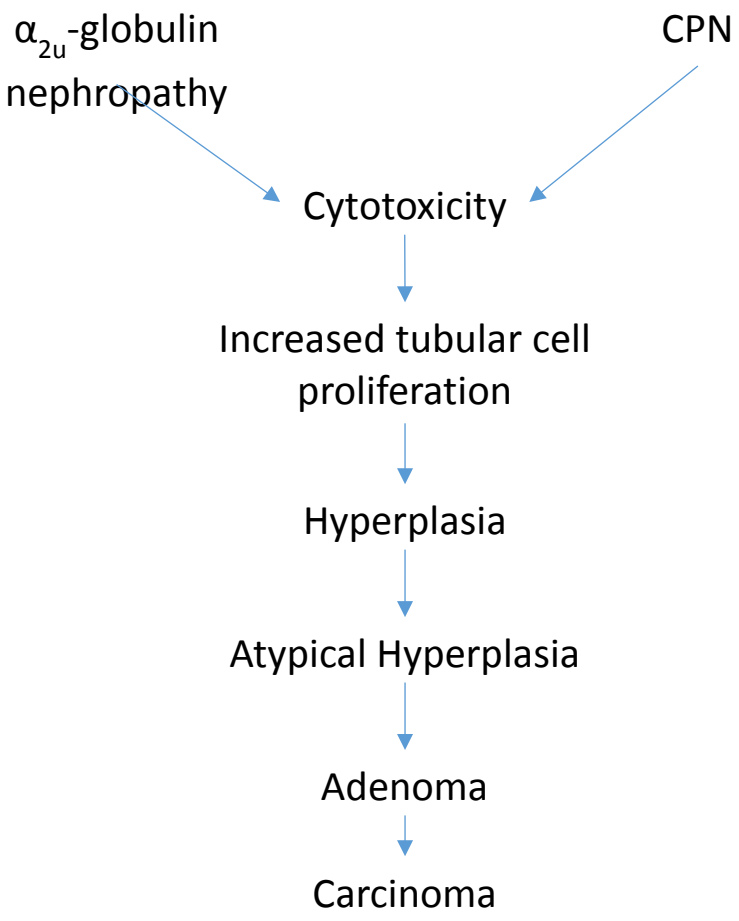

In evaluating the evidence for these modes of action, careful consideration of the quality of the publications is essential. Many of the contrary publications actually are of poor quality and in some instances should not be considered at all.

Furthermore, all of the kidney changes identified in the proposed IRIS document associated with TBA administration to rats are associated with α_{2u}-globulin nephropathy or/and CPN, except for the cortical-medullary calcification that is common in F344 rats. This latter finding also is not relevant to humans based on a long series of articles published over the past 30 years or more.

The evidence for α_{2u}-globulin includes the demonstration by Borghoff that TBA is non-covalently bound to α_{2u}-globulin (Borghoff et al., 2001), the presence of the typical α_{2u}-globulin granules in the proximal tubule cells (Hard et al., 2011), particularly following Mallory-Heidenhain (MH) staining, in the 13-week bioassay (Hard et al., 2011; NTP bioassay), and the presence of linear mineralization in the renal papillae in the 2-year bioassay (Hard et al., 2011; NTP bioassay). By itself, α_{2u}-globulin nephropathy would only explain a relatively small incidence of ATH and adenomas. As demonstrated by Dr. Gordon Hard, the changes with regard to α_{2u}-globulin include presence of casts in the tubules at the 13-week bioassay. These were present only focally, but are clearly there and are documented in the Hard et al. paper on the PWG concerning the NTP studies on TBA (Hard et al., 2011). I want to emphasize that the strongest evidence for α_{2u}-globulin and CPN is based on the evaluation of the NTP bioassay (13-week and 2-year) slides. Some of the other publications raising questions about α_{2u}-globulin involvement with TBA do not necessarily involve these studies. Since the NTP bioassay is the basis for the evaluation of the IRIS assessment, the evaluation of the slides from this study should be the standard by which the others are measured. As indicated by Dr. Hard at the public meeting, the data supporting an α_{2u}-globulin mode of action for TBA is robust, but by itself does not explain all of the renal findings.

The evidence for enhanced CPN is also robust. It is important to keep in mind all of the pathological findings that are part of CPN, but were discussed separately in the draft IRIS report. It is not appropriate to discuss these separately, since they are all part of CPN. A 100% correlation will not be evident based on the descriptions from the studies, since sometimes the individual components of CPN are identified by the pathologist and reported whereas at other times they are lumped together under the broad heading of CPN. However, there is an extensive literature delineating the features of CPN, and these include necrosis with enhanced regenerative proliferation, inflammation (including focal suppurative), tubular casts, transitional hyperplasia, and linear papillary mineralization (calcification).

The draft IRIS report focuses on transitional hyperplasia as a separate pathologic finding following TBA administration and uses it for calculation of an RfD. This is not appropriate since this hyperplasia is part of the CPN process. In actuality, it is hyperplasia of the lining of the renal

papilla, and not hyperplasia of the urothelium of the true kidney pelvis. This was specifically examined by the PWG (Hard et al., 2011), and no instance of true urothelial hyperplasia was identified. In all instances, the hyperplasia was the typical proliferation seen along the renal papillae that is characteristic of CPN. In the NTP report on TBA, they also indicate that the transitional hyperplasia is part of CPN and is a characteristic of CPN (see page 56).

All of the findings, except for the cortical medullary calcification, that were identified in the kidneys of rats administered TBA were associated with either α_{2u}-globulin and/or CPN (Hard et al., 2011). There were no other changes identified. There was no evidence of cytotoxicity in areas of the kidney that were not involved with CPN. There was no evidence of increased apoptosis. There was no evidence of mitogenic (mitotic) activity in tubules not involved with CPN.

Furthermore, the evidence is very strong that TBA is non-genotoxic. The NTP performed genotoxicity assays including the Ames assay, mouse lymphoma cell assay, chromosomal aberration studies in CHO cells, and an *in vivo* micronucleus assay in mice, and these were uniformly negative. The IRIS draft document mentions a few other studies that suggested possible oxidative damage or reduced glutathione activities, particularly relying on the Acharya et al. papers from 1995 and 1997. These Acharya papers should be dismissed for poor quality and not considered as an indication of potential genotoxicity. As I discussed at the public session, the animals used by Acharya et al. showed severe toxicity even at a dose that was used in the NTP bioassay. This is clear evidence that they are having a different response than was seen in NTP studies, although it is unclear what exactly this is due to. There is a possibility, actually quite likely, that the animals were infected, possibly with *Helicobacter hepaticus*, which could produce liver toxicity. The histologic appearance presented in the photomicrograph of the kidneys showed autolysis, not necrosis or other abnormalities. Since the tissues were clearly not fixed adequately, any measurements that were performed on these tissues would be invalid, in addition to the fact that the animals were well above the maximum tolerated dose (MTD) for these animals with this chemical at this dose. The fact that the IRIS draft report gave any credence to these publications raises questions in my mind as to the legitimacy of the systematic review process that was performed. Clearly, these studies do not warrant a level of

quality that should be considered. If some mention of them is to be made, there should be some discussion of the problems of quality.

The lack of human relevance of the findings in the rat kidney is clear: none of the findings, α_{2u}-globulin nephropathy, CPN, or cortical-medullary calcification, are relevant to humans. They are rat specific findings. α_{2u}-globulin was accepted as rat specific in the IRIS draft report. In the literature, cortical-medullary calcification dates back several decades, and also represents a rat specific phenomenon. As Dr. Hard indicated in the public session, it is more common in females than in male rats, and it is probably due to a calcium/phosphate inbalance in these animals. Nevertheless, although more readily observed in H&E stained slides and greater amounts in females, the incidence is nearly 100% in both males and females if more sensitive stains are performed for calcium, such as the Von Kossa stain.

The relevance of CPN to humans has also been discussed extensively, predominantly in publications by Hard et al (2004; 2005; 2009; 2012; 2013). However, in addition to the presentation on control animals in the NTP that Gordon Hard made at the public hearing, there have been previous studies from the NTP that suggested a similar finding, including Seely et al. (2002) and Travlos et al. (2011) In the IRIS draft report, it is specifically stated that the relevance to humans of CPN is unknown or remains unclear. This is based entirely on publications by Ronald Melnick and colleagues without any critical discussion of their presentation in those publications (2012; 2013). Again, this indicates to me a lack of critical evaluation of the quality of the publications rather than just accepting what is written and reporting it. There are several deficiencies of the Melnick et al. (2012; 2013) publications, most notably, that the evaluation was based on chemically treated rats, not controls, and the chemicals involved a broad range of modes of action, including genotoxicity. This is like comparing apples and watermelons. Whether CPN might have also contributed to the kidney tumor findings in these studies can be argued, particularly for well-known modes of action such as genotoxicity. In addition, there was no review of specific animals, and reliance only on reported information. Dr. Melnick clearly has confused the distinction between mode of action and mechanism. Although we do not know its specific mechanism of causation, CPN very clearly involves cytotoxicity and regeneration, a well-accepted mode of action for carcinogenesis. In the IRIS report, the issue of toxicity and

regeneration is also confused. In the IRIS reort, P. 1-28, it is stated tha the "study did not report cytotoxicity, however which, combined with the early time point makes unlikely that cell proliferation was compensatory." This statement is incorrect and reflects a lack of understanding of the pathology. CPN was accentuated. CPN by definition involves cytotoxicity (necrosis) and regeneration, and the increased proliferation occurs early. The increased proliferation is clearly "compensatory". The increased proliferation associated with CPN in response to the necrosis has been demonstrated in several reports, as early as 1989 (Konishi and Ward, 1989). Again, the diagnosis of CPN includes necrosis, even if the feature of necrosis is not separately listed. Necrosis and regenerative proliferation are characteristic features of CPN. In the papers referred to in the IRIS report that are contrary to this need to be examined for quality, as necrosis and increased proliferation, regeneration, are defining features of CPN.

What has become clear from the data presented by Dr. Hard at the public session as well as presented in Seely et al. (2002) and Travlos et al. (2011), is that the mean CPN score is not the key parameter, but rather, how many animals have the highest grades of CPN in a given study. In the report that Dr. Hard presented at the public hearing, those with the highest grade of CPN had a nearly 25% incidence of atypical tubular hyperplasia or adenomas, and these were in control animals that were not treated with any exogenous chemicals.

Furthermore, there was an increase in kidney weight in both the 13-week bioassay and in the 2-year bioassay. Increased kidney weight is a common finding with both α_{2u}-globulin and with CPN. It a non-specific finding, and by itself does not indicate anything that would be occurring in addition to α_{2u}-globulin nephropathy or CPN.

In summary, all of the changes identified in the kidneys of the rats in the 13-week and 2-year bioassays performed by NTP can be explained by α_{2u}-globulin nephropathyand CPN, with the addition of cortical-medullary calcification. None of these are relevant to humans, so there is no relevance of these kidney tumors to human cancer risk, and these should not be considered further for risk assessment, based on the mode of action/human relevance framework consideration and based on consideration of the 2005 US EPA Guidelines. Other modes of

action have been excluded, including genotoxicity, cytotoxicity apart from CPN and α_{2u}-globulin, or direct mitogenicity. The evidence is strong, reproducible, and biologically plausible.

I will also offer a few comments regarding the thyroid. Fundamentally, there was a minimal if any effect on tumor incidence in the thyroid of the mice. The only statistical significance based on $P < .05$ was for a trend, and incorporating survival into the evaluation. Dr. Joseph Haseman at the NTP promulgated a "rule" that for common tumors statistical significance should be at a P value less than .01, rather than .05 (Haseman, 1983). This is because of the high variability of incidences of common tumors. To help reduce the likelihood of false positives, he believed that the P value should be less than .01, rather than .05. This has been adopted internationally in the pharmaceutical industry and is incorporated into ICH Guidelines, which are used by the US FDA as well as other drug evaluation regulatory agencies around the world. It has also been utilized by other regulatory agencies in various parts of the world. If that is applied to the thyroid tumor data for TBA in mice, there is no statistically significant increased incidence of tumors. This would fit with the unusual dose response that was observed in this study, with the high-dose animals having a lower incidence than the mid-dose animals. Such variability could well occur based on the fact that this is a common tumor (defined by Haseman, a tumor occurring spontaneously in > 1% of control animals).

Even if statistically significant, the relevance of this finding to humans is likely to be negligible. That is because the known causes of thyroid follicular cancer in humans are radiation or inherited disorders such as multiple endocrine neoplasia (MEN). In rodent models of follicular carcinogenesis, if the chemical is non-genotoxic, the effect is due to decreased thyroid hormones resulting in TSH elevation and stimulation of proliferation of follicular cells. Hypothyroidism has been extensively evaluated in human populations and is essentially not related to the development of follicular cancer in humans. All of the non-genotoxic mechanisms in the animal models involve the decrease in circulating thyroid hormones with increasing TSH production whether it is due to a direct effect on the thyroid or an indirect effect by altering thyroid hormone metabolism in the liver.

In summary, TBA in the NTP bioassay in rats and mice showed an increased incidence of tumors in the male rat kidney by modes of action that are not relevant to humans. The increase in thyroid tumors in mice is marginal, at most, unlikely to be relevant to humans, and represents only an increase in benign tumors, not malignant carcinomas. Based on this information, it is reasonable to conclude that TBA is not carcinogenic for humans.

REFERENCES

Acharya, S., Mehta, K., Rodrigues, S., Pereira, J., Krishnan, S., Rao, C.V. (1995). Administration of subtoxic doses of t-butyl alcohol and trichloroacetic acid to male Wistar rats to study the interactive toxicity. Toxicol Lett 80(1): 97-104.

Acharya, S., Mehta, K., Rodrigues, S., Pereira, J., Krishnan, S., Rao, C.V. (1997). A histopathological study of liver and kidney in male Wistar rats treated with subtoxic doses of t-butyl alcohol and trichloroacetic acid. Exp Toxicol Pathol 49(5): 369-373.

Borghoff, S. J., Prescott,J.S., Janszen,D.B., Wong,B.A., Everitt,J.I. (2001). α2u-globulin nephropathy, renal cell proliferation, and dosimetry of inhaled *tert*-butyl alcohol in male and female F-344 rats. Toxicol Sci 61: 176-186.

Hard, G. C. and J. C. Seely (2005). Recommendations for the interpretation of renal tubule proliferative lesions occurring in rat kidneys with advanced chronic progressive nephropathy (CPN). Toxicol Pathol 33(6): 641-649.

Hard, G. C. and K. N. Khan (2004). A contemporary overview of chronic progressive nephropathy in the laboratory rat, and its significance for human risk assessment. Toxicol Pathol 32(2): 171-180.

Hard, G. C., Johnson, K. J., Cohen, S. M. (2009). A comparison of rat chronic progressive nephropathy with human renal disease-implications for human risk assessment. Crit Rev Toxicol 39(4): 332-346.

Hard, G. C., Bruner, R. H., Cohen, S. M., Pletcher, J. M., Regan, K. S. (2011). Renal histopathology in toxicity and carcinogenicity studies with tert-butyl alcohol administered in drinking water to F344 rats: a pathology working group review and re-evaluation. Regul Toxicol Pharmacol 59(3): 430-436.

Hard, G. C., Betz, L. J., Seely, J. C. (2012). Association of Advanced Chronic Progressive Nephropathy (CPN) with Renal Tubule Tumors and Precursor Hyperplasia in Control F344 Rats from Two-Year Carcinogenicity Studies. Toxicol Pathol 40(3): 473-481.

Hard, G. C., Banton, M. I., Bretzlaff, R. S., Dekant, W., Fowles, J. R., Mallett, A. K., McGregor, D. B., Roberts, K. M., Sielken, R. L., Jr., Valdez-Flores, C., Cohen, S. M. (2013). Consideration of rat chronic progressive nephropathy in regulatory evaluations for carcinogenicity. Toxicol Sci 132(2): 268-275.

Haseman, J. K. (1983). A reexamination of false-positive rates for carcinogenesis studies. Fundam Appl Toxicol 3(4): 334-339.

Konishi, N. and J. M. Ward (1989). Increased Levels of DNA Synthesis in Hyperplastic Renal Tubules of Aging Nephropathy in Female F344/NCr Rats. Vet Pathol Online 26(1): 6-10.

Melnick, R. L., Burns, K. M., Ward, J. M., Huff, J. (2012). Chemically exacerbated chronic progressive nephropathy not associated with renal tubular tumor induction in rats: an evaluation based on 60 carcinogenicity studies by the national toxicology program. Toxicol Sci 128(2): 346-356.

Melnick, R. L., Ward, J. M., Huff, J. (2013). War on Carcinogens: Industry Disputes Human Relevance of Chemicals Causing Cancer in Laboratory Animals Based on Unproven Hypotheses, Using Kidney Tumors as an Example. Int J Occup Environ Health 19(4): 255-260.

Seely, J. C., Haseman, Joseph K., Nyska, Abraham, Wolf, Douglas C., Everitt, Jeffrey I., Hailey, James R. (2002). The Effect of Chronic Progressive Nephropathy on the Incidence of Renal Tubule Cell Neoplasms in Control Male F344 Rats. Toxicol Pathol 30(6): 681-686.

Travlos, G. S., Hard, G. C., Betz, L. J., Kissling, G. E. (2011). Chronic progressive nephropathy in male f344 rats in 90-day toxicity studies: its occurrence and association with renal tubule tumors in subsequent 2-year bioassays. Toxicol Pathol 39(2): 381-389.

Comments to the Docket regarding the EPA IRIS Assessment on Tertiary-butyl alcohol (TBA)

Samuel M. Cohen, MD, PhD
Department of Pathology & Microbiology
University of Nebraska Medical Center
Omaha, NE 68198-3135

Following are comments regarding the recently published toxicological review of tert-butyl alcohol (tert-butanol) (CAS Mo. 75-65-0) which was published in June 2017. I was reviewer of the previous IRIS document as requested by the National Academy of Sciences. These comments are from myself, without support from any company or other individuals.

I have extensive experience in human and in animal pathology, including rats and mice, and I am still a practicing surgical pathologist. In addition, I have more than 50 years experience in experimental toxicology, carcinogenesis, and pathology research and have published extensively with nearly 400 publications in my career. I have received numerous honors for my achievements, notably the Lehman Award for excellence in risk assessment research from the Society of Toxicology, the Merit Award from the Society of Toxicology, the Lifetime Achievement Award from the Society of Toxicologic Pathology, and the Distinguished Scientist Award from the American College of Toxicology. I have served on numerous national and international committees and panels, including those from the NIH, NAS, IPCS, IARC, EPA, FDA, NTP and NIEHS, including serving on the Boards of Scientific Counselors of both the NTP and NIEHS at different times. I also serve on the FEMA Expert Panel for the evaluation of flavors, which evaluates the safety of flavor ingredients in foods. I have extensive experience in kidney pathology, and I have served on a number of pathology working groups involving kidney pathology, including the one organized for TBA.

TBA was evaluated in a National Toxicology Program (NTP, 1995) two year bioassay accompanying shorter term assays, in particular, a 90-day dose range finding study. An increased incidence of tumors was identified in the male rat kidney, with no increased tumor incidences in the female rat. In the male and female mouse, there was a slight increase in benign thyroid follicular tumors (adenomas) and follicular hyperplasia.

At the previous review held in June, 2016, the scientists involved in the production of the IRIS document were strongly recommended to seek expertise in pathology for review of the animal studies, in particular, those related to the kidney. It is striking to me that this advice has not been followed by the IRIS scientists. There is no pathologist listed in their assessment team, contributors to the document, the production team, or contractor support. In addition, I do not see any pathologists selected for the Scientific Advisory Board (SAB) that is reviewing this document, nor is pathology listed as one of the areas of expertise to be represented on the SAB. I believe this to be a significant deficiency, as my comments below will indicate. Many of these comments were made at my presentation and discussion at last year's review, as well as in my previous comments to the docket on TBA.

The kidney slides from the various studies performed in rats at the NTP were reviewed by a pathology working group (PWG) of which I was a member (Hard et al., 2011). It would appear that the IRIS report has discounted the findings of this PWG and are discounting the findings presented in the NTP report and in the extensive literature on the issues being evaluated (Hard et al., 2004; 2005; 2009; 2011; 2012; 2013; Seely et al., 2002; Travlos et al., 2011; Frazier et al., 2012). The key issues are whether the findings in the kidneys can be completely explained by changes involving α_{2u}-globulin nephropathy, chronic progressive nephropathy (CPN), and corticomedullary calcification. It would appear from the current IRIS document that they accept that the corticomedullary junction calcification is a common rat phenomenon and is not relevant to humans, so I will not discuss that further.

The IRIS document discusses at length the various aspects of α_{2u}-globulin nephropathy and CPN. Rather than focus on the pathology and biology related to the various manifestations of these two disease entities, they have resorted to a statistical analysis showing that certain pathologic findings were not due to either α_{2u}-globulin or CPN. The statistical analyses that have been performed are erroneous for a number of reasons. Primarily, both the numerators and denominators used in these calculations are incorrect. To begin with, the three features that they are focusing on are renal pelvic transitional hyperplasia, suppurative inflammation, and increased kidney weights. All three of these are manifestations of CPN (Frazier et al., 2012; NTP, 1995). However, the findings of suppurative inflammation and transitional cell hyperplasia occur only in higher grades of CPN, grade 3 and grade 4, not with the lower grades. Thus, to do statistical analyses involving all of the cases of CPN is incorrect. Furthermore, these statistical analyses are made on the presumption that the recordings of these findings are always listed by the pathologist reading these slides. This also is incorrect, since, depending on the pathologist and depending on the findings, they may not list all of the particular details involved with CPN, just lumping them together under the diagnosis of CPN. Thus, without going through the slides and reviewing them specifically, animal by animal for grade, and the specific changes that can occur with CPN, a statistical analysis is inappropriate and can be quite misleading.

It is important to understand the overall pathology and biology of CPN to make a proper assessment of the data. CPN is a common finding in rat kidney, with nearly all animals by 10 weeks of age having some degree of CPN, even involving a single nephron (Travlos et al., 2011; Frazier et al., 2012; Hard et al., 2011; 2013). Thus, incidences in a 13 week study, with the animals 6 to 8 weeks of age at the beginning of the study, or in a 2 year bioassay, will be nearly 100%. This is true in both males and females, but with greater severity in the males. Incidences less than this can be reported because many pathologists will ignore the very early signs of CPN when there is only involvement of only a few nephrons or there will be a sampling issue. Importantly, the well-defined features of CPN have been extensively delineated in the INHAND criteria published by the Society of Toxicologic Pathologists in 2012 (Frazier et al., 2012). The "earliest lesion detectible in young adults is a basophilic tubule or evidence of regeneration in outer kidney, but soon thereafter basophilia is accompanied by crowded nuclei and/or thickened basement membrane." The characteristic features of CPN include tubular basophilia, nuclear crowding, thickened basement membrane, hyaline casts, tubular atrophy, tubular dilitation, focal glomerular sclerosis, glomerular atrophy, mononuclear cell inflammatory infiltrate, transitional

cell hyperplasia of the renal pelvis lining (to be discussed in greater detail below), and interstitial fibrosis. Not all features will be present in every kidney affected with CPN, but depends on the grade of the disease which will be partly a reflection of age of the rat. An increase in kidney weight is a gross finding of CPN, and also α_{2u}-globulin. It is important to understand that some of these changes occur early and are characteristic of all cases of CPN, whereas others occur only in more advanced stages. Increased kidney weight is an early feature as is tubular basophilia with nuclear crowding and thickened basement membrane, the characteristic features of CPN. Not all of the features that I have just listed will be present in every case of CPN, and the study pathologists will not always record all of the individual features, but just note the diagnosis of CPN. What needs to be understood about the biology of CPN is that it is a degenerative disease with consequent regeneration, with a high rate of cell turnover. This has been repeatedly demonstrated (Frazier et al., 2012; Konishi and Ward, 1989). Thus, the extensive discussion in the IRIS report about lack of cell necrosis and cytotoxicity is erroneous, as these are a part of CPN by definition. This again reflects the way pathologists list the diagnoses. CPN is recorded, but the cytotoxicity, degeneration, and hyperplasia are frequently not listed separately since they are an integral part of CPN. This is another example of the fallacies of a statistical approach as used by IRIS, and again is a clear indication that they have not sought pathology expertise nor do they understand the biology and pathology of CPN. The basophilia and tubular hyperplasia that is characteristic of early as well as late CPN and are an indication of the proliferation, Furthermore, the proliferation is always in response to the degenerative changes that are occurring in the tubules in CPN.

Increased kidney weight and suppurative inflammation or chronic inflammation are part of CPN (Frazier et al., 2012). They are not specific findings to CPN, but if CPN is present, they will be assumed to be part of the CPN diagnosis unless there are other parts of the kidney not involved with CPN that show evidence of inflammation. This was specifically examined in the PWG review of the slides, and was found not to occur (Hard et al., 2011). Thus, all of the degenerative and proliferative changes in the kidney could be identified in areas that were involved with either CPN or α_{2u}-globulin nephropathy (see below). There was no area of the kidney that showed changes distinct from CPN or α_{2u}-globulin nephropathy. All of these findings were described in detail in the report and the publication of the PWG.

The IRIS report also tries to argue that the findings in the female involved a lack of tumors despite the findings of increased kidney weight, inflammation, and transitional cell hyperplasia. They argue that these occurred separately from the CPN. They further argue that these are independent because the degree of CPN in the females on average was similar to that seen in the males. What is critical to note is that the highest grade of CPN (grade 4) is much less common in the female than in the male (Hard et al., 2012; Frazier et al., 2012; NTP, 1995). Furthermore, the changes of more severe CPN occur earlier in the age of the male rat than in the female rat so that there is a greater chance for the proliferative changes seen with CPN to evolve into a tumor in the males than in the females.

The issue of transitional cell hyperplasia also needs to be specifically discussed. This is a finding that is associated with CPN (Frazier et al., 2012). This association is specifically stated in the NTP

report on TBA on p. 56 (NTP, 1995), a statement ignored by the IRIS authors. Unfortunately, it has been traditional amongst pathologists to classify the increased proliferation seen along the lining of the renal papillae as part of the kidney pelvis. This is inaccurate, and has been discussed in detail in the PWG report (Hard et al., 2011). True transitional cell (urothelial cell) hyperplasia occurs in the lining of the renal pelvis, which is separate from the kidney papillae. The true pelvis is an extension of the lower urinary tract including the ureters and urinary bladder (Murphy et al., 2004; Wu et al., 2009). The true kidney pelvis, ureters and urinary bladder are lined by an epithelium currently named the urothelium but was previously referred to as a transitional cell epithelium (Murphy et al., 2004; wu et al., 2009). Both terms are currently used, but the preferred terminology is urothelium or urothelial cell epithelium. This is a characteristic epithelium with a well-defined layered structure (Wu et al., 2009). This is not the epithelium that lines the kidney papillae (Hard et al., 2011). The lining of the kidney papillae (Figure 1) is generally cuboidal to slightly columnar, is a single cell layer, and does not have the characteristic proteins of the urothelium (uroplakins).

Figure 1. Modified from Hard et al., 2011, figure 5. Labeling in the figure has been added. Figure shows the renal papilla, the hyperplasia of the epithelial lining of the papilla, and the normal kidney pelvis.

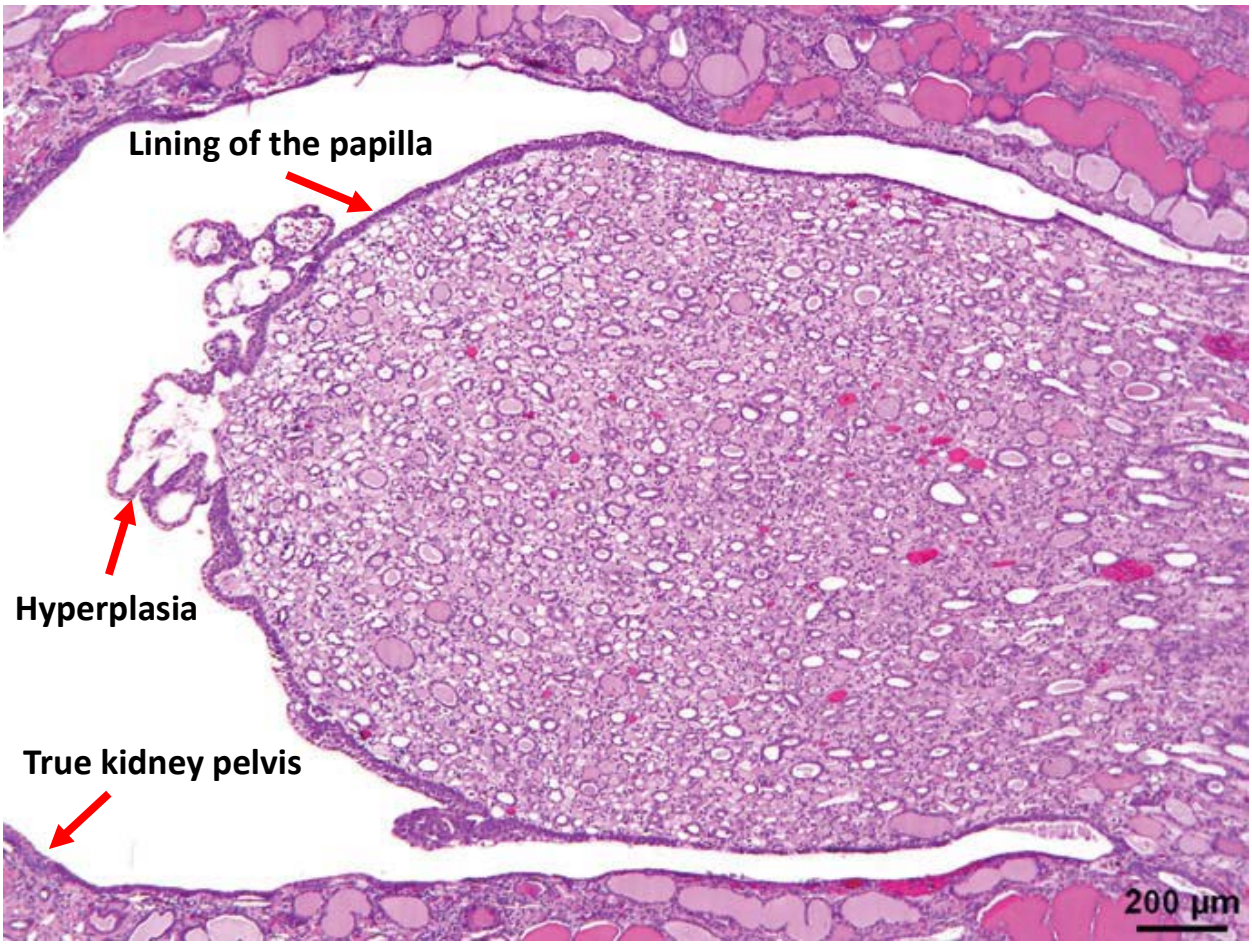

The proliferation that occurs in the lining of the papillae is a distinct form of "hyperplasia", is not a transitional (urothelial) cell hyperplasia of the kidney pelvis. The hyperplasia seen in the TBA study was entirely the proliferation of the lining of the renal papillae and was not proliferation of the true kidney pelvis (Figure 1). This was specifically examined in the PWG and is stated clearly in that report (Hard et al., 2011). What is important to understand is that this proliferation of the lining of the renal papillae is a finding of advanced CPN, usually grade 3 or grade 4. This is explicitly stated in the NTP report (NTP, 1995) on TBA on page 56; they indicate that this hyperplasia is a manifestation of CPN. It in no way is a reflection of a direct effect of the chemical on this epithelial lining, but rather, it is secondary to the CPN itself. It is also important to note that this type of proliferation does not occur in humans. I have never seen it in my career, and I have spoken with nephropathologists who also indicate that this type of proliferation has not been identified in humans. Furthermore, I cannot find reference to it in textbooks (Jennette et al., 2015; Taal et al., 2012) nor in a brief review of the recent nephropathology literature. Thus, even if the IRIS insists that this is an independent finding, it is irrelevant to humans. However, it is important to understand that this is not a separate finding from CPN in any circumstance in the TBA study, but is merely another manifestation of advanced CPN.

Suppurative inflammation is also a part CPN, primarily due to the degeneration of the tubules with an inflammatory reaction to the material from the lumen of the tubules or the cast-like material that can form. Again, this is not a direct effect of the chemical, but rather, is a consequence of advanced CPN, with greater likelihood of inflammation occurring as the more advanced stages of CPN are attained. This is also related to the chronic interstitial inflammatory infiltrate that is frequently seen in these end stage kidneys, along with fibrosis, which is the end stage of the inflammation.

In summary, all of the findings of increased kidney weight, suppurative inflammation, and transitional cell hyperplasia (actually hyperplasia of the papillae lining) are all manifestations with TBA of CPN, with the addition that the increased kidney weight could also be contributed to be by the α_{2u}-globulin nephropathy, which I will discuss below.

The relationship of CPN to the development of kidney tumors has been extensively examined utilizing NTP bioassay data. One would anticipate that CPN would lead to an increase in renal proliferative lesions including renal atypical hyperplasia and tumors, particularly adenomas, since it is a proliferative nephropathy. In general, the incidence is usually relatively low secondary to CPN, but can be higher. This was best illustrated by a study by Hard et al. (2012) which examined the control rats in a large number of 2 year bioassays from the NTP. He utilized an 8 grade system rather than the usual 4 grade system, but his grade 8 his generally equivalent to the grade 4 of the NTP classification. He was able to show that in males, 41 of 170 male rats that had the highest grades of CPN, had atypical hyperplasia or renal cell tumors (24.1%) and in the females, 1 of 6 animals with grade 8 CPN had atypical hyperplasia or tumors (16.7%). From this data, one can see a number of factors. First, the incidence of high grade CPN is much greater in male rats than in female rats. Secondly, with end stage CPN involving end stage kidney disease, there is a significant incidence of renal cell tumors. Because CPN is a proliferative disease, the increased incidence of tumors with the most advanced grades of this disease fits with what we know about

the relationship of increased cell proliferation and carcinogenesis. Similar findings supporting this relationship have also been reported by others, including an early report by Seely et al. (2002), but that study involved a smaller number of studies that were evaluated. It is important to note that the studies by Hard et al. (2012) and Seely et al. (2002) involved actual re-examination of the kidneys from these studies for both the diagnosis and grading of CPN as well as identification of atypical hyperplasia and tumors. They did not rely on the reports. It should be noted that the hyperplasia routinely seen with CPN is not considered atypical tubular hyperplasia, but is the more "typical" hyperplasia seen with tubules that is a characteristic feature of CPN, even in its early stages. It is only with the expansion of the proliferation that it becomes "atypical" and is classified as atypical tubular hyperplasia. It is the atypical tubular hyperplasia that evolves into adenomas. Adenomas occasionally evolve into carcinomas, but most of the lesions seen with CPN remain as either atypical tubular hyperplasia or adenomas. The specific criteria for these tumors have been well delineated in the INHAND classification document.

As has been evaluated extensively, CPN does not occur in humans and there is no analogous disease in humans. The numerous distinctions between chronic renal disease in humans versus CPN in rats has been described extensively by Hard et al. (2009). There is no doubt that CPN is not relevant to humans, and should not be included in a risk assessment for humans. Thus, all of the findings that have been attributed to CPN in the TBA study in the kidney, including increased kidney weight, suppurative inflammation and transitional cell hyperplasia, are related to CPN and are not relevant to humans.

There has been some controversy regarding the human relevance of tumors associated with CPN. The above discussion clearly shows that CPN can be the cause of renal cell atypical tubular hyperplasia and renal cell tumors. The evidence for this is overwhelming. Specific key events in the mode of action have been well-described by Hard et al. (2013). These include: 1) exposure to chemical (usually at high concentrations); 2) metabolic activation (if necessary); 3) exacerbated CPN, including increased number of rats with end stage renal disease; 4) increased tubule cell proliferation; 5) hyperplasia; and 6) adenoma (infrequently carcinoma) (see Figure 2). These key events are well-delineated, and fit with the IPCS and EPA framework for mode of action analysis in examination of human relevance (Sonich-Mullin et al., 2001; Meek et al., 2003; Seed et al., 2005; Boobis et al., 2006; 2008). Since CPN is not relevant to humans, the tumors associated with CPN are obviously not relevant to humans, either.

Figure 2. The modes of action for a α_{2u}-globulin nephropathy and CPN, both starting with cell loss (exfoliation in α_{2u}-globulin nephropathy and cytotoxicity or degeneration for CPN). α_{2u}-globulin nephropathy is induced by the binding of the chemical to α_{2u}-globulin, and its incorporation into the tubule cell lysosomes.

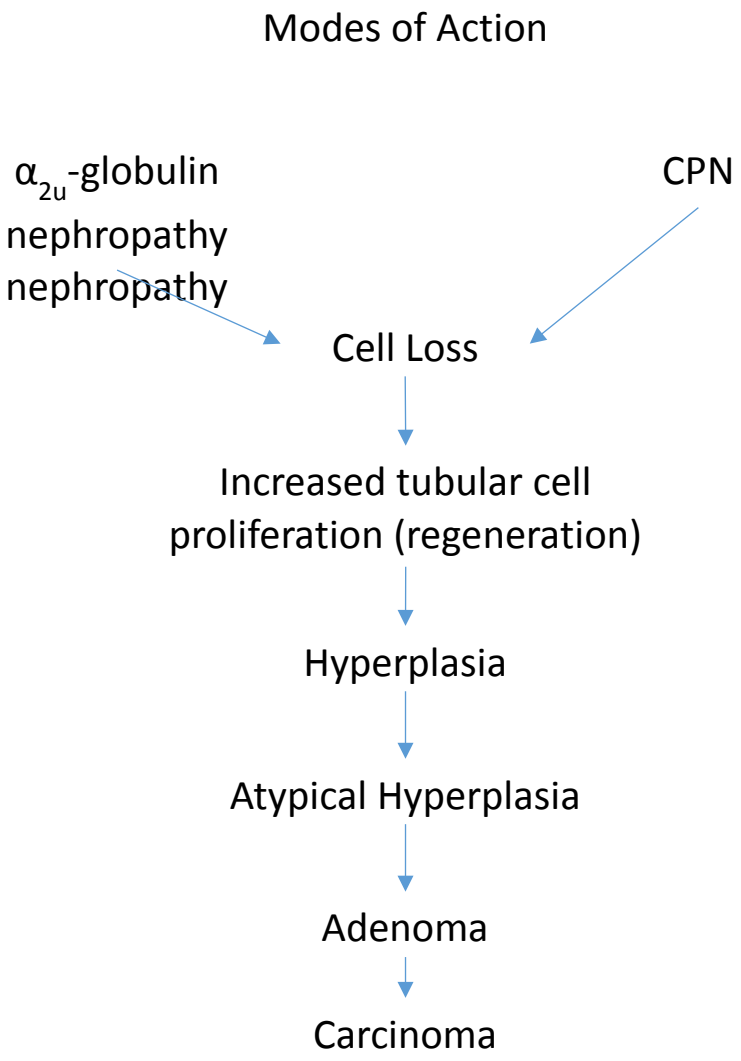

The IRIS document again brings up the arguments of Dr. Ronald Melnick in which he and his colleagues try to argue that CPN is not a mode of action and that the kidney tumors are relevant to humans (Melnick et al., 2012; 2013). There are numerous parts of Dr. Melnick's examination and discussion which are erroneous, as described in detail in Hard et al. (2013). To begin with, Melnick et al. (2012; 2013) confuse mode of action with mechanism of action. Mode of action requires an identification of identifiable key events that lead from the exposure to the chemical to the development of the apical endpoint, in this instance kidney tumors. This has been well met for CPN. This contrasts with mechanism of action where the molecular details would be known.

Obviously that is not known for CPN, nor is it known for most causes of cancer in animals or in humans, although progress is being made along these lines. Second of all, his statistical analyses are completely erroneous (Hard et al., 2013). To begin with, his analysis includes studies of chemicals for which well-known modes of action have been identified, including genotoxicity. To lump all of these together for an evaluation of CPN is clearly misleading and statistically not appropriate. Furthermore, the analysis does not evaluate specifically animals with end stage renal disease, which would have an increased incidence of renal tumors, rather than all stages of CPN, including early stages of CPN. Additionally, the studies that he incorporated in his analysis utilized various classification schemes for CPN, and different pathologists at different times have included different criteria in their overall diagnostic details for CPN. None of this is taken into account in his analysis, nor were any of the studies re-examined. It should be noted that Dr. Melnick is not a pathologist. Furthermore, this is the same Dr. Melnick (Melnick, 1992) that has argued that the mechanism for α_{2u}-globulin nephropathy-induced tumors is wrong despite a clear description of the fallacies of his argument (Borghoff et al., 1993). Furthermore, the MOA is widely accepted (IARC, 1999; Meek et al., 2003), including by the EPA and is delineated in the IRIS document for TBA, is wrong. He argues that they are relevant to humans. For the IRIS document to dwell and rely on the arguments by Dr. Melnick without a critical analysis is unacceptable. Particularly, when the details examining the Melnick publications have been delineated in Hard et al. (2013), which the IRIS document does not discuss.

The other issue is α_{2u}-globulin. The IRIS report delineates a great deal of detail regarding this issue, but appears to be stymied by a lack of casts being identified in the NTP report despite their being identified in the review by the PWG. The issue of casts is actually irrelevant. Although having casts or cast-like material present is helpful in the diagnosis (Frazier et al., 2012), there are other findings which clearly support the relationship of TBA to α_{2u}-globulin nephropathy (Hard et al., 2011). Most notably is the finding of linear mineralization in the 2 year study. This is a characteristic finding, although not pathognomonic, for α_{2u}-globulin nephropathy. Importantly, it indicates that there has been tubular degeneration over time with eventual calcification of the tubules, including the contents. Essentially, by definition, this indicates that cast-like material had to be present within the tubules at some point in the development of this mineralization possibly later than the 13 weeks of the shorter term study. It should be kept in mind that this mineralization is to be distinguished from the corticomedullary calcification described earlier, which is a common finding in rats, both male and female. The issue with α_{2u}-globulin that appears to be unclear to the writers of the IRIS document is that it involves cell loss. The writers of the IRIS document appear to be confused about the issue of toxicity and regeneration with regard to α_{2u}-globulin. It is not an issue of whether it is necrosis or not, but actually is related to cell loss. The characteristic finding of α_{2u}-globulin is the "exfoliation" of tubular cells into the lumen of the tubule. It is not known whether these are alive at the time of exfoliation or not. However, once they have fallen off into the tubular lumen, they will die and progress down the nephron. Over time, these accumulate and form the cast-like material, which over an even greater length of time undergo degenerative changes and become calcified, leading to the formation of the linear mineralization that is characteristic of α_{2u}-globulin nephropathy. Thus, one does not necessarily have to see tubular necrosis or even tubular cell degeneration for there to be cell loss. The important observation is that there is cell loss, and when there is cell loss, the tubule has to

proliferate to regenerate the lost cells. Thus, like CPN, this is an issue of degeneration (in this instance, cell loss) with regeneration (Borghoff et al., 2001). Thus, both α_{2u}-globulin nephropathy and CPN lead to an increase in cell proliferation, which over time leads to an increase in renal tumors (see Figure 2).

It is well-accepted, including by EPA, that α_{2u}-globulin nephropathy is not relevant to humans, and therefore, the tumors associated with α_{2u}-globulin nephropathy are not relevant to humans, and therefore the tumors associated with α_{2u}-globulin nephropathy are also not relevant to humans (IARC, 1999). This is a well-accepted conclusion by nearly everyone, except possibly Dr. Melnick.

Some concern was raised in the IRIS report that the incidence of tumors in the study with TBA in the male rat was higher than usually seen with α_{2u}-globulin or CPN. This is likely due to the fact that there would be expected to be a synergy between these two factors, since both increase cell proliferation. Furthermore, TBA is increasing the extent of CPN, including higher grades which are more likely to lead to tumor development. Since both α_{2u}-globulin nephropathy and CPN increase cell proliferation, there is a greater likelihood that tumors will evolve over time, particularly over the time of a 2 year bioassay. Since α_{2u}-globulin is a male rat specific phenomenon, the synergy between these two will only be seen in the male rat, and readily explains why there were tumors in the male rat and not in the female rat. Although tumors have been identified associated with CPN in female rats in other studies, these are very uncommon, largely due to the fact that very few female rats in the 2 year bioassay develop end stage renal disease as described above. One can readily develop a mode of action framework for the findings in the rat kidney that fully explain all of the findings (see Figure 2). All of the findings in the kidneys in the study with TBA, including those in the male and in the female can be attributed to corticumedullary calcification, α_{2u}-globulin nephropathy, or CPN. Since all three of these are not relevant to humans, none of the findings in the male or female rat kidneys in the TBA bioassay are relevant to humans and should not be used for risk assessment purposes, whether qualitative or quantitative.

The evidence that TBA is non-genotoxic is strong. This includes the NTP genotoxicity assays (NTP; 1995): the Ames assay, the mouse lymphoma cell assay, chromosomal aberration studies in CHO cells, and an *in vivo* micronucleus assay in mice. Those were uniformly negative. In the IRIS draft document, they mention a few other studies suggesting possible oxidative damage or reduced glutathione activities, particularly referencing the two publications by Acharya (1995; 1997). It is disturbing that the IRIS document described these papers without any critical analysis of the quality of the data in these papers. Both of these publications have severe limitations with respect to methodology, which raise serious questions as to the reliability of the data for consideration for risk assessment. To begin with, in the first paper, they describe a level of toxicity in the animals at a dose for which there was no toxicity seen in the NTP bioassay. Although it is unclear as to what this was due, there is a strong possibility that this was due to the animals being infected, possibly with *Helicobacter hepaticus.* The publications by Acharya describe possible liver toxicity, although it is unclear that this is actually present. Liver toxicity is not seen in the NTP publication on TBA. Furthermore, the histology is poorly presented, and the slides from the

kidneys actually show some degree of autolysis rather than necrosis. If the tissues were not fixed adequately, this would raise questions regarding the other studies that were performed. Liver toxicity is associated Helicobacter infections, and unless this was specifically analyzed for, it could well have been present. There is no statement with regard to the specific pathogen free (SPF) status of the animals, either at the time of purchase or the quality of the animal facility. In the 1990's, many of the laboratories in India where this study was performed, had complications with numerous infections in their animals. This would completely explain the findings that they were observing, so that it is unlikely that TBA was responsible for any of their findings. Furthermore, they do not describe whether or not the animals were randomized for placement in the groups, the number of animals per group was small (6), and there is no indication whether the evaluations were performed in a blinded fashion. Furthermore, they describe weight loss in the first paper. Although the animals were weighed in the second study, there is no description of the results. In addition, there is no pathologist involved in the evaluation of the histopathologic slide preparations.

Overall, TBA is clearly a non-genotoxic chemical. All of the findings in the kidney, including increased kidney weight, suppurative inflammation, and transitional cell hyperplasia, in both males and females, can be explained by CPN, α_{2u}-globulin nephropathy, and corticomedullary calcification. None of these disorders occur in humans, so none of these findings are relevant to humans. They therefore should not be used in a risk assessment.
In addition in the 2 year bioassay in mice, there was no evidence of changes in the kidneys, but there was a slight increase in the incidence of follicular cell thyroid tumors and hyperplasia. In pair wise comparisons, none of these were statistically significant. There was $p < .05$ for trend. This is a common tumor in mice (common is defined by Haseman (1983) as a spontaneous incidence of 1% or greater). Statistical significance has been recommended by Haseman at $p < .01$ rather than $< .05$ because of the wide variations that can occur in the incidence of these common tumors. This consideration of using $p < .01$ rather than .05 has been adopted internationally in the pharmaceutical industry and is incorporated into the ICH Guidelines. These guidelines are used by the US FDA and drug evaluation regulatory agencies around the world. It has also been used by agencies involved in other types of chemicals. Applying this rule to the thyroid tumors seen in the mouse study with TBA would indicate that this is not statistically significant, and thus there is no significant tumor incidence in the mice. Furthermore, although extensive studies have not been performed to evaluate the effects of TBA on thyroid and thyroid-related hormones, it is well known that in rats in particular, but also in mice, that the quantitative aspects of thyroid homeostasis differ between rodents and humans (Meek et al., 2003; IARC, 1999; Hill et al., 1989). This is largely because of the presence of thyroid-binding globulin in humans as well as a larger reserve of thyroid hormone in the follicle material of the thyroid itself. Furthermore, all of the modes of action that have been identified for non-genotoxic chemicals producing thyroid follicular tumors in rodents have involved hypothyroidism, TSH stimulation, and consequent increased cell proliferation of the follicle cells. This is true regardless of what causes the decrease in circulating thyroid hormone (T3 and/or T4), whether due to increased metabolism of the circulating thyroid hormone or direct thyrotoxicity, the end result is an increase in pituitary secretion of TSH and consequent increase of thyroid follicular proliferation and ultimately tumors. However, extensive epidemiology studies have been performed in

humans examining various types of hypothyroidism, including iodine deficiency, and there does not appear to be any relationship between hypothyroidism and an increase in follicular thyroid tumors in humans. The only known carcinogen for the human thyroid is radiation. Thus, there is no statistical significance in the incidence of thyroid tumors in the mice, and even if there was, the findings would not be relevant to humans.

REFERENCES

Acharya, S., Mehta, K., Rodrigues, S., Pereira, J., Krishnan, S., Rao, C.V. (1995). Administration of subtoxic doses of t-butyl alcohol and trichloroacetic acid to male Wistar rats to study the interactive toxicity. Toxicol Lett 80(1): 97-104.

Acharya, S., Mehta, K., Rodrigues, S., Pereira, J., Krishnan, S., Rao, C.V. (1997). A histopathological study of liver and kidney in male Wistar rats treated with subtoxic doses of t-butyl alcohol and trichloroacetic acid. Exp Toxicol Pathol 49(5): 369-373.

Boobis, A. R., Cohen, S. M., Dellarco, V., McGregor, D., Meek, M. E., Vickers, C., Willcocks, D., Farland, W. (2006). IPCS framework for analyzing the relevance of a cancer mode of action for humans. Crit. Rev. Toxicol. 36(10): 781-792.

Boobis, A. R., Doe, J. E., Heinrich-Hirsch, B., Meek, M. E., Munn, S., Ruchirawat, M., Schlatter, J., Seed, J., Vickers, C. (2008). IPCS framework for analyzing the relevance of a noncancer mode of action for humans. Crit. Rev. Toxicol. 38(2): 87-96.

Borghoff, S. J., Lehman-McKeeman, L.D., Shor, B.G., Hard, G.C., Swenberg, J.A. (1993). Critique of R. Melnick's An alternative hypothesis on the role of chemically induced protein droplet (□2u-globulin) nephropathy in renal carcinogenesis. Regul. Toxicol. Pharmacol. 18: 357-364.

Borghoff, S. J., Prescott,J.S., Janszen,D.B., Wong,B.A., Everitt,J.I. (2001). α2u-globulin nephropathy, renal cell proliferation, and dosimetry of inhaled *tert*-butyl alcohol in male and female F-344 rats. Toxicol Sci 61: 176-186.

Frazier, K. S., Seely, J. C., Hard, G. C., Betton, G., Burnett, R., Nakatsuji, S., Nishikawa, A., Durchfeld-Meyer, B., Bube, A. (2012). Proliferative and nonproliferative lesions of the rat and mouse urinary system. Toxicol. Pathol. 40(4 Suppl): 14S-86S.

Hard, G. C. and J. C. Seely (2005). Recommendations for the interpretation of renal tubule proliferative lesions occurring in rat kidneys with advanced chronic progressive nephropathy (CPN). Toxicol Pathol 33(6): 641-649.

Hard, G. C. and K. N. Khan (2004). A contemporary overview of chronic progressive nephropathy in the laboratory rat, and its significance for human risk assessment. Toxicol Pathol 32(2): 171-180.

Hard, G. C., Johnson, K. J., Cohen, S. M. (2009). A comparison of rat chronic progressive nephropathy with human renal disease-implications for human risk assessment. Crit Rev Toxicol 39(4): 332-346.

Hard, G. C., Bruner, R. H., Cohen, S. M., Pletcher, J. M., Regan, K. S. (2011). Renal histopathology in toxicity and carcinogenicity studies with tert-butyl alcohol administered in drinking water to F344 rats: a pathology working group review and re-evaluation. Regul Toxicol Pharmacol 59(3): 430-436.

Hard, G. C., Betz, L. J., Seely, J. C. (2012). Association of Advanced Chronic Progressive Nephropathy (CPN) with Renal Tubule Tumors and Precursor Hyperplasia in Control F344 Rats from Two-Year Carcinogenicity Studies. Toxicol Pathol 40(3): 473-481.

Hard, G. C., Banton, M. I., Bretzlaff, R. S., Dekant, W., Fowles, J. R., Mallett, A. K., McGregor, D. B., Roberts, K. M., Sielken, R. L., Jr., Valdez-Flores, C., Cohen, S. M. (2013). Consideration of rat chronic progressive nephropathy in regulatory evaluations for carcinogenicity. Toxicol Sci 132(2): 268-275.

Haseman, J. K. (1983). A reexamination of false-positive rates for carcinogenesis studies. Fundam Appl Toxicol 3(4): 334-339.

Hill, R. N., Erdreich,L. S., Paynter,O. E., Roberts,P. A., Rosenthal,S. L., Wilkinson,C. F. (1989). Thyroid follicular cell carcinogenesis. Fundam. Appl. Toxicol. **12**: 629-697.

IARC (1999). Consensus Report. International Agency for Research on Cancer. IARC Scientific Publications 147: 1-32.

Jennette, J. C., Olson, J. L., Silva, F. G., and D'Agati, V. D. Heptinstall's Pathology of the Kidney, Vol. 1 & 2, 2015.

Konishi, N. and J. M. Ward (1989). Increased Levels of DNA Synthesis in Hyperplastic Renal Tubules of Aging Nephropathy in Female F344/NCr Rats. Vet Pathol Online 26(1): 6-10.

Meek, M. E., Bucher, J. R., Cohen, S. M., Dellarco, V., Hill, R. N., Lehman-McKeeman, L. D., Longfellow, D. G., Pastoor, T., Seed, J., Patton, D. E. (2003). A framework for human relevance analysis of information on carcinogenic modes of action. Crit. Rev. Toxicol. 33(6): 591-653.

Melnick, R. L. (1992). An alternative hypothesis on the role of chemically induced protein droplet (2u-globulin) nephropathy in renal carcinogenesis. Regul. Toxicol. Pharmacol. 16: 111-125.

Melnick, R. L., Burns, K. M., Ward, J. M., Huff, J. (2012). Chemically exacerbated chronic progressive nephropathy not associated with renal tubular tumor induction in rats: an evaluation based on 60 carcinogenicity studies by the national toxicology program. Toxicol Sci 128(2): 346-356.

Melnick, R. L., Ward, J. M., Huff, J. (2013). War on Carcinogens: Industry Disputes Human Relevance of Chemicals Causing Cancer in Laboratory Animals Based on Unproven Hypotheses, Using Kidney Tumors as an Example. Int J Occup Environ Health 19(4): 255-260.

Murphy, W. M., Grignon, D. J., and Perlman, E. J. Tumors of the Kidney, Bladder and Related Urinary Structures. AFIP Atlas of Tumor Pathology, Series 4, Vol. 1, 2004, p. 241-362.

National Toxicology Program (NTP). Toxicology and Carcinogenic Studies of A-Butyl Alcohol in F344/N Rats and B6C3F1 Mice. NTP Technical Report Series No. 436, 1995.

Seed, J., Carney, E. W., Corley, R. A., Crofton KM., DeSesso, J. M.,Foster, P.M. and R. Kavlock, Kimmel, G,Klaunig, J., Meek, M. E., Preston, R. J., Slikker, W., Jr., Tabacova, S, William, G.M. (2005). Overview: Using Mode of Action and Life Stage Information to Evaluate the Human Relevance of Animal Toxicity Data. Crit. Rev. Toxicol. 35: 663-672.

Seely, J. C., Haseman, Joseph K., Nyska, Abraham, Wolf, Douglas C., Everitt, Jeffrey I., Hailey, James R. (2002). The Effect of Chronic Progressive Nephropathy on the Incidence of Renal Tubule Cell Neoplasms in Control Male F344 Rats. Toxicol Pathol 30(6): 681-686.

Sonich-Mullin,C., Fielder,R., Wiltse,J., Baetcke,K., Dempsey,J.,Fenner-Crisp,P., Grant,D., Hartley,M., Knaap,A., Kroese,D., Mangelsdorf,I., Meek,E., Rice,J.M., Younes,M. (2001). IPCS Conceptual Framework for Evaluating a Mode of Action for Chemical Carcinogenesis. Regul. Toxicol. Pharmacol. 34: 146-152.

Taal, M. W., Chertow, G. M., Marsden, P. A., Skorecki, K., Yu, A. S. L., and Brenner, B. M. Brenner and Rector's The Kidney. Ninth Edition, Vol., 1 & 2, 2012.

Travlos, G. S., Hard, G. C., Betz, L. J., Kissling, G. E. (2011). Chronic progressive nephropathy in male f344 rats in 90-day toxicity studies: its occurrence and association with renal tubule tumors in subsequent 2-year bioassays. Toxicol Pathol 39(2): 381-389.

Wu, X., Kong, X. P., Pellicer, A., Kreibicvh, G, Sun, T. T. Uroplakins in urothelial biology, function, and disease. Kidney Int. 75(11): 1153-1165.

Comments to the Docket regarding the EPA IRIS Assessment on ETBE

Samuel M. Cohen, MD, PhD
Department of Pathology & Microbiology
University of Nebraska Medical Center
Omaha, NE 68198-3135

Following are comments regarding the recently published toxicological review of Ethyl tert-butyl ether (ETBE) (CAS RN 637-92-3) which was published in June 2017. I was a participant in the PWG reported as Cohen et al., (2011). These comments are from myself, without support from any company or other individuals.

I have extensive experience in human and in animal pathology, including rats and mice, and I am still a practicing surgical pathologist. In addition, I have more than 50 years of experience in experimental toxicology, carcinogenesis, and pathology research and have published extensively with nearly 400 publications in my career. I have received numerous honors for my achievements, notably the Lehman Award for excellence in risk assessment research from the Society of Toxicology, the Merit Award from the Society of Toxicology, the Lifetime Achievement Award from the Society of Toxicologic Pathology, and the Distinguished Scientist Award from the American College of Toxicology. I have served on numerous national and international committees and panels, including those from the NIH, NAS, IPCS, IARC, EPA, FDA, NTP and NIEHS, including serving on the Boards of Scientific Counselors of both the NTP and NIEHS at different times. I also serve on the FEMA Expert Panel for the evaluation of flavors, which evaluates the safety of flavor ingredients in foods. I have extensive experience in kidney pathology, and I have served on a number of pathology working groups involving kidney pathology, including the one organized for ETBE.

Ethyl tert-butyl ether (ETBE) is the subject of a draft toxicological review by IRIS. In the review last year, the authors of the ETBE draft document were strongly encouraged to seek pathology expertise in reviewing the material. This obviously has not been done. There is no pathologist listed in their assessment team, contributors to the document, the production team, or contractor support. In addition, I do not see any pathologists selected for the Scientific Advisory Board (SAB) that is reviewing this document, nor is pathology listed as one of the areas of expertise to be represented on the SAB. Many of the comments that I am making regarding ETBE I have made in my comments regarding tert-butyl alcohol (TBA), and I refer the EPA to those comments, rather than repeat them in detail here.

For ETBE, the issues are kidney changes in the rat, particularly in males, and the increased incidence of liver tumors in rats treated with ETBE. Ultimately, none of the findings regarding the kidney nor the liver tumors are relevant to human risk, and therefore, should not be incorporated into a risk assessment for ETBE. The centriloblular hypertrophy of the liver could be relevant to humans so could be used for risk assessment purposes. I will first address the changes in the kidney, which are non-cancer, and then address the issue of liver toxicity and tumors.

As with TBA, the authors for the IRIS document have completely misinterpreted the pathology findings regarding the kidney and their relationship to chronic progressive nephropathy (CPN). I have written about these changes in detail in the document for TBA, and I refer the reader to those comments. However, let me address some of the specifics regarding ETBE. It is very likely that the changes in the kidneys secondary to ETBE are related to its metabolism to TBA. Since the exposure to TBA would be less than the direct administration of TBA, it is not surprising that the changes are less severe and do not result in tumors.

Findings regarding alpha2u-globulin nephropathy are detailed in the PWG report on ETBE (Cohen et al., 2011). The changes are consistent with alpha2u-globulin nephropathy, are male specific, and are not relevant to humans. Details regarding the findings for CPN and ETBE are also detailed in that PWG report.

The pathologic findings related to CPN have been extensively delineated in INHAND criteria published by the Society of Toxicologic Pathologists in 2012 (Frazier et al., 2012). The characteristic histopathologic features of CPN in include tubular basophilia, nuclear crowding, thickened basement membrane, hyaline casts, tubular atrophy, tubular dilitation, focal glomerular sclerosis, glomerular atrophy, inflammatory infiltrate, transitional cell hyperplasia of the renal pelvis lining (to be discussed in greater detail below), and interstitial fibrosis (Frazier et al., 2012). Not all features will be present in every kidney affected with CPN, but depends on the grade of the disease which will partly be a reflection of age of the rat. An increase in kidney weight is a gross finding related to CPN, as well as α_{2u}-globulin, and is a non-specific finding regarding many forms of kidney toxicity in rodents. As the disease progresses, renal function decreases leading to an increase in BUN and creatinine levels, and ultimately, if it progresses to end-stage kidney, and results in uremia.

The IRIS authors have chosen to separate several manifestations of the kidney changes as separate entities from CPN, including urothelial hyperplasia, increased blood concentrations of total cholesterol, BUN, and creatinine, and increased kidney weight. These are all manifestations of CPN (or combined with α_{2u}-globulin), and cannot be separated. The statistical approaches described by IRIS are inappropriate for several reasons as detailed in my TBA comments. The changes in urothelial hyperplasia and the blood levels of BUN and creatinine will only occur in the more severe grades of CPN, and thus are not usually present in earlier grades, such as grade 1 or 2. Important to note for the evaluation is that the pathologist will not always record all of the features separately in their list of diagnoses but will lump them together under CPN, or might delineate one or more of the specific changes. Thus, without going through a specific review of the slides to list each of the features for individual animals, a statistical comparison cannot be made.

It should be noted that the increased levels of BUN and creatinine are a manifestation of end-stage kidney disease. These are usual features with high grades of CPN, which is increasing in incidence and severity over time in many of the rat strains that are used for tumor bioassays. This is particularly true for the F344 rat, and has led to the termination of the use of that strain by the NTP because of the marked increase in mortality secondary to renal failure secondary to CPN.

The issue of transitional cell hyperplasia also needs to be specifically discussed. This is a finding that is associated with CPN (Frazier et al., 2012). This association is specifically stated in the NTP report on TBA on p. 56 (NTP, 1995), a statement ignored by the IRIS authors. Unfortunately, it has been traditional amongst pathologists to classify the increased proliferation seen along the lining of the renal papillae as part of the kidney pelvis. This is inaccurate, and has been discussed in detail in the PWG report on TBA (Hard et al., 2011) and the PWG report on ETBE (Cohen et al., 2011). True transitional cell (urothelial cell) hyperplasia occurs in the lining of the renal pelvis, which is distinct from the kidney papillae. The true pelvis is an extension of the lower urinary tract, including the ureters and urinary bladder (Murphy et al., 2004; Wu et al., 2009). The true kidney pelvis, ureters and urinary bladder are lined by an epithelium currently named the urothelium but was previously referred to as a transitional cell epithelium (Murphy et al., 2004; wu et al., 2009). Both terms are currently used, but the preferred terminology is urothelium or urothelial cell epithelium. This is a characteristic epithelium with a well-defined layered structure (Wu et al., 2009). This is not the epithelium that lines the kidney papillae (Hard et al., 2011). The lining of the kidney papillae (Figure 1) is generally cuboidal to slightly columnar, is a single cell layer, and does not have the characteristic proteins of the urothelium (uroplakins).

Figure 1. Modified from Hard et al., 2011, figure 5. Labeling in the figure has been added. Figure shows the renal papilla, the hyperplasia of the epithelial lining of the papilla, and the normal kidney pelvis.

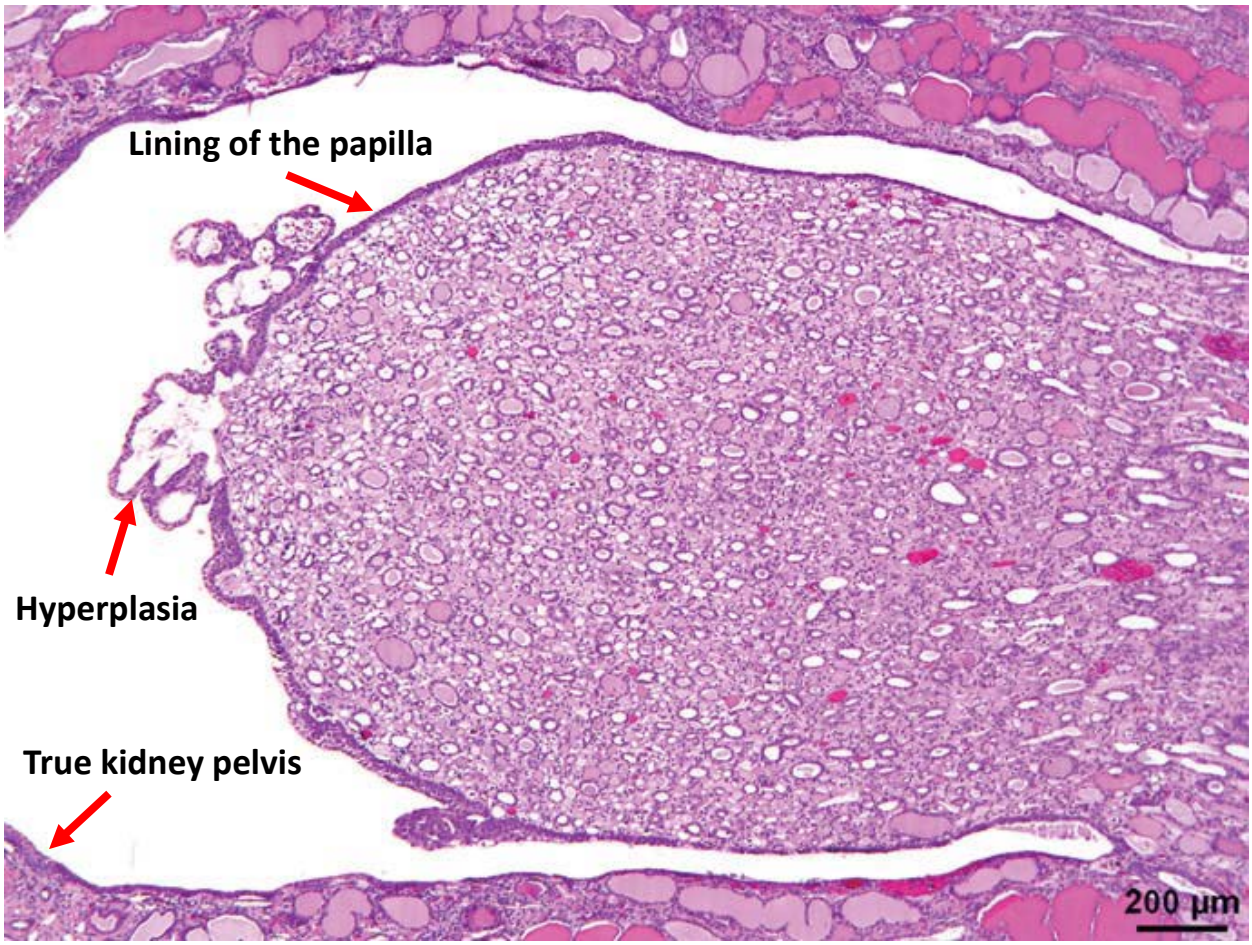

The proliferation that occurs in the lining of the papillae is a distinct form of "hyperplasia", is not a transitional (urothelial) cell hyperplasia of the kidney pelvis. The hyperplasia seen in the TBA study was entirely the proliferation of the lining of the renal papillae and was not proliferation of the true kidney pelvis (Figure 1). This was specifically examined in the PWG and is stated clearly in that report (Hard et al., 2011). This is also the "renal pelvis hyperplasia" in the ETBE studies which described in the PWG report on ETBE (Cohen et al. 2011). What is important to understand is that this proliferation of the lining of the renal papillae is a finding of advanced CPN, usually grade 3 or grade 4. It in no way is a reflection of a direct effect of the chemical on this epithelial lining, but rather, it is secondary to the CPN itself. It is also important to note that this type of proliferation does not occur in humans. I have never seen it in my career, and I have spoken with nephropathologists who also indicate that this type of proliferation has not been identified in humans. Furthermore, I cannot find reference to it in nephropathology textbooks (Jennette et al., 2015; Taal et al., 2012) nor in a brief review of the recent nephropathology literature. Thus, even if the IRIS insists that this is an independent finding, it is irrelevant to humans. However, it is important to understand that this is not a separate finding from CPN in any circumstance in the TBA or ETBE studies, but is merely another manifestation of advanced CPN.

Most importantly, CPN in rats is not relevant to humans (Hard and Seely, 2005; Hard and Khan, 2004; Hard et al., 2009; 2011; 2012; 2013; Seely et al., 2002; Travlos et al., 2011). The IRIS document continues to cite the contrary opinion of Melnick et al., (2012; 2013), but do not mention the numerous deficiencies of his data and arguments as delineated in detail in Hard et al. (2013). All of the kidney findings in the ETBE studies can be explained by CPN and α_{2u}-globulin which are not relevant to humans, and therefore should not be used for human risk assessment.

It is also known that the changes of CPN are more extensive and appear earlier in the male rat compared to the female rat. Furthermore, there are similar changes in male and female mice with similar pathologic and clinical manifestations, but the extent is generally not as frequent or as severe as in the rat. Thus, the rat has greater changes than the mouse, and the male has changes greater than the female regarding CPN in rats or CPN-like changes in mice.

In summary, all of the kidney changes that are described in the IRIS report regarding the kidney can be attributed to CPN and α_{2u}-globulin nephropathy. This includes increased kidney weight, urothelial hyperplasia (actually hyperplasia of the kidney papilla lining), and increased blood concentrations of total blood cholesterol, BUN and creatinine. Since CPN is not relevant to humans, these findings described by IRIS in response to ETBE administration also are not relevant to humans. As has been extensively evaluated, CPN does not occur in humans and there is no analogous disease in humans. The numerous distinctions between chronic renal disease in humans versus CPN in rats has been described extensively by Hard et al. (2009). Without doubt, CPN is not relevant to humans and should not be included in a risk assessment for humans. Thus, all of the findings that have been attributed to CPN in the ETBE study involving the kidney are related to CPN and are not relevant to humans and should not be used in a risk assessment.

The discussion regarding findings in the liver also reflect a significant lack of pathology expertise by the writers of this document. They report on the bioassays of ETBE which have been performed by gavage, water administration, and by inhalation. The indication is that there was an increased incidence of tumors in male rats only, and only in the gavage study and in the

inhalation study. In the inhalation study, there was only a slight increase in adenomas, but not carcinomas. Administration in the water study was completely negative, and all studies were negative in female rats. These results suggest a weak effect at most with respect to the liver.

The IRIS document tries to explain the possible modes of action that could be involved with ETBE-induced liver tumors, but get lost in their understanding of the pathology and with respect to mode of action analysis. They indicate that the finding of centrilobular hypertrophy of the liver is seen only in the shorter term studies but not in the two year bioassays, indicating that this is a transient effect and likely not related to the tumorigenic finding. This goes against an extensive literature discussing various modes of action that produce centrilobular hypertrophy and ultimately liver tumors. It has been clearly shown that centrilobular hypertrophy occurs early in the life span of the animals, and usually is not detectable at the two year time point largely because of the extensive changes that are present in the liver. This has been discussed in detail by Dr. Robert Maronpot (Maronpot et al., 2010), a renowned authority in liver histopathology who was the head of the pathology branch of the National Toxicology Program for many years. Numerous authors have actually argued that this reflects an adaptive response rather than an adverse response (Hall et al., 2012). Furthermore, a lack of comprehensive evaluation of not only the pathology but an understanding of modes of action related to centrilobular hypertrophy is reflected by the fact that they do not even cite the publication by Corton et al. (2014), which provided an extensive analysis of the mode of action for CAR activated tumorigenesis in the liver. This is disturbing because Dr. Corton is an EPA scientist and led the team of international scientists that developed the mode of action analysis on PPARα that was published in 2014. Undoubtedly, the centrilobular hypertrophy was related to one of the nuclear receptors, CAR, PXR, or PPARα, which are well-known to produce centrilobular hypertrophy early in the course of treatment, for some chemicals within days. Evidence for activation of these receptors has been published by various authors (e.g. Kakehashi et al., 2013). These are associated with an increase in liver weight early in the course of the experiment, and with the eventual development of liver tumors in the two year bioassay. The amount of data presented in the IRIS document clearly shows that one or more of these receptors are affected. Centrilobular hypertrophy is related to activation of these receptors, and the centrilobular hypertrophy is related to the eventual development of these liver tumors.

The IRIS document also suggests that because there is a lack of complete correlation between the finding of centrilobular hypertrophy in different studies by different routes of administration and the ultimate development of tumors, it can't be related to the development of the tumors. This reflects a distinct lack of understanding of the relationship of these findings, and a relationship to toxicokinetics and changes over time. Most importantly, although the metabolic changes related to CAR, PXR, and PPARα occur in humans at high doses of exposure to these chemicals, the human liver does not respond to activation of these receptors with an increase in cell proliferation, which is a central key event to the mode of action in the animal models for these tumors (Corton et al., 2014; Elcombe et al., 2014).

Increased hepatocyte proliferation in addition to activation of these receptors and centrilobular hypertrophy have been demonstrated (Kakehashi et al., 2015). PPARα has been accepted as a mode of action that is not relevant to humans and most organizations accept CAR and PXR

activation (frequently together) as also not relevant to humans. Epidemiology study with drugs that act by these mechanisms (fibrates for PPARα activation and phenobarbital and various anti-anxiety drugs for CAR activation) have consistently not shown a relationship to an increase in tumor formation, even at doses that are similar in the human compared to the animal studies.

A lack of understanding of the overall mode of action approach to evaluation is evident in some of the comments made in the IRIS documents, as has been an issue for IRIS documents in the past (Guyton et al., 2009). For example, one of the statements that they make (page 1-53) is that data gaps exist and a lack of information regarding gap junctions and clonal expansion are cited as examples. Gap junction communication loss is not considered one of the key events in the mode of action, but rather is considered an associative of that event (Corton et al., 2014; Elcombe et al., 20174). The issue of clonal expansion refers primarily to the appearance of foci, but is clearly present if there is development of adenomas and/or carcinomas, since these are clonal expansions of liver cells, as are the foci. Difficulties of the IRIS program with use of mode of action data has been addressed previously (Meek et al., 2008). There is a well-established framework for evaluation of mode of action in animals and human relevance (Sonich-Mullen et al., 2001; Meek et al., 2003; Seed et al., 2005; Boobis et al., 2006; 2008) that is incorporated into EPA's cancer guidelines and is also used for non-cancer toxicities. Scientists from numerous governmental agencies participated in development of this framework, including scientists from EPA, and at least for pesticide evaluations in EPA-OPP registrants are required to use it in their presentations to the Agency.

The IRIS document also refers to an investigation by Maltoni et al. (1999). They delineate the serious flaws in that study, which were corroborated by a peer review of that study by a number of pathologists from the United States, including individuals from the National Toxicology Program (Malarkey et al., 2011). Fundamentally, the Maltoni et al. studies have a poor quality of pathology, have not been peer reviewed (prior to the Malarkey et al. review), and are significantly complicated by the presence of pneumonia in all of the animals in the facility. There are also numerous other deficiencies. This study should not be considered for any risk assessment. As an example, the European Food Safety Authority (EFSA) has refused to consider any of the publications from the Ramazzini Institute because of significant deficiencies in the study design and execution.

The IRIS document also refers to studies by Hagiwara et al. (2011; 2013; 2015) in which ETBE is administered after pretreatment with a number of DNA reactive carcinogens. These models should be considered carefully, since they have not been validated. Most importantly, IRIS does not provide a critical analysis of these studies. The study involving the administration of five different DNA reactive carcinogens before treatment with ETBE (Hagiwara et al., 2011) is particularly suspect. This is primarily because of the extensive variability in the incidence of tumors in this model when the animals are treated only with these five DNA reactive chemicals, without a subsequent test chemical, such as ETBE. This variability makes interpretation of the results extremely difficult, if not impossible. For example, in the five chemical initiation study (Hagiwara et al., 2011) there is an increased incidence of urinary bladder tumors, but in the study specifically looking at the BBN model without the other 4 DNA reactive chemicals showed no effect by ETBE (Hagiwara et al., 2013). In addition, in the five chemical initiation study, they

reported forestomach tumors (Hagiwara et al., 2011). Forestomach tumors are not relevant to humans, so it is unclear why the IRIS document does not address this lack of relevance any further. The effects on the thyroid are probably the most variable in the five chemical study.In the experiment in which the animals were initiated with N-ethyl-N-(2-hydroxyethyl)nitrosamine (EHEN) there is an increase in liver tumor and kidney tumors (Hagiwara et al., 2051). This is not surprising since ETBE by itself slightly increased the incidence of liver tumors. Any chemical that by itself produces an increased incidence of tumors will also be positive in such a two-stage initiation/promotion assay. The finding of kidney tumors suggests that in this model, at least, ETBE is metabolized adequately to TBA leading to a possible increase in kidney tumors.

In summary, the liver tumors are slightly increased with ETBE, are present in only one sex, and are variable depending on the route of administration. Based on the information available, it is likely that the mode of action involves activation of a nuclear receptor, reflected in the development of centrilobular hypertrophy, with the ultimate slight increase in liver tumors, primarily adenomas. This mode of action and these tumors are not relevant to human risk assessment. If a quantitative extrapolation to human risk regarding non-cancer findings is to be performed, one could use the centrilobular hypertrophy as a potential risk to humans as a non-cancer finding, since this is likely to occur in humans with any of these three nuclear receptors. This is in contrast to the lack of human relevance of any of the kidney findings.

In summary, there is no human relevant cancer finding with ETBE. The non-cancer kidney findings with ETBE are not relevant to humans, but the centrilobular hypertrophy that is seen with ETBE in the liver is potentially relevant to humans, but will be a high dose phenomenon only.

REFERENCES

Boobis, A. R., Cohen, S. M., Dellarco, V., McGregor, D., Meek, M. E., Vickers, C., Willcocks, D., Farland, W. (2006). IPCS framework for analyzing the relevance of a cancer mode of action for humans. Crit. Rev. Toxicol. 36(10): 781-792.

Boobis, A. R., Doe, J. E., Heinrich-Hirsch, B., Meek, M. E., Munn, S., Ruchirawat, M., Schlatter, J., Seed, J., Vickers, C. (2008). IPCS framework for analyzing the relevance of a noncancer mode of action for humans. Crit. Rev. Toxicol. 38(2): 87-96.

Cohen, S.M.; Hard, G.C., Regan, K.S., Seely, J.C., Bruner, R.H. (2011) Pathology working group review of selected histopathologic changes in the kidneys of rats assigned to toxicology and carcinogenicity studies of ethyl tertiary butyl ether (ETBE): Japan Bioassay Research Center studies no.: 0065 and 0691 [Unpublished report] (pp. 1-30). Research Triangle Park, NC: Research Pathology Associates under contract to Lyondell Chemical Company.

Corton, J. C., Cunningham, M. L., Hummer, B. T., Lau, C., Meek, B., Peters, J. M., Popp, J. A., Rhomberg, L., Seed, J., Klaunig, J. E. (2014). Mode of action framework analysis for receptor-mediated toxicity: The peroxisome proliferator-activated receptor alpha (PPARalpha) as a case study. Crit. Rev. Toxicol. 44(1): 1-49.

Elcombe, C. R., Peffer, R. C., Wolf, D. C., Bailey, J., Bars, R., Bell, D., Cattley, R. C., Ferguson, S. S., Geter, D. ,Goetz, A., Goodman, J. I., Hester, S., Jacobs, A., Omiecinski, C. J., Schoeny, R., Xie, W., Lake, B. G. (2014). Mode of action and human relevance analysis for nuclear receptor-mediated liver toxicity: A case study with phenobarbital as a model constitutive androstane receptor (CAR) activator. Crit. Rev. Toxicol. 44(1): 64-82.

Frazier, K. S., Seely, J. C., Hard, G. C., Betton, G., Burnett, R., Nakatsuji, S., Nishikawa, A., Durchfeld-Meyer, B., Bube, A. (2012). Proliferative and nonproliferative lesions of the rat and mouse urinary system. Toxicol. Pathol. 40(4 Suppl): 14S-86S.

Guyton, K. Z., Chiu, W. A., Bateson, T. F., Jinot, J., Scott, C. S., Brown, R. C., Caldwell, J. C. (2009). A Reexamination of the PPAR-α Activation Mode of Action as a Basis for Assessing Human Cancer Risks of Environmental Contaminants. Environ. Health Perspect. 117(11): 1664-1672.

Hall, A. P., Elcombe, C. R., Foster, J. R., Harada, T., Kaufmann, W., Knippel, A., Kuttler, K., Malarkey, D. E., Maronpot, R. R., Nishikawa, A., Nolte, T., Schulte, A., Strauss, V., York, M. J. (2012). Liver hypertrophy: a review of adaptive (adverse and non-adverse) changes--conclusions from the 3rd International ESTP Expert Workshop. Toxicol. Pathol. 40(7): 971-994.

Hagiwara, A., Doi, Y., Imai, N., Nakashima, H., Ono, T., Kawabe, M., Furukawa, F., Tamano, S., Nagano, K., Fukushima, S. (2011). Medium-term multi-organ carcinogenesis bioassay of ethyl tertiary-butyl ether in rats. Toxicology 289(2–3): 160-166.

Hagiwara, A., Imai, N., Doi, Y., Suguro, M., Kawabe, M., Furukawa, F., Nagano, K., Fukushima, S. (2013). No Promoting Effect of Ethyl Tertiary-butyl Ether (ETBE) on Rat Urinary Bladder Carcinogenesis Initiated with N-Butyl-N-(4-hydroxybutyl)nitrosamine. J. Toxicol. Pathol. 26(4): 351-357.

Hagiwara, A., Doi, Y., Imai, N., Suguro, M., Kawabe, M., Furukawa, F., Tamano, S., Nagano, K., Fukushima, S. (2015). Promotion of liver and kidney carcinogenesis by ethyl tertiary-butyl ether (ETBE) in male Wistar rats. J. Toxicol. Pathol. 28(4): 189-195.

Hard, G. C. and Khan, K. N. (2004). A contemporary overview of chronic progressive nephropathy in the laboratory rat, and its significance for human risk assessment. Toxicol. Pathol. 32(2): 171-180.

Hard, G. C. and Seely, J. C. (2005). Recommendations for the interpretation of renal tubule proliferative lesions occurring in rat kidneys with advanced chronic progressive nephropathy (CPN). Toxicol. Pathol. 33(6): 641-649.

Hard, G. C. and Khan, K. N. (2004). A contemporary overview of chronic progressive nephropathy in the laboratory rat, and its significance for human risk assessment. Toxicol. Pathol. 32(2): 171-180.

Hard, G. C., Johnson, K. J., Cohen, S. M. (2009). A comparison of rat chronic progressive nephropathy with human renal disease-implications for human risk assessment. Crit. Rev. Toxicol. 39(4): 332-346.

Hard, G. C., Bruner, R. H., Cohen, S. M., Pletcher, J. M., Regan, K. S. (2011). Renal histopathology in toxicity and carcinogenicity studies with tert-butyl alcohol administered in drinking water to F344 rats: a pathology working group review and re-evaluation. Regul. Toxicol. Pharmacol. 59(3): 430-436.

Hard, G. C., Betz, L. J., Seely, J. C. (2012). Association of Advanced Chronic Progressive Nephropathy (CPN) with Renal Tubule Tumors and Precursor Hyperplasia in Control F344 Rats from Two-Year Carcinogenicity Studies. Toxicol. Pathol. 40(3): 473-481.

Hard, G. C., Banton, M. I., Bretzlaff, R. S., Dekant, W., Fowles, J. R., Mallett, A. K., McGregor, D. B., Roberts, K. M., Sielken, R. L., Jr., Valdez-Flores, C., Cohen, S. M. (2013). Consideration of rat chronic progressive nephropathy in regulatory evaluations for carcinogenicity. Toxicol. Sci. 132(2): 268-275.

Jennette, J. C., Olson, J. L., Silva, F. G., and D'Agati, V. D. Heptinstall's Pathology of the Kidney, Vol. 1 & 2, 2015.

Kakehashi, A., Hagiwara, A., Imai, N., Nagano, K., Nishimaki, F., Banton, M., Wei, M., Fukushima, S., Wanibuchi, H. (2013). Mode of action of ethyl tertiary-butyl ether hepatotumorigenicity in the rat: Evidence for a role of oxidative stress via activation of CAR, PXR and PPAR signaling pathways. Toxicol. Appl. Pharmacol. 273(2): 390-400.

Kakehashi, A., Hagiwara, A., Imai, N., Wei, M., Fukushima, S., Wanibuchi, H. (2015). Induction of cell proliferation in the rat liver by the short-term administration of ethyl tertiary-butyl ether. J. Toxicol. Pathol. 28(1): 27-32.

Malarkey, D. E., Bucher, J. R. (2011). Summary of the National Toxicology Program and Environmental Protection Agency-sponsored review of pathology materials from selected Ramazzini Institute rodent cancer bioassays [NTP]. Research Triangle Park: National Toxicology Program.

Maltoni, C., Bepoggi, F., Soffritti, M., Minardi, F. (1999). Comprehensive long-term experimental project of carcinogenicity bioassays on gasoline oxygenated additives: plan and first report of results from the study on ethyl-tertiary-butyl ether (ETBE). Eur. J. Oncol. 4: 493-508.

Maronpot, R. R., Yoshizawa, K., Nyska, A., Harada, T., Flake, G., Mueller, G., Singh, B., Ward, J. M. (2010). Hepatic enzyme induction: histopathology. Toxicol. Pathol. 38(5): 776-795.

Meek, M. E., Bucher, J. R., Cohen, S. M., Dellarco, V., Hill, R. N., Lehman-McKeeman, L. D., Longfellow, D. G., Pastoor, T., Seed, J., Patton, D. E. (2003). A framework for human relevance analysis of information on carcinogenic modes of action. Crit. Rev. Toxicol. 33(6): 591-653.

Meek, M. E., Bucher, J. R., Cohen, S. M., Dellarco, V., Hill, R. N., Lehman-McKeeman, L. D., Longfellow, D. G., Pastoor, T., Seed, J., Patton, D. E. (2003). A framework for human relevance analysis of information on carcinogenic modes of action. Crit. Rev. Toxicol. 33(6): 591-653.

Meek, M. E., Berry, C., Boobis, A. R., Cohen, S. M., Hartley, M., Munn, S., Olin, S., Schlatter, J., Vickers, C. (2008). Re: Guyton, Kathryn Z., Barone, Stanley, Jr., Brown, Rebecca C., Euling, Susan Y., Jinot, Jennifer, Makris, Susan (2008). Mode of action frameworks: a critical analysis. Journal of Toxicology and Environmental Health, Part B, 11(1): 16-31. J. Toxicol. Environ. Health. B. Crit. Rev. 11(8): 681-683; author reply 684-685.

Melnick, R. L., Burns, K. M., Ward, J. M., Huff, J. (2012). Chemically exacerbated chronic progressive nephropathy not associated with renal tubular tumor induction in rats: an evaluation based on 60 carcinogenicity studies by the national toxicology program. Toxicol. Sci. 128(2): 346-356.

Melnick, R. L., Ward, J. M., Huff, J. (2013). War on Carcinogens: Industry Disputes Human Relevance of Chemicals Causing Cancer in Laboratory Animals Based on Unproven Hypotheses, Using Kidney Tumors as an Example. Int. J. Occup. Environ. Health 19(4): 255-260.

Murphy, W. M., Grignon, D. J., and Perlman, E. J. Tumors of the Kidney, Bladder and Related Urinary Structures. AFIP Atlas of Tumor Pathology, Series 4, Vol. 1, 2004, p. 241-362.

National Toxicology Program (NTP). Toxicology and Carcinogenic Studies of A-Butyl Alcohol in F344/N Rats and B6C3F1 Mice. NTP Technical Report Series No. 436, 1995.

Seed, J., Carney, E. W., Corley, R. A., Crofton KM., DeSesso, J. M.,Foster, P.M. and R. Kavlock, Kimmel, G,Klaunig, J., Meek, M. E., Preston, R. J., Slikker, W., Jr., Tabacova, S, William, G.M. (2005). Overview: Using Mode of Action and Life Stage Information to Evaluate the Human Relevance of Animal Toxicity Data. Crit. Rev. Toxicol. 35: 663-672.

Seely, J. C., Haseman, Joseph K., Nyska, Abraham, Wolf, Douglas C., Everitt, Jeffrey I., Hailey, James R. (2002). The Effect of Chronic Progressive Nephropathy on the Incidence of Renal Tubule Cell Neoplasms in Control Male F344 Rats. Toxicol. Pathol. 30(6): 681-686.

Sonich-Mullin,C., Fielder,R., Wiltse,J., Baetcke,K., Dempsey,J.,Fenner-Crisp,P., Grant,D., Hartley,M., Knaap,A., Kroese,D., Mangelsdorf,I., Meek,E., Rice,J.M., Younes,M. (2001). IPCS Conceptual Framework for Evaluating a Mode of Action for Chemical Carcinogenesis. Regul. Toxicol. Pharmacol. 34: 146-152.

Taal, M. W., Chertow, G. M., Marsden, P. A., Skorecki, K., Yu, A. S. L., and Brenner, B. M. Brenner and Rector's The Kidney. Ninth Edition, Vol., 1 & 2, 2012.

Travlos, G. S., Hard, G. C., Betz, L. J., Kissling, G. E. (2011). Chronic progressive nephropathy in male f344 rats in 90-day toxicity studies: its occurrence and association with renal tubule tumors in subsequent 2-year bioassays. Toxicol. Pathol. 39(2): 381-389.

Wu, X., Kong, X. P., Pellicer, A., Kreibicvh, G, Sun, T. T. Uroplakins in urothelial biology, function, and disease. Kidney Int. 75(11): 1153-1165.

Check for updates

Original Manuscript

Toxicologic Pathology
1-7
© The Author(s) 2018
Reprints and permission:
sagepub.com/journalsPermissions.nav
DOI: 10.1177/0192623318762694
journals.sagepub.com/home/tpx
SAGE

Epithelium Lining Rat Renal Papilla: Nomenclature and Association with Chronic Progressive Nephropathy (CPN)

Nathália P. Souza[1,2], Gordon C. Hard[3], Lora L. Arnold[1], Kirk W. Foster[1], Karen L. Pennington[1], and Samuel M. Cohen[1,4]

Abstract

Chronic progressive nephropathy (CPN) occurs commonly in rats, more frequently and severely in males than females. High-grade CPN is characterized by increased layers of the renal papilla lining, designated as urothelial hyperplasia in the International Harmonization of Nomenclature and Diagnostic Criteria classification. However, urothelium lining the pelvis is not equivalent to the epithelium lining the papilla. To evaluate whether the epithelium lining the renal papilla is actually urothelial in nature and whether CPN-associated multicellularity represents proliferation, kidney tissues from aged rats with CPN, from rats with multicellularity of the renal papilla epithelium of either low-grade or marked severity, and from young rats with normal kidneys were analyzed and compared. Immunohistochemical staining for uroplakins (urothelial specific proteins) was negative in the papilla epithelium in all rats with multicellularity or not, indicating these cells are not urothelial. Mitotic figures were rarely observed in this epithelium, even with multicellularity. Immunohistochemical staining for Ki-67 was negative. Papilla lining cells and true urothelium differed by scanning electron microscopy. Based on these findings, we recommend that the epithelium lining the papilla not be classified as urothelial, and the CPN-associated lesion be designated as vesicular alteration of renal papilla instead of hyperplasia and distinguished in diagnostic systems from kidney pelvis urothelial hyperplasia.

Keywords

renal papilla epithelium, urothelium, hyperplasia, proliferation, chronic progressive nephropathy

Based on the general view that the mucosal surfaces of the collecting ducts, calyces, pelvis, ureter, bladder, and urethra all have the same embryologic origin, it is widely held that the term *urothelium* applies to the lining epithelium of all of these parts of the kidney and lower urinary tract (Miyazaki and Nishiyama 2017), including the lining of the renal papilla. However, at a more detailed level, the collecting system (collecting ducts, calyces, pelvis, and ureter) develops by successive branching of the distal portion of the ureteric bud. In contrast, the urothelial lining of the bladder and urethra derive from the cloacal endoderm via the urogenital sinus (Song and Yosypiv 2011). The epithelium lining the outer surface of the renal papilla is an extension of the cuboidal epithelium of the distal collecting ducts, which under normal conditions, is a single-cell layer. The true kidney pelvis begins at the fornices of the kidney papilla and transitions rapidly from a single-cell layer to a multilayered, stratified epithelium with the typical appearance of urothelium (Korshid and Moffat 1974; Silverblatt 1974). The urothelium is highly specialized, with a single basal layer, one to a few layers of intermediate cells, and superficially, characteristic umbrella-like cells that are large, thin, and polygonal (Hicks, Ketterer, and Warren 1974; Pauli, Alroy, and Weinstein 1983). Tight junctions hold the superficial cell layer together as a major barrier to the urine. The luminal membrane of the urothelial superficial cells is composed of a series of plaques and ridges. Ultrastructurally, the luminal membrane is typified by an asymmetric unit membrane and, internally, by fusiform vesicles (Hicks, Ketterer, and Warren 1974; Pauli, Alroy, and Weinstein 1983). The

[1] Department of Pathology and Microbiology, University of Nebraska Medical Center, Omaha, Nebraska, USA
[2] São Paulo State University (UNESP), Botucatu Medical School, Department of Pathology, Center for the Evaluation of the Environmental Impact on Human Health (TOXICAM), Botucatu, São Paulo, Brazil
[3] Private Consultant, Tairua, New Zealand
[4] Havlik-Wall Professor of Oncology

Corresponding Author:
Samuel M. Cohen, Department of Pathology and Microbiology, University of Nebraska Medical Center, 983500 Nebraska Medical Center, Omaha, NE 68198, USA.
Email: scohen@unmc.edu

luminal membrane of the urothelium consists of highly specialized, protective plaques, composed of uroplakins, which are membranous glycoproteins unique to urothelium (Jacobs et al. 1976; Wu et al. 2009; Lee 2011). Although the urothelium by light microscopy and the luminal surface ultrastructurally is similar from kidney pelvis to urethra, the uroplakin content differs along with its expandability, reflecting the different embryonic origins of the different parts of the urinary tract (Wu et al. 2009).

In contrast to this typical multicellular layering of the urothelium, the lining epithelium of the papilla is a single layer of regularly shaped cuboidal cells lacking an asymmetric unit membrane and fusiform vesicles (Korshid and Moffat 1974). By scanning electron microscopy (SEM), the cells lining the renal papilla have a luminal surface showing microvilli and microplicae, not the plaques and peaked ridges of urothelium (Carroll et al. 1974; Andrews and Porter 1974; Bulger, Siegel, and Pendergrass 1974). Also, there is no evidence of single cilia typically seen on the luminal surface of collecting duct cells (Carroll et al. 1974; Andrews and Porter 1974; Bulger et al. 1974). This particular mucosal lining is relevant to an emerging controversy that has regulatory implications for the risk assessment of chemicals exacerbating chronic progressive nephropathy (CPN), a common renal disease in rats (Hard, Johnson, and Cohen 2009; Hard et al. 2011, 2013). CPN is a recognized confounder of renal pathology interpretation in subchronic and chronic toxicity bioassays (Wolf and Mann 2005), particularly in male rats, which are more severely affected than females. One of the many morphologic changes that typify advanced CPN in chronic bioassays is the appearance of multicellularity of the renal papilla lining, which has traditionally been diagnosed as *urothelial hyperplasia* (Frazier et al. 2012) or *transitional epithelial (cell) hyperplasia* (National Toxicology Program 2007). In this communication, we question the classification of this lesion regarding both urothelial and hyperplastic, based on light microscopic, scanning electron microscopic, and immunohistochemical investigations.

Materials and Method

Animals for Light Microscopic Evaluation of Serial Sections of End-stage CPN

Hematoxylin and eosin (H&E)-stained serial sections of left and right kidneys (sectioned at 5 μm intervals for a distance of 0.25 mm) were reexamined from four F344 male rats with end-stage CPN from a previous 2-year bioassay (Hard and Seely 2005) to trace the nature and extent of renal papillary lesions associated with CPN of advanced severity. For each of the 4 rats, one kidney was sectioned transversely, and the other was sectioned sagittally. This assessment was supported by more than 20 years of experience evaluating rat kidneys with advanced CPN.

Animals for Immunohistochemistry and SEM

Eight untreated male F344 rats from a previous study (Cohen et al. 1995) and seven untreated male Sprague-Dawley rats used as breeders in a previous protocol (unpublished) were used in the present study. The respective protocols were approved by the University of Nebraska Medical Center Institutional Animal Care and Use Committee. At sacrifice, F344 rats were 133 to 135 weeks old (aged rat group), and Sprague-Dawley rats were 10 to 15 weeks old (young rat group). All eight F344 rats and five of the seven Sprague-Dawley rats were used for immunohistochemistry; the other two Sprague-Dawley rats were used for SEM evaluation.

Study Design for Evaluation of Lining of Kidney Papilla

Kidney tissue was fixed in 10% phosphate-buffered formalin, dehydrated, and embedded in paraffin by standard procedures. Kidney tissue from all of the aged F344 rats had a diagnosis of CPN, of which four had a severe grade (grade 4) CPN, accompanied by the typical CPN-related papilla lining alteration diagnosed previously as "urothelial hyperplasia." The remaining four aged F344 rats had CPN of low-grade severity, usually grade 2, without the renal papilla lining alteration. All kidneys from the five young Sprague-Dawley rats were graded as normal, that is, CPN grade 0. The differentiation of the papilla lining epithelium in both young and aged male rats was assessed by immunohistochemical staining for uroplakins, proteins that are specific for urothelium (Wu et al. 2009). The proliferation rate of the renal papilla lining was assessed by Ki-67 immunohistochemical staining (Wood et al. 2015) and by evaluation of H&E-stained kidney tissue for the presence of mitotic figures.

Uroplakins and Ki-67 Immunohistochemistry

Kidney sections from young and aged rats were used for immunohistochemical detection of uroplakins or Ki-67. Urinary bladder and intestinal tissue were used as positive controls for uroplakins and Ki-67, respectively. The stratified, nonpapillary renal pelvis lining served as an internal control for uroplakins, and the tubules in the renal parenchyma served as an internal control for Ki-67 labeling. Briefly, after deparaffinization of the sections and exposure of the slides to 3% H_2O_2 for 20 min to quench endogenous peroxidase activity, heat-induced antigen retrieval was performed in 0.01 M citrate buffer, pH 6.0, using a pressure cooker for 5 min. One percent nonfat milk was used to block nonspecific staining. Sections were immunostained using polyclonal rabbit total bovine uroplakin antibody (gift from Dr. Tung-Tien Sun, NYU School of Medicine, New York, NY), diluted 1:200, or monoclonal mouse anti-rat Ki-67 antibody (Dako, Carpenteria, CA), diluted 1:25, overnight at 4°C. Secondary antibody incubation was performed either with anti-rabbit IgG (for uroplakin) or anti-mouse IgG (for Ki-67) diluted 1:200 for 1 hr followed by incubation using the avidin–biotin–peroxidase complex (ABC) for

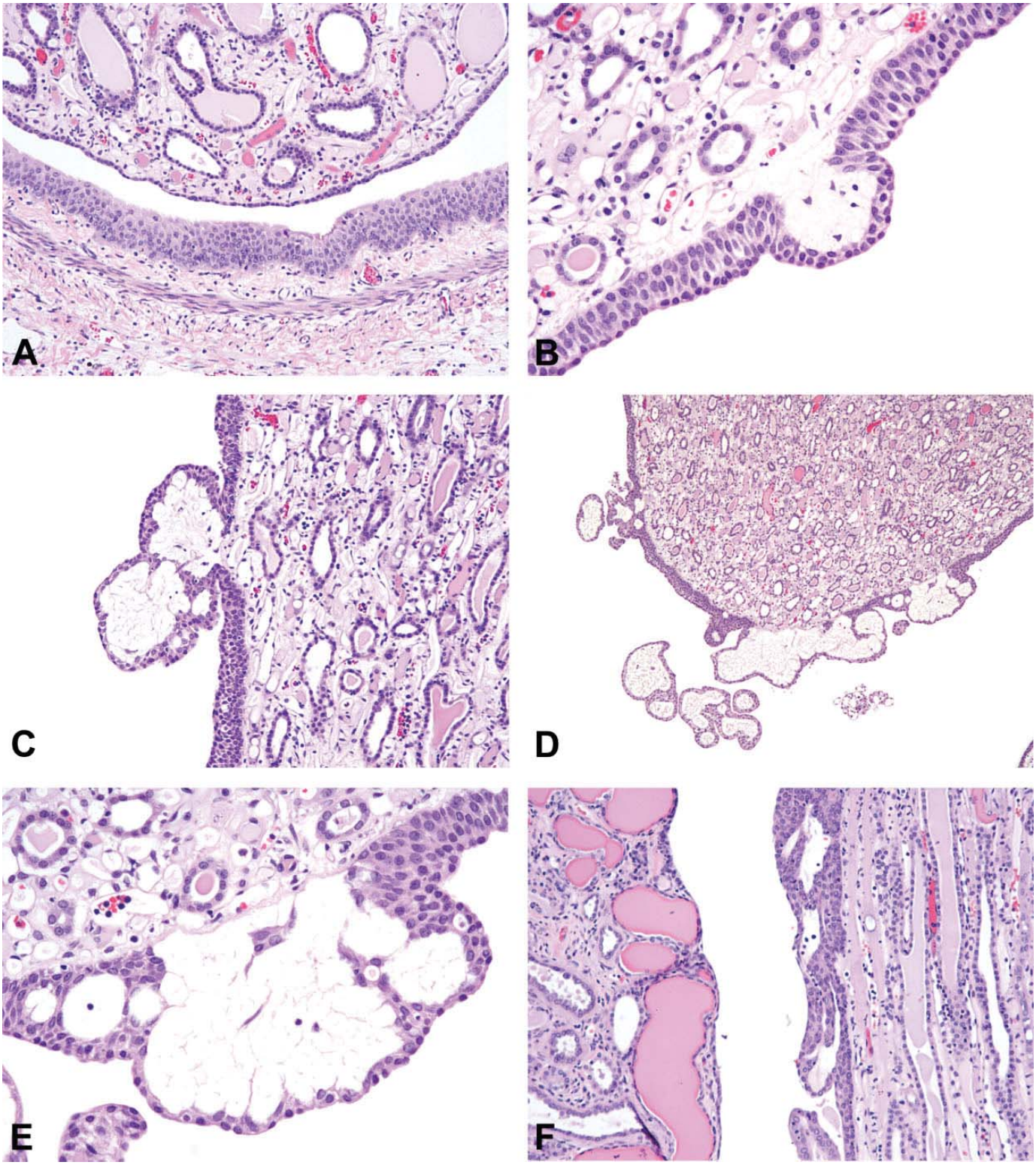

Figure 1. (A). Renal papilla (top) with single-cell layer lining epithelium contrasted to the multilayered true kidney pelvis urothelium (bottom). (B) At their edge, chronic progressive nephropathy (CPN)-associated lesions commence and end as a blister-like or vesicular, outpouching of the papilla lining. The apparently thickened papilla lining is likely accentuated by tangential sectioning. (C) A papillary lesion becoming complex, with two apparent vesicles. The loose interior of each vesicle is structureless, containing a reticulum of wispy, poorly staining material. The epithelial lining is a single layer, with multiple layers extending to the adjoining papilla. (D). Typical complex vesicular lesion at the papilla tip consisting of several vesicular profiles, most lined by a single epithelial layer. (E) Higher magnification of part of the lesion in (D). The outer lining of

45 min (Vectastain Elite ABC kit, Vector Laboratories, Burlingame, CA). Positive reactions resulted in brown cytoplasmic staining for uroplakins or brown nuclear staining for Ki-67 using DAB (3,3′-diaminobenzidine) as the substrate (DAB substrate kit, Vector Laboratories). Uroplakin and Ki-67 staining were assessed as negative or positive.

SEM Evaluation

Kidney tissue from two of the seven young Sprague-Dawley rats was fixed in Trump's fixative, dehydrated through an ascending series of ethanol concentrations (EtOH; 50–100%) followed by 1:1 100% EtOH and hexamethyldisilazane (HMDS) and 100% HMDS. The tissue was coated with gold prior to examination by SEM, and analysis was performed using a Quanta 200 Scanning Electron Microscope (FEI Company, Hillsboro, OR, USA).

Results

Morphology of Renal Papilla Alteration in End-stage Rat Kidney

Of the four F344 rats with serially sectioned end-stage CPN-affected kidney, three of the four sagittal sections had no renal papilla in the section. One sagittal section had a detached stump representing the lower quarter of the papilla including the papilla tip. The four transverse sections all included some papilla, but in two cases, this comprised only the proximal third arising from the medulla. Two rats had a reasonable representation of the length of the papilla along with the distal third of papilla from a sagittal section; thus, three papillary specimens provided information on CPN-related papillary lesions.

The CPN-associated papilla lining lesions tended to involve the lower half of the papilla and not the upper half. If the papilla section included only the proximal third of the papilla (which is often the case in practice), no CPN-related papillary lesions were observed.

From the serial sections of the three papilla specimens, there were approximately 15 individual lesions that were tracked at 5-μm intervals in one direction from the point of sectioning. In contrast to the normal smooth epithelial lining of the papilla and the smooth multilayered urothelium of the kidney pelvis (Figure 1A), the papilla lining lesions were small, blister-like outpouchings or vesicular hollow protrusions from the lining into the pelvis lumen (Figures 1B). The lining epithelium of many of these vesicles retained the appearance of a single-cell layer (Figures 1C–E), but in some, multicellularity appeared to be associated with collapse of the vesicle, or was a result of tangential sectioning of the vesicle wall (Figure 1E and F). Tracking along the serial sections, many lesions became complex and multilocular, but in all cases, the lesion eventually disappeared or remained a simple vesicle. There was no progression beyond this vesicular appearance and no evidence of proliferative hypercellularity. As the edge of a disappearing vesicle was approached, the vesicle wall assumed a multicellular, solid appearance, but this was due to tangential sectioning of a curved surface. The vesicles were devoid of histologically identifiable contents, except for very pale wisps of structureless material, a scattering of small dense nuclei, and a rare macrophage or fibroblast. In one vesicular lesion, there was hemorrhage, which persisted through many serial sections. An occasional mitotic figure was observed in the papilla lining, but rarely in the vesicle walls. Also, there was no evidence of inflammation in any papillary lining lesion.

Uroplakin Staining

The epithelial cells lining the nonpapillary parts of the renal pelvis were positive for cytoplasmic uroplakin staining in all kidney samples. No cytoplasmic uroplakin staining was observed in the epithelium lining the length of the papilla in any of the rats, whether young or old, or whether affected by advanced CPN papilla lining lesions or not (Figure 2A–C).

Ki-67 Staining and Mitotic Figures

No nuclear staining was observed for Ki-67 in the cells lining the renal papilla in any of the rats including those with vesicle-like outpouchings of the papilla lining and collapsed, multicellular forms. Acting as a positive control, a few Ki-67 positive cells were observed in the proximal tubules of the cortex and in the pelvic urothelium and rarely in the collecting ducts. No mitotic figures were observed in the renal papilla lining of any of the rat kidneys used for immunohistochemical investigation, nor were any observed in the papilla lining cells in the corresponding H&E-stained sections.

SEM Evaluation

SEM of the kidney pelvis showed the typical structure of the luminal surface of the large urothelial superficial cells with plaques and peaked microridges (Jacobs et al. 1976). At the fornix, there was an abrupt, albeit irregular transition to the type of cells lining the renal papilla (Figure 2D), which were considerably smaller and cuboidal to polygonal in shape with microvilli and/or microplicae (Figures 2E-F; Bulger et al. 1974). We did not observe cilia on any cells lining the papilla nor did we detect cilia on the lining cells of the collecting ducts as they opened onto the pelvic space (Figure 2E).

Discussion

There is an absence of immunohistochemical staining for uroplakins of the epithelium lining the renal papilla, and the

Figure 1. (continued). the vesicular outpouching retains the single-cell layer, but the basal epithelium appears thickened, probably due to tangential sectioning. The vesicle interior is a loose network of structureless wispy material or collapse of vesicles. (F) Papilla lining lesion where the vesicle outpouching has collapsed to give an appearance of multicellularity. Cortex of kidney showing CPN is on the left.

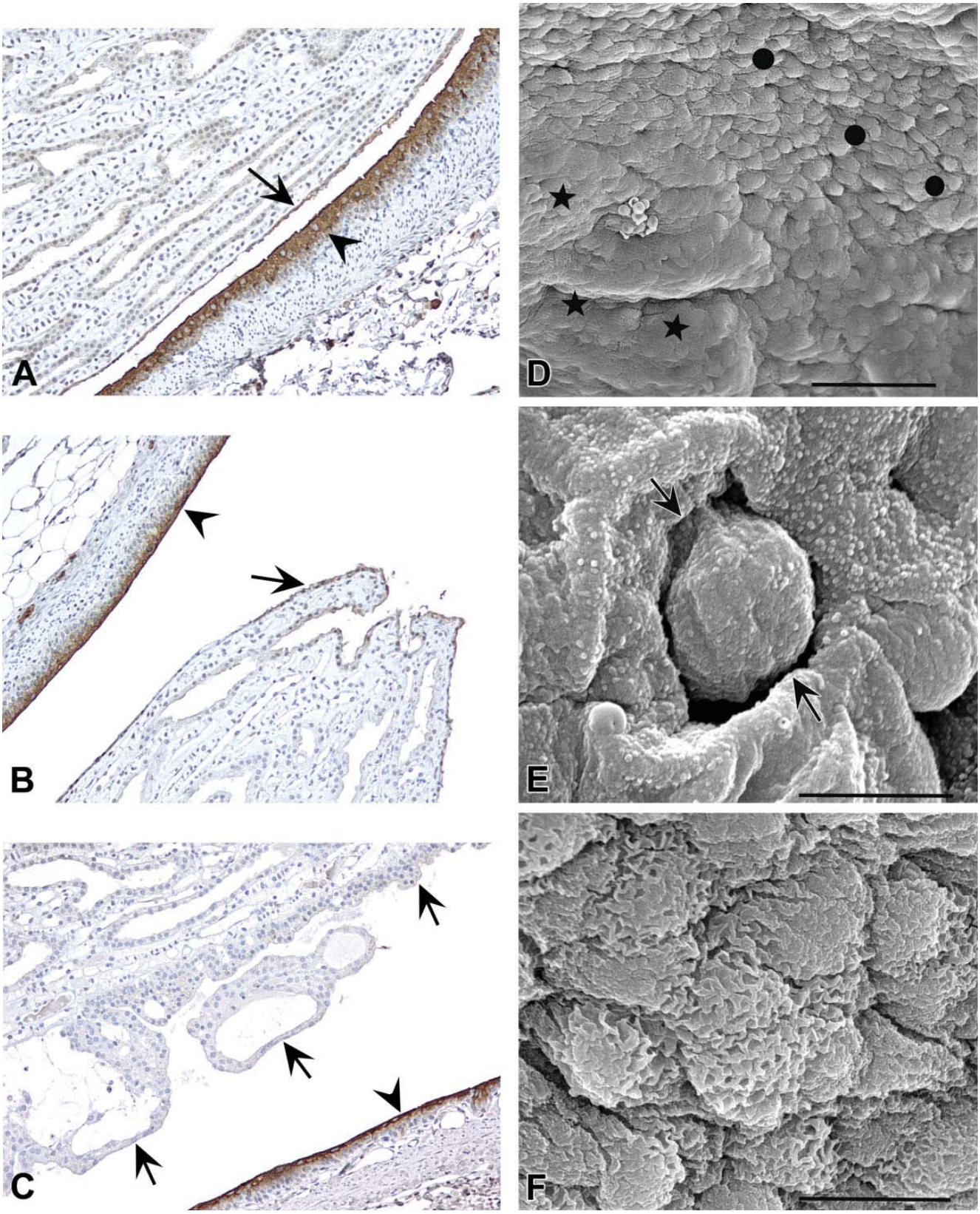

Figure 2. (A) Immunohistochemical staining of a kidney of a young rat without chronic progressive nephropathy (CPN) for uroplakins, showing strong staining of true kidney pelvis urothelium (arrowhead) but lack of staining for the epithelial lining of the renal papilla (arrow) and collecting duct epithelium. Slight edge effect staining was noted within the apical aspect of the renal papilla epithelium and occasionally in the collecting ducts,

luminal surface cells lining the papilla do not share the appearance of superficial urothelial cells, as observed by SEM. Thus, the lining epithelium of the rat kidney papilla is clearly not urothelium. The appearance of the cells lining the renal papilla is cuboidal by light microscopy and has a luminal surface distinct from the true urothelium as viewed by SEM. Based on these observations, the lining epithelium of the rat kidney papilla needs to be categorized separately from the true urothelium of the kidney pelvis lining in classification schemes and in histopathology evaluations of kidney. We recommend that the nomenclature in International Harmonization of Nomenclature and Diagnostic Criteria (INHAND) for the single-cell lining of the renal papilla be specified as *cuboidal lining of renal papilla*, as has been previously described in Cohen (2013) and Greaves (2012). The present INHAND site clearly distinguishes between papilla and pelvis but is not clear as to the lining epithelium of the papilla being urothelial or not. Furthermore, in practice, the lesion on the papilla associated with CPN is commonly referred to as renal pelvic urothelial (transitional cell) hyperplasia.

It is unclear whether the cells lining the papilla are an extension of the collecting duct lining cells, as we did not observe cilia on the papilla lining cells. However, the general features of the cells that we could observe by SEM in the collecting ducts appeared similar to those lining the papilla. Although most epithelial cells lining the collecting ducts proximal to their connection to the papilla lining epithelium, have a single cilium, some cells do not have a cilium but have short microvilli and microplicae (Carrroll et al. 1974; Bulger et al. 1974; Andrews and Porter 1974) such as what we observed of the epithelium lining the papilla and the adjoining collecting duct epithelium.

The distinction between this lining epithelium and the true urothelium is critical in the assessment of toxicologic pathology evaluations. The types of toxicities occurring in the true urothelium of the kidney pelvis are distinct from those affecting the glomeruli, tubules, or collecting ducts but are similar to those occurring in the urothelium of the ureters and urinary bladder. However, toxic responses affecting the urothelium of the urinary bladder tend to be more frequent and more severe compared to the urothelial lining of the renal pelvis and ureters, probably due to the storage function of the bladder, resulting in extended exposure to urine (Cohen 1998; Cohen et al. 2007; Wu et al. 2009).

Serial sectioning of rat kidney illustrates the importance of including the length of the papilla in the histological specimen, as CPN-related papilla lining alterations affected mainly the distal two-thirds of the papilla. Tracking along serial sections of papilla demonstrated that the lesions were vesicular and did not transition into the solid or proliferative character typical of hyperplasia. They remained vesicular until they disappeared from the section, except in cases of lining collapse. This lesion was distinct from the hyperplastic papilla lining induced by potassium bromate, which was a multicellular thickening of the lining projecting into the pelvis lumen as papillary fronds or sessile mats (Wolf et al. 1998). In contrast, CPN-associated papilla lining alteration was consistently vesicular in nature without morphological progression to a proliferative state. By light microscopy, only rare mitotic figures were observed, and immunohistochemistry with Ki-67 antibody, a characteristic marker for DNA replication (Wood et al. 2015), revealed an absence of cell proliferation. In addition, there was no inflammatory component to this unique lesion.

The distinction between histopathologic alterations of the lining epithelium of the papilla and those of the urothelial lining of the kidney pelvis is of more than academic interest, because the papillary lesion associated with advanced CPN is currently classified by regulatory and authoritative agencies as urothelial hyperplasia or *transitional cell hyperplasia*. The term transitional cell hyperplasia was also used in the latest version of the INHAND classification system of histopathologic changes in rodent kidney (Frazier et al. 2012) when referring to this lesion under the heading of *CPN* and was also used by Hard and Khan (2004) in the latest review of CPN. Because of this inaccurate nomenclature, the CPN-related renal papilla lesion has been regarded sometimes as a distinct form of toxic response with proliferative potential, separate from CPN. It *is* a part of CPN, and more importantly, like CPN overall, this vesicular lesion has not been described in humans (Taal et al. 2012; Jennette et al. 2015). This lesion appears to be unique to high grades of CPN in the rat.

By definition, the term *hyperplasia* denotes an abnormal increase in the number of cells in a tissue or organ lining. However, it connotes a proliferative lesion. The vesicular morphology, the lack of any conspicuous proliferative activity, and the lack of progression of this renal papilla alteration to more advanced lesions, including historically an absence of neoplastic development, indicates that this is not a true hyperplastic response. Based on these differences, we recommend that the nomenclature for this renal papilla lesion be revised and referred to as *vesicular alteration of renal papilla lining* and that it be specified separately from kidney pelvis and separate from urothelial. In the INHAND listing for this entity (to INHAND Global Editorial and Steering Committee;

Figure 2. (continued). but no cytoplasmic staining was observed. (B) Immunohistochemical staining of a kidney of an old rat with CPN but without vesicular lesion of renal papilla, showing strong staining of true kidney pelvis urothelium (arrowhead) but lack of staining for the epithelial lining of the renal papilla (arrow) and collecting duct epithelium. (C) Immunohistochemical staining of a kidney of an old rat with CPN but with vesicular lesion of renal papilla, showing strong staining of true kidney pelvis urothelium (arrowhead) but lack of staining for the epithelial lining of the renal papilla (arrows) and collecting duct epithelium. Epithelial lining of vesicular lesions does not stain. (D) Scanning electron microscopy (SEM) of luminal surface at fornix showing large polygonal cells (stars) of the true urothelium irregularly merging with smaller cells of the papilla lining epithelium (circles). (E) SEM of papilla with opening of collection duct (arrows). Cells lining the papilla and collecting duct have numerous short, uniform microvilli, with no evidence of cilia. (F) SEM of cells lining the papilla showing microplicae on the surface.

Frazier et al. 2012), we recommend the following: organ: *kidney*, specific site: *renal papilla*, and descriptor: *vesicular alteration of papilla lining*.

Acknowledgment

The authors wish to acknowledge the support of the Fred and Pamela Buffett Cancer Center Tissue Sciences Facility Shared Resource, supported by the National Cancer Institute under award number P30 CA036727.

Author Contribution

All authors (NS, GH, LA, RF, KP, SC) contributed to conception or design; data acquisition, analysis, or interpretation; drafting the manuscript; and critically revising the manuscript. All authors gave final approval and agreed to be accountable for all aspects of work in ensuring that questions relating to the accuracy or integrity of any part of the work are appropriately investigated and resolved.

Declaration of Conflicting Interests

The author(s) declared no potential conflicts of interest with respect to the research, authorship, and/or publication of this article.

Funding

The author(s) disclosed receipt of the following financial support for the research, authorship, and/or publication of this article: This study was supported by the Fred and Pamela Buffett Cancer Center support grant (P30CA036727).

References

Andrews, P. M., and Porter, K. R. (1974). A scanning electron microscopic study of the nephron. *Am J Anat* **140**, 81–115.

Bulger, R. E., Siegel, F. L., and Pendergrass, R. (1974). Scanning and transmission electron microscopy of the rat kidney. *Am J Anat* **139**, 483–501.

Carroll, N., Crock, G. W., Funder, C. C., Green, C. R., Ham, K. N., and Tange, J. D. (1974). Scanning electron microscopy of the rat renal papilla. *J Anat* **117**, 447–52.

Cohen, S. M. (1998). Urinary bladder carcinogenesis. *Toxicol Pathol* **26**, 121–27.

Cohen, S. M. (2013). Lower urinary tract. In *Haschek and Rousseaux's Handbook of Toxicologic Pathology* (W. M. Hascheck-Hock, C. G. Rousseaux, and M. A. Wallig, eds.), 3rd ed., pp. 1775–93. Elsevier, Academic Press, New York.

Cohen, S. M., Garland, E. M., Cano, M., St John, M. K., Khachab, M., Wehner, J. M., and Arnold, L. L. (1995). Effects of sodium ascorbate, sodium saccharin and ammonium chloride on the male rat urinary bladder. *Carcinogenesis* **16**, 2743–50.

Cohen, S. M., Ohnishi, T., Clark, N. M., He, J., and Arnold, L. L. (2007). Investigations of rodent urinary bladder carcinogens: Collection, processing, and evaluation of urine and bladders. *Toxicol Pathol* **35**, 337–47.

Frazier, K. S., Seely, J. C., Hard, G. C., Betton, G., Burnett, R., Nakatsuji, S., Nishikawa, A., Durchfeld-Meyer, B., and Bube, A. (2012). Proliferative and nonproliferative lesions of the rat and mouse urinary system. *Toxicol Pathol* **40**, 14S–86S.

Greaves, P. (2012). Urinary tract. In *Histopathology of Preclinical Toxicity Studies* (P. Greaves, ed.), 4th ed., pp. 537–614. Elsevier. Academic Press, New York.

Hard, G. C., Banton, M. I., Bretzlaff, R. S., Dekant, W., Fowles, J. R., Mallett, A. K., McGregor, D. B., et al. (2013). Consideration of rat chronic progressive nephropathy in regulatory evaluations for carcinogenicity. *Toxicol Sci* **132**, 268–75.

Hard, G. C., Bruner, R. H., Cohen, S. M., Pletcher, J. M., and Regan, K. S. (2011). Renal histopathology in toxicity and carcinogenicity studies with tert-butyl alcohol administered in drinking water to F344 rats: A pathology working group review and re-evaluation. *Regul Toxicol Pharmacol* **59**, 430–36.

Hard, G. C., Johnson, K. J., and Cohen, S. M. (2009). A comparison of rat chronic progressive nephropathy with human renal disease—Implications for human risk assessment. *Crit Rev Toxicol* **39**, 332–46.

Hard, G. C., and Khan, K. N. (2004). A contemporary overview of chronic progressive nephropathy in the laboratory rat, and its significance for human risk assessment. *Toxicol Pathol* **32**, 171–80.

Hard, G. C., and Seely, J. C. (2005). Histological investigation of diagnostically challenging tubule profiles in advanced chronic progressive nephropathy (CPN) in the Fischer 344 rat. *Toxicol Pathol* **34**, 941–48.

Hicks, R. M., Ketterer, B., and Warren, R. C. (1974). The ultrastructure and chemistry of the luminal plasma membrane of the mammalian urinary bladder: A structure with low permeability to water and ions. *Phil Trans R Soc Lond* **268**, 23–38.

Jacobs, J. B., Arai, M., Cohen, S. M., and Friedell, G. H. (1976). Early lesions in experimental bladder cancer: Scanning electron microscopy of cell surface markers. *Cancer Res* **36**, 2512–17.

Jennette, J. C., Olson, J. L., Silva, F. G., and D'Agati, V. D. (2015). *Heptinstall's Pathology of the Kidney*, 7th ed., Vol. 1 & 2. Wolters Kluwer Health, Philadelphia, PA.

Korshid, M. R., and Moffat, D. B. (1974). The epithelia lining the renal pelvis in the rat. *J Anat* **118**, 561–69.

Lee, G. (2011). Uroplakins in the lower urinary tract. *Int Neurourol J* **15**, 4–12.

Miyazaki, J., and Nishiyama, H. (2017). Epidemiology of urothelial carcinoma. *Int J Urol* **24**, 730–34.

National Toxicology Program. (2007). *Toxicology and Carcinogenesis Studies of Methyl Isobutyl Ketone (CAS No. 108-10-1) in F344 Rats and B6C3F$_1$ Mice.NTP TR 538, NIH Publication No. 07-4476*. NIEHS, Research Triangle Park, NC.

Pauli, B. U., Alroy, J., and Weinstein, R. S. (1983). The ultrastructure and pathobiology of urinary bladder cancer. In *The Pathology of Bladder Cancer* (G. T. Bryan and S. M. Cohen, eds.), pp. 41–140. CRC Press, Boca Raton, FL.

Silverblatt, F. J. (1974). Ultrastructure of the renal pelvic epithelium of the rat. *Kidney Int* **5**, 214–20.

Song, R., and Yosypiv, I. V. (2011). Genetics of congenital anomalies of the kidney and urinary tract. *Pediatr Nephrol* **26**, 353–64. doi:10.1007/s00467-010-1629-4

Taal, M. W., Chertow, G. M., Marsden, P. A., Skorecki, K., Yu, A. S. L., and Brenner, B. M. (2012). *Brenner and Rector's The Kidney*, 9th ed., Vol., 1 & 2. Elsevier, Philadelphia, PA.

Wolf, D. C., Crosby, L. M., George, M. H., Kilburn, S. R., Moore, T. M., Miller, R. T., and DeAngelo, A. B. (1998). Time- and dose-dependent development of potassium bromate-induced tumors in male Fischer 344 rats. *Toxicol Pathol* **26**, 724–29.

Wolf, D. C., and Mann, P. C. (2005). Confounders in interpreting pathology for safety and risk assessment. *Toxicol Appl Pharmacol* **202**, 302–08.

Wood, C. E., Hukkanen, R. R., Sura, R., Jacobson-Kram, D., Nolte, T., Odin, M., and Cohen, S. M. (2015). Scientific and Regulatory Policy Committee (SRPC) Review*: Interpretation and use of cell proliferation data in cancer risk assessment. *Toxicol Pathol* **43**, 760–75.

Wu, X. R., Kong, X. P., Pellicer, A., Kreibich, G., and Sun, T. T. (2009). Uroplakins in urothelial biology, function, and disease. *Kidney Int* **75**, 1153–65.