Comments to the Docket regarding the EPA IRIS Assessment on ETBE

Samuel M. Cohen, MD, PhD
Department of Pathology & Microbiology
University of Nebraska Medical Center
Omaha, NE 68198-3135

Following are comments regarding the recently published toxicological review of Ethyl tert-butyl ether (ETBE) (CAS RN 637-92-3) which was published in June 2017. I was a participant in the PWG reported as Cohen et al., (2011). These comments are from myself, without support from any company or other individuals.

I have extensive experience in human and in animal pathology, including rats and mice, and I am still a practicing surgical pathologist. In addition, I have more than 50 years of experience in experimental toxicology, carcinogenesis, and pathology research and have published extensively with nearly 400 publications in my career. I have received numerous honors for my achievements, notably the Lehman Award for excellence in risk assessment research from the Society of Toxicology, the Merit Award from the Society of Toxicology, the Lifetime Achievement Award from the Society of Toxicologic Pathology, and the Distinguished Scientist Award from the American College of Toxicology. I have served on numerous national and international committees and panels, including those from the NIH, NAS, IPCS, IARC, EPA, FDA, NTP and NIEHS, including serving on the Boards of Scientific Counselors of both the NTP and NIEHS at different times. I also serve on the FEMA Expert Panel for the evaluation of flavors, which evaluates the safety of flavor ingredients in foods. I have extensive experience in kidney pathology, and I have served on a number of pathology working groups involving kidney pathology, including the one organized for ETBE.

Ethyl tert-butyl ether (ETBE) is the subject of a draft toxicological review by IRIS. In the review last year, the authors of the ETBE draft document were strongly encouraged to seek pathology expertise in reviewing the material. This obviously has not been done. There is no pathologist listed in their assessment team, contributors to the document, the production team, or contractor support. In addition, I do not see any pathologists selected for the Scientific Advisory Board (SAB) that is reviewing this document, nor is pathology listed as one of the areas of expertise to be represented on the SAB. Many of the comments that I am making regarding ETBE I have made in my comments regarding tert-butyl alcohol (TBA), and I refer the EPA to those comments, rather than repeat them in detail here.

For ETBE, the issues are kidney changes in the rat, particularly in males, and the increased incidence of liver tumors in rats treated with ETBE. Ultimately, none of the findings regarding the kidney nor the liver tumors are relevant to human risk, and therefore, should not be incorporated into a risk assessment for ETBE. The centriloblular hypertrophy of the liver could be relevant to humans so could be used for risk assessment purposes. I will first address the changes in the kidney, which are non-cancer, and then address the issue of liver toxicity and tumors.

As with TBA, the authors for the IRIS document have completely misinterpreted the pathology findings regarding the kidney and their relationship to chronic progressive nephropathy (CPN). I have written about these changes in detail in the document for TBA, and I refer the reader to those comments. However, let me address some of the specifics regarding ETBE. It is very likely that the changes in the kidneys secondary to ETBE are related to its metabolism to TBA. Since the exposure to TBA would be less than the direct administration of TBA, it is not surprising that the changes are less severe and do not result in tumors.

Findings regarding alpha2u-globulin nephropathy are detailed in the PWG report on ETBE (Cohen et al., 2011). The changes are consistent with alpha2u-globulin nephropathy, are male specific, and are not relevant to humans. Details regarding the findings for CPN and ETBE are also detailed in that PWG report.

The pathologic findings related to CPN have been extensively delineated in INHAND criteria published by the Society of Toxicologic Pathologists in 2012 (Frazier et al., 2012). The characteristic histopathologic features of CPN in include tubular basophilia, nuclear crowding, thickened basement membrane, hyaline casts, tubular atrophy, tubular dilitation, focal glomerular sclerosis, glomerular atrophy, inflammatory infiltrate, transitional cell hyperplasia of the renal pelvis lining (to be discussed in greater detail below), and interstitial fibrosis (Frazier et al., 2012). Not all features will be present in every kidney affected with CPN, but depends on the grade of the disease which will partly be a reflection of age of the rat. An increase in kidney weight is a gross finding related to CPN, as well as α_{2u}-globulin, and is a non-specific finding regarding many forms of kidney toxicity in rodents. As the disease progresses, renal function decreases leading to an increase in BUN and creatinine levels, and ultimately, if it progresses to end-stage kidney, and results in uremia.

The IRIS authors have chosen to separate several manifestations of the kidney changes as separate entities from CPN, including urothelial hyperplasia, increased blood concentrations of total cholesterol, BUN, and creatinine, and increased kidney weight. These are all manifestations of CPN (or combined with α_{2u}-globulin), and cannot be separated. The statistical approaches described by IRIS are inappropriate for several reasons as detailed in my TBA comments. The changes in urothelial hyperplasia and the blood levels of BUN and creatinine will only occur in the more severe grades of CPN, and thus are not usually present in earlier grades, such as grade 1 or 2. Important to note for the evaluation is that the pathologist will not always record all of the features separately in their list of diagnoses but will lump them together under CPN, or might delineate one or more of the specific changes. Thus, without going through a specific review of the slides to list each of the features for individual animals, a statistical comparison cannot be made.

It should be noted that the increased levels of BUN and creatinine are a manifestation of end-stage kidney disease. These are usual features with high grades of CPN, which is increasing in incidence and severity over time in many of the rat strains that are used for tumor bioassays. This is particularly true for the F344 rat, and has led to the termination of the use of that strain by the NTP because of the marked increase in mortality secondary to renal failure secondary to CPN.

The issue of transitional cell hyperplasia also needs to be specifically discussed. This is a finding that is associated with CPN (Frazier et al., 2012). This association is specifically stated in the NTP report on TBA on p. 56 (NTP, 1995), a statement ignored by the IRIS authors. Unfortunately, it has been traditional amongst pathologists to classify the increased proliferation seen along the lining of the renal papillae as part of the kidney pelvis. This is inaccurate, and has been discussed in detail in the PWG report on TBA (Hard et al., 2011) and the PWG report on ETBE (Cohen et al., 2011). True transitional cell (urothelial cell) hyperplasia occurs in the lining of the renal pelvis, which is distinct from the kidney papillae. The true pelvis is an extension of the lower urinary tract, including the ureters and urinary bladder (Murphy et al., 2004; Wu et al., 2009). The true kidney pelvis, ureters and urinary bladder are lined by an epithelium currently named the urothelium but was previously referred to as a transitional cell epithelium (Murphy et al., 2004; wu et al., 2009). Both terms are currently used, but the preferred terminology is urothelium or urothelial cell epithelium. This is a characteristic epithelium with a well-defined layered structure (Wu et al., 2009). This is not the epithelium that lines the kidney papillae (Hard et al., 2011). The lining of the kidney papillae (Figure 1) is generally cuboidal to slightly columnar, is a single cell layer, and does not have the characteristic proteins of the urothelium (uroplakins).

Figure 1. Modified from Hard et al., 2011, figure 5. Labeling in the figure has been added. Figure shows the renal papilla, the hyperplasia of the epithelial lining of the papilla, and the normal kidney pelvis.

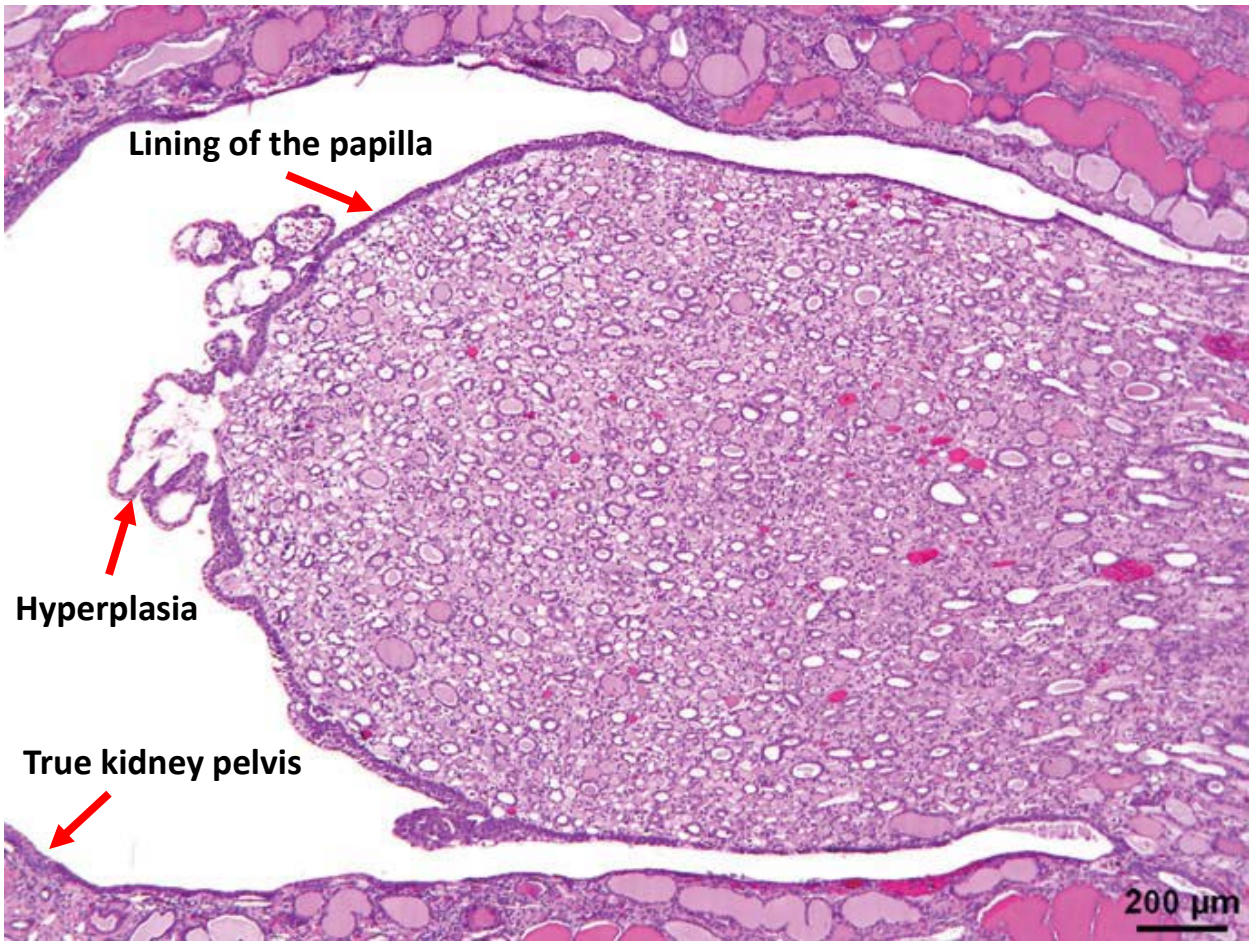

The proliferation that occurs in the lining of the papillae is a distinct form of "hyperplasia", is not a transitional (urothelial) cell hyperplasia of the kidney pelvis. The hyperplasia seen in the TBA study was entirely the proliferation of the lining of the renal papillae and was not proliferation of the true kidney pelvis (Figure 1). This was specifically examined in the PWG and is stated clearly in that report (Hard et al., 2011). This is also the "renal pelvis hyperplasia" in the ETBE studies which described in the PWG report on ETBE (Cohen et al. 2011). What is important to understand is that this proliferation of the lining of the renal papillae is a finding of advanced CPN, usually grade 3 or grade 4. It in no way is a reflection of a direct effect of the chemical on this epithelial lining, but rather, it is secondary to the CPN itself. It is also important to note that this type of proliferation does not occur in humans. I have never seen it in my career, and I have spoken with nephropathologists who also indicate that this type of proliferation has not been identified in humans. Furthermore, I cannot find reference to it in nephropathology textbooks (Jennette et al., 2015; Taal et al., 2012) nor in a brief review of the recent nephropathology literature. Thus, even if the IRIS insists that this is an independent finding, it is irrelevant to humans. However, it is important to understand that this is not a separate finding from CPN in any circumstance in the TBA or ETBE studies, but is merely another manifestation of advanced CPN.

Most importantly, CPN in rats is not relevant to humans (Hard and Seely, 2005; Hard and Khan, 2004; Hard et al., 2009; 2011; 2012; 2013; Seely et al., 2002; Travlos et al., 2011). The IRIS document continues to cite the contrary opinion of Melnick et al., (2012; 2013), but do not mention the numerous deficiencies of his data and arguments as delineated in detail in Hard et al. (2013). All of the kidney findings in the ETBE studies can be explained by CPN and α_{2u}-globulin which are not relevant to humans, and therefore should not be used for human risk assessment.

It is also known that the changes of CPN are more extensive and appear earlier in the male rat compared to the female rat. Furthermore, there are similar changes in male and female mice with similar pathologic and clinical manifestations, but the extent is generally not as frequent or as severe as in the rat. Thus, the rat has greater changes than the mouse, and the male has changes greater than the female regarding CPN in rats or CPN-like changes in mice.

In summary, all of the kidney changes that are described in the IRIS report regarding the kidney can be attributed to CPN and α_{2u}-globulin nephropathy. This includes increased kidney weight, urothelial hyperplasia (actually hyperplasia of the kidney papilla lining), and increased blood concentrations of total blood cholesterol, BUN and creatinine. Since CPN is not relevant to humans, these findings described by IRIS in response to ETBE administration also are not relevant to humans. As has been extensively evaluated, CPN does not occur in humans and there is no analogous disease in humans. The numerous distinctions between chronic renal disease in humans versus CPN in rats has been described extensively by Hard et al. (2009). Without doubt, CPN is not relevant to humans and should not be included in a risk assessment for humans. Thus, all of the findings that have been attributed to CPN in the ETBE study involving the kidney are related to CPN and are not relevant to humans and should not be used in a risk assessment.

The discussion regarding findings in the liver also reflect a significant lack of pathology expertise by the writers of this document. They report on the bioassays of ETBE which have been performed by gavage, water administration, and by inhalation. The indication is that there was an increased incidence of tumors in male rats only, and only in the gavage study and in the

inhalation study. In the inhalation study, there was only a slight increase in adenomas, but not carcinomas. Administration in the water study was completely negative, and all studies were negative in female rats. These results suggest a weak effect at most with respect to the liver.

The IRIS document tries to explain the possible modes of action that could be involved with ETBE-induced liver tumors, but get lost in their understanding of the pathology and with respect to mode of action analysis. They indicate that the finding of centrilobular hypertrophy of the liver is seen only in the shorter term studies but not in the two year bioassays, indicating that this is a transient effect and likely not related to the tumorigenic finding. This goes against an extensive literature discussing various modes of action that produce centrilobular hypertrophy and ultimately liver tumors. It has been clearly shown that centrilobular hypertrophy occurs early in the life span of the animals, and usually is not detectable at the two year time point largely because of the extensive changes that are present in the liver. This has been discussed in detail by Dr. Robert Maronpot (Maronpot et al., 2010), a renowned authority in liver histopathology who was the head of the pathology branch of the National Toxicology Program for many years. Numerous authors have actually argued that this reflects an adaptive response rather than an adverse response (Hall et al., 2012). Furthermore, a lack of comprehensive evaluation of not only the pathology but an understanding of modes of action related to centrilobular hypertrophy is reflected by the fact that they do not even cite the publication by Corton et al. (2014), which provided an extensive analysis of the mode of action for CAR activated tumorigenesis in the liver. This is disturbing because Dr. Corton is an EPA scientist and led the team of international scientists that developed the mode of action analysis on PPARα that was published in 2014. Undoubtedly, the centrilobular hypertrophy was related to one of the nuclear receptors, CAR, PXR, or PPARα, which are well-known to produce centrilobular hypertrophy early in the course of treatment, for some chemicals within days. Evidence for activation of these receptors has been published by various authors (e.g. Kakehashi et al., 2013). These are associated with an increase in liver weight early in the course of the experiment, and with the eventual development of liver tumors in the two year bioassay. The amount of data presented in the IRIS document clearly shows that one or more of these receptors are affected. Centrilobular hypertrophy is related to activation of these receptors, and the centrilobular hypertrophy is related to the eventual development of these liver tumors.

The IRIS document also suggests that because there is a lack of complete correlation between the finding of centrilobular hypertrophy in different studies by different routes of administration and the ultimate development of tumors, it can't be related to the development of the tumors. This reflects a distinct lack of understanding of the relationship of these findings, and a relationship to toxicokinetics and changes over time. Most importantly, although the metabolic changes related to CAR, PXR, and PPARα occur in humans at high doses of exposure to these chemicals, the human liver does not respond to activation of these receptors with an increase in cell proliferation, which is a central key event to the mode of action in the animal models for these tumors (Corton et al., 2014; Elcombe et al., 2014).

Increased hepatocyte proliferation in addition to activation of these receptors and centrilobular hypertrophy have been demonstrated (Kakehashi et al., 2015). PPARα has been accepted as a mode of action that is not relevant to humans and most organizations accept CAR and PXR

activation (frequently together) as also not relevant to humans. Epidemiology study with drugs that act by these mechanisms (fibrates for PPARα activation and phenobarbital and various anti-anxiety drugs for CAR activation) have consistently not shown a relationship to an increase in tumor formation, even at doses that are similar in the human compared to the animal studies.

A lack of understanding of the overall mode of action approach to evaluation is evident in some of the comments made in the IRIS documents, as has been an issue for IRIS documents in the past (Guyton et al., 2009). For example, one of the statements that they make (page 1-53) is that data gaps exist and a lack of information regarding gap junctions and clonal expansion are cited as examples. Gap junction communication loss is not considered one of the key events in the mode of action, but rather is considered an associative of that event (Corton et al., 2014; Elcombe et al., 20174). The issue of clonal expansion refers primarily to the appearance of foci, but is clearly present if there is development of adenomas and/or carcinomas, since these are clonal expansions of liver cells, as are the foci. Difficulties of the IRIS program with use of mode of action data has been addressed previously (Meek et al., 2008). There is a well-established framework for evaluation of mode of action in animals and human relevance (Sonich-Mullen et al., 2001; Meek et al., 2003; Seed et al., 2005; Boobis et al., 2006; 2008) that is incorporated into EPA's cancer guidelines and is also used for non-cancer toxicities. Scientists from numerous governmental agencies participated in development of this framework, including scientists from EPA, and at least for pesticide evaluations in EPA-OPP registrants are required to use it in their presentations to the Agency.

The IRIS document also refers to an investigation by Maltoni et al. (1999). They delineate the serious flaws in that study, which were corroborated by a peer review of that study by a number of pathologists from the United States, including individuals from the National Toxicology Program (Malarkey et al., 2011). Fundamentally, the Maltoni et al. studies have a poor quality of pathology, have not been peer reviewed (prior to the Malarkey et al. review), and are significantly complicated by the presence of pneumonia in all of the animals in the facility. There are also numerous other deficiencies. This study should not be considered for any risk assessment. As an example, the European Food Safety Authority (EFSA) has refused to consider any of the publications from the Ramazzini Institute because of significant deficiencies in the study design and execution.

The IRIS document also refers to studies by Hagiwara et al. (2011; 2013; 2015) in which ETBE is administered after pretreatment with a number of DNA reactive carcinogens. These models should be considered carefully, since they have not been validated. Most importantly, IRIS does not provide a critical analysis of these studies. The study involving the administration of five different DNA reactive carcinogens before treatment with ETBE (Hagiwara et al., 2011) is particularly suspect. This is primarily because of the extensive variability in the incidence of tumors in this model when the animals are treated only with these five DNA reactive chemicals, without a subsequent test chemical, such as ETBE. This variability makes interpretation of the results extremely difficult, if not impossible. For example, in the five chemical initiation study (Hagiwara et al., 2011) there is an increased incidence of urinary bladder tumors, but in the study specifically looking at the BBN model without the other 4 DNA reactive chemicals showed no effect by ETBE (Hagiwara et al., 2013). In addition, in the five chemical initiation study, they

reported forestomach tumors (Hagiwara et al., 2011). Forestomach tumors are not relevant to humans, so it is unclear why the IRIS document does not address this lack of relevance any further. The effects on the thyroid are probably the most variable in the five chemical study.In the experiment in which the animals were initiated with N-ethyl-N-(2-hydroxyethyl)nitrosamine (EHEN) there is an increase in liver tumor and kidney tumors (Hagiwara et al., 2051). This is not surprising since ETBE by itself slightly increased the incidence of liver tumors. Any chemical that by itself produces an increased incidence of tumors will also be positive in such a two-stage initiation/promotion assay. The finding of kidney tumors suggests that in this model, at least, ETBE is metabolized adequately to TBA leading to a possible increase in kidney tumors.

In summary, the liver tumors are slightly increased with ETBE, are present in only one sex, and are variable depending on the route of administration. Based on the information available, it is likely that the mode of action involves activation of a nuclear receptor, reflected in the development of centrilobular hypertrophy, with the ultimate slight increase in liver tumors, primarily adenomas. This mode of action and these tumors are not relevant to human risk assessment. If a quantitative extrapolation to human risk regarding non-cancer findings is to be performed, one could use the centrilobular hypertrophy as a potential risk to humans as a non-cancer finding, since this is likely to occur in humans with any of these three nuclear receptors. This is in contrast to the lack of human relevance of any of the kidney findings.

In summary, there is no human relevant cancer finding with ETBE. The non-cancer kidney findings with ETBE are not relevant to humans, but the centrilobular hypertrophy that is seen with ETBE in the liver is potentially relevant to humans, but will be a high dose phenomenon only.

REFERENCES

Boobis, A. R., Cohen, S. M., Dellarco, V., McGregor, D., Meek, M. E., Vickers, C., Willcocks, D., Farland, W. (2006). IPCS framework for analyzing the relevance of a cancer mode of action for humans. Crit. Rev. Toxicol. 36(10): 781-792.

Boobis, A. R., Doe, J. E., Heinrich-Hirsch, B., Meek, M. E., Munn, S., Ruchirawat, M., Schlatter, J., Seed, J., Vickers, C. (2008). IPCS framework for analyzing the relevance of a noncancer mode of action for humans. Crit. Rev. Toxicol. 38(2): 87-96.

Cohen, S.M.; Hard, G.C., Regan, K.S., Seely, J.C., Bruner, R.H. (2011) Pathology working group review of selected histopathologic changes in the kidneys of rats assigned to toxicology and carcinogenicity studies of ethyl tertiary butyl ether (ETBE): Japan Bioassay Research Center studies no.: 0065 and 0691 [Unpublished report] (pp. 1-30). Research Triangle Park, NC: Research Pathology Associates under contract to Lyondell Chemical Company.

Corton, J. C., Cunningham, M. L., Hummer, B. T., Lau, C., Meek, B., Peters, J. M., Popp, J. A., Rhomberg, L., Seed, J., Klaunig, J. E. (2014). Mode of action framework analysis for receptor-mediated toxicity: The peroxisome proliferator-activated receptor alpha (PPARalpha) as a case study. Crit. Rev. Toxicol. 44(1): 1-49.

Elcombe, C. R., Peffer, R. C., Wolf, D. C., Bailey, J., Bars, R., Bell, D., Cattley, R. C., Ferguson, S. S., Geter, D. ,Goetz, A., Goodman, J. I., Hester, S., Jacobs, A., Omiecinski, C. J., Schoeny, R., Xie, W., Lake, B. G. (2014). Mode of action and human relevance analysis for nuclear receptor-mediated liver toxicity: A case study with phenobarbital as a model constitutive androstane receptor (CAR) activator. Crit. Rev. Toxicol. 44(1): 64-82.

Frazier, K. S., Seely, J. C., Hard, G. C., Betton, G., Burnett, R., Nakatsuji, S., Nishikawa, A., Durchfeld-Meyer, B., Bube, A. (2012). Proliferative and nonproliferative lesions of the rat and mouse urinary system. Toxicol. Pathol. 40(4 Suppl): 14S-86S.

Guyton, K. Z., Chiu, W. A., Bateson, T. F., Jinot, J., Scott, C. S., Brown, R. C., Caldwell, J. C. (2009). A Reexamination of the PPAR-α Activation Mode of Action as a Basis for Assessing Human Cancer Risks of Environmental Contaminants. Environ. Health Perspect. 117(11): 1664-1672.

Hall, A. P., Elcombe, C. R., Foster, J. R., Harada, T., Kaufmann, W., Knippel, A., Kuttler, K., Malarkey, D. E., Maronpot, R. R., Nishikawa, A., Nolte, T., Schulte, A., Strauss, V., York, M. J. (2012). Liver hypertrophy: a review of adaptive (adverse and non-adverse) changes--conclusions from the 3rd International ESTP Expert Workshop. Toxicol. Pathol. 40(7): 971-994.

Hagiwara, A., Doi, Y., Imai, N., Nakashima, H., Ono, T., Kawabe, M., Furukawa, F., Tamano, S., Nagano, K., Fukushima, S. (2011). Medium-term multi-organ carcinogenesis bioassay of ethyl tertiary-butyl ether in rats. Toxicology 289(2–3): 160-166.

Hagiwara, A., Imai, N., Doi, Y., Suguro, M., Kawabe, M., Furukawa, F., Nagano, K., Fukushima, S. (2013). No Promoting Effect of Ethyl Tertiary-butyl Ether (ETBE) on Rat Urinary Bladder Carcinogenesis Initiated with N-Butyl-N-(4-hydroxybutyl)nitrosamine. J. Toxicol. Pathol. 26(4): 351-357.

Hagiwara, A., Doi, Y., Imai, N., Suguro, M., Kawabe, M., Furukawa, F., Tamano, S., Nagano, K., Fukushima, S. (2015). Promotion of liver and kidney carcinogenesis by ethyl tertiary-butyl ether (ETBE) in male Wistar rats. J. Toxicol. Pathol. 28(4): 189-195.

Hard, G. C. and Khan, K. N. (2004). A contemporary overview of chronic progressive nephropathy in the laboratory rat, and its significance for human risk assessment. Toxicol. Pathol. 32(2): 171-180.

Hard, G. C. and Seely, J. C. (2005). Recommendations for the interpretation of renal tubule proliferative lesions occurring in rat kidneys with advanced chronic progressive nephropathy (CPN). Toxicol. Pathol. 33(6): 641-649.

Hard, G. C. and Khan, K. N. (2004). A contemporary overview of chronic progressive nephropathy in the laboratory rat, and its significance for human risk assessment. Toxicol. Pathol. 32(2): 171-180.

Hard, G. C., Johnson, K. J., Cohen, S. M. (2009). A comparison of rat chronic progressive nephropathy with human renal disease-implications for human risk assessment. Crit. Rev. Toxicol. 39(4): 332-346.

Hard, G. C., Bruner, R. H., Cohen, S. M., Pletcher, J. M., Regan, K. S. (2011). Renal histopathology in toxicity and carcinogenicity studies with tert-butyl alcohol administered in drinking water to F344 rats: a pathology working group review and re-evaluation. Regul. Toxicol. Pharmacol. 59(3): 430-436.

Hard, G. C., Betz, L. J., Seely, J. C. (2012). Association of Advanced Chronic Progressive Nephropathy (CPN) with Renal Tubule Tumors and Precursor Hyperplasia in Control F344 Rats from Two-Year Carcinogenicity Studies. Toxicol. Pathol. 40(3): 473-481.

Hard, G. C., Banton, M. I., Bretzlaff, R. S., Dekant, W., Fowles, J. R., Mallett, A. K., McGregor, D. B., Roberts, K. M., Sielken, R. L., Jr., Valdez-Flores, C., Cohen, S. M. (2013). Consideration of rat chronic progressive nephropathy in regulatory evaluations for carcinogenicity. Toxicol. Sci. 132(2): 268-275.

Jennette, J. C., Olson, J. L., Silva, F. G., and D'Agati, V. D. Heptinstall's Pathology of the Kidney, Vol. 1 & 2, 2015.

Kakehashi, A., Hagiwara, A., Imai, N., Nagano, K., Nishimaki, F., Banton, M., Wei, M., Fukushima, S., Wanibuchi, H. (2013). Mode of action of ethyl tertiary-butyl ether hepatotumorigenicity in the rat: Evidence for a role of oxidative stress via activation of CAR, PXR and PPAR signaling pathways. Toxicol. Appl. Pharmacol. 273(2): 390-400.

Kakehashi, A., Hagiwara, A., Imai, N., Wei, M., Fukushima, S., Wanibuchi, H. (2015). Induction of cell proliferation in the rat liver by the short-term administration of ethyl tertiary-butyl ether. J. Toxicol. Pathol. 28(1): 27-32.

Malarkey, D. E., Bucher, J. R. (2011). Summary of the National Toxicology Program and Environmental Protection Agency-sponsored review of pathology materials from selected Ramazzini Institute rodent cancer bioassays [NTP]. Research Triangle Park: National Toxicology Program.

Maltoni, C., Bepoggi, F., Soffritti, M., Minardi, F. (1999). Comprehensive long-term experimental project of carcinogenicity bioassays on gasoline oxygenated additives: plan and first report of results from the study on ethyl-tertiary-butyl ether (ETBE). Eur. J. Oncol. 4: 493-508.

Maronpot, R. R., Yoshizawa, K., Nyska, A., Harada, T., Flake, G., Mueller, G., Singh, B., Ward, J. M. (2010). Hepatic enzyme induction: histopathology. Toxicol. Pathol. 38(5): 776-795.

Meek, M. E., Bucher, J. R., Cohen, S. M., Dellarco, V., Hill, R. N., Lehman-McKeeman, L. D., Longfellow, D. G., Pastoor, T., Seed, J., Patton, D. E. (2003). A framework for human relevance analysis of information on carcinogenic modes of action. Crit. Rev. Toxicol. 33(6): 591-653.

Meek, M. E., Bucher, J. R., Cohen, S. M., Dellarco, V., Hill, R. N., Lehman-McKeeman, L. D., Longfellow, D. G., Pastoor, T., Seed, J., Patton, D. E. (2003). A framework for human relevance analysis of information on carcinogenic modes of action. Crit. Rev. Toxicol. 33(6): 591-653.

Meek, M. E., Berry, C., Boobis, A. R., Cohen, S. M., Hartley, M., Munn, S., Olin, S., Schlatter, J., Vickers, C. (2008). Re: Guyton, Kathryn Z., Barone, Stanley, Jr., Brown, Rebecca C., Euling, Susan Y., Jinot, Jennifer, Makris, Susan (2008). Mode of action frameworks: a critical analysis. Journal of Toxicology and Environmental Health, Part B, 11(1): 16-31. J. Toxicol. Environ. Health. B. Crit. Rev. 11(8): 681-683; author reply 684-685.

Melnick, R. L., Burns, K. M., Ward, J. M., Huff, J. (2012). Chemically exacerbated chronic progressive nephropathy not associated with renal tubular tumor induction in rats: an evaluation based on 60 carcinogenicity studies by the national toxicology program. Toxicol. Sci. 128(2): 346-356.

Melnick, R. L., Ward, J. M., Huff, J. (2013). War on Carcinogens: Industry Disputes Human Relevance of Chemicals Causing Cancer in Laboratory Animals Based on Unproven Hypotheses, Using Kidney Tumors as an Example. Int. J. Occup. Environ. Health 19(4): 255-260.

Murphy, W. M., Grignon, D. J., and Perlman, E. J. Tumors of the Kidney, Bladder and Related Urinary Structures. AFIP Atlas of Tumor Pathology, Series 4, Vol. 1, 2004, p. 241-362.

National Toxicology Program (NTP). Toxicology and Carcinogenic Studies of A-Butyl Alcohol in F344/N Rats and B6C3F1 Mice. NTP Technical Report Series No. 436, 1995.

Seed, J., Carney, E. W., Corley, R. A., Crofton KM., DeSesso, J. M.,Foster, P.M. and R. Kavlock, Kimmel, G,Klaunig, J., Meek, M. E., Preston, R. J., Slikker, W., Jr., Tabacova, S, William, G.M. (2005). Overview: Using Mode of Action and Life Stage Information to Evaluate the Human Relevance of Animal Toxicity Data. Crit. Rev. Toxicol. 35: 663-672.

Seely, J. C., Haseman, Joseph K., Nyska, Abraham, Wolf, Douglas C., Everitt, Jeffrey I., Hailey, James R. (2002). The Effect of Chronic Progressive Nephropathy on the Incidence of Renal Tubule Cell Neoplasms in Control Male F344 Rats. Toxicol. Pathol. 30(6): 681-686.

Sonich-Mullin,C., Fielder,R., Wiltse,J., Baetcke,K., Dempsey,J.,Fenner-Crisp,P., Grant,D., Hartley,M., Knaap,A., Kroese,D., Mangelsdorf,I., Meek,E., Rice,J.M., Younes,M. (2001). IPCS Conceptual Framework for Evaluating a Mode of Action for Chemical Carcinogenesis. Regul. Toxicol. Pharmacol. 34: 146-152.

Taal, M. W., Chertow, G. M., Marsden, P. A., Skorecki, K., Yu, A. S. L., and Brenner, B. M. Brenner and Rector's The Kidney. Ninth Edition, Vol., 1 & 2, 2012.

Travlos, G. S., Hard, G. C., Betz, L. J., Kissling, G. E. (2011). Chronic progressive nephropathy in male f344 rats in 90-day toxicity studies: its occurrence and association with renal tubule tumors in subsequent 2-year bioassays. Toxicol. Pathol. 39(2): 381-389.

Wu, X., Kong, X. P., Pellicer, A., Kreibicvh, G, Sun, T. T. Uroplakins in urothelial biology, function, and disease. Kidney Int. 75(11): 1153-1165.