Comments to the Docket regarding the EPA IRIS Assessment on Tertiary-butyl alcohol (TBA)

Samuel M. Cohen, MD, PhD
Department of Pathology & Microbiology
University of Nebraska Medical Center
Omaha, NE 68198-3135

Following are comments regarding the recently published toxicological review of tert-butyl alcohol (tert-butanol) (CAS Mo. 75-65-0) which was published in June 2017. I was reviewer of the previous IRIS document as requested by the National Academy of Sciences. These comments are from myself, without support from any company or other individuals.

I have extensive experience in human and in animal pathology, including rats and mice, and I am still a practicing surgical pathologist. In addition, I have more than 50 years experience in experimental toxicology, carcinogenesis, and pathology research and have published extensively with nearly 400 publications in my career. I have received numerous honors for my achievements, notably the Lehman Award for excellence in risk assessment research from the Society of Toxicology, the Merit Award from the Society of Toxicology, the Lifetime Achievement Award from the Society of Toxicologic Pathology, and the Distinguished Scientist Award from the American College of Toxicology. I have served on numerous national and international committees and panels, including those from the NIH, NAS, IPCS, IARC, EPA, FDA, NTP and NIEHS, including serving on the Boards of Scientific Counselors of both the NTP and NIEHS at different times. I also serve on the FEMA Expert Panel for the evaluation of flavors, which evaluates the safety of flavor ingredients in foods. I have extensive experience in kidney pathology, and I have served on a number of pathology working groups involving kidney pathology, including the one organized for TBA.

TBA was evaluated in a National Toxicology Program (NTP, 1995) two year bioassay accompanying shorter term assays, in particular, a 90-day dose range finding study. An increased incidence of tumors was identified in the male rat kidney, with no increased tumor incidences in the female rat. In the male and female mouse, there was a slight increase in benign thyroid follicular tumors (adenomas) and follicular hyperplasia.

At the previous review held in June, 2016, the scientists involved in the production of the IRIS document were strongly recommended to seek expertise in pathology for review of the animal studies, in particular, those related to the kidney. It is striking to me that this advice has not been followed by the IRIS scientists. There is no pathologist listed in their assessment team, contributors to the document, the production team, or contractor support. In addition, I do not see any pathologists selected for the Scientific Advisory Board (SAB) that is reviewing this document, nor is pathology listed as one of the areas of expertise to be represented on the SAB. I believe this to be a significant deficiency, as my comments below will indicate. Many of these comments were made at my presentation and discussion at last year's review, as well as in my previous comments to the docket on TBA.

The kidney slides from the various studies performed in rats at the NTP were reviewed by a pathology working group (PWG) of which I was a member (Hard et al., 2011). It would appear that the IRIS report has discounted the findings of this PWG and are discounting the findings presented in the NTP report and in the extensive literature on the issues being evaluated (Hard et al., 2004; 2005; 2009; 2011; 2012; 2013; Seely et al., 2002; Travlos et al., 2011; Frazier et al., 2012). The key issues are whether the findings in the kidneys can be completely explained by changes involving α_{2u}-globulin nephropathy, chronic progressive nephropathy (CPN), and corticomedullary calcification. It would appear from the current IRIS document that they accept that the corticomedullary junction calcification is a common rat phenomenon and is not relevant to humans, so I will not discuss that further.

The IRIS document discusses at length the various aspects of α_{2u}-globulin nephropathy and CPN. Rather than focus on the pathology and biology related to the various manifestations of these two disease entities, they have resorted to a statistical analysis showing that certain pathologic findings were not due to either α_{2u}-globulin or CPN. The statistical analyses that have been performed are erroneous for a number of reasons. Primarily, both the numerators and denominators used in these calculations are incorrect. To begin with, the three features that they are focusing on are renal pelvic transitional hyperplasia, suppurative inflammation, and increased kidney weights. All three of these are manifestations of CPN (Frazier et al., 2012; NTP, 1995). However, the findings of suppurative inflammation and transitional cell hyperplasia occur only in higher grades of CPN, grade 3 and grade 4, not with the lower grades. Thus, to do statistical analyses involving all of the cases of CPN is incorrect. Furthermore, these statistical analyses are made on the presumption that the recordings of these findings are always listed by the pathologist reading these slides. This also is incorrect, since, depending on the pathologist and depending on the findings, they may not list all of the particular details involved with CPN, just lumping them together under the diagnosis of CPN. Thus, without going through the slides and reviewing them specifically, animal by animal for grade, and the specific changes that can occur with CPN, a statistical analysis is inappropriate and can be quite misleading.

It is important to understand the overall pathology and biology of CPN to make a proper assessment of the data. CPN is a common finding in rat kidney, with nearly all animals by 10 weeks of age having some degree of CPN, even involving a single nephron (Travlos et al., 2011; Frazier et al., 2012; Hard et al., 2011; 2013). Thus, incidences in a 13 week study, with the animals 6 to 8 weeks of age at the beginning of the study, or in a 2 year bioassay, will be nearly 100%. This is true in both males and females, but with greater severity in the males. Incidences less than this can be reported because many pathologists will ignore the very early signs of CPN when there is only involvement of only a few nephrons or there will be a sampling issue. Importantly, the well-defined features of CPN have been extensively delineated in the INHAND criteria published by the Society of Toxicologic Pathologists in 2012 (Frazier et al., 2012). The "earliest lesion detectible in young adults is a basophilic tubule or evidence of regeneration in outer kidney, but soon thereafter basophilia is accompanied by crowded nuclei and/or thickened basement membrane." The characteristic features of CPN include tubular basophilia, nuclear crowding, thickened basement membrane, hyaline casts, tubular atrophy, tubular dilitation, focal glomerular sclerosis, glomerular atrophy, mononuclear cell inflammatory infiltrate, transitional

cell hyperplasia of the renal pelvis lining (to be discussed in greater detail below), and interstitial fibrosis. Not all features will be present in every kidney affected with CPN, but depends on the grade of the disease which will be partly a reflection of age of the rat. An increase in kidney weight is a gross finding of CPN, and also α_{2u}-globulin. It is important to understand that some of these changes occur early and are characteristic of all cases of CPN, whereas others occur only in more advanced stages. Increased kidney weight is an early feature as is tubular basophilia with nuclear crowding and thickened basement membrane, the characteristic features of CPN. Not all of the features that I have just listed will be present in every case of CPN, and the study pathologists will not always record all of the individual features, but just note the diagnosis of CPN. What needs to be understood about the biology of CPN is that it is a degenerative disease with consequent regeneration, with a high rate of cell turnover. This has been repeatedly demonstrated (Frazier et al., 2012; Konishi and Ward, 1989). Thus, the extensive discussion in the IRIS report about lack of cell necrosis and cytotoxicity is erroneous, as these are a part of CPN by definition. This again reflects the way pathologists list the diagnoses. CPN is recorded, but the cytotoxicity, degeneration, and hyperplasia are frequently not listed separately since they are an integral part of CPN. This is another example of the fallacies of a statistical approach as used by IRIS, and again is a clear indication that they have not sought pathology expertise nor do they understand the biology and pathology of CPN. The basophilia and tubular hyperplasia that is characteristic of early as well as late CPN and are an indication of the proliferation, Furthermore, the proliferation is always in response to the degenerative changes that are occurring in the tubules in CPN.

Increased kidney weight and suppurative inflammation or chronic inflammation are part of CPN (Frazier et al., 2012). They are not specific findings to CPN, but if CPN is present, they will be assumed to be part of the CPN diagnosis unless there are other parts of the kidney not involved with CPN that show evidence of inflammation. This was specifically examined in the PWG review of the slides, and was found not to occur (Hard et al., 2011). Thus, all of the degenerative and proliferative changes in the kidney could be identified in areas that were involved with either CPN or α_{2u}-globulin nephropathy (see below). There was no area of the kidney that showed changes distinct from CPN or α_{2u}-globulin nephropathy. All of these findings were described in detail in the report and the publication of the PWG.

The IRIS report also tries to argue that the findings in the female involved a lack of tumors despite the findings of increased kidney weight, inflammation, and transitional cell hyperplasia. They argue that these occurred separately from the CPN. They further argue that these are independent because the degree of CPN in the females on average was similar to that seen in the males. What is critical to note is that the highest grade of CPN (grade 4) is much less common in the female than in the male (Hard et al., 2012; Frazier et al., 2012; NTP, 1995). Furthermore, the changes of more severe CPN occur earlier in the age of the male rat than in the female rat so that there is a greater chance for the proliferative changes seen with CPN to evolve into a tumor in the males than in the females.

The issue of transitional cell hyperplasia also needs to be specifically discussed. This is a finding that is associated with CPN (Frazier et al., 2012). This association is specifically stated in the NTP

report on TBA on p. 56 (NTP, 1995), a statement ignored by the IRIS authors. Unfortunately, it has been traditional amongst pathologists to classify the increased proliferation seen along the lining of the renal papillae as part of the kidney pelvis. This is inaccurate, and has been discussed in detail in the PWG report (Hard et al., 2011). True transitional cell (urothelial cell) hyperplasia occurs in the lining of the renal pelvis, which is separate from the kidney papillae. The true pelvis is an extension of the lower urinary tract including the ureters and urinary bladder (Murphy et al., 2004; Wu et al., 2009). The true kidney pelvis, ureters and urinary bladder are lined by an epithelium currently named the urothelium but was previously referred to as a transitional cell epithelium (Murphy et al., 2004; wu et al., 2009). Both terms are currently used, but the preferred terminology is urothelium or urothelial cell epithelium. This is a characteristic epithelium with a well-defined layered structure (Wu et al., 2009). This is not the epithelium that lines the kidney papillae (Hard et al., 2011). The lining of the kidney papillae (Figure 1) is generally cuboidal to slightly columnar, is a single cell layer, and does not have the characteristic proteins of the urothelium (uroplakins).

Figure 1. Modified from Hard et al., 2011, figure 5. Labeling in the figure has been added. Figure shows the renal papilla, the hyperplasia of the epithelial lining of the papilla, and the normal kidney pelvis.

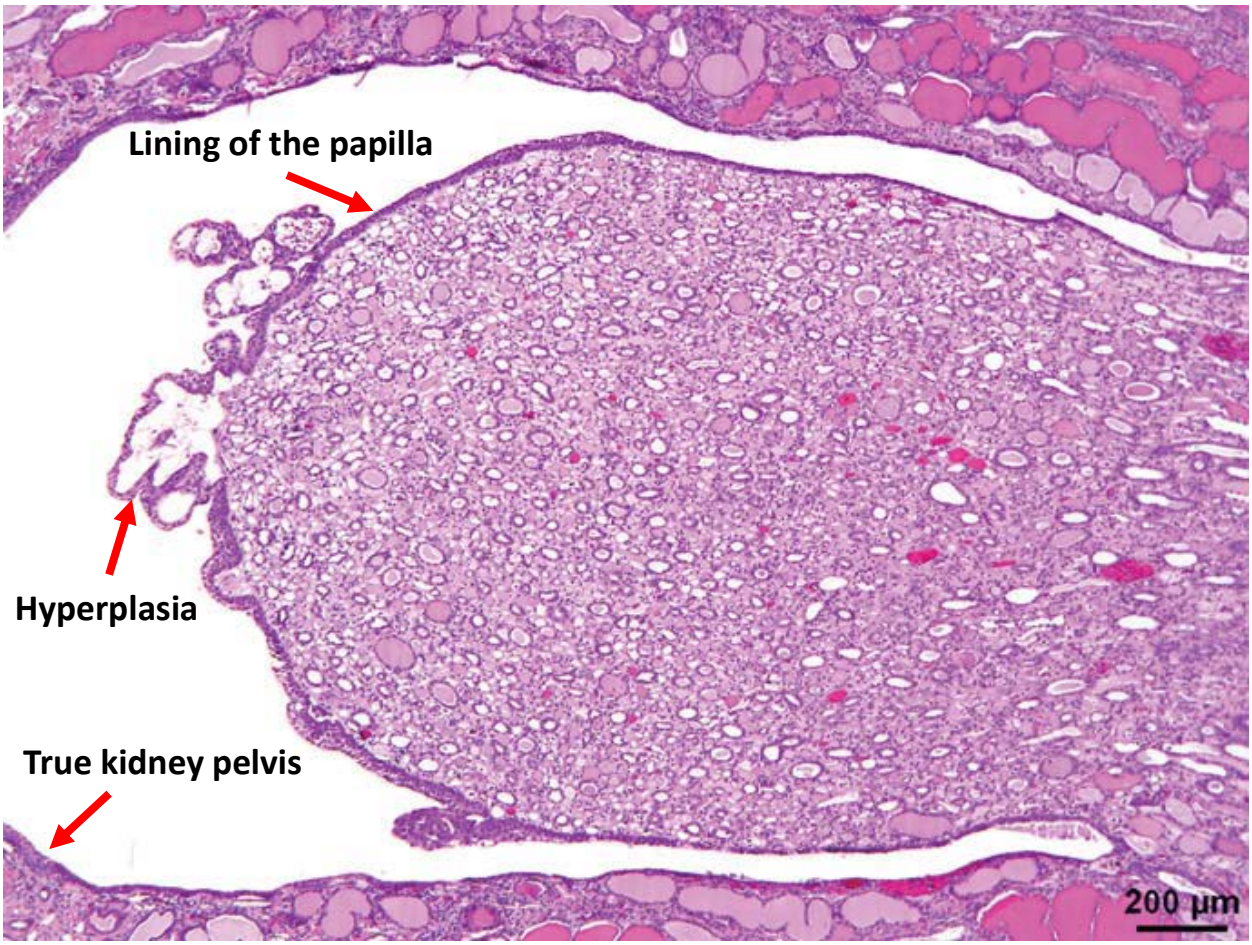

The proliferation that occurs in the lining of the papillae is a distinct form of "hyperplasia", is not a transitional (urothelial) cell hyperplasia of the kidney pelvis. The hyperplasia seen in the TBA study was entirely the proliferation of the lining of the renal papillae and was not proliferation of the true kidney pelvis (Figure 1). This was specifically examined in the PWG and is stated clearly in that report (Hard et al., 2011). What is important to understand is that this proliferation of the lining of the renal papillae is a finding of advanced CPN, usually grade 3 or grade 4. This is explicitly stated in the NTP report (NTP, 1995) on TBA on page 56; they indicate that this hyperplasia is a manifestation of CPN. It in no way is a reflection of a direct effect of the chemical on this epithelial lining, but rather, it is secondary to the CPN itself. It is also important to note that this type of proliferation does not occur in humans. I have never seen it in my career, and I have spoken with nephropathologists who also indicate that this type of proliferation has not been identified in humans. Furthermore, I cannot find reference to it in textbooks (Jennette et al., 2015; Taal et al., 2012) nor in a brief review of the recent nephropathology literature. Thus, even if the IRIS insists that this is an independent finding, it is irrelevant to humans. However, it is important to understand that this is not a separate finding from CPN in any circumstance in the TBA study, but is merely another manifestation of advanced CPN.

Suppurative inflammation is also a part CPN, primarily due to the degeneration of the tubules with an inflammatory reaction to the material from the lumen of the tubules or the cast-like material that can form. Again, this is not a direct effect of the chemical, but rather, is a consequence of advanced CPN, with greater likelihood of inflammation occurring as the more advanced stages of CPN are attained. This is also related to the chronic interstitial inflammatory infiltrate that is frequently seen in these end stage kidneys, along with fibrosis, which is the end stage of the inflammation.

In summary, all of the findings of increased kidney weight, suppurative inflammation, and transitional cell hyperplasia (actually hyperplasia of the papillae lining) are all manifestations with TBA of CPN, with the addition that the increased kidney weight could also be contributed to be by the α_{2u}-globulin nephropathy, which I will discuss below.

The relationship of CPN to the development of kidney tumors has been extensively examined utilizing NTP bioassay data. One would anticipate that CPN would lead to an increase in renal proliferative lesions including renal atypical hyperplasia and tumors, particularly adenomas, since it is a proliferative nephropathy. In general, the incidence is usually relatively low secondary to CPN, but can be higher. This was best illustrated by a study by Hard et al. (2012) which examined the control rats in a large number of 2 year bioassays from the NTP. He utilized an 8 grade system rather than the usual 4 grade system, but his grade 8 his generally equivalent to the grade 4 of the NTP classification. He was able to show that in males, 41 of 170 male rats that had the highest grades of CPN, had atypical hyperplasia or renal cell tumors (24.1%) and in the females, 1 of 6 animals with grade 8 CPN had atypical hyperplasia or tumors (16.7%). From this data, one can see a number of factors. First, the incidence of high grade CPN is much greater in male rats than in female rats. Secondly, with end stage CPN involving end stage kidney disease, there is a significant incidence of renal cell tumors. Because CPN is a proliferative disease, the increased incidence of tumors with the most advanced grades of this disease fits with what we know about

the relationship of increased cell proliferation and carcinogenesis. Similar findings supporting this relationship have also been reported by others, including an early report by Seely et al. (2002), but that study involved a smaller number of studies that were evaluated. It is important to note that the studies by Hard et al. (2012) and Seely et al. (2002) involved actual re-examination of the kidneys from these studies for both the diagnosis and grading of CPN as well as identification of atypical hyperplasia and tumors. They did not rely on the reports. It should be noted that the hyperplasia routinely seen with CPN is not considered atypical tubular hyperplasia, but is the more "typical" hyperplasia seen with tubules that is a characteristic feature of CPN, even in its early stages. It is only with the expansion of the proliferation that it becomes "atypical" and is classified as atypical tubular hyperplasia. It is the atypical tubular hyperplasia that evolves into adenomas. Adenomas occasionally evolve into carcinomas, but most of the lesions seen with CPN remain as either atypical tubular hyperplasia or adenomas. The specific criteria for these tumors have been well delineated in the INHAND classification document.

As has been evaluated extensively, CPN does not occur in humans and there is no analogous disease in humans. The numerous distinctions between chronic renal disease in humans versus CPN in rats has been described extensively by Hard et al. (2009). There is no doubt that CPN is not relevant to humans, and should not be included in a risk assessment for humans. Thus, all of the findings that have been attributed to CPN in the TBA study in the kidney, including increased kidney weight, suppurative inflammation and transitional cell hyperplasia, are related to CPN and are not relevant to humans.

There has been some controversy regarding the human relevance of tumors associated with CPN. The above discussion clearly shows that CPN can be the cause of renal cell atypical tubular hyperplasia and renal cell tumors. The evidence for this is overwhelming. Specific key events in the mode of action have been well-described by Hard et al. (2013). These include: 1) exposure to chemical (usually at high concentrations); 2) metabolic activation (if necessary); 3) exacerbated CPN, including increased number of rats with end stage renal disease; 4) increased tubule cell proliferation; 5) hyperplasia; and 6) adenoma (infrequently carcinoma) (see Figure 2). These key events are well-delineated, and fit with the IPCS and EPA framework for mode of action analysis in examination of human relevance (Sonich-Mullin et al., 2001; Meek et al., 2003; Seed et al., 2005; Boobis et al., 2006; 2008). Since CPN is not relevant to humans, the tumors associated with CPN are obviously not relevant to humans, either.

Figure 2. The modes of action for a α_{2u}-globulin nephropathy and CPN, both starting with cell loss (exfoliation in α_{2u}-globulin nephropathy and cytotoxicity or degeneration for CPN). α_{2u}-globulin nephropathy is induced by the binding of the chemical to α_{2u}-globulin, and its incorporation into the tubule cell lysosomes.

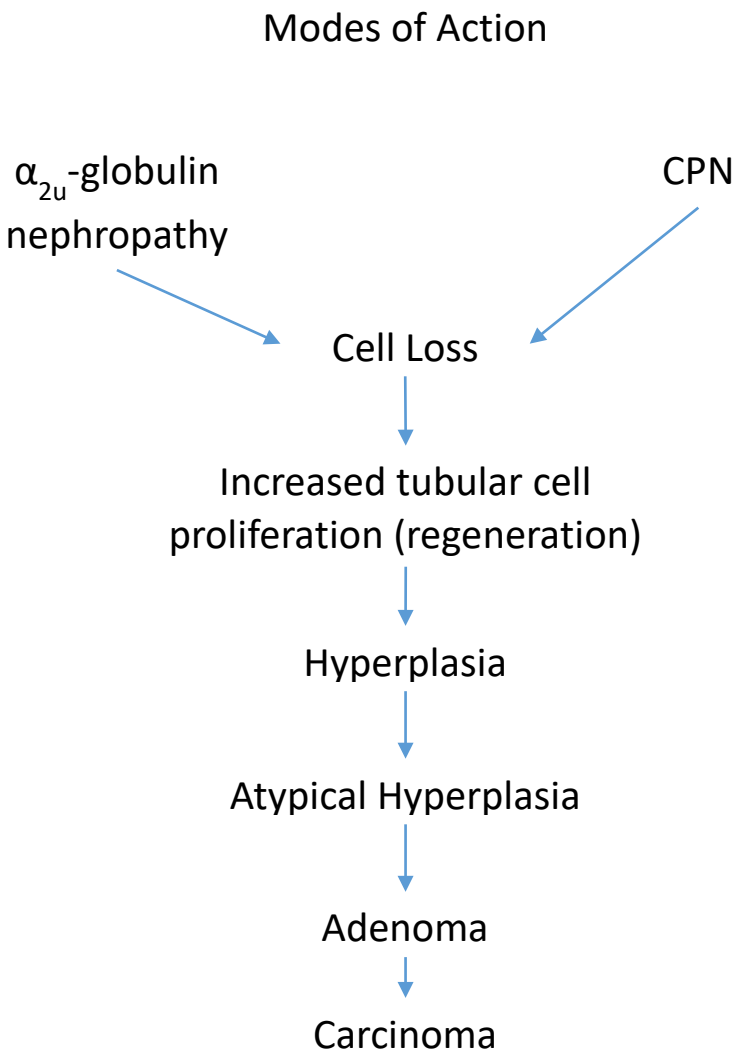

The IRIS document again brings up the arguments of Dr. Ronald Melnick in which he and his colleagues try to argue that CPN is not a mode of action and that the kidney tumors are relevant to humans (Melnick et al., 2012; 2013). There are numerous parts of Dr. Melnick's examination and discussion which are erroneous, as described in detail in Hard et al. (2013). To begin with, Melnick et al. (2012; 2013) confuse mode of action with mechanism of action. Mode of action requires an identification of identifiable key events that lead from the exposure to the chemical to the development of the apical endpoint, in this instance kidney tumors. This has been well met for CPN. This contrasts with mechanism of action where the molecular details would be known.

Obviously that is not known for CPN, nor is it known for most causes of cancer in animals or in humans, although progress is being made along these lines. Second of all, his statistical analyses are completely erroneous (Hard et al., 2013). To begin with, his analysis includes studies of chemicals for which well-known modes of action have been identified, including genotoxicity. To lump all of these together for an evaluation of CPN is clearly misleading and statistically not appropriate. Furthermore, the analysis does not evaluate specifically animals with end stage renal disease, which would have an increased incidence of renal tumors, rather than all stages of CPN, including early stages of CPN. Additionally, the studies that he incorporated in his analysis utilized various classification schemes for CPN, and different pathologists at different times have included different criteria in their overall diagnostic details for CPN. None of this is taken into account in his analysis, nor were any of the studies re-examined. It should be noted that Dr. Melnick is not a pathologist. Furthermore, this is the same Dr. Melnick (Melnick, 1992) that has argued that the mechanism for α_{2u}-globulin nephropathy-induced tumors is wrong despite a clear description of the fallacies of his argument (Borghoff et al., 1993). Furthermore, the MOA is widely accepted (IARC, 1999; Meek et al., 2003), including by the EPA and is delineated in the IRIS document for TBA, is wrong. He argues that they are relevant to humans. For the IRIS document to dwell and rely on the arguments by Dr. Melnick without a critical analysis is unacceptable. Particularly, when the details examining the Melnick publications have been delineated in Hard et al. (2013), which the IRIS document does not discuss.

The other issue is α_{2u}-globulin. The IRIS report delineates a great deal of detail regarding this issue, but appears to be stymied by a lack of casts being identified in the NTP report despite their being identified in the review by the PWG. The issue of casts is actually irrelevant. Although having casts or cast-like material present is helpful in the diagnosis (Frazier et al., 2012), there are other findings which clearly support the relationship of TBA to α_{2u}-globulin nephropathy (Hard et al., 2011). Most notably is the finding of linear mineralization in the 2 year study. This is a characteristic finding, although not pathognomonic, for α_{2u}-globulin nephropathy. Importantly, it indicates that there has been tubular degeneration over time with eventual calcification of the tubules, including the contents. Essentially, by definition, this indicates that cast-like material had to be present within the tubules at some point in the development of this mineralization possibly later than the 13 weeks of the shorter term study. It should be kept in mind that this mineralization is to be distinguished from the corticomedullary calcification described earlier, which is a common finding in rats, both male and female. The issue with α_{2u}-globulin that appears to be unclear to the writers of the IRIS document is that it involves cell loss. The writers of the IRIS document appear to be confused about the issue of toxicity and regeneration with regard to α_{2u}-globulin. It is not an issue of whether it is necrosis or not, but actually is related to cell loss. The characteristic finding of α_{2u}-globulin is the "exfoliation" of tubular cells into the lumen of the tubule. It is not known whether these are alive at the time of exfoliation or not. However, once they have fallen off into the tubular lumen, they will die and progress down the nephron. Over time, these accumulate and form the cast-like material, which over an even greater length of time undergo degenerative changes and become calcified, leading to the formation of the linear mineralization that is characteristic of α_{2u}-globulin nephropathy. Thus, one does not necessarily have to see tubular necrosis or even tubular cell degeneration for there to be cell loss. The important observation is that there is cell loss, and when there is cell loss, the tubule has to

proliferate to regenerate the lost cells. Thus, like CPN, this is an issue of degeneration (in this instance, cell loss) with regeneration (Borghoff et al., 2001). Thus, both α_{2u}-globulin nephropathy and CPN lead to an increase in cell proliferation, which over time leads to an increase in renal tumors (see Figure 2).

It is well-accepted, including by EPA, that α_{2u}-globulin nephropathy is not relevant to humans, and therefore, the tumors associated with α_{2u}-globulin nephropathy are not relevant to humans, and therefore the tumors associated with α_{2u}-globulin nephropathy are also not relevant to humans (IARC, 1999). This is a well-accepted conclusion by nearly everyone, except possibly Dr. Melnick.

Some concern was raised in the IRIS report that the incidence of tumors in the study with TBA in the male rat was higher than usually seen with α_{2u}-globulin or CPN. This is likely due to the fact that there would be expected to be a synergy between these two factors, since both increase cell proliferation. Furthermore, TBA is increasing the extent of CPN, including higher grades which are more likely to lead to tumor development. Since both α_{2u}-globulin nephropathy and CPN increase cell proliferation, there is a greater likelihood that tumors will evolve over time, particularly over the time of a 2 year bioassay. Since α_{2u}-globulin is a male rat specific phenomenon, the synergy between these two will only be seen in the male rat, and readily explains why there were tumors in the male rat and not in the female rat. Although tumors have been identified associated with CPN in female rats in other studies, these are very uncommon, largely due to the fact that very few female rats in the 2 year bioassay develop end stage renal disease as described above. One can readily develop a mode of action framework for the findings in the rat kidney that fully explain all of the findings (see Figure 2). All of the findings in the kidneys in the study with TBA, including those in the male and in the female can be attributed to corticumedullary calcification, α_{2u}-globulin nephropathy, or CPN. Since all three of these are not relevant to humans, none of the findings in the male or female rat kidneys in the TBA bioassay are relevant to humans and should not be used for risk assessment purposes, whether qualitative or quantitative.

The evidence that TBA is non-genotoxic is strong. This includes the NTP genotoxicity assays (NTP; 1995): the Ames assay, the mouse lymphoma cell assay, chromosomal aberration studies in CHO cells, and an *in vivo* micronucleus assay in mice. Those were uniformly negative. In the IRIS draft document, they mention a few other studies suggesting possible oxidative damage or reduced glutathione activities, particularly referencing the two publications by Acharya (1995; 1997). It is disturbing that the IRIS document described these papers without any critical analysis of the quality of the data in these papers. Both of these publications have severe limitations with respect to methodology, which raise serious questions as to the reliability of the data for consideration for risk assessment. To begin with, in the first paper, they describe a level of toxicity in the animals at a dose for which there was no toxicity seen in the NTP bioassay. Although it is unclear as to what this was due, there is a strong possibility that this was due to the animals being infected, possibly with *Helicobacter hepaticus.* The publications by Acharya describe possible liver toxicity, although it is unclear that this is actually present. Liver toxicity is not seen in the NTP publication on TBA. Furthermore, the histology is poorly presented, and the slides from the

kidneys actually show some degree of autolysis rather than necrosis. If the tissues were not fixed adequately, this would raise questions regarding the other studies that were performed. Liver toxicity is associated Helicobacter infections, and unless this was specifically analyzed for, it could well have been present. There is no statement with regard to the specific pathogen free (SPF) status of the animals, either at the time of purchase or the quality of the animal facility. In the 1990's, many of the laboratories in India where this study was performed, had complications with numerous infections in their animals. This would completely explain the findings that they were observing, so that it is unlikely that TBA was responsible for any of their findings. Furthermore, they do not describe whether or not the animals were randomized for placement in the groups, the number of animals per group was small (6), and there is no indication whether the evaluations were performed in a blinded fashion. Furthermore, they describe weight loss in the first paper. Although the animals were weighed in the second study, there is no description of the results. In addition, there is no pathologist involved in the evaluation of the histopathologic slide preparations.

Overall, TBA is clearly a non-genotoxic chemical. All of the findings in the kidney, including increased kidney weight, suppurative inflammation, and transitional cell hyperplasia, in both males and females, can be explained by CPN, α_{2u}-globulin nephropathy, and corticomedullary calcification. None of these disorders occur in humans, so none of these findings are relevant to humans. They therefore should not be used in a risk assessment.
In addition in the 2 year bioassay in mice, there was no evidence of changes in the kidneys, but there was a slight increase in the incidence of follicular cell thyroid tumors and hyperplasia. In pair wise comparisons, none of these were statistically significant. There was $p < .05$ for trend. This is a common tumor in mice (common is defined by Haseman (1983) as a spontaneous incidence of 1% or greater). Statistical significance has been recommended by Haseman at $p < .01$ rather than $< .05$ because of the wide variations that can occur in the incidence of these common tumors. This consideration of using $p < .01$ rather than .05 has been adopted internationally in the pharmaceutical industry and is incorporated into the ICH Guidelines. These guidelines are used by the US FDA and drug evaluation regulatory agencies around the world. It has also been used by agencies involved in other types of chemicals. Applying this rule to the thyroid tumors seen in the mouse study with TBA would indicate that this is not statistically significant, and thus there is no significant tumor incidence in the mice. Furthermore, although extensive studies have not been performed to evaluate the effects of TBA on thyroid and thyroid-related hormones, it is well known that in rats in particular, but also in mice, that the quantitative aspects of thyroid homeostasis differ between rodents and humans (Meek et al., 2003; IARC, 1999; Hill et al., 1989). This is largely because of the presence of thyroid-binding globulin in humans as well as a larger reserve of thyroid hormone in the follicle material of the thyroid itself. Furthermore, all of the modes of action that have been identified for non-genotoxic chemicals producing thyroid follicular tumors in rodents have involved hypothyroidism, TSH stimulation, and consequent increased cell proliferation of the follicle cells. This is true regardless of what causes the decrease in circulating thyroid hormone (T3 and/or T4), whether due to increased metabolism of the circulating thyroid hormone or direct thyrotoxicity, the end result is an increase in pituitary secretion of TSH and consequent increase of thyroid follicular proliferation and ultimately tumors. However, extensive epidemiology studies have been performed in

humans examining various types of hypothyroidism, including iodine deficiency, and there does not appear to be any relationship between hypothyroidism and an increase in follicular thyroid tumors in humans. The only known carcinogen for the human thyroid is radiation. Thus, there is no statistical significance in the incidence of thyroid tumors in the mice, and even if there was, the findings would not be relevant to humans.

REFERENCES

Acharya, S., Mehta, K., Rodrigues, S., Pereira, J., Krishnan, S., Rao, C.V. (1995). Administration of subtoxic doses of t-butyl alcohol and trichloroacetic acid to male Wistar rats to study the interactive toxicity. Toxicol Lett 80(1): 97-104.

Acharya, S., Mehta, K., Rodrigues, S., Pereira, J., Krishnan, S., Rao, C.V. (1997). A histopathological study of liver and kidney in male Wistar rats treated with subtoxic doses of t-butyl alcohol and trichloroacetic acid. Exp Toxicol Pathol 49(5): 369-373.

Boobis, A. R., Cohen, S. M., Dellarco, V., McGregor, D., Meek, M. E., Vickers, C., Willcocks, D., Farland, W. (2006). IPCS framework for analyzing the relevance of a cancer mode of action for humans. Crit. Rev. Toxicol. 36(10): 781-792.

Boobis, A. R., Doe, J. E., Heinrich-Hirsch, B., Meek, M. E., Munn, S., Ruchirawat, M., Schlatter, J., Seed, J., Vickers, C. (2008). IPCS framework for analyzing the relevance of a noncancer mode of action for humans. Crit. Rev. Toxicol. 38(2): 87-96.

Borghoff, S. J., Lehman-McKeeman, L.D., Shor, B.G., Hard, G.C., Swenberg, J.A. (1993). Critique of R. Melnick's An alternative hypothesis on the role of chemically induced protein droplet (2u-globulin) nephropathy in renal carcinogenesis. Regul. Toxicol. Pharmacol. 18: 357-364.

Borghoff, S. J., Prescott,J.S., Janszen,D.B., Wong,B.A., Everitt,J.I. (2001). α2u-globulin nephropathy, renal cell proliferation, and dosimetry of inhaled *tert*-butyl alcohol in male and female F-344 rats. Toxicol Sci 61: 176-186.

Frazier, K. S., Seely, J. C., Hard, G. C., Betton, G., Burnett, R., Nakatsuji, S., Nishikawa, A., Durchfeld-Meyer, B., Bube, A. (2012). Proliferative and nonproliferative lesions of the rat and mouse urinary system. Toxicol. Pathol. 40(4 Suppl): 14S-86S.

Hard, G. C. and J. C. Seely (2005). Recommendations for the interpretation of renal tubule proliferative lesions occurring in rat kidneys with advanced chronic progressive nephropathy (CPN). Toxicol Pathol 33(6): 641-649.

Hard, G. C. and K. N. Khan (2004). A contemporary overview of chronic progressive nephropathy in the laboratory rat, and its significance for human risk assessment. Toxicol Pathol 32(2): 171-180.

Hard, G. C., Johnson, K. J., Cohen, S. M. (2009). A comparison of rat chronic progressive nephropathy with human renal disease-implications for human risk assessment. Crit Rev Toxicol 39(4): 332-346.

Hard, G. C., Bruner, R. H., Cohen, S. M., Pletcher, J. M., Regan, K. S. (2011). Renal histopathology in toxicity and carcinogenicity studies with tert-butyl alcohol administered in drinking water to F344 rats: a pathology working group review and re-evaluation. Regul Toxicol Pharmacol 59(3): 430-436.

Hard, G. C., Betz, L. J., Seely, J. C. (2012). Association of Advanced Chronic Progressive Nephropathy (CPN) with Renal Tubule Tumors and Precursor Hyperplasia in Control F344 Rats from Two-Year Carcinogenicity Studies. Toxicol Pathol 40(3): 473-481.

Hard, G. C., Banton, M. I., Bretzlaff, R. S., Dekant, W., Fowles, J. R., Mallett, A. K., McGregor, D. B., Roberts, K. M., Sielken, R. L., Jr., Valdez-Flores, C., Cohen, S. M. (2013). Consideration of rat chronic progressive nephropathy in regulatory evaluations for carcinogenicity. Toxicol Sci 132(2): 268-275.

Haseman, J. K. (1983). A reexamination of false-positive rates for carcinogenesis studies. Fundam Appl Toxicol 3(4): 334-339.

Hill, R. N., Erdreich,L. S., Paynter,O. E., Roberts,P. A., Rosenthal,S. L., Wilkinson,C. F. (1989). Thyroid follicular cell carcinogenesis. Fundam. Appl. Toxicol. **12**: 629-697.

IARC (1999). Consensus Report. International Agency for Research on Cancer. IARC Scientific Publications 147: 1-32.

Jennette, J. C., Olson, J. L., Silva, F. G., and D'Agati, V. D. Heptinstall's Pathology of the Kidney, Vol. 1 & 2, 2015.

Konishi, N. and J. M. Ward (1989). Increased Levels of DNA Synthesis in Hyperplastic Renal Tubules of Aging Nephropathy in Female F344/NCr Rats. Vet Pathol Online 26(1): 6-10.

Meek, M. E., Bucher, J. R., Cohen, S. M., Dellarco, V., Hill, R. N., Lehman-McKeeman, L. D., Longfellow, D. G., Pastoor, T., Seed, J., Patton, D. E. (2003). A framework for human relevance analysis of information on carcinogenic modes of action. Crit. Rev. Toxicol. 33(6): 591-653.

Melnick, R. L. (1992). An alternative hypothesis on the role of chemically induced protein droplet (2u-globulin) nephropathy in renal carcinogenesis. Regul. Toxicol. Pharmacol. 16: 111-125.

Melnick, R. L., Burns, K. M., Ward, J. M., Huff, J. (2012). Chemically exacerbated chronic progressive nephropathy not associated with renal tubular tumor induction in rats: an evaluation based on 60 carcinogenicity studies by the national toxicology program. Toxicol Sci 128(2): 346-356.

Melnick, R. L., Ward, J. M., Huff, J. (2013). War on Carcinogens: Industry Disputes Human Relevance of Chemicals Causing Cancer in Laboratory Animals Based on Unproven Hypotheses, Using Kidney Tumors as an Example. Int J Occup Environ Health 19(4): 255-260.

Murphy, W. M., Grignon, D. J., and Perlman, E. J. Tumors of the Kidney, Bladder and Related Urinary Structures. AFIP Atlas of Tumor Pathology, Series 4, Vol. 1, 2004, p. 241-362.

National Toxicology Program (NTP). Toxicology and Carcinogenic Studies of A-Butyl Alcohol in F344/N Rats and B6C3F1 Mice. NTP Technical Report Series No. 436, 1995.

Seed, J., Carney, E. W., Corley, R. A., Crofton KM., DeSesso, J. M.,Foster, P.M. and R. Kavlock, Kimmel, G,Klaunig, J., Meek, M. E., Preston, R. J., Slikker, W., Jr., Tabacova, S, William, G.M. (2005). Overview: Using Mode of Action and Life Stage Information to Evaluate the Human Relevance of Animal Toxicity Data. Crit. Rev. Toxicol. 35: 663-672.

Seely, J. C., Haseman, Joseph K., Nyska, Abraham, Wolf, Douglas C., Everitt, Jeffrey I., Hailey, James R. (2002). The Effect of Chronic Progressive Nephropathy on the Incidence of Renal Tubule Cell Neoplasms in Control Male F344 Rats. Toxicol Pathol 30(6): 681-686.

Sonich-Mullin,C., Fielder,R., Wiltse,J., Baetcke,K., Dempsey,J.,Fenner-Crisp,P., Grant,D., Hartley,M., Knaap,A., Kroese,D., Mangelsdorf,I., Meek,E., Rice,J.M., Younes,M. (2001). IPCS Conceptual Framework for Evaluating a Mode of Action for Chemical Carcinogenesis. Regul. Toxicol. Pharmacol. 34: 146-152.

Taal, M. W., Chertow, G. M., Marsden, P. A., Skorecki, K., Yu, A. S. L., and Brenner, B. M. Brenner and Rector's The Kidney. Ninth Edition, Vol., 1 & 2, 2012.

Travlos, G. S., Hard, G. C., Betz, L. J., Kissling, G. E. (2011). Chronic progressive nephropathy in male f344 rats in 90-day toxicity studies: its occurrence and association with renal tubule tumors in subsequent 2-year bioassays. Toxicol Pathol 39(2): 381-389.

Wu, X., Kong, X. P., Pellicer, A., Kreibicvh, G, Sun, T. T. Uroplakins in urothelial biology, function, and disease. Kidney Int. 75(11): 1153-1165.