A 01

CODING FORMS FOR SRC INDEXING

Microfiche No.		
OTS0559858		
New Doc ID	Old Doc ID	
88000000051S	8EHQ-1299-14611S	
Date Produced	Date Received	TSCA Section
12/10/99	12/13/99	8E
Submitting Organization		
BAYER CORP		
Contractor		
BAYER AG, TOX LAB		
Document Title		
INITIAL SUBMISSION: TSCA HLTH & SFTY STUDY CVR SHT W/CONTIN SHT RE PRELIM HISTOPATH EVAL IN SUBCHRONIC INHALATION DOG STUDY OF STROBILURIN [], W/ATTCHMT & DATED 121099 (SANITIZED)		
Chemical Category		
STROBILURIN (CONFIDENTIAL)		

A 03

TSCA HEALTH & SAFETY STUDY COVER SHEET

8EHQ-1299-14611S

TSCA CBI STATUS:

-CHECK IF THIS PAGE CONTAINS CONFIDENTIAL BUSINESS INFORMATION (CBI)

Clearly mark the confidential information with bracketing and check the box in the appropriate section (☐ *Contains CBI*)
Submit a sanitized cover sheet with CBI deleted. Mark the sanitized copy, "Public Display Copy" in the heading.

RECEIVED OPPT NCIC 1999 DEC 13 AM 11:52

1.0 SUBMISSION TYPE ☐ *Contains CBI*

8(d) X 8(e) ☐ FYI ☐ 4 ☐ OTHER: Specify_____

-XX- Intial Submission -Follow-up Submission ☐ Final Report Submission

Previous EPA Submission Number or Title if update or follow-up:

☐ continuation sheet attached

2.1 SUMMARY/ABSTRACT ATTACHED (may be required for 8(e): optional for §4, 8(d) & FYI)	2.2 SUBMITTER TRACKING NUMBER OR INTERNAL ID	2.3 FOR EPA USE ONLY
X - YES NO	Cert# P 917006945 99-2-79	

3.0 CHEMICAL/TEST SUBSTANCE IDENTITY -*Contains CBI*

Reported Chemical Name (specify nomenclature if other than CAS name):

CAS#: Not yet assigned

Purity _____%

- Single Ingredient

☐ Commerical/Tech Grade

-Mixture *Trade Name:* _ *Common Name:* Strobilurin___

PUBLIC COPY

4.0 REPORT/STUDY TITLE - *Contains CBI*

Preliminary Micropathology data from a Subchronic Dog Toxicity Study – Study #

☐ Continuation sheet attached

5.1 STUDY/TSCATS INDEXING TERMS

[CHECK ONE]

HEALTH EFFECTS (HE): X ENVIRONMENTAL EFFECTS (EE):_____ ENVIRONMENTAL FATE (EF):_____

5.2 STUDY/TSCATS INDEXING TERMS (see instructions for 4 digit codes)

STUDY TYPE: TOX	SUBJECT ORGANISM (HE, EE only): DOGS	ROUTE OF EXPOSURE (HE only):____	VEHICLE OF EXPOSURE (HEonly)__
*Other:*_____	Other:_____	*Other:*_____	*Other:*___

6.0 REPORT/STUDY INFORMATION ☐ *Contains CBI* - Study is GLP

Laboratory Bayer AG – Tox Lab Report/Study Date: N/A

Source of Data/Study Sponsor (if different than submitter) Bayer AG Number of pages 1

☐ continuation sheet attached

RECEIVED OPPT NCIC 00 JAN 11 AM 9:56

7.0 SUBMITTER INFORMATION ☐ *Contains CBI*

Submitter: Donald W. Lamb, Ph.D Title: V. P., Prod. Safety & Reg. Affrs Phone: 412-777-7431

Company Name: Bayer Corporation Company Address: 100 Bayer Road

Pittsburgh, PA 15205-9741 Submitter Address (if different): _____

Technical Contact: Donald W. Lamb, Ph.D Phone: (412)777-7431

☐ continuation sheet attached

8.0 ADDITIONAL/OPTIONAL STUDY COMMENTS - *Contains CBI*

Company Sanitized

☐ continuation sheet attached

Submitter Signature: Donald W. Lamb **Date:** 12/10/99

Page 1 of 2

8EHQ-99-14611
88000000051S
[illegible]

MR 29783

A 04

9.0 CONTINUATION SHEET

TSCA CBI STATUS:

☐ CHECK IF THIS PAGE CONTAINS CONFIDENTIAL BUSINESS INFORMATION (CBI)

Clearly mark the confidential information with bracketing and check the box in the appropriate section (☐ Contains CBI). Submit a sanitized cover sheet with CBI deleted. Mark the sanitized copy, "Public Display Copy" in the heading

Submitter Tracking Number/Internal ID

P917006945
99-2-79

CONTINUED FROM COVER SHEET SECTION #____2.1_____

Based on the damage to the kidney, preliminary data from this subchronic dog study is being reported.

Abstract

A preliminary micropathology evaluation was performed on the following potential target organs from all dogs on study: liver, kidney, pituitary, thyroid, bone marrow and heart. Lesions suggestive of a compound relationship were observed in the liver and kidney.

The liver lesion consisted of a hepatocytomegaly and affected the males and females from the 800 and 2500 ppm dose groups (M: 0,0,3,4; F: 0,0,3,4). [1] The hepatocytomegaly was characterized by an enlargement of the hepatocytes resulting in a narrowing of the sinusoids. The hepatocyte cytoplasm was more ground-glass in appearance compared to that of the control dogs, which displayed a slight to moderate background accumulation of glycogen material. The liver lesion was compatible with the clinical pathology findings of liver enzyme induction (all dose groups) and the liver weight increases in the 800 and 2500 ppm male and female dogs.

The kidney lesion consisted of a degeneration of the proximal tubular epithelial cells, and was confined to the mid- to deep renal cortices. The location of the affected tubules suggests that the lesion may be confined to the P3 segment of the proximal tubules. The proximal tubular degeneration occurred only in the male dogs and spanned all dose groups (M: 0,1,1,3). As depicted in the attached photographs (Figures 1-4), the renal lesion consisted of a minimal to mild cellular swelling resulting in enlargement of the tubular epithelium, causing the nuclei to be more widely spaced apart. Additionally, the cells were less confluent compared to that of the control animals; the cell shape was more rounded and the cell borders were more distinct. Rarely individual cell necrosis was observed (not shown in the photographs), characterized by shrunken cells with eosinophilic cytoplasm and nuclear pyknosis; these findings lended evidence to the degenerative nature of this lesion.

Due to the minimal to mild nature of this lesion, there were no accompanying alterations in the clinical chemistry parameters relating to the kidney. However, there were increases in the relative kidney weights of the dogs with this microscopic alteration.

[1] Sex: Lesion incidence for the controls, 100, 800, and 2500 ppm dogs (4/sex/group).

PUBLIC COPY

A 05

Representative Photomicrographs of the Degenerative Kidney Lesion Observed in the Subchronic Dog Study with Study Number

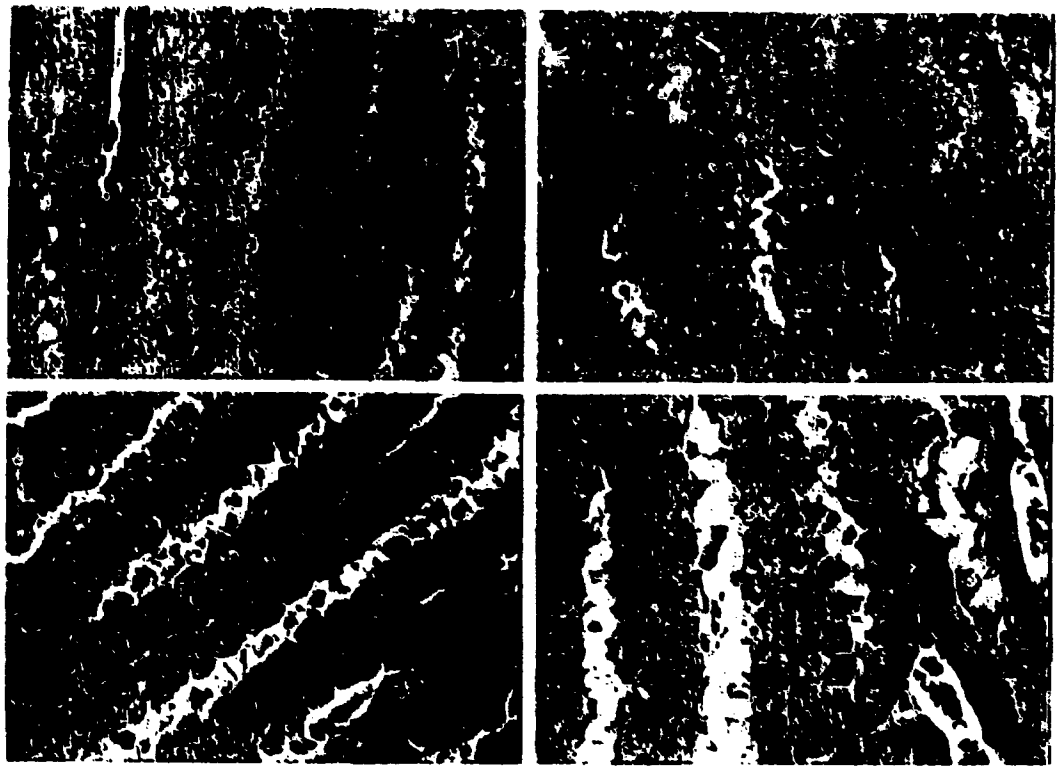

LEGEND

Top left: Male control dog AK0004: normal proximal tubular epithelium in the mid- to deep renal cortex. Note the height, number, and uniformity of the tubular epithelial cells. 400X, H&E.

Top right: 2500 ppm male dog AK3001:
Lower left: 800 ppm male dog AK2002:
Lower right: 100 ppm male dog AK1002:

All treated photomicrographs depict cellular swelling, resulting in enlargement of the tubular epithelial cells with increased distance between nuclei. Also note that the epithelial cells are rounding up and their borders are becoming more distinct.

PUBLIC COPY