"Contains NO CBI"

1987

MILES

1992 SEP -8 PM 1:27

OTS CBIC

Miles Inc.
Mobay Road
Pittsburgh, PA 15205-9741
Phone: 412 777-2000

August 17, 1992

8EHQ-92-12041
INIT 9/8/92
8892001028I

Document Processing Center (TS-790)
Office of Toxic Substances
Environmental Protection Agency
401 M Street, SW
Washington, DC 20460
Attention: Section 8(e) Coordinator
(CAP Agreement)

RE: 8E-CAP-0065

Dear Sir:

Miles Inc. is submitting a study under the TSCA Section 8(e) Compliance Audit Program (CAP Agreement 8E-CAP-0065).

The tested chemical in the attached document isbeta-(4-chlorophenoxy)-alpha-(1,1-dimethylethyl)-1H-1,2,4-triazole-1-ethanol and can be represented by the CAS Registry Number 55219-65-3.

The title of the accompanying document is KWG 0519 (Triadimenol, BAYTAN Active Ingredient) Chloronic Toxicological Study on Mice (Feeding Experiment Over Two Years) by B. Bomhard dated April 29, 1982.

The results in this study that may be considered reportable according to the TSCA 8(e) Reporting Guide include an elevated incidence of liver adenomas and hyperplastic nodules in females.

This compound has not been the subject of a previous TSCA Section 8(e) submission or premanufacture notification. This study has been sent to EPA under FIFRA as a registered pesticide.

The information submitted in this report is not considered Confidential Business Information.

If you have any questions on this submission, please contact me.

Sincerely,

Donald W Lamb

Donald W. Lamb, Ph.D
Vice President
Product Safety and Regulatory Affairs
412-777-7431

1/31/95

BOX-2/4.CAP/vmk
Attachments
Certified Mail P 827 215 558

EHR FILE
No. 1503

82291

BAYER AG
INSTITUTE OF TOXICOLOGY

Wuppertal, 29.4.1982

Report no.: 10855

Confidential

Copyright by Bayer AG
the use, utilisation or distribution
is only permitted with the consent
of Bayer AG.

KWG 0519

(Triadimenol, Baytan(R) active ingredient)

CHRONIC TOXICOLOGICAL STUDY ON MICE

(Feeding experiment over two years)

by
Dr. E. Bomhard
and
Dr. E. Löser

In the appendix: histopathology report by

Dr. S. C. Saxena and Dr. H. Ehard
Batelle-Institut e.V. Frankfurt/Main

BAYER AG

BAYER AG

BAYER AG

Reproduction of all or part of this report is not permissible.
If necessary, further copies can be obtained from the authors.

Confidential

Copyright by Bayer AG
the use, utilisation or distribution is only permitted with the consent of Bayer AG.

INDEX

		Page
1.	SUMMARY	2
2.	INTRODUCTION	3
3.	MATERIAL AND METHODS	4
4.	RESULTS	10
4.1.	General examinations	10
4.1.1	Appearance and behaviour of the mice	10
4.1.2	Food and test compound intake	10
4.1.3	Body weights	11
4.1.4	Mortality rate	11
4.2	Clinical lab tests	15
4.2.1	Hematology	15
4.2.2	Clinical-chemical tests	18
4.3	Gross pathology	23
4.3.1	Autopsies on the mice which died during the study or were moribund and sacrificed	23
4.3.2	Autopsies on the animals sacrificed at end of study	23
4.3.3	Organ weights	23
4.4	Histopathological tests	23
4.4.1	Non-blastomatous alterations	25
4.4.2	Blastomatous alterations	25
5.	DISCUSSION AND EVALUATION OF THE RESULTS	29
6.	REFERENCES	31
7.	KEY AND GERMAN TRANSLATIONS FOR ABBREVIATIONS IN THE TABLES	32
8.	APPENDIX	
	for index see Appendix cover page	
	001 - 151	
	histopathology report attached	

BAYER AG

Confidential

Copyright by Bayer AG
the use, utilisation or distribution is only permitted with the consent of Bayer AG.

1. SUMMARY

1.1. 50 male and 50 female mice were administered KWG 0519 for 24 months in their food, in the following concentrations: 0 (control), 125, 500 and 2,000 ppm.

1.2. Appearance, behaviour, food intake and mortality rates of the male and female mice were not affected in the dose groups up to 2,000 ppm incl. Growth was slightly retarded for the male and female mice after 500 and 2,000 ppm.

1.3. There was no blood damage due to KWG 0519 in doses up to 2,000 ppm.

1.4. The male and female mice in the 125 and 500 ppm dose groups suffered no liver damage according to clinical chemistry, gross pathology and histopathology. Increased enzyme activity in the plasma (ALP, GOT, GPT), increased liver weights, and also a higher incidence of hyperplastic liver nodules in some cases after 2,000 ppm are considered a consequence of treatment.

1.5. Clinical chemistry, gross pathology and histopathology gave no indication of kidney damage in the dose groups up to 2,000 ppm incl.

1.6. In all the groups, blood sugar concentrations in the plasma were in the normal range, and also the cholesterol concentration in the 125 and 500 ppm groups. Significantly lower cholesterol values after 2,000 ppm may have been connected with the treatment.

1.7. Histopathological tests revealed a higher incidence of cystic alterations in the thyroids of the male mice in the 2,000 ppm dose group.

1.8. Gross pathology and histopathology of the other organs gave no indications of treatment-induced alterations in any dose group .

1.9. The type, localization, incidence and time of occurrence of tumors observed gave no indication of oncogenic effects.

1.10. The dose of 125 ppm was therefore tolerated without damage.

Confidential

Copyright by Bayer AG
the use, utilisation or distribution
is only permitted with the consent
of Bayer AG.

2. INTRODUCTION

KWG 0519 is an active ingredient with fungicidal properties, and has the following structural formula.

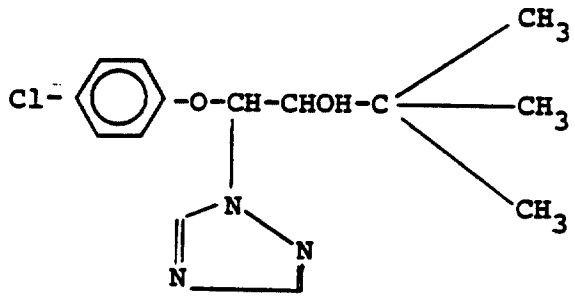

Chemical name: ß-(4-chlorophenoxy)-α-(1,1-dimethylethyl)-1 H-1,2,4-triazole-1-ethanol

Common name: triadimenol

We conducted a toxicity study on male and female mice with KWG 0519, study no. KWG 0519/006. The results are reported in the following.

BAYER AG

Confidential

Copyright by Bayer AG
the use, utilisation or distribution
is only permitted with the consent
of Bayer AG.

3. MATERIAL AND METHODS

3.1. Test compound sample

The toxicological study was conducted with an 80 % pre-mix of a technical grade sample in batch no. 16004/77 (received 1/78; purity approx. 95 %) in Wessalon S (precipitated synthetic silica, Degussa Co., X-ray amorphous).

3.2. Experimental animals and their housing and feeding

We conducted the feeding experiment with SPF mice (strain CF_1/W 74, breeder Winkelmann, Borchen). At the start of the study the mice were approx. 5 to 6 weeks old. The males had an average starting weight of 26 g and the females 20 g. The animals were kept singly and conventionally in Makrolon cages type I (SPIEGEL and GÖNNERT, 1961) on dust-free wood granules at a room temperature of 22 $\pm$ 1.5° C, a relative humidity of approx. 60 % $\pm$ 5 % and with a twelve hour light/dark rhythm (artificial light from 7 am to 7 pm CET). During the study the animals' cages were changed weekly, and fresh pulverised food (Altromin 1321, manufacturer: Altromin GmbH, Lage) and tap water was provided ad libitum. The animals were identified by cage marks.

3.3. Duration of study

The study lasted 24 months (July 1978 to July 1980).

3.4. Application route, dosages and study groups

We mixed KWG 0519 in the following concentrations in the pulverised food.

Confidential

Copyright by Bayer AG
the use, utilisation or distribution
is only permitted with the consent
of Bayer AG.

0 (control)	ppm
125	ppm
500	ppm
2,000	ppm

There were 50 male and 50 female mice in each group for each dose.

At the start of the study male and female mice were distributed throughout the groups with the aid of a random list. The animals were then numbered consecutively.

3.5. Food analyses

The test compound's stability in mouse feed over the study period was ascertained by analyses at the start of the study.
The test compound content in the feed mixture was analysed at regular intervals.

3.6. General examinations

3.6.1. Inspection of the experimental animals
The experimental animals were inspected daily and alterations and symptoms logged.

3.6.2. Determination of body weight and food intake
The animal's body weights were determined weekly, and from the 15th study week every three weeks. The weekly food intake was determined by weighing the uneaten food.

Confidential

Copyright by Bayer AG
the use, utilisation or distribution
is only permitted with the consent
of Bayer AG.

3.7. Clinical lab tests

Clinical lab tests were carried out twelve months after the start of feeding and at the end of the study on ten male and ten female mice for each dose group. Blood for the blood sugar test was taken from unnarcotised, and for the other determinations from ether-narcotised animals, from the retro-orbital venus plexus (according to NÖLLER, 1955).

3.7.1. Haematological tests

Erythrocyte, leucocyte and thrombocyte counts, MCV and haemoglobin levels: by Coulter Counter.
Differential blood count: by light microscopy with smears (staining according to Wright modified).
Reticulocyte count: by light microscopy after staining with brilliant cresyl blue.
Haematocrit, MCH and MCHC: by Coulter Counter.

3.7.2. Clinical-chemical tests

Enzymes in the plasma:

alkaline phosphatase (ALP) as recommended by the Deutsche Gesellschaft für Klinische Chemie (1972)

glutamate oxalacetate transaminase (GOT), optimised, as recommended by the Deutsche Gesellschaft für Klinische Chemie (1972)

glutamate pyruvate transaminase (GPT), optimised, as recommended by the Deutsche Gesellschaft für Klinische Chemie (1972)

Substrates in the plasma:

creatinine according to FABINY and ERTINGSHAUSEN (1971)
urea according to GUTMANN and BERGMEYER (1974)
blood sugar according to SCHMIDT (1961)
cholesterol according to TRINDER (1969)
bilirubin according to JENDRASSIK and GROF (1938)
total protein according to WEICHSELBAUM (1946)

Confidential

Copyright by Bayer AG
the use, utilisation or distribution is only permitted with the consent of Bayer AG.

3.8. Gross pathology

3.8.1. Autopsies on mice which died during the study, or were moribund and sacrificed

The mice which died during the study, or were moribund and sacrificed, were dissected and grossly examined, and the organs and alterations which seemed suitable for evaluation were fixed in 10 % formaldehyde.

3.8.2. Autopsies on the mice sacrificed at the end of the study

At the end of the study all the surviving animals were narcotised with diethyl ether and sacrificed by exsanguination. The animals were then dissected and grossly examined. We determined the weights of the following organs from the sacrificed mice: heart, lung, liver, spleen, kidneys, and testicles. The weighed organs, and in addition brain, pituitary, thyroid, adrenals, stomach, pancreas, urinary bladder, ovaries and uterus, femur with skeletal muscles and N. ischiadicus, also all grossly identified alterations were fixed in 10 % buffered formaldehyde.

3.9. Histopathological examinations

The above organs and tissue from the animals moribund and sacrificed during the study, or which died, or which were sacrificed at the end of the experiment were sent to the Batelle-Institut, Frankfurt/Main for histopathological examination.

Details of histological techniques and staining methods are given in the appended report.

Confidential

Copyright by Bayer AG
the use, utilisation or distribution is only permitted with the consent of Bayer AG.

3.10. Statistics

The following were computed: arithmetical group means, standard deviation s, upper and lower confidence limits on the confidence level of 1 - alpha = 95 % and 1 - alpha = 99 %.

The values for the test group and the control group were compared with the significance test (U test) according to MANN,WHITNEY and WILCOXON on the significance level alpha = 5 % and alpha = 1 %.

The mortality rates of the treated groups were, along with the tumor rates, compared with the aid of the exact Fisher test on the significance level alpha = 5 % and alpha = 1 % with the control group.

Significant differences to the control group are marked in the mean tables in the report for $p < 0.05$ with one asterisk (*) and for $p < 0.01$ with two asterisks (**).

The IBM 370/145 computer was used.

The random lists were produced with the Subprogram Randu from the IBM Scientific Subroutine Package on the IBM 370 computer.

3.11. Records

All the records (for example raw data, histological sections, blood smears, blocks, organ specimens and report) have been filed in the BAYER AG Institute of Toxicology.

Confidential

Copyright by Bayer AG
the use, utilisation or distribution
is only permitted with the consent
of Bayer AG.

3.12. Participants in the study

Study directors	Dr. Bomhard, Dr. Löser
Haematology, clinical chemistry	Dr. Frank
Gross pathology	Dr. Krötlinger
Histopathology	Dr. Saxena, Dr. Ehrd
Statistics	Dipl. Math. Bambynek
Feed analyses	Dr. Blass
Records and data checks	Dipl. Biol. De backer

BAYER AG
BAYER AG
BAYER AG

Confidential

Copyright by Bayer AG
the use, utilisation or distribution
is only permitted with the consent
of Bayer AG.

4. RESULTS

(Means with standard deviations and results of the statistical calculations and single figures are detailed in the appendix)

4.1. General examinations

4.1.1. Appearance and behaviour of the mice

During the study the mice receiving KWG 0519 in doses of 125 to 2,000 ppm in their feed did not differ in appearance and behaviour from the control animals. There were no differences in liveliness and condition of pelt for the mice in these dose groups.

4.1.2. Food and test compound intake

The following Table 1 gives the mice's mean food consumption in each dose group for the total study period and per day. The mean quantity of total active ingredient consumed is also indicated.

Tabelle 1/Table 1	DOSIS / DOSE (PPM)			
	0	125	500	2000
MAENNLICH/MALE				
FUTTERAUFNAHME / FOOD CONSUMPTION				
G/TIER	7021	7041	7089	7309
G/TIER/TAG	10	10	10	10
WIRKSTOFFAUFNAHME / INTAKE OF ACTIVE INGREDIENT				
G/TIER		0.88	3.54	14.62
G/KG KGW		25.56	105.92	458.53
G/KG KGW/TAG		0.03	0.14	0.62
WEIBLICH/FEMALE				
FUTTERAUFNAHME / FOOD CONSUMPTION				
G/TIER	7689	7730	7603	7454
G/TIER/TAG	10	11	10	10
WIRKSTOFFAUFNAHME / INTAKE OF ACTIVE INGREDIENT				
G/TIER		0.97	3.80	14.91
G/KG KGW		36.99	148.72	598.49
G/KG KGW/TAG		0.05	0.20	0.81

Confidential

Copyright by Bayer AG
the use, utilisation or distribution
is only permitted with the consent
of Bayer AG.

As may be seen from these figures, the male and female mice in all treatment groups consumed about the same quantity of pulverised feed as the control animals.

4.1.3. Body weights

Figs. 1 and 2 (pages 12 and 13) show the curves of the mean body weights of the male and female mice in relation to study period.

As graphs 1 and 2 show, the male and female mice in the 125 ppm study group made about the same gain in weight as the control animals. Temporary significant differences from the control group in this dosage are not attributed to treatment, as the weight differences were very slight. After 500 ppm the male and female mice usually had significantly lower body weights during the first study year, and the same was true of the majority of weighings after 2,000 ppm.

4.1.4. Mortality rate

Table 2 (page 14) gives the mortality rates at 12, 18 and 24 months of the experiment, separately for dose and sex. The cumulative mortality rates over the entire time of the study are detailed in figs. 3 and 4 (see appendix).

BAYER AG

Vertraulich
Eigentum der Firma Bayer AG
Benutzung, Verwertung oder Weitergabe nur mit Einwilligung der Bayer AG gestattet

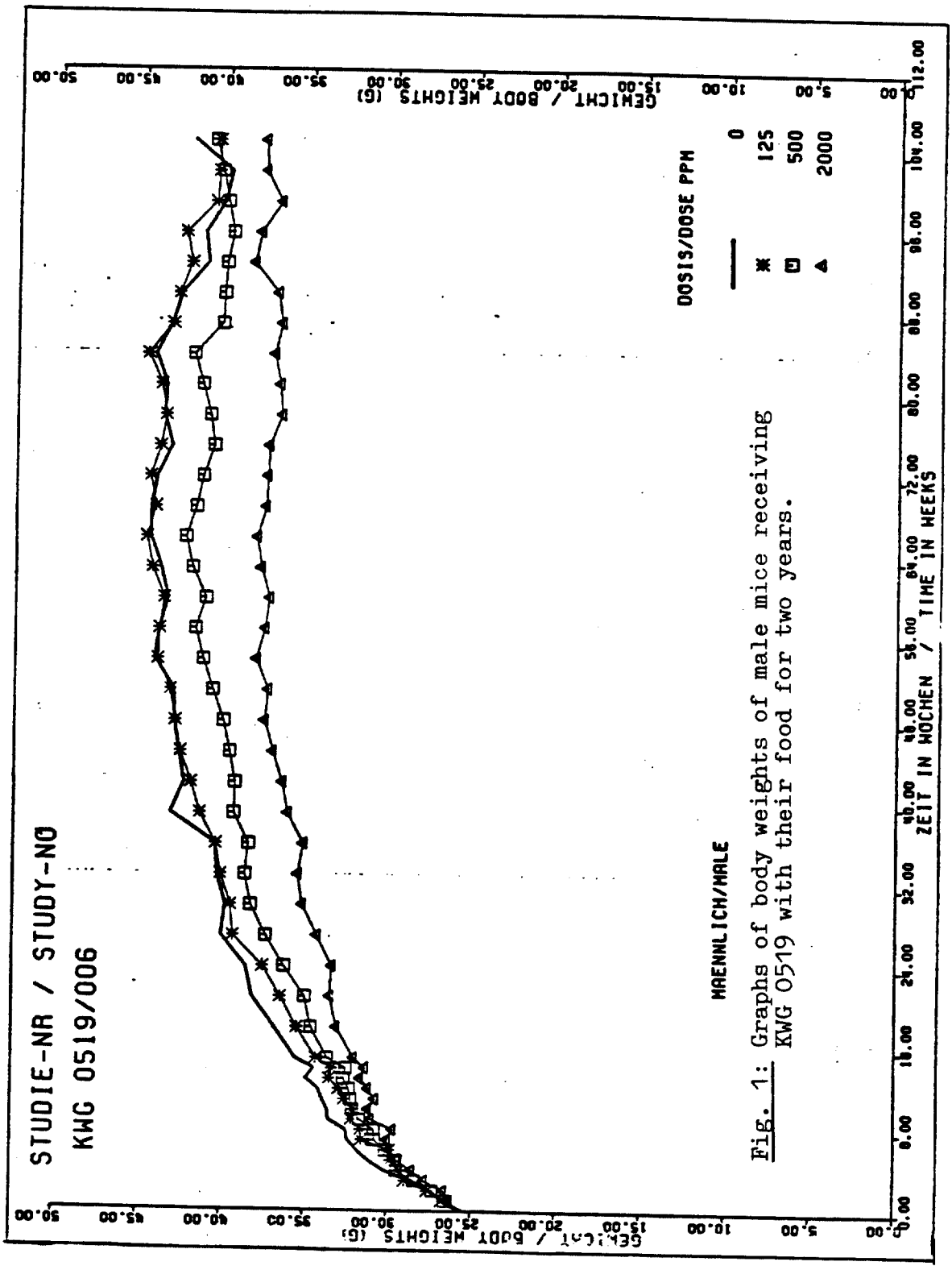

Fig. 1: Graphs of body weights of male mice receiving KWG 0519 with their food for two years.

Vertraulich
Eigentum der Firma Bayer AG
Benutzung, Verwertung oder Weitergabe nur mit Einwilligung der Bayer AG gestattet

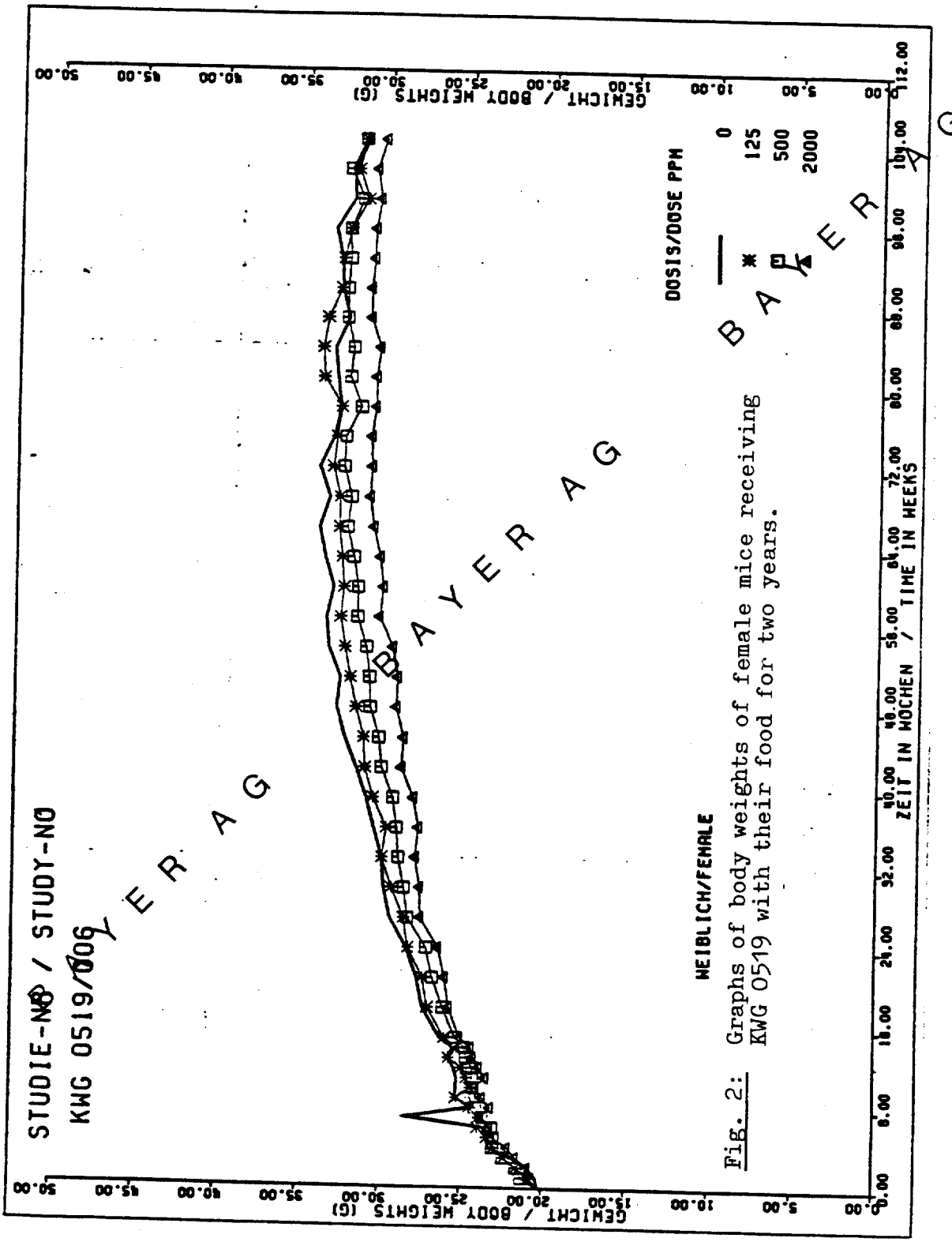

Fig. 2: Graphs of body weights of female mice receiving KWG 0519 with their food for two years.

Confidential

Copyright by Bayer AG
the use, utilisation or distribution
is only permitted with the consent
of Bayer AG.

Tabelle 2 /Table 2

STERBLICHKEIT / MORTALITY			
DOSE DOSIS PPM	NUMBER USED EINGESETZTE TIERE	NUMBER DIED VERENDETE TIERE	MORTALITY STERBLICH KEIT %
12 MONATE / 12 MONTHS			
MAENNLICH/MALE			
0	50	4	8.0
125	50	2	4.0
500	50	3	6.0
2000	50	4	8.0
WEIBLICH/FEMALE			
0	50	3	6.0
125	50	7	14.0
500	50	2	4.0
2000	50	2	4.0
18 MONATE / 18 MONTHS			
MAENNLICH/MALE			
0	50	10	20.0
125	50	16	32.0
500	50	14	28.0
2000	50	13	26.0
WEIBLICH/FEMALE			
0	50	13	26.0
125	50	16	32.0
500	50	12	24.0
2000	50	13	26.0
24 MONATE / 24 MONTHS			
MAENNLICH/MALE			
0	50	38	76.0
125	50	39	78.0
500	50	37	74.0
2000	50	33	66.0
WEIBLICH/FEMALE			
0	50	34	68.0
125	50	34	68.0
500	50	33	66.0
2000	50	31	62.0

As may be seen from Table 2 and Figs. 3 and 4, the treatment had no effect on mortality.

Confidential

Copyright by Bayer AG
the use, utilisation or distribution
is only permitted with the consent
of Bayer AG.

4.2. Clinical lab tests

4.2.1. Haematology

The mean results of the haematological tests for the twelve months after start of the study for ten male and ten female mice are given in the following Tables 3 and 4 (page 16 and 17).

As may be seen from Table 3, the treated mice in the 125 to 2,000 ppm dose groups did not differ twelve months after start of the study either in erythrocyte, leucocyte and thrombocyte counts or in haemoglobin and haematocrit levels toxicologically significantly and in relation to dosage from the control animals. Likewise for the mean cell volume (MCV), the mean cellular haemoglobin level (MCA), and for the mean cellular haemoglobin concentration (MCHC) there were no differences in comparison to the control animals for these study groups which could be attributed to treatment. All the figures, including those deviating significantly and in some cases apparently in relation to dose, are entirely within the normal range for mice of this age.

The figures for the differential blood count (Table 4) indicate that the treatment had no significant effect on the proportions of the various cell types. The forms of the various cell types also did not result in any pathological findings.

The results of the haematological tests carried out at the end of the study are given in Tables 5 and 6 (page 17).

Tabelle 3/Table 3

BLUT-UNTERSUCHUNG / HAEMATOLOGY 12 MONATE / 12 MONTHS									
DOSE DOSIS PPM	ERY TERA/L	RETI 0/00	LEU GIGA/L	THROM GIGA/L	HGB G/L	HCT L/L	MCH PG/E	MCHC G/L	MCV FL
MAENNLICH/MALE									
0	8.62	29	7.1	1194	146	0.45	16.9	323	52
125	8.35	29	5.9	1044	146	0.45	17.4*	322	54*
500	8.40	29	4.6**	1117	147	0.46	17.4*	318	55**
2000	8.32**	30	4.9*	1238	149	0.46	17.9**	326	55*
WEIBLICH/FEMALE									
0	8.66	35	4.9	917	155	0.45	17.9	342	52
125	8.22*	35	4.1	865	147	0.44	17.9	334	54
500	8.34*	34	3.4*	971	152	0.45	18.2	339	54
2000	7.98**	32	3.4*	867	150	0.44	18.8**	339	56**

Tabelle 4/Table 4

DIFFERENTIALBLUTBILD / DIFFERENTIAL BLOOD COUNT (%) 12 MONATE / 12 MONTHS								
DOSE DOSIS PPM	BASO	EOSIN	IPC JGL	STAB	SEGM	LYM	MONO	PLAS
MAENNLICH/MALE								
0	0.0	0.9	0.0	0.0	20.1	79.0	0.0	0.0
125	0.0	1.0	0.0	0.0	22.1	76.9	0.0	0.0
500	0.0	0.5	0.0	0.0	21.8	77.7	0.0	0.0
2000	0.0	0.7	0.0	0.0	23.4	75.9	0.0	0.0
WEIBLICH/FEMALE								
0	0.0	0.2	0.0	0.0	15.4	84.4	0.0	0.0
125	0.0	0.4	0.0	0.0	15.0	84.6	0.0	0.0
500	0.0	0.1	0.0	0.0	17.9	82.0	0.0	0.0
2000	0.0	0.1	0.0	0.0	15.8	84.1	0.0	0.0

Confidential
Copyright by Bayer AG
the use, utilisation or distribution
is only permitted with the consent
of Bayer AG.

Tab. 5

BLUT-UNTERSUCHUNG / HAEMATOLOGY
24 MONATE / 24 MONTHS

DOSE DOSIS PPM	ERY TERA/L	RETI 0/00	LEU GIGA/L	THROM GIGA/L	HGB G/L	HCT L/L	MCH PG/E	MCHC G/L	MCV FL
MAENNLICH/MALE									
0	8.69	10	6.1	1169	145	0.452	16.7	321	52
125	8.50	11	7.1	1012	139	0.446	16.3	312	53
500	8.91	12	5.8	1156	146	0.461	16.5	318	52
2000	8.66	7*	5.6	1186	146	0.454	17.0	324	53
WEIBLICH/FEMALE									
0	7.28	10	4.5	801	143	0.393	19.6	364	54
125	7.03	10	4.2	815	137	0.361*	19.6	382	51**
500	8.20**	9	4.3	943	141	0.433**	17.2**	326**	53
2000	7.37	12	4.8	952*	138	0.384	18.8	361	52*

Tab. 6

DIFFERENTIALBLUTBILD / DIFFERENTIAL BLOOD COUNT (%)
24 MONATE / 24 MONTHS

DOSE DOSIS PPM	BASO	EOSIN	IPC JGL	STAB	SEGM	LYM	MONO	PLAS
MAENNLICH/MALE								
0	0.0	1.0	0.0	0.2	29.5	69.3	0.0	0.0
125	0.0	0.7	0.0	0.2	33.0	66.0	0.1	0.0
500	0.0	0.6	0.0	0.5	32.4	66.5	0.0	0.0
2000	0.0	0.6	0.0	0.4	29.9	69.1	0.0	0.0
WEIBLICH/FEMALE								
0	0.0	0.9	0.0	0.4	26.1	72.6	0.0	0.0
125	0.0	1.9	0.0	0.7	20.5	76.9	0.0	0.0
500	0.0	0.9	0.0	0.1	14.7*	84.3**	0.0	0.0
2000	0.0	0.5	0.0	1.2	26.0	72.3	0.0	0.0

Confidential

Copyright by Bayer AG
the use, utilisation or distribution is only permitted with the consent of Bayer AG.

Confidential
Copyright by Bayer AG
the use, utilisation or distribution
is only permitted with the consent
of Bayer AG.

As Tables 5 and 6 show, there were also no indications of treatment-induced damage to the blood or blood-forming tissue at the end of the experiment for male and female mice in all the study groups. Individual statistically significant differences are toxicologically insignificant in view of the relatively high individual spreads in mice of this age.

However, the examination of the differential blood count for all the female mice in all the dose groups examined, and for one male mouse in each of the 125 and 500 ppm dose groups, also for nine males in the 2,000 ppm dose group revealed the presence of Jolly bodies. Some animals had in addition polychromasia (see relevant pages in the appendix). Subsequent additional tests (reticulocyte count and appraisal) and checks produced no explanation of these findings due to the fact that the smears had in the meantime faded. It could only be observed that the number of reticulocytes for mice of this age was abnormally low. Toxicological significance is not attributed to these findings, they may have resulted during the preparation of the smears.

4.2.2. Clinical-chemical tests

Twelve months after start of the study we determined the activities of the alkaline phosphatase (ALP) and the transaminases GOT and GPT, also the substrates bilirubin, total protein, urea, creatinine, cholesterol and blood sugar in the plasma. The mean results of these analyses are given in Table 7 (page 20). As may be seen from this table, the male mice after 2,000, and the female mice in all treatment groups showed significantly higher activities of GOT in the plasma than the control animals.

Confidential

Copyright by Bayer AG
the use, utilisation or distribution
is only permitted with the consent
of Bayer AG.

In addition, compared with the control group: after 2,000 ppm the GPT activities in the plasma were significantly higher and the cholesterol level was significantly lower for both sexes; for the males after 500 and 2,000 ppm the ALP was also significantly higher; only after 2,000 ppm was the total protein level significantly lower.

BAYER AG
BAYER AG
BAYER AG
BAYER AG

Confidential

Copyright by Bayer AG
the use, utilisation or distribution
is only permitted with the consent
of Bayer AG.

Tabelle 7/Table 7

KLIN.-CHEM. UNTERSUCHUNGEN / CLINICAL CHEMISTRY
12 MONATE / 12 MONTHS

DOSE DOSIS PPM	ALP U/L	GOT U/L	GPT U/L	BILI UMOL/L	PROT/P EIW/P G/L	UREA HST MMOL/L	CREA KREA UMOL/L	CHOL MMOL/L	GLUC MMOL/L
MAENNLICH/MALE									
0	89	30.8	52.9	1.7	59.3	9.29	42	2.87	8.20
125	90	29.2	69.3	2.2	58.2	10.33	39	2.76	8.80
500	100•	32.1	53.1	1.7	57.6	9.48	38	2.70	8.40
2000	133•	44.6••	98.1••	1.1	55.8•	10.11	40	1.64••	8.45
WEIBLICH/FEMALE									
0	137	37.4	33.8	1.8	57.2	9.73	41	2.34	7.91
125	143	52.8•	46.8	2.4	55.5	11.21	45	2.24	7.89
500	139	60.4••	61.4	2.4	55.6	9.49	38	2.16	8.33
2000	137	68.1••	81.4••	2.1	54.8	9.37	42	1.69••	7.90

Confidential

Copyright by Bayer AG
the use, utilisation or distribution is only permitted with the consent of Bayer AG.

The results of the clinical-chemical lab tests at end of study are compiled in Table 8 (page 22) as means.

As this table shows, after 2,000 ppm male and female mice had distinctly and significantly higher GOT and GPT activities in the plasma. After 500 ppm, the GOT and GPT activities were also slightly, but in some cases significantly higher. Only in the males receiving 2,000 ppm the cholesterol levels in the plasma were significantly lower at end of study. The remaining, and in some cases significant differences showed a distribution not related to dosage.

BAYER AG BAYER AG BAYER AG

Confidential

Copyright by Bayer AG
the use, utilisation or distribution
is only permitted with the consent
of Bayer AG.

Tabelle 8 /Table 8

KLIN.-CHEM. UNTERSUCHUNGEN / CLINICAL CHEMISTRY
24 MONATE / 24 MONTHS

DOSE DOSIS PPM	ALP U/L	GOT U/L	GPT U/L	BILI UMOL/L	PROT/P EIW/P G/L	UREA HST MMOL/L	CREA KREA UMOL/L	CHOL MMOL/L	GLUC MMOL/L
MAENNLICH/MALE									
0	198	37.5	53.7	2.3	57.9	9.00	40	3.49	7.91
125	427	54.0 •	71.4	2.7	56.2	8.54	35 •	2.51 •	7.45
500	308	58.2	88.0 •	2.8 •	60.6	9.18	34 ••	2.91	7.96
2000	695 ••	97.8 ••	159.4 ••	2.3	54.0	9.05	33 ••	2.40 ••	7.82
WEIBLICH/FEMALE									
0	255	40.0	30.7	2.6	58.2	8.87	35	2.45	6.64
125	268	48.6	42.8	2.8	55.2	10.91 •	30 •	2.01	7.35
500	196	53.6 •	48.0 •	2.2	53.9 •	10.53	31 •	2.44	7.41 •
2000	628 ••	185.7 ••	283.5 ••	2.6	56.7	11.45 •	34	2.83	6.71

Confidential
Copyright by Bayer AG
the use, utilisation or distribution
is only permitted with the consent
of Bayer AG.

4.3. Gross pathology

4.3.1. Autopsies on the mice which died during the study or were moribund and sacrificed

All the mice which died during the study or were moribund and sacrificed were dissected. There was a higher incidence of enlarged or swollen livers, in some cases with nodules, in the 2,000 ppm dose group than in the other groups. The other findings did not indicate any connection with the treatment (the autopsy findings are on pages 122 to 142 in the appendix).

4.3.2. Autopsies on the animals sacrificed at end of study

The number of animals with swollen livers and/or nodular formations after 2,000 ppm was also increased at end of study. Other possibly substance-induced alterations were not observed (autopsy findings are on pages 143 to 151 in the appendix).

4.3.3. Organ weights

The mean organ weights of heart, lung, liver, spleen, kidneys and testicles established at end of experiment are detailed in the following Table 9 (page 24). The corresponding relative organ weights (per 100 g body weight) are detailed in Table 10 (page 24).

As these tables show, the male and female mice's liver weights were significantly increased after 2,000 ppm. The remaining differences were not attributed to treatment due to their minor nature and random distribution.

4.4. Histopathological tests

These were carried out by Dr. S. C. Saxena and Dr. H. Ehard, Batelle-Institut (see report in appendix).

Confidential

Copyright by Bayer AG
the use, utilisation or distribution
is only permitted with the consent
of Bayer AG.

Tabelle 9/Table 9

ABSOLUTE ORGANGEWICHTE / ABSOLUTE ORGAN WEIGHTS (MG)							
DOSE DOSIS PPM	BODY-W TIER-G (G)	HEART HERZ	LUNG LUNGE	LIV LEB	SPLE MILZ	KIDN NIE	TEST HO
MAENNLICH/MALE							
0	42	218	249	2294	125	828	196
125	41	216	312	3164	208	781	190
500	41	196	256	2645	130	731	212 ns
2000	38 •	209	253	3449 ••	144	806	212 •
WEIBLICH/FEMALE							
0	31	140	224	1656	195	510	
125	32	147	292	1900	355	514	
500	32	141	252	1801	190	496	
2000	30	142	205	2865 ••	144 •	483	

Tabelle 10/Table 10

RELATIVE ORGANGEWICHTE / RELATIVE ORGAN WEIGHTS (MG/100G)							
DOSE DOSIS PPM	BODY-W TIER-G (G)	HEART HERZ	LUNG LUNGE	LIV LEB	SPLE MILZ	KIDN NIE	TEST HO
MAENNLICH/MALE							
0	42	519	595	5459	297	1976	469
125	41	537	844	7652	511	1934	474
500	41	483	661	6506	320	1799	512
2000	38 •	553	665 •	9047 ••	377	2131	565 ••
WEIBLICH/FEMALE							
0	31	451	724	5315	622	1642	
125	32	468	979	5978	1054	1630	
500	32	448	819	5690	593	1577	
2000	30	467	677	9086 ••	472 •	1587	

Copyright by Bayer AG
the use, utilisation or distribution
is only permitted with the consent
of Bayer AG.

The findings are summarised as follows.

4.4.1. Non-blastomatous alterations

The female animals in the 2,000 ppm dose group had a slightly increased number of livers with hyperplastic nodules (seven compared with two in the control group). For the males in this group there were more hyperplasias of the liver (five) than in the control group (two), also some more cystic alterations in the thyroid.

4.4.2. Blastomatous alterations

All the tissue suspected to be tumours identified by gross pathology in all the mice which died or were moribund and sacrificed during the study, and mice sacrificed at end of study was submitted for histopathological tests. The tumour types identified as neoplasia and additional ones detected by histopathology are detailed in Table 11 (pages 26 and 27) and in the histopathology report in the appendix (summary pages 9 to 11 and 02-17 / Appendix I and individual in Appendix III). These contain full details.

The tumour incidence revealed in these tables do not indicate a treatment-induced effect on total tumour incidence or on the number of mice with tumours in the groups up to and including 2,000 ppm.

In regard to the localisations of the tumours and the blastoma types it was ascertained that predominantly pulmonary carcinomas, malignant lymphomas and hepatocellular adenomas occurred, as is normal for mice of this strain.

There were in some cases quite substantial fluctuations in the incidence of these tumours from group to group, both a distinctly lower incidence occurring in treated groups (malignant lymphoma/males; pulmonary carcinoma/females), and a higher incidence (liver adenomas/females). The latter were increased statistically significantly after 2,000 ppm ($p \leq 0.05$).

Copyright by Bayer AG
the use, utilisation or distribution
is only permitted with the consent
of Bayer AG.

Table 11

Tumour incidence in male and female mice administered KWG 0519 with their food for two years

dose (ppm)	0	125	500	2000	0	125	500	2000
localisation/tumour type	male mice				female mice			
lung								
fibroma	0	0	0	1	0	0	0	0
carcinoma	20	17	10	14	10	14	15	6
liver								
adenoma/ cystic adenoma	6	4	5	8	0	0	4	6
adenocarcinoma	2	0	0	1	1	0	1	0
angiosarcoma	0	0	0	0	0	0	1	0
pancreas								
islet cell adenoma	1	0	1	0	0	0	0	0
thymus								
thymoma (b)	0	0	0	0	0	0	1	0
urinary bladder								
papilloma	0	0	0	0	1	0	0	0
carcinosarcoma	0	0	0	2	0	0	0	0
adrenal								
adenoma	3	6	3	3	0	2	0	2
phaeochromocytoma	0	2	0	1	0	0	0	1
thyroid								
adenoma	0	1	0	0	0	0	0	0
testicles								
interstitial cell tumour (b)	1	1	2	0	-	-	-	-
seminal vesicle								
mesenchymal tumour (m)	0	0	1	0	-	-	-	-
pituitary								
adenoma	0	0	0	0	0	0	1	0
mamma								
adenocarcinoma	0	0	0	0	2	0	0	0
ovary								
luteoma	-	-	-	-	1	2	3	2
arrhenoblastoma (b)	-	-	-	-	0	0	0	1
cystic adenoma	-	-	-	-	1	0	0	0

Confidential

Copyright by Bayer AG
the use, utilisation or distribution
is only permitted with the consent
of Bayer AG.

Table 11

Tumour incidence in male and female mice administered KWG 0519 with their food for two years

dose (ppm)	0	125	500	2000	0	125	500	2000
localization/tumour type	male mice				female mice			
uterus								
adenoma	-	-	-	-	0	0	0	1
adenocarcinoma	-	-	-	-	1	0	0	0
sarcoma	-	-	-	-	1	0	0	0
leiomyosarcoma	-	-	-	-	3	1	1	2
mesenchymal tumour (m)	-	-	-	-	1	0	1	1
cervix								
kerato-acanthoma	-	-	-	-	0	1	0	0
leiomyosarcoma	-	-	-	-	1	0	0	1
connective tissue								
lipoma	1	1	0	0	0	0	0	0
osteoma	1	0	3	1	0	1	3	2
fibromyxoma (m)	1	0	0	0	0	0	0	0
osteogenic sarcoma	0	0	0	0	1	0	1	2
fibrosarcoma	0	0	0	0	0	1	0	0
mesenchymal tumour (m)	0	0	0	0	1	0	0	0
reticulo-hystiocytary system (RHS)								
malignant lymphoma	17	6	6	10	18	17	23	18
reticulosarcoma	0	0	0	1	0	0	0	0
muscular tissue								
leiomyosarcoma	0	0	0	0	0	0	1	0
surface epithelial tissue								
squamous epithelial carcinoma	0	0	0	1	0	0	0	0
no. of tumours	53	38	31	43	43	39	56	45
of these malignant	40	23	17	29	40	33	44	30
no. mice with tumours	36	31	25	32	32	32	38	35
no. mice with over 1 tumour	14	6	5	10	10	6	15	10
no. mice with only benign	4	9	9	7	0	4	5	8
no. mice with only malignant	24	18	12	20	29	27	27	20
no. mice with benign and malignant	8	4	4	5	3	1	6	7

Confidential

Copyright by Bayer AG
the use, utilisation or distribution
is only permitted with the consent
of Bayer AG.

In view of the relatively wide spreads, and due to the fact that the incidence was still within the normal area of variation (as found in comparable parallel or earlier studies), this is not regarded as an indication of the test substance's oncogenic potential. For the other tumours and localisations, in most cases small in number, no accumulation specific to a group could be identified.

As comparison of the histopathological individual findings and the autopsy findings of mice dying or moribund and sacrificed concurrently reveals, the time at which the tumours arose was not affected by treatment either.

Confidential

Copyright by Bayer AG
the use, utilisation or distribution
is only permitted with the consent
of Bayer AG.

5. DISCUSSION AND EVALUATION OF THE RESULTS

Male and female mice were administered KWG 0519 for two years in doses of 0, 125, 500 and 2,000 ppm with their food.

Appearance, general behaviour, food intake and mortality rate were not affected by the treatment. The dosage of 125 ppm had no effect on the mice's growth. Significantly lower body weights were recorded after 500 ppm, primarily in the first study year, and after 2,000 ppm almost during the entire study period.

The haematological tests conducted during the study and at end of study gave no indication of damage to the blood or blood forming tissue in the group up to and including 2,000 ppm.

Periods of significantly higher GOT activities were recorded in the 125 and 500 ppm treatment groups, and in addition significantly higher GPT activities after 500 ppm at end of study. As all the individual values are within the relatively great area of variation for mice of these ages, and no morphological correlations were detected, they are not considered indications of an adverse effect on liver function. On the other hand, the distinctly higher ALP, GOT and GPT activities in the 2,000 ppm dose group especially at end of study, together with the significantly higher liver weights and the higher incidence of partly nodular hyperplasias should be considered an index of treatment-induced liver stress. The markedly lower cholesterol levels in the plasma after 2,000 ppm, especially after one study year, could be the consequence of a substance-induced effect on lipid metabolism.

In contrast no toxicological significance is attributed to the significantly lower protein levels in the plasma of male mice after twelve months, as the figures are within the normal area of variation for this parameter.

Confidential

Copyright by Bayer AG
the use, utilisation or distribution
is only permitted with the consent
of Bayer AG.

Clinical-chemical, pathological-anatomical and histopathological examinations gave no indication of damage to kidneys and efferent urinary tract organs.

The results of the histopathological examination revealed higher numbers of cystic alterations in the thyroid for male mice in the 2,000 ppm dose group. There were no signs of effect on this organ in the females in this dosage and in the other groups.

The blood sugar level in the plasma was not affected by treatment.

Gross pathology and histopathological examination of the other organs produced no evidence of substance-induced damage.

The type, localisation, incidence and time of occurrence of the tumours identified gave no indication of oncogenic effect.

The dose of 125 ppm was therefore tolerated without damage by male and female mice under the conditions described.

(Prof. Dr. D. Lorke)	(Dr. E. Bomhard)	(Dr. E. Löser)
Head and Director of Institute	Study Director	Study Director

Checked by
Inst. of Toxicology
Archive
19.4.82

Confidential
Copyright by Bayer AG
the use, utilisation or distribution
is only permitted with the consent
of Bayer AG.

6. LITERATUR/REFERENCES

FABINY, D. und ERTINGSHAUSEN, G.
Clin. Chem. 17 (8), 696, 1971

GUTMANN, I. und BERGMEYER, H.U. in: H.U. BERGMEYER
Methoden der enzym. Analyse, 3. Aufl., Bd. II,
Verlag Chemie Weinheim 1974

JENDRASSIK, L. und GROF, P.
Biochem. Zschr. 297, 81, 1938

NÖLLER, H.G.
Klin. Wschr. 33, 770, 1955

SCHMIDT, F.H.
Klin. Wschr. 39, 1244, 1961

SPIEGEL, A. und GÖNNERT, R.
Zschr. Versuchstierkunde 1, 38, 1961

TRINDER, P.
Ann. clin. Biochem. 6, 24, 1969

WEICHSELBAUM, T.E.
Amer. J. clin. Path. 16, 40, 1946

Empfehlung der Deutschen Gesellschaft für Klinische Chemie
Z. Klin. Chem. u. Klin. Biochem. 10, 182, 1972

BAYER AG

7. KEY AND GERMAN TRANSLATIONS FOR ABBREVIATIONS IN THE TABLES

7. LEGENDE ZU DEN ABKÜRZUNGEN IN DEN TABELLEN

MW	Mittelwert/Means
STAND	Standardabweichung/Standard deviation
TIER-NR/ ANIM.No.	Tier-Nummer/Animal number
W1	1. Woche/Week 1
ERY	Erythrozyten/Erythrocytes
LEU	Leukozyten/Leucocytes
THROM	Thrombozyten/Thrombocytes
HGB	Hämoglobin/Haemoglobin
HCT	Hämatokrit/Haematocrit
MCH	mittlerer corpusculärer Hämoglobingehalt/ mean corpuscular haemoglobin
MCHC	mittlere Zellhämoglobinkonzentration/ mean corpuscular haemoglobin concentration
MCV	mittleres Zellvolumen/mean corpuscular volume
THP	Thromboplastinzeit/Thromboplastin time
BASO	Basophile/Basophiles
EOSIN	Eosinophile/Eosinophiles
JGL/IPC	Jugendliche/Immature polymorphonuclear neutrophiles
STAB	stabkernige Neutrophile/Stab cells
SEGM	segmentkernige Neutrophile/Polymorphonuclear neutrophiles
LYM	Lymphozyten/Lymphocytes
MONO	Monozyten/Monocytes
PLAS	Plasmazellen/Plasma cells
ALP	Alkalische Phosphatase/Alkaline phosphatase
GOT	Glutamat-Oxalacetat-Transaminase/ Glutamate-oxaloacetate-transaminase
GPT	Glutamat-Pyruvat-Transaminase/Glutamate-pyruvate-transaminase
BILI	Bilirubin/Bilirubin
EIWP/PROT/P	Eiweiß im Plasma/Protein in Plasm
HST/UREA	Harnstoff/UREA nitrogen
KREA/CREA	Kreatinin/Creatinine
EIWH/PROTU	Eiweiß im Harn/Protein in Urine
CHOL	Cholesterin/Cholesterol
GLUC	Glukose/Glucose

Confidential
Copyright by Bayer AG
the use, utilisation or distribution
is only permitted with the consent
of Bayer AG.

TIER-G/BODY-W	Tiergewicht/Body weight
LEB/LIV	Leber/Liver
MILZ/SPLE	Milz/Spleen
NIE/KIDN	Nieren/Kidneys
NN/ADRE	Nebennieren/Adrenals
HO/TEST	Hoden/Testes

* Unterschied zur Kontrolle für $p < 0,05$ signifikant
difference against control: $p < 0,05$ significant
** Unterschied zur Kontrolle für $p < 0,01$ signifikant
difference against control: $p < 0,01$ significant
ns nicht signifikant/not significant

OG/UCL 1 % Obergrenze des Vertrauensbereiches des Mittelwertes auf dem Konfidenzniveau $1-\alpha = 99$ %/upper confidence limit of mean value at the confidence level of $1-\alpha = 99$ %

OG/UCL 5 % s.o. für Konfidenzniveau $1-\alpha = 95$ %/s.a. for $1-\alpha = 95$ %

UG/LCL 1 % Untergrenze des Vertrauensbereiches des Mittelwertes auf dem Konfidenzniveau $1-\alpha = 99$ %/lower confidence limit of mean value at the confidence level of $1-\alpha = 99$ %

UG/LCL 5 % s.o. für Konfidenzniveau $1-\alpha = 95$ %/s.a. for $1-\alpha = 95$ %

TS 1 % Testentscheid auf dem Signifikanzniveau $\alpha = 1$ %/test result at the $\alpha = 1$ % significance level

TS 5 % Testergebnis auf dem Signifikanzniveau $\alpha = 5$ %/test result at the $\alpha = 5$ % significance level

Special key for grosspathology report

LE = liver
KI = kidneys
AD = adrenal
OV = ovaries
UT = uterus
TE = testicles
SP = spleen
EP = epididymis
TH = thyroid
OE = oesophagus
PI = pituitary
TY = thymus
LU = lung
ST = stomach
UR = urinary bladder
SE = seminal vesicle
LY = lymph nodes

m.s. = moribund and sacrificed
n.f. = no findings
\+ = a few organs slightly autolytic
++ = some organs autolytic
+++ = most organs autolytic (gross appraisal possible)
++++ = complete corpus very autolytic

IN = intestine
PA = pancreas

8. APPENDIX

Pages

Mortality curves	001 - 002
Means with standard deviations and results of statistic calculations	003 - 029
Food consumption	030 - 045
Body weights, male mice	046 - 065
Body weights, female mice	066 - 085
Haematology	086 - 097
Clinical Chemistry	098 - 105
Absolute organ weights	106 - 113
Relative organ weights	114 - 121
Autopsy findings of animals died or sacrificed moribund during study	122 - 142
Autopsy findings of animals sacrificed at the end of the study	143 - 151
Histopathology report	

Vertraulich

Eigentum der Firma Bayer AG
Benutzung, Verwertung oder Weitergabe nur mit Einwilligung der Bayer AG gestattet

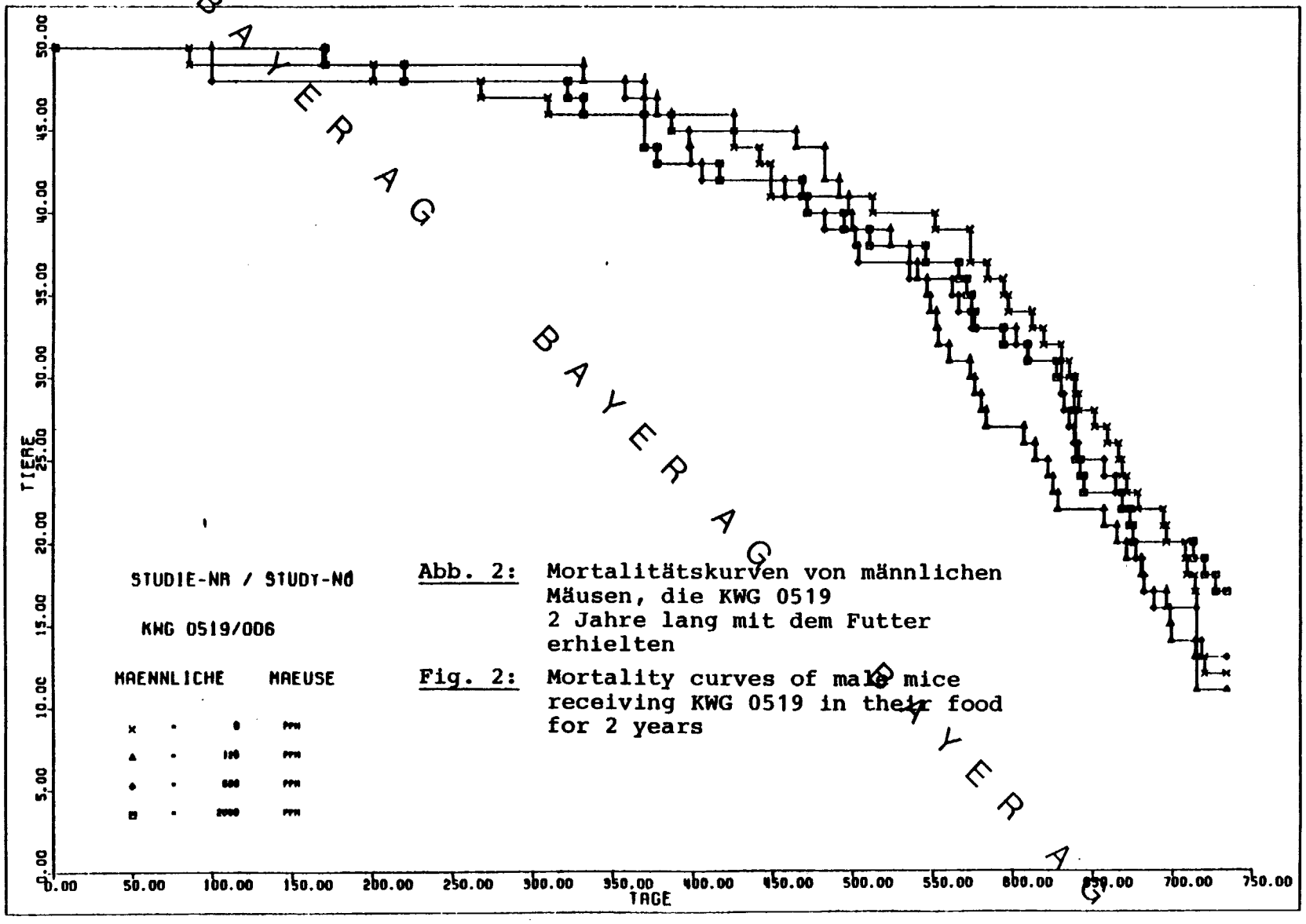

Abb. 2: Mortalitätskurven von männlichen Mäusen, die KWG 0519 2 Jahre lang mit dem Futter erhielten

Fig. 2: Mortality curves of male mice receiving KWG 0519 in their food for 2 years

001

Vertraulich

Eigentum der Firma Bayer AG
Benutzung, Verwertung oder Weitergabe nur mit Einwilligung der Bayer AG gestattet

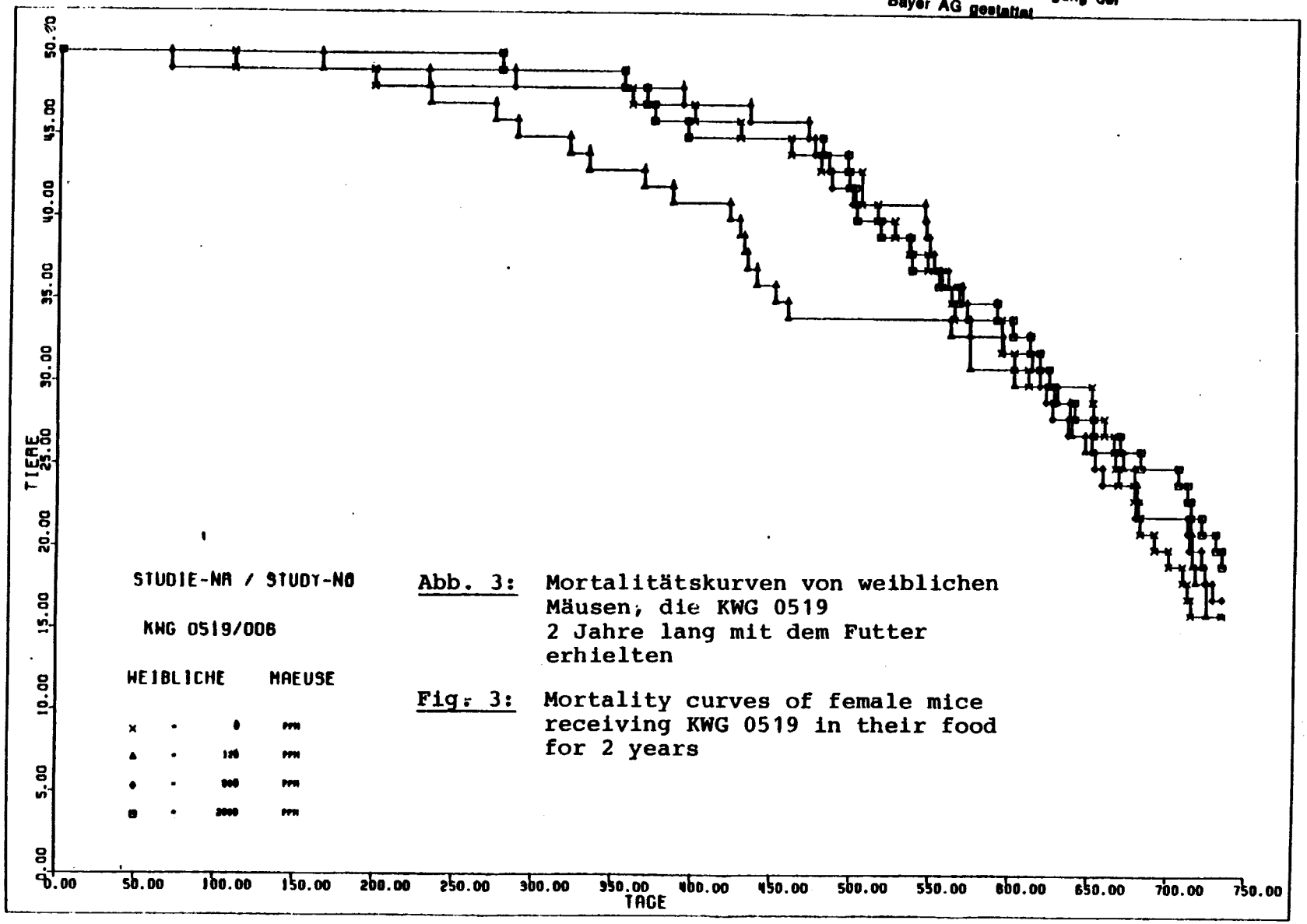

Abb. 3: Mortalitätskurven von weiblichen Mäusen, die KWG 0519 2 Jahre lang mit dem Futter erhielten

Fig. 3: Mortality curves of female mice receiving KWG 0519 in their food for 2 years

STUDIE-NR. / STUDY-NO. KMG 0519/006

TIERGEWICHTE / BODY WEIGHTS (G)

DOSE / DOSIS / PPM		W 0	W 1	W 2	W 3	W 4	W 5	W 6	W 7	W 8	W 9
MAENNLICH/MALE											
0	MW/MEANS	25.7	26.7	27.5	28.7	30.2	31.1	31.8	32.4	32.5	*33.5
	STAND	1.5	1.4	1.4	1.8	1.7	1.9	1.6	2.2	2.1	2.1
	UG/LCL 1%	25.1	26.1	26.9	28.0	29.5	30.4	31.2	31.5	31.7	32.7
	OG/UCL 1%	26.2	27.2	28.0	29.4	30.8	31.8	32.4	33.2	33.3	34.3
	UG/LCL 5%	25.3	26.3	27.1	28.2	29.6	30.6	31.3	31.8	31.9	32.9
	OG/UCL 5%	26.1	27.1	27.9	29.2	30.7	31.7	32.3	33.0	33.1	34.1
125	MW/MEANS	25.5	26.7	27.6	28.9	29.3	29.8	29.9	31.5	31.6	32.2
	STAND	1.7	1.5	1.8	2.0	1.9	2.1	2.1	2.1	2.4	2.5
	UG/LCL 1%	24.9	26.2	26.9	28.2	28.5	29.0	29.1	30.7	30.7	31.2
	OG/UCL 1%	26.2	27.3	28.3	29.7	30.0	30.6	30.8	32.3	32.5	33.1
	UG/LCL 5%	25.1	26.3	27.1	28.4	28.7	29.2	29.3	30.9	30.9	31.4
	OG/UCL 5%	26.0	27.2	28.1	29.5	29.8	30.4	30.5	32.1	32.3	32.9
	TS 1%	-	-	-	-	-	+	+	-	-	+
	TS 5%	-	-	-	-	+	+	+	-	-	+
500	MW/MEANS	25.4	26.5	27.3	28.4	29.4	29.4	30.1	30.7	30.8	31.7
	STAND	1.4	1.4	1.6	1.8	1.9	2.1	2.3	2.5	2.3	2.9
	UG/LCL 1%	24.8	26.0	26.7	27.7	28.7	28.7	29.2	29.8	29.9	30.6
	OG/UCL 1%	25.9	27.0	27.9	29.0	30.1	30.2	31.0	31.7	31.7	32.7
	UG/LCL 5%	25.0	26.1	26.8	27.9	28.9	28.9	29.4	30.0	30.1	30.8
	OG/UCL 5%	25.8	26.9	27.7	28.9	29.9	30.0	30.7	31.5	31.4	32.6
	TS 1%	-	-	-	-	-	+	+	+	+	+
	TS 5%	-	-	-	-	+	+	+	+	+	+
2000	MW/MEANS	25.7	26.3	26.6	27.8	28.5	29.4	29.9	30.0	29.7	31.0
	STAND	1.9	1.9	2.0	2.2	2.4	2.5	2.6	2.5	2.8	2.8
	UG/LCL 1%	25.0	25.6	25.8	26.9	27.6	28.5	28.9	29.0	28.6	29.9
	OG/UCL 1%	26.4	27.0	27.4	28.6	29.4	30.3	30.9	31.0	30.7	32.0
	UG/LCL 5%	25.1	25.7	26.0	27.1	27.8	28.7	29.1	29.3	28.9	30.2
	OG/UCL 5%	26.2	26.8	27.2	28.4	29.2	30.1	30.6	30.7	30.5	31.8
	TS 1%	-	-	-	-	+	+	+	+	+	+
	TS 5%	-	-	+	+	+	+	+	+	+	+

Vertraulich
Eigentum der Firma Bayer AG
Benutzung, Verwertung oder Weitergabe nur mit Einwilligung der Bayer AG gestattet

BAYER AG

STUDIE-NR. / STUDY-NO. KWG 0519/006

TIERGEWICHTE / BODY WEIGHTS (G)

DOSE DOSIS PPM		W 10	W 11	W 12	W 13	W 14	W 15	W 18	W 21	W 24	W 27
MAENNLICH/MALE											
0	MW/MEANS	33.6	33.9	34.2	34.9	34.4	35.6	36.8	38.1	38.6	40.1
	STAND	2.3	2.9	3.0	2.3	2.6	2.6	3.0	3.6	3.8	3.9
	UG/LCL 1%	32.7	32.8	33.0	34.0	33.5	34.6	35.7	36.8	37.1	38.6
	OG/UCL 1%	34.4	35.0	35.3	35.8	35.4	36.6	38.0	39.5	40.0	41.6
	UG/LCL 5%	32.9	33.1	33.3	34.2	33.7	34.8	36.0	37.1	37.5	38.9
	OG/UCL 5%	34.2	34.7	35.0	35.6	35.2	36.3	37.7	39.2	39.6	41.2
125	MW/MEANS	32.1	32.6	32.9	33.5	33.4	34.3	35.5	36.5	37.5	39.3
	STAND	2.6	2.8	2.6	2.6	2.7	2.8	3.1	3.7	4.0	4.4
	UG/LCL 1%	31.1	31.5	32.0	32.5	32.4	33.2	34.3	35.0	36.0	37.6
	OG/UCL 1%	33.0	33.6	33.9	34.5	34.4	35.4	36.6	37.9	39.0	41.0
	UG/LCL 5%	31.3	31.8	32.2	32.8	32.6	33.5	34.6	35.4	36.4	38.1
	OG/UCL 5%	32.8	33.4	33.6	34.2	34.1	35.1	36.3	37.5	38.7	40.6
	TS 1%	*	*	*	*	-	-	-	-	-	-
	TS 5%	*	*	*	*	*	*	*	*	-	-
500	MW/MEANS	32.1	32.2	32.3	32.6	32.5	33.6	34.6	35.0	36.3	37.4
	STAND	2.6	2.6	2.7	2.7	2.6	2.6	3.1	3.1	3.0	4.3
	UG/LCL 1%	31.1	31.2	31.3	31.6	31.5	32.6	33.4	33.8	35.1	35.7
	OG/UCL 1%	33.1	33.2	33.3	33.7	33.5	34.6	35.8	36.2	37.4	39.0
	UG/LCL 5%	31.3	31.4	31.5	31.9	31.8	32.9	33.7	34.1	35.4	36.1
	OG/UCL 5%	32.8	33.0	33.1	33.4	33.3	34.4	35.5	35.9	37.1	38.6
	TS 1%	*	*	*	*	*	*	*	*	*	*
	TS 5%	*	*	*	*	*	*	*	*	*	*
2000	MW/MEANS	31.1	30.7	31.2	31.6	31.4	32.1	33.1	33.5	33.4	34.3
	STAND	2.7	2.8	3.2	3.2	2.9	3.0	3.3	3.7	3.7	4.3
	UG/LCL 1%	30.1	29.7	29.9	30.4	30.3	30.9	31.9	32.1	32.0	32.7
	OG/UCL 1%	32.2	31.8	32.4	32.9	32.5	33.2	34.3	34.9	34.8	36.0
	UG/LCL 5%	30.4	29.9	30.2	30.7	30.5	31.2	32.2	32.4	32.3	33.1
	OG/UCL 5%	31.9	31.5	32.1	32.6	32.2	32.9	34.0	34.6	34.5	35.5
	TS 1%	*	*	*	*	*	*	*	*	*	*
	TS 5%	*	*	*	*	*	*	*	*	*	*

STUDIE-NR. / STUDY-NO. KMG 0519/006

TIERGEWICHTE / BODY WEIGHTS (G)

DOSE DOSIS PPM		W 30	W 33	W 36	W 39	W 42	W 45	W 48	W 51	W 54	W 57
MAENNLICH/MALE											
0	MW/MEANS	39.9	40.3	40.5	43.2	42.4	42.7	43.0	43.0	44.2	43.9
	STAND	4.1	4.4	4.6	5.0	4.8	5.0	4.7	5.4	5.7	5.9
	UG/LCL 1%	38.3	38.6	38.7	41.2	40.5	40.7	41.1	40.9	41.9	41.6
	OG/UCL 1%	41.4	42.0	42.3	45.1	44.2	44.6	44.8	45.1	46.4	46.3
	UG/LCL 5%	38.7	39.1	39.1	41.7	41.0	41.2	41.6	41.4	42.5	42.2
	OG/UCL 5%	41.0	41.6	41.8	44.6	43.8	44.1	44.4	44.6	45.9	45.7
125	MW/MEANS	39.5	40.1	40.4	41.4	41.9	42.6	42.9	43.3	44.0	43.9
	STAND	4.6	5.0	5.0	5.2	5.5	5.6	5.5	6.0	5.8	5.8
	UG/LCL 1%	37.8	38.2	38.5	39.4	39.8	40.4	40.8	40.9	41.7	41.6
	OG/UCL 1%	41.3	42.1	42.3	43.4	44.1	44.7	45.0	45.6	46.3	46.2
	UG/LCL 5%	38.2	38.7	39.0	39.9	40.3	41.0	41.3	41.5	42.3	42.2
	OG/UCL 5%	40.8	41.6	41.9	42.9	43.5	44.2	44.5	45.0	45.7	45.6
	TS 1%	-	-	-	-	-	-	-	-	-	-
	TS 5%	-	-	-	-	-	-	-	-	-	-
500	MW/MEANS	38.3	38.6	38.5	39.4	39.3	39.6	40.0	40.7	41.3	41.7
	STAND	4.5	4.6	4.6	4.8	4.5	4.9	4.6	5.0	5.4	6.1
	UG/LCL 1%	36.6	36.8	36.7	37.5	37.6	37.7	38.2	38.7	39.1	39.2
	OG/UCL 1%	40.0	40.4	40.2	41.2	41.0	41.5	41.8	42.6	43.4	44.3
	UG/LCL 5%	37.0	37.3	37.1	38.0	38.0	38.2	38.7	39.2	39.7	39.9
	OG/UCL 5%	39.6	40.0	39.8	40.7	40.6	41.1	41.4	42.1	42.9	43.6
	TS 1%	-	-	-	+	+	+	+	-	+	+
	TS 5%	-	+	+	+	+	+	+	+	+	-
2000	MW/MEANS	35.2	35.5	35.2	36.1	36.5	37.0	37.5	37.4	38.1	37.6
	STAND	3.9	4.6	4.8	4.6	5.0	5.4	5.1	5.6	5.6	5.5
	UG/LCL 1%	33.7	33.7	33.3	34.3	34.5	35.0	35.5	35.2	35.8	35.3
	OG/UCL 1%	36.7	37.3	37.0	37.9	38.4	39.1	39.6	39.6	40.4	39.9
	UG/LCL 5%	34.1	34.2	33.8	34.8	35.0	35.5	36.0	35.7	36.4	35.9
	OG/UCL 5%	36.3	36.8	36.6	37.5	37.9	38.6	39.1	39.0	39.8	39.3
	TS 1%	+	+	+	+	+	+	+	+	+	+
	TS 5%	+	+	+	+	+	+	+	+	+	+

BAYER AG
BAYER AG
BAYER AG
005

STUDIE-NR. / STUDY-NO. KWG 0519/006

TIERGEWICHTE / BODY WEIGHTS (G)

DOSE DOSIS PPM		W 60	W 63	W 66	W 69	W 72	W 75	W 78	W 81	W 84	W 87
MAENNLICH/MALE											
0	MW/MEANS	43.4	43.9	44.5	44.5	44.1	43.3	43.8	43.6	44.3	43.4
	STAND	5.9	6.2	5.8	6.1	5.9	5.6	5.9	7.1	6.7	5.5
	UG/LCL 1%	41.1	41.3	42.0	41.9	41.7	40.9	41.2	40.5	41.3	40.8
	OG/UCL 1%	45.8	46.4	46.9	47.1	46.6	45.7	46.3	46.7	47.3	45.9
	UG/LCL 5%	41.7	42.0	42.7	42.6	42.3	41.5	41.9	41.3	42.0	41.4
	OG/UCL 5%	45.2	45.8	46.3	46.4	46.0	45.1	45.6	45.9	46.5	45.3
125	MW/MEANS	43.7	44.4	44.7	44.2	44.5	43.9	43.6	43.9	44.7	43.3
	STAND	6.0	5.9	5.7	6.3	6.1	6.0	5.4	5.6	5.4	5.5
	UG/LCL 1%	41.3	42.0	42.4	41.6	41.9	41.3	41.2	41.1	41.8	40.2
	OG/UCL 1%	46.0	46.7	47.0	46.8	47.2	46.6	46.1	46.7	47.6	46.3
	UG/LCL 5%	41.9	42.6	43.0	42.3	42.6	42.0	41.8	41.9	42.6	41.0
	OG/UCL 5%	45.4	46.2	46.4	46.2	46.5	45.9	45.5	45.9	46.8	45.5
	TS 1%	-	-	-	-	-	-	-	-	-	-
	TS 5%	-	-	-	-	-	-	-	-	-	-
500	MW/MEANS	41.1	42.0	42.4	41.8	41.4	40.7	41.0	41.4	42.0	40.3
	STAND	5.4	5.4	5.2	5.2	5.1	4.7	5.3	5.6	5.1	5.7
	UG/LCL 1%	38.9	39.7	40.2	39.5	39.1	38.6	38.6	38.8	39.5	37.5
	OG/UCL 1%	43.4	44.2	44.6	44.0	43.7	42.8	43.4	44.1	44.4	43.1
	UG/LCL 5%	39.5	40.3	40.7	40.1	39.7	39.2	39.2	39.5	40.1	38.2
	OG/UCL 5%	42.8	43.7	44.0	43.5	43.1	42.3	42.8	43.4	43.8	42.4
	TS 1%	-	-	-	-	-	-	-	-	-	-
	TS 5%	-	-	-	+	-	-	-	-	-	+
2000	MW/MEANS	37.3	37.9	38.1	37.6	37.5	37.4	36.7	36.8	37.2	36.7
	STAND	5.5	5.6	5.8	5.7	5.6	6.0	5.4	5.4	5.7	5.4
	UG/LCL 1%	35.0	35.5	35.7	35.2	35.1	34.8	34.3	34.3	34.4	34.1
	OG/UCL 1%	39.6	40.2	40.6	40.0	39.9	40.1	39.1	39.3	39.9	39.4
	UG/LCL 5%	35.6	36.1	36.3	35.8	35.7	35.5	34.9	35.0	35.1	34.8
	OG/UCL 5%	39.1	39.6	39.9	39.4	39.3	39.4	38.5	38.6	39.2	38.7
	TS 1%	+	+	+	+	+	+	+	+	+	+
	TS 5%	+	+	+	+	+	+	+	+	+	+

Vertraulich
Eigentum der Firma Bayer AG
Benutzung, Verwertung oder Weitergabe nur mit Einwilligung der Bayer AG gestattet

STUDIE-NR. / STUDY-NO. KWG 0519/006

TIERGEWICHTE / BODY WEIGHTS (G)

DOSE DOSIS PPM		W 90	W 93	W 96	W 99	W 102	W 105
MAENNLICH/MALE							
0	MW/MEANS	42.8	41.2	41.4	40.3	39.9	42.1
	STAND	5.8	5.6	6.5	6.5	5.9	4.7
	UG/LCL 1%	39.9	38.2	37.6	36.4	35.7	37.9
	OG/UCL 1%	45.6	44.2	45.2	44.2	44.0	46.3
	UG/LCL 5%	40.7	39.0	38.6	37.4	36.9	39.1
	OG/UCL 5%	44.9	43.5	44.2	43.1	42.9	45.0
125	MW/MEANS	42.9	42.2	42.5	40.8	40.6	40.6
	STAND	5.5	5.9	5.2	6.1	6.7	5.6
	UG/LCL 1%	39.6	38.6	39.1	36.5	34.9	35.3
	OG/UCL 1%	46.2	45.7	46.0	45.1	46.3	46.0
	UG/LCL 5%	40.5	39.6	40.0	37.6	36.6	36.9
	OG/UCL 5%	45.3	44.8	45.0	43.9	44.7	44.4
	TS 1%	-	-	-	-	-	-
	TS 5%	-	-	-	-	-	-
500	MW/MEANS	40.2	40.1	39.7	40.1	40.4	40.8
	STAND	5.9	6.3	7.2	6.2	5.6	5.4
	UG/LCL 1%	37.2	36.6	35.3	35.5	36.1	36.3
	OG/UCL 1%	43.2	43.6	44.2	44.6	44.7	45.4
	UG/LCL 5%	38.0	37.5	36.5	36.8	37.3	37.6
	OG/UCL 5%	42.4	42.7	43.0	43.4	43.5	44.1
	TS 1%	-	-	-	-	-	-
	TS 5%	-	-	-	-	-	-
2000	MW/MEANS	37.0	38.4	38.0	36.8	37.8	37.8
	STAND	5.3	4.4	4.7	4.2	3.4	3.7
	UG/LCL 1%	34.3	35.9	35.1	34.1	35.6	35.2
	OG/UCL 1%	39.7	41.0	40.9	39.6	40.0	40.5
	UG/LCL 5%	35.0	36.5	35.9	34.9	36.2	35.9
	OG/UCL 5%	39.0	40.3	40.2	38.8	39.4	39.7
	TS 1%	+	-	-	-	-	-
	TS 5%	+	-	-	-	-	+

BAYER AG BAYER AG BAYER AG

STUDIE-NR. / STUDY-NO. KWG 0519/006

TIERGEWICHTE / BODY WEIGHTS (G)

DOSE DOSIS PPM		W 0	W 1	W 2	W 3	W 4	W 5	W 6	W 7	W 8	W 9
WEIBLICH/FEMALE											
0	MW/MEANS	20.2	20.4	20.8	21.8	23.3	23.4	23.6	28.3	24.4	25.3
	STAND	1.3	1.3	1.5	1.7	1.7	1.6	1.9	2.8	2.0	2.3
	UG/LCL 1%	19.8	19.9	20.3	21.2	22.6	22.8	22.9	27.3	23.6	24.4
	OG/UCL 1%	20.7	20.9	21.4	22.5	23.9	24.0	24.3	29.4	25.2	26.2
	UG/LCL 5%	19.9	20.0	20.4	21.3	22.8	23.0	23.1	27.5	23.8	24.6
	OG/UCL 5%	20.6	20.8	21.3	22.3	23.8	23.9	24.1	29.1	25.0	26.0
125	MW/MEANS	20.5	20.8	21.6	22.3	22.9	23.4	23.9	23.9	24.5	25.3
	STAND	1.4	1.3	1.5	1.6	2.0	2.0	1.7	2.1	2.0	1.9
	UG/LCL 1%	19.9	20.3	21.0	21.7	22.2	22.6	23.3	23.1	23.7	24.5
	OG/UCL 1%	21.0	21.3	22.1	22.9	23.7	24.1	24.6	24.7	25.3	26.0
	UG/LCL 5%	20.1	20.4	21.1	21.9	22.4	22.8	23.5	23.3	23.9	24.7
	OG/UCL 5%	20.9	21.2	22.0	22.8	23.5	23.9	24.4	24.5	25.1	25.8
	TS 1%	-	-	-	-	-	-	-	+	-	-
	TS 5%	-	-	+	-	-	-	-	+	-	-
500	MW/MEANS	20.3	21.2	21.6	22.4	23.0	23.0	23.1	23.7	24.1	24.4
	STAND	1.1	1.0	1.1	1.2	1.3	1.5	1.4	1.4	1.5	2.0
	UG/LCL 1%	19.9	20.8	21.1	21.9	22.5	22.4	22.6	23.1	23.5	23.7
	OG/UCL 1%	20.7	21.6	22.0	22.8	23.5	23.5	23.6	24.2	24.6	25.2
	UG/LCL 5%	20.0	20.9	21.2	22.0	22.6	22.5	22.7	23.3	23.7	23.9
	OG/UCL 5%	20.6	21.5	21.9	22.7	23.3	23.4	23.5	24.1	24.5	25.0
	TS 1%	-	+	-	-	-	-	-	+	-	-
	TS 5%	-	+	+	-	-	-	-	+	-	+
2000	MW/MEANS	20.3	20.9	20.9	21.6	22.1	23.0	23.2	23.7	23.2	23.7
	STAND	1.1	1.1	1.2	1.2	1.7	1.6	1.7	1.4	1.6	1.6
	UG/LCL 1%	19.9	20.4	20.5	21.2	21.5	22.4	22.6	23.2	22.6	23.1
	OG/UCL 1%	20.7	21.3	21.3	22.0	22.7	23.7	23.8	24.3	23.8	24.3
	UG/LCL 5%	20.0	20.5	20.6	21.3	21.6	22.6	22.7	23.3	22.7	23.2
	OG/UCL 5%	20.6	21.2	21.2	21.9	22.6	23.5	23.7	24.1	23.6	24.1
	TS 1%	-	-	-	-	+	-	-	+	+	+
	TS 5%	-	-	-	-	+	-	-	+	+	+

STUDIE-NR. / STUDY-NO. KWG 0519/006

TIERGEWICHTE / BODY WEIGHTS (G)

DOSE DOSIS PPM		W 10	W 11	W 12	W 13	W 14	W 15	W 18	W 21	W 24	W 27
WEIBLICH/FEMALE											
0	MW/MEANS	25.3	25.3	25.4	25.8	25.5	26.3	27.4	27.8	28.4	29.5
	STAND	2.4	2.4	2.4	2.7	2.5	2.4	2.6	3.3	2.7	3.0
	UG/LCL 1%	24.4	24.4	24.5	24.8	24.5	25.4	26.4	26.5	27.4	28.3
	OG/UCL 1%	26.2	26.2	26.4	26.8	26.5	27.3	28.4	29.1	29.5	30.6
	UG/LCL 5%	24.6	24.6	24.8	25.0	24.8	25.7	26.7	26.8	27.7	28.6
	OG/UCL 5%	25.9	25.9	26.1	26.5	26.2	27.0	28.2	28.7	29.2	30.3
125	MW/MEANS	24.4	24.7	25.0	25.7	25.3	26.0	27.1	27.4	28.3	28.6
	STAND	2.2	2.1	2.1	2.0	2.3	2.2	2.3	2.6	2.7	2.8
	UG/LCL 1%	23.6	23.9	24.2	25.0	24.4	25.2	26.2	26.4	27.3	27.5
	OG/UCL 1%	25.3	25.5	25.7	26.5	26.1	26.8	28.0	28.4	29.3	29.7
	UG/LCL 5%	23.8	24.1	24.4	25.2	24.6	25.4	26.4	26.7	27.5	27.8
	OG/UCL 5%	25.1	25.3	25.5	26.3	25.9	26.6	27.7	28.1	29.1	29.4
	TS 1%	-	-	-	-	-	-	-	-	-	-
	TS 5%	-	-	-	-	-	-	-	-	-	-
500	MW/MEANS	24.2	24.3	24.3	24.7	24.8	25.4	26.1	26.8	27.2	28.4
	STAND	1.4	1.5	1.6	1.5	1.9	1.5	1.5	1.9	2.2	2.1
	UG/LCL 1%	23.7	23.7	23.7	24.1	24.1	24.8	25.6	26.1	26.4	27.6
	OG/UCL 1%	24.8	24.9	24.9	25.3	25.5	25.9	26.7	27.6	28.0	29.2
	UG/LCL 5%	23.8	23.9	23.8	24.2	24.2	24.9	25.7	26.3	26.6	27.8
	OG/UCL 5%	24.6	24.7	24.7	25.1	25.3	25.8	26.6	27.4	27.8	29.0
	TS 1%	+	-	+	-	-	-	+	-	-	-
	TS 5%	+	+	+	+	-	+	+	+	+	+
2000	MW/MEANS	24.1	23.5	23.9	24.3	24.4	25.1	25.8	26.1	26.5	27.6
	STAND	1.8	1.7	2.0	1.6	2.0	1.8	1.7	1.9	2.3	2.1
	UG/LCL 1%	23.5	22.9	23.2	23.7	23.6	24.4	25.1	25.3	25.6	26.8
	OG/UCL 1%	24.8	24.1	24.6	24.9	25.2	25.8	26.4	26.8	27.3	28.4
	UG/LCL 5%	23.6	23.0	23.3	23.8	23.8	24.6	25.3	25.5	25.8	27.0
	OG/UCL 5%	24.7	24.0	24.5	24.7	25.0	25.6	26.3	26.6	27.1	28.2
	TS 1%	+	+	+	+	-	+	+	+	+	+
	TS 5%	+	+	+	+	+	+	+	+	+	+

BAYER AG

STUDIE-NR. / STUDY-NO. KMG 0519/006

TIERGEWICHTE / BODY WEIGHTS (G)

DOSE DOSIS PPM		W 30	W 33	W 36	W 39	W 42	W 45	W 48	W 51	W 54	W 57
WEIBLICH/FEMALE											
0	MW/MEANS	29.9	30.0	30.5	31.0	31.7	32.4	32.9	32.7	33.4	33.6
	STAND	3.2	3.4	3.7	3.7	3.8	4.2	3.9	4.3	5.1	5.8
	UG/LCL 1%	28.6	28.7	29.1	29.6	30.2	30.8	31.4	31.0	31.4	31.3
	OG/UCL 1%	31.1	31.4	32.0	32.4	33.1	34.0	34.4	34.4	35.4	35.9
	UG/LCL 5%	28.9	29.1	29.4	30.0	30.6	31.2	31.8	31.5	31.9	31.9
	OG/UCL 5%	30.8	31.0	31.6	32.1	32.8	33.6	34.0	34.0	34.9	35.3
125	MW/MEANS	29.4	30.0	29.7	30.6	31.1	31.2	31.7	32.1	32.4	32.7
	STAND	3.1	2.9	3.4	3.2	3.0	3.1	2.8	3.6	3.7	3.8
	UG/LCL 1%	28.2	28.9	28.4	29.3	29.9	30.0	30.6	30.6	30.9	31.1
	OG/UCL 1%	30.6	31.1	31.1	31.9	32.3	32.5	32.9	33.6	34.0	34.3
	UG/LCL 5%	28.5	29.2	28.7	29.6	30.2	30.3	30.8	31.0	31.3	31.5
	OG/UCL 5%	30.3	30.8	30.7	31.5	32.0	32.2	32.6	33.2	33.6	33.9
	TS 1%	-	-	-	-	-	-	-	-	-	-
	TS 5%	-	-	-	-	-	-	-	-	-	-
500	MW/MEANS	28.6	29.0	29.1	29.4	30.1	30.3	30.9	30.9	31.1	31.7
	STAND	2.3	2.4	2.8	2.6	2.7	3.0	2.7	3.0	3.2	3.3
	UG/LCL 1%	27.8	28.1	28.0	28.4	29.1	29.1	29.8	29.7	29.9	30.4
	OG/UCL 1%	29.5	29.9	30.2	30.4	31.1	31.4	31.9	32.1	32.4	33.0
	UG/LCL 5%	28.0	28.3	28.3	28.6	29.3	29.4	30.1	30.0	30.2	30.7
	OG/UCL 5%	29.3	29.7	29.9	30.1	30.9	31.2	31.6	31.8	32.1	32.7
	TS 1%	-	-	-	+	-	+	+	-	-	-
	TS 5%	+	-	-	+	+	+	+	+	+	-
2000	MW/MEANS	27.7	28.0	27.8	28.1	28.9	28.8	29.2	29.2	29.5	30.4
	STAND	2.1	2.3	2.5	2.3	2.5	2.9	2.6	2.9	3.3	3.5
	UG/LCL 1%	26.8	27.1	26.8	27.2	27.9	27.6	28.2	28.1	28.2	29.0
	OG/UCL 1%	28.5	28.8	28.7	29.0	29.8	29.9	30.2	30.3	30.8	31.8
	UG/LCL 5%	27.1	27.3	27.1	27.5	28.2	27.9	28.5	28.3	28.5	29.3
	OG/UCL 5%	28.3	28.6	28.5	28.8	29.6	29.6	30.0	30.0	30.5	31.4
	TS 1%	+	+	+	+	+	+	+	+	+	+
	TS 5%	+	+	+	+	+	+	+	+	+	+

STUDIE-NR. / STUDY NO. KWG 0519/006

TIERGEWICHTE / BODY WEIGHTS (G)

DOSIS PPM		W 60	W 63	W 66	W 69	W 72	W 75	W 78	W 81	W 84	W 87
WEIBLICH/FEMALE											
0	MW/MEANS	33.2	33.7	34.1	33.5	34.1	33.3	32.9	33.1	33.3	32.5
	STAND	5.1	5.1	4.9	5.2	5.2	4.8	4.6	4.6	4.3	4.5
	UG/LCL 1%	31.2	31.7	32.1	31.3	31.9	31.2	30.8	31.0	31.3	30.3
	OG/UCL 1%	35.2	35.8	36.1	35.6	36.3	35.3	35.0	35.3	35.3	34.7
	UG/LCL 5%	31.7	32.2	32.6	31.9	32.5	31.8	31.3	31.5	31.8	30.8
	OG/UCL 5%	34.7	35.2	35.6	35.1	35.8	34.8	34.4	34.7	34.8	34.1
125	MW/MEANS	32.5	32.7	32.9	32.9	33.3	33.1	32.9	33.9	34.0	33.7
	STAND	4.0	4.2	4.0	4.1	4.2	4.3	4.0	4.6	4.0	4.1
	UG/LCL 1%	30.8	30.8	31.0	30.9	31.3	31.1	31.0	31.7	32.0	31.7
	OG/UCL 1%	34.3	34.6	34.7	34.8	35.3	35.1	34.7	36.1	36.0	35.8
	UG/LCL 5%	31.3	31.3	31.5	31.4	31.8	31.6	31.5	32.3	32.5	32.2
	OG/UCL 5%	33.8	34.1	34.3	34.3	34.8	34.6	34.3	35.5	35.5	35.3
	TS 1%	-	-	-	-	-	-	-	-	-	-
	TS 5%	-	-	-	-	-	-	-	-	-	-
500	MW/MEANS	31.7	32.0	32.4	32.2	32.6	32.6	31.6	32.3	32.2	32.6
	STAND	3.9	3.4	3.2	3.4	3.7	3.4	3.6	3.8	3.8	5.1
	UG/LCL 1%	30.1	30.6	31.1	30.8	31.1	31.1	30.1	30.6	30.4	30.1
	OG/UCL 1%	33.2	33.3	33.6	33.6	34.2	34.0	33.2	34.1	33.9	35.1
	UG/LCL 5%	30.5	31.0	31.4	31.1	31.5	31.5	30.5	31.0	30.8	30.7
	OG/UCL 5%	32.8	33.0	33.3	33.2	33.8	33.6	32.8	33.6	33.5	34.4
	TS 1%	-	-	-	-	-	-	-	-	-	-
	TS 5%	-	-	-	-	-	-	-	-	-	-
2000	MW/MEANS	30.2	30.4	30.8	31.0	30.9	31.0	30.8	30.7	30.5	31.1
	STAND	3.4	3.5	3.5	3.4	3.2	3.4	3.6	4.0	3.8	4.2
	UG/LCL 1%	28.8	29.0	29.4	29.6	29.6	29.5	29.2	28.9	28.8	29.1
	OG/UCL 1%	31.5	31.8	32.2	32.4	32.3	32.5	32.3	32.6	32.3	33.1	
	UG/LCL 5%	29.1	29.3	29.7	30.0	29.9	29.9	29.6	29.4	29.2	29.6
	OG/UCL 5%	31.2	31.4	31.8	32.1	31.9	32.1	31.9	32.1	31.8	32.6
	TS 1%	+	+	+	-	+	-	-	-	+	-
	TS 5%	+	+	+	+	+	+	+	+	+	-

BAYER AG

STUDIE-NR. / STUDY-NO. KMG 0519/006

TIERGEWICHTE / BODY WEIGHTS (G)

DOSE DOSIS PPM		W 90	W 93	W 96	W 99	W 102	W 105
WEIBLICH/FEMALE							
0	MW/MEANS	32.9	33.0	33.3	32.3	32.3	31.4
	STAND	4.3	6.1	5.3	5.7	5.6	5.3
	UG/LCL 1%	30.8	29.9	30.3	28.6	28.2	27.5
	OG/UCL 1%	35.0	36.1	36.3	35.9	36.4	35.3
	UG/LCL 5%	31.3	30.7	31.1	29.6	29.4	28.5
	OG/UCL 5%	34.5	35.3	35.6	34.9	35.3	34.2
125	MW/MEANS	32.9	32.8	32.4	31.4	32.0	31.6
	STAND	3.9	3.7	4.1	3.8	3.6	3.6
	UG/LCL 1%	30.9	30.8	30.1	29.1	29.6	28.9
	OG/UCL 1%	34.9	34.9	34.7	33.7	34.4	34.2
	UG/LCL 5%	31.5	31.4	30.7	29.7	30.3	29.7
	OG/UCL 5%	34.4	34.3	34.1	33.1	33.7	33.5
	TS 1%	-	-	-	-	-	-
	TS 5%	-	-	-	-	-	-
500	MW/MEANS	32.6	32.4	32.5	31.7	32.4	31.6
	STAND	3.6	3.4	3.9	4.2	4.0	3.9
	UG/LCL 1%	30.7	30.5	30.2	29.2	29.9	28.8
	OG/UCL 1%	34.5	34.3	34.7	34.3	35.0	34.4
	UG/LCL 5%	31.2	31.0	30.8	29.9	30.6	29.6
	OG/UCL 5%	34.0	33.8	34.1	33.6	34.3	33.6
	TS 1%	-	-	-	-	-	-
	TS 5%	-	-	-	-	-	-
2000	MW/MEANS	31.1	31.0	30.9	30.6	30.9	30.4
	STAND	3.3	2.6	3.3	4.5	3.1	3.0
	UG/LCL 1%	29.5	29.6	29.1	28.1	29.1	28.4
	OG/UCL 1%	32.8	32.3	32.7	33.1	32.8	32.4
	UG/LCL 5%	29.9	29.9	29.6	28.8	29.6	28.9
	OG/UCL 5%	32.4	32.0	32.3	32.5	32.3	31.8
	TS 1%	-	-	-	-	-	-
	TS 5%	-	-	-	-	-	-

STUDIE-NR. / STUDY-NO. KWG 0519/006

TIERGEWICHTE / BODY WEIGHTS (G)

DOSE DOSIS PPM		W 90	W 93	W 96	W 99	W 102	W 105
WEIBLICH/FEMALE							
0	MW/MEANS	32.9	33.0	33.3	32.3	32.3	31.4
	STAND	4.3	6.1	5.3	5.7	5.6	5.3
	UG/LCL 1%	30.8	29.9	30.3	28.6	28.2	27.5
	OG/UCL 1%	35.0	36.1	36.3	35.9	36.4	35.3
	UG/LCL 5%	31.3	30.7	31.1	29.6	29.4	28.5
	OG/UCL 5%	34.5	35.3	35.6	34.9	35.3	34.2
125	MW/MEANS	32.9	32.8	32.4	31.4	32.0	31.6
	STAND	3.9	3.7	4.1	3.8	3.6	3.6
	UG/LCL 1%	30.9	30.8	30.1	29.1	29.6	28.9
	OG/UCL 1%	34.9	34.9	34.7	33.7	34.4	34.2
	UG/LCL 5%	31.5	31.4	30.7	29.7	30.3	29.7
	OG/UCL 5%	34.4	34.3	34.1	33.1	33.7	33.5
	TS 1%	-	-	-	-	-	-
	TS 5%	-	-	-	-	-	-
500	MW/MEANS	32.6	32.4	32.5	31.7	32.4	31.6
	STAND	3.6	3.4	3.9	4.2	4.0	3.9
	UG/LCL 1%	30.7	30.5	30.2	29.2	29.9	28.8
	OG/UCL 1%	34.5	34.3	34.7	34.3	35.0	34.4
	UG/LCL 5%	31.2	31.0	30.8	29.9	30.6	29.6
	OG/UCL 5%	34.0	33.8	34.1	33.6	34.3	33.6
	TS 1%	-	-	-	-	-	-
	TS 5%	-	-	-	-	-	-
2000	MW/MEANS	31.1	31.0	30.9	30.6	30.9	30.4
	STAND	3.3	2.6	3.3	4.5	3.1	3.0
	UG/LCL 1%	29.5	29.6	29.1	28.1	29.1	28.4
	OG/UCL 1%	32.8	32.3	32.7	33.1	32.8	32.4
	UG/LCL 5%	29.9	29.9	29.6	28.8	29.6	28.9
	OG/UCL 5%	32.4	32.0	32.3	32.5	32.3	31.8
	TS 1%	-	-	-	-	-	-
	TS 5%	-	-	-	-	-	-

BAYER AG

STUDIE-NR. / STUDY-NO. KWG 0519/006

BLUT-UNTERSUCHUNG / HAEMATOLOGY
12 MONATE / 12 MONTHS

DOSE DOSIS PPM		ERY TERA/L	RETI 0/00	LEU GIGA/L	THROM GIGA/L	HGB G/L	HCT L/L	MCH PG/E	MCHC G/L	MCV FL
MAENNLICH/MALE										
0	MW/MEANS	8.62	29	7.1	1194	146	0.45	16.9	323	52
	STAND	0.21	3	2.6	138	6	0.02	0.5	4	2
	UG/LCL 1%	8.41	26	4.4	1053	139	0.43	16.4	318	51
	OG/UCL 1%	8.83	33	9.7	1336	152	0.47	17.4	327	54
	UG/LCL 5%	8.47	27	5.2	1096	141	0.44	16.6	320	51
	OG/UCL 5%	8.76	32	8.9	1293	150	0.47	17.2	326	53
125	MW/MEANS	8.35	29	5.9	1044	146	0.45	17.4	322	54
	STAND	0.62	3	0.9	216	12	0.03	0.6	9	1
	UG/LCL 1%	7.72	26	4.9	822	133	0.42	16.8	313	53
	OG/UCL 1%	8.99	33	6.8	1266	158	0.48	18.0	332	56
	UG/LCL 5%	7.91	27	5.2	890	137	0.43	17.0	316	53
	OG/UCL 5%	8.79	32	6.5	1199	154	0.47	17.8	329	55
	TS 1%	-	-	-	-	-	-	-	-	-
	TS 5%	-	-	-	-	-	-	+	-	+
500	MW/MEANS	8.40	29	4.6	1117	147	0.46	17.4	318	55
	STAND	0.38	4	1.4	125	8	0.02	0.5	7	2
	UG/LCL 1%	8.01	26	3.2	988	139	0.44	16.9	312	53
	OG/UCL 1%	8.79	33	6.0	1246	154	0.48	18.0	325	57
	UG/LCL 5%	8.13	27	3.6	1028	141	0.44	17.1	314	53
	OG/UCL 5%	8.67	32	5.6	1207	152	0.48	17.8	323	56
	TS 1%	-	-	+	-	-	-	-	-	+
	TS 5%	-	-	+	-	-	-	+	-	+
2000	MW/MEANS	8.32	30	4.9	1238	149	0.46	17.9	326	55
	STAND	0.31	3	1.4	207	8	0.02	0.6	9	2
	UG/LCL 1%	8.00	27	3.4	1026	141	0.44	17.3	317	53
	OG/UCL 1%	8.64	33	6.4	1451	156	0.47	18.5	335	57
	UG/LCL 5%	8.10	28	3.9	1090	143	0.44	17.5	320	53
	OG/UCL 5%	8.54	32	5.9	1386	154	0.47	18.3	333	56
	TS 1%	+	-	-	-	-	-	+	-	-
	TS 5%	+	-	+	-	-	-	+	-	+

STUDIE-NR. / STUDY-NO. KWG 0519/006

BLUT-UNTERSUCHUNG / HAEMATOLOGY
12 MONATE / 12 MONTHS

DOSE DOSIS PPM		ERY TERA/L	RETI O/OO	LEU GIGA/L	THROM GIGA/L	HGB G/L	HCT L/L	MCH PG/E	MCHC G/L	MCV FL
WEIBLICH/FEMALE										
0	MW/MEANS	8.66	35	4.9	917	155	0.45	17.9	342	52
	STAND	0.31	5	1.3	107	8	0.01	0.7	17	2
	UG/LCL 1%	8.35	30	3.5	807	147	0.44	17.1	324	50
	OG/UCL 1%	8.98	40	6.2	1026	163	0.47	18.6	359	54
	UG/LCL 5%	8.44	32	3.9	840	149	0.44	17.4	329	51
	OG/UCL 5%	8.89	38	5.8	994	160	0.46	18.4	354	54
125	MW/MEANS	8.22	35	4.1	865	147	0.44	17.9	334	54
	STAND	0.44	8	1.0	111	9	0.02	0.6	16	2
	UG/LCL 1%	7.77	28	3.1	751	137	0.42	17.3	318	51
	OG/UCL 1%	8.68	43	5.1	979	158	0.46	18.5	351	56
	UG/LCL 5%	7.91	30	3.4	786	140	0.43	17.4	323	52
	OG/UCL 5%	8.54	41	4.8	945	154	0.45	18.3	346	55
	TS 1%	-	-	-	-	-	-	-	-	-
	TS 5%	+	-	-	-	-	-	-	-	-
500	MW/MEANS	8.34	34	3.4	971	152	0.45	18.2	339	54
	STAND	0.20	5	1.2	137	7	0.02	0.5	7	2
	UG/LCL 1%	8.13	29	2.2	830	144	0.43	17.7	332	52
	OG/UCL 1%	8.55	39	4.7	1111	160	0.47	18.8	345	55
	UG/LCL 5%	8.19	31	2.6	872	147	0.43	17.8	334	53
	OG/UCL 5%	8.49	38	4.3	1069	157	0.46	18.6	343	55
	TS 1%	-	-	-	-	-	-	-	-	-
	TS 5%	+	-	+	-	-	-	-	-	-
2000	MW/MEANS	7.98	32	3.4	867	150	0.44	18.8	339	56
	STAND	0.40	4	0.9	76	8	0.02	0.6	14	2
	UG/LCL 1%	7.57	28	2.5	789	142	0.42	18.2	325	53
	OG/UCL 1%	8.39	36	4.4	945	159	0.47	19.5	354	58
	UG/LCL 5%	7.69	29	2.8	813	144	0.43	18.4	329	54
	OG/UCL 5%	8.26	35	4.1	922	156	0.46	19.3	350	57
	TS 1%	+	-	-	-	-	-	+	-	+
	TS 5%	+	-	+	-	-	-	+	-	+

BAYER AG

STUDIE-NR. / STUDY-NO. KWG 0519/006

DIFFERENTIALBLUTBILD / DIFFERENTIAL BLOOD COUNT (%)
12 MONATE / 12 MONTHS

DOSE DOSIS PPM		BASO	EOSIN	IPC JGL	STAB	SEGM	LYM	MONO	PLAS
MAENNLICH/MALE									
0	MW/MEANS	0.0	0.9	0.0	0.0	20.1	79.0	0.0	0.0
	STAND	0.0	1.1	0.0	0.0	7.6	7.7	0.0	0.0
	UG/LCL 1%	0.0	-0.0	0.0	0.0	12.3	71.1	0.0	0.0
	OG/UCL 1%	0.0	2.0	0.0	0.0	27.9	86.9	0.0	0.0
	UG/LCL 5%	0.0	0.1	0.0	0.0	14.6	73.5	0.0	0.0
	OG/UCL 5%	0.0	1.7	0.0	0.0	25.6	84.5	0.0	0.0
125	MW/MEANS	0.0	1.0	0.0	0.0	22.1	76.9	0.0	0.0
	STAND	0.0	1.1	0.0	0.0	5.6	6.2	0.0	0.0
	UG/LCL 1%	0.0	-0.0	0.0	0.0	16.4	70.5	0.0	0.0
	OG/UCL 1%	0.0	2.1	0.0	0.0	27.8	83.3	0.0	0.0
	UG/LCL 5%	0.0	0.2	0.0	0.0	18.1	72.5	0.0	0.0
	OG/UCL 5%	0.0	1.8	0.0	0.0	26.1	81.3	0.0	0.0
	TS 1%	-	-	-	-	-	-	-	-
	TS 5%	-	-	-	-	-	-	-	-
500	MW/MEANS	0.0	0.5	0.0	0.0	21.8	77.7	0.0	0.0
	STAND	0.0	0.7	0.0	0.0	6.6	6.8	0.0	0.0
	UG/LCL 1%	0.0	-0.0	0.0	0.0	15.0	70.7	0.0	0.0
	OG/UCL 1%	0.0	1.2	0.0	0.0	28.6	84.7	0.0	0.0
	UG/LCL 5%	0.0	-0.0	0.0	0.0	17.1	72.8	0.0	0.0
	OG/UCL 5%	0.0	1.0	0.0	0.0	26.5	82.6	0.0	0.0
	TS 1%	-	-	-	-	-	-	-	-
	TS 5%	-	-	-	-	-	-	-	-
2000	MW/MEANS	0.0	0.7	0.0	0.0	23.4	75.9	0.0	0.0
	STAND	0.0	0.7	0.0	0.0	8.4	8.9	0.0	0.0
	UG/LCL 1%	0.0	0.0	0.0	0.0	14.8	66.7	0.0	0.0
	OG/UCL 1%	0.0	1.4	0.0	0.0	32.0	85.1	0.0	0.0
	UG/LCL 5%	0.0	0.2	0.0	0.0	17.4	69.5	0.0	0.0
	OG/UCL 5%	0.0	1.2	0.0	0.0	29.4	82.3	0.0	0.0
	TS 1%	-	-	-	-	-	-	-	-
	TS 5%	-	-	-	-	-	-	-	-

STUDIE-NR. / STUDY-NO. KWG 0519/006

DIFFERENTIALBLUTBILD / DIFFERENTIAL BLOOD COUNT (%)
12 MONATE / 12 MONTHS

DOSE DOSIS PPM		BASO	EOSIN	IPC JGL	STAB	SEGM	LYM	MONO	PLAS
WEIBLICH/FEMALE									
0	MW/MEANS	0.0	0.2	0.0	0.0	15.4	84.4	0.0	0.0
	STAND	0.0	0.4	0.0	0.0	4.6	4.5	0.0	0.0
	UG/LCL 1%	0.0	-0.0	0.0	0.0	10.7	79.8	0.0	0.0
	OG/UCL 1%	0.0	0.6	0.0	0.0	20.1	89.0	0.0	0.0
	UG/LCL 5%	0.0	-0.0	0.0	0.0	12.1	81.2	0.0	0.0
	OG/UCL 5%	0.0	0.5	0.0	0.0	18.7	87.6	0.0	0.0
125	MW/MEANS	0.0	0.4	0.0	0.0	15.6	84.6	0.0	0.0
	STAND	0.0	0.5	0.0	0.0	4.3	4.4	0.0	0.0
	UG/LCL 1%	0.0	-0.0	0.0	0.0	10.6	80.1	0.0	0.0
	OG/UCL 1%	0.0	0.9	0.0	0.0	19.4	88.1	0.0	0.0
	UG/LCL 5%	0.0	0.0	0.0	0.0	11.9	81.5	0.0	0.0
	OG/UCL 5%	0.0	0.8	0.0	0.0	18.1	87.7	0.0	0.0
	TS 1%	-	-	-	-	-	-	-	-
	TS 5%	-	-	-	-	-	-	-	-
500	MW/MEANS	0.0	0.1	0.0	0.0	17.9	82.0	0.0	0.0
	STAND	0.0	0.3	0.0	0.0	4.9	4.9	0.0	0.0
	UG/LCL 1%	0.0	-0.0	0.0	0.0	12.8	77.0	0.0	0.0
	OG/UCL 1%	0.0	0.4	0.0	0.0	23.0	87.0	0.0	0.0
	UG/LCL 5%	0.0	-0.0	0.0	0.0	14.4	78.5	0.0	0.0
	OG/UCL 5%	0.0	0.3	0.0	0.0	21.4	85.5	0.0	0.0
	TS 1%	-	-	-	-	-	-	-	-
	TS 5%	-	-	-	-	-	-	-	-
2000	MW/MEANS	0.0	0.1	0.0	0.0	15.8	84.1	0.0	0.0
	STAND	0.0	0.3	0.0	0.0	4.4	4.4	0.0	0.0
	UG/LCL 1%	0.0	-0.0	0.0	0.0	11.3	79.6	0.0	0.0
	OG/UCL 1%	0.0	0.4	0.0	0.0	20.3	88.6	0.0	0.0
	UG/LCL 5%	0.0	-0.0	0.0	0.0	12.6	80.9	0.0	0.0
	OG/UCL 5%	0.0	0.3	0.0	0.0	19.0	87.3	0.0	0.0
	TS 1%	-	-	-	-	-	-	-	-
	TS 5%	-	-	-	-	-	-	-	-

BAYER AG

STUDIE-NR. / STUDY-NO. KWG 0519/006

BLUT-UNTERSUCHUNG / HAEMATOLOGY
24 MONATE / 24 MONTHS

DOSE DOSIS PPM		ERY TERA/L	RETI O/OO	LEU GIGA/L	THROM GIGA/L	HGB G/L	HCT L/L	MCH PG/E	MCHC G/L	MCV FL
MAENNLICH/MALE										
0	MW/MEANS	8.69	10	6.1	1169	145	0.452	16.7	321	52
	STAND	0.83	3	2.1	424	10	0.046	0.7	14	1
	UG/LCL 1%	7.84	7	3.9	733	134	0.404	16.0	307	51
	OG/UCL 1%	9.54	13	8.3	1604	155	0.500	17.4	335	53
	UG/LCL 5%	8.10	8	4.6	866	138	0.419	16.2	311	51
	OG/UCL 5%	9.28	12	7.7	1472	152	0.485	17.2	331	53
125	MW/MEANS	8.50	11	7.1	1012	139	0.446	16.3	312	53
	STAND	1.58	5	3.0	375	25	0.089	0.7	27	4
	UG/LCL 1%	6.88	5	4.0	627	113	0.355	15.6	285	49
	OG/UCL 1%	10.12	16	10.3	1398	164	0.538	17.0	340	57
	UG/LCL 5%	7.37	7	5.0	744	121	0.383	15.8	293	50
	OG/UCL 5%	9.63	15	9.3	1280	156	0.510	16.8	331	55
	TS 1%	-	-	-	-	-	-	-	-	-
	TS 5%	-	-	-	-	-	-	-	-	-
500	MW/MEANS	8.91	12	5.8	1156	146	0.461	16.5	318	52
	STAND	1.33	4	2.0	150	15	0.070	0.9	13	2
	UG/LCL 1%	7.54	8	3.7	1003	130	0.389	15.6	305	49
	OG/UCL 1%	10.28	15	7.9	1310	162	0.533	17.4	331	54
	UG/LCL 5%	7.95	9	4.4	1049	135	0.411	15.8	309	50
	OG/UCL 5%	9.86	14	7.3	1263	157	0.511	17.1	327	53
	TS 1%	-	-	-	-	-	-	-	-	-
	TS 5%	-	-	-	-	-	-	-	-	-
2000	MW/MEANS	8.66	7	5.6	1186	146	0.454	17.0	324	53
	STAND	1.21	10	1.5	300	14	0.062	1.2	22	2
	UG/LCL 1%	7.42	-0	4.0	878	132	0.391	15.8	301	51
	OG/UCL 1%	9.91	17	7.1	1493	161	0.518	18.2	347	54
	UG/LCL 5%	7.80	0	4.5	971	136	0.410	16.2	308	51
	OG/UCL 5%	9.53	14	6.7	1400	156	0.499	17.9	340	54
	TS 1%	-	-	-	-	-	-	-	-	-
	TS 5%	-	+	-	-	-	-	-	-	-

STUDIE-NR. / STUDY-NO. KWG 0519/006

BLUT-UNTERSUCHUNG / HAEMATOLOGY
24 MONATE / 24 MONTHS

DOSE DOSIS PPM		ERY TERA/L	RETI O/OO	LEU GIGA/L	THROM GIGA/L	HGB G/L	HCT L/L	MCH PG/E	MCHC G/L	MCV FL
WEIBLICH/FEMALE										
0	MW/MEANS	7.28	10	4.5	801	143	0.393	19.6	364	54
	STAND	0.34	5	1.0	119	7	0.019	1.2	19	2
	UG/LCL 1%	6.93	4	3.5	679	136	0.373	18.4	345	52
	OG/UCL 1%	7.64	15	5.5	924	150	0.413	20.9	383	56
	UG/LCL 5%	7.04	6	3.8	716	138	0.379	18.8	350	53
	OG/UCL 5%	7.53	13	5.2	886	148	0.407	20.5	377	55
125	MW/MEANS	7.03	10	4.2	815	137	0.361	19.6	382	51
	STAND	0.63	3	1.0	226	17	0.031	2.1	40	1
	UG/LCL 1%	6.39	7	3.1	583	129	0.329	17.4	340	50
	OG/UCL 1%	7.68	13	5.3	1047	144	0.392	21.7	423	52
	UG/LCL 5%	6.58	8	3.5	653	132	0.339	18.1	353	50
	OG/UCL 5%	7.49	12	5.0	977	142	0.383	21.1	410	52
	TS 1%	-	-	-	-	-	-	-	-	+
	TS 5%	-	-	-	-	-	-	-	-	+
500	MW/MEANS	8.20	9	4.3	943	141	0.433	17.2	326	53
	STAND	0.56	3	1.6	213	6	0.027	0.8	17	1
	UG/LCL 1%	7.62	6	2.4	724	134	0.405	16.4	309	52
	OG/UCL 1%	8.78	13	6.1	1163	148	0.461	18.1	344	54
	UG/LCL 5%	7.80	7	3.0	791	136	0.413	16.6	314	52
	OG/UCL 5%	8.60	12	5.5	1096	146	0.452	17.8	339	54
	TS 1%	+	-	-	-	-	+	+	+	-
	TS 5%	+	-	-	-	-	+	+	+	-
2000	MW/MEANS	7.37	12	4.8	952	138	0.384	18.8	361	52
	STAND	0.69	6	2.2	179	17	0.041	3.2	60	1
	UG/LCL 1%	6.67	6	2.5	768	120	0.343	15.5	299	51
	OG/UCL 1%	8.08	19	7.0	1135	155	0.426	22.1	423	54
	UG/LCL 5%	6.88	8	3.2	824	125	0.355	16.5	318	51
	OG/UCL 5%	7.87	17	6.3	1080	150	0.414	21.1	404	53
	TS 1%	-	-	-	-	-	-	-	-	-
	TS 5%	-	-	-	+	-	-	-	-	+

STUDIE-NR. / STUDY-NO. KWG 0519/006

DIFFERENTIALBLUTBILD / DIFFERENTIAL BLOOD COUNT (%)
24 MONATE / 24 MONTHS

DOSE DOSIS PPM		BASO	EOSIN	IPC JGL	STAB	SEGM	LYM	MONO	PLAS
MAENNLICH/MALE									
0	MW/MEANS	0.0	1.0	0.0	0.2	29.5	69.3	0.0	0.0
	STAND	0.0	0.7	0.0	0.4	9.5	9.6	0.0	0.0
	UG/LCL 1%	0.0	0.3	0.0	-0.0	19.7	59.4	0.0	0.0
	OG/UCL 1%	0.0	1.7	0.0	0.6	39.3	79.2	0.0	0.0
	UG/LCL 5%	0.0	0.5	0.0	-0.0	22.7	62.4	0.0	0.0
	OG/UCL 5%	0.0	1.5	0.0	0.5	36.3	76.2	0.0	0.0
125	MW/MEANS	0.0	0.7	0.0	0.2	33.0	66.0	0.1	0.0
	STAND	0.0	0.9	0.0	0.4	12.3	12.4	0.3	0.0
	UG/LCL 1%	0.0	-0.0	0.0	-0.0	20.4	53.2	-0.0	0.0
	OG/UCL 1%	0.0	1.7	0.0	0.6	45.6	78.8	0.4	0.0
	UG/LCL 5%	0.0	0.0	0.0	-0.0	24.2	57.1	-0.0	0.0
	OG/UCL 5%	0.0	1.4	0.0	0.5	41.8	74.9	0.3	0.0
	TS 1%	-	-	-	-	-	-	-	-
	TS 5%	-	-	-	-	-	-	-	-
500	MW/MEANS	0.0	0.6	0.0	0.5	32.4	66.5	0.0	0.0
	STAND	0.0	0.8	0.0	0.7	21.1	20.8	0.0	0.0
	UG/LCL 1%	0.0	-0.0	0.0	-0.0	10.7	45.1	0.0	0.0
	OG/UCL 1%	0.0	1.5	0.0	1.2	54.1	87.9	0.0	0.0
	UG/LCL 5%	0.0	-0.0	0.0	-0.0	17.3	51.6	0.0	0.0
	OG/UCL 5%	0.0	1.2	0.0	1.0	47.5	81.4	0.0	0.0
	TS 1%	-	-	-	-	-	-	-	-
	TS 5%	-	-	-	-	-	-	-	-
2000	MW/MEANS	0.0	0.6	0.0	0.4	29.9	69.1	0.0	0.0
	STAND	0.0	0.7	0.0	0.5	9.7	9.2	0.0	0.0
	UG/LCL 1%	0.0	-0.0	0.0	-0.0	19.9	59.6	0.0	0.0
	OG/UCL 1%	0.0	1.3	0.0	0.9	39.9	78.6	0.0	0.0
	UG/LCL 5%	0.0	0.1	0.0	0.0	23.0	62.5	0.0	0.0
	OG/UCL 5%	0.0	1.1	0.0	0.8	36.8	75.7	0.0	0.0
	TS 1%	-	-	-	-	-	-	-	-
	TS 5%	-	-	-	-	-	-	-	-

STUDIE-NR. / STUDY-NO. KWG 0519/006

DIFFERENTIALBLUTBILD / DIFFERENTIAL BLOOD COUNT (%)
24 MONATE / 24 MONTHS

DOSE DOSIS PPM		BASO	EOSIN	LPC JGL	STAB	SEGM	LYM	MONO	PLAS
WEIBLICH/FEMALE									
0	MW/MEANS	0.0	0.9	0.0	0.4	26.1	72.6	0.0	0.0
	STAND	0.0	0.9	0.0	0.5	9.6	9.5	0.0	0.0
	UG/LCL 1%	0.0	0.0	0.0	-0.0	16.2	62.8	0.0	0.0
	OG/UCL 1%	0.0	1.8	0.0	0.9	36.0	82.4	0.0	0.0
	UG/LCL 5%	0.0	0.3	0.0	0.0	19.2	65.8	0.0	0.0
	OG/UCL 5%	0.0	1.5	0.0	0.8	33.0	79.4	0.0	0.0
125	MW/MEANS	0.0	1.9	0.0	0.7	20.4	76.9	0.0	0.0
	STAND	0.0	2.8	0.0	1.3	12.8	15.6	0.0	0.0
	UG/LCL 1%	0.0	-0.0	0.0	-0.0	7.4	60.8	0.0	0.0
	OG/UCL 1%	0.0	4.8	0.0	2.0	33.6	93.0	0.0	0.0
	UG/LCL 5%	0.0	-0.0	0.0	-0.0	11.3	65.7	0.0	0.0
	OG/UCL 5%	0.0	3.9	0.0	1.6	29.7	88.1	0.0	0.0
	TS 1%	-	-	-	-	-	-	-	-
	TS 5%	-	-	-	-	-	-	-	-
500	MW/MEANS	0.0	0.9	0.0	0.1	14.7	84.3	0.0	0.0
	STAND	0.0	1.9	0.0	0.3	7.7	7.5	0.0	0.0
	UG/LCL 1%	0.0	-0.0	0.0	-0.0	6.7	76.6	0.0	0.0
	OG/UCL 1%	0.0	2.8	0.0	0.4	22.7	92.0	0.0	0.0
	UG/LCL 5%	0.0	-0.0	0.0	-0.0	9.2	78.9	0.0	0.0
	OG/UCL 5%	0.0	2.2	0.0	0.3	20.2	89.7	0.0	0.0
	TS 1%	-	-	-	-	-	+	-	-
	TS 5%	-	-	-	-	+	+	-	-
2000	MW/MEANS	0.0	0.5	0.0	1.2	26.0	72.3	0.0	0.0
	STAND	0.0	1.0	0.0	1.9	15.4	16.5	0.0	0.0
	UG/LCL 1%	0.0	-0.0	0.0	-0.0	10.2	55.4	0.0	0.0
	OG/UCL 1%	0.0	1.5	0.0	3.2	41.8	89.2	0.0	0.0
	UG/LCL 5%	0.0	-0.0	0.0	-0.0	15.0	60.5	0.0	0.0
	OG/UCL 5%	0.0	1.2	0.0	2.6	37.0	84.1	0.0	0.0
	TS 1%	-	-	-	-	-	-	-	-
	TS 5%	-	-	-	-	-	-	-	-

BAYER AG

STUDIE-NR. / STUDY-NO. KWG 0519/006

KLIN.-CHEM. UNTERSUCHUNGEN / CLINICAL CHEMISTRY
12 MONATE / 12 MONTHS

DOSE DOSIS PPM		ALP U/L	GOT U/L	GPT U/L	BILI µMOL/L	PROT/P EIW/P G/L	UREA HST MMOL/L	CREA KREA µMOL/L	CHOL MMOL/L	GLUC MMOL/L
MAENNLICH/MALE										
0	MW/MEANS	89	30.8	52.9	1.7	59.3	9.29	42	2.87	8.20
	STAND	23	17.1	39.1	0.7	3.5	1.96	4	0.45	1.14
	UG/LCL 1%	66	13.2	12.7	1.0	55.7	7.28	38	2.41	7.02
	OG/UCL 1%	113	48.4	93.0	2.4	62.9	11.30	46	3.34	9.37
	UG/LCL 5%	73	18.5	24.9	1.2	56.8	7.90	39	2.55	7.38
	OG/UCL 5%	105	43.0	80.8	2.2	61.8	10.69	45	3.20	9.01
125	MW/MEANS	90	29.2	69.3	2.2	58.2	10.33	39	2.76	8.80
	STAND	29	9.8	46.1	1.2	5.1	1.99	7	0.36	0.78
	UG/LCL 1%	60	19.1	21.9	1.0	53.0	8.28	31	2.40	8.01
	OG/UCL 1%	120	39.3	116.7	3.4	63.5	12.37	46	3.13	9.60
	UG/LCL 5%	69	22.2	36.3	1.4	54.6	8.90	33	2.51	8.25
	OG/UCL 5%	111	36.3	102.3	3.1	61.9	11.75	44	3.02	9.36
	TS 1%	-	-	-	-	-	-	-	-	-
	TS 5%	-	-	-	-	-	-	-	-	-
500	MW/MEANS	100	32.1	53.1	1.7	57.6	9.48	38	2.70	8.40
	STAND	25	3.4	12.6	0.5	2.3	1.27	5	0.31	0.67
	UG/LCL 1%	74	28.6	40.2	1.2	55.3	8.18	33	2.38	7.72
	OG/UCL 1%	125	35.6	66.0	2.2	59.9	10.79	44	3.02	9.09
	UG/LCL 5%	82	29.7	44.2	1.4	56.0	8.58	35	2.48	7.93
	OG/UCL 5%	117	34.5	62.1	2.0	59.2	10.39	42	2.92	8.88
	TS 1%	-	-	-	-	-	-	-	-	-
	TS 5%	-	+	-	-	-	-	-	-	-
2000	MW/MEANS	133	44.6	98.1	1.1	55.8	10.11	40	1.64	8.45
	STAND	47	7.1	39.2	0.5	2.2	1.48	4	0.46	0.73
	UG/LCL 1%	84	37.3	57.8	0.6	53.5	8.59	36	1.16	7.70
	OG/UCL 1%	181	51.8	138.4	1.6	58.0	11.63	44	2.11	9.20
	UG/LCL 5%	99	39.5	70.0	0.8	54.2	9.05	37	1.31	7.93
	OG/UCL 5%	166	49.6	126.1	1.5	57.3	11.17	43	1.97	8.97
	TS 1%	-	+	+	-	-	-	-	+	-
	TS 5%	+	+	+	-	+	-	-	+	-

STUDIE-NR. / STUDY-NO. KWG 0519/006

KLIN.-CHEM. UNTERSUCHUNGEN / CLINICAL CHEMISTRY
12 MONATE / 12 MONTHS

DOSE DOSIS PPM		ALP U/L	GOT U/L	GPT U/L	BILI µMOL/L	PROT/P EIW/P G/L	UREA HST MMOL/L	CREA KREA µMOL/L	CHOL MMOL/L	GLUC MMOL/L
WEIBLICH/FEMALE										
0	MW/MEANS	137	37.4	33.8	1.8	57.2	9.73	41	2.34	7.91
	STAND	39	10.1	10.2	0.4	2.2	1.49	4	0.35	0.70
	UG/LCL 1%	96	27.1	23.4	1.4	54.9	8.20	38	1.98	7.19
	OG/UCL 1%	177	47.7	44.3	2.3	59.5	11.26	45	2.69	8.63
	UG/LCL 5%	109	30.2	26.6	1.5	55.6	8.66	39	2.09	7.41
	OG/UCL 5%	164	44.6	41.1	2.1	58.8	10.80	44	2.59	8.41
125	MW/MEANS	143	52.8	46.8	2.4	55.5	11.21	45	2.24	7.89
	STAND	51	18.4	17.2	1.1	3.3	2.60	5	0.33	0.61
	UG/LCL 1%	91	33.9	29.2	1.3	52.1	8.53	40	1.91	7.26
	OG/UCL 1%	195	71.8	64.4	3.6	58.9	13.88	49	2.58	8.52
	UG/LCL 5%	106	39.7	34.5	1.6	53.1	9.35	41	2.01	7.45
	OG/UCL 5%	179	66.0	59.1	3.3	57.8	13.07	48	2.47	8.33
	TS 1%	-	-	-	-	-	-	-	-	-
	TS 5%	-	+	-	-	-	-	-	-	-
500	MW/MEANS	139	60.4	61.4	2.4	55.6	9.49	38	2.16	8.33
	STAND	29	30.6	42.3	0.8	2.3	1.26	6	0.28	0.44
	UG/LCL 1%	109	29.0	17.9	1.4	53.3	8.20	32	1.87	7.88
	OG/UCL 1%	169	91.9	104.8	3.3	58.0	10.78	44	2.45	8.78
	UG/LCL 5%	118	38.5	31.1	1.7	54.0	8.59	34	1.95	8.02
	OG/UCL 5%	160	82.3	91.6	3.0	57.3	10.39	42	2.36	8.65
	TS 1%	-	+	-	-	-	-	-	-	-
	TS 5%	-	+	-	-	-	-	-	-	-
2000	MW/MEANS	137	68.1	81.4	2.1	54.8	9.37	42	2.69	7.90
	STAND	29	24.0	31.0	0.8	2.3	1.26	6	0.12	0.65
	UG/LCL 1%	107	43.4	49.5	1.2	52.5	8.07	35	1.56	7.23
	OG/UCL 1%	167	92.8	113.3	3.0	57.1	10.67	48	1.81	8.57
	UG/LCL 5%	116	50.9	59.2	1.5	53.2	8.47	37	1.60	7.44
	OG/UCL 5%	158	85.3	103.6	2.7	56.4	10.28	46	1.77	8.37
	TS 1%	-	+	+	-	-	-	-	+	-
	TS 5%	-	+	+	-	-	-	-	+	-

STUDIE-NR. / STUDY-NO. KWG 0519/006

KLIN.-CHEM. UNTERSUCHUNGEN / CLINICAL CHEMISTRY
24 MONATE / 24 MONTHS

DOSE DOSIS PPM		ALP U/L	GOT U/L	GPT U/L	BILI µMOL/L	PROT/P EIW/P G/L	UREA HST MMOL/L	CREA KREA µMOL/L	CHOL MMOL/L	GLUC MMOL/L
MAENNLICH/MALE										
0	MW/MEANS	198	37.5	53.7	2.3	57.9	9.00	40	3.49	7.91
	STAND	127	7.4	36.8	0.6	4.7	1.34	4	0.85	0.62
	UG/LCL 1%	68	29.9	15.9	1.6	53.1	7.63	36	2.61	7.27
	OG/UCL 1%	329	45.0	91.5	3.0	62.7	10.37	44	4.36	8.54
	UG/LCL 5%	107	32.2	27.4	1.9	54.5	8.04	37	2.88	7.46
	OG/UCL 5%	289	42.7	80.0	2.7	61.3	9.96	43	4.09	8.35
125	MW/MEANS	427	54.0	71.4	2.7	56.2	8.54	35	2.51	7.45
	STAND	440	14.9	29.5	0.9	6.8	2.16	4	0.80	0.87
	UG/LCL 1%	-0	38.6	41.2	1.8	49.2	6.32	31	1.69	6.56
	OG/UCL 1%	878	69.3	101.7	3.6	63.2	10.76	39	3.34	8.35
	UG/LCL 5%	112	43.3	50.4	2.1	51.3	7.00	32	1.94	6.83
	OG/UCL 5%	741	64.7	92.5	3.4	61.1	10.08	38	3.09	8.08
	TS 1%	-	-	-	-	-	-	-	-	-
	TS 5%	-	+	-	-	-	-	+	+	-
500	MW/MEANS	308	58.2	88.0	2.8	60.6	9.18	34	2.91	7.96
	STAND	383	28.3	41.8	0.6	9.7	1.02	3	0.80	1.00
	UG/LCL 1%	-0	29.1	45.1	2.2	50.7	8.13	30	2.09	6.94
	OG/UCL 1%	702	87.4	130.9	3.5	70.6	10.22	37	3.74	8.98
	UG/LCL 5%	34	38.0	58.1	2.4	53.7	8.45	31	2.34	7.25
	OG/UCL 5%	582	78.5	117.9	3.3	67.6	9.90	36	3.49	8.67
	TS 1%	-	-	-	-	-	-	+	-	-
	TS 5%	-	-	+	+	-	-	+	-	-
2000	MW/MEANS	695	97.8	159.4	2.3	54.0	9.05	33	2.40	7.82
	STAND	572	94.6	139.5	1.0	5.3	1.40	4	2.46	1.83
	UG/LCL 1%	107	0.6	16.1	1.4	48.5	7.61	30	-0.00	5.94
	OG/UCL 1%	1283	195.0	302.7	3.3	59.4	10.49	37	4.93	9.70
	UG/LCL 5%	286	30.1	59.6	1.7	50.2	8.05	31	0.65	6.51
	OG/UCL 5%	1105	165.4	259.1	3.0	57.8	10.05	36	4.16	9.13
	TS 1%	+	+	+	-	-	-	+	+	-
	TS 5%	+	+	+	-	-	-	+	+	-

STUDIE-NR. / STUDY-NO. KWG 0519/006

KLIN.-CHEM. UNTERSUCHUNGEN / CLINICAL CHEMISTRY
24 MONATE / 24 MONTHS

DOSE DOSIS PPM		ALP U/L	GOT U/L	GPT U/L	BILI µMOL/L	PROT/P EIW/P G/L	UREA HST MMOL/L	CREA KREA µMOL/L	CHOL MMOL/L	GLUC MMOL/L
WEIBLICH/FEMALE										
0	MW/MEANS	255	40.0	30.7	2.6	58.2	8.87	35	2.45	6.64
	STAND	181	10.4	13.7	0.6	4.1	1.86	6	0.64	0.89
	UG/LCL 1%	69	29.3	16.6	2.1	54.1	6.96	29	1.79	5.73
	OG/UCL 1%	440	50.7	44.8	3.2	62.4	10.78	41	3.11	7.56
	UG/LCL 5%	125	32.5	20.8	2.2	55.3	7.54	31	1.99	6.01
	OG/UCL 5%	384	47.4	40.5	3.0	61.2	10.20	39	2.91	7.28
125	MW/MEANS	268	48.6	42.8	2.8	55.2	10.91	30	2.01	7.35
	STAND	154	19.8	17.9	0.5	5.3	2.16	4	0.68	0.87
	UG/LCL 1%	110	28.3	24.4	2.3	49.8	8.70	26	1.32	6.46
	OG/UCL 1%	427	69.0	61.2	3.3	60.6	13.13	33	2.71	8.24
	UG/LCL 5%	158	34.5	30.0	2.4	51.4	9.37	27	1.53	6.73
	OG/UCL 5%	379	62.8	55.6	3.1	59.0	12.45	32	2.50	7.97
	TS 1%	-	-	-	-	-	-	-	-	-
	TS 5%	-	-	-	-	-	+	+	-	-
500	MW/MEANS	196	53.6	48.0	2.2	53.9	10.53	31	2.44	7.41
	STAND	87	14.8	14.9	0.7	5.0	1.52	10	0.61	0.68
	UG/LCL 1%	106	38.4	32.7	1.4	48.8	8.96	21	1.82	6.71
	OG/UCL 1%	286	68.8	63.3	2.9	59.0	12.10	41	3.07	8.11
	UG/LCL 5%	134	43.0	37.3	1.6	50.4	9.44	24	2.01	6.93
	OG/UCL 5%	259	64.1	58.7	2.7	57.5	11.62	38	2.88	7.90
	TS 1%	-	-	-	-	-	-	-	-	-
	TS 5%	-	+	+	-	+	-	+	-	+
2000	MW/MEANS	628	185.7	283.5	2.6	56.7	11.45	34	2.83	6.71
	STAND	734	199.9	410.8	0.6	6.3	3.47	5	2.65	1.37
	UG/LCL 1%	-0	-0.0	-0.0	2.0	50.3	7.88	29	0.40	5.30
	OG/UCL 1%	1382	391.2	705.7	3.2	63.2	15.01	40	5.35	8.12
	UG/LCL 5%	103	42.8	-0.0	2.1	52.2	8.97	31	0.93	5.73
	OG/UCL 5%	1153	328.7	577.4	3.0	61.2	13.93	38	4.72	7.69
	TS 1%	+	+	+	-	-	-	-	-	-
	TS 5%	+	+	+	-	-	+	-	-	-

STUDIE-NR. / STUDY-NO. KWG 0519/006

ABSOLUTE ORGANGEWICHTE / ABSOLUTE ORGAN WEIGHTS (MG)

DOSE DOSIS PPM		BODY-W TIER-G (G)	HEART HERZ	LUNG LUNGE	LIV LEB	SPLE MILZ	KIDN NIE	TEST HO
MAENNLICH/MALE								
0	MW/MEANS	42	218	249	2294	125	828	196
	STAND	5	46	81	541	57	166	16
	UG/LCL 1%	38	177	176	1809	74	679	181
	OG/UCL 1%	46	259	321	2779	177	976	210
	UG/LCL 5%	39	189	197	1950	89	722	185
	OG/UCL 5%	45	247	300	2638	162	933	206
125	MW/MEANS	41	216	312	3164	208	781	190
	STAND	6	41	232	1777	193	104	37
	UG/LCL 1%	35	177	90	1465	24	681	155
	OG/UCL 1%	46	255	534	4862	392	880	226
	UG/LCL 5%	37	188	155	1969	78	710	165
	OG/UCL 5%	44	244	468	4358	337	851	216
	TS 1%	-	-	-	-	-	-	-
	TS 5%	-	-	-	-	-	-	-
500	MW/MEANS	41	196	256	2645	130	731	212
	STAND	5	31	140	1013	39	107	50
	UG/LCL 1%	36	170	138	1787	96	640	168
	OG/UCL 1%	45	222	374	3503	163	822	257
	UG/LCL 5%	38	177	172	2033	106	667	181
	OG/UCL 5%	44	215	341	3257	153	796	244
	TS 1%	-	-	-	-	-	-	-
	TS 5%	-	-	-	-	-	-	-
2000	MW/MEANS	38	209	253	3449	144	806	212
	STAND	4	49	57	1021	85	130	25
	UG/LCL 1%	35	175	213	2159	85	714	194
	OG/UCL 1%	40	244	293	4738	204	898	230
	UG/LCL 5%	36	184	224	2513	101	739	199
	OG/UCL 5%	40	234	282	4385	188	873	225
	TS 1%	-	-	-	+	-	-	-
	TS 5%	+	-	-	+	-	-	+

STUDIE-NR. / STUDY-NO. KWG 0519/006

ABSOLUTE ORGANGEWICHTE / ABSOLUTE ORGAN WEIGHTS (MG)

DOSE DOSIS PPM		BODY-W TIER-G (G)	HEART HERZ	LUNG LUNGE	LIV LEB	SPLE MILZ	KIDN NIE
WEIBLICH/FEMALE							
0	MW/MEANS	31	140	224	1656	195	510
	STAND	5	26	69	357	102	85
	UG/LCL 1%	27	121	173	1393	120	448
	OG/UCL 1%	35	159	275	1919	270	573
	UG/LCL 5%	29	126	187	1466	141	465
	OG/UCL 5%	34	154	261	1846	249	556
125	MW/MEANS	32	147	292	1900	355	514
	STAND	4	21	211	640	456	85
	UG/LCL 1%	29	131	136	1429	19	442
	OG/UCL 1%	34	162	447	2372	691	577
	UG/LCL 5%	30	135	179	1559	112	469
	OG/UCL 5%	33	158	404	2241	598	560
	TS 1%	-	-	-	-	-	-
	TS 5%	-	-	-	-	-	-
500	MW/MEANS	32	141	252	1801	190	496
	STAND	4	19	135	395	199	52
	UG/LCL 1%	29	128	157	1522	50	459
	OG/UCL 1%	34	154	348	2081	331	533
	UG/LCL 5%	30	131	183	1598	88	469
	OG/UCL 5%	34	150	322	2005	293	523
	TS 1%	-	-	-	-	-	-
	TS 5%	-	-	-	-	-	-
2000	MW/MEANS	30	142	205	2865	144	483
	STAND	3	17	37	2388	98	92
	UG/LCL 1%	28	131	181	1288	79	422
	OG/UCL 1%	32	153	230	4442	209	544
	UG/LCL 5%	29	134	187	1714	97	439
	OG/UCL 5%	32	150	223	4016	191	528
	TS 1%	-	-	-	+	-	-
	TS 5%	-	-	-	+	+	-

BAYER AG

STUDIE-NR. / STUDY-NO. KMG 0519/006

RELATIVE ORGANGEWICHTE / RELATIVE ORGAN WEIGHTS (MG/100G)

DOSE DOSIS PPM		BODY-W TIER-G (G)	HEART HERZ	LUNG LUNGE	LIV LEB	SPLE MILZ	KIDN NIE	TEST HO
MAENNLICH/MALE								
0	MW/MEANS	42	519	595	5459	297	1976	469
	STAND	5	98	184	1134	126	370	49
	UG/LCL 1%	38	431	430	4443	184	1644	425
	OG/UCL 1%	46	607	761	6476	410	2308	513
	UG/LCL 5%	39	457	478	4739	217	1740	437
	OG/UCL 5%	45	581	712	6180	377	2211	500
125	MW/MEANS	41	537	844	7652	511	1934	474
	STAND	6	105	856	4036	449	216	97
	UG/LCL 1%	35	437	26	3795	82	1728	381
	OG/UCL 1%	46	637	1662	11508	940	2141	566
	UG/LCL 5%	37	466	269	4940	210	1789	409
	OG/UCL 5%	44	607	1419	10363	813	2079	538
	TS 1%	-	-	-	-	-	-	-
	TS 5%	-	-	-	-	-	-	-
500	MW/MEANS	41	483	661	6506	320	1799	512
	STAND	5	68	479	2468	100	208	109
	UG/LCL 1%	36	425	255	4415	235	1623	414
	OG/UCL 1%	45	541	1066	8597	405	1976	609
	UG/LCL 5%	38	441	371	5014	259	1673	443
	OG/UCL 5%	44	524	950	7997	380	1925	581
	TS 1%	-	-	-	-	-	-	-
	TS 5%	-	-	-	-	-	-	-
2000	MW/MEANS	38	553	665	9047	377	2131	565
	STAND	4	112	115	4292	206	270	79
	UG/LCL 1%	35	473	584	6006	231	1939	509
	OG/UCL 1%	40	633	747	12087	523	2322	621
	UG/LCL 5%	36	495	606	6840	271	1992	524
	OG/UCL 5%	40	611	725	11253	483	2270	605
	TS 1%	-	-	-	+	-	-	+
	TS 5%	+	-	+	+	-	-	+

Vertraulich

Eigentum der Firma Bayer AG
Benutzung, Verwertung oder Weitergabe nur mit Einwilligung der Bayer AG gestattet

STUDIE-NR. / STUDY-NO. KMG 0519/006

RELATIVE ORGANGEWICHTE / RELATIVE ORGAN WEIGHTS (MG/100G)

DOSE DOSIS PPM		BODY-W TIER-G (G)	HEART HERZ	LUNG LUNGE	LIV LEB	SPLE MILZ	KIDN NIE
WEIBLICH/FEMALE							
0	MW/MEANS	31	451	724	5315	622	1642
	STAND	5	74	216	989	300	252
	UG/LCL 1%	27	397	565	4586	401	1456
	OG/UCL 1%	35	506	883	6044	843	1827
	UG/LCL 5%	29	412	609	4788	462	1507
	OG/UCL 5%	34	491	839	5842	782	1776
125	MW/MEANS	32	468	979	5978	1054	1630
	STAND	4	66	898	1581	1260	191
	UG/LCL 1%	29	419	317	4813	126	1490
	OG/UCL 1%	34	517	1640	7142	1982	1771
	UG/LCL 5%	30	432	500	5135	383	1529
	OG/UCL 5%	33	503	1457	6820	1726	1732
	TS 1%	-	-	-	-	-	-
	TS 5%	-	-	-	-	-	-
500	MW/MEANS	32	448	819	5690	593	1577
	STAND	4	55	500	972	612	114
	UG/LCL 1%	29	409	465	5001	160	1496
	OG/UCL 1%	34	487	1173	6379	1027	1657
	UG/LCL 5%	30	420	562	5190	279	1518
	OG/UCL 5%	34	477	1076	6190	908	1635
	TS 1%	-	-	-	-	-	-
	TS 5%	-	-	-	-	-	-
2000	MW/MEANS	30	467	677	9086	472	1587
	STAND	3	28	112	6498	319	262
	UG/LCL 1%	28	449	603	4795	261	1414
	OG/UCL 1%	32	486	750	13378	682	1759
	UG/LCL 5%	29	454	623	5954	318	1460
	OG/UCL 5%	32	481	731	12218	625	1713
	TS 1%	-	-	-	+	-	-
	TS 5%	-	-	-	+	+	-

BAYER AG

STUDIE-NR. / STUDY-NO KMG 0519/006

FUTTERAUFNAHME / FOOD CONSUMPTION

DOSIS/DOSE PPM		W 1	W 2	W 3	W 4	W 5	W 6	W 7	W 8	W 9	W 10	W 11	W 12	W 13
MAENNLICH/MALE														
0	G/GRUPPE	2362	2710	2540	2596	2646	2612	2528	2666	2849	2717	2864	2939	2807
	DIVISOR	350	350	350	350	350	350	350	350	400	350	350	300	344
	G/TIER/TAG	6.75	7.74	7.26	7.42	7.56	7.46	7.22	7.62	7.12	7.76	8.18	9.80	8.16
125	G/GRUPPE	2133	2559	2454	2336	2460	2570	2424	2579	2878	2657	2910	2800	2655
	DIVISOR	350	350	350	350	350	350	350	350	400	350	350	300	350
	G/TIER/TAG	6.09	7.31	7.01	6.67	7.03	7.34	6.93	7.37	7.19	7.59	8.31	9.33	7.59
500	G/GRUPPE	2126	2273	2402	2364	2564	2605	2313	2421	2866	2761	2868	2942	2810
	DIVISOR	350	350	350	350	350	350	350	350	400	350	350	300	350
	G/TIER/TAG	6.07	6.49	6.86	6.75	7.33	7.44	6.61	6.92	7.16	7.89	8.19	9.81	8.03
2000	G/GRUPPE	2242	2106	2478	2475	2550	2423	2543	2551	2874	2942	2902	2922	2713
	DIVISOR	350	350	350	350	350	350	350	350	400	350	350	300	350
	G/TIER/TAG	6.41	6.02	7.08	7.07	6.71	6.92	7.27	7.29	7.18	8.41	8.29	9.74	7.75

geprüft
Inst. f. Toxikologie
Archiv

Vertraulich

Eigentum der Firma Bayer AG
Benutzung, Verwertung oder Weitergabe nur mit Einwilligung der
Bayer AG gestattet

STUDIE-NR. / STUDY-NO ENG 0519/006

FUTTERAUFNAHME / FOOD CONSUMPTION

DOSIS/DOSE PPM	W 14	W 15	W 16	W 17	W 18	W 19	W 20	W 21	W 22	W 23	W 24	W 25	W 26
MAENNLICH/MALE													
0 G/GRUPPE	2755	2386	2793	2895	2735	2705	2540	2620	2826	2570	3187	2996	3207
DIVISOR	392	294	343	343	392	294	343	343	343	343	392	343	343
G/TIER/TAG	7.03	8.12	8.14	8.44	6.98	9.20	7.41	7.64	8.24	7.49	8.13	8.73	9.35
125 G/GRUPPE	2740	2515	2720	2800	2640	2911	2596	2603	2430	2390	2929	2914	3273
DIVISOR	400	300	350	350	400	300	350	350	350	350	399	343	343
G/TIER/TAG	6.85	8.38	7.77	8.00	6.60	9.70	7.42	7.44	6.94	6.83	7.34	8.50	9.54
500 G/GRUPPE	2622	2430	2702	2730	2789	2712	2445	2542	2950	2472	2648	3054	3481
DIVISOR	400	288	336	336	384	288	336	336	336	336	384	336	336
G/TIER/TAG	6.55	8.44	8.04	8.12	7.26	9.69	7.28	7.57	8.78	7.36	6.90	9.09	10.36
2000 G/GRUPPE	2651	2635	2775	2890	2880	2770	2516	2591	3113	2568	3204	3147	3727
DIVISOR	400	300	350	350	400	300	350	350	350	350	400	344	343
G/TIER/TAG	6.63	8.78	7.93	8.26	7.20	9.23	7.19	7.40	8.89	7.34	8.01	9.15	10.87

geprüft
Inst. f. Toxikologie
Archiv

STUDIE-NR. / STUDY-NO KMG 0519/006

FUTTERAUFNAHME / FOOD CONSUMPTION

DOSIS/DOSE PPM	W 27	W 28	W 29	W 30	W 31	W 32	W 33	W 34	W 35	W 36	W 37	W 38	W 39
MAENNLICH/MALE													
0 G/GRUPPE	3483	3350	2966	3140	3085	3383	3114	3265	2846	3049	3072	3587	3548
DIVISOR	343	392	290	336	336	336	336	336	288	432	336	240	377
G/TIER/TAG	10.15	8.55	10.23	9.35	9.18	10.07	9.27	9.72	9.88	7.06	9.14	14.95	9.41
125 G/GRUPPE	3402	3391	3307	3111	3109	3260	3261	3097	2730	3368	3614	3282	3620
DIVISOR	343	392	294	343	343	343	343	343	294	441	343	245	392
G/TIER/TAG	9.92	8.65	11.25	9.07	9.06	9.50	9.51	9.03	9.29	7.64	10.54	13.40	9.23
500 G/GRUPPE	3114	3452	3539	3065	3063	3182	3479	3068	2944	3354	3624	3314	3022
DIVISOR	336	384	288	336	336	336	336	336	288	432	336	240	384
G/TIER/TAG	9.27	8.99	12.29	9.12	9.06	9.47	10.35	9.13	10.22	7.76	10.79	13.81	7.87
2000 G/GRUPPE	3494	3482	3810	3039	3215	3075	3582	3297	3164	3283	3632	3751	3600
DIVISOR	343	392	294	343	343	337	336	336	288	432	336	240	384
G/TIER/TAG	10.19	8.88	12.96	8.86	9.37	9.12	10.66	9.81	10.99	7.60	10.81	15.63	9.37

geprüft
Inst. f. Toxikologie
Archiv

STUDIE-NR. / STUDY-NO RMG 0519/006

FUTTERAUFNAHME / FOOD CONSUMPTION

DOSIS/DOSE PP4	W 40	W 41	W 42	W 43	W 44	W 45	W 46	W 47	W 48	W 49	W 50	W 51	W 52
MAENNLICH/MALE													
0 G/GRUPPE	3251	3080	3131	2907	3048	3060	3205	3053	3201	3277	3011	3167	2943
DIVISOR	329	329	376	282	329	322	322	368	322	322	322	276	322
G/TIER/TAG	9.88	9.36	8.33	10.31	9.26	9.50	9.95	8.30	9.94	10.18	9.35	11.47	9.14
125 G/GRUPPE	3251	3099	3223	3004	3150	3135	3129	3190	3123	3255	3011	3107	2894
DIVISOR	343	343	392	294	343	343	343	392	336	336	336	288	336
G/TIER/TAG	9.48	9.03	8.22	10.22	9.18	9.14	9.12	8.14	9.29	9.69	8.96	10.79	8.61
500 G/GRUPPE	3345	3282	3227	3378	3401	3176	3401	2915	3053	3170	3112	3015	3112
DIVISOR	336	336	384	288	336	336	336	384	336	336	336	287	329
G/TIER/TAG	9.96	9.77	8.40	11.73	10.12	9.45	10.12	7.59	9.09	9.43	9.26	10.51	9.46
2000 G/GRUPPE	3571	3462	3350	3104	3451	3232	3354	3321	3226	3131	3197	3263	3101
DIVISOR	336	336	384	288	336	336	334	376	322	322	322	276	322
G/TIER/TAG	10.63	10.30	8.72	10.78	10.27	9.62	10.03	8.83	10.02	9.72	9.93	11.82	9.63

BAYER AG
geprüft
Inst. f. Toxikologie
Archiv
033

STUDIE-NR. / STUDY-NO KBG 0519/006

FUTTERAUFNAHME / FEED CONSUMPTION

DOSIS/DOSE PPM	W 53	W 54	W 55	W 56	W 57	W 58	W 59	W 60	W 61	W 62	W 63	W 64	W 65
MAENNLICH/MALE													
0 G/GRUPPE	2672	2490	3321	3071	3079	2833	2987	3174	2947	3243	3001	2850	2877
DIVISOR	322	322	367	270	315	315	315	315	312	308	307	299	287
G/TIER/TAG	8.30	7.73	9.05	11.37	9.77	8.99	9.48	10.08	9.45	10.53	9.78	9.53	10.02
125 G/GRUPPE	2613	2611	2825	2969	2891	2883	2934	3172	3114	3150	2964	2778	3006
DIVISOR	333	327	368	275	322	322	322	322	319	315	315	315	315
G/TIER/TAG	7.85	7.98	7.68	10.75	8.98	8.95	9.11	9.85	9.76	10.00	9.41	8.82	9.54
500 G/GRUPPE	2600	2479	3339	3101	2914	2702	2801	2870	2851	3051	2951	2801	2934
DIVISOR	326	322	367	270	310	299	294	294	294	294	294	294	294
G/TIER/TAG	7.98	7.70	9.10	11.49	9.40	9.04	9.53	9.76	9.70	10.38	10.04	9.53	10.15
2000 G/GRUPPE	2924	2623	3168	3234	3298	2873	3106	3382	2871	3278	3027	3064	3320
DIVISOR	316	306	344	258	301	301	301	296	294	294	294	294	294
G/TIER/TAG	9.25	8.57	9.21	12.53	10.96	9.54	10.32	11.43	9.77	11.15	10.30	10.42	11.29

geprüft
Inst. f. Toxikologie
Archiv

STUDIEN-NR. / STUDY-NO ANG 0519/006

FUTTERAUFNAHME / FOOD CONSUMPTION

DOSIS/DOSE PPM		W 66	W 67	W 68	W 69	W 70	W 71	W 72	W 73	W 74	W 75	W 76	W 77	W 78
MAENNLICH/MALE														
0	G/GRUPPE	2905	2921	2976	2823	2887	3034	2867	2530	2573	2839	3031	3196	3182
	DIVISOR	287	287	287	287	246	287	328	287	280	240	360	240	280
	G/TIER/TAG	10.12	10.18	10.37	9.84	11.74	10.57	8.74	8.82	9.19	11.83	8.42	13.32	11.36
125	G/GRUPPE	2924	3018	2932	2803	2641	2947	2966	2584	2541	2857	3439	2984	2675
	DIVISOR	315	309	308	304	252	288	320	273	273	232	342	223	251
	G/TIER/TAG	9.28	9.77	9.52	9.22	10.48	10.23	9.27	9.47	9.31	12.31	10.06	13.38	10.66
500	G/GRUPPE	2984	3031	2789	3070	2723	2869	2895	2504	2616	2694	3549	2838	2887
	DIVISOR	288	287	281	278	234	273	306	259	259	222	333	217	252
	G/TIER/TAG	10.36	10.56	9.93	11.04	11.64	9.82	9.46	9.67	10.10	12.14	10.66	13.08	11.46
2000	G/GRUPPE	3087	3076	3049	3149	2886	2952	2891	2528	2899	3035	3483	3113	3187
	DIVISOR	294	292	281	280	240	277	312	271	266	228	342	228	264
	G/TIER/TAG	10.50	10.53	10.85	11.25	12.02	10.66	9.27	9.33	10.90	13.31	10.18	13.65	12.07

Geprüft
Inst. f. Toxikologie
Archiv

BAYER AG

035

STUDIE-NR. / STUDY-NO KMG 0519/006

FUTTERAUFNAHME / FEED CONSUMPTION

DOSIS/DOSE PPM		W 79	W 80	W 81	W 82	W 83	W 84	W 85	W 86	W 87	W 88	W 89	W 90	W 91
MAENNLICH/MALE														
0	G/GRUPPE	2886	3341	2006	2745	2392	2412	2334	2682	2749	2764	2862	2690	2515
	DIVISOR	277	273	273	269	222	291	250	239	238	233	226	192	215
	G/TIER/TAG	10.42	12.24	7.35	10.17	10.77	8.29	9.34	11.22	11.55	11.86	12.66	14.01	11.70
125	G/GRUPPE	2533	2668	2124	2218	1879	1934	1996	2117	1860	2115	2282	2145	2352
	DIVISOR	236	223	217	215	174	218	189	189	186	179	173	137	154
	G/TIER/TAG	10.73	11.96	9.79	10.32	10.80	8.87	10.56	11.20	10.00	11.82	13.19	15.66	15.27
500	G/GRUPPE	2575	2756	2010	2341	2058	2219	1924	2661	2707	2657	2865	2532	2907
	DIVISOR	252	252	244	237	198	264	231	230	223	217	217	186	197
	G/TIER/TAG	10.22	10.94	8.24	9.88	10.39	8.41	8.33	11.57	12.14	12.24	13.20	13.61	14.76
2000	G/GRUPPE	2851	3140	2290	2691	2514	2542	2382	2145	2361	2659	2940	2631	2982
	DIVISOR	259	259	257	247	199	264	229	224	223	217	217	183	210
	G/TIER/TAG	11.01	12.12	8.91	10.73	12.63	9.63	10.40	9.58	10.59	12.25	13.55	14.38	14.20

geprüft
Inst. f. Toxikologie
Archiv

STUDIE-NR. / STUDY-NO KWS 0519/0006

FUTTERAUFNAHME / FOOD CONSUMPTION

DOSIS/DOSE PPM		W 92	W 93	W 94	W 95	W 96	W 97	W 98	W 99	W 100	W 101	W 102	W 103	W 104	W 105
MAENNLICH/MALE															
0	G/GRUPPE	2014	1611	1747	1841	1620	1568	1797	1739	1724	1477	1335	1407	638	692
	DIVISOR	202	196	189	209	145	160	154	154	144	160	126	101	72	60
	G/TIER/TAG	9.97	8.22	9.24	8.81	11.25	9.80	11.67	11.29	11.97	9.23	10.60	13.93	8.86	11.53
125	G/GRUPPE	1630	1372	1855	1785	1494	1665	1450	1335	1463	1351	1092	1132	597	735
	DIVISOR	154	154	153	167	119	133	123	119	112	112	96	88	66	55
	G/TIER/TAG	10.97	8.91	12.12	10.69	12.55	11.02	11.79	11.22	13.06	12.06	11.37	12.86	9.05	13.36
500	G/GRUPPE	1804	1306	1688	1906	1799	1736	1646	1382	1362	1389	1118	1180	630	685
	DIVISOR	180	175	174	190	134	142	124	114	112	128	110	107	78	65
	G/TIER/TAG	10.02	7.46	9.70	10.03	13.43	12.23	13.27	12.12	12.16	10.85	10.16	11.03	8.08	10.54
2000	G/GRUPPE	1850	1334	1648	1748	1734	1536	1656	1504	1525	1503	1389	1547	1057	1054
	DIVISOR	181	161	161	184	134	144	140	140	140	160	138	149	106	85
	G/TIER/TAG	10.22	8.29	10.24	9.50	12.72	10.67	11.83	10.74	10.89	9.39	10.07	10.38	9.97	12.40

BAYER AG

geprüft
Inst. f. Toxikologie
Archiv

037

STUDIE-NR. / STUDY-NO KMG 0519/006

FUTTERAUFNAHME / FOOD CONSUMPTION

DOSIS/DOSE PPM		W 1	W 2	W 3	W 4	W 5	W 6	W 7	W 8	W 9	W 10	W 11	W 12	W 13
WEIBLICH/FEMALE														
0	G/GRUPPE	2531	2636	2700	2840	2669	2756	2702	2868	2948	3050	2785	3049	2910
	DIVISOR	350	350	350	350	350	350	350	350	400	350	350	350	350
	G/TIER/TAG	7.23	7.53	7.71	8.11	7.63	7.87	7.72	8.19	7.37	8.71	7.96	8.71	8.31
125	G/GRUPPE	2588	2500	2685	2695	2733	2658	2735	3023	2868	3030	2904	3105	3170
	DIVISOR	350	350	350	350	350	350	350	350	400	350	350	350	350
	G/TIER/TAG	7.39	7.14	7.67	7.70	7.81	7.59	7.81	8.64	7.17	8.66	8.30	8.87	9.06
500	G/GRUPPE	2311	2318	2370	2415	2732	2373	2473	2816	2900	3108	3037	2992	2910
	DIVISOR	350	350	350	350	350	350	350	350	400	349	343	343	343
	G/TIER/TAG	6.60	6.62	6.77	6.90	7.81	6.78	7.07	8.05	7.25	8.91	8.85	8.72	8.48
2000	G/GRUPPE	2495	2219	2208	2156	2458	2315	2575	2380	2960	2985	2860	3122	3012
	DIVISOR	350	350	350	350	350	350	350	350	400	350	350	350	350
	G/TIER/TAG	7.13	6.34	6.31	6.16	7.02	6.61	7.36	6.80	7.40	8.53	8.17	8.92	8.61

geprüft
Inst. f. Toxikologie
Archiv

BAYER AG

STUDIE-NR. / STUDY-NO KMG-0519/006

FUTTERAUFNAHME / FEED CONSUMPTION

DOSIS/DOSE PPM	W 14	W 15	W 16	W 17	W 18	W 19	W 20	W 21	W 22	W 23	W 24	W 25	W 26
WEIBLICH/FEMALE													
0 G/GRUPPE	2540	2665	2640	2805	2800	2821	2721	2754	2847	2879	2142	3050	3526
DIVISOR	350	300	348	343	392	294	343	343	343	343	392	343	294
G/TIER/TAG	7.26	8.88	8.16	8.41	7.14	9.60	7.93	8.03	8.30	8.39	5.46	8.89	11.99
125 G/GRUPPE	2710	2742	2765	2875	2920	2801	2623	2908	3050	2685	2455	3375	3357
DIVISOR	350	300	350	350	400	300	350	350	350	350	396	343	294
G/TIER/TAG	7.74	9.14	7.90	8.21	7.30	9.34	7.49	8.31	8.71	7.67	6.20	9.84	11.42
500 G/GRUPPE	2715	2813	2885	2835	2892	2771	2742	2901	3348	2749	2324	3325	3568
DIVISOR	343	294	343	343	392	294	343	343	343	343	392	343	294
G/TIER/TAG	7.92	9.57	8.41	8.27	7.38	9.43	7.99	8.46	9.76	8.01	5.93	9.69	12.14
2000 G/GRUPPE	2690	2745	2800	2895	2819	2850	2730	2682	3721	2770	2731	3001	3755
DIVISOR	350	300	350	350	400	300	350	350	350	350	400	350	300
G/TIER/TAG	7.69	9.82	8.00	8.27	7.05	9.50	7.80	7.66	10.63	7.91	6.83	8.57	12.52

BAYER AG

geprüft
Inst. f. Toxikologie
Archiv

BAYER AG

039

Vertraulich

Eigentum der Firma Bayer AG
Benutzung, Verwertung oder Weitergabe nur mit Einwilligung der Bayer AG gestattet

STUDIE-NR. / STUDY-NO Kuu 0519/006

FUTTERAUFNAHME / FOOD CONSUMPTION

DOSIS/DOSE PPM	W 27	W 28	W 29	W 30	W 31	W 32	W 33	W 34	W 35	W 36	W 37	W 38	W 39
WEIBLICH/FEMALE													
0 G/GRUPPE	3836	3520	3525	3404	3260	3509	3349	3467	3563	3668	3488	3991	3471
DIVISOR	392	392	288	336	336	336	336	336	288	432	336	288	336
G/TIER/TAG	9.79	8.98	12.24	10.13	9.70	10.44	9.97	10.32	12.37	8.49	10.38	13.86	10.33
125 G/GRUPPE	3774	3325	3804	3394	3314	3575	3425	3384	3454	3706	3103	3347	4142
DIVISOR	392	392	294	343	343	343	343	330	282	423	329	282	329
G/TIER/TAG	9.63	8.48	12.94	9.90	9.66	10.42	9.99	10.25	12.25	8.76	9.43	11.87	12.59
500 G/GRUPPE	3754	3012	3967	3363	3345	3395	3380	3293	3514	3576	3548	2778	4554
DIVISOR	392	392	294	343	343	343	343	343	294	441	343	294	343
G/TIER/TAG	9.58	7.68	13.49	9.72	9.75	9.90	9.85	9.60	11.95	8.11	10.34	9.45	13.28
2000 G/GRUPPE	3565	3400	4110	3540	3382	3281	3512	3267	3499	3680	3803	3190	4526
DIVISOR	400	400	300	350	350	350	350	350	300	450	350	300	350
G/TIER/TAG	8.91	8.50	13.70	10.11	9.66	9.37	10.03	9.33	11.66	8.18	10.87	10.63	12.93

geprüft
Inst. f. Toxikologie
Archiv

STUDIE-NR. / STUDY-NO KK/00519/006

FUTTERAUFNAHME / FOOD CONSUMPTION

DOSIS/DOSE PPM	W 40	W 41	W 42	W 43	W 44	W 45	W 46	W 47	W 48	W 49	W 50	W 51	W 52
WEIBLICH/FEMALE													
0 G/GRUPPE	3941	3717	3663	3514	3472	3253	3411	3522	3432	3309	3351	3455	3247
DIVISOR	336	336	384	336	288	336	336	384	336	336	336	288	336
G/TIER/TAG	11.73	11.06	9.54	10.46	12.06	9.68	10.15	9.17	10.21	9.85	9.97	12.00	9.81
125 G/GRUPPE	3961	3677	3445	3364	3341	3321	3400	3391	3374	3192	3244	3351	3220
DIVISOR	322	322	360	315	270	315	313	352	303	301	301	258	301
G/TIER/TAG	12.30	11.42	9.57	10.68	12.37	10.54	10.86	9.63	11.14	10.60	10.78	12.99	10.70
500 G/GRUPPE	4346	3642	3545	3220	3440	3494	3512	3433	3433	3171	3281	3326	3001
DIVISOR	341	341	384	336	288	336	336	384	336	336	336	288	336
G/TIER/TAG	12.67	10.68	9.23	9.58	11.94	10.40	10.45	8.94	10.22	9.44	9.76	11.55	8.93
2000 G/GRUPPE	4418	3627	3568	3423	3529	3375	4441	3497	3522	3290	3256	3227	3264
DIVISOR	347	343	392	343	294	343	343	392	343	343	343	291	336
G/TIER/TAG	12.73	10.57	9.10	9.98	12.00	9.84	10.03	8.92	10.27	9.59	9.49	11.09	9.71

BAYER AG

geprüft
Inst. f. Toxikologie
Archiv

BAYER AG

STUDIEN-NR. / STUDY-NO: KWG 0519/006

FUTTERAUFNAHME / FEED CONSUMPTION

DOSIS/DOSE ppm	W 53	W 54	W 55	W 56	W 57	W 58	W 59	W 60	W 61	W 62	W 63	W 64	W 65
WEIBLICH/FEMALE													
0 G/GRUPPE	3252	3268	3884	3611	3492	3655	3391	3562	3631	3570	3377	3332	3345
DIVISOR	329	329	376	329	281	322	322	322	322	315	315	315	315
G/TIER/TAG	9.88	9.93	10.33	10.98	12.43	11.35	10.53	11.06	11.28	11.33	10.72	10.58	10.62
125 G/GRUPPE	2961	2920	3131	3230	3276	2998	3143	2919	2982	2975	2914	2840	3039
DIVISOR	297	294	335	287	246	287	287	287	281	267	256	252	247
G/TIER/TAG	9.97	9.93	9.35	11.25	13.32	10.45	10.95	10.17	10.61	11.14	11.38	11.27	12.30
500 G/GRUPPE	3029	3519	3580	3387	3433	3608	3481	3421	3437	3377	3247	3332	3392
DIVISOR	336	336	384	336	282	329	329	329	329	328	322	322	322
G/TIER/TAG	9.01	10.47	9.32	10.14	12.17	10.97	10.58	10.40	10.45	10.30	10.08	10.35	10.53
2000 G/GRUPPE	2993	3174	3122	3451	3276	2991	3103	3115	3475	3205	3223	3245	3298
DIVISOR	333	324	368	322	271	315	315	315	315	315	315	315	315
G/TIER/TAG	8.99	9.80	8.48	10.72	12.09	9.50	9.85	9.89	11.03	10.17	10.23	10.30	10.47

geprüft
Inst. f. Toxikologie
Archiv

STUDIE-NR. / STUDY-NO. Kw 05197/006

FUTTERAUFNAHME / FOOD CONSUMPTION

DOSIS/DOSE PPM	W 66	W 67	W 68	W 69	W 70	W 71	W 72	W 73	W 74	W 75	W 76	W 77	W 78
WEIBLICH/FEMALE													
0 G/GRUPPE	3315	3187	3232	3171	3139	3212	3138	3243	3414	3126	3747	3646	3348
DIVISOR	312	308	308	303	301	258	344	287	283	240	352	229	266
G/TIER/TAG	10.62	10.35	10.49	10.47	10.43	12.45	9.12	11.30	12.06	13.02	10.64	15.92	12.59
125 G/GRUPPE	3015	2992	2682	2697	2667	2696	2472	2477	2664	2693	3256	3134	2900
DIVISOR	241	238	238	238	238	204	272	238	238	204	306	204	238
G/TIER/TAG	12.51	12.57	11.27	11.33	11.21	13.22	9.09	10.41	11.19	13.20	10.64	15.36	12.18
500 G/GRUPPE	3245	3072	3160	3125	3240	3240	3062	2824	3546	3150	3968	3644	3760
DIVISOR	322	322	314	308	298	252	330	287	287	246	369	246	284
G/TIER/TAG	10.08	9.54	10.06	10.15	10.95	12.86	9.28	9.84	12.36	12.80	10.75	14.81	13.24
2000 G/GRUPPE	3211	3177	3122	3141	3297	3324	3105	2747	3183	2874	3539	3559	3383
DIVISOR	315	315	315	311	308	264	329	280	278	234	351	227	259
G/TIER/TAG	10.19	10.09	9.91	10.10	10.70	12.64	9.44	9.81	11.45	12.28	10.08	15.68	13.06

BAYER AG
geprüft
Inst. f. Toxikologie
Archiv
BAYER AG

STUDIE-Nr. / STUDY-NO KMG 0519/006

FUTTERAUFNAHME / FOOD CONSUMPTION

DOSIS/DOSE PPM		W 79	W 80	W 81	W 82	W 83	W 84	W 85	W 86	W 87	W 88	W 89	W 90	W 91
WEIBLICH/FEMALE														
0	G/GRUPPE	2943	3198	2706	2473	2833	2731	2742	2439	2405	3143	3114	2842	3002
	DIVISOR	259	254	242	238	204	242	234	223	217	211	210	180	210
	G/TIER/TAG	11.36	12.59	11.18	10.39	13.89	10.04	11.72	10.94	11.08	14.90	14.83	15.79	14.30
125	G/GRUPPE	3004	3102	2428	2298	2223	1857	2168	2932	2790	2694	2762	2952	2946
	DIVISOR	238	238	232	229	186	248	217	216	210	210	210	179	203
	G/TIER/TAG	12.62	13.03	10.47	9.64	11.95	7.49	9.99	13.57	13.29	12.83	13.15	16.49	14.51
500	G/GRUPPE	3623	3506	2768	2447	2191	2287	2221	2472	2395	2939	3099	2786	3009
	DIVISOR	264	258	252	242	198	264	230	224	224	220	209	170	195
	G/TIER/TAG	13.72	13.59	10.98	10.11	11.07	8.66	9.66	11.04	10.69	13.36	14.83	16.39	15.43
2000	G/GRUPPE	3369	3373	2677	2446	2413	2595	2438	2878	3085	2964	3012	2975	3029
	DIVISOR	257	252	251	245	210	280	240	236	231	226	218	180	210
	G/TIER/TAG	13.01	13.39	10.67	9.98	11.49	9.27	10.16	12.19	13.35	13.12	13.82	16.53	14.42

geprüft
Inst. f. Toxikologie
Archiv

STUDIE-NR. / STUDY-NO KWS 0515/0006

FUTTERAUFNAHME / FOOD CONSUMPTION

VER

DOSIS/DOSE PPM	W 92	W 93	W 94	W 95	W 96	W 97	W 98	W 99	W 100	W 101	W 102	W 103	W 104	W 105
WEIBLICH/FEMALE														
0 G/GRUPPE	2180	1965	2110	2214	1984	1945	1979	1919	1767	1542	1542	1460	965	1075
DIVISOR	210	210	203	216	196	167	152	145	140	133	125	144	96	96
G/TIER/TAG	11.31	9.36	10.39	10.25	13.59	11.65	13.02	13.23	12.62	11.59	12.34	10.14	10.05	11.20
125 G/GRUPPE	2376	1903	2053	1972	1816	1943	1804	1768	1771	1634	1499	1613	1094	1373
DIVISOR	190	189	182	208	155	174	157	154	154	154	148	165	98	96
G/TIER/TAG	12.51	9.75	11.28	9.48	11.72	10.99	11.49	11.48	11.50	10.61	10.13	9.78	11.16	14.30
500 G/GRUPPE	2355	1658	2104	2083	1995	2112	1982	1951	2214	1671	1682	1812	1255	1402
DIVISOR	189	189	177	192	144	168	154	154	154	154	151	178	107	102
G/TIER/TAG	12.46	8.77	11.89	10.85	13.85	12.57	12.22	12.67	14.38	10.85	11.14	10.18	11.73	13.75
2000 G/GRUPPE	2346	1705	2130	1938	1823	1825	1945	1922	1821	2031	1757	1929	1301	1452
DIVISOR	199	196	190	216	159	182	178	175	175	174	165	196	126	120
G/TIER/TAG	11.30	9.72	11.21	8.97	11.47	10.03	10.93	10.98	10.41	11.67	10.65	9.84	10.33	12.10

BAYER AG

geprüft
Inst. f. Toxikologie
Archiv

BAYER AG

045

STUDIE-NR. / STUDY-NO. KHG 0519/006

046

Inst. f. Toxikologie
Archiv

TIERGEWICHTE / BODY WEIGHTS (G)

DOSE DOSIS PPM	ANIM.NO TIER-NR	W 0	W 1	W 2	W 3	W 4	W 5	W 6	W 7	W 8	W 9
MAENNLICH/MALE											
0	1	27	27	29	31	31	32	33	34	33	35
	2	25	26	27	28	28	30	32	32	32	32
	3	27	27	27	26	30	31	31	33	33	34
	4	27	27	28	30	31	31	32	33	33	33
	5	24	26	27	25	31	31	32	33	34	34
	6	28	25	27	29	29	30	30	32	32	35
	7	25	28	29	30	31	31	33	34	34	35
	8	25	29	29	30	32	32	34	34	34	36
	9	26	26	27	29	30	30	31	32	31	32
	10	26	27	28	30	31	29	31	34	35	35
	11	26	26	28	30	31	32	33	33	33	34
	12	28	26	27	25	32	34	35	36	37	38
	13	27	27	28	28	29	29	30	32	32	33
	14	26	27	29	31	33	33	34	34	35	36
	15	26	27	26	29	31	32	32	32	31	33
	16	26	29	30	32	33	34	34	36	36	35
	17	26	26	27	29	31	32	32	33	33	34
	18	24	26	26	27	28	31	31	30	31	32
	19	25	26	28	30	31	32	33	32	32	33
	20	25	26	28	31	33	34	34	35	34	35
	21	25	26	27	28	29	30	30	30	31	31
	22	26	28	28	28	31	32	33	35	34	34
	23	28	27	27	28	30	30	30	31	31	32
	24	25	27	29	30	32	33	33	34	34	35
	25	26	27	28	28	30	29	31	32	32	34
	26	28	27	27	30	31	31	31	31	31	32
	27	26	27	27	28	30	31	31	33	33	34
	28	24	28	28	28	31	33	33	35	34	34
	29	28	29	30	32	33	34	34	31	35	37
	30	25	25	26	26	28	29	30	37	34	32
	31	24	27	27	30	31	32	32	30	33	34
	32	26	25	26	27	28	30	30	30	31	32
	33	27	30	30	30	31	33	33	33	34	35
	34	24	26	27	30	32	33	33	33	34	35
	35	25	27	26	27	29	31	31	31	31	33
	36	24	25	26	27	30	31	32	30	31	32
	37	25	27	27	25	28	31	30	30	29	31
	38	23	26	28	28	28	30	32	32	31	32
	39	24	27	30	32	32	33	33	34	34	34
	40	24	25	26	27	27	28	28	28	28	29
	41	24	23	24	25	27	28	30	29	29	31
	42	24	26	25	27	29	29	30	29	29	31
	43	24	24	25	26	27	27	30	29	29	29
	44	29	25	25	27	28	29	30	30	30	31
	45	28	25	26	26	27	28	29	28	29	30
	46	28	29	29	32	32	34	33	34	34	35
	47	26	29	30	29	29	33	32	35	36	39
	48	24	29	28	27	31	34	35	35	34	37
	49	27	28	28	31	32	32	34	35	34	35
	50	24	26	28	27	29	29	30	31	31	32

STUDIE-NR. / STUDY-NO. KWG 0519/006

TIERGEWICHTE / BODY WEIGHTS (G)

Inst. f. Toxikologie
Archiv
STICHPROBENWEISE
KONTROLLIERT
STICHPROBE 10 %

DOSE DOSIS PPM	ANIM.NO TIER-NR	W 0	W 1	W 2	W 3	W 4	W 5	W 6	W 7	W 8	W 9
MAENNLICH/MALE											
125	101	23	24	25	27	26	27	27	28	29	27
	102	27	29	30	32	32	32	32	34	34	35
	103	27	29	30	32	32	31	32	33	34	33
	104	24	27	27	28	30	29	30	33	33	32
	105	26	27	29	32	32	32	32	33	34	34
	106	28	29	31	33	34	34	34	35	37	37
	107	26	28	28	28	30	29	29	30	31	32
	108	25	27	28	29	29	30	29	31	29	31
	109	26	27	28	29	29	28	28	30	27	29
	110	24	26	26	29	30	31	30	32	32	34
	111	26	27	28	28	28	28	28	30	30	30
	112	27	29	27	28	29	28	31	34	35	35
	113	25	27	28	30	30	31	31	33	33	33
	114	24	26	28	29	30	31	30	31	31	31
	115	25	26	28	30	30	31	32	33	34	35
	116	24	26	26	29	29	30	30	31	31	31
	117	26	25	26	26	26	26	25	27	27	29
	118	26	27	26	28	30	32	31	33	33	34
	119	24	27	30	32	33	32	32	35	35	34
	120	25	25	25	26	27	27	28	29	29	30
	121	28	28	30	30	31	31	30	32	32	32
	122	25	25	26	28	28	28	27	28	31	30
	123	23	28	30	32	31	31	31	33	33	34
	124	29	28	29	30	30	30	31	32	32	34
	125	25	25	27	29	26	27	26	29	29	30
	126	31	30	28	28	28	29	30	32	32	33
	127	27	27	30	28	28	26	26	28	28	27
	128	27	30	31	32	32	33	34	36	35	36
	129	25	27	27	27	26	29	30	30	32	31
	130	26	28	30	32	30	33	32	33	34	34
	131	25	26	26	29	27	29	30	31	30	30
	132	25	27	30	31	30	30	30	31	32	31
	133	25	25	26	28	30	30	30	31	32	32
	134	26	26	28	30	30	32	32	33	34	35
	135	24	26	26	28	28	29	29	31	31	30
	136	27	27	27	30	31	32	31	34	34	34
	137	26	25	27	28	28	29	29	31	30	31
	138	22	28	29	30	31	33	33	35	34	35
	139	25	26	28	30	31	32	31	33	33	34
	140	23	23	23	24	25	24	24	26	25	26
	141	24	26	28	29	29	30	30	32	32	33
	142	24	24	26	28	28	29	29	31	31	32
	143	26	26	26	27	28	26	28	30	29	31
	144	27	27	27	28	28	28	29	30	29	29
	145	24	27	28	30	30	31	31	32	32	34
	146	26	28	29	31	31	32	32	34	34	37
	147	26	26	27	28	29	30	29	31	30	30
	148	25	26	26	27	27	26	28	30	30	31
	149	28	27	27	28	28	29	29	31	30	32
	150	25	27	28	30	30	30	31	31	32	34

BAYER AG LEVERKUSEN

STUDIE-NR. / STUDY-NO. KHG 0519/006

TIERGEWICHTE / BODY WEIGHTS (G)

Inst. f. Toxikologie
Archiv
STICHPROBENWEISE
KONTROLLIERT
STICHPROBE 10...%

DOSE DOSIS PPM	ANIM.NO TIER-NR	W 0	W 1	W 2	W 3	W 4	W 5	W 6	W 7	W 8	W 9
MAENNLICH/MALE											
500	201	24	25	27	28	29	29	29	30	30	31
	202	27	27	29	29	30	29	29	30	32	33
	203	25	28	28	27	28	30	27	28	31	33
	204	26	28	28	29	29	30	31	31	33	33
	205	24	26	29	28	29	30	30	31	31	33
	206	24	28	29	29	30	30	30	30	30	30
	207	28	27	27	28	28	28	30	30	30	31
	208	25	26	28	28	30	30	31	31	31	33
	209	24	25	26	27	27	28	29	29	30	22
	210	25	30	32	34	35	35	37	39	37	39
	211	28	27	26	27	27	27	28	29	31	31
	212	24	25	25	25	27	27	27	28	29	29
	213	24	26	28	29	31	29	30	32	32	32
	214	26	27	27	28	28	28	28	28	28	30
	215	25	27	29	29	30	30	29	32	32	32
	216	26	27	27	30	31	29	28	29	28	29
	217	24	28	28	27	30	30	30	30	31	34
	218	26	27	27	30	31	30	31	31	31	31
	219	26	27	28	29	29	30	32	31	31	32
	220	27	27	28	29	30	29	29	29	30	31
	221	26	26	26	26	27	27	28	28	30	29
	222	24	25	26	27	27	25	26	26	25	25
	223	24	27	28	29	30	29	31	31	30	32
	224	27	27	27	28	29	30	31	31	31	32
	225	28	26	26	29	30	30	32	30	32	30
	226	26	27	29	31	31	32	33	33	34	35
	227	27	27	27	29	32	33	34	34	34	35
	228	27	24	25	25	26	26	26	26	26	27
	229	24	29	29	30	31	30	32	32	31	34
	230	28	27	27	28	29	29	28	29	28	30
	231	26	27	27	30	31	31	32	33	33	34
	232	26	25	24	27	28	28	29	29	28	29
	233	25	25	24	25	27	27	27	27	29	30
	234	24	27	29	31	33	33	34	35	35	35
	235	26	29	30	28	30	30	31	32	32	34
	236	27	25	26	27	29	29	29	29	29	30
	237	24	26	28	31	31	31	33	32	33	34
	238	26	25	26	28	28	28	30	31	31	31
	239	25	28	28	29	30	30	30	31	31	32
	240	24	25	25	26	27	27	27	28	27	28
	241	23	25	24	25	25	24	26	28	27	29
	242	23	24	27	28	29	29	29	30	28	30
	243	25	26	29	30	30	29	30	31	30	32
	244	25	27	26	28	29	30	30	31	32	34
	245	23	24	27	30	32	32	32	34	33	34
	246	25	27	29	31	30	33	33	34	34	35
	247	27	29	28	29	31	31	32	31	31	34
	248	27	27	26	28	30	29	30	32	32	35
	249	24	25	26	27	28	29	30	30	31	31
	250	24	27	29	28	31	33	34	35	34	34

Vertraulich
Eigentum der Firma Bayer AG
Benutzung, Verwertung oder Weitergabe nur mit Einwilligung der Bayer AG gestattet

C49

Inst. f. Toxikologie
Archiv
STICHPROBENKONTROLLIERT
STICHPROBE 10 %

STUDIE-NR. / STUDY-NO. KWG 0519/006

TIERGEWICHTE / BODY WEIGHTS (G)

DOSE DOSIS PPM	ANIM.NO TIER-NR	W 0	W 1	W 2	W 3	W 4	W 5	W 6	W 7	W 8	W 9
MAENNLICH/MALE											
2000	301	27	29	28	26	28	32	32	31	32	33
	302	27	28	29	29	28	31	32	33	29	34
	303	24	26	30	29	29	31	31	31	31	32
	304	22	24	23	25	27	27	27	28	27	27
	305	27	28	28	29	29	31	31	32	32	34
	306	27	29	29	31	31	32	32	31	33	33
	307	23	25	25	25	25	26	26	26	27	27
	308	26	27	27	29	31	31	33	34	32	34
	309	27	27	26	28	29	29	30	30	31	30
	310	27	26	28	30	30	31	31	31	29	31
	311	26	26	29	29	30	30	31	31	31	32
	312	25	26	27	30	31	32	32	33	34	34
	313	28	27	28	30	30	31	32	31	31	33
	314	24	26	25	27	27	28	28	29	29	29
	315	23	24	24	26	26	27	26	27	28	27
	316	22	21	21	22	22	23	23	24	23	24
	317	26	27	27	28	30	30	30	31	31	31
	318	27	27	27	29	28	30	30	31	30	32
	319	26	28	27	29	29	31	32	31	32	31
	320	24	24	24	26	27	28	28	29	29	30
	321	25	26	26	27	28	28	29	29	29	28
	322	26	28	28	28	29	30	31	33	33	34
	323	26	26	26	27	28	28	29	29	26	30
	324	26	27	27	28	29	29	28	29	28	31
	325	24	25	26	27	27	27	28	28	26	28
	326	28	29	28	30	31	32	33	33	33	34
	327	30	30	31	33	34	34	35	34	34	35
	328	25	25	26	27	29	28	30	30	29	31
	329	28	27	28	29	30	31	31	31	30	31
	330	29	28	27	29	30	30	30	30	29	31
	331	25	28	28	31	31	32	32	32	31	34
	332	23	24	25	26	25	27	26	26	26	28
	333	26	27	25	28	26	28	28	25	26	27
	334	26	26	27	28	30	29	30	31	30	31
	335	26	26	26	27	26	27	28	26	26	29
	336	24	24	23	23	25	24	24	26	24	27
	337	25	26	27	27	29	29	30	31	30	31
	338	28	27	27	29	31	32	33	33	33	34
	339	24	23	22	23	24	25	26	26	23	26
	340	25	25	26	27	28	29	29	30	28	30
	341	24	25	26	27	28	29	30	30	29	30
	342	24	25	26	27	28	30	30	31	29	31
	343	25	27	27	28	29	30	31	29	31	33
	344	28	28	29	31	32	33	33	33	35	37
	345	23	24	24	26	27	28	29	29	30	29
	346	27	28	29	29	30	32	32	32	32	34
	347	29	29	29	31	33	34	35	35	34	35
	348	27	28	28	28	30	31	31	29	31	32
	349	25	24	28	28	28	29	30	29	30	31
	350	24	23	24	23	24	24	25	27	27	29

BAYER AG

STUDIE-NR. / STUDY-NO. KWG 0519/006

TIERGEWICHTE / BODY WEIGHTS (G)

Inst. f. Toxikologie
Archiv
STICHPROBENPLAN
KONTROLLIERT
STICHPROBE Nr. 11

DOSE PPM	ANIM.NO TIER-NR	W 10	W 11	W 12	W 13	W 14	W 15	W 18	W 21	W 24	W 27
MAENNLICH/MALE											
0	1	36	36	36	36	37	37	40	39	41	43
	2	33	33	34	34	33	34	35	36	36	39
	3	34	35	35	35	35	36	37	38	39	40
	4	33	33	34	34	34	34	35	36	36	37
	5	34	35	35	35	36	37	38	38	40	40
	6	33	32	32	33	32	34	35	36	36	37
	7	36	37	36	37	36	37	37	39	38	39
	8	36	36	37	38	37	38	38	39	40	42
	9	33	33	33	34	33	35	37	37	38	38
	10	36	36	37	37	37	38	42	45	46	47
	11	35	35	35	34	35	36	37	37	38	38
	12	39	41	40	41	41	42	43	48	49	51
	13	33	34	34	34	34	35	35	36	37	38
	14	37	38	39	40	39	41	42	45	45	46
	15	34	36	35	36	34	36	37	40	39	41
	16	36	36	36	36	37	39	42	42	42	44
	17	34	35	35	36	34	37	37	38	38	39
	18	32	33	32	33	33	34	34	35	35	37
	19	33	34	35	35	32	34	36	36	37	39
	20	36	36	37	37	38	39	41	43	43	43
	21	32	32	32	32	31	33	33	34	34	35
	22	34	35	35	36	34	36	40	41	42	44
	23	32	33	34	34	33	34	36	37	37	38
	24	34	35	35	35	35	36	38	40	39	41
	25	33	34	35	35	34	35	37	38	36	40
	26	32	32	32	35	34	36	36	36	37	38
	27	34	34	34	35	35	35	35	37	38	39
	28	34	34	35	35	34	35	38	39	39	41
	29	36	37	37	37	38	40	40	41	43	44
	30	32	33	32	33	34	34	36	37	37	38
	31	34	34	35	36	36	36	38	41	43	44
	32	30	32	32	35	32	34	33	35	36	37
	33	32	34	33	34	34	36	36	40	39	42
	34	36	37	37	37	38	39	41	42	43	45
	35	34	35	35	35	36	36	38	39	40	41
	36	32	32	33	33	32	33	33	34	35	37
	37	31	22	20							
	38	32	32	32	32	33	32	33	33	33	34
	39	34	35	36	36	34	36	37	38	38	39
	40	29	30	30	30	29	30	30	31	32	32
	41	30	29	31	30	29	31	32	32	33	35
	42	31	31	32	33	32	34	35	37	38	40
	43	30	30	30	30	29	30	31	31	30	32
	44	32	32	34	33	32	33	34	35	35	38
	45	29	30	31	32	32	32	34	34	34	36
	46	35	34	36	37	36	37	37	39	39	40
	47	38	38	38	38	37	38	39	41	39	41
	48	37	37	36	38	38	38	40	40	42	43
	49	35	36	36	35	36	38	40	45	46	50
	50	32	32	33	34	34	33	36	39	39	41

C51

STUDIE-NR. / STUDY-NO. KWG 0519/006

TIERGEWICHTE / BODY WEIGHTS (G)

Inst. f. Toxikologie
Archiv
STICHPROBENWEISE
KONTROLLIERT
STICHPROBE 20

DOSE DOSIS PPM	ANIM.NO TIER-NR	W 10	W 11	W 12	W 13	W 14	W 15	W 18	W 21	W 24	W 27
MAENNLICH/MALE											
125	101	27	28	30	30	29	30	32	31		
	102	35	38	38	38	40	42	43	46	48	49
	103	34	35	36	38	36	37	37	39	40	43
	104	32	33	33	34	34	34	36	38	38	40
	105	32	33	34	35	34	36	38	38	40	43
	106	38	40	40	40	40	42	42	43	45	47
	107	31	31	33	33	33	34	35	36	36	38
	108	31	33	32	34	33	34	36	38	37	39
	109	30	31	30	32	32	32	33	33	34	36
	110	34	35	35	35	36	37	40	42	43	44
	111	31	31	33	31	30	31	33	33	34	37
	112	35	35	34	36	34	36	39	40	42	44
	113	34	34	34	36	35	35	37	39	40	44
	114	30	32	32	33	33	34	35	37	39	40
	115	36	37	35	35	34	35	37	37	39	39
	116	31	31	32	34	34	35	36	36	35	37
	117	29	29	30	30	30	30	32	32	32	34
	118	33	35	36	37	36	38	42	46	48	50
	119	33	33	34	35	34	34	33	34	34	34
	120	30	30	31	31	31	31	31	31	32	32
	121	33	33	33	34	34	35	36	37	36	38
	122	28	28	28	30	29	29	31	31	31	34
	123	36	36	36	31	38	37	38	39	40	43
	124	34	33	32	34	34	35	36	38	37	40
	125	29	29	30	31	30	31	32	33	33	35
	126	33	34	33	34	33	35	36	36	36	41
	127	29	30	30	30	31	31	32	33	34	36
	128	35	37	36	37	36	37	37	39	40	42
	129	31	31	32	31	30	33	31	37	36	38
	130	33	35	35	35	35	35	36	36	37	38
	131	30	31	31	31	32	32	34	36	38	39
	132	32	32	32	33	33	34	35	37	39	42
	133	32	32	33	32	33	33	33	33	34	33
	134	35	34	33	35	35	35	36	36	38	39
	135	30	30	31	31	31	31	32	32	33	34
	136	35	35	35	35	35	36	38	39	40	42
	137	30	31	31	32	31	32	34	35	36	37
	138	35	35	35	36	37	37	38	42	40	42
	139	34	34	35	36	35	36	38	37	38	40
	140	26	25	26	27	28	29	28	28	30	31
	141	35	34	35	35	35	37	38	39	40	42
	142	31	31	31	33	33	34	36	37	38	38
	143	30	30	31	32	31	33	34	33	35	35
	144	31	31	31	31	30	32	33	33	33	34
	145	33	33	34	33	33	34	34	36	37	37
	146	33	35	36	38	37	39	40	40	42	47
	147	28	31	32	31	32	33	33	33	34	35
	148	32	31	32	33	32	34	36	38	41	45
	149	30	30	30	32	32	33	33	34	36	37
	150	34	34	35	35	36	36	38	39	41	44

BAYER AG BAYER AG BAYER AG

STUDIE-NR. / STUDY-NO. KHG 0519/C06

TIERGEWICHTE / BODY WEIGHTS (G)

Inst. f. Toxikologie
Archiv
STICHPROBENPRÜFUNG
KONTROLLIERT
STICHPROBE 48 %

DOSE DOSIS PPM	ANIM.NO TIER-NR	W 10	W 11	W 12	W 13	W 14	W 15	W 18	W 21	W 24	W 27
MAENNLICH/MALE											
500	201	31	30	32	33	33	34	37	36	38	40
	202	32	34	34	34	34	34	36	36	38	39
	203	34	34	33	32	32	33	33	33	35	38
	204	33	33	34	33	33	34	35	35	35	36
	205	32	31	33	32	32	33	34	34	35	36
	206	31	30	32	31	31	32	32	32	34	36
	207	31	31	31	31	31	31	32	32	33	34
	208	34	34	34	34	34	35	38	40	39	41
	209	29	31	29	32	32	31	31	33	33	34
	210	40	41	40	42	39	42	41	32	36	50
	211	32	32	32	32	30	33	35	34	35	36
	212	30	30	29	29	30	31	31	31	34	33
	213	33	32	32	32	33	33	36	37	37	43
	214	30	30	30	30	30	30	32	32	43	34
	215	32	32	32	33	34	34	34	37	38	30
	216	32	33	34	35	33	36	40	40	40	43
	217	33	34	33	34	35	34	37	38	39	40
	218	32	33	33	33	33	34	35	34	35	36
	219	33	33	33	33	34	35	36	37	38	39
	220	31	32	32	32	31	33	34	38	39	41
	221	29	30	30	31	30	31	32	33	35	36
	222	26	25	26	25						
	223	32	32	32	32	34	33	34	34	35	36
	224	32	33	34	34	34	34	35	34	35	37
	225	30	29	24	31						
	226	35	34	33	35	34	36	37	40	39	40
	227	36	36	36	37	37	39	40	44	37	47
	228	26	27	33	26	23	26	26	30	33	29
	229	33	34	35	35	34	35	37	36	38	37
	230	29	30	30	33	32	32	33	34	33	34
	231	33	34	28	35	35	35	37	39	31	40
	232	30	31	35	31	31	31	31	32	36	33
	233	30	29	33	30	27	36	30	31	38	31
	234	35	35	31	34	36	35	36	35	37	37
	235	33	34	35	30	33	35	36	36	35	37
	236	31	30	31	32	30	31	32	32	37	34
	237	34	34	35	35	35	35	35	36	30	39
	238	32	32	32	32	32	33	34	34	33	35
	239	31	32	32	32	33	34	34	35	32	39
	240	28	28	28	29	29	29	30	30	34	33
	241	29	30	29	31	30	31	32	32	37	34
	242	31	31	30	32	32	32	32	32	39	34
	243	32	31	32	32	31	33	34	33	38	36
	244	34	34	34	35	35	35	37	36	38	39
	245	34	34	34	34	35	36	36	36	37	39
	246	36	35	34	33	33	36	37	37	38	39
	247	35	33	34	37	34	36	36	37	36	40
	248	36	36	37	32	36	38	42	43	47	49
	249	32	31	31	34	30	31	32	33	33	34
	250	35	36	35	36	32	34	36	36	36	37

C53

STUDIE-NR. / STUDY-NO. KMG 0519/006

TIERGEWICHTE / BODY WEIGHTS (G)

Inst. f. Toxikologie
Archiv
STICHPROBENWEISE
KONTROLLIERT
STICHPROBE 10 %

DOSE DOSIS PPM	ANIM.NO TIER-NR	W 10	W 11	W 12	W 13	W 14	W 15	W 18	W 21	W 24	W 27
MAENNLICH/MALE											
2000	301	33	34	34	35	34	36	37	36	40	38
	302	34	35	36	37	36	37	41	43	41	45
	303	32	31	32	32	33	34	34	34	33	34
	304	29	28	28	29	29	29	31	30	31	32
	305	34	34	34	35	35	34	36	38	37	38
	306	33	33	33	33	32	33	33	36	35	36
	307	27	27	27	27	27	27	29	28	27	29
	308	34	35	35	36	36	36	38	39	38	40
	309	31	31	32	32	30	32	36	38	37	40
	310	32	32	31	32	31	32	33	36	33	35
	311	32	33	33	33	34	33	36	36	37	39
	312	34	34	34	35	33	35	36	36	35	37
	313	34	34	34	34	34	35	36	37	35	37
	314	30	29	29	30	30	31	31	32	33	33
	315	27	27	27	27	27	26	27	27	26	27
	316	26	26	23	23	23	24	26	27	26	27
	317	31	31	31	31	33	33	34	34	32	33
	318	31	30	31	31	32	32	34	35	37	38
	319	32	31	33	32	31	33	34	34	36	36
	320	30	30	31	31	31	32	33	34	35	36
	321	30	29	30	30	31	31	33	33	33	34
	322	35	33	34	35	35	36	36	37	37	39
	323	29	29	29	28	30	30	31	30	29	31
	324	30	29	30	30	30	31	32	32	32	32
	325	28	28	25	27	28	29	29	28	31	29
	326	35	34	35	36	35	36	37	37	37	40
	327	37	35	34	35	31	34	37	36	37	37
	328	31	31	32	32	31	31	32	31	32	33
	329	32	31	31	33	32	33	33	33	33	34
	330	31	28	30	32	32	33	31	34		
	331	33	32	32	33	31	33	32	32	33	30
	332	27	25	26	27	26	27	29	28	29	27
	333	26	26	25	27	28	29	29	27	28	26
	334	32	31	32	32	32	33	32	32	33	30
	335	28	29	28	28	30	31	32	32	33	34
	336	26	28	28	28	28	27	29	31	27	31
	337	32	31	33	33	33	35	36	36	35	37
	338	35	34	35	35	35	35	39	39	39	40
	339	26	25	25	25	26	26	26	26	26	25
	340	31	31	32	32	31	31	32	32	32	32
	341	31	29	30	31	31	31	32	32	32	33
	342	29	30	32	32	32	33	33	34	33	35
	343	32	32	30	32	33	33	35	34	34	35
	344	35	35	37	38	37	37	38	40	41	41
	345	30	29	30	31	29	30	32	31	31	32
	346	33	34	35	35	34	34	35	36	36	37
	347	34	34	36	35	34	35	34	35	35	36
	348	33	32	33	32	32	34	32	35	35	36
	349	31	30	32	32	31	31	32	32	33	34
	350	29	28	29	29	29	30	30	30	30	31

BAYER AG

C54

STUDIE-NR. / STUDY-NO. KWG 0519/006

TIERGEWICHTE / BODY WEIGHTS (G)

Inst. f. Toxikologie
Archiv
STICHPROBENWEISE
KONTROLLIERT
STICHPROBE 10 %

DOSE DOSIS PPM	ANIM.NO TIER-NR	W 30	W 33	W 36	W 39	W 42	W 45	W 48	W 51	W 54	W 57
MAENNLICH/MALE											
0	1	42	43	44	45	45	46	46	47	47	47
	2	41	41	44	47	47	48	49	50	51	50
	3	40	41	42	43	44	44	43	44	43	45
	4	37	38	38	37	39	39	40	38	40	41
	5	42	44	44	45	46	46	45	48	50	51
	6	38	38	39	39	39	36	37	38	38	37
	7	39	39	40	41	42	43	43	43	42	43
	8	41	42	34	44	45	46	46	46	49	48
	9	39	39	39	40	40	41	42	41	42	41
	10	47	45	44	46	48	48	48	48	49	47
	11	39	39	38	40	41	41	42	41	43	43
	12	53	53	54	55	56	56	56	56	58	59
	13	39	38	38	38	39	41	42	41	42	41
	14	46	47	48	48	45					
	15	39	41	41	43	42	41	42	43	44	46
	16	43	44	44	47	47	48	48	50	50	50
	17	39	40	40							
	18	36	36	38	37	38	37	38	36	38	37
	19	37	36	37	37	36	36	36	36	36	37
	20	43	43	44	45	45	47	46	48	48	48
	21	36	35	36	37	38	38	38	38	39	39
	22	37	44	44	47	45	46	47	46	46	45
	23	38	38	39	38	38	40	40	39	40	41
	24	41	42	41	41	42	43	43	42	43	42
	25	40	40	41	43	43	43	44	44	46	46
	26	37	38	37	38	38	38	39	39	40	40
	27	39	40	41	41	42	43	43	43	44	44
	28	40	42	41	43	43	44	44	44	45	45
	29										
	30	37	38	39	40	41	40	41	40	41	40
	31	46	46	47	38	50	50	51	50	53	53
	32	37	37	39	41	41	42	42	44	46	46
	33	41	43	44	45	46	46	46	48	50	50
	34	45	46	46	46	47	48	47	50	52	52
	35	41	42	41	42	43	44	43	44	47	45
	36	37	38	39	40	41	42	43	41	43	42
	37										
	38	34	34	39	35	35	37	37	37	39	38
	39	39	39	35	47	43	41	42	42	41	42
	40	32	32	31	39	33	33	34	32	33	32
	41	34	32	33	41	35	36	37	36	36	35
	42	41	41	39	50	46	47	47	48	49	48
	43	33	32	31	38	33	33	34	33	33	32
	44	37	37	36	46	41	42	42	42	44	44
	45	36	37	37	44	39	39	39	37	40	39
	46	40	40	41	48	41	42	42	42	42	
	47	40	41	40	47	43	42	43	42	43	42
	48	45	45	46	52	47	48	48	48	49	49
	49	50	51	51	60	54	54	53	55	58	57
	50	40	39	39	45	39	38	39	39	41	38

STUDIE-NR. / STUDY-NO. KWG 0519/006

TIERGEWICHTE / BODY WEIGHTS (G)

Inst. f. Toxikologie
Archiv
STICHPROBENVERSUCH
KONTROLLTEST
STICHPROBE 10 %

DOSE DOSIS PPM	ANIM.NO TIER-NR	W 30	W 33	W 36	W 39	W 42	W 45	W 48	W 51	W 54	W 57
MAENNLICH/MALE											
125	101										
	102	49	52	53	53	54	55	56	55	56	54
	103	43	44	45	46	45	47	47	47	48	46
	104	41	42	43	46	47	50	50	52	51	50
	105	42	44	43	44	46	48	48	48	50	49
	106	48	48	47	49	50	51	50	52	53	53
	107	37	38	38	38	39	39	40	41	43	43
	108	40	40	41	42	42	43	43	43	43	43
	109	36	34	37	36	38	37	38	38	36	38
	110	45	46	47	48	48	49	49	52	51	51
	111	37	38	34	39	40	41	42	42	43	43
	112	46	48	48	51	52	53	53	52	54	55
	113	46	47	44	47	48	50	50	51	51	51
	114	39	40	42	41	43	43	43	43	43	42
	115	39	40	41	41	42	42	41	43	44	44
	116	36	36	37	38	38	40	41	41	42	41
	117	32	33	34	34	34	35	36	35	35	35
	118	50	52	53	54	55	54	54	56	57	56
	119	35	33	35	38	38	38	38	38	39	39
	120	33	32	33	34	35	35	36	35	37	36
	121	38	39	38	39	39	40	40	40	40	39
	122	35	34	34	34	35	34	35	34	35	36
	123	43	42	43	43	43	44	44	44	45	46
	124	39	40	38	40	40	40	41	40	42	40
	125	35	35	35	36	36	36	36	36	36	36
	126	40	41	41	43	45	46	46	50	50	51
	127	35	36	37	37	38	39	40	39	40	41
	128	42	43	43	43	44	43	43	43	43	45
	129	40	39	39	41	42	40	41	35		
	130	37	39	39	39	41	42	42	41	42	43
	131	37	37	37	40	40	40	41	40	41	42
	132	42	43	44	46	49	48	49	48	50	50
	133	34	34	35	35	33	35	36	37	38	38
	134	38	39	39	39	36	37	37	39	42	40
	135	34	34	35	36	33	36	36	37	37	37
	136	42	43	44	43	44	44	43	44	45	46
	137	37	39	38	38	39	40	41	41	41	40
	138	43	44	43	46	44	46	46	47	49	48
	139	40	40	41	40	42	42	41	43	44	44
	140	32	33	33	33	34	35	36	35	36	37
	141	43	43	44	45	46	47	47	46	47	47
	142	39	40	40	40	40	41	41	42	44	42
	143	36	36	36	38	39	40				
	144	34	35	35	36	37	38	39	39	40	41
	145	38	38	39	40	41	41	42	41	44	42
	146	47	48	48	49	50	51	51	52		
	147	35	36	37	36	37	37	37	38	39	38
	148	45	46	48	49	49	49	49	52	52	52
	149	37	38	38	39	38	38	37	39	38	39
	150	45	45	45	47	47	48	48	50	51	51

BAYER AG BAYER AG BAYER AG

C56

STUDIE-NR. / STUDY-NO. KWG 0519/006

TIERGEWICHTE / BODY WEIGHTS (G)

Inst. f. Toxikologie
Archiv
STICHPROBENARCHIV
KONTROLLIERT
STICHPROBE 10

DOSE DOSIS PPM	ANIM.NO TIER-NR	w 30	w 33	w 36	w 39	w 42	w 45	w 48	w 51	w 54	w 57
MAENNLICH/MALE											
500	201	42	42	43	45	44	44	45	47	47	48
	202	40	40	39	41	40	41	42	43	45	45
	203	41	42	39	41	39	38	38	40	40	39
	204	36	37	36	37	37	37	38	38	35	37
	205	36	36	37	37	37	38	39	39	39	40
	206	37	36	34	36	37	39	40	38	39	40
	207	34	34	34	35	35	36	36	38	39	
	208	42	43	43	45	45	45	44	45	48	50
	209	35	34	35	36	38	37	38	39	39	38
	210	51	51	51	51	51	53	53	55	57	58
	211	37	38	37	39	37	38	38	38	40	41
	212	33	34	33	33	33	33	34	33	35	35
	213	44	45	44	45	45	47	47	49	49	49
	214	35	36	36	36	36	37	37	37	38	39
	215	38	39	39	40	39	39	40	40	42	42
	216	43	43	44	44	43	43	43	41	43	45
	217	42	42	43	43	44	44	45	44	45	46
	218	36	36	36	37	37	38	38	38	38	40
	219	41	41	41	41	42	42	43	44	45	46
	220	42	43	44	45	45	45	45	45	46	45
	221	38	39	38	37	36	38	38	39	41	
	222										
	223	37	36	36	35	37	36	37	38	37	38
	224	39	39	38	38	39	38	38	41	43	43
	225										
	226	43	43	44	45	44	45	45	47	48	50
	227	49	49	49	52	49	49	48	50	51	52
	228	29	30	32	31	33	33	34	34	34	30
	229	38	39	37	38	36	32	34			
	230	35	35	35	38	37	36	36	37	38	39
	231	42	44	42	44	45	46	46	44		
	232	34	34	34	34	35	35	36	35	36	35
	233	32	32	32	33	33	33	34	34	34	34
	234	37	36	37	38	37	38	39	39	39	40
	235	38	38	37	39	39	39	40	41	41	42
	236	34	34	34	35	35	35	35	36	36	36
	237	38	39	40	41	40	40	39	40	42	41
	238	35	35	35	37	37	36	36	38	39	39
	239	39	39	39	40	41	40	41	42	43	44
	240	32	32	32	34	33	33	34	35	36	36
	241	34	35	34	35	35	35	35	35	33	
	242	33	34	33	34	34	34	35	35	36	36
	243	38	37	38	38	38	40	40	42	42	42
	244	38	39	40	40	41	42	42	43	44	44
	245	40	42	40	42	42	44	43	42	44	43
	246	39	39	39	39	40	41	42	41	40	42
	247	41	41	42	42	43	44	44	45	45	46
	248	49	51	49	50	49	52	52	54	54	54
	249	34	35	35	34	35	36	37	36	32	26
	250	38	37	37	39	39	38	38	38	42	40

STUDIE-NR. / STUDY-NO. KWG 0519/006

TIERGEWICHTE / BODY WEIGHTS (G)

Inst. f. Toxikologie
Archiv
STICHPROBE VERTE
KONTROLLIERT
STICHPROBE 40...%

DOSE DOSIS PPM	ANIM.NO TIER-NR	W 30	W 33	W 36	W 39	W 42	W 45	W 48	W 51	W 54	W 57
MAENNLICH/MALE											
2000	301	38	39	40	41	41	40	41	41	42	42
	302	44	47	51	51	53	54	54	56	54	55
	303	35	34	34	35	35	34	35	35		
	304	32	33	33	32	33	33	34	33	32	32
	305	40	40	39	40	39	42	41	41		
	306	38	38	39	39	41	42	42	42	45	43
	307	30	30	29	31	30	30	31	31	31	31
	308	40	42	41	41	43	45	46	46	45	46
	309	41	43	43	44	43	44	44	44	44	41
	310	36	36	37	38	38	37	38	38	38	39
	311	39	40	40	41	41	41				
	312	36	36	37	37	37	37	38	37	38	37
	313	38	38	40	40	42	44	44	44	45	45
	314	33	33	34	34	34	35	35	35	35	35
	315	29	28	28	28	27	27	28	29	30	29
	316	28	28	27	29	27	28	29	28	30	29
	317	30									
	318	40	41	40	43	43	46	46	46	47	46
	319	36	36	36	38	40	39	39	39	40	40
	320	36	37	38	39	39	40	41	42	43	43
	321	35	34	33	35	35	36	36	30		
	322	40	40	39	40	41	42	42	43	46	45
	323	32	32	31	32	33	32	33	34	35	35
	324	32	32	32	32	35	35	36	34	36	36
	325	31	32	30	32	31	32	32	33	34	34
	326	40	41	40	41	42	43	43	45	46	46
	327	38	37	37	37	38	39	40	38	40	39
	328	33	33	33	33	34	35	36	34	35	34
	329	35	35	35	36	36	37	38	37	38	37
	330										
	331	33	32	32	33	35	34	35	36	37	37
	332	29	29	29	30	31	30	31	30	31	31
	333	32	30	29	31	29	31	32	31	32	31
	334	34	34	33	35	36	36	36	35	36	36
	335	35	35	34	35	36	37	38	37	37	37
	336	33	31	31	33	33	34	34	33	34	34
	337	38	39	37	38	38	40	40	39	40	38
	338	41	46	40	40	40	42	42	42	42	42
	339	28	27	27	28	28	28	29	29	29	29
	340	32	31	31	32	32	31				
	341	34	33	32	34	34	34	34	33	32	32
	342	35	35	35	37	36	36	37	37	38	37
	343	35	35	34	36	36	36	36	38	38	37
	344	42	43	42	42	43	43	42	44	44	38
	345	32	33	32	32	33	33	33	33	32	33
	346	39	38	37	39	38	39	40	40	41	41
	347	37	37	37	38	38	39	40	39	40	40
	348	35	35	37	36	36	37	37	37	36	35
	349	34	34	33	35	35	36	36	37	36	36
	350	32	32	31	31	32	33	34	34	34	33

BAYER AG

STUDIE-NR. / STUDY-NO. KWG 0519/006

TIERGEWICHTE / BODY WEIGHTS (G)

Inst. f. Toxikologie
Archiv
STICHPROBENPRÜFUNG
KONTROLLE
STICHPROBE 20...34

DOSE DOSIS PPM	ANIM.NO TIER-NR	W 60	W 63	W 66	W 69	W 72	W 75	W 78	W 81	W 84	W 87
MAENNLICH/MALE											
0	1	49	48	49	49	49	48	49	49	50	49
	2	51	53	53	53	52	49	50	50	49	48
	3	45	46	46	46	46	45	46	46	46	45
	4	40	40	41	39	41	40	40	39	40	39
	5	51	52	52	52	51	49	49	51	52	52
	6	38	38	39	38	38	37	38	37	38	37
	7	43	44	43	43	44	43	42	41	41	41
	8	47	47	47	49	48	47	48	48	48	46
	9	42	42	43	43	42	41	41	41	40	41
	10	44									
	11	41	42	42	42	42	42	42	42	42	41
	12	58	58	57	59	59	52	54	57	57	48
	13	40	39	40	41	40	39	39	42	41	42
	14										
	15	43	43	42	44	43	42	41	41	42	40
	16	52	50	51	50	51	50	52	53	53	52
	17										
	18	37	37	38	37	38	37	38	38	38	39
	19	38	38	39	39	38	39	40	39	40	39
	20	49	50	50	51	50	47	48	49	49	50
	21	38	40	40	41	39	41	41	40	41	43
	22	44	45	45	46	44	45	45	45	44	38
	23	41	41	42	40	40	38	39	39	40	37
	24	43	42	43	42	43	41	40	42	41	42
	25	45	46	46	43	38	35	33	29		
	26	39	39	40	39	40	39	38	41	41	38
	27	42	41	42	44	45	44	45	47	47	45
	28	45	46	46	47	46	46	47	46	46	
	29										
	30	41	42	42	43	43	41	42	36		
	31	53	54	53	54	54	50	51	53	54	50
	32	46	46	47	47	48	47	49	48		
	33	48	51	50	50	49	48	50	51	52	49
	34	51	53	52	55	56	55	56	57	57	54
	35	46	47	48	48	48	47	47	48	48	47
	36	42	43	43	42	43	43	42	43	42	41
	37										
	38	39	38	39	40	39	38	39	38	39	38
	39	42	43	43	42	43	43	43	41	41	39
	40	32	33	34	33	34	33	34	34	35	33
	41	32	32								
	42	46	46	47	44	41	37	38	32	32	
	43	33	33	32	33	33	34	34	33	34	43
	44	43	44								
	45	36	37	38	37	37	37	38	37	37	36
	46										
	47	41	41	42	43	44	45	46			
	48	43									
	49	57	57	58	57	51	57	56	58	57	52
	50	39	39	40	40	40					

STUDIE-NR. / STUDY-NO. KWG 0519/006

C59

Inst. f. Toxikologie
Archiv
STICHPROBENPLAN
KONTROLLIERT
STICHPROBE 10 %

TIERGEWICHTE / BODY WEIGHTS (G)

DOSE DOSIS PPM	ANIM.NO TIER-NR	W 60	W 63	W 66	W 69	W 72	W 75	W 78	W 81	W 84	W 87
MAENNLICH/MALE											
125	101										
	102	54	55	55	55	56	49	48	47	48	38
	103	46	45	46	46	45	43				
	104	50	49	49							
	105	46	48	48	46	47	45	46	44	45	43
	106	55	54	55	55	55	57				
	107	43	45	46	48	47	47	49	48	48	48
	108	44	44	45	44	42	40	41	42	43	44
	109	35	34	34	37	37	37	37	36		
	110	52	51	51	51	51	51	52	52	53	52
	111	43	45	45	43						
	112	54	54	53	52	51	47	44	42	42	
	113	52	53	53	53	53	50	47	35		
	114	41	42	42	40	37	37	33			
	115	44	45	44	45	46	44	45	45	44	43
	116	40	41	42	41	37	38	38			
	117	35	36	37	36	36	35	35	36	36	36
	118	56	57	57	58	57	56	40			
	119	41	39	40	39	39	39	40	39	40	40
	120	36	35	36	35	36	34				
	121	39	40	40	33						
	122	37	37	38	36	37	36	36	37	37	36
	123	44	46	46	46	46	46	48	48	47	47
	124	40	41	42	41	42	42	40	42	42	38
	125	34									
	126	50	53	53	53	52	52	53	57	57	54
	127	41	43	42	41	41	42	44	45	45	42
	128	44	45	45	44	44	43	43	44	43	42
	129										
	130	43	43	44	43	44	43	43	47		
	131	42	42	43	45	47	48	46	44		
	132	48	51	51	51	49	49	50	51	51	51
	133	38	39	40	40	40	39	40	40	41	39
	134	39	40	40	39	39					
	135	37	38	38	39	38	38	40	40	40	38
	136	46	46	46	45	45	45	45	46	46	45
	137	40	40	41	39	38	37	36	35	36	33
	138	49	48	48	50	49	49	49			
	139	44	45	44							
	140	36	37	38	38	38	37	38	39	40	39
	141	47	47	48	47	47	47	48	48	47	48
	142	42	42	43	43	42	42	44	44	45	45
	143										
	144	41	42	41							
	145	43	44	43	43	44	42	43	43	43	42
	146										
	147	37	36	38	36						
	148	52	52	53	52	52	54	54	54	55	52
	149	37	38	38	39	40	40	40	41	42	42
	150	51	50	51	50	51	50	50	50	51	48

Eigentum der Firma Bayer AG
Benutzung, Verwertung oder Weitergabe nur mit Einwilligung der Bayer AG gestattet

C60

STUDIE-NR. / STUDY-NO. KWG 0519/006

Inst. f. Toxikologie
Archiv
STICHPROBE WEISE
KONTROLLIERT
STICHPROBE 20 %

TIERGEWICHTE / BODY WEIGHTS (G)

DOSE DOSIS PPM	ANIM.NO TIER-NR	W 60	W 63	W 66	W 69	W 72	W 75	W 78	W 81	W 84	W 87
MAENNLICH/MALE											
500	201	47	48	48	49	48	46	45	42	43	34
	202	43	45	44	46	47	49	49	52	53	49
	203	40	43	44	44	43	44	45	46	46	43
	204	36	35	36	35	33	33	32	30		
	205	39	41	41	40	41	40	41	42	42	41
	206	37	37	38	38	39	38	38	39	40	36
	207										
	208	49	49	50	50	49	47	47	46	46	46
	209	39	40								
	210	54	55	56	55	50	36	30			
	211	38	40	41	42	39	40	41	41	40	38
	212	34	35	35	35	35	35	36	36	37	33
	213	47	47	46	48	47	47	49	51	51	
	214	39	39	40	40	40	39	38	40	41	40
	215	41	41	42	43	42	43	44	40	40	42
	216	47	45	46	39						
	217	45	46	46	48	48	47	47	47	47	47
	218	38	39	40	39	38	38	39	38	39	39
	219	47	48	48	48	48	47	49	52	51	52
	220	47	47	47	46	46	44	46	47	47	46
	221										
	222										
	223	37	38	38	37	37	37	37	37	38	37
	224	42	44	43	43	43	43	45	44	43	45
	225										
	226	48	50	50	50	48	46	47	48	49	51
	227	49	49	48							
	228	30	30	32	31	30	32	33	32	33	31
	229										
	230	38	38	37	39	38	37	37	37	36	37
	231										
	232	35	35	36	34	35	35	36	37	38	36
	233	34	35	35	35	35	35	35	35	36	35
	234	38	39	40	39	39	39	40	39	40	
	235	39	41	42	42	41	42	44	44	43	44
	236	34	36	37	36	35	35	34	35	36	34
	237	39	40	42	41	40	38				
	238	38	38	39	39	37	38	35	35	35	32
	239	44	44	43	44	45	45	45	46	45	44
	240	35	36	37	38	38	36	37	38	37	38
	241										
	242	35	37	38	37	36	37	36	37	37	36
	243	42	43	42	42	43	43	43	44	44	42
	244	44	44	45	45	45	45	46	47	48	46
	245	43	44	43	43	44	44	43	44	44	34
	246	41	42	42	42	42	41	41	41	40	41
	247	46	47	47	47	47	46	45			
	248	51	52	53							
	249										
	250	39	41	41	40						

C61

STUDIE-NR. / STUDY-NO. KmG 0519/006

TIERGEWICHTE / BODY WEIGHTS (G)

Inst. f. Toxikologie
Archiv
STICHPROBENWEISE
KONTROLLIERT
STICHPROBE 20. 9.

DOSE DOSIS PPM	ANIM.NO TIER-NR	W 60	W 63	W 66	W 69	W 72	W 75	W 78	W 81	W 84	W 87
MAENNLICH/MALE											
2000	301	41	42	43	42	42	42	43	42	42	41
	302	52	52	54	52	50	49	48	46	47	41
	303										
	304	32	31	32	30	28	29	28	28	28	25
	305										
	306	45	45	44	44	43	42	42	45	46	43
	307	30	32	31	28	26	25	23	22	22	25
	308	45	47	49	47	45	43	42	43	42	44
	309	41	41	42	41	40	39	38	37	37	32
	310	38	41	40	39	40	40	40	40	41	39
	311										
	312	37	38	37	37	37	36	37	36	36	37
	313	45	45	44	44	44	40	41	42	42	41
	314	35	34	35	36	36	36	36	34	35	
	315	31	32	32	31	32	32	31	32	32	32
	316	28	29	30	30	29	32	32	31	31	33
	317										
	318	46	46	45	47	48	47	46	47	47	47
	319	41	41	42	42	40	40	41	40	41	40
	320	42	43	43	42	41	38	36	35		
	321										
	322	45	46	47	46	46	45	45	45	45	45
	323	35	35	36	35	36	36	35	35	35	36
	324	35	37	36	37	38	36	35	33		
	325	35	34	35	34	36					
	326	46	47	49							
	327	38	39	40	39	40	39	39	40	40	40
	328	34	34	34	34	34	34	34	34	33	
	329	37	38	37	38	41	56				
	330										
	331	36	37	38	38	37	36	37	37	36	38
	332	30	31	30	30	31	31	31	33	33	32
	333	31	32	33	33	32	32	33	34	34	33
	334	36	35	37	36	37	36	36	36	35	36
	335	37	38	36	37	37	38	38	40	41	41
	336	34	35	35	34	35	35	35	34	34	34
	337	40	40	41	40	40	40	40	39	38	34
	338	42	44	44	45	44	43	43	42	43	43
	339	29	29	30	29	28	29	28	30	30	29
	340										
	341	32	31	32	33						
	342	37	37	36	37	36	36	38	38	37	37
	343	36	37	35	36	36	35	36	36	36	35
	344										
	345	33	33	34	32	33	32	31	33	33	35
	346	41	41	43	41	38	37	35			
	347	41	40	40	42	42	41	40	41	40	38
	348	32	33	32	34	33	33	32	33	34	33
	349	35	36	36							
	350	32	32	32	32	32	32	32	32		

STUDIE-NR. / STUDY-NO. KMG 0519/006

062

TIERGEWICHTE / BODY WEIGHTS (G)

Inst. f. Toxikologie
Archiv
STICHPROBENKONTROLLE
STICHPROBE 10.

DOSE DOSIS PPM	ANIM.NO TIER-NR	W 90	W 93	W 96	W 99	W 102	W 105
MAENNLICH/MALE							
0	1	48					
	2	47	47	46	43	38	
	3	45	45	43	39	37	
	4	41	40	40	40		
	5	51	50	52	51	50	48
	6	37	37	37	37	37	
	7	41	39				
	8	45	44	45	47		
	9	38	39	41	38		
	10						
	11	40	39	38	31		
	12						
	13	42	41	42	39	40	40
	14						
	15	38	36				
	16	52	51	50	49	46	45
	17						
	18	38	40				
	19	40	38	40	39	38	39
	20						
	21	44					
	22	38	38	38	38	37	37
	23	36	32	26			
	24	41	40	41	41	40	39
	25						
	26	39	38	39	37	36	39
	27	44	39	40	42	42	42
	28						
	29						
	30						
	31	52	52	53	51	49	50
	32						
	33	49	48	47	44	44	45
	34	55	50	44	40	30	
	35	48	47	49	48	48	46
	36	41	39				
	37						
	38	43					
	39	37	37	32	25		
	40	33	34	34	33	33	35
	41						
	42						
	43	33	33	35	34	33	
	44						
	45						
	46						
	47						
	48						
	49	50					
	50						

C63

STUDIE-NR. / STUDY-NO. KWG 0519/006

TIERGEWICHTE / BODY WEIGHTS (G)

Inst. f. Toxikologie
Archiv
STICHPROBENWEISE
KONTROLLIERT
STICHPROBE ... %

DOSE ANIM.NO DOSIS TIER-NR PPM		W 90	W 93	W 96	W 99	W 102	W 105
MAENNLICH/MALE							
125	101						
	102	38	40				
	103						
	104						
	105	42	42	39			
	106						
	107	48	46	42	33	30	29
	108	43	43	42	42		
	109						
	110	52	51	50	50	49	47
	111						
	112						
	113						
	114						
	115						
	116						
	117	36	34	42	34	34	33
	118						
	119	40	40	39	39	40	44
	120						
	121						
	122	35	35	36	35		
	123	47	46	47	47	46	46
	124	36	31				
	125						
	126	53	53	52	50		
	127	44	44	45	43	45	46
	128	43	42	43	41	40	39
	129						
	130						
	131						
	132						
	133	41	42	40	40	49	
	134						
	135						
	136	33	32	42	42		
	137	39	38	30	27	28	
	138						
	139						
	140	46	45	38			
	141	44	43	46	44	43	42
	142	43	42	43	39	38	39
	143						
	144						
	145						
	146						
	147						
	148	51	51	50	46	45	42
	149	43	40	42	41	41	40
	150	47	48				

BAYER AG

STUDIE-NR. / STUDY-NO. KMG 0519/006

TIERGEWICHTE / BODY WEIGHTS (G)

Inst. f. Toxikologie
Archiv
STICHPROBENPLAN
KONTR.
STICHPROBE 10 %

DOSE DOSIS PPM	ANIM.NO TIER-NR	w 90	w 93	w 96	w 99	w 102	w 105
MAENNLICH/MALE							
500	201	31	27	27			
	202	51	49	49	47	46	47
	203	40	39				
	204						
	205	42	41	42	41	41	41
	206	40	44	42	45	42	40
	207						
	208	45					
	209						
	210						
	211						
	212	34	35	33			
	213						
	214	39	38	38			
	215	41	41	40	39	40	40
	216						
	217	47	47	46	45	43	45
	218	39	38	39	37	36	32
	219	52	53	53	51	50	49
	220	45	45				
	221						
	222						
	223	36	33				
	224	43	40	29			
	225						
	226	49	50	51	49	49	47
	227						
	228	31	32	31	31	32	32
	229						
	230	37	37	37	37	37	38
	231						
	232	36	35	35	32	31	
	233	36	35	35	35	36	37
	234						
	235	43	47	48			
	236	33	34	34	32		
	237						
	238	28					
	239	44	44	43	42	43	43
	240	39					
	241						
	242	37	36	38	36	37	
	243	43	39				
	244	44	43	44	42	43	40
	245						
	246	41					
	247						
	248						
	249						
	250						

STUDIE-NR. / STUDY-NO. KHG 0519/006

C65

Inst. f. Toxikologie
Archiv
STICHPROBENGEWICHT
KONTROLLIERT
STICHPROBE 10 %

TIERGEWICHTE / BODY WEIGHTS (G)

DOSE DOSIS PPM	ANIM.NO TIER-NR	W 90	W 93	W 96	W 99	W 102	W 105
MAENNLICH/MALE							
2000	301	42	42	42	40	40	
	302	41					
	303						
	304	28					
	305						
	306	43	43	43	41	40	40
	307	26					
	308	44	44	44	43	43	44
	309						
	310	40	40	40	40	40	41
	311						
	312	37	37	36	35	36	35
	313	42	42	39	38	38	
	314						
	315	33	32	32	32	33	33
	316	33					
	317						
	318	46	46	47			
	319	40					
	320						
	321						
	322	45	45	45	44	44	44
	323	29					
	324						
	325						
	326						
	327	41	41	40	41	40	42
	328						
	329						
	330						
	331	37	38	38	37	38	37
	332	35	34	33	32	33	34
	333	33	36				
	334	37	36	36	35	36	37
	335	40	40	39	39	40	39
	336	34	34	33	33	34	37
	337	32					
	338	43	42	41	41	42	42
	339	29	29	29	28		
	340						
	341						
	342	37	38	37	35	37	36
	343	36	37	37	35	35	35
	344						
	345	36	36	35	35	35	33
	346						
	347	38	39				
	348	33	33	33	33	34	34
	349						
	350						

BAYER AG

STUDIE-NR. / STUDY-NO. KWG 0519/006

C66
Inst. f. Toxikologie
Archiv
STICHPROBENKONTROLLE
STICHPROBE 19...

TIERGEWICHTE / BODY WEIGHTS (G)

DOSE DOSIS PPM	ANIM.NO TIER-NR	W 0	W 1	W 2	W 3	W 4	W 5	W 6	W 7	W 8	W 9
WEIBLICH/FEMALE											
0	51	22	20	19	20	21	22	20	23	22	21
	52	21	22	22	23	24	24	24	26	26	28
	53	19	20	21	22	22	23	23	25	24	23
	54	21	21	22	21	22	23	27	31	29	28
	55	20	21	22	23	23	23	24	27	26	26
	56	21	22	23	23	25	24	25	30	27	27
	57	21	21	22	23	25	26	25	31	26	27
	58	20	21	21	21	23	24	24	26	24	23
	59	20	22	22	23	24	24	24	29	25	25
	60	19	21	20	20	22	24	23	30	26	25
	61	21	21	22	23	23	25	24	29	24	24
	62	21	21	21	22	23	24	24	29	22	25
	63	20	19	20	22	22	22	23	29	25	25
	64	19	17	18	20	21	22	22	28	22	24
	65	20	21	21	23	23	23	24	29	25	25
	66	18	17	17	17	18	18	18	21	18	17
	67	22	22	23	25	25	27	25	31	27	27
	68	22	20	19	21	21	21	21	27	23	24
	69	20	21	23	25	25	26	26	32	27	28
	70	18	19	20	21	22	23	22	28	23	23
	71	21	22	23	23	25	26	26	32	28	29
	72	18	20	19	20	22	22	22	28	22	24
	73	18	19	21	21	21	22	22	27	22	23
	74	18	18	18	19	20	22	22	27	22	22
	75	22	20	21	24	25	25	26	31	27	26
	76	19	19	19	20	21	23	22	28	23	23
	77	21	20	20	21	23	24	24	29	24	25
	78	22	22	23	23	25	25	24	32	26	28
	79	21	23	23	25	26	25	25	31	25	26
	80	21	19	19	20	22	22	21	29	23	25
	81	20	19	19	21	22	21	23	27	22	24
	82	22	21	21	23	24	22	24	30	25	27
	83	20	22	22	23	25	24	25	30	24	25
	84	20	19	20	20	22	20	20	25	21	22
	85	21	21	23	23	25	24	24	30	24	26
	86	21	21	22	24	26	26	28	33	27	29
	87	21	20	21	23	24	23	24	29	24	26
	88	21	21	22	23	25	24	24	31	25	27
	89	18	20	21	23	24	24	24	30	26	26
	90	18	19	21	22	24	24	26	31	25	26
	91	20	19	20	22	23	22	23	29	23	23
	92	19	20	20	22	25	24	24	29	25	29
	93	21	20	21	23	25	24	24	31	25	27
	94	21	19	21	21	23	23	23	30	24	26
	95	22	21	20	19	23	24	25	26	25	29
	96	19	20	20	20	23	23	22	23	23	25
	97	21	22	22	22	26	25	26	26	26	27
	98	20	21	21	21	25	24	23	25	25	26
	99	21	22	20	20	22	22	22	24	25	25
	100	20	21	21	22	24	24	23	22	23	24

Vertraulich

Eigentum der Firma Bayer AG
Benutzung, Verwertung oder Weitergabe nur mit Einwilligung der Bayer AG gestattet

C67

Inst. f. Toxikologie
Archiv
STICHPROBENKONTROLLE
STICHPROBE, AB ...%

STUDIE-NR. / STUDY-NO. KWG 0519/006

TIERGEWICHTE / BODY WEIGHTS (G)

DOSE PPM	ANIM.NO TIER-NR	W 0	W 1	W 2	W 3	W 4	W 5	W 6	W 7	W 8	W 9
WEIBLICH/FEMALE											
125	151	22	22	23	25	24	27	27	28	29	27
	152	22	22	24	24	24	25	25	26	25	26
	153	21	22	22	23	22	23	23	23	24	24
	154	21	23	23	24	24	24	26	28	26	26
	155	20	21	23	24	23	24	24	25	25	25
	156	19	21	21	22	22	23	24	23	23	25
	157	20	19	20	22	21	23	24	23	24	24
	158	21	23	24	24	26	27	28	26	24	27
	159	22	21	21	22	23	23	24	24	25	25
	160	22	22	25	26	28	28	28	26	28	29
	161	22	20	21	22	22	23	23	23	24	24
	162	22	23	23	24	25	24	25	27	27	28
	163	21	21	23	23	22	21	23	25	26	24
	164	22	22	22	22	20	23	24	26	24	23
	165	23	23	23	24	23	24	25	26	25	27
	166	16	21	23	23	26	27	26	27	28	28
	167	21	21	22	22	22	23	23	25	24	25
	168	20	22	23	23	24	23	24	24	25	25
	169	21	20	19	19	21	22	21	22	22	23
	170	20	20	21	21	22	23	23	23	24	24
	171	22	22	24	24	25	24	25	24	24	25
	172	18	19	20	20	20	20	22	19	23	23
	173	19	19	20	21	22	22	24	23	24	25
	174	20	20	22	21	23	22	23	25	24	24
	175	21	20	20	20	20	21	22	22	22	23
	176	21	22	22	24	26	25	25	26	27	27
	177	20	20	21	21	22	23	23	23	23	25
	178	20	21	22	22	24	24	24	25	25	27
	179	20	19	21	21	22	22	23	23	24	27
	180	19	21	22	24	26	26	27	25	26	28
	181	20	19	21	23	22	23	24	23	22	25
	182	21	21	22	22	23	24	25	24	26	27
	183	20	21	22	24	24	25	25	26	26	26
	184	22	18	20	21	20	20	21	21	22	23
	185	21	21	23	23	25	24	25	24	26	26
	186	22	22	22	22	22	23	23	23	23	24
	187	19	22	23	24	25	26	26	25	26	27
	188	19	20	20	21	22	24	23	21	22	22
	189	18	20	20	20	20	20	21	21	21	22
	190	18	18	19	20	20	21	21	20	21	23
	191	21	19	19	20	19	20	21	19	21	22
	192	19	21	19	21	23	23	23	22	24	24
	193	22	19	20	21	22	23	23	27	25	25
	194	21	21	21	21	23	23	24	23	23	27
	195	20	20	19	21	22	21	24	23	24	26
	196	20	21	20	22	23	24	24	24	26	26
	197	21	21	21	22	23	21	22	22	22	25
	198	19	22	24	26	26	27	26	25	30	30
	199	20	21	22	23	25	26	27	26	27	27
	200	22	21	21	22	24	22	23	22	23	23

C68

Inst. f. Toxikologie
Archiv
STICHPROBENVERGLEICH
KONTROLLIERT
STICHPROBE..20..%

STUDIE-NR. / STUDY-NO. KMG C519/C06

TIERGEWICHTE / BODY WEIGHTS (G)

DOSE PPM	ANIM.NO TIER-NR	W 0	W 1	W 2	W 3	W 4	W 5	W 6	W 7	W 8	W 9
WEIBLICH/FEMALE											
500	251	22	22	22	23	23	23	25	25	25	26
	252	20	20	22	22	22	23	23	25	23	25
	253	21	23	22	23	22	22	22	23	22	23
	254	20	22	23	24	24	24	24	23	24	23
	255	22	23	24	24	23	26	25	25	27	29
	256	22	23	23	24	24	24	25	26	26	26
	257	19	21	21	22	23	22	22	23	25	23
	258	20	21	22	22	22	23	22	23	25	24
	259	20	22	23	22	23	23	23	24	23	24
	260	19	19	22	23	23	23	23	24	24	26
	261	20	21	21	23	23	23	24	24	24	25
	262	20	21	22	22	22	22	22	24	23	23
	263	20	21	21	21	22	22	22	24	23	24
	264	20	22	22	22	24	22	23	24	25	26
	265	20	22	22	23	25	24	26	26	26	26
	266	22	23	23	22	23	23	22	24	23	24
	267	20	21	22	22	23	22	22	22	23	23
	268	21	22	22	22	22	22	23	23	24	24
	269	22	22	22	23	21	20	22	23	24	25
	270	21	20	20	21	22	22	23	23	24	25
	271	19	22	23	23	24	25	26	25	25	26
	272	22	23	23	24	24	25	25	24	25	26
	273	22	21	20	20	20	20	21	21	22	23
	274	21	22	21	22	23	23	24	25	24	25
	275	20	21	22	23	24	24	24	24	26	24
	276	19	21	21	23	24	25	24	24	24	24
	277	20	20	21	23	23	23	25	25	26	25
	278	21	22	22	22	24	24	23	24	22	26
	279	21	22	22	23	23	24	23	24	25	25
	280	21	22	22	24	23	23	23	24	24	25
	281	18	20	20	20	19	19	19	19	21	19
	282	19	20	20	21	23	22	22	23	23	24
	283	20	21	20	19	20	19	21	22	22	22
	284	19	21	21	21	23	24	23	24	24	25
	285	19	20	22	23	25	24	25	26	26	26
	286	21	21	22	22	24	24	23	24	25	25
	287	20	22	23	25	25	25	23	24	24	24
	288	20	22	22	22	23	22	22	23	24	24
	289	19	19	19	21	21	21	21	23	23	22
	290	19	21	21	23	23	24	23	24	25	26
	291	20	21	22	22	24	24	23	24	25	25
	292	21	20	21	22	24	23	23	25	24	25
	293	20	22	22	24	25	24	23	20	20	16
	294	21	22	23	24	24	22	22	21	22	25
	295	20	21	20	22	23	23	24	24	25	26
	296	20	20	21	23	24	24	24	24	25	25
	297	22	22	21	22	23	24	24	25	26	25
	298	20	20	19	21	22	22	21	22	23	23
	299	18	20	21	22	23	23	23	23	25	24
	300	20	20	20	22	23	24	24	25	26	27

STUDIE-NR. / STUDY-NO. KWG 0519/006

C69

TIERGEWICHTE / BODY WEIGHTS (G)

Inst. f. Toxikologie
Archiv
STICHPROBENWEISE
KONTROLLIERT
STICHPROBE 20 %

DOSE DOSIS PPM	ANIM.NO TIER-NR	W 0	W 1	W 2	W 3	W 4	W 5	W 6	W 7	W 8	W 9
WEIBLICH/FEMALE											
2000	351	21	21	21	22	22	23	23	24	25	24
	352	22	23	23	24	25	26	26	27	25	26
	353	20	21	22	23	23	24	24	24	25	25
	354	22	21	21	23	23	24	23	23	24	25
	355	19	20	19	19	20	20	20	22	22	23
	356	19	20	21	21	23	22	22	24	22	23
	357	21	21	21	21	22	23	23	23	23	24
	358	20	21	23	23	23	23	23	24	24	23
	359	20	21	19	20	21	22	21	22	22	22
	360	19	22	22	22	24	24	26	26	23	24
	361	21	22	22	22	24	24	24	24	23	24
	362	21	20	19	21	21	22	23	24	24	24
	363	19	22	23	23	24	25	26	25	25	26
	364	20	22	22	23	23	25	24	26	24	25
	365	20	20	21	22	24	25	25	25	25	24
	366	21	22	21	22	21	23	23	23	22	22
	367	20	24	23	24	24	26	27	27	26	26
	368	22	22	22	21	22	24	24	23	22	23
	369	22	21	21	23	24	24	23	23	22	26
	370	22	22	21	21	22	25	23	24	24	25
	371	19	20	22	20	23	23	23	23	24	25
	372	21	20	19	21	21	23	23	24	24	24
	373	21	21	21	21	22	24	24	23	22	23
	374	20	19	20	20	21	20	22	22	18	22
	375	20	20	20	20	19	21	22	23	22	23
	376	20	21	22	21	24	24	23	25	25	25
	377	20	20	21	21	21	21	20	21	21	20
	378	20	19	19	20	22	22	22	22	22	22
	379	19	19	19	21	21	20	18	22	22	23
	380	19	21	21	22	23	25	24	25	24	23
	381	21	22	21	22	23	24	24	24	26	26
	382	19	22	23	23	23	25	24	25	25	26
	383	22	21	21	22	22	23	23	24	24	25
	384	20	21	21	22	23	25	24	24	23	23
	385	21	19	19	20	19	20	21	21	21	21
	386	18	21	21	23	22	22	23	25	22	23
	387	20	20	21	22	22	23	24	25	23	25
	388	22	21	20	22	20	19	22	22	20	22
	389	20	20	21	21	21	23	23	23	23	22
	390	20	21	21	22	21	23	24	24	24	25
	391	21	22	21	24	22	23	24	25	25	24
	392	20	20	20	21	21	21	22	23	22	22
	393	18	19	19	20	19	21	20	21	21	20
	394	20	21	21	21	22	24	25	25	25	25
	395	21	21	20	21	19	22	23	22	24	24
	396	22	21	21	21	23	24	24	24	24	24
	397	21	20	20	21	22	23	22	24	22	22
	398	20	22	21	21	22	23	24	24	22	23
	399	20	19	20	21	19	23	24	23	22	22
	400	19	22	22	23	25	24	26	26	25	26

BAYER AG

STUDIE-NR. / STUDY-NO. KWG 0519/006

C70

Inst. f. Toxikologie
Archiv
STICHPROBENWEISE
KONTROLLIERT
STICHPROBE 10...%

TIERGEWICHTE / BODY WEIGHTS (G)

DOSE DOSIS PPM	ANIM.NO TIER-NR	W 10	W 11	W 12	W 13	W 14	W 15	W 18	W 21	W 24	W 27
WEIBLICH/FEMALE											
0	51	22	23	23	23	24	26	25	26	26	27
	52	27	27	28	28	27	28	29	29	30	31
	53	24	24	24	24	25	25	27	26	27	28
	54	29	28	30	32	30	30	31	32	32	35
	55	26	26	27	27	27	26	28	28	27	29
	56	28	28	27	29	28	28	29	30	29	31
	57	28	28	27	30	29	29	30	30	31	30
	58	23	23	23	24	24	25	27	28	29	28
	59	25	24	25	26	25	27	28	27	27	29
	60	25	25	25	26	25	26	29	27	28	29
	61	24	24	24	25	25	25	27	29	32	33
	62	26	25	26	24	24	27	28	28	30	32
	63	25	25	25	25	26	26	27	26	28	28
	64	23	22	23	22	22	23	24	23	25	25
	65	27	26	26	26	28	29	30	29	32	31
	66	18	18	17	19	18	20	19	18	21	23
	67	28	29	28	29	28	30	30	30	30	31
	68	24	24	24	25	24	26	25	27	27	29
	69	27	29	29	29	29	30	31	30	31	31
	70	23	24	23	24	24	24				
	71	30	29	29	29	29	29	31	32	32	33
	72	23	23	23	24	24	24	24	25	26	26
	73	22	24	23	23	23	24	25	25	26	26
	74	21	21	21	20	21	21	22	22	22	23
	75	27	28	27	27	27	27	29	30	30	31
	76	23	23	24	24	23	23	25	25	27	27
	77	26	26	25	26	25	27	28	28	29	29
	78	26	27	27	26	26	29	30	30	32	35
	79	25	26	26	28	27	30	30	29	28	31
	80	23	23	25	25	23	24	26	26	26	28
	81	23	22	24	23	22	24	24	22	25	25
	82	27	27	26	25	26	26	26	29	29	29
	83	26	25	25	25	26	25	27	28	29	28
	84	22	21	21	20	21	21	24	22	24	24
	85	26	26	27	26	25	27	27	28	29	29
	86	28	27	28	29	29	30	32	32	31	34
	87	24	24	25	25	25	26	27	26	27	31
	88	24	25	26	26	26	27	28	29	30	31
	89	26	27	27	26	26	28	27	30	31	31
	90	27	26	27	28	25	28	30	36	31	32
	91	23	23.	24	25	25	25	26	26	27	27
	92	28	27	27	28	28	28	31	35	33	34
	93	28	28	28	28	29	27	28	30	31	30
	94	26	26	25	27	26	26	27	27	27	29
	95	28	29	29	31	30	30	32	33	32	37
	96	25	26	25	24	26	26	26	27	26	29
	97	28	28	29	28	27	28	28	29	30	30
	98	26	26	26	26	26	26	26	26	28	28
	99	26	23	25	26	25	26	27	27	28	30
	100	25	25	24	24	22	25	26	25	26	27

STUDIE-NR. / STUDY-NO. KWG 0519/006

TIERGEWICHTE / BODY WEIGHTS (G)

Inst. f. Toxikologie
Archiv
STICHPROBENWEISE
KONTROLLIERT
STICHPROBE 10 ...%

DOSE DOSIS PPM	ANIM.NO TIER-NR	W 10	W 11	W 12	W 13	W 14	W 15	W 18	W 21	W 24	W 27
WEIBLICH/FEMALE											
125	151	27	28	29	29	30	29	30	30	31	31
	152	25	26	26	27	26	28	30	29	30	29
	153	23	23	24	24	24	24	26	25	27	28
	154	24	25	25	24	23	27	26	30	31	31
	155	24	24	25	26	25	27	29	28	29	29
	156	24	24	24	25	25	27	27	26	25	26
	157	24	24	24	24	24	25	25	25	25	24
	158	25	25	25	26	26	27	28	26	26	28
	159	24	26	27	27	26	27	28	29	29	31
	160	29	29	30	31	30	29	30	32	32	32
	161	22	23	23	26	25	25	24	24	29	27
	162	27	28	28	28	28	29	31	31	32	32
	163	24	25	25	26	26	27	28	29	29	30
	164	22	24	24	25	24	25	26	27	29	27
	165	24	25	26	27	26	28	27	28	29	29
	166	27	28	28	29	29	30	31	31	33	33
	167	27	25	25	26	26	24	26	28	29	29
	168	27	26	26	26	28	26	27	28	31	30
	169	22	22	23	25	25	25	24	25	28	27
	170	24	23	25	25	25	25	26	26	28	27
	171	26	26	26	27	27	28	30	27	28	27
	172	24	21	23	26	23	24	27	27	27	29
	173	24	24	23	25	25	25	26	26	29	26
	174	25	25	24	25	26	26	24	24	25	25
	175	23	22	23	23	22	23	24	23	24	24
	176	27	29	27	28	27	27	29	29		
	177	24	23	25	24	24	25	26	27	27	28
	178	27	26	27	28	28	28	27	29	28	28
	179	25	25	26	27	26	24	26	26	27	26
	180	29	27	27	28	31	29	29	33	34	37
	181	22	24	22	23	22	21	23	22	25	25
	182	26	26	26	27	26	26	28	28	30	30
	183	26	26	26	27	26	27	28	29	27	30
	184	21	22	21	21	23	24	25	26	27	28
	185	24	23	24	25	24	26	27	27	29	28
	186	23	23	25	26	25	26	29	29	30	29
	187	26	27	28	28	27	27	29	29	30	31
	188	21	22	22	22	23	23	24	24	24	25
	189	21	22	22	23	23	23	23	23	24	25
	190	21	22	22	22	22	23	24	25	25	27
	191	20	20	21	22	21	22	23	23	24	24
	192	23	23	23	25	24	25	27	28	29	29
	193	24	24	24	26	25	25	26	27	27	28
	194	25	26	26	27	26	27	28	27	26	30
	195	23	25	24	27	25	26	28	28	28	28
	196	25	26	26	26	26	26	28	30	30	32
	197	23	24	25	24	22	25	27	26	26	27
	198	28	27	27	27	21	31	33	33	36	35
	199	28	27	28	28	28	30	30	32	32	34
	200	23	23	23	25	24	25	26	26	27	27

BAYER AG

STUDIE-NR. / STUCY-NO. KWG 0519/006

C72

Inst. f. Toxikologie
Archiv
KONTROLLE
STICHPROBE 10...%

TIERGEWICHTE / BODY WEIGHTS (G)

DOSE PPM	ANIM.NO DOSIS TIER-NR	W 10	W 11	W 12	W 13	W 14	W 15	W 18	W 21	W 24	W 27
WEIBLICH/FEMALE											
500	251	25	26	26	26	27	27	28	29	31	33
	252	25	24	24	25	24	26	26	26	26	26
	253	23	24	24	25	21	24	26	26	24	26
	254	25	24	23	23	22	25	24	24	28	29
	255	26	28	28	28	27	29	30	31	32	31
	256	26	27	26	27	28	28	29	30	31	31
	257	22	22	23	24	23	25	25	26	22	26
	258	24	23	24	24	25	24	23	25	24	27
	259	24	24	24	25	24	25	26	26	28	31
	260	25	26	25	25	23	25	27	28	28	29
	261	24	25	24	25	23	25	25	26	27	29
	262	23	24	23	23	20	25	25	25	26	27
	263	24	24	24	25	24	25	26	26	27	26
	264	25	25	25	24	26	26	26	27	27	28
	265	26	26	27	27	27	27	28	30	30	31
	266	24	24	25	26	23	26	26	30	28	27
	267	23	23	21	24	23	24	26	27	25	27
	268	24	23	23	24	25	24	25	26	28	29
	269	24	23	24	24	24	25	25	27	27	29
	270	25	24	25	25	25	25	27	31	30	33
	271	26	26	26	26	26	27	27	28	30	32
	272	25	24	25	25	24	25	27	29	29	31
	273	23	23	22	23	24	23	25	26	25	26
	274	25	25	25	25	26	27	27	28	27	29
	275	25	26	25	27	26	26	26	26	26	29
	276	24	23	23	22	24	24	26	26	27	27
	277	26	25	25	26	26	25	27	28	29	29
	278	26	24	24	24	26	27	27	29	29	30
	279	26	25	26	26	25	27	27	26	25	27
	280	26	24	24	25	25	26	26	27	27	28
	281	19	19	20	19	19	20	22	21	22	23
	282	22	24	23	24	27	26	25	28	27	29
	283	21	21	21	22	24	23	24	24	24	25
	284	24	25	24	24	26	25	25	25	27	28
	285	25	26	26	27	26	26	29	28	29	30
	286	25	26	25	26	25	25	27	27	29	30
	287	25	23	23	24	24	26	27	26	26	28
	288	24	24	25	24	24	24	26	27	27	29
	289	22	23	23	23	24	23	25	25	25	25
	290	24	25	25	24	25	26	26	25	28	27
	291	24	25	25	25	26	25	26	26	26	27
	292	24	24	26	25	27	27	28	28	30	31
	293										
	294	24	24	25	26	27	27	28	29	29	29
	295	25	25	27	25	26	26	26	27	28	28
	296	24	24	24	25	26	26	27	26	27	27
	297	25	25	24	26	26	26	26	26	28	31
	298	23	23	23	23	24	24	24	24	25	26
	299	23	24	23	24	25	25	25	26	26	27
	300	25	26	25	25	27	26	27	27	27	28

C73

STUDIE-NR. / STUDY-NO. KHG 0519/C06

TIERGEWICHTE / BODY WEIGHTS (G)

Inst. f. Toxikologie
Archiv
STICHPROBENWEISE
KONTROLLIERT
STICHPROBE 10...%

DOSE DOSIS PPM	ANIM.NO TIER-NR	W 10	W 11	W 12	W 13	W 14	W 15	W 18	W 21	W 24	W 27
WEIBLICH/FEMALE											
2000	351	23	24	25	25	24	25	25	25	25	27
	352	26	24	25	26	28	28	28	27	29	30
	353	24	25	23	25	24	25	26	25	25	25
	354	26	25	26	26	25	26	26	27	28	28
	355	23	22	22	23	23	25	24	25	23	25
	356	23	24	22	24	25	24	24	26	25	29
	357	25	23	22	24	25	25	25	25	25	28
	358	25	25	25	25	24	25	26	29	27	28
	359	22	23	23	23	23	24	25	25	25	25
	360	25	26	26	25	26	28	28	28	28	29
	361	26	24	23	23	23	24	26	27	25	25
	362	24	24	25	26	26	27	27	29	29	30
	363	26	26	28	27	25	27	27	29	30	30
	364	26	25	26	26	26	26	28	29	29	30
	365	26	24	26	26	26	26	26	30	28	29
	366	22	24	22	24	24	26	26	26	26	28
	367	27	25	26	27	27	29	28	28	28	31
	368	24	23	24	24	24	26	27	27	26	27
	369	27	25	27	26	27	27	27	28	28	24
	370	24	24	25	26	27	26	26	27	26	27
	371	24	24	24	25	23	24	25	24	26	26
	372	24	23	24	23	23	24	23	23	24	26
	373	24	23	21	22	22	24	24	24	25	28
	374	22	22	23	22	21	22	25	27	27	29
	375	24	23	23	23	24	26	25	26	25	27
	376	26	24	26	26	27	27	31	29	30	31
	377	21	20	21	22	21	21	24	24	24	25
	378	24	23	23	23	23	24	25	24	25	25
	379	23	23	22	23	22	22	22	23	23	25
	380	25	24	25	25	25	26	26	26	27	28
	381	18	24	25	25	25	26	26	26	29	28
	382	26	25	26	26	26	27	28	27	29	30
	383	25	26	26	25	25	25	26	26	28	29
	384	24	22	23	24	26	27	27	26	27	30
	385	22	21	21	22	19	22	23	24	23	26
	386	23	21	23	24	24	24	26	26	25	29
	387	26	26	26	25	27	26	28	27	31	30
	388	22	21	22	22	22	23	26	24	27	27
	389	25	22	21	22	21	23	24	23	22	25
	390	26	24	26	25	25	25	25	26	28	27
	391	26	25	27	26	25	26	26	27	28	29
	392	22	19	21	21	22	23	23	22	22	22
	393	21	19	21	21	21	22	23	23	23	24
	394	26	26	26	25	26	26	26	27	28	29
	395	25	24	24	26	26	27	28	28	30	30
	396	24	24	25	25	25	25	26	26	26	28
	397	24	22	24	23	26	25	24	25	28	28
	398	24	23	22	23	25	26	27	26	27	29
	399	22	22	23	23	23	22	25	25	25	25
	400	25	25	22	25	28	26	27	28	29	30

BAYER AG

C74

Inst. f. Toxikologie
Archiv
STICHPROBENWEISE
KONTROLLIERT
STICHPROBE 10...%

STUDIE-NR. / STUDY-NO. KWG 0519/006

TIERGEWICHTE / BODY WEIGHTS (G)

DOSE DOSIS PPM	ANIM.NO TIER-NR	W 30	W 33	W 36	W 39	W 42	W 45	W 48	W 51	W 54	W 57
WEIBLICH/FEMALE											
0	51	28	27	26	28	29	28	29	28	27	27
	52	31	34	30	32	33	34	34	34	33	34
	53	28	29	28	30	29	31	32	31	32	34
	54	33	36	38	38	41	43	43	43	46	49
	55	30	29	30	31	32	33	33	33	33	32
	56	31	32	31	34	34	34	35	36	36	36
	57	31	33	31	33	34	34	34	35	35	34
	58	31	32	31	31	33	34	34	34	37	38
	59	29	29	28	29	31	30	31	30	31	29
	60	29	32	31	31	32	33	32	34	32	32
	61	34	34	35	36	36	38	38	40	42	42
	62	31	31	32	33	32	34	34	35	35	33
	63	28	28	29	29	29	30	31	30	31	32
	64	24	24	25	26	25	26	27	27	27	26
	65	32	32	32	34	36	37	37	37	39	41
	66	24	23	24	23	24	25	26	25	24	22
	67	33	34	35	36	36	38	38	37	38	
	68	29	28	29	33	29	29	30	29	29	28
	69	33	31	32	34	34	33	34	34	35	35
	70										
	71	35	34	34	34	36	36	36	37	35	36
	72	26	27	28	27	28	28	29	28	28	30
	73	26	26	28	28	29	31	32	31	34	32
	74	24	23	24	24	25	25	26	25	25	24
	75										
	76	27	28	29	27	27	28	29	30	32	32
	77	29	29	30	30	30	30	31	29		
	78	33	34	34	36	37	40	40	41	42	44
	79	30	31	32	31	32	34	34	35	38	37
	80	27	27	27	29	30	31	32	32	32	32
	81	25	26	25	25	26	27	28	27	26	26
	82	31	30	30	30	31	31	32	31	30	32
	83	29	30	33	31	32	32	33	33	35	34
	84	25	24	25	25	29	28	29	27	25	26
	85	29	29	30	31	30	31	32	31	34	33
	86	33	35	36	34	35	37	37	36	36	35
	87	29	28	31	30	30	31	32	31	32	32
	88	30	31	31	31	32	32	33	33	33	33
	89	32	32	32	32	32	32	31	32	34	34
	90	33	32	34	32	34	35	34	34	37	49
	91	29	29	28	30	29	31	32	30	30	31
	92	37	35	39	38	38	40	41	42	44	42
	93	30	32	34	33	35	34	34	33	35	36
	94	30	29	29	29	31	30	31	31	32	31
	95	39	38	41	41	42	43	43	43	45	43
	96	28	28	28	30	30	30	31	30	31	31
	97	31	31	31	31	33	32	33	33	32	32
	98	30	29	28	30	29	31	31	31	30	30
	99	31	30	30	31	31	32	32	33	33	34
	100	27	27	27	28	28	28	29	29	29	30

STUDIE-NR. / STUDY-NO. KWG 0519/006

Inst. f. Toxikologie
Archiv

TIERGEWICHTE / BODY WEIGHTS (G)

DOSE PPM	ANIM.NO DOSIS TIER-NR	W 30	W 33	W 36	W 39	W 42	W 45	W 48	W 51	W 54	W 57
WEIBLICH/FEMALE											
125	151	32	34	34	33	33	33	34	35	35	36
	152	32	32	32	32	34	32	33	33	35	33
	153	28	28	28	28						
	154	33	31	32	34	34	33	34	35	36	36
	155	30	29	30							
	156	27	27	28	28	28	29	30	29		
	157	26	27	27	28	28	28	29	28	28	30
	158	28	29	25	29	29	30	30	31	31	30
	159	30	30	32	31	30	32	32	33	34	33
	160	32	33	34	35	34	34	34	35	36	36
	161	25	28	30	29	30	30	31	29	30	29
	162	33	35	34	36	35	36	36	35	36	36
	163	32	32	31	32	32	31	32	32	34	34
	164	29	29	28	30	31	30	31	29	30	30
	165	30	31	30	33	33	32	32			
	166	34	35	35	36	36	36	37	36	38	38
	167	28	30	30	30	30	30	31	30	31	32
	168	30	31	33	31	32	34	33	35	35	35
	169	28	30								
	170	29	30	31	30	30	33	32	33	34	35
	171	31	31	30	32	33	33	34	33	33	33
	172	27	28	27	28	29	28	29	28	29	30
	173	28	29	24	28	30	29	30	39	29	30
	174	25	25	26	26	28	28	29	28	28	
	175	25	27	27	27	27	28	28	29	30	30
	176										
	177	28	29	30	30	30	33	33	35	37	37
	178	30	31	31	31	30	31	32	31	31	32
	179	27	28	28	28	29	29	30	30	29	29
	180	37	35	36	38	35	38	37	41	41	43
	181	27	27	26	27	29	27	28	27	29	29
	182	32	32	33	34	35	34				
	183	30	31	31	31	32	31	32	32	34	33
	184	28	29	29	29	30	30	31	32	31	31
	185	30	32	31	33	34	34	34	34	34	36
	186	30	30	31	32	32	32	33	33	33	34
	187	31	33	33	31	33	33	33	35	36	38
	188	24	26	25	25	25	25	26	27	27	26
	189	25	25	25	26	27	27	28	27	28	26
	190	27	27	29	28	29	30	31	32	31	31
	191	23	24	24	24	24	24	25	26	25	25
	192	30	31	24	31	33	30	31	31	33	33
	193	29	28	28	30	29	29	30	30	30	30
	194	30	31	31	30	31	31	31	32	31	32
	195	31	28	24	29	30	30	30	29	28	30
	196	31	34	33	34	35	36	35	37	38	37
	197	28	27	27	28	28	29	30	28	29	30
	198	38	36	37	37	38	38	38	39	39	39
	199	34	35	34	35	36	35	36	37	35	35
	200	28									

BAYER AG BAYER AG

STUDIE-NR. / STUDY-NO. KWG 0519/006

C76
Inst. f. Toxikologie
Archiv
STUDIENPROTOKOLL
KONTROLLIERT
STICHPROBE 20...%

TIERGEWICHTE / BODY WEIGHTS (G)

DOSE DOSIS PPM	ANIM.NO TIER-NR	W 30	W 33	W 36	W 39	W 42	W 45	W 48	W 51	W 54	W 57
WEIBLICH/FEMALE											
500	251	31	31	31	34	33	35	35	34	35	35
	252	28	27	27	29	28	28	29	28	30	28
	253	27	30	28	28	29	29	30	31	33	34
	254	30	31	32	31	33	33	34	36	36	36
	255	32	31	32	32	34	33	33	35	33	36
	256	33	33	34	31	34	34	34	33	35	36
	257	25	23	23	27	25	24	25	25	27	28
	258	27	26	27	27	28	27	28	29	28	31
	259	32	32	34	34	34	35	34	37	37	37
	260	30	30	31	31	32	32	33	35	33	35
	261	28	29	30	29	30	30	31	30	31	31
	262	28	28	29	28	30	30	30	31	31	35
	263	27	28	27	28	30	28	29	28	28	28
	264	28	28	30	28	30	30	31	31	31	31
	265	31	32	32	31	33	33	33	35	35	35
	266	30	28	29	29	30	30	31	31	31	35
	267	28	28	29	30	29	29	30	30	30	30
	268	27	27	28	31	29	28	29	28	29	31
	269	29	29	29	31	30	30	30	30	31	31
	270	34	36	37	36	38	39	38	39	39	40
	271	31	33	33	35	36	37	37	36	38	36
	272	30	32	33	31	32	33	34	33	35	35
	273	27	27	26	27	28	27	28	28	30	28
	274	28	29	29	26						
	275	29	30	30	32	31	31	32	32	33	33
	276	27	27	27	27	28	28	29	28	28	29
	277	29	30	31	30	30	31	32	31	31	31
	278	29	30	28	28	30	32	32	32	31	31
	279	28	27	27	27	29	29	30	29	28	29
	280	29	30	26	28	28	28	29	29	28	27
	281	22	24	22	23	23	24	24	24	23	24
	282	29	30	29	29	30	31	31	31	28	30
	283	23	24	24	25	26	25	26	26	25	27
	284	28	28	29	29	31	29	30	30	31	32
	285	29	31	30	31	30	31	31	30	31	
	286	32	30	31	33	32	31	32	31	32	31
	287	29	28	28	28	30	31	31	30	32	31
	288	30	30	30	30	31	32	33	33	31	34
	289	26	27	26	26	27	27	28	29	28	28
	290	30	30	30	29	31	30	31	31	30	31
	291	28	28	28	27	28	28	29	29	29	30
	292	30	30	31	31	31	31	30	29	31	29
	293										
	294	31	30	30	30	30	31	32	31	31	31
	295	27	28	28	27	28	29	29	29	29	30
	296	28	28	28	29	28	29	30	30	32	30
	297	29	30	31	30	31	31	32	32	32	34
	298	25	25	26	26	27	27	28	28	28	28
	299	27	30	29	30	30	32	32	34	36	35
	300	28	28	28	30	30	32	32	33	31	33

STUDIE-NR. / STUDY-NO. KWG 0519/006

TIERGEWICHTE / BODY WEIGHTS (G)

Inst. f. Toxikologie
Archiv
STICHPROBENWEISE
KONTROLLIERT
STICHPROBE 10 %

DOSE ANIM.NO DOSIS TIER-NR PPM		W 30	W 33	W 36	W 39	W 42	W 45	W 48	W 51	W 54	W 57
WEIBLICH/FEMALE											
2000	351	28	27	27	27	29	28	29	27	28	30
	352	30	30	30	25						
	353	27	26	25	26	28	25	27	29	28	27
	354	28	29	28	27	26	29	30	30	28	29
	355	25	24	25	25	27	25	26	26	27	27
	356	28	29	28	27	27	27	28	28	29	30
	357	27	27	28	28	31	28	28	29	29	30
	358	29	29	29	29	30	30	30	29	30	31
	359	25	25	25	26	26	26	27	26	26	26
	360	28	29	29	29	30	30	31	30	30	30
	361	27	26	25	28	26	24	24	26	27	26
	362	29	29	31	31	32	33	33	33	35	35
	363	31	31	31	32	33	34	34	33	35	35
	364	31	30	30	30	31	31	32	31	32	32
	365	30	29	29	31	31	31	32	31	31	31
	366	29	28	27	32	29	29	30	29	30	31
	367	31	31	29	30	32	30	30	32	33	34
	368	28	30	29	30	31	31	31	32	34	35
	369	29	30	30	30	30	31	30	31	32	34
	370	27	28	28	27	27	29	30	29	29	30
	371	27	27	27	27	28	27	28	28		
	372	25	26	23	26	26	24	25	25	26	27
	373	27	26	27	27	26	25	26	26	27	25
	374	28	29	28	30	31	31	31	30	31	29
	375	25	26	26	26	26	27	27	27	28	29
	376	32	32	32	33	34	35	35	36	35	36
	377	25	25	25	27	27	26	27	27	27	28
	378	25	26	26	27	27	27	28	27	26	27
	379	23	23	23	26	25	25	25	26	26	26
	380	28	29	29	28	30	29	30	29	30	31
	381	29	30	31	31	31	32	32	32	33	34
	382	29	31	32	31	33	35	34	37	39	41
	383	27	29	28	28	30	29	30	30	30	31
	384	29	28	29	32	31	29	30	29	30	31
	385	25	28	24	24	26	25	26	26	24	25
	386	28	25	26	26	26	27	27	28	26	27
	387	30	31	31	31	32	33	33	34	36	36
	388	25	27	26	26	27	28	28	28	27	27
	389	25	26	25	26	26	27	28	26	26	27
	390	27	29	27	27	29	27	28	27	28	29
	391	28	29	29	28	30	29	30	30	28	29
	392	23	23	23	24	24	24	25	25	24	
	393	24	23	24	24	26	25	26	24		
	394	28	29	30	29	30	29	30	29	28	29
	395	30	31	32	30	32	33	33	33	32	35
	396	28	29	30	28	29	30	30	30	29	31
	397	28	29	28	29	29	31	30			
	398	29	28	27	27	28	29	29	30	31	30
	399	28	27	26	27	27	28	28	27	26	29
	400	31	30	31	31	33	33	32	34	31	34

BAYER AG BAYER AG BAYER AG

Eigentum der Firma Bayer AG
Benutzung, Verwertung oder Weitergabe nur mit Einwilligung der Bayer AG gestattet

C78

STUDIE-NR. / STUDY-NO. KHG 0519/006

Inst. f. Toxikologie
Archiv
STICHPROBENWEISE
KONTROLLIERT
STICHPROBE 20 %

TIERGEWICHTE / BODY WEIGHTS (G)

DOSE DOSIS PPM	ANIM.NO TIER-NR	W 60	W 63	W 66	W 69	W 72	W 75	W 78	W 81	W 84	W 87
WEIBLICH/FEMALE											
0	51	23	28	28	28	31	29	28	29	29	28
	52	33	34	34	34	35	34	35	35	34	34
	53	35	34	35							
	54	46	47	46	45	47					
	55	31	33	33	32	32	31	30	31	32	32
	56	36	39	38	41	42	43				
	57	36	36	36	36	36	36	37	38	37	37
	58	39	38	39	37	37	37	35	37	37	
	59	31	31	32	31	32	31	30	31	32	
	60	32	33	33	32	33	33	33	34	34	33
	61	41	38	39	29						
	62	34	35	35	37	40	41	38			
	63	32	32	33	32	31	30	31	32	32	31
	64	27	26	27	27	27	28	27	27	27	28
	65	39	41	41	41	42	42	43			
	66	23	24	25	24	25	26	27	26	27	27
	67										
	68	29	29	30	31	32	26				
	69	33	34	34	33	34	34	32	34	34	
	70										
	71	36	36	36	37	38	37	37	37	37	39
	72	30	29	30	30	31	30	30	30	31	30
	73	32	32	32	32	33	32	33	34	33	32
	74	26	26	27	25	25	25	25	26	27	26
	75										
	76	34	36	36	35	35	36	36	39	39	39
	77										
	78	43	44	44	46	45	44	45	45	45	46
	79	38	39	40	39	38	38	37	38	38	35
	80	32	33	33	33	36	35	36	35	36	34
	81	25	27	27	27	27	27	27	27	27	27
	82	30	33	32	33	32	32	31	31	32	32
	83	33	33	33	31	33	32	31	33	33	34
	84	30	29	30	28	27	29	27	27	27	27
	85	34	33	34	32	32	31	29	29	30	26
	86	37	37	36	38	36	35	31	30	31	29
	87	32	32	33	31	32	31	30			
	88	33	33								
	89	34	33	34	34	34	33	35	35	34	34
	90	30									
	91	31	32	32	32	32	33	33	35	35	35
	92	42	42	42	43	43	41	42	42	41	33
	93	36	35	36	34	35	34	34	35	34	32
	94	30	31	32	30	31	32	32	32	32	35
	95	45	47	47	45	43	40	38	39	40	39
	96	30	31	32	31	30	30	30	31	32	31
	97	33	32	32	32	33	33	32	33	33	33
	98	28	29	30	31	33	30				
	99	33	32	32	32						
	100	30	29	30	29	29	30	30	29	30	29

STUDIE-NR. / STUDY-NO. KHG 0519/006

TIERGEWICHTE / BODY WEIGHTS (G)

Inst. f. Toxikologie
Archiv
STICHPROBE
KONTROLLE
STICHPROBE 10

DOSE PPM	ANIM.NO TIER-NR	W 60	W 63	W 66	W 69	W 72	W 75	W 78	W 81	W 84	W 87
WEIBLICH/FEMALE											
125	151	40	39	40	40	41	40	41	43	42	40
	152	38									
	153										
	154	35									
	155										
	156										
	157	27	27	28	28	30	29	29	29	30	28
	158	31	30	31	30	31	30	30	30	31	31
	159	30									
	160	36	38								
	161	31	31	33	31	31	31	31	31	31	31
	162	37	37	38	37	38	39	37	39	38	39
	163	34	33	33	33	36	34	33	34	34	32
	164	30	29	31	30	31	31	30	30	31	30
	165										
	166	37	38	39	37	39	39	38	40	40	40
	167	31	30	31	31	32	32	32	32	32	32
	168	34	35	34	36	36	35	35	35	34	35
	169										
	170	35	36	35	34	35	36	37	38	37	40
	171	32	33	34	33	33	33	32	33	33	35
	172	29	29	30	29	29	29	29	29	30	29
	173	29	29	28	29	31	30	31	38		
	174										
	175	31	28	28	29	29	31	30	28		
	176										
	177	36	38	37	40	40	39	38	41	41	39
	178	33	32	32	32	33	34	35	36	36	36
	179	30	32	32	31	32	31	32	33	32	32
	180	44	43	44	43	44	43	40	42	41	39
	181	28	28	29	30	29	29	28	29	30	30
	182										
	183	34	35								
	184	31	31	32	31	31	31	31	32	32	31
	185	38	37	37	38	39	40	38	40	39	40
	186	34	34	33	34	33	33	32	33	33	34
	187										
	188	29	29	30	29	29	29	29	30	31	30
	189	27	27	28	29	30	30	32	33	33	
	190	30	32	31	31	31	30	32	31	31	31
	191	26	26	27	27	27	27	26	28	28	28
	192	33	35	35	38	37	38	38	37	37	36
	193	31	29	30	32	31	27	28			
	194	32	33	33	32	31	32	31	32	33	32
	195	29	30	31	29	29	29	29	29	30	29
	196	37	37	36	38	37	34	34	34	33	34
	197	29	29	30	29	29	31	29	29	30	30
	198	37	38	38	38	38	39	40	41	40	39
	199	27									
	200										

BAYER AG BAYER AG BAYER AG

STUDIE-NR. / STUDY-NO. KHG 0519/006

Inst. f. Toxikologie
Archiv
STICHPROBENWEISE
KONTROLLIERT
STICHPROBE 10...%

TIERGEWICHTE / BODY WEIGHTS (G)

DOSE ANIM.NO DOSIS TIER-NR PPM		W 60	W 63	W 66	W 69	W 72	W 75	W 78	W 81	W 84	W 87
WEIBLICH/FEMALE											
500	251	36	36	37	35	38	38				
	252	27	27	28	27	25	25	25	24	24	25
	253	34	34	33	31	34	31	31	32	32	30
	254	45	38	39	38	39	38	37	38	37	37
	255	36	37	38	36	36	35	36	37		
	256	35	37	37							
	257	28	27	28	27	30	30	29	31	31	30
	258	31	28	30	28	27	28	28	27	28	27
	259	37	37	36	38	37	37	40			
	260	34	35	34	33	33	34	33	34	33	32
	261	32	31	32	33	31	32	32	31	31	32
	262	34	35	36	36						
	263	28	28	30	29	29	29	29	29	29	29
	264	31	31	31	32	31	32	31	33	32	32
	265	36	35	34	37	38	39	35	36	36	53
	266	35	34	34	34	33	34	33	34	34	33
	267	30	31	32	30	30	31	30	32	32	31
	268	29	32	31	31	30	32	31	31	32	31
	269	31	32	32	32	31	31	30	31		
	270	40	38	39	38	38	35	35	38	37	39
	271	38	39	40	38	40	38	38	41	41	40
	272	33	34	34	34	37	34	35	37	38	35
	273	28	28	29	29	29	29	29	31	30	30
	274										
	275	32	34	33	33	33	32	32	34	33	33
	276	30	30	31	30	28	28	27	28	28	27
	277	32	33	32	34	35	34	33	35	34	35
	278	29	30	31	34	36	37	34			
	279	27	29	30	29	30	30	30	30	30	29
	280	27	28	28	28						
	281	23	26	26	25	25	25	25	25	25	26
	282	29	28	29							
	283	26	28	28							
	284	31	31	32	32	33	33	33	33	32	34
	285										
	286	32	33	33	32	34	35	34	35	35	34
	287	31									
	288	34	33	34	33	34	34	33	34	34	31
	289	28	28	29	28	29	29	28	29	29	29
	290	30	31	30	29	31	32	30	30	31	32
	291	29	30	31	29	31	31	31	32	32	31
	292	30	31	32	33	32	32	28	27	27	
	293										
	294	31	30	32	32	32	31	26			
	295	30	31	31	31	31	31	29	31	30	32
	296	30	31	31	30	31	31	31	31	31	30
	297	33	33	32	35	35	35				
	298	29	29	30	29	29	30	30	30		
	299	34	36	35	37	37	36	36	37	37	37
	300	34	34	35	34	36	37	37	36	36	36

Vertraulich

Eigentum der Firma Bayer AG
Benutzung, Verwertung oder Weitergabe nur mit Einwilligung der Bayer AG gestattet

Inst. f. Toxikologie
Archiv
STICHPROBE
KONTROLLE
STICHPROBE 20...

STUDIE-NR. / STUDY-NO. KWG 0519/006 C81

TIERGEWICHTE / BODY WEIGHTS (G)

DOSE PPM	ANIM.NO DOSIS TIER-NR	W 60	W 63	W 66	W 69	W 72	W 75	W 78	W 81	W 84	W 8
WEIBLICH/FEMALE											
2000	351	30	28	29	27	30	32	30	29	30	30
	352										
	353	27	28	29	29	31					
	354	29	30	31	30	28	28	27	28	28	30
	355	27	27	28							
	356	29	28	29	28	29	30	30	24	24	25
	357	29	30	30	30	31	30	30	30	30	30
	358	30	30	31	31	31	32	31	31	31	30
	359	26	25	26	26	27	26	26	26	26	26
	360	30	30	31	31	29	30	29	29	28	30
	361	27	26	27	27						
	362	35	37	36	36	35	36	34	36	35	36
	363	35	35	36	35	34	31				
	364	32	33	33	31						
	365	31	32	32	32	33	33	32	31	31	32
	366	30	29	29	30	30	31	31	31	30	31
	367	33	34	34	33	34	34	34	35	34	34
	368	33	35	36	35	35	35	37	37	36	36
	369	34	32	33	33						
	370	29	31	30	32	30	31				
	371										
	372	27	28	28	27	26	27	27			
	373	27	26	27	27	26	26	26	26	26	28
	374	30	29	30	29	30	30	28	28	27	
	375	28	29	28	30	30	30	29	29	29	29
	376	38	37	37	40						
	377	27	28	28	30	29	29	29	29	29	28
	378	28	27	28	28	28	28	29	28	28	27
	379	26	28	28	27	28	27	28	27	28	28
	380	30	30	31	31	30	30	31	31	31	30
	381	31	34	34	33	35	33	34	35	34	36
	382	41	42	43	41	42	41	41	41	40	
	383	30	30	31	32	32	32	31	31	32	30
	384	29	30	29	31	31	32	31	30	30	31
	385	25	26	26	25	26	26	27	27	28	30
	386	26	27	27	29	28	27	27	26	25	26
	387	36	37	37	36	35	36	39	41	41	46
	388	28	28	29	29	29	28	27	28	28	28
	389	27	28	28	28	29	28	28	28	27	29
	390	29	29	30	30	31	34	36			
	391	30	30	31	31	30	30	30	31	31	30
	392										
	393										
	394	29	29	30	32	31	32	31	32	32	34
	395	36	33	34	35	34	36	34	33	33	38
	396	31	30	31	31	33	32	30	31	30	32
	397										
	398	30	31	30	33	33	32	32	33	32	32
	399	28	28	27	29	29	28	28	29	30	28
	400	34	33	33	35	35	36	34	35	35	37

BAYER AG LEVERKUSEN

STUDIE-NR. / STUDY-NO. KMG 0519/006

C82

Inst. f. Toxikologie
Archiv
STICHPROBENWEISE
KONTROLLIERT
STICHPROBE 10 %

TIERGEWICHTE / BODY WEIGHTS (G)

DOSE DOSIS PPM	ANIM.NO TIER-NR	W 90	W 93	W 96	W 99	W 102	W 105
WEIBLICH/FEMALE							
0	51	29	30	28	29	29	28
	52	33	35	33	33	32	32
	53						
	54						
	55	32	32	32	31	31	29
	56						
	57	37	36	35	34	33	33
	58						
	59						
	60	34	35	36			
	61						
	62						
	63	31	30	31	29		
	64	31	28	31			
	65						
	66	27	27	28	25	28	26
	67						
	68						
	69						
	70						
	71	39	52				
	72	32	32	35	41		
	73	32	32	32			
	74	27	25	26	25	26	25
	75						
	76	40	42	42	42	42	39
	77						
	78	45	48	49	48	48	46
	79	36	35	43			
	80	35	35	36	33		
	81	28	27	27	26	27	25
	82	32	31	33	32	31	30
	83	35	35	34	32	32	32
	84	28	29	30	31	32	34
	85	28	28				
	86	29	27				
	87						
	88						
	89	33	35	33	34	34	33
	90						
	91						
	92	32	33	34	32	32	31
	93	31	30	32	30		
	94	37					
	95	39	30				
	96	32	30	31	30	32	30
	97	34	38				
	98						
	99						
	100	29	29	29	28	28	29

STUDIE-NR. / STUDY-NO. KHG 0519/006

C83

TIERGEWICHTE / BODY WEIGHTS (G)

Inst. f. Toxikologie
Archiv
STICHPROBENWEISE
KONTROLLIERT
STICHPROBE 10 %

DOSE PPM	ANIM.NO DOSIS TIER-NR	h 90	h 93	h 96	h 99	h 102	h 105
WEIBLICH/FEMALE							
125	151	34	27	25			
	152						
	153						
	154						
	155						
	156						
	157	27	26	26	24	23	
	158	30	31	33	34	32	31
	159						
	160						
	161	31	30	31	30	30	28
	162	39	39	44			
	163	33	33	33	33	33	31
	164	31	30	30	29	30	28
	165						
	166						
	167	31	32	32	29		
	168	35	33	32	31	32	31
	169						
	170	38	40	37	39	36	35
	171	34	35	34	34	35	35
	172	29					
	173						
	174						
	175						
	176						
	177	38	38	35	31	29	24
	178	36	36	35	35	37	35
	179	33	33	32	31	32	32
	180	39	33				
	181	29	30	29	28	28	
	182						
	183						
	184	31	31	30	29		
	185	38	35	33			
	186	32	34	34	33	35	35
	187						
	188	30	29	29	30	30	30
	189						
	190	31	30	28	25		
	191	26					
	192	34	37	34	34	35	
	193						
	194	32	32	32	32	32	32
	195	29					
	196	35	34	34	33	34	34
	197	29	28	28	28	28	27
	198	41	38	40	39	37	37
	199						
	200						

BAYER AG

C84

STUDIE-NR. / STUDY-NO. KWG 0519/C06

TIERGEWICHTE / BODY WEIGHTS (G)

Inst. f. Toxikologie
Archiv
STICHPROBENWEISE
KONTROLLIERT
STICHPROBE 10 %

DOSE DOSIS PPM	ANIM.NO TIER-NR	W 90	W 93	W 96	W 99	W 102	W 105
WEIBLICH/FEMALE							
500	251						
	252						
	253	31	31	31	30	32	31
	254	35	34				
	255						
	256						
	257						
	258	28	28	28	28	28	28
	259						
	260	33	33	35	33	33	
	261	36					
	262						
	263	30	29	29	29	30	29
	264	33					
	265						
	266	34	33	34	33	34	31
	267	31	30	30	29	31	30
	268	31	31	33	32	32	32
	269						
	270	40	40	40	40	40	38
	271	42	42	43	42	42	40
	272	36	35	35	36	36	36
	273	30	31	31	30	31	31
	274						
	275	33	33				
	276	27	29	28	28	30	28
	277	33	34	33	33	34	
	278						
	279	29	32	31	27	28	28
	280						
	281	26	26	25	26	25	25
	282						
	283						
	284	33	33	34	33	30	
	285						
	286	35	36	35			
	287						
	288	31	31	33	33		
	289	30	30	28			
	290						
	291	31	30	32	33	34	34
	292						
	293						
	294						
	295	31	32	31	31	32	31
	296	31	31	31	31	31	30
	297						
	298						
	299	36	35	36	36	36	35
	300	36	34	33	25		

STUDIE-NR. / STUDY-NO. KWG 0519/006

085

TIERGEWICHTE / BODY WEIGHTS (G)

Inst. f. Toxikologie
Archiv
STICHPROBENWEISE
KONTROLLIERT
STICHPROBE 10 %

DOSE DOSIS PPM	ANIM.NO TIER-NR	W 90	W 93	W 96	W 99	W 102	W 105
WEIBLICH/FEMALE							
2000	351	31	30	29	29	30	29
	352						
	353						
	354	28	28	29	29	30	28
	355						
	356						
	357	31	30	28	27	28	27
	358	26	28				
	359	29	30	27	26	27	26
	360	33	31	30	30	31	31
	361						
	362	33	33	29	30	32	
	363						
	364						
	365	31	34	34	33	35	
	366	34	31	31	33		
	367	35	36	37	38	37	36
	368	26	38	36	36	36	35
	369						
	370						
	371						
	372						
	373	30	27	26	26		
	374						
	375	29	31	32	34	35	34
	376						
	377	28	30	29	27	28	29
	378	28	28	28	27	29	28
	379	31	28	28	27	28	30
	380	36	32	32	32	32	
	381	31	35	37	44		
	382						
	383	32	31	30	30	31	31
	384	32	32	31	30	30	31
	385						
	386	27					
	387	41					
	388	28	28	28	24	26	27
	389	29	30	29	28	29	29
	390						
	391	31	31	31	30	30	30
	392						
	393						
	394	35	32	37			
	395						
	396	32	30				
	397						
	398	33	32	32	32	32	32
	399	29	28	28	28	29	28
	400	35	33	36	36	35	36

BAYER AG

STUDIE-NR. / STUDY-NO. KWG 0519/006

BLUT-UNTERSUCHUNG / HAEMATOLOGY
12 MONATE / 12 MONTHS

DOSE PPM	ANIM.NO TIER-NR	ERY TERA/L	RETI 0/00	LEU GIGA/L	THROM GIGA/L	HGB G/L	HCT L/L	MCH PG/E	MCHC G/L	MCV FL
MAENNLICH/MALE										
0	1	8.99	28	6.5	1341	156	0.48	17.4	325	53
	2	8.72	33	4.9	1109	141	0.43	16.2	328	49
	3	8.35	31	6.8	1222	140	0.44	16.8	318	53
	4	8.59	25	12.0	1045	140	0.44	16.3	318	51
	5	8.61	35	5.6	1150	150	0.46	17.4	326	53
	6	8.41	25	7.5	1263	139	0.43	16.5	323	51
	7	8.42	31	5.8	1361	144	0.44	17.1	327	52
	8	8.85	31	5.2	952	155	0.48	17.5	323	54
	9	8.72	26	11.3	1348	148	0.47	17.0	315	54
	10	8.51	28	5.1	1150	143	0.44	16.8	325	52
125	102	8.65	29	6.6	1088	154	0.47	17.8	328	54
	103	8.51	33	7.4	1056	151	0.47	17.7	321	55
	104	8.13	30	4.6	1133	144	0.45	17.7	320	55
	105	9.11	26	6.5	1204	148	0.46	16.2	322	50
	106	7.07	34	6.1	653	124	0.39	17.5	318	55
	107	8.39	25	4.4	889	144	0.46	17.2	313	55
	108	8.22	26	5.0	1257	144	0.45	17.5	320	55
	109	7.87	31	6.1	1372	132	0.42	16.8	314	53
	110	8.33	26	6.1	969	145	0.45	17.4	322	54
	111	9.24	32	5.8	821	169	0.49	18.3	345	53
500	201	8.21	29	6.2	1204	137	0.44	16.7	311	54
	202	8.53	35	5.5	958	150	0.46	17.6	326	54
	203	8.95	26	3.3	1180	158	0.50	17.7	316	56
	204	8.26	27	3.7	952	144	0.45	17.4	320	54
	205	8.09	25	3.4	1239	136	0.43	16.8	316	53
	206	8.31	31	4.4	1150	147	0.48	17.7	306	58
	207	9.02	25	4.3	1222	158	0.48	17.5	329	53
	208	8.55	34	4.7	1198	149	0.47	17.4	317	55
	209	8.29	29	3.2	1156	142	0.44	17.1	323	53
	210	7.77	31	7.4	912	144	0.45	18.5	320	58

Geprüft
Inst. f. Toxikologie
Archiv

STUDIE-NR. / STUDY NO. KWG 0519/006

BLUT-UNTERSUCHUNG / HAEMATOLOGY
12 MONATE / 12 MONTHS

DOSE DOSIS PPM	ANIM.NO TIER-NR	ERY TERA/L	HCT 0/00	LEU GIGA/L	THROM GIGA/L	HGB G/L	HCT L/L	MCH PG/E	MCHC G/L	MCV FL
MAENNLICH/MALE										
2000	301	8.16	29	3.2	1103	138	0.43	16.9	321	53
	302	7.98	32	6.3	1414	148	0.46	18.5	322	58
	303	8.33	29	6.5	1668	144	0.46	17.3	313	55
	304	8.29	31	7.2	1384	145	0.43	17.5	337	52
	305	8.30	32	4.6	1216	146	0.44	17.6	332	53
	306	9.13	36	5.7	1162	165	0.48	18.1	344	53
	307	8.06	27	4.1	958	144	0.45	17.9	320	56
	308	8.30	26	3.4	1222	148	0.46	17.8	322	55
	309	8.42	30	3.6	1027	154	0.47	18.3	328	56
	310	8.23	27	4.3	1228	155	0.48	18.8	323	58

BAYER AG

geprüft
Inst. f. Toxikologie
Archiv

BAYER AG

STUDIE-NR. / STUDY-NO. KWG 0519/006

BLUT-UNTERSUCHUNG / HAEMATOLOGY
12 MONATE / 12 MONTHS

DOSE DOSIS PPM	ANIM.NO TIER-NR	ERY TERA/L	RETI 0/00	LEU GIGA/L	THROM GIGA/L	HGB G/L	HCT L/L	MCH PG/E	MCHC G/L	MCV FL
WEIBLICH/FEMALE										
0	51	8.46	31	4.4	878	155	0.44	18.3	352	52
	52	8.78	43	2.4	958	160	0.47	18.2	340	54
	53	9.18	30	5.0	975	160	0.46	17.4	348	50
	54	8.50	36	6.3	1139	144	0.46	16.9	313	54
	55	8.71	29	4.9	821	155	0.46	17.8	337	53
	56	8.57	39	2.7	826	150	0.45	17.5	333	53
	57	8.68	34	5.8	787	169	0.46	19.5	367	53
	58	8.04	35	6.0	844	143	0.44	17.8	325	55
	59	8.99	40	5.5	998	157	0.43	17.5	365	48
	60	8.74	33	5.6	941	154	0.46	17.6	335	53
125	151	8.02	31	3.2	838	150	0.45	18.7	333	56
	152	8.09	52	4.9	987	149	0.41	18.4	363	51
	154	7.19	29	3.8	742	128	0.42	17.8	305	58
	156	8.64	31	3.1	1051	153	0.46	17.7	333	53
	157	8.71	34	3.2	844	156	0.47	17.9	332	54
	158	8.03	26	2.8	793	135	0.42	16.8	321	52
	159	8.23	37	5.1	692	149	0.44	18.1	339	53
	160	8.25	42	4.6	872	142	0.44	17.2	323	53
	161	8.56	39	5.2	872	150	0.43	17.5	349	50
	162	8.51	33	4.9	963	158	0.46	18.6	343	54
500	251	8.14	39	2.9	1022	144	0.44	17.7	327	54
	252	8.51	30	4.2	798	162	0.48	19.0	338	56
	253	8.71	42	5.3	929	162	0.47	18.6	345	54
	254	8.32	36	3.7	993	150	0.45	18.0	333	54
	255	8.11	37	4.1	787	141	0.41	17.4	344	51
	256	8.10	38	2.8	935	145	0.42	17.9	345	52
	257	8.20	31	3.0	975	150	0.44	18.3	341	54
	258	8.38	33	1.9	1263	159	0.46	19.0	346	55
	259	8.50	26	1.6	923	152	0.46	17.9	330	54
	260	8.43	31	4.8	1080	155	0.46	18.4	337	55

geprüft
Inst. f. Toxikologie
Archiv

STUDIE-NR. / STUDY-NO. KWG 0519/006

BLUT-UNTERSUCHUNG / HAEMATOLOGY
12 MONATE / 12 MONTHS

DOSE DOSIS PPM	ANIM.NO TIER-NR	ERY TERA/L	RETI 0/00	LEU GIGA/L	THROM GIGA/L	HGB G/L	HCT L/L	MCH PG/E	MCHC G/L	MCV FL
WEIBLICH/FEMALE										
2000	351	7.68	35	2.4	975	148	0.44	19.3	336	57
	353	7.98	36	4.3	889	156	0.46	19.5	339	58
	354	8.89	30	3.7	949	161	0.48	18.1	335	54
	355	7.49	34	2.8	949	139	0.45	18.6	309	60
	356	8.34	37	3.1	844	158	0.47	18.9	336	56
	357	8.02	28	2.5	810	160	0.44	20.0	364	55
	358	7.85	32	4.0	778	148	0.43	18.9	344	55
	359	7.98	26	3.4	781	149	0.42	18.7	355	53
	360	7.61	29	2.8	793	137	0.41	18.0	334	54
	361	7.94	33	5.4	906	147	0.43	18.5	342	54

BAYER AG

geprüft
Inst. f. Toxikologie
Archiv

BAYER AG

BAYER AG

STUDIE-NR. / STUDY-NO. KWG 0519/006

DIFFERENTIALBLUTBILD / DIFFERENTIAL BLOOD COUNT (%)
12 MONATE / 12 MONTHS

DOSE DOSIS PPM	ANIM.NO TIER-NR	BASO	EOSIN	IPC JGL	STAB	SEGM	LYM	MONO	PLAS
MAENNLICH/MALE									
0	1	0	3	0	0	16	81	0	0
	2	0	0	0	0	32	68	0	0
	3	0	0	0	0	21	79	0	0
	4	0	1	0	0	11	88	0	0
	5	0	2	0	0	33	65	0	0
	6	0	0	0	0	22	78	0	0
	7	0	0	0	0	19	81	0	0
	8	0	0	0	0	10	90	0	0
	9	0	1	0	0	20	79	0	0
	10	0	2	0	0	17	81	0	0
125	102	0	2	0	0	23	75	0	0
	103	0	1	0	0	19	80	0	0
	104	0	0	0	0	23	77	0	0
	105	0	1	0	0	22	77	0	0
	106	0	0	0	0	12	88	0	0
	107	0	2	0	0	21	77	0	0
	108	0	3	0	0	33	64	0	0
	109	0	1	0	0	21	78	0	0
	110	0	0	0	0	28	72	0	0
	111	0	0	0	0	19	81	0	0
500	201	0	0	0	0	10	90	0	0
	202	0	1	0	0	20	79	0	0
	203	0	0	0	0	32	68	0	0
	204	0	1	0	0	22	77	0	0
	205	0	2	0	0	29	69	0	0
	206	0	0	0	0	26	74	0	0
	207	0	1	0	0	19	80	0	0
	208	0	0	0	0	21	79	0	0
	209	0	0	0	0	25	75	0	0
	210	0	0	0	0	14	86	0	0
2000	301	0	1	0	0	22	77	0	0
	302	0	0	0	0	16	84	0	0
	303	0	2	0	0	43	55	0	0
	304	0	0	0	0	18	82	0	0
	305	0	1	0	0	29	70	0	0
	306	0	1	0	0	27	72	0	0
	307	0	0	0	0	17	83	0	0
	308	0	0	0	0	22	78	0	0
	309	0	1	0	0	15	84	0	0
	310	0	1	0	0	25	74	0	0

geprüft
Inst. f. Toxikologie
Archiv

STUDIE-NR. / STUDY-NO. KWG 0519/006

C91

DIFFERENTIALBLUTBILD / DIFFERENTIAL BLOOD COUNT (%)
12 MONATE / 12 MONTHS

DOSE DOSIS PPM	ANIM.NO TIER-NR	BASO	EOSIN	IPC JGL	STAB	SEGM	LYM	MONO	PLAS
WEIBLICH/FEMALE									
0	51	0	0	0	0	18	82	0	0
	52	0	0	0	0	24	76	0	0
	53	0	1	0	0	13	86	0	0
	54	0	0	0	0	21	79	0	0
	55	0	0	0	0	18	82	0	0
	56	0	0	0	0	11	89	0	0
	57	0	0	0	0	11	89	0	0
	58	0	1	0	0	13	86	0	0
	59	0	0	0	0	11	89	0	0
	60	0	0	0	0	14	86	0	0
125	151	0	0	0	0	20	80	0	0
	152	0	0	0	0	11	89	0	0
	154	0	0	0	0	12	88	0	0
	156	0	0	0	0	15	85	0	0
	157	0	1	0	0	14	85	0	0
	158	0	0	0	0	12	88	0	0
	159	0	1	0	0	8	91	0	0
	160	0	1	0	0	20	79	0	0
	161	0	1	0	0	19	80	0	0
	162	0	0	0	0	19	81	0	0
500	251	0	0	0	0	11	89	0	0
	252	0	0	0	0	20	80	0	0
	253	0	0	0	0	18	82	0	0
	254	0	0	0	0	22	78	0	0
	255	0	1	0	0	15	84	0	0
	256	0	0	0	0	11	89	0	0
	257	0	0	0	0	24	76	0	0
	258	0	0	0	0	24	76	0	0
	259	0	0	0	0	20	80	0	0
	260	0	0	0	0	14	86	0	0
2000	351	0	0	0	0	18	82	0	0
	353	0	1	0	0	15	84	0	0
	354	0	0	0	0	15	85	0	0
	355	0	0	0	0	16	84	0	0
	356	0	0	0	0	22	78	0	0
	357	0	0	0	0	11	89	0	0
	358	0	0	0	0	12	88	0	0
	359	0	0	0	0	24	76	0	0
	360	0	0	0	0	11	89	0	0
	361	0	0	0	0	14	86	0	0

BAYER AG

geprüft
Inst. f. Toxikologie
Archiv

STUDIE-NR. / STUDY-NO. KWG 0519/006

092

BLUT-UNTERSUCHUNG / HAEMATOLOGY
24 MONATE / 24 MONTHS

DOSE DOSIS PPM	ANIM.NO TIER-NR	ERY TERA/L	RETI O/OO	LEU GIGA/L	THROM GIGA/L	HGB G/L	HCT L/L	MCH PG/E	MCHC G/L	MCV FL
MAENNLICH/MALE										
0	3	10.49	12	9.6	1269	162	0.566	15.4	286	54
	5	7.97	10	9.7	1531	136	0.422	17.1	322	53
	13	8.69	10	3.9	1162	143	0.443	16.5	323	51
	16	9.01	15	7.0	1549	149	0.450	16.5	331	50
	19	9.20	8	5.8	1150	155	0.478	16.8	324	52
	22	8.49	14	4.7	1162	140	0.441	16.5	317	52
	24	8.80	7	6.3	106	140	0.440	15.9	318	50
	26	8.46	7	4.7	993	151	0.448	17.8	337	53
	27	7.30	9	5.9	1580	127	0.387	17.4	328	53
	31	8.48	6	3.6	1186	144	0.441	17.0	327	52
125	107	12.19	12	14.6	209	190	0.683	15.6	278	56
	110	8.24	10	5.5	1150	147	0.437	17.8	337	53
	117	8.47	11	4.3	1245	141	0.440	16.6	320	52
	119	5.92	23	9.6	484	93	0.367	15.7	253	62
	123	7.75	6	8.2	1115	129	0.403	16.6	320	52
	127	8.55	15	6.0	1384	144	0.436	16.8	330	51
	128	9.22	3	5.2	1133	150	0.470	16.3	319	51
	141	8.92	10	5.9	1162	144	0.446	16.1	323	50
	142	8.02	10	5.3	946	129	0.385	16.1	335	48
	148	7.74	8	6.9	1293	121	0.395	15.6	307	51
500	202	9.23	10	6.0	1335	148	0.461	16.0	321	50
	205	8.42	14	4.7	1133	136	0.429	16.2	317	51
	206	8.09	9	8.0	1360	144	0.453	17.8	318	56
	215	12.32	17	6.8	1010	187	0.653	15.2	286	53
	217	9.13	7	6.3	1323	148	0.456	16.2	324	50
	218	9.46	13	5.6	935	147	0.454	15.5	324	48
	219	8.46	6	5.1	1033	137	0.440	16.2	311	52
	226	8.24	16	9.7	1180	137	0.420	16.6	326	51
	228	8.14	14	3.0	1204	143	0.440	17.6	325	54
	230	7.58	10	3.2	1051	133	0.402	17.5	331	53

geprüft
Inst. f. Toxikologie

092

STUDIE-NR. / STUDY-NO. KWG 0519/006

093

BLUT-UNTERSUCHUNG / HAEMATOLOGY
24 MONATE / 24 MONTHS

DOSE DOSIS PPM	ANIM.NO TIER-NR	ERY TERA/L	RETI O/OO	LEU GIGA/L	THROM GIGA/L	HGB G/L	HCT L/L	MCH PG/E	MCHC G/L	MCV FL
MAENNLICH/MALE										
2000	301	11.39	2	5.3	1144	160	0.604	14.0	265	53
	306	6.91	8	4.0	609	120	0.366	17.4	328	53
	308	8.57	2	6.1	1335	143	0.446	16.7	321	52
	310	7.29	33	7.8	1587	128	0.401	17.6	319	55
	312	8.90	10	4.6	1186	154	0.454	17.3	339	51
	315	8.60	3	4.4	1482	156	0.464	18.1	336	54
	322	8.56	3	7.4	872	156	0.462	18.2	337	54
	327	8.63	2	3.5	1045	141	0.431	16.3	327	50
	331	8.37	5	7.2	1469	143	0.435	17.1	329	52
	332	9.42	2	5.6	1127	163	0.480	17.3	339	51

BAYER AG
BAYER AG
BAYER AG
geprüft
Inst. f. Toxikologie
Archiv

STUDIE-NR. / STUDY-NO. KWG 0519/006

BLUT-UNTERSUCHUNG / HAEMATOLOGY
24 MONATE / 24 MONTHS

Vertraulich

Eigentum der Firma Bayer AG
Benutzung, Verwertung oder Weitgabe nur mit Einwilligung der Bayer AG gestattet

DOSE DOSIS PPM	ANIM.NO TIER-NR	ERY TERA/L	RETI O/OO	LEU GIGA/L	THROM GIGA/L	HGB G/L	HCT L/L	MCH PG/E	MCHC G/L	MCV FL
WEIBLICH/FEMALE										
0	51	7.14	16	3.1	952	157	0.414	22.0	379	58
	52	7.78	7	5.9	975	145	0.420	18.6	345	54
	55	7.59	13	5.7	832	143	0.402	18.8	355	53
	57	7.24	12	3.4	861	144	0.384	19.9	375	53
	66	6.91	9	5.1	647	132	0.380	19.1	347	55
	74	6.70	16	4.2	889	142	0.355	21.2	400	53
	76	7.05	5	5.1	659	142	0.381	20.1	373	54
	78	7.46	3	4.6	686	149	0.403	20.0	370	54
	81	7.64	12	3.5	781	138	0.405	18.1	341	53
	82	7.34	2	4.4	731	137	0.389	18.7	352	53
125	157	6.27	8	2.8	878	136	0.339	21.7	402	54
	158	7.65	6	3.0	946	141	0.398	18.4	354	52
	161	7.83	5	4.6	975	147	0.399	18.8	368	51
	163	7.83	12	4.2	826	133	0.399	17.0	333	51
	164	7.22	13	6.2	576	130	0.368	18.0	353	51
	168	7.03	7	— *	708	140	0.351	19.9	398	50
	170	6.03	10	4.4	844	145	0.308	24.0	471	51
	171	6.71	14	4.5	334	123	0.349	18.3	353	52
	177	7.17	13	3.8	935	134	0.358	18.7	374	50
	178	6.60	10	4.5	1127	138	0.337	20.9	410	51
500	253	7.72	10	4.5	998	143	0.394	18.5	363	51
	258	8.23	3	3.8	1341	142	0.436	17.3	326	53
	263	7.86	13	3.2	642	134	0.424	17.0	316	54
	266	9.12	9	— **	781	150	0.483	16.4	310	53
	267	8.95	5	8.3	855	150	0.465	16.8	322	52
	268	7.93	10	3.8	1156	143	0.420	18.0	340	53
	270	8.36	14	4.1	1080	144	0.435	17.2	331	52
	271	8.33	10	2.5	815	138	0.433	16.6	319	52
	272	8.30	8	4.6	748	133	0.440	16.0	302	53
	273	7.22	11	3.5	1016	131	0.397	18.4	335	55

* Extremwert (31.8) nicht zum Mittelwertsvergleich herangezogen
** Extremwert (65.9) nicht zum Mittelwertsvergleich herangezogen

geprüft
Inst. f. Toxikologie

STUDIE-NR. / STUDY-NR. KWG 0519/006

BLUT-UNTERSUCHUNG / HAEMATOLOGY
24 MONATE / 24 MONTHS

DOSE DOSIS PPM	ANIM.NO TIER-NR	ERY TERA/L	RETI O/OO	LEU GIGA/L	THROM GIGA/L	HGB G/L	HCT L/L	MCH PG/E	MCHC G/L	MCV FL
WEIBLICH/FEMALE										
2000	351	7.24	13	5.7	912	151	0.384	20.9	394	53
	354	7.96	6	3.8	1127	148	0.430	18.6	344	54
	357	8.43	10	3.9	565	139	0.447	16.5	311	53
	359	7.80	8	3.0	946	149	0.413	19.1	360	53
	360	7.57	5	3.6	1062	131	0.401	17.3	327	53
	362	6.71	12	3.8	1056	99	0.342	14.8	289	51
	367	6.06	23	10.1	1103	157	0.321	25.9	489	53
	368	6.98	10	5.0	1080	144	0.349	20.6	413	50
	375	7.81	22	6.1	742	122	0.398	15.6	306	51
	377	7.18	14	2.7	929	135	0.359	18.8	376	50

BAYER AG

geprüft
Inst. f. Toxikologie
Archiv

BAYER AG

095

Vertraulich

Eigentum der Firma Bayer AG
Benutzung, Verwertung oder Weitergabe nur mit Einwilligung der Bayer AG gestattet

STUDIE-NR. / STUDY-NO. KWG 0519/006 096

DIFFERENTIALBLUTBILD / DIFFERENTIAL BLOOD COUNT (%)
24 MONATE / 24 MONTHS

DOSE DOSIS PPM	ANIM.NO TIER-NR	BASO	EOSIN	IPC JGL	STAB	SEGM	LYM	MONO	PLAS
MAENNLICH/MALE									
0	3	0	1	0	0	45	54	0	0
	5	0	1	0	0	34	65	0	0
	13	0	1	0	1	27	71	0	0
	16	0	1	0	0	40	59	0	0
	19	0	2	0	0	21	77	0	0
	22	0	2	0	0	35	63	0	0
	24	0	1	0	0	19	80	0	0
	26	0	0	0	0	19	81	0	0
	27	0	1	0	0	20	79	0	0
	31	0	0	0	1	35	64	0	0
125	107	0	0	0	0	34	66	0	0
	110	0	1	0	0	23	76	0	0
	117	0	0	0	0	21	79	0	0
	119*	0	1	0	1	54	44	0	0
	123	0	0	0	1	21	78	0	0
	127	0	1	0	0	26	73	0	0
	128	0	1	0	0	27	72	0	0
	141**	0	3	0	0	29	68	0	0
	142	0	0	0	0	46	54	0	0
	148	0	0	0	0	49	50	1	0
500	202	0	0	0	0	23	77	0	0
	205	0	0	0	0	28	72	0	0
	206	0	0	0	0	85	15	0	0
	215	0	0	0	1	27	72	0	0
	217	0	1	0	0	17	82	0	0
	218	0	0	0	1	42	57	0	0
	219	0	2	0	2	33	63	0	0
	226	0	2	0	0	8	90	0	0
	228	0	1	0	0	40	59	0	0
	230***	0	0	0	1	21	78	0	0
2000	301	0	2	0	0	21	77	0	0
	306***	0	0	0	0	31	69	0	0
	308***	0	0	0	1	29	70	0	0
	310***	0	1	0	1	19	79	0	0
	312***	0	0	0	0	38	62	0	0
	315***	0	0	0	0	48	52	0	0
	322***	0	1	0	0	36	63	0	0
	327***	0	0	0	1	20	79	0	0
	331***	0	1	0	0	21	78	0	0
	332***	0	1	0	1	36	62	0	0

* zusätzlicher Befund: Polychromasie, basophile Tüpfelung
** zusätzlicher Befund: Jolly-Körperchen
*** zusätzlicher Befund: Jolly-Körperchen, Polychromasie

geprüft
Inst. f. Toxikologie
Archiv

STUDIE-NR. / STUDY-NO. KWG 0519/006

DIFFERENTIALBLUTBILD / DIFFERENTIAL BLOOD COUNT (%)
24 MONATE / 24 MONTHS

DOSE DOSIS PPM	ANIM.NO TIER-NR	BASO	EOSIN	IPC JGL	STAB	SEGM	LYM	MONO	PLAS
WEIBLICH/FEMALE *									
0	51	0	0	0	0	20	80	0	0
	52	0	2	0	0	34	64	0	0
	55	0	1	0	0	23	76	0	0
	57	0	0	0	1	47	52	0	0
	66	0	2	0	1	20	77	0	0
	74	0	0	0	0	20	80	0	0
	76	0	1	0	1	14	84	0	0
	78	0	1	0	1	24	74	0	0
	81	0	0	0	0	34	66	0	0
	82	0	2	0	0	25	73	0	0
125	157	0	3	0	3	42	52	0	0
	158	0	0	0	0	26	74	0	0
	161	0	0	0	0	15	85	0	0
	163	0	1	0	1	26	72	0	0
	164	0	0	0	0	22	78	0	0
	168	0	0	0	0	0	100	0	0
	170	0	3	0	0	19	78	0	0
	171**	0	0	0	0	7	93	0	0
	177	0	9	0	3	36	52	0	0
	178	0	3	0	0	12	85	0	0
500	253	0	0	0	0	15	85	0	0
	258	0	2	0	0	25	74	0	0
	263	0	0	0	0	24	76	0	0
	266	0	1	0	0	2	97	0	0
	267	0	0	0	0	13	87	0	0
	268	0	0	0	0	6	94	0	0
	270	0	0	0	0	22	78	0	0
	271	0	1	0	0	19	80	0	0
	272	0	0	0	1	11	88	0	0
	273	0	6	0	0	10	84	0	0
2000	351	0	1	0	1	11	87	0	0
	354	0	3	0	0	10	87	0	0
	357	0	0	0	0	17	83	0	0
	359	0	0	0	0	38	62	0	0
	360	0	1	0	1	21	77	0	0
	362	0	0	0	6	61	33	0	0
	367	0	0	0	1	29	70	0	0
	368	0	0	0	0	14	86	0	0
	375	0	0	0	3	29	68	0	0
	377	0	0	0	0	30	70	0	0

* Bei allen weiblichen Tieren aller Dosisgruppen wurden im Differentialblutbild Jolly-Körperchen gesehen

** zusätzlicher Befund: Polychromasie

BAYER AG

geprüft
Inst. f. Toxikologie
Archiv

STUDIE-NR. / STUDY-NO. KWG 0519/006

KLIN.-CHEM. UNTERSUCHUNGEN / CLINICAL CHEMISTRY
12 MONATE / 12 MONTHS

DOSE DOSIS PPM	ANIM.NO TIER-NR	ALP U/L	GOT U/L	GPT U/L	BILI µMOL/L	PROT/P EIW/P G/L	UREA HST MMOL/L	CREA KREA µMOL/L	CHOL MMOL/L	GLUC MMOL/L
MALNNLICH/MALE										
0	1	84	22.1	60.7	0.6	60.8	10.38	48	3.38	6.83
	2	104	21.6	31.4	1.5	59.0	7.86	41	3.31	10.80
	3	67	28.4	94.1	1.3	58.1	14.16	46	2.93	8.27
	4	140	34.4	43.2	2.6	63.2	7.91	35	2.49	7.25
	5	70	18.8	27.5	1.2	62.8	8.74	40	3.08	8.27
	6	73	77.5	146.9	1.6	53.9	8.15	39	3.55	7.28
	7	74	31.2	30.2	1.6	59.8	8.51	44	2.32	7.94
	8	106	25.9	25.7	2.2	53.5	8.16	39	2.27	8.31
	9	96	20.7	35.8	2.8	58.3	10.52	43	2.69	7.77
	10	78	27.3	33.2	1.6	63.3	8.55	44	2.71	9.25
125	102	107	30.5	95.5	1.7	62.8	7.74	47	2.69	9.17
	103	85	28.2	37.9	1.3	59.6	10.11	48	3.30	7.79
	104	84	24.5	35.3	1.8	62.3	9.64	40	2.78	9.57
	105	77	26.0	34.6	5.2	63.7	11.10	35	2.54	8.40
	106	66	18.9	40.0	3.0	55.6	9.23	27	2.20	8.63
	107	90	32.7	92.6	1.4	58.2	15.13	35	2.45	7.95
	108	60	21.5	49.7	1.9	56.1	9.45	32	2.62	9.17
	109	58	51.1	176.9	2.2	46.8	11.55	46	2.75	10.30
	110	151	38.9	94.6	2.4	61.9	9.25	41	2.96	8.85
	111	121	19.9	35.7	1.3	55.1	10.06	34	3.33	8.20
500	201	81	27.5	50.9	1.1	59.4	11.58	29	3.22	8.16
	202	89	31.8	37.0	1.8	59.7	9.09	34	3.00	9.11
	203	89	31.4	49.3	2.8	56.8	9.77	34	2.37	7.28
	204	166	30.7	61.6	1.7	58.4	7.46	39	2.52	8.77
	205	83	34.8	50.5	1.4	54.8	10.90	44	2.82	8.60
	206	98	31.3	42.1	1.6	57.5	9.61	40	2.46	8.06
	207	86	39.6	78.5	1.9	58.6	8.17	42	2.23	7.93
	208	108	29.4	64.9	1.3	61.0	10.03	43	2.82	8.18
	209	96	30.2	55.6	1.8	54.2	8.25	36	2.64	9.68
	210	100	34.3	40.9	1.7	55.4	9.99	43	2.91	8.27

Geprüft
Inst. f. Toxikologie
Archiv

STUDIE-NR. / STUDY-NR. KWG 0519/006

KLIN.-CHEM. UNTERSUCHUNGEN / CLINICAL CHEMISTRY
12 MONATE / 12 MONTHS

DOSE DOSIS PPM	ANIM.NO TIER-NR	ALP U/L	GOT U/L	GPT U/L	BILI µMOL/L	PROT/P EIW/P G/L	UREA HST MMOL/L	CREA KREA µMOL/L	CHOL MMOL/L	GLUC MMOL/L
MAENNLICH/MALE										
2000	301	232	43.7	84.0	2.0	54.3	11.70	40	1.56	8.60
	302	153	47.6	109.3	0.6	58.4	10.68	37	1.79	8.99
	303	59	32.7	46.9	1.2	58.5	8.21	40	1.16	7.84
	304	179	52.9	91.0	1.4	51.7	11.14	38	0.86	7.19
	305	103	41.3	81.8	0.6	56.9	10.51	47	1.76	7.61
	306	132	52.4	99.0	1.0	56.5	10.49	46	1.65	8.74
	307	121	52.2	197.5	1.2	54.2	7.03	40	1.98	8.34
	308	113	45.1	107.0	0.9	56.0	11.35	34	1.41	8.96
	309	131	43.1	74.9	0.7	54.1	10.60	40	1.63	8.56
	310	104	34.6	89.2	1.7	57.0	9.39	38	2.57	9.67

geprüft
Inst. f. Toxikologie
Archiv

BAYER AG

STUDIE-NR. / STUDY-NO. KWG 0519/006

KLIN.-CHEM. UNTERSUCHUNGEN / CLINICAL CHEMISTRY
12 MONATE / 12 MONTHS

DOSE DOSIS PPM	ANIM.NO TIER-NR	ALP U/L	GOT U/L	GPT U/L	BILI µMOL/L	PROT/P EIW/P G/L	UREA HST MMOL/L	CREA KREA µMOL/L	CHOL MMOL/L	GLUC MMOL/L
WEIBLICH/FEMALE										
0	51	137	31.7	30.0	— *	59.6	9.04	44	2.22	7.61
	52	113	34.5	19.7	2.7	58.3	8.93	39	2.61	6.99
	53	138	35.0	35.4	1.4	58.3	9.66	38	2.29	8.16
	54	123	23.0	22.1	1.8	53.5	10.95	36	2.61	7.88
	55	133	28.4	34.7	1.5	59.6	10.67	45	2.20	7.12
	56	91	56.2	44.2	1.8	56.8	6.42	47	1.70	9.14
	57	186	39.7	45.3	1.5	57.3	11.41	42	2.35	8.08
	58	105	33.2	26.9	1.8	54.1	11.00	37	2.99	8.92
	59	221	50.9	29.7	2.1	55.5	10.35	43	2.06	7.79
	60	118	41.5	50.4	1.7	59.4	8.87	43	2.33	7.44
125	151	123	44.9	29.9	0.9	59.5	8.57	46	2.31	8.09
	152	144	38.3	45.7	1.4	59.6	11.01	49	2.23	7.54
	154	100	43.6	40.7	0.9	50.1	14.05	46	2.75	6.68
	156	170	48.8	47.3	4.4	56.7	13.40	37	1.69	7.90
	157	182	44.2	32.4	2.9	56.5	10.54	42	2.48	8.05
	158	125	64.4	45.3	2.3	55.8	14.10	51	1.80	8.37
	159	96	77.8	49.4	3.2	57.2	14.04	41	2.28	7.17
	160	260	85.2	81.8	3.5	51.7	7.35	50	2.44	8.02
	161	129	56.4	68.7	2.7	56.2	10.84	45	2.43	8.31
	162	97	24.9	26.7	2.3	51.5	8.17	39	2.00	8.78
500	251	114	138.2	98.1	2.4	53.3	10.66	36	2.33	8.04
	252	177	58.3	69.2	— *	57.1	10.91	47	2.21	7.44
	253	179	87.1	161.9	1.5	58.1	8.59	37	2.48	8.37
	254	117	42.7	37.4	2.4	57.4	9.51	42	2.11	8.23
	255	134	53.5	25.9	1.4	51.4	7.95	35	1.97	8.60
	256	162	46.0	34.6	2.7	57.8	7.90	36	2.66	8.49
	257	152	43.8	31.4	3.3	56.3	8.56	40	2.15	8.60
	258	118	37.4	28.7	2.4	52.9	9.03	27	2.09	7.90
	259	148	45.4	67.3	1.4	55.9	10.64	46	1.79	8.81
	260	90	52.0	59.2	3.7	56.1	11.13	37	1.77	8.84

* Plasmamenge für Bestimmung nicht ausreichend

geprüft
Inst. f. Toxikologie
Archiv

STUDIE-NR. / STUDY-NO. KWG 0519/006

KLIN.-CHEM. UNTERSUCHUNGEN / CLINICAL CHEMISTRY
12 MONATE / 12 MONTHS

DOSE DOSIS PPM	ANIM.NO TIER-NR	ALP U/L	GOT U/L	GPT U/L	BILI µMOL/L	PROT/P EIW/P G/L	UREA HST MMOL/L	CREA KREA µMOL/L	CHOL MMOL/L	GLUC MMOL/L
WEIBLICH/FEMALE										
2000	351	111	58.6	91.5	3.0	58.0	7.68	41	1.96	7.11
	353	139	90.0	114.2	— *	51.7	9.92	32	1.49	8.01
	354	138	62.9	64.4	1.1	51.5	8.82	36	1.59	8.45
	355	152	107.4	122.7	2.3	58.4	10.36	47	1.64	8.20
	356	97	37.1	34.0	3.0	54.2	8.93	44	1.73	9.02
	357	112	66.4	66.8	2.4	55.9	10.49	36	1.74	6.92
	358	163	75.5	84.5	1.1	55.0	8.89	50	1.66	8.41
	359	125	88.0	94.6	2.3	55.1	10.99	51	1.73	7.70
	360	197	27.6	34.6	2.6	54.3	7.23	40	1.68	7.84
	361	138	67.5	107.1	1.1	53.8	10.40	42	1.65	7.37

* Plasmamenge für Bestimmung nicht ausreichend

BAYER AG

geprüft
Inst. f. Toxikologie
Archiv

BAYER AG

Vertraulich
Eigentum der Firma Bayer AG
Benutzung, Verwertung oder Weitergabe nur mit Einwilligung der Bayer AG gestattet

STUDIE-NR. / STUDY-NO. KWG 0519/006

KLIN.-CHEM. UNTERSUCHUNGEN / CLINICAL CHEMISTRY
24 MONATE / 24 MONTHS

DOSE DOSIS PPM	ANIM.NO TIER-NR	ALP U/L	GOT U/L	GPT U/L	BILI µMOL/L	PROT/P EIW/P G/L	UREA HST MMOL/L	CREA KREA µMOL/L	CHOL MMOL/L	GLUC MMOL/L
MAENNLICH/MALE										
0	5	84	24.3	23.5	3.1	49.7	9.63	37	3.34	6.74
	13	339	31.7	43.3	2.6	63.7	8.13	46	4.03	8.25
	16	500	41.0	53.6	3.3	65.9	7.57	41	4.87	6.89
	19	193	35.1	22.4	1.7	57.4	9.63	37	3.24	8.70
	22	117	34.0	39.7	1.8	55.4	7.34	34	3.34	7.91
	24	166	32.8	35.6	2.3	57.7	8.27	40	2.77	8.18
	26	129	45.3	27.8	2.0	58.0	11.80	45	3.04	8.08
	27	145	49.5	57.2	1.8	55.5	10.08	41	2.37	8.08
	31	184	39.1	94.6	2.1	61.1	8.99	37	4.89	7.91
	33	124	41.9	139.3	— *	54.6	8.56	45	2.98	8.32
125	107	345	63.7	85.2	2.6	51.0	9.22	38	2.44	6.25
	110	426	59.9	94.4	3.2	59.8	7.99	39	3.59	7.58
	117	113	29.4	36.5	2.1	57.1	8.05	41	2.73	8.46
	119	592	78.3	129.2	4.1	39.7	6.14	26	1.35	6.67
	123	471	54.8	93.5	2.8	56.8	7.53	34	2.38	8.42
	127	127	33.0	36.1	1.4	61.0	11.34	35	2.51	8.46
	128	127	47.9	65.1	2.4	53.5	9.27	32	3.30	7.87
	141	378	47.1	50.6	4.1	59.9	12.43	38	3.48	7.67
	142	1577	62.4	70.3	2.6	60.3	5.32	33	2.08	6.60
	148	109	63.2	53.5	2.0	62.8	8.10	35	1.29	6.56
500	202	142	47.2	122.6	3.4	75.2	10.11	41	3.34	8.18
	205	106	30.8	39.6	2.6	53.8	9.80	36	2.99	8.77
	206	179	109.6	57.3	2.7	47.8	11.24	33	1.83	7.75
	215	618	105.8	158.3	3.5	59.7	8.38	29	4.29	6.72
	217	115	35.9	44.1	4.2	57.0	8.12	33	2.66	8.60
	218	132	61.2	120.0	2.4	80.0	7.91	35	3.95	7.53
	219	205	50.0	125.5	2.2	60.1	9.19	34	3.19	9.14
	226	1309	66.0	80.7	2.3	58.0	8.81	35	2.35	8.36
	228	148	38.0	44.8	2.4	55.8	9.46	32	1.95	5.94
	230	125	38.0	87.2	2.7	59.0	8.74	29	2.60	8.60

* Plasmamenge für Bestimmung nicht ausreichend

geprüft
Inst. f. Toxikologie
Archiv

STUDIE-NR. / STUDY-NR. KWG 0519/006

KLIN.-CHEM. UNTERSUCHUNGEN / CLINICAL CHEMISTRY
24 MONATE / 24 MONTHS

DOSE DOSIS PPM	ANIM.NO TIER-NR	ALP U/L	GOT U/L	GPT U/L	BILI µMOL/L	PROT/P EIW/P G/L	UREA HST MMOL/L	CREA KREA µMOL/L	CHOL MMOL/L	GLUC MMOL/L
MAENNLICH/MALE										
2000	301	609	338.3	108.3	2.7	52.3	10.69	31	1.53	4.77
	306	1074	45.9	72.9	2.0	57.0	10.83	33	1.43	8.87
	308	472	63.5	215.5	4.5	55.1	9.14	37	1.33	7.94
	310	1859	182.9	537.4	2.6	64.3	8.70	33	9.23	7.67
	312	207	46.9	90.6	1.7	52.7	7.14	31	1.86	8.70
	315	403	93.8	166.5	2.3	47.4	9.80	33	3.01	6.68
	322	265	41.0	100.6	2.1	50.4	8.45	30	1.41	6.48
	327	185	47.8	89.7	1.5	47.4	9.55	30	1.05	11.78
	331	1441	49.8	114.4	1.1	59.6	6.52	42	1.43	7.43
	332	437	68.0	98.0	3.0	53.6	9.70	33	1.75	7.91

BAYER AG

geprüft
Inst. f. Toxikologie
Archiv

BAYER AG

STUDIE-NR. / STUDY-NO. KWG 0519/006

KLIN.-CHEM. UNTERSUCHUNGEN / CLINICAL CHEMISTRY
24 MONATE / 24 MONTHS

DOSE DOSIS PPM	ANIM.NO TIER-NR	ALP U/L	GOT U/L	GPT U/L	BILI µMOL/L	PROT/P EIW/P G/L	UREA HST MMOL/L	CREA KREA µMOL/L	CHOL MMOL/L	GLUC MMOL/L
WEIBLICH/FEMALE										
0	51	301	35.9	18.5	2.9	60.2	6.93	43	1.98	7.64
	52	148	37.4	24.4	2.7	50.6	8.81	32	2.72	6.56
	55	255	38.4	40.4	2.4	58.4	8.73	33	2.53	5.92
	57	175	36.8	20.1	2.3	56.6	9.44	30	2.19	6.32
	66	229	43.0	15.9	3.6	52.2	7.04	29	1.60	6.54
	74	749	31.5	21.9	3.1	62.4	11.63	37	2.80	7.54
	76	178	31.0	60.3	1.6	59.1	11.78	35	3.45	7.40
	78	205	30.0	38.0	2.1	60.9	9.80	32	3.42	7.68
	81	162	62.5	39.1	2.7	62.9	8.11	46	1.97	5.36
	82	144	53.1	28.1	3.0	59.1	6.42	30	1.85	5.47
125	158	177	38.3	30.8	3.0	50.5	15.45	30	1.66	7.44
	161	174	39.4	20.8	2.0	53.0	11.77	35	2.33	6.63
	163	324	56.9	34.6	2.4	53.2	11.40	29	1.87	7.28
	164	585	33.2	47.5	3.0	54.0	10.35	25	1.79	6.23
	168	388	38.7	53.2	2.0	57.6	9.67	35	1.93	6.32
	170	199	30.7	31.2	3.0	56.0	9.10	27	2.11	7.59
	171	375	99.0	76.2	3.0	49.0	10.07	30	1.20	7.40
	177	50	45.0	37.5	3.5	68.3	12.31	32	3.73	7.80
	178	143	56.4	67.2	3.1	56.2	11.55	27	1.97	7.59
	179	268	48.8	29.0	2.7	54.1	7.44	25	1.54	9.24
500	253	237	46.6	40.7	2.4	53.8	9.31	27	1.86	6.73
	258	105	60.8	35.9	1.8	45.8	11.23	27	2.17	6.57
	263	232	45.6	45.0	3.3	54.5	9.49	25	2.33	6.44
	266	236	69.7	57.4	1.8	59.6	10.99	31	2.71	7.70
	267	399	71.8	79.3	1.8	54.8	8.96	29	1.86	8.12
	268	149	36.1	34.1	3.3	59.0	9.61	26	2.16	7.06
	270	132	37.1	37.6	2.1	54.4	8.77	24	2.39	8.09
	271	110	71.8	66.6	2.7	57.1	13.37	28	2.48	7.50
	272	197	59.1	42.9	1.6	44.8	11.62	41	3.99	8.32
	273	165	37.1	40.5	1.0	55.6	11.94	55	2.48	7.59

geprüft
Inst. f. Toxikologie
Archiv

STUDIE-NR. / STUDY-NO. KWG 0519/006

KLIN.-CHEM. UNTERSUCHUNGEN / CLINICAL CHEMISTRY
24 MONATE / 24 MONTHS

DOSE DOSIS PPM	ANIM.NO TIER-NR	ALP U/L	GOT U/L	GPT U/L	BILI µMOL/L	PROT/P EIW/P G/L	UREA HST MMOL/L	CREA KREA µMOL/L	CHOL MMOL/L	GLUC MMOL/L
WEIBLICH/FEMALE										
2000	351	253	54.2	99.5	2.0	53.0	10.93	43	1.65	7.57
	354	237	81.6	83.3	2.0	54.4	9.46	35	1.04	7.18
	357	341	57.0	42.5	1.8	55.2	10.05	28	1.19	7.52
	359	365	138.8	276.3	3.5	53.6	10.10	37	2.41	4.10
	360	259	39.2	42.7	2.9	52.2	8.41	37	1.18	8.88
	362	416	326.4	110.9	2.1	58.0	19.76	36	1.07	5.20
	367	2555	403.9	659.9	3.2	73.9	15.12	37	7.81	6.34
	368	327	54.5	94.9	2.3	56.8	9.06	26	1.93	7.73
	375	1200	626.6	1326.4	3.3	55.8	11.80	30	7.72	6.16
	377	324	75.2	98.9	2.8	54.4	9.79	35	2.26	6.44

BAYER AG

geprüft
Inst. f. Toxikologie
Archiv

105

Vertraulich
Eigentum der Firma Bayer AG
Benutzung, Verwertung oder Weitergabe nur mit Einwilligung der Bayer AG gestattet

STUDIE-NR. / STUDY-NO. KMG 0519/006

ABSOLUTE ORGANGEWICHTE / ABSOLUTE ORGAN WEIGHTS (MG)

DOSE DOSIS PPM	ANIM.NO TIER-NR	BODY-W TIER-G (G)	HEART HERZ	LUNG LUNGE	LIV LEB	SPLE MILZ	KIDN NIE	TEST HO
MAENNLICH/MALE								
0	1							
	2							
	3							
	4							
	5	48	272	230	2262	142	816	211
	6							
	7							
	8							
	9							
	10							
	11							
	12							
	13	40	161	229	2334	96	810	200
	14							
	15							
	16	45	339	492	3700	181	1296	207
	17							
	18							
	19	39	188	211	2181	90	774	218
	20							
	21							
	22	37	210	242	2041	132	896	196
	23							
	24	39	204	296	1755	150	732	198
	25							
	26	39	215	232	1798	102	748	174
	27	42	207	209	2852	146	897	189
	28							
	29							
	30							
	31	50	206	200	2573	99	798	189
	32							
	33	45	212	203	2024	259	825	190
	34							
	35	46	192	228	1993	49	719	214
	36							
	37							
	38							
	39							
	40	35	206	212	2015	57	621	163
	41							
	42							
	43							
	44							
	45							
	46							
	47							
	48							
	49							
	50							

geprüft
Inst. f. Toxikologie
Archiv

STUDIE-NR. / STUDY-NO. KwG 0519/006

ABSOLUTE ORGANGEWICHTE / ABSOLUTE ORGAN WEIGHTS (MG)

DOSE DOSIS PPM	ANIM.NO TIER-NR	BODY-W TIER-G (G)	HEART HERZ	LUNG LUNGE	LIV LEB	SPLE MILZ	KIDN NIE	TEST HO
MAENNLICH/MALE								
125	101							
	102							
	103							
	104							
	105							
	106							
	107	29	183	970	1251	226	601	155
	108							
	109							
	110	47	211	214	2447	119	937	244
	111							
	112							
	113							
	114							
	115							
	116							
	117	33	154	160	1473	80	641	197
	118							
	119	44	184	229	6554	650	709	221
	120							
	121							
	122							
	123	46	256	269	3716	209	848	182
	124							
	125							
	126							
	127	46	197	179	2296	95	690	190
	128	39	261	460	2181	97	835	241
	129							
	130							
	131							
	132							
	133							
	134							
	135							
	136							
	137							
	138							
	139							
	140							
	141	42	224	274	3572	87	810	208
	142	39	197	212	2423	151	863	184
	143							
	144							
	145							
	146							
	147							
	148	42	212	204	2565	505	819	137
	149	40	297	259	6321	66	833	135
	150							

BAYER AG
BAYER AG
BAYER AG
BAYER AG

geprüft
Inst. f. Toxikologie
Archiv

Vertraulich

Eigentum der Firma Bayer AG
Benutzung, Verwertung oder Weitergabe nur mit Einwilligung der Bayer AG gestattet

STUDIE-NR. / STUDY-NO. KWG 0519/006

ABSOLUTE ORGANGEWICHTE / ABSOLUTE ORGAN WEIGHTS (MG)

DOSE DOSIS PPM	ANIM.NO TIER-NR	BODY-W TIER-G (G)	HEART HERZ	LUNG LUNGE	LIV LEB	SPLE MILZ	KIDN NIE	TEST HO
MAENNLICH/MALE								
500	201							
	202	47	241	220	3861	116	708	282
	203							
	204							
	205	41	196	184	2434	187	653	235
	206	40	135	223	1607	174	542	106
	207							
	208							
	209							
	210							
	211							
	212							
	213							
	214							
	215	40	180	232	5360	144	752	208
	216							
	217	45	211	255	2802	195	834	265
	218	32	177	717	2868	156	622	
	219	49	200	218	2305	119	615	196
	220							
	221							
	222							
	223							
	224							
	225							
	226	47	261	235	2940	131	918	221
	227							
	228	32	195	212	1782	74	635	184
	229							
	230	38	177	200	2095	104	775	228
	231							
	232							
	233	37	178	203	1851	90	611	193
	234							
	235							
	236							
	237							
	238							
	239	43	198	208	2407	85	813	270
	240							
	241							
	242							
	243							
	244	40	198	224	2071	109	791	160
	245							
	246							
	247							
	248							
	249							
	250							

geprüft
Inst. f. Toxikologie
Archiv

STUDIE-NR. / STUDY-NO. KWG 0519/006

ABSOLUTE ORGANGEWICHTE / ABSOLUTE ORGAN WEIGHTS (MG)

DOSE DOSIS PPM	ANIM.NO TIER-NR	BODY-W TIER-G (G)	HEART HERZ	LUNG LUNGE	LIV LEB	SPLE MILZ	KIDN NIE	TEST HO
MAENNLICH/MALE								
2000	301							
	302							
	303							
	304							
	305							
	306	40	158	300	3737	140	909	231
	307							
	308	44	245	275	3422	143	830	216
	309							
	310	41	191	225	9510	161	650	236
	311							
	312	35	194	210	2319	85	718	198
	313							
	314							
	315	33	196	204	3136	78	622	202
	316							
	317							
	318							
	319							
	320							
	321							
	322	44	276	359	2642	160	809	208
	323							
	324							
	325							
	327	42	198	268	2568	400	964	212
	328							
	329							
	330							
	331	37	206	207	3057	102	837	198
	332	34	186	213	2435	71	656	220
	333							
	334	37	181	220	2596	103	716	201
	335	39	358	379	2405	97	876	223
	336	37	222	308	1668	64	989	231
	337							
	338	42	220	275	5911	152	868	213
	339							
	340							
	341							
	342	36	176	216	3561	273	927	221
	343	35	209	228	3828	200	777	197
	344							
	345	33	151	175	3212	139	685	140
	346							
	347							
	348	34	190	233	2219	87	677	262
	349							
	350							

BAYER AG

geprüft
Inst. f. Toxikologie
Archiv

STUDIE-NR. / STUDY-NO. KWG 0519/006

ABSOLUTE ORGANGEWICHTE / ABSOLUTE ORGAN WEIGHTS (MG)

DOSE DOSIS PPM	ANIM.NO TIER-NR	BODY-W TIER-G (G)	HEART HERZ	LUNG LUNGE	LIV LEB	SPLE MILZ	KIDN NIE
WEIBLICH/FEMALE							
0	51	28	141	260	1263	121	468
	52	32	133	243	2003	462	539
	53						
	54						
	55	29	126	182	1634	102	465
	56						
	57	33	144	211	1805	272	452
	58						
	59						
	60						
	61						
	62						
	63						
	64						
	65						
	66	26	133	175	1182	133	474
	67						
	68						
	69						
	70						
	71						
	72						
	73						
	74	25	115	149	1383	145	343
	75						
	76	39	151	192	1979	133	573
	77						
	78	46	177	230	2024	123	628
	79						
	80						
	81	25	114	200	1416	100	407
	82	30	128	237	1273	147	555
	83	32	213	212	1762	348	585
	84	34	135	163	1002	354	414
	85						
	86						
	87						
	88						
	89	33	149	441	2073	250	576
	90						
	91						
	92	31	103	300	1960	165	472
	93						
	94						
	95						
	96	30	147	192	2059	165	579
	97						
	98						
	99						
	100	29	135	202	1677	119	634

geprüft
Inst. f. Toxikologie
Archiv

STUDIE-NR. / STUDY-NO. KWG 0519/006

ABSOLUTE ORGANGEWICHTE / ABSOLUTE ORGAN WEIGHTS (MG)

DOSE DOSIS PPM	ANIM.NO TIER-NR	BODY-W TIER-G (G)	HEART HERZ	LUNG LUNGE	LIV LEB	SPLE MILZ	KIDN NIE
WEIBLICH/FEMALE							
125	151						
	152						
	153						
	154						
	155						
	156						
	157						
	158	31	179	310	1510	165	815
	159						
	160						
	161	28	130	201	1571	193	417
	162						
	163	31	173	600	1590	126	474
	164	28	130	175	1516	222	507
	165						
	166						
	167						
	168	31	138	204	1560	275	432
	169						
	170	35	145	197	1594	150	491
	171	35	161	271	3775	1608	547
	172						
	173						
	174						
	175						
	176						
	177	24	134	987	1618	65	437
	178	35	149	221	1711	122	658
	179	32	145	206	1737	141	529
	180						
	181						
	182						
	183						
	184						
	185						
	186	35	136	197	2516	885	617
	187						
	188	30	125	230	1705	123	478
	189						
	190						
	191						
	192						
	193						
	194	32	139	227	1799	97	460
	195						
	196	34	120	213	1711	203	484
	197	27	145	184	1522	113	410
	198	37	197	241	2976	1192	675
	199						
	200						

BAYER AG

geprüft
Inst. f. Toxikologie
Archiv

STUDIE-NR. / STUDY-NO. KWG 0519/006

ABSOLUTE ORGANGEWICHTE / ABSOLUTE ORGAN WEIGHTS (MG)

DOSE DOSIS PPM	ANIM.NO TIER-NR	BODY-W TIER-G (G)	HEART HERZ	LUNG LUNGE	LIV LEB	SPLE MILZ	KIDN NIE
WEIBLICH/FEMALE							
500	251						
	252						
	253	31	149	191	1578	142	492
	254						
	255						
	256						
	257						
	258	28	124	207	1477	102	507
	259						
	260						
	261						
	262						
	263	29	130	178	1597	93	422
	264						
	265						
	266	31	146	261	2498	726	493
	267	30	156	291	2010	218	492
	268	32	154	202	1883	94	512
	269						
	270	38	140	230	1974	158	540
	271	40	161	201	2047	157	581
	272	36	183	239	2413	241	573
	273	31	100	228	1552	114	474
	274						
	275						
	276	28	127	174	1329	94	421
	277						
	278						
	279	28	149	727	1343	134	443
	280						
	281	25	123	153	1352	38	424
	282						
	283						
	284						
	285						
	286						
	287						
	288						
	289						
	290						
	291	34	145	225	2517	675	576
	292						
	293						
	294						
	295	31	139	209	1833	66	529
	296	30	129	403	1514	97	471
	297						
	298						
	299	35	136	171	1708	87	482
	300						

geprüft
Inst. f. Toxikologie

Vertraulich
Eigentum der Firma Bayer AG
Benutzung, Verwertung oder Weitergabe nur mit Einwilligung der Bayer AG gestattet

STUDIE-NR. / STUDY-NO. KmG 0519/006

ABSOLUTE ORGANGEWICHTE / ABSOLUTE ORGAN WEIGHTS (MG)

DOSE DOSIS PPM	ANIM.NO TIER-NR	BODY-W TIER-G (G)	HEART HERZ	LUNG LUNGE	LIV LEB	SPLE MILZ	KIDN NIE
WEIBLICH/FEMALE							
2000	351	29	122	164	2551	127	475
	352						
	353						
	354	28	144	176	1441	79	466
	355						
	356						
	357	27	119	170	1694	229	418
	358						
	359	26	127	141	1515	93	198
	360	31	137	249	1953	113	500
	361						
	362						
	363						
	364						
	365						
	366						
	367	36	166	219	9639	347	567
	368	35	162	205	2024	128	556
	369						
	370						
	371						
	372						
	373						
	374						
	375	34	162	228	9392	326	577
	376						
	377	29	156	237	2176	105	636
	378	28	130	249	1971	74	406
	379	30	139	208	1944	64	487
	380						
	381						
	382						
	383	31	144	242	2137	75	567
	384	31	143	243	2093	152	492
	385						
	386						
	387						
	388	27	118	203	1812	365	435
	389	29	131	150	2788	62	513
	390						
	391	30	139	233	1783	120	435
	392						
	393						
	394						
	395						
	396						
	397						
	398	32	142	166	2084	96	466
	399	28	138	168	1566	65	451
	400	36	178	251	3473	112	535

BAYER AG
BAYER AG
BAYER AG
BAYER AG
geprüft
Inst. f. Toxikologie

STUDIE-NR. / STUDY-NO. KHG 0519/006

RELATIVE ORGANGEWICHTE / RELATIVE ORGAN WEIGHTS (MG/100G)

DOSE DOSIS PPM	ANIM.NO TIER-NR	BODY-W TIER-G (G)	HEART HERZ	LUNG LUNGE	LIV LEB	SPLE MILZ	KIDN NIE	TEST HO
MAENNLICH/MALE								
0	1							
	2							
	3							
	4							
	5	48	567	479	4713	296	1700	440
	6							
	7							
	8							
	9							
	10							
	11							
	12							
	13	40	402	572	5835	240	2025	500
	14							
	15							
	16	45	753	1093	8222	402	2880	460
	17							
	18							
	19	39	482	541	5592	231	1985	559
	20							
	21							
	22	37	568	654	5516	357	2422	530
	23							
	24	39	523	759	4500	385	1877	508
	25							
	26	39	551	595	4610	262	1918	446
	27	42	493	498	6790	348	2136	450
	28							
	29							
	30							
	31	50	412	400	5146	198	1596	378
	32							
	33	45	471	451	4498	576	1833	422
	34							
	35	46	417	496	4333	107	1563	465
	36							
	37							
	38							
	39							
	40	35	589	606	5757	163	1774	466
	41							
	42							
	43							
	44							
	45							
	46							
	47							
	48							
	49							
	50							

geprüft
Inst. f. Toxikologie
Archiv

STUDIE-NR. / STUDY-NO. KWG 0519/006

RELATIVE ORGANGEWICHTE / RELATIVE ORGAN WEIGHTS (MG/100G)

DOSE DOSIS PPM	ANIM.NO TIER-NR	BODY-W TIER-G (G)	HEART HERZ	LUNG LUNGE	LIV LEB	SPLE MILZ	KIDN NIE	TEST HO
MAENNLICH/MALE								
125	101							
	102							
	103							
	104							
	105							
	106							
	107	29	631	3345	4314	779	2072	534
	108							
	109							
	110	47	449	455	5206	253	1994	519
	111							
	112							
	113							
	114							
	115							
	116							
	117	33	467	485	4464	242	1942	597
	118							
	119	44	418	516	14895	1477	1611	502
	120							
	121							
	122							
	123	46	557	585	8078	454	1843	396
	124							
	125							
	126							
	127	46	428	389	4991	207	1500	413
	128	39	669	1175	5562	249	2141	618
	129							
	130							
	131							
	132							
	133							
	134							
	135							
	136							
	137							
	138							
	139							
	140							
	141	42	533	652	8505	207	1929	495
	142	39	505	544	6213	387	2213	472
	143							
	144							
	145							
	146							
	147							
	148	42	505	486	6107	1202	1950	326
	149	40	742	647	15802	165	2092	338
	150							

BAYER AG

BAYER AG

BAYER AG

BAYER AG

geprüft
Inst. f. Toxikologie

STUDIE-NR. / STUDY-NO. KWG 0519/006

RELATIVE ORGANGEWICHTE / RELATIVE ORGAN WEIGHTS (MG/100G)

DOSE DOSIS PPM	ANIM.NO TIER-NR	BODY-W TIER-G (G)	HEART HERZ	LUNG LUNGE	LIV LEB	SPLE MILZ	KIDN NIE	TEST HO
MAENNLICH/MALE								
500	201							
	202	47	513	468	8215	247	1506	600
	203							
	204							
	205	41	478	449	5937	456	1690	573
	206	40	338	557	4017	435	1355	265
	207							
	208							
	209							
	210							
	211							
	212							
	213							
	214							
	215	40	450	580	13400	360	1880	520
	216							
	217	45	469	567	6227	433	1853	589
	218	32	553	2241	8963	488	1944	
	219	49	408	445	4704	243	1663	400
	220							
	221							
	222							
	223							
	224							
	225							
	226	47	555	500	6255	279	1953	470
	227							
	228	32	609	663	5569	231	1984	575
	229							
	230	38	466	526	5513	274	2039	600
	231							
	232							
	233	37	481	549	5003	243	1651	522
	234							
	235							
	236							
	237							
	238							
	239	43	460	484	5598	198	1691	628
	240							
	241							
	242							
	243							
	244	40	495	560	5177	272	1577	400
	245							
	246							
	247							
	248							
	249							
	250							

geprüft
Inst. f. Toxikologie
Archiv

STUDIE-NR. / STUDY-NO. KWG 0519/006

RELATIVE ORGANGEWICHTE / RELATIVE ORGAN WEIGHTS (MG/100G)

DOSE DOSIS PPM	ANIM.NO TIER-NR	BODY-W TIER-G (G)	HEART HERZ	LUNG LUNGE	LIV LEB	SPLE MILZ	KIDN NIE	TEST HO
MAENNLICH/MALE								
2000	301							
	302							
	303							
	304							
	305							
	306	40	395	750	9342	350	2258	577
	307							
	308	44	557	625	7777	325	2041	491
	309							
	310	41	466	559	23195	393	1585	576
	311							
	312	35	554	600	6626	243	2051	566
	313							
	314							
	315	33	594	618	9505	236	1885	612
	316							
	317							
	318							
	319							
	320							
	321							
	322	44	627	816	6005	364	1839	473
	323							
	324							
	325							
	327	42	471	638	7067	952	2255	505
	328							
	329							
	330							
	331	37	557	559	8262	276	2262	535
	332	34	547	626	7162	209	1929	647
	333							
	334	37	489	595	7016	278	1935	543
	335	39	918	972	6167	249	2246	572
	336	37	600	832	4508	173	2673	624
	337							
	338	42	524	655	14074	362	2067	507
	339							
	340							
	341							
	342	36	489	600	9892	758	2575	614
	343	35	597	651	10537	571	2220	563
	344							
	345	33	458	530	9733	421	2076	424
	346							
	347							
	348	34	559	685	6526	256	1991	771
	349							
	350							

BAYER AG

BAYER AG

BAYER AG

geprüft
Inst. f. Toxikologie
Archiv

Vertraulich

Eigentum der Firma Bayer AG
Benutzung, Verwertung oder Weiter
gabe nur mit Einwilligung der
Bayer AG gestattet

STUDIE-NR. / STUDY-NO. KWG 0519/006

RELATIVE ORGANGEWICHTE / RELATIVE ORGAN WEIGHTS (MG/100G)

DOSE DOSIS PPM	ANIM.NO TIER-NR	BODY-W TIER-G (G)	HEART HERZ	LUNG LUNGE	LIV LEB	SPLE MILZ	KIDN NIE
WEIBLICH/FEMALE							
0	51	28	504	929	4511	432	1671
	52	32	416	759	6259	1256	1684
	53						
	54						
	55	29	434	628	5634	352	1603
	56						
	57	33	436	639	5470	824	1370
	58						
	59						
	60						
	61						
	62						
	63						
	64						
	65						
	66	26	512	673	4546	512	1823
	67						
	68						
	69						
	70						
	71						
	72						
	73						
	74	25	460	596	5532	580	1372
	75						
	76	39	387	492	5074	341	1469
	77						
	78	46	385	500	4400	267	1365
	79						
	80						
	81	25	456	800	5664	400	1628
	82	30	427	790	4243	490	1850
	83	32	666	663	5506	1088	1828
	84	34	397	479	2947	1041	1218
	85						
	86						
	87						
	88						
	89	33	452	1336	6282	879	1745
	90						
	91						
	92	31	332	968	6323	532	1523
	93						
	94						
	95						
	96	30	490	640	6863	550	1930
	97						
	98						
	99						
	100	29	466	657	5783	410	2186

geprüft
Inst. f. Toxikologie
Archiv

STUDIE-NR. / STUDY-NO. KWG 0519/006

RELATIVE ORGANGEWICHTE / RELATIVE ORGAN WEIGHTS (MG/100G)

DOSE DOSIS PPM	ANIM.NO TIER-NR	BODY-W TIER-G (G)	HEART HERZ	LUNG LUNGE	LIV LEB	SPLE MILZ	KIDN NIE
WEIBLICH/FEMALE							
125	151						
	152						
	153						
	154						
	155						
	156						
	157						
	158	31	577	1000	4871	532	1984
	159						
	160						
	161	28	464	718	5611	689	1489
	162						
	163	31	558	1935	5129	406	1529
	164	28	464	625	5363	793	1811
	165						
	166						
	167						
	168	31	445	658	5032	887	1394
	169						
	170	35	414	563	4554	429	1403
	171	35	460	774	10786	4594	1563
	172						
	173						
	174						
	175						
	176						
	177	24	558	4113	6742	271	1821
	178	35	426	631	4889	349	1880
	179	32	453	644	5428	441	1653
	180						
	181						
	182						
	183						
	184						
	185						
	186	35	389	563	7189	2529	1763
	187						
	188	30	417	767	5683	410	1593
	189						
	190						
	191						
	192						
	193						
	194	32	434	709	5622	303	1438
	195						
	196	34	353	626	5032	597	1424
	197	27	537	681	5637	419	1519
	198	37	532	651	8043	3222	1824
	199						
	200						

BAYER AG
BAYER AG
BAYER AG
BAYER AG
geprüft
Inst. f. Toxikologie

STUDIE-NR. / STUDY-NO. KWG 0519/006

RELATIVE ORGANGEWICHTE / RELATIVE ORGAN WEIGHTS (MG/100G)

DOSE DOSIS PPM	ANIM.NO TIER-NR	BODY-W TIER-G (G)	HEART HERZ	LUNG LUNGE	LIV LEB	SPLE MILZ	KIDN NIE
WEIBLICH/FEMALE							
500	251						
	252						
	253	31	481	616	5090	458	1587
	254						
	255						
	256						
	257						
	258	28	443	739	5275	364	1811
	259						
	260						
	261						
	262						
	263	29	448	614	5507	321	1455
	264						
	265						
	266	31	471	842	8058	2342	1590
	267	30	520	970	6700	727	1640
	268	32	481	631	5884	294	1600
	269						
	270	38	368	605	5195	416	1421
	271	40	402	502	5117	392	1452
	272	36	508	664	6703	669	1592
	273	31	323	735	5006	368	1529
	274						
	275						
	276	28	454	621	4746	336	1504
	277						
	278						
	279	28	532	2596	4796	479	1582
	280						
	281	25	492	612	5408	152	1656
	282						
	283						
	284						
	285						
	286						
	287						
	288						
	289						
	290						
	291	34	426	662	7403	1985	1694
	292						
	293						
	294						
	295	31	448	674	5913	213	1706
	296	30	430	1343	5047	323	1570
	297						
	298						
	299	35	389	489	4880	249	1377
	300						

geprüft
Inst. f. Toxikologie
Leverkusen

Vertraulich
Eigentum der Firma Bayer AG
Benutzung, Verwertung oder Wei
gabe nur mit Einwilligung der
Bayer AG gestattet

STUDIE-NR. / STUDY-NO. KWG 0519/006

RELATIVE ORGANGEWICHTE / RELATIVE ORGAN WEIGHTS (MG/100G)

DOSE DOSIS PPM	ANIM.NO TIER-NR	BODY-W TIER-G (G)	HEART HERZ	LUNG LUNGE	LIV LEB	SPLE MILZ	KIDN NIE
WEIBLICH/FEMALE							
2000	351	29	421	566	8797	438	1638
	352						
	353						
	354	28	514	629	5146	282	1664
	355						
	356						
	357	27	441	630	6274	848	1541
	358						
	359	26	488	542	5827	358	762
	360	31	442	803	6300	365	1613
	361						
	362						
	363						
	364						
	365						
	366						
	367	36	461	608	26775	964	1575
	368	35	463	589	5783	366	1589
	369						
	370						
	371						
	372						
	373						
	374						
	375	34	476	671	27624	959	1697
	376						
	377	29	538	817	7503	362	2193
	378	28	464	889	7039	264	1450
	379	30	463	693	6480	213	1623
	380						
	381						
	382						
	383	31	465	781	6894	242	1829
	384	31	461	784	6752	490	1587
	385						
	386						
	387						
	388	27	437	752	6711	1352	1611
	389	29	452	517	9614	214	1769
	390						
	391	30	463	777	5943	400	1450
	392						
	393						
	394						
	395						
	396						
	397						
	398	32	444	519	6513	300	1456
	399	28	493	600	7021	232	1611
	400	36	494	697	9647	311	1486

BAYER AG
BAYER AG
BAYER AG
BAYER AG
geprüft
Inst. f. Toxikologie

Died during study
study KWG 0519/006 **dose:** 0 ppm **findings** 122 a

anim. no.	sex	death/ study day	degree auto-lysis	
37	m	4.10.78	+++	n.f.
		85		
29	m	27. 1.79		LU fleshy; cervical LY enlarged
		200		
17	m	4.4.79		ST mucosal haemorrhage; LU lob. dxtr. fleshy areas
		267		
14	m	16.5.79	+++	TY grey hard nodule (1.4 x 0.6 cm)
		309		
46	m	1.8.79		LU lob. sup. dxtr. and lob. inf. dxtr. med. flesh coloured;
		386		LI distinct lobulation
48	m	9.9.79		LU lob. sup. dxtr. grey hard; lob. sin. pinpoint sized, white
		425		spot; SP enlarged (3.0 x 1.0 cm), swollen; LI enlarged;
				LY enlarged
10	m	25.9.79	m.s.	SPINE above tail root skin inflamed and adherent; SP enlarg-
		441		ed (2.5 x 0.6 cm) swollen
41	m	2.10.79		n.f.
		448		
44	m	2.10.79	++	n.f.
		448		
50	m	5.12.79	++	SP enlarged (4.3 x 1.4 cm), swollen
		512		

anim. no.	sex	death/ study day	degree auto-lysis	Died during study study KWG 0519/006 dose: 0 ppm findings 122 b
47	m	13.1.80		LU pale; SP enlarged (3.1 x 0.6 cm), swollen; LI discoloured
		551		grey-red, dotted with dark red-black spots (up to 0.2 cm Ø);
				LY meserentici, enlarged
32	m	4.2.80		adipose; LU lob. sup. dxtr. white hard nodule (0.2 cm Ø);
		573		LI distinct lobulation; PI enlarged (0.25 cm Ø)
25	m	4.2.80		LU focal dark red areas, lob. inf. dxtr. lat. white hard nodule
		573		(1.2 cm Ø); LI enlarged, lob. sin. soft brown nodule (1.2cm Ø)
30	m	15.2.80		LU flesh coloured, lob. sup. dxtr. white hard, lob. sin. white
		584		hard nodule (0.2 cm Ø); SP enlarged (3.6 x 1.1 cm) swollen;
				LY enlarged
42	m	25.2.80		LU pale, lob. inf. dxtr. med. hard, brown, penetrating nodule
		594		(0.5 cm Ø); SP enlarged (3.6 x 0.9 cm), swollen; LI enlarged,
				swollen, distinct lobulation; left KI isolated crater-shaped
				recesses (0.1 cm Ø)
28	m	28.2.80		adipose; UR enlarged (1.4 cm Ø); LI distinct lobulation
		597		
20	m	14.3.80		adipose
		612		

BAYER AG

anim. no.	sex	death/ study day	degree auto-lysis	Died during study **study KWG 0519/006 dose:** 0 ppm **findings** 123 a
12	m	21.3.80		LU focal, dark red areas; LI enlarged, swollen, grey-white-
		619		beige spotted surface; SP enlarged (2.4 x 0.5 cm), swollen
45	m	1.4.80	+	adipose; LU focal, dark red areas; LI distinct lobulation;
		630		left KI pinpoint sized, serous cyst
1	m	6.4.80		LU discoloured dark red, with partial yellow coating
		635		
38	m	10.4.80		LU discoloured dark red; TY enlarged; PLEURAL CAVITY filled
		639		with bloody fluid; SP enlarged (3.3 x 0.9 cm), marbled surface;
				PANCREAS nodular hardened
21	m	12.4.80	++	LU partly flesh coloured; SP enlarged (3.1 x 1.0 cm), swollen,
		641		white-grey, marbled surface; LY enlarged
49	m	22.4.80	+++	LU lob. sin. white hard area (0.3 cm Ø); SP enlarged (3.2 x
		651		0.7 cm), swollen; LI lob. sin. swollen; LY enlarged
18	m	30.4.80		LU discoloured dark red; SP enlarged (2.3 x 0.6 cm); LI en-
		659		larged; LY enlarged; SE enlarged; UR enlarged (1.2 cm Ø);
				KI, AD pale
7	m	7.5.80		LU surrounded with blood clots; LI clay coloured; SP enlarged
		666		(2.3 x 0.5 cm); SE enlarged; PI serous cyst (0.3 cm Ø)
15	m	9.5.80		LU flesh coloured; right TE enlarged, hard; left KI beige
		668		coloured, hard area (0.3 cm Ø)

Died during study
study KWG 0519/006 dose: 0 ppm **findings** 123 b

anim. no.	sex	death/ study day	degree auto-lysis	
36	m	12.5.80	+++	LU lob. dxtr. yellow, soft nodule (0.8 cm Ø)
		671		
23	m	19.5.80	+	LU focal, dark red areas; ST mucosal haemorrhage; SMALL INTEST-
		678		INE red-brown contents
9	m	4.6.80		LU focal, dark red areas; SP clay coloured; UR enlarged (1.0
		694		cm Ø), contains bloody fluid
39	m	6.6.80	+++	LU discoloured black
		696		
8	m	18.6.80	+++	SE enlarged; KI perirenal fatty tissue widespread , hard
		708		
4	m	19.6.80	++	LU discoloured dark red
		709		
11	m	24.6.80		LU focal, dark red areas; CRANIUM hardend; BASE OF SCULL below
		714		the PI a stone-hard, white nodule
6	m	25.6.80	m.s.	LU lob. sin. white area (0.1 cm Ø), lob dxtr. discoloured reddis;
		715		SE enlarged; SP marbled surface; LI clay coloured; left KI
				pinpoint sized, serous cyst ; LY enlarged
34	m	25.6.80	m.s.	LU lob. inf. dxtr. lat. hard, grey nodule (0.4 cm Ø); LI clay
		715		coloured; right SE hard, partly soft nodule filled with bloody
				fluid and soft brown and green mass (1.6 cm Ø)

Died during study
study KWG 0519/006 dose: 0 ppm **findings** 124

anim. no.	sex	death/ study day	degree auto-lysis	
43	m	25.6.80	m.s.	SP enlarged (3.6 x 0.6 cm), swollen; LY enlarged;
		715		PI bloody
2	m	25.6.80	m.s.	LU lob. sup. dxtr. grey, hard nodule (0.3 cm Ø); SE enlarged;
		715		CRANIUM hardend
3	m	30.6.80		LU flesh coloured, lob. sup. dxtr. white, hard, penetrating
		720		nodule (0.4 cm Ø); LI lob. sin. enlarged, swollen, hard;
				entire LI enlarged; KI covered with serous cysts

Confidential

Copyright by Bayer AG
the use, utilisation or distribution
is only permitted with the consent
of Bayer AG.

anim. no.	sex	death/ study day	degree auto-lysis	Died during study study KWG 0519/006 dose: 0 ppm findings 125 a
70	f	29.10.78		ST scattered mucosal haemorrhage
		110		
75	f	25.1.79	++++	no appraisal possible
		198		
77	f	6.7.79	++	TY beige, hard nodule (1.0 x 1.2 cm); LU fleshy areas;
		360		SP enlarged (3.0 x 0.8 cm), swollen
67	f	14.8.79		SP enlarged (4.6 x 1.4 cm); ST scattered mucosal haemorrhage;
		399		LI enlarged, swollen; LY enlarged
90	f	12.9.79	++++	no appraisal possible
		428		
88	f	14.10.79	+	PLEURAL CAVITY in SP and ST a hard, partly soft nodule filled
		460		with bloody fluid and solid mass (2.5 cm Ø)
53	f	2.11.79		PLEURAL CAVITY filled with blood clots; LU dark red; SP enlarg-
		479		ed (2.5 x 0.6 cm), swollen; LI enlarged; LY enlarged;
				FATTY TISSUE excess present
61	f	28.11.79	m.s.	UT horns enlarged (0.3 cm Ø)
		505		
99	f	28.11.79	m.s.	right HEAD OF FEMUR bony hardening (0.8 cm Ø); UT horns swolle
		505		(0.35 cm Ø); left OV serous cyst (0.30 cm Ø); AD enlarged
				(0.2 cm Ø); PELVIS left under spine bone-hard thickening
				(2.0 - 1.0 cm); CRANIUM hardened, in PI area hard nodule (0.25cm Ø)

Died during study
study KWG 0519/006 **dose:** 0 ppm **findings** 125 b

anim. no.	sex	death/ study day	degree auto-lysis	
54	f	8.12.79		adipose; LU filled with blood; ST enlarged; AD pale
		515		
68	f	19.12.79		PLEURAL CAVITY 4 ml clear fluid; LU partly flesh coloured;
		526		TY hard, beige nodule (1.8 cm Ø); SP enlarged (2.6 x 0.7 cm);
				right KI pinpoint sized, serous cyst ; PI enlarged, glassy
98	f	28.12.79	+++	SP enlarged (4.6 x 0.8 cm), swollen; OV in each a hard, grey
		535		nodule (1.2 cm Ø)
56	f	9.1.80	+++	SP enlarged (4.2 x 1.2 cm) swollen; LY enlarged
		547		
62	f	18.1.80		LU focal, excessive air and liquid contents; SP enlarged
		556		(3.3 x 0.8 cm),swollen; LI distinct lobulation; ST mucosal
				haemorrhage; UR 0.3 ml bloody fluid; LY enlarged
87	f	24.1.80	+	LU lob. sup. dxtr. flesh coloured; SP enlarged (3.2 x 0.7 cm),
		562		swollen; ST mucosal haemorrhage; SMALL IN reddish contents
59	f	25.2.80	++	LU focal, dark red areas; UT neck thickened (1.2 cm Ø), hard,
		594		left OV serous cyst (0.6 cm Ø)
58	f	25.2.80		PLEURAL CAVITY 3 ml milky, opaque fluid; LU flesh coloured,
		594		TY soft, beige excrescence, (1.2 x 0.8 cm); LI distinct
				lobulation, clay coloured in parts; UT horns thickened (0.4 cm Ø)

Confidential

Copyright by Bayer AG
the use, utilisation or distribution
is only permitted with the consent
of Bayer AG.

Died during study

study KWG 0519/006 **dose:** 0 ppm **findings** 126 a

anim. no.	sex	death/ study day	degree auto-lysis	
69	f	4.3.80	++	HYPOGASTRIUM in subcutaneous connective tissue a beige-red,
		602		partly soft, partly hard nodule (3.0 x 2.3 cm) breaking out;
				SP enlarged (2.2 x 0.4 cm); UT horns thickened (0.3 cm Ø)
91	f	13.3.80		LU pinpoint sized, dark spots, lob. sup. dxtr. white-grey
		611		nodule (0.3 cm Ø); UT horns thickened (0.4 cm Ø); SP enlarged
				(2.5 x 0.6 cm), swollen
94	f	22.4.80	m.s.	apathetic; LU focal, dark red areas, lob. inf. dxtr. lat. white
		651		area (0.4 cm Ø); SP enlarged (3.2 x 1.0 cm), swollen, spotted
				grey-white surface; UT left horn beige hard nodule (0.7 cm Ø);
				LI and LY enlarged; ST mucosal haemorrhage; SMALL IN red-brown
				contents; KI pale, bumpy surface
97	f	29.4.80		LU flesh coloured; SP enlarged (3.4 x 0.6 cm), swollen;
		652		LI and LY enlarged
95	f	30.4.80		LU flesh coloured; LI distinct lobulation; SP enlarged
		659		(2.4 x 0.5 cm); UT horns thickened (0.6 cm Ø); right OV yellow
				hard nodule (0.8 cm Ø); LI clay coloured; ST scattered mucosal
				haemorrhage
71	f	6.5.80		LU marginal, dark red areas; LI clay coloured; SP enlarged
		665		(3.2 x 0.8 cm), swollen; left OV serous cyst (0.7 cm Ø)
85	f	7.5.80		LU white-grey, hard areas (up to 0.3 cm Ø); PLEURAL CAVITY
		666		5 ml bloody fluid; left KI pinpoint sized, serous cysts

anim. no.	sex	death/ study day	degree auto-lysis	Died during study study KWG 0519/006 dose: 0 ppm findings 126 b
86	f	9.5.80	m.s.	WEIGHT LOSS; LU lob. inf. dxtr. lat. and lob. inf. dxtr. med.
		668		discoloured dark red
79	f	19.5.80	+	LU discoloured reddish; SP enlarged (2.7 x 0.6 cm), swollen;
		678		LI enlarged, swollen, soft, marbled surface; UT horns, neck
				and OV adhesion with a soft, partly hard nodule (3.5 x 1.4 cm)
				filled with yellowish paste; LY enlarged; KI pinpoint sized,
				serous and bloody cysts
73	f	22.5.80	m.s.	NECK skin inflamed and adherent between the ears; SP enlarged
		681		(2.7 x 0.7 cm), swollen; LI clay coloured; UT thickened (0.5
				cm Ø), hard; OV serous cyst (0.6 cm Ø), green, soft nodule
				(0.3 - 0.6 cm Ø)
64	f	23.5.80	m.s.	LU lob. sup. dxtr. flesh coloured; SP enlarged (4.0 x 1.2 cm),
		682		grey-white, marbled surface; LI enlarged; LY enlarged;
				KI, AD, PI pale
60	f	1.6.80		ABDOMEN 7 ml dark red liquid; PA bloody cyst (1.0 cm Ø);
		691		right OV bloody cyst (1.0 cm); LI portal fissure reddish,
				soft nodule (2.6 cm Ø)
72	f	10.6.80		LU flesh coloured; LI enlarged; SP enlarged (3.3 x 0.7 cm),
		700		swollen; LY enlarged; ST, IN, SP, PA, left KI, left AD, UT and
				OV fused with a serous cyst (1.3 cm Ø) and a hard nodule (1.4
				cm Ø)

Confidential

Copyright by Bayer AG
the use, utilisation or distribution
is only permitted with the consent
of Bayer AG.

anim. no.	sex	death/ study day	degree auto-lysis	Died during study study KWG 0519/006 dose: 0 ppm findings 126 c
80	f	19.6.80 709		LU flesh coloured; LI marbled surface; SP enlarged (4.5 x 0.9 cm), swollen; KI clay coloured; ST mucosal haemorrhage; LY enlarged; CRANIUM hardend

Confidential
Copyright by Bayer AG
the use, utilisation or distribution is only permitted with the consent of Bayer AG.

Died during study
study KWG 0519/006 **dose:** 0 ppm **findings** 127

anim. no.	sex	death/ study day	degree auto-lysis	
93	f	22.6.80	+	NECK and THORACIC area skin inflamed, adherent; UU lob dxtr.
		712		white, hard nodule (0.7 cm Ø); SP enlarged (2.6 x 0.5 cm),
				swollen; left OV bloody cyst (0.7 cm Ø)
63	f	24.6.80	m.s.	apathetic; SP enlarged (2.7 x 1.0 cm); UT left horn red-beige,
		714		hard nodule (1.6 x 2.0 cm)
65	f	26.1.80	++++	no appraisal due to advanced autolysis, nothing fixed
		431		

Died during study
study KWG 0519/006 dose: 125 ppm **findings** 128 a

anim. no.	sex	death/ study day	degree auto-lysis	
101	m	26.12.78		ST mucosal haemorrhage; IN bloody contents
		168		
143	m	7.6.79	++++	appraisal not possible
		331		
129	m	15.7.79		THORACIC CAVITY 2 ml clear-serous fluid; LU fleshy areas;
		369		LI distinct lobulation
146	m	23.7.79		adipose; LI filled with blood
		377		
125	m	9.9.79	+++	LI lob. sin. soft, brown nodule (1,5 cm Ø)
		425		
139	m	18.10.79	+++	LU fleshy; TY soft, grey nodule (1.0 cm Ø)
		464		
104	m	5.11.79		LI lob. sin. light hardening (1.4 x 1.0 cm); SE left wing
		482		hardened, discoloured red and grey
144	m	5.11.79		n.f.
		482		
121	m	14.11.79	m.s.	underside hairless; TY yellow, grey hard nodule (0.5 cm Ø);
		491		SP enlarged (2.8 x 0.6 cm); right TE rudimentary (0.3 cm Ø);
				KI enlarged (1.2 x 0.8 cm), right KI spotlike gelatinous cyst
111	m	22.11.79	+	LU lob. sup. dxtr. hard, white nodule (0.8 x 0.4 cm), lob. inf.
		499		dxtr. med. and lat. several hard, white nodules (0.1 cm Ø),(cont.)

Confidential

Copyright by Bayer AG
the use, utilisation or distribution
is only permitted with the consent
of Bayer AG.

Died during study
study KWG 0519/006 dose: 125 ppm **findings** 128 b

anim. no.	sex	death/ study day	degree auto-lysis	
111	m	22.11.79	(cont.)	right KI cranial end, white, soft thickening (0.1 cm Ø), left
				KI on neck soft, pulpy nodule (0.3 cm Ø); HYPOGASTRIUM hard,
				whitish nodule (0.6 cm Ø), section whitish; right THIGH white
				nodule (0.7 cm Ø), section white, soft
147	m	20.11.79	+	SALIVARY GLANDS enlarged, left 0.8 cm Ø, right 0.6 cm Ø; LU
		497		flesh coloured, lob. inf. dxtr. med. soft light-grey nodule
				(0.25 cm Ø); UR enlarged (1.5 cm Ø); SE yellowish; ST mucosal
				haemorrhage; left KI enlarged (1.8 x 0.9 cm), clay coloured
				with black spots, right KI enlarged (1.4 x 0.7 cm), limp, clay
				coloured, with dark grey spots; AD slightly enlarged (0.25 cm Ø)
134	m	16.12.79	+++	UR enlarged (1.2 cm Ø), containing bloody fluid
		523		
120	m	28.12.79	++	LI distinct lobulation
		535		
103	m	2.1.80		LU focal, dark red areas; ST mucosal haemorrhage; SMALL IN red-
		540		brown content
106	m	8.1.80		THORACIC CAVITY 4 ml bloody-serous fluid; ABDOMEN 10 ml
		546		bloody fluid; SP very enlarged (6.4 x 2.0 cm), swollen, dis-
				coloured beige-white, hard; LY mesenterici enlarged
118	m	10.1.80		adipose
		548		

Confidential

Copyright by Bayer AG
the use, utilisation or distribution
is only permitted with the consent
of Bayer AG.

Died during study **study KWG 0519/006** **dose:** 125 ppm **findings** 129 a

anim. no.	sex	death/ study day	degree auto-lysis	
138	m	14.1.80	+	adipose; UR enlarged (1.0 cm Ø); SE enlarged; LI distinct
		552		lobulation, partly clay coloured
116	m	15.1.80		LU pinpoint sized dark spots; SP enlarged (2.7 x 0.6 cm), yellow-
		553		ish spots; LI yellowish spotted surface; LY meserentici enlarged
114	m	22.1.80		THORAX, FRONT EXTREMITIES and ABDOMEN skin inflamed and adherent;
		560		SP enlarged (2.2 x 0.5 cm)
109	m	4.2.80		LU focal dark red areas; ST enlarged
		573		
113	m	7.2.80	+	LU pinpoint sized, dark red spots; LI partly clay coloured
		576		
130	m	11.2.80	++++	appraisal no longer possible
		580		
131	m	14.2.80		LU lob. sin. white, hard nodule (0.4 cm Ø); LI sand coloured,
		583		distinct lobulation; ST mucosa discoloured black; KI and AD
				pale
112	m	9.3.80		LU focal dark red areas, lob. sup. dxtr. hard, white-grey nodule
		607		(1.2 cm Ø), lob. inf. dxtr. lat. hard, white-grey nodule (0.4 cm
				Ø); SE enlarged
145	m	16.3.80	+++	adipose
		614		
132	m	24.3.80		adipose; PLEURAL CAVITY filled with blood clots; LU partly
		622		flesh coloured; LI clay coloured

Died during study
study KWG 0519/006 dose: 125 ppm **findings** 129 b

anim. no.	sex	death/ study day	degree auto-lysis	
135	m	27.3.80		adipose; LU focal dark red areas
		625		
115	m	30.3.80		LU lob. sin. hard white area (0.2 cm Ø), lob. dxtr. hard, beige
		628		nodule (0.6 cm Ø); SP enlarged (3.2 x 0.6 cm), swollen
150	m	28.4.80	++++	appraisal no longer possible
		657		
102	m	6.5.80		LU focal dark red areas; LI lob. dxtr. soft, beige-brown, bloody
		665		nodule (2.4 x 1.5 cm); SP clay coloured; KI covered in pinpoint
				sized black spots
124	m	12.5.80	++++	appraisal no longer possible
		671		
140	m	21.5.80		LU surrounded by blood clots; LI clay coloured, soft
		680		
105	m	23.5.80	m.s.	LI lob. sin. enlarged, swollen, portal fissure dark red, soft
		682		nodule (1.4 cm Ø)
122	m	6.6.80	++	LU discoloured reddish
		696		

anim. no.	sex	death/ study day	degree auto-lysis	Died during study study KWG 0519/006 dose: 125 ppm findings 130 a
126	m	8.6.80		adipose; LU discoloured dark red; LI enlarged; KI pale, crater-
		698		shaped, pinpoint sized recesses
108	m	9.6.80	+	LU lob. dxtr. dark shading; ST mucosa covered with grey-green
		699		slime
136	m	24.6.80	m.s.	LU flesh coloured; ABDOMEN, FATTY TISSUE enriched, hard, yellow-
		714		ish, adhering to intestine and accessory sex glands
137	m	25.6.80		LU discoloured reddish, lob. sup. dxtr. enlarged, beige-red,
		715		hard, lob. inf. dxtr. lat. grey, hard nodule (0.2 cm Ø), lob. sin.
				grey hard area (0.1 cm Ø)
133	m	25.6.80	m.s.	TE, AD adhesion with scrotum and fatty tissue; FATTY TISSUE en-
		715		riched, hard; LI enlarged, hard, marbled surface; KI clay colour-
				ed, pinpoint sized, serous cyst
176	f	23.12.78	++++	appraisal no longer possible
		165		
200	f	28.2.79	++	SP enlarged (3.9 x 0.6 - 0.9 cm); TE excrescence; LU dark
		232		coloured marked with light areas
169	f	1.3.79	+++	ST mucosal haemorrhage in fundus area
		233		
155	f	11.4.79		ST mucosal haemorrhage; IN bloody content
		274		

Confidential

Copyright by Bayer AG
the use, utilisation or distribution
is only permitted with the consent
of Bayer AG.

Died during study
study KWG 0519/006 dose: 125 ppm **findings** 130 b

anim. no.	sex	death/ study day	degree auto-lysis	
153	f	25.4.79		ST mucosal haemorrhage; IN bloody content
		288		
182	f	28.5.79	+++	OV right, soft nodule (1.2 x 1.0 cm), left, white nodule
		321		(1.5 x 1.3 cm); SP enlarged (3.3 x 0.5 cm)
165	f	9.6.79		UT horns thickened (0.3 cm Ø); SP enlarged (3.3 x 0.6 cm)
		333		
156	f	14.7.79		n.f.
		368		
174	f	1.8.79	++++	appraisal not possible
		386		
187	f	6.9.79	m.s.	left side of abdomen skin thickened, red
		422		
159	f	12.9.79	+++	TY soft beige nodule (1.0 cm Ø)
		428		
154	f	17.9.79	+	UT horns thickened (0.3 cm Ø); left OV bloody cyst (0.6 cm Ø)
		433		

Died during study
study KWG 0519/006 dose: 125 ppm **findings** 131 a

anim. no.	sex	death/ study day	degree auto-lysis	
152	f	23.9.79		PLEURAL CAVITY 2 ml brownish opaque fluid; LU fleshy; ABDOMEN
		439		10 ml brownish opaque fluid, fatty tissue enriched, hard, reddish
183	f	5.10.79	+	LU pale; SP enlarged (2.7 x 0.5 cm); ST mucosal haemorrhage;
		451		SMALL IN black contents; LY enlarged
160	f	13.10.79		LU fleshy; TY beige hard nodule (1.5 x 1.0 cm); SP enlarged
		459		(3.2 x 0.7 cm), swollen; LI lob. sin. enlarged, swollen, soft
193	f	24.1.80	++	LU focal dark red areas; SP enlarged (2.4 x 0.5 cm);
		562		UT right horn soft, grey nodule (0.4 cm Ø); left OV serous cyst
				(0.7 cm Ø); ST scattered mucosal haemorrhage; PI serous cyst
				(0.1 cm Ø)
173	f	5.2.80		LU focal dark red areas, lob. inf. dxtr. lat. white hard nodule
		574		(0.3 cm Ø); SP enlarged (3.6 x 0.6 cm), swollen; LI enlarged,
				swollen, lumpy surface
175	f	5.2.80	m.s.	left FRONT EXTREMITY mutilated, bloody; SP enlarged (2.8 x 0.6 cm,
		574		swollen; LU lob. sin. grey hard area (0.2 cm Ø); UT right horn
				in middle a dark red, hard, nodule with nodular structure (1.1 x
				0.6 cm)
189	f	4.3.80		UT horns thickened (0.3 cm Ø); left OV bloody cyst (0.6 cm Ø);
		602		ST bloody content, mucosal haemorrhage; SMALL IN red-brown con-
				tents; right KI clay coloured, lumpy excrescences; left KI
				enlarged, clay coloured, lumpy excrescences; LY enlarged

Died during study **study KWG 0519/006** **dose:** 125 ppm **findings** 131 b

anim. no.	sex	death/ study day	degree auto-lysis	
166	f	31.3.80	+++	SP enlarged (4.7 x 0.8 cm), swollen; LI enlarged; LY enlarged
		629		
191	f	8.4.80	m.s.	LU lob. sin and lob. dxtr. upper part dark red; SP enlarged
		637		(3.3 x 0.8 cm); ST mucosa reddened; KI pale
195	f	9.4.80	m.s.	GALL BLADDER enlarged; right OV serous cyst (0.4 cm Ø); ST
		638		mucosal haemorrhage
172	f	18.4.80		SP enlarged (3.2 x 0.5 cm); UT right horn grey-white hard
		647		nodule (0.8 cm Ø); ST mucosal haemorrhage; SMALL IN red-brown
				content
180	f	12.5.80	m.s.	in genital area, round anus, also in thigh area skin inflamed,
		671		adherent; LU lob. sin. white hard area (0.4 cm Ø); SP enlarged
				(3.0 x 0.5 cm), swollen; right OV serous cyst (0.7 cm Ø)
162	f	19.5.80		SP enlarged (3.6 x 1.0 cm), swollen; LI enlarged, swollen,
		678		hard; ST mucosal haemorrhage; LY enlarged; KI, AD, UT, LU,
				BRAIN, PI pale
151	f	21.5.80	+	LU lob. sin. and lob. sup. dxtr. partly flesh coloured, lob.
		680		inf. dxtr. lat. enlarged, beige-white, hard; LI partly clay
				coloured
185	f	22.5.80	m.s.	LU lob. sin. enlarged, soft, contains greenish paste and hard
		681		beige nodule (0.7 cm Ø); right OV soft, yellow nodule (0.6 cm Ø)
190	f	24.6.80	m.s.	LU lob. inf. dxtr. lat. enlarged, hard, white, other lobes pale,
		714		pinpoint sized glassy spots

Died during study

study KWG 0519/006 **dose:** 125 ppm **findings** 132

anim. no.	sex	death/ study day	degree auto-lysis	
167	f	25.6.80	m.s.	LU lob. inf. dxtr. lat. enlarged, beige, hard, rest of LU dark
		715		red areas; left OV yellow, soft nodule (0.3 cm Ø) and a serous
				cyst (0.4 cm Ø)
184	f	25.6.80	m.s.	left REAR EXTREMITY skin inflamed, adherent; SP enlarged (2.0
		715		x 0.5 cm); left OV bloody cyst (1.4 cm Ø)
192	f	27.6.80		SP clay coloured; LI enlarged; UT neck thickened (1.2 cm Ø),
		717		hard, contains yellowish paste
181	f	4.7.80		UT neck thickened (0.8 cm Ø), hard; left OV beige hard nodule
		724		(0.6 cm Ø); left KI enlarged, dark red
157	f	4.7.80	m.s.	n.f.
		724		
199	f	15.9.79	++++	due to advanced autolysis could not be appraised, not fixed
		431		

Died during study
study KWG 0519/006 dose: 500 ppm **findings** 133 a

anim. no.	sex	death/ study day	degree auto-lysis	
225	m	18.10.78	+++	SE enlarged, partly discoloured yellowish-brown; ST mucosal
		99		haemorrhage in fundus area
222	m	18.10.78	m.s.	HYPOGASTRIUM skin inflamed; SP enlarged (2.2 x 0.6 cm); ST
		99		mucosal haemorrhage in fundus area
229	m	3.7.79		ST mucosal haemorrhage; IN bloody content
		357		
231	m	15.7.79	++++	no appraisal possible
		369		
241	m	1.8.79		LU fleshy areas; SP enlarged (4.0 x 0.7 cm), swollen; ST muco-
		386		sal haemorrhage; IN bloody content
221	m	12.8.79	+++	UR enlarged (1.2 cm Ø), contains red fluid; SP enlarged (2.7 x
		397		0.4 cm)
207	m	13.8.79	++++	adipose; otherwise no appraisal possible
		398		
249	m	20.8.79		TY hard, beige-grey nodule (1.2 x 0.7 cm)
		405		
209	m	11.10.79	++	adipose; LU partly dark red; UR enlarged (1.2 cm Ø)
		457		
248	m	25.10.79	++	adipose
		471		
227	m	5.11.79		ST in fundus area heavy mucosal haemorrhage
		482		

Confidential

Copyright by Bayer AG
the use, utilisation or distribution
is only permitted with the nsent
of Bayer AG.

Died during study
study KWG 0519/006 dose: 500 ppm **findings** 133 b

anim. no.	sex	death/ study day	degree auto-lysis	
250	m	24.11.79	+	LU flesh coloured, lob. inf. dxtr. lat. soft grey nodule
		501		(0.4 cm Ø); LI slightly swollen
216	m	26.11.79	+++	SALIVARY GLANDS enlarged (0.8 cm Ø); UR filled with red-brown
		503		fluid; SE yellowish
237	m	28.12.79		LU lob. sin. white hard nodule (0.2 cm Ø); AD pinpoint sized
		535		white spots on surface
247	m	24.1.80	++++	appraisal not possible
		562		
210	m	28.1.80		LU dark red, lob. inf. dxtr. lat. white hard nodule (1.2 cm Ø),
		566		all organs discoloured reddish
204	m	5.2.80	m.s.	apathetic; SP enlarged (3.4 x 1.0 cm), swollen; CRANIUM hardened
		574		
234	m	4.3.80	+	LU lob. sin. beige-grey hard area (0.2 cm Ø); SP reduced in
		602		size, transparent

BAYER AG

Died during study
study KWG 0519/006 **dose:** 500 ppm **findings** 134 a

anim. no.	sex	death/ study day	degree auto-lysis	
213	m	11.3.80		adipose; LU pinpoint sized red spots
		609		
211	m	1.4.80		LU flesh coloured; ABDOMEN organs discoloured reddish; LI clay
		630		coloured; SE right wing hard dark-red nodule (1.6 cm Ø); ST
				fundus area reddened; SMALL IN red-brown content
245	m	1.4.80	++	LU flesh coloured; LI distinct lobulation; SP enlarged (3.3 x
		630		0.6 cm), swollen; LY mesenterici enlarged
246	m	3.4.80		PLEURAL CAVITY 3 ml clear fluid; LU dark red; SP enlarged
		632		(2.7 x 0.8 cm), swollen; LI enlarged, gravelly surface
240	m	7.4.80	++++	no appraisal possible
		636		
238	m	9.4.80	m.s.	SP enlarged (2.9 x 0.7 cm), marbled surface
		638		
208	m	12.4.80	++	LU flesh coloured; LI portal fissure soft dark-red-brown bloody
		641		nodule (2.0 cm Ø)
243	m	28.4.80	+++	SP enlarged (3.6 x 0.5 cm), swollen
		657		
223	m	5.5.80	m.s.	left THORAX and UNDERSIDE skin inflamed, adherent; SP enlarged
		664		(2.4 x 0.5 cm), swollen; LU, BRAIN and PI pale; left KI pin-
				point sized serous cyst

Confidential
Copyright by Bayer AG
the use, utilisation or distribution
is only permitted with the consent
of Bayer AG.

Died during study
study KWG 0519/006 dose: 500 ppm **findings** 134 b

anim. no.	sex	death study day	degree auto-lysis	findings
203	m	9.5.80		LI partly clay coloured areas; ST mucosal haemorrhage; SMALL
		668		IN red-brown content
220	m	14.5.80		adipose; LU partly discoloured reddish; SP clay coloured; LI
		673		lob. sin. penetrating soft beige-brown nodule (1.5 cm Ø)
224	m	16.5.80	+	PLEURAL CAVITY 2 ml bloody fluid; LU flesh coloured; ABD.
		675		ORGANS bloody
214	m	18.5.80	+	adipose; LU focal dark red areas; LI distinct lobulation
		677		
212	m	22.5.80		LU lob. sup. dxtr. white hard area; LI enlarged, swollen;
		681		TE, EP reduced in size; ST mucosal haemorrhage; SMALL IN
				red-brown content; OY enlarged
201	m	23.5.80	m.s.	LU lob. dxtr. enlarged, hard, white; LI lob. sin. white dark
		682		red nodule (1.4 cm Ø); left KI reduced in size
235	m	29.5.80		LU lob. sup. dxtr. 2 white hard nodules (0.1 and 0.3 cm Ø);
		688		SP enlarged (2.4 x 0.5 cm); SE enlarged; LI clay coloured,
				portal fissure dark red soft nodule (3.6 x 1.8 cm); KI clay
				coloured
236	m	25.6.80	m.s.	LU partly dark red, lob. inf. dxtr. lat. white hard nodule
		715		(0.2 cm Ø); left KI pinpoint sized serous cyst
242	m	25.6.80	+	LI distinct lobulation; SP clay coloured
		715		

Confidential

Copyright by Bayer AG
the use, utilisation or distribution
is only permitted with the consent
of Bayer AG.

Died during study
study KWG 0519/006 **dose:** 500 ppm **findings** 135 a

anim. no.	sex	death/ study day	degree auto-lysis	
232	m	28.6.80	+	LU enlarged, flesh coloured, LI lob.sin. swollen, hard, dis=
		718		coloured yellowish
293	f	19.9.78	+	ST mucosal haemorrhage
		70		
274	f	23.4.79	++++	appraisal not possible
		286		
285	f	7.8.79		n.f.
		392		
287	f	18.9.79	++	LU fleshy; UT right horn thickened (0.7 cm Ø), soft; left OV
		434		soft dark nodule (0.7 cm Ø); SP enlarged (3.6 x 1.0 cm), swollen;
				LI enlarged, swollen; AD enlarged (0.2 - 0.3 cm Ø)
283	f	25.10.79	++	SP reduced in size; SMALL IN reddish content
		471		
256	f	29.10.79		LU fleshy areas; TY beige, hard nodule (1.1 cm Ø); UT horns
		475		thickened (0.3 cm Ø)
282	f	7.11.79		ear injury, pus entered and collected in maxillary sinus; SP
		484		enlarged (2.5 x 0.6 cm), dotted with grey-beige spots; ST fundus
				area reddened; KI bumpy surface partly light discoloured

Died during study
study KWG 0519/006 **dose:** 500 ppm **findings** 135 b

anim. no.	sex	death/ study day	degree auto-lysis	
262	f	9.11.79		LU lob.sin hard, pale nodule (0.5 cm Ø); SP enlarged (2.4 x
		486		0.8 cm); LI lob.sin. several light to reddish marginal spots;
				ST in fundus area mucosal haemorrhage; MESENTERIUM red nodule
				with light spots throughout (2.5 x 0.7 cm); right OV serous
				cyst (0.5 cm Ø)
280	f	22.11.79		SP enlarged (2.4 x 0.5 cm), swollen; OV enlarged, cysts (0.2
		499		cm Ø)
297	f	7.1.80	++++	appraisal not possible
		545		
251	f	8.1.80	+	LU pinpoint sized and pinhead sized dark spots; SP enlarged
		546		(3.3 x 0.8 cm), swollen; LI enlarged; ST mucosal haemorrhage;
				SMALL IN black-brown content; LY enlarged; CRANIUM hardened
278	f	10.1.80	+++	LU partly flesh coloured; SP enlarged (3.2 x 0.5 cm), swollen;
		548		ST mucosal haemorrhage; SMALL IN black-brown content; UT
				left horn thickened (0.4 cm Ø); LY mesenterici very enlarged
294	f	13.1.80	+	ST bloody content, mucosal haemorrhage; SMALL IN brown-black
		551		content 19g

BAYER AG

Died during study
study KWG 0519/006 **dose:** 500 ppm **findings** 136 a

anim. no.	sex	death/ study day	degree auto-lysis	
259	f	22.1.80	+++	SP, LI and KI very enlarged
		560		
298	f	31.1.80		PLEURAL CAVITY 3 ml milky opaque fluid; LU flesh coloured;
		569		ABDOMEN 8 ml milky opaque fluid; SP enlarged (2.2 x 0.6 cm),
				swollen; DIAPHRAGM soft beige coating
255	f	3.2.80	+	LU pale; SP enlarged (3.5 x 0.8 cm), swollen; LI enlarged;
		572		LY enlarged
269	f	5.2.80		left OV dark red hard nodule (0.8 cm Ø); ST mucosal haemorrhage;
		574		SMALL IN brown-black content; right FEMUR white hard nodule
				(0.4 cm Ø); CRANIUM hardened
292	f	26.2.80		TAIL ROOT skin inflamed; SP enlarged (2.5 x 0.5 cm)
		595		
265	f	15.3.80	++	body increased in size; LU increased fluid content; ABDOMEN
		613		filled with dark red fluid; SP swollen; FATTY TISSUE excess
				present; LI lob.sin. soft dark-brown penetrating nodule (1.4
				cm Ø), portal fissure soft dark-brown nodule (1.5 cm Ø) with
				all lobes adherent; ST fundus area mucosal haemorrhage; IN
				reddish content
265	f	15.3.80	++	left KI limp, filled with milky fluid; right KI white-grey
		613		areas on surface

anim. no.	sex	death study day	degree auto-lysis	Died during study study KWG 0519/006 dose: 500 ppm findings 136 b
252	f	20.3.80		LU lob.sin. 2 white-grey areas (0.2 cm), one central, one mar-
		618		ginal; SP enlarged (3.2 x 0.5 cm), swollen; LY mesenterici
				enlarged
290	f	24.3.80		TG beige hard nodule (1.0 cm Ø); LU lob.sin. flesh coloured,
		622		lob dxtr. pinpoint sized red spots; SP enlarged (3.5 x 1.2 cm),
				swollen; CRANIUM hardened
257	f	28.3.80		SP enlarged (2.6 x 0.6 cm), swollen; right KI white-beige areas
		626		(0.01 - 0.05 cm Ø); left AD pinpoint sized white spot; left
				FEMUR stone hard white nodule (1.0 cm Ø)
261	f	7.4.80	+	LI hardened, swollen, pussy
		636		
264	f	22.4.80	+++	LU enlarged, swollen, adhesion to diaphragm
		651		
254	f	24.4.80	++	LU lob.sup.dxtr. white hard nodule (0.4 cm Ø), lob.med.dxtr.
		653		white hard nodule (1.0 cm Ø); right FEMUR white beige nodule
				(1.1 cm Ø)
275	f	29.4.80	+	LU focal dark red areas, lob.inf.dxtr.lat. white hard nodule
		658		(0.2 cm Ø); left OV bloody cyst (1.0 cm Ø)
286	f	20.5.80		LU surrounded by blood clots; LI clay coloured; OV serous
		679		cyst, right 1.1 cm, left 0.7 cm; PI enlarged (0.3 cm Ø), pale

Confidential
Copyright by Bayer AG
the use, utilisation or distribution
is only permitted with the consent
of Bayer AG.

Died during study
study KWG 0519/006 **dose:** 500 ppm **findings** 136 c

anim. no.	sex	death/ study day	degree auto-lysis	
289	f	20.5.80		LU focal dark red areas; ABDOMEN fatty tissue discoloured
		679		yellowish, hard; SP enlarged (2.6 x 0.5 cm), swollen; LI, KI, AD,
				clay coloured; left OV serous cyst (0.6 cm Ø)
288	f	22.6.80	+	LU flesh coloured; SP enlarged (4.2 x 0.8 cm), swollen;
		712		LY enlarged

Died during study
study KWG 0519/006 **dose:** 500 ppm **findings** 137

anim. no.	sex	death/ study day	degree auto-lysis	
300	f	23.6.80	+	LU lob.sup.dxtr. enlarged, hard, white-grey-red, rest of LU
		713		dark red
260	f	1.7.80		LU flesh coloured, lob.sin white hard nodule (1.0 cm Ø); LI
		721		enlarged; OV left serous cyst (0.7 cm Ø), right serous cyst
				(0.5 cm Ø)
284	f	3.7.80		LU grey-black areas; KI clay coloured; left OV serous cyst
		723		(1.2 cm Ø)
277	f	8.7.80		LU lob.sup.dxtr. beige hard nodule (0.3 cm Ø); SP enlarged
		728		(4.5 x 1.0 cm), swollen; ST mucosal haemorrhage; LI enlarged,
				swollen; right FEMUR thickened (1.5 x 1.0 cm), white, hard;
				CRANIUM hardened

Died during study
study KWG 0519/006 **dose:** 2000 ppm **findings** 138 a

anim. no.	sex	death/ study day	degree auto-lysis	
330	m	28.12.78		ST mucosal haemorrhage; CAECUM contains bloody mass; LARGE IN
		170		bloody content; LI partly clay coloured
317	m	15.2.79	m.s.	baldness, inflamed skin from right rear extremity over right side
		219		abdomen up to rib level; right rear extremity adherent to abdomen
				skin; SP enlarged (3.3 x 0.7 cm); LI distinct emergence of
				white areas
340	m	28.5.79		SP enlarged (2.5 x 0.4 cm); LU focal increased air content
		321		
311	m	7.6.79		n.f.
		331		
321	m	15.7.79	+++	TY hard grey nodule (1.1 cm Ø); SP enlarged (3.0 x 0.6 cm)
		369		
305	m	15.7.79	++	LU dispersed, no longer present, pleura shiny green
		369		
303	m	23.7.79	m.s.	right THORAX inflamed skin; SP enlarged (2.7 x 0.6 cm);
		377		LI, LU, KI filled with blood
344	m	31.8.79		LU white piebald surface, fleshy; SP enlarged (4.2 x 1.5 cm),
		416		swollen; LI enlarged, swollen; LY enlarged
326	m	22.10.79	+++	SP enlarged (2.2 x 0.5 cm)
		468		
349	m	25.10.79		right SIDE NECK stone-hard white nodule (1.2 cm Ø); ST mucosal
		471		haemorrhage; SMALL IN bloody content

Died during study
study KWG 0519/006 **dose:** 2000 ppm **findings** 138 b

anim. no.	sex	death study day	degree auto-lysis	
341	m	17.11.79	++	right EYE badly encrusted; LU flesh coloured; ST inflated;
		494		AD dark red
325	m	3.12.79	+++	ST mucosal haemorrhage; SMALL IN brownish content
		510		
329	m	7.1.80	+++	right SIDE NECK soft, grey-black nodule (1.4 cm Ø)
		545		
346	m	28.1.80	++++	appraisal not possible
		566		
324	m	2.2.80		THORAX 3 ml bloody fluid; LU flesh coloured; TY hard beige
		571		nodule (1.2 cm Ø)
350	m	5.2.80		adipose; LU pinpoint sized red spots, lob.sin. grey hard area
		574		(0.1 cm Ø); UR enlarged (1.4 cm Ø); discoloured reddish
320	m	7.2.80		LI enlarged, swollen; ST mucosal haemorrhage; SMALL IN red-
		576		brown content

Died during study
study KWG 0519/006 **dose:** 2000 ppm **findings** 139 a

anim. no.	sex	death/ study day	degree auto-lysis	
314	m	25.2.80	++++	no appraisal possible
		594		
328	m	11.3.80		LU focal dark red areas
		609		
309	m	29.3.80	+	LU focal dark red areas; SP enlarged (2.6 x 0.6 cm), swollen;
		627		UR enlarged (1.2 cm Ø); left KI enlarged, marbled surface
323	m	9.4.80	m.s.	LU discoloured dark red; LI lob.sin. swollen, permeated with
		638		pus
304	m	9.4.80	m.s.	n.f.
		638		
302	m	10.4.80		LI swollen, in places light spots; ST mocusal haemorrhage
		639		
337	m	10.4.80		LU lob.sin. light nodule (0.2 cm Ø); ST mucosal haemorrhage
		639		
307	m	10.4.80	m.s.	SP marbled surface; KI left bumpy surface, right pale
		639		
316	m	13.4.80		LU flesh coloured; LI enlarged, swollen, soft; the other organs
		642		bloody
319	m	15.4.80		LU focal dark red areas; LI enlarged, swollen, partly beige
		644		coloured surface

Died during study
study KWG 0519/006 **dose:** 2000 ppm **findings** 139 b

anim. no.	sex	death study day	degree auto-lysis	
347	m	9.5.80		UR enlarged (2.6 x 1.3 cm); SP enlarged (2.5 x 0.7 cm), swollen
		668		
333	m	14.5.80		LU surrounded by blood clots; LI clay coloured; ST serous
		673		cyst (0.8 cm Ø)
318	m	16.5.80	++	adipose; LU focal dark red areas
		675		
339	m	23.6.80	++	LU lob.sin. white hard spot (0.1 cm Ø)
		713		
313	m	30.6.80		LU enlarged, lob.inf.dxtr. lat. enlarged, white, hard; LI en-
		720		larged; SP marbled surface
301	m	7.7.80	died after blood taken	SP enlarged (3.6 x 0.9 cm), swollen; KI enlarged, soft, beige
		727		with scattered red areas; LY enlarged

BAYER AG

Died during study
study KWG 0519/006 **dose:** 2000 ppm **findings** 140 a

anim. no.	sex	death/ study day	degree auto-lysis	
352	f	15.4.79		LU fleshy; TY beige hard nodule (1.5 cm Ø)
		278		
397	f	1.7.79	+	LU dark red; LI swollen (3.5 cm Ø); ST multiple mucosal hae-
		355		morrhage with foci; SP very enlarged (4.6 x 1.5 cm, weight 2.4g)
393	f	15.7.79		ST mucosal haemorrhage, bloody content; IN bloody content
		369		
371	f	20.7.79		TY beige soft nodule (0.6 cm Ø); LU fleshy
		374		
392	f	10.8.79		ST mucosal haemorrhage; IN bloody content
		395		
364	f	19.11.79	++	PLEURAL CAVITY full dark brown fluid; LU dark brown-red
		496		
361	f	20.11.79	+	PLEURAL CAVITY filled with milky opaque fluid; LU dark red;
		497		LI, ST, IN, KI and AD adherent with a hard yellowish nodule;
				OV enlarged (0.3 cm Ø)
376	f	24.11.79	+	PLEURAL AREA 0.5 ml reddish clear fluid; LU flesh coloured;
		501		LI lob.dxtr. access at bottom edge a soft nodule (1.2 cm Ø),
				partly spongy structure, lob.sin. visceral side soft thickening
				(0.4 cm Ø), diaphragm side grey-brown slight thickening (0.25 cm Ø);
				UT swollen; OV enlarged (0.5 cm Ø)

Confidential
Copyright by Bayer AG
the use, utilisation or distribution
is only permitted with the consent
of Bayer AG.

Died during study
study KWG 0519/006 **dose:** 2000 ppm **findings** 140 b

anim. no.	sex	death/ study day	degree auto-lysis	
369	f	25.11.79	+++	LU flesh coloured; TY soft greyish thickening (0.6 cm Ø); SP
		502		enlarged (3.4 x 1.0 cm), slight nodular structure; ST brown-red
				slimy content; LI slightly swollen; UT horns slightly swollen;
				OV enlarged left 0.6 cm Ø, right 0.3 cm Ø; AD enlarged, left
				0.3cm Ø, right 0.2 cm Ø
353	f	10.12.79		LU pale, focal dark red areas; SP very enlarged (4.7 x 1.2 cm),
		517		swollen; LI enlarged, serous cysts scattered on surface; ST mu-
				cosal haemorrhage; CRANIUM hardened; FOREHEAD subcutaneous
				haemorrhage
363	f	29.12.79		LU flesh coloured; TY hard beige nodule (1.2 cm Ø); SP enlarged
		536		(3.8 x 0.6 cm), swollen; LI in places clay coloured areas
370	f	30.12.79		LU discoloured brownish, oily shiny surface; SP enlarged (5.1
		537		x 1.3 cm), swollen; LI enlarged; ST mucosal haemorrhage
390	f	16.1.80		SP enlarged (4.6 x 1.2 cm), swollen, soft, scattered yellow and
		554		beige areas with foci; LI enlarged, swollen; ST mucosal haemorrh-
				age; SMALL IN reddish content; UT corpus enlarged (1.1 cm Ø),
				hard; right FEMUR white, stone-hard nodule (0.5 cm Ø); CRANIUM
				hardened
372	f	29.1.80		LU focal dark red areas; left KI pale, soft, filled with clear
		567		liquid

Died during study
study KWG 0519/006 dose: 2000 ppm **findings** 141 a

anim. no.	sex	death/ study day	degree auto-lysis	
382	f	22.2.80		LU except lob.inf.dxtr.lat. flesh coloured; TY beige hard
		591		nodule (1.3 cm Ø); SP enlarged (2.8 x 0.5 cm), swollen; UT
				horns thickened (0.3 cm Ø)
374	f	3.3.80		right REAR EXTREMITY 2 white stone-hard nodules (0.3 cm Ø);
		601		LU lob.dxtr. dotted with pinpoint sized red spots; ABDOMEN
				level with KI at spine a white hard nodule (0.8 cm Ø); SP en-
				larged (3.2 x 0.5 cm), swollen; LI enlarged; CRANIUM hardened
385	f	14.3.80		LU focal dark red areas; SP enlarged (3.6 x 0.8 cm), swollen
		612		
395	f	20.3.80	+	LU sand coloured; LI enlarged, swollen, black-white spots;
		618		SP enlarged (2.4 x 0.6 cm), swollen; UT neck thickened, hard
				(1.5 cm Ø), right horn thickened (0.4 cm Ø)
356	f	26.3.80	m.s.	TAIL knocked off, area round tail root - skin inflamed; LU focal
		624		dark red areas; SP enlarged (2.2 x 0.7 cm), swollen; LI enlarg-
				ed, swollen
386	f	29.3.80		n.f.
		627		
387	f	11.4.80		GALL BLADDER enlarged (0.5 cm Ø); ST mucosal haemorrhage;
		640		KI marbled surface
396	f	23.4.80	m.s.	EYE ENVIRONS inflamed; LU focal dark red areas; LI enlarged;
		652		SP enlarged (2.5 x 0.6 cm), swollen; right KI at hilus soft

(cont.)

Died during study
study KWG 0519/006 **dose:** 2000 ppm **findings** 141 b

anim. no.	sex	death/ study day	degree auto-lysis	
396	f	23.4.80	(cont.)	beige area from both sides (0.7 cm Ø)
358	f	10.5.80	+	LU surrounded by blood clots; LI clay coloured
		669		
394	f	23.5.80	m.s.	LU focal dark red areas; SP enlarged (4.6 x 1.1 cm), swollen;
		682		LI enlarged; UT horns thickened, right 0.6 cm Ø containing
				serous fluid, left 1.5 cm Ø, hard, containing yellowish paste;
				right KI white-beige areas (up to 0.4 cm Ø)
381	f	16.6.80		LU flesh coloured; SP enlarged (2.2 x 0.7 cm); LI enlarged,
		706		swollen, permeated with soft dark brown nodules (up to 1.2 cm Ø);
				LY enlarged; FATTY TISSUE enriched
366	f	22.6.80	+	LU flesh coloured, dark red; SP enlarged (3.1 x 0.9 cm), swol-
		712		len; KI dotted with dark red spots; LY enlarged; ST mucosal
				haemorrhage
373	f	24.6.80	m.s.	left FEMUR thickened (1.2 cm Ø), containing greyish gelatinous
		714		mass
365	f	1.7.80		LI lob.dxtr. hard dark brown penetrating nodule (1.4 cm Ø); SP
		721		enlarged (2.7 x 0.7 cm Ø), swollen; OV right bloody cyst
				(1.4 cm Ø), left hard nodule (0.6 cm Ø)
362	f	10.7.80		SP enlarged (3.1 x 0.8 cm), swollen, pale; ST mucosal haemorrh-
		730		age; KI, AD clay coloured; CRANIUM hardened
380	f	14.7.80	+	LU flesh coloured; SP enlarged (4.2 x 1.0 cm), swollen; LI en-
		734		larged, discoloured yellow-black; LY enlarged

Died during study
study KWG 0519/006 **dose:** 2000 ppm **findings** 142

anim. no.	sex	death/ study day	degree auto-lysis	
355	f	3.11.79 480	++++	advanced autolysis, no appraisal possible, nothing fixed

Sacrificed end study
study KWG 0519/006 dose: 0 ppm **findings** 143 a

anim. no.	sex	death/ study day	degree auto-lysis	
5	m	14.7.80		LU lob.sin. beige spots (1 mm Ø); KI covered with blisters
				(1-2 mm Ø)
13	m	14.7.80		SE enlarged (5.0 cm Ø)
16	m	14.7.80		LI lob.sin. 1 cm Ø thickening, lob.caud. thickened, swollen
				(2 cm x 1 cm); KI clay coloured, dotted with cysts (0.1 - 0.7 cm);
				LU lob.sin. white hard area (0.3 cm Ø); HEART atrium thickened
19	m	14.7.80		KI scattered cysts (0.1 - 0.3 cm Ø)
22	m	14.7.80		LU lob.sin. pinpoint sized cysts; left KI cyst (0.2 cm Ø)
24	m	14.7.80		PA hardened; LU lob.inf.dxtr.lat. white thickening (0.5 x 0.3
				cm Ø); KI scattered cysts (0.1 - 0.2 cm Ø)
26	m	14.7.80		left KI flattened, scattered pinpoint sized serous cysts
31	m	14.7.80		LI clay coloured; right AD enlarged (0.3 cm Ø); PERIRENAL left
				soft yellowish nodule in fatty tissue (0.3 cm Ø)
33	m	14.7.80		SP beige coloured hardening (0.4 cm Ø); LI proc.pap. clumped
				and adherent, beige coloured, soft; KI bumpy surface
35	m	14.7.80		PA thickened; LU lob.sin. light beige thickening (0.2 cm Ø),
				several dark red spots (0.1 - 0.2 cm Ø); SP reduced in size
				(1.2 x 0.2 cm)
40	m	14.7.80		LU lob.med.dxtr. beige thickening (0.2 cm Ø); KI scattered
				cysts (0.1 cm Ø); SP reduced in size (1.4 x 0.2 cm)

Confidential
Copyright by Bayer AG
the use, utilisation or distribution
is only permitted with the consent
of Bayer AG.

Sacrificed end study
study KWG 0519/006 dose: 0 ppm **findings** 143 b

anim. no.	sex	death/ study day	degree auto-lysis	
27	m	14.7.80		LU lob. sin. nodule (25 mm Ø); LI proc.pap. clay coloured, clumped and adherent (5 mm Ø)
51	f	15.7.80		n.f.
52	f	15.7.80		KI white nodule (on right 0.3 cm, on left 0.5 cm Ø); LU lob. inf.dxtr.lat. white nodule; SP enlarged (0.2 x 7 cm)
55	f	15.7.80		OV serous cyst (right 0.5 cm Ø, left 0.3 cm Ø); LU lob.sin. white patches (0.2 - 0.3 cm Ø)
57	f	15.7.80		left OV serous cyst (1.0 cm Ø); right GROIN white hard nodule (1.0 cm Ø); LU lob.inf.dxtr.lat. yellow hard nodule (0.3 cm Ø)
66	f	15.7.80		LU lob.sin. white spots (0.1 - 0.2 cm Ø)
74	f	15.7.80		right OV cyst (0.3 cm Ø) filled with bloody fluid; KI right white-beige nodule (0.4 - 0.5 cm Ø)

Sacrificed end study
study KWG 0519/006 **dose:** 0 ppm **findings** 144

anim. no.	sex	death study day	degree auto-lysis	
76	f	15.7.80		PI enlarged (0.2 x 0.4 cm), bloody
78	f	15.7.80		PA hardened; LU scattered beige patches (0.1 - 0.3 cm)
81	f	15.7.80		OV thickened, on left UT horn soft bloody nodule (0.3 cm Ø);
				lob.sin white hard nodule (0.2 cm Ø), lob.sup.dxtr. yellow
				hard nodule (0.3 cm Ø), lob.inf.dxtr.lat. yellow soft nodule
				(0.1 cm Ø)
82	f	15.7.80		PA hardened; LU scattered pinpoint sized black patches;
				OV in each a serous cyst (0.3 cm Ø)
83	f	15.7.80		OV enlarged, right 1.0 cm Ø filled with clear fluid, left 1.0
				cm Ø filled with bloody gelatinous mass
84	f	15.7.80		SP enlarged (2.6 x 0.7 cm); LI clay coloured; left OV enlarg-
				ed (5.0 cm Ø), filled with bloody fluid and gelatinous mass;
				KI clay coloured; BRAIN and PI pale
89	f	15.7.80		SP enlarged (2.3 x 0.7 cm); LU lob.inf.dxtr.lat. beige nodule
				(0.7 cm Ø), lob.sin. dark red spot (0.4 cm Ø)
92	f	15.7.80		OV serous cyst (right 1.1 cm Ø, left 0.8 cm Ø); LU scattered
				white-beige patches (0.2 - 0.3 cm Ø)
96	f	15.7.80		OV right filled with liquid, left enlarged, filled with yellow
				hard mass (0.8 cm Ø)
100	f	15.7.80		OV serous cyst (0.3 cm Ø)

Sacrificed end study **study KWG 0519/006** **dose:** 125 ppm **findings** 145 a

anim. no.	sex	death/ study day	degree auto-lysis	
107	m	14.7.80		PA light, hardened; LU lob.sin. dark beige patches (0.1 -0.2 cm
				Ø), lob.med.dxtr. enlarged (1.5 x 0.4 cm), light beige, hardened,
				lob.inf.dxtr.med. flesh coloured; KI scattered cysts (0.1 cm Ø)
110	m	14.7.80		KI bumpy surface, on left scattered dark cysts (0.15 cm - 0.2
				cm Ø); LI proc.pap. clumped and adherent (1.4 x 0.9 cm Ø), soft,
				partly beige
117	m	14.7.80		LU lob.sin. dark red patch (0.2 cm Ø); right AD beige spotted
119	m	14.7.80		UR enlarged (1.8 x 2.0 cm); SP swollen (3.0 cm Ø); LI enlarg-
				ed, swollen, marbled surface; LU hard spots, thickening (0.2 cm
				Ø)
123	m	14.7.80		LI lob.sin. beige hardening (0.7 x 0.6 cm Ø); LU lob.sup.dxtr.
				beige thickening, hardened (0.3 cm Ø)
127	m	14.7.80		KI cysts (0.1 - 0.2 cm)
128	m	14.7.80		LU lob.med.dxtr. swollen, hardened; KI scattered pinpoint sized
				cysts
141	m	14.7.80		LU lob.sin. pale, thickened (0.5 cm Ø); LI proc.papillaris
				beige, soft, enlarged (1.7 cm Ø), clumpy and adherent
142	m	14.7.80		PA cyst (0.7 x 0.3 cm Ø); LI lob.sin. swollen, lob.caud. pink
				with hardened areas
148	m	14.7.80		LU pale; SP enlarged (2.7 x 0.9 cm); left TE reduced in size;
				KI bumpy surfaces, scattered cysts (0.1 - 0.2 cm Ø); SE en-
				larged, filled with yellowish slimy mass

Sacrificed end study
study KWG 0519/006 **dose:** 125 ppm **findings** 145 b

anim. no.	sex	death study day	degree auto-lysis	findings
149	m	14.7.80		PI enlarged; KI several cysts (0.1 - 0.2 cm); LU lob.sin. brown light-beige hardening (0.7 cm Ø); SP reduced in size (0.3 x 1.2 cm); LI lob.sin, lob.sin. access. enlarged, hardened, adherent, lob.dxtr.access. light-beige thickening (0.6 x 1.1 cm)
158	f	15.7.80		LU lob.sin. white hard nodule (0.5 cm Ø)
161	f	15.7.80		OV a serous cyst in each (0.3 cm Ø)
163	f	15.7.80		LU lob.inf.dxtr.med. enlarged, hardened, swollen, lob.sin. beige area (0.3 cm Ø); UT both horns thickened (0.8 cm Ø), on right horn serous cyst (1.0 cm Ø)
164	f	15.7.80		UT horns thickened (0.6 cm Ø); LU several patches (0.2 - 0.3 cm Ø)
168	f	15.7.80		OV filled with clear fluid, on left cyst (0.2 cm Ø)

Sacrificed end study
study KWG 0519/006 **dose:** 125 ppm **findings** 146

anim. no.	sex	death/ study day	degree auto-lysis	
170	f	15.7.80		UT horns several cysts filled with gelatinous colourless mass
171	f	15.7.80		SP enlarged (4.4 x 2.1 cm); LU lob.sin. beige patch (0.1 cm Ø);
				LI enlarged, bumpy surface; CRANIUM hardened
177	f	15.7.80		LU lob.sin. adherent, penetrating white nodule (1.2 cm Ø), lob.
				dxtr. flesh coloured; OV filled with clear fluid
178	f	15.7.80		n.f.
179	f	15.7.80		OV left cyst (1.5 x 1.8 cm), filled with brown fluid, right cyst
				(1.3 x 1.1 cm), filled with serous liquid
186	f	15.7.80		SP enlarged (1.0 x 3.5 cm); UT horns enlarged (0.5 cm Ø); both
				AD enlarged (0.3 cm Ø)
188	f	15.7.80		LU dotted with white hard areas (0.2 - 0.3 cm); PA serous cyst
				(0.2 cm Ø); OV left serous cyst (0.3 cm Ø), right 2 cysts (0.2
				cm Ø)
194	f	15.7.80		UT right horn top part thickened (0.8 cm Ø), filled with dark
				red gelatinous fluid; OV right serous cyst (1.1 cm Ø)
196	f	15.7.80		LI swollen; right GROIN thickened (2.0 cm Ø), hard, grey, beige
				SP enlarged (0.5 x 2.0 cm); UT horns enlarged (0.4 cm Ø), on
				left near ova thickening (0.8 cm Ø) filled with hard mass
197	f	15.7.80		UT several cysts (0.2 - 0.4 cm), filled with gelatinous clear
				mass; OV left enlarged, hard (0.7 cm Ø)
198	f	15.7.80		LI lob.sin. pinpoint sized spots; SP enlarged (3.6 x 1.0 cm);
				UT right horn hardening in top section (1.0 cm Ø); LI pale, clay coloured

Sacrificed end study
study KWG 0519/006 **dose:** 500 ppm **findings** 147 a

anim. no.	sex	death study day	degree auto-lysis	
202	m	14.7.80		LI lob.dxtr. access. beige nodule (1.5 x 1.3 cm), lob.caud.
				serous cyst (0.3 cm Ø)
205	m	14.7.80		n.f.
206	m	14.7.80		IN mesentery clumped and adherent, hard (6 x 1.5 cm); BRAIN and
				PI pale; HEART beige-grey hard adhesion (1 cm Ø); PA clumped
				and adherent, pale (1.3 cm Ø); SP pale, partly nodular hard
				areas (up to 0.3 cm Ø); KI pale, left perirenal fatty tissue
				clumped, hardened, yellowish
215	m	14.7.80		SE enlarged (3 cm Ø); LI lob.dxtr. access. swollen, thickened,
				hardened
217	m	14.7.80		LU lob.sin. beige cyst (0.2 cm Ø)
218	m	14.7.80		LI lob.sin. and lob.dxtr.access. adherent, swollen, thickened;
				LU lob.sin. enlarged, large beige nodule (1.2 x 0.9 cm)
219	m	14.7.80		LI lob.dxtr.access. thickening (0.8 cm); right KI several
				cysts (0.1 cm Ø), left KI bumpy surface
226	m	14.7.80		LI lob.sin. clumped and adherent, soft edge (1.4 cm Ø); LU
				lob.sin. flesh coloured with pinpoint sized red spots; PI pale
228	m	14.7.80		n.f.
230	m	14.7.80		PA hardened; KI several cysts (0.1 - 0.2 cm); right AD enlarged
233	m	14.7.80		n.f.
239	m	14.7.80		PA hardened

Sacrificed end study
study KWG 0519/006 **dose:** 500 ppm **findings** 147 b

anim. no.	sex	death/ study day	degree auto-lysis	
244	m	14.7.80		LU lob.sin. beige spots (0.2 cm Ø); left KI cyst (0.2 cm Ø);
				left EP dark
253	f	15.7.80		left OV filled with serous fluid; UT horns enlarged, thickened
				(0.5 cm Ø)
258	f	15.7.80		right KI 2 cysts (0.2 cm Ø)
263	f	15.7.80		UT horns enlarged (0.5 cm Ø); right OV glassy cyst (0.4 cm Ø);
				LU flesh coloured

Confidential

Copyright by Bayer AG
the use, utilisation or distribution
is only permitted with the consent
of Bayer AG.

Sacrificed end study
study KWG 0519/006 **dose:** 500 ppm **findings** 148

anim. no.	sex	death study day	degree auto-lysis	
266	f	15.7.80		LY enlarged; LI lob.dxtr. 2 soft brown nodules; SP enlarged
				(1.0 x 3.0 cm)
267	f	15.7.80		LI reduced in size, area round portal fissure greenish, yellow
268	f	15.7.80		right OV serous cyst (1.8 cm Ø)
270	f	15.7.80		LU lob.sin. thickening (0.3 cm Ø); UT horns thickened (0.6 cm Ø)
271	f	15.7.80		LI clay coloured; LU flesh coloured; right AD enlarged
				(0.2 cm Ø); UT enlarged (0.4 cm Ø); right OV enlarged (0.5 cm)
272	f	15.7.80		left OV clear cyst (0.3 cm Ø); UT horn bottom part 2 thickenings;
				hardened
273	f	15.7.80		UT horns both thickened (0.5 cm Ø) with several serous cysts
				(0.5 - 0.7 cm Ø)
276	f	15.7.80		UT horns thickened (0.5 cm Ø)
279	f	15.7.80		LU lob.dxtr. enlarged, swollen, hardened, beige coloured
281	f	15.7.80		LU flesh coloured; UT enlarged (0.4 cm Ø)
291	f	15.7.80		SP enlarged (2.2 x 0.8 cm), white-grey areas (0.7 cm Ø),
				swollen; right OV 2 serous cysts (0.6 cm, 0.3 cm Ø); LY enlarged
295	f	15.7.80		left OV cyst (0.5 cm) filled with red fluid
296	f	15.7.80		LU lob.dxtr. thickening (0.8 cm Ø); left OV filled with yellow
				fluid (1.0 cm Ø), cyst (0.4 cm Ø); UT horns thickened (0.5 cm Ø)
299	f	15.7.80		LU flesh coloured; UT enlarged (0.4 cm Ø)

Sacrificed end study
study KWG 0519/006 **dose:** 2000 ppm **findings** 149 a

anim. no.	sex	death/ study day	degree auto-lysis	
306	m	14.7.80		KI bumpy surfaces; LI lob.dxtr. beige-brown nodule with nodular
				structure; LU lob.sup.dxtr. white hard nodule (0.5 x 0.4 cm)
308	m	14.7.80		KI several cysts (0.1 - 0.3 cm); LU several white patches
				(0.2 - 0.3 cm); LI proc.pap. swollen, enlarged, lob.caud.
				thickened, white patches
310	m	14.7.80		PA hardened; LU lob.sup.dxtr. white nodule (0.3 cm Ø); LI
				swollen, enlarged, hardened
312	m	14.7.80		KI bumpy surface
315	m	14.7.80		KI several serous cysts (0.1 cm - 0.2 cm), bumpy surface;
				LI lob.dxtr. enlarged, swollen, nodular structure
322	m	14.7.80		SE enlarged (4 x 2cm); left KI several cysts (0.1 cm Ø); LU
				red patches
327	m	14.7.80		n.f.
331	m	14.7.80		KI bumpy surface; LI lob.dxtr.access. enlarged, swollen,
				nodular structure
332	m	14.7.80		LI proc.papillaris serous cyst (3 x 2.3 cm); LU lob.sin.
				white nodule (0.3 cm Ø)
334	m	14.7.80		right KI several cysts (1.0 cm Ø); PA hardened; LI lob.caud.
				cyst (0.3 cm Ø)
335	m	14.7.80		PA hardened; KI bumpy surface; HEART atrium enlarged;
				LU lob.inf.dxtr.lat. flesh coloured

Sacrificed end study
study KWG 0519/006 **dose:** 2000 ppm **findings** 149 b

anim. no.	sex	death study day	degree auto-lysis	
336	m	14.7.80		KI left bumpy surface, right cyst (0.1 cm Ø), slightly swollen;
				LU lob.sup.dxtr. white nodule (0.6 cm Ø)
338	m	14.7.80		PA hardened; LI swollen, enlarged, lob.sin. nodular
342	m	14.7.80		LI lob.sin. marbled nodule (1.0 x 0.7 cm), lob.caud. enlarged
				(1.5 x 1.2 cm), nodular structure
343	m	14.7.80		LI lob.dxtr. nodular structure, enlarged (2.0 cm Ø)
345	m	14.7.80		LI hardened, red spots, lob.sin. and lob.sin.access. several
				nodules (0.2 - 1.2 cm Ø)
348	m	14.7.80		n.f.

Sacrificed end study
study KWG 0519/006 **dose:** 2000 ppm **findings** 150 a

anim. no.	sex	death/ study day	degree auto-lysis	
351	f	15.7.80		LI proc.pap. swollen, enlarged; OV right cyst (0.1 cm Ø)
354	f	15.7.80		right OV serous cyst (0.3 cm Ø)
357	f	15.7.80		left OV glassy cyst (0.3 cm Ø) with focal haemorrhage, hard
				beige thickening (0.4 cm Ø); LU flesh coloured; SP enlarged
				(0.6 x 2.5 cm); UT enlarged, right horn 0.8 cm Ø, left horn
				0.4 cm Ø
359	f	15.7.80		LU in places flesh coloured; UT thickened (0.4 cm Ø)
360	f	15.7.80		UT left horn thickening (1.0 cm Ø) filled with gelatinous
				beige mass; OV serous cysts (1.0 cm Ø)
367	f	15.7.80		SP enlarged (2.2 x 0.7 cm); LI enlarged, swollen with many
				nodules, lobes adherent
368	f	15.7.80		SP enlarged (0.4 x 1.8 cm); LU flesh coloured; right OV enlarg-
				ed, with glassy cyst (0.3 cm Ø) and serous cyst (0.3 cm Ø);
				UT enlarged (0.4 cm Ø)
375	f	15.7.80		LI enlarged, swollen, with many nodules, partly yellowish and
				beige; SP enlarged (2.0 x 0.7 cm)
377	f	15.7.80		LI lob.sin. with brown beige nodules (0.6 cm Ø); right OV
				serous cyst (0.5 cm Ø)
378	f	15.7.80		UT horns thickened (0.4 cm Ø); LU lob.sin. grey area (0.2 cm Ø),
				lob.inf.dxtr.med. white hard nodule (0.4 cm Ø)

Sacrificed end study
study KWG 0519/006 **dose:** 2000 ppm **findings** 150 b

anim. no.	sex	death/ study day	degree auto-lysis	findings
379	f	15.7.80		LU 2 whitish thickenings (0.3 cm Ø); right OV enlarged, contains clear fluid; UT left horn cyst (0.1 cm Ø)
383	f	15.7.80		right UT horn serous cyst (0.3 cm Ø); LU lob.dxtr. several dark red areas (0.1 - 0.3 cm Ø), a hard area (0.4 cm Ø)
384	f	15.7.80		right OV serous cyst (0.5 cm Ø), right horn swollen (1.0 x 0.8 cm Ø); LU lob.sin. 2 white hard nodules (0.2 cm, 0.1 cm Ø)
388	f	15.7.80		UT horns thickened (0.4 cm Ø), left horn serous cyst (0.3 cm Ø); left OV serous cyst (0.4 cm Ø); SP enlarged (2.4 x 0.6 cm)
389	f	15.7.80		LI nodular adhesions; OV right serous cyst (0.3 cm Ø)
391	f	15.7.80		PA hardened; UT enlarged (0.4 cm Ø); LU scattered beige patches (0.2 cm Ø)
398	f	15.7.80		UT several cysts (0.1 cm Ø)

BAYER AG

Sacrificed end study
study KWG 0519/006 dose: 2000 ppm **findings** 151

anim. no.	sex	death/ study day	degree auto-lysis	
399	f	15.7.80		LU lob.sin. grey thickening (0.2 cm Ø); UT enlarged (0.4 cm Ø); left OV glassy cyst (0.3 cm Ø)
400	f	15.7.80		LI lob.sin. nodular adhesions, clay coloured, proc.pap. glassy cyst (0.3 cm Ø), lob.caud. glassy cyst (0.2 cm Ø); LU flesh coloured; UT enlarged, nodular, several cysts (0.5 cm Ø)

Confidential

Copyright by Bayer AG
the use, utilisation or distribution
is only permitted with the consent

247

"Contains NO CBI"

PAGE NO(S) _____

ADDITIONS OR CORRECTIONS

FOR NUMBERED REPORTS

BEST COPY AVAILABLE

REPORT NUMBER (82291) HAS BEEN:

_X_ REVISED _____ PROOFED _____

_✓_ ADDENDUM ADDED _____ PROOFED _____

___ VOIDED (SAME AS: _____)

REASON FOR REVISION: _____

REASON FOR ADDING ADDENDUM: Addition of Pathology : Histopathology

OTHER: _____

FROM: S. N. Ryan

DATE: 10-18-88

RF #F-37 (2-20-87)
Supersedes: (8-23-77)

"Contains NO CBI"

Study Title

KWG 0519 (TRIADIMENOL)

CHRONIC TOXICOLOGICAL STUDY ON MICE

(FEEDING EXPERIMENT OVER TWO YEARS)

1508

Data Requirement

EPA Guideline 83-1

Author

Dr. E. Bomhard

Dr. E. Loser

Study Completion Date

April 29, 1982

Performing Laboratory

BAYER AG
Institute of Toxicology
Friedrich-Ebert-Strasse 217-333
D-5600 Wuppertal 1
Federal Republic of Germany

Report No. 10855A

Addendum to Report No. 10855

Laboratory Project ID

Report No. 82291

INFORMATION RESOURCES

GOOD LABORATORY PRACTICE STATEMENT

This study was not done in compliance with the Good Laboratory Practice requirements for 40 CFR Part 160. This study was performed previous to Good Laboratory Practice requirements.

SUBMITTER

MOBAY CORPORATION

Dr. J.H. Thyssen J. H. Thyssen

Director Corporate Toxicology

Date 10-17-88

SPONSOR

AGRICULTURAL CHEMICALS DIVISION

Dr. J.H. Thyssen J. H. Thyssen

Director Corporate Toxicology

Date 10-17-88

STUDY DIRECTOR

Signature for the Study Dir. J. H. Thyssen

Date 10-17-88

003

KWG 0519 - MOUSE CHRONIC TOXICITY STUDY
PATHOLOGY REPORT

1st June 1988

Bayer AG
Institut fur Toxikologie
Friedrich-Ebert-Strasse 217-233
5600 WUPPERTAL 1
West Germany

AUTHENTICATION

We the undersigned, hereby declare that the pathology data translated and reported herein provide a correct and faithful record or the original data as supplied by Bayer AG, West Germany.

A. M. Barth

Anne Barth (Translation)
CEd

1. June 1988
Date

CANTAB Group
Hinchingbrook Hospital
Huntingdon
CAMBS PE18 8NT
England

Paul N. Brooks (Computerisation)
BSc MIBiol CBiol

1. Juni 1988.
Date

Cherry Garden Cottage
Great Sampford
SAFFRON WALDEN
Essex CB10 2NX
England

KWG 0519 - Mouse Chronic Toxicity Study
Histopathology Report

METHODS

Macroscopic and microscopic pathology data were provided from the above study for the purpose of translation from German into English with computerised report production.

200 male and 200 female mice were employed in a chronic toxicity study using the test material KWG 0519, which was administered by admixture with the diet at dose levels of 0ppm, 125ppm, 500ppm and 2500ppm. The distribution of animals within the four groups was as follows:

Dose Group	Dose Level KWG 0519	Male Mice	Female Mice
01	0ppm	1-50	51-100
02	125ppm	101-150	151-200
03	500ppm	201-250	251-300
04	2500ppm	301-350	351-400

Data were provided for the following routinely evaluated tissues:

Adrenal/1
Adrenal/2
Bone (femur)
Bone marrow (femur)
Brain
Heart
Kidney/1
Kidney/2
Liver
Lung
Ovary/1
Ovary/2
Pancreas
Pituitary
Sciatic nerve
Skeletal muscle
Spleen
Stomach
Testis/1
Testis/2
Thyroid/1
Thyroid/2
Urinary bladder

Information was included concerning masses and grossly abnormal tissues sampled and processed in addition to the above.

Where no comment is made for an organ, no abnormality was detected

COMMENTS ON UPGRADE:

General comments

1. Several macroscopic observations did not have a corresponding microscopic comment. A statement to the effect that no abnormality was observed could not be included against the relevant tissues in the upgrade because there was no indication as to whether or not they had been taken at necropsy or examined microscopically.

2. There was an appreciable amount of unnecessary repetition of lesion description. This was left out of the upgraded report.

3. In some instances, essentially the same lesion was reported by the original pathologists in different ways. The upgraded report follows this exactly since to do otherwise would mean changing the original pathology report terminology which should only be done by the original pathologist.

4. Lesions were frequently assigned grades of minimal, moderate or severe, or were simply reported as present. Here again, the upgraded report follows lesion grading exactly as given in the original report, since the grading of previously ungraded lesions could not be undertaken without appraisal of the slides concerned. The upgraded report uses the grading system PRESENT (meaning that no grade was given), MINIMAL, MODERATE or MARKED and the incidence of lesions is summarised accordingly.

5. In contrast to point 4, some lesions are double graded ie. for severity (eg. minimal) and for distribution (eg. focal). This makes summarising overall severity of lesions impossible and the upgraded report refers only to severity grades without reference to distribution.

6. For bilateral organs, sometimes a condition would be recorded as unilateral or bilateral and on other occasions this was not specified. The upgraded report assumes that, when there is no mention of lateral distribution, the lesions reported occur in both of paired organs.

Specific comments

1. There are two animals with the number 181 and animal number 188 is missing from the original report. Following the examination of macroscopic against microscopic data it was assumed that mouse ref 1745/80 was mouse number 181 and that mouse ref 1517/80 was mouse number 188.

2.'Stem cell lymphoma' was regarded as 'malignant lymphoma' for the purposes of the upgraded report.

3. Lung 'peritonitis' was changes to 'pleuritis' during upgrading.

4. The macroscopic data were computerised and inevitably the output is not identical to the original text. However, it is very close to the original with the exception that 'swollen' has largely been left out where it occurs with 'enlarged' since they mean essentially the same thing.

Paul N. Brooks

BEST COPY AVAILABLE

Macroscopic and microscopic findings were provided in textual form and in the first instance all observations were translated from German into English. Histopathology data were then coded and entered into the ROELEE84 pathology computerisation system. All organs routinely sampled according to the study protocol were regarded as 'Protocol Organs' and those tissues sampled because of the presence of a gross lesion were regarded as 'Non-Protocol Organs'. Non-protocol organs were not sampled from all animals.

A list of specified conditions routinely evaluated for protocol organs and a list of the grading systems used is given below. Conditions observed only occasionally are recorded as comments.

Macroscopic data were similarly coded and computerised, but due to restrictions placed upon the coding and entry of such varied textual data the output is in some cases not entirely the same as the original. However, care has been taken to ensure that the original meaning is unchanged.

The results are divided into five sections detailing:

1. Non-neoplastic lesions - males
2. Non-neoplastic lesions - females
3. Neoplastic lesions - males
4. Neoplastic lesions - females
5. Individual animal pathological findings

RMG E31F - Mouse Chronic Toxicity Study
Histopathology Report

The following specific conditions have been routinely evaluated:

Adrenal	Adrenal tumour	graded
	Calcification	graded
	Pigment	graded
	Pigmentation	graded
	Amyloid	graded
	Hyperplastic nodule	graded
	Haemorrhagic cyst	graded
	Hyperplasia glomerulosa	graded
	Fat vacuoles	graded
	Haematopoiesis	graded
	Congestion	graded
	Hypertrophy	graded
Bone marrow (femur)	Inflammation chronic	graded
	Haematopoiesis	graded
	Hypoplasia	graded
Brain	Calcification.	graded
	Fat vacuoles	graded
	Gliosis	graded
	Haemorrhage	graded
	Hydrocephalus	graded
	Congestion	graded
	Vacuolisation	graded
	Meningitis	graded
	Oedema	graded
	Ventricular dilatation	graded

BEST COPY AVAILABLE

KWG 0519 - Mouse Chronic Toxicity Study
Histopathology Report

Heart	Thrombosis	graded 1
	Fat vacuoles	graded 1
	Fibrosis	graded 1
	Inflammation chronic	graded 1
	Haemorrhage	graded 1
	Mononuclear cells	graded 1
	Leukocytosis	graded 1
	Congestion	graded 1
	Dilated chamber	graded 1
	Periarteritis	graded 1
	ventricular dilatation	graded 1
	Degeneration muscular	graded 1
	Pericarditis	graded 1
	Thickening endocardium	graded 1
	Calcification	graded 1
	Hypertrophy	graded 1
Kidney	Calcification	graded 1
	Necrosis	graded 1
	Fibrosis	graded 1
	Myelitis	graded 1
	Hydronephrosis	graded 1
	Haemorrhage	graded 1
	Amyloid	graded 1
	Congestion	graded 1
	Tubulopathy	graded 1
	Interstitial nephritis	graded 1
	Cysts	graded 1
	Pyelonephritis	graded 1
	Ectasia vascular	graded 1
	Dilatation glomerular loops	graded 1
	Dilatation renal pelvis	graded 1
	Progressive nephropathy	graded 1
	Pyelitis	graded 1

BEST COPY AVAILABLE

KWG 0519 - Mouse Chronic Toxicity Study
Histopathology Report

Liver	Liver tumour	graded 3
	Hyperplasia	graded 1
	Infarct	graded 1
	Calcification	graded 1
	Fat vacuoles	graded 1
	Necrosis	graded 1
	Fibrosis	graded 1
	Inflammation granulomatous	graded 1
	Haemorrhage	graded 1
	Mononuclear cells	graded 1
	Pigmentation	graded 1
	Amyloid	graded 1
	Haematopoiesis	graded 1
	Congestion	graded 1
	Hyperplastic nodule	graded 1
	Hypertrophy	graded 1
	Vacuolisation	graded 1
	Pericholangitis	graded 1
	Cysts	graded 1
	Inflammation portal	graded 1
	Hyalinosis	graded 1
	Hepatocytic hyperpigmentation	graded 1
	Haemorrhagic cyst	graded 1
	Hyperplastic nodules	graded 1
	Hyperplasia focal	graded 1
	Thrombosis	graded 1
	Haemorrhage	graded 1
	Periarteritis	graded 1
Lung	Lung tumour	graded 1
	Thrombosis	graded 1
	Oedema	graded 1
	Necrosis	graded 1
	Fibrosis	graded 1
	Bronchopneumonia	graded 1
	Haemorrhage	graded 1
	Adenomatosis	graded 1
	Pleuritis	graded 1
	Pigmentation	graded 1
	Pneumonia	graded 1
	Leukocytosis	graded 1
	Congestion	graded 1
	Atelectasis	graded 1
	Emphysema	graded 1
	Mucoid cyst	graded 1
	Ectasia vascular	graded 1
	Thickened alveolar walls	graded 1
	Hyperplasia lymphoid	graded 1
	Peritonitis	graded 1
	Osseous metaplasia	graded 1

BEST COPY AVAILABLE

KWG 0519 - Mouse Chronic Toxicity Study
Histopathology Report

Ovary	Ovarian tumour	graded 9
	Thrombus	graded 1
	Inflammation acute	graded 1
	Inflammation chronic	graded 1
	Hyperplasia polycoid	graded 1
	Haemorrhage	graded 1
	Pigmentation	graded 1
	Atrophy	graded 1
	Arteritis	graded 1
	Cysts	graded 1
	Hypertrophic corpora lutea	graded 1
	Cystic follicle	graded 1
	Haemorrhagic cyst	graded 1
	Hyperplasia papillomatous	graded 1
	Pus	graded 1
Pancreas	Pancreatic tumour	graded 4
	Atrophy	graded 1
	Oedema	graded 1
	Fibrosis	graded 1
	Inflammation chronic	graded 1
	Mononuclear cells	graded 1
	Atrophy	graded 1
	Congestion	graded 1
	Vacuolisation	graded 1
	Cysts	graded 1
	Periarteritis	graded 1
	Haemorrhagic cyst	graded 1
	Fatty cyst	graded 1
	Amyloid	graded 1
	Hyperplasia islets	graded 1
	Cystic dysplasia	graded 1
Pituitary	Pituitary tumour	graded 6
	Cysts	graded 1
	Haemorrhagic cyst	graded 1
	Haemorrhage	graded 1

BEST COPY AVAILABLE

Seminal vesicle	Atrophy epithelial	graded 1
	Calcification	graded 1
	Haemorrhage	graded 1
	Ectasia simple	graded 1
	Coagulum	graded 1
	Cysts	graded 1
	Haemorrhagic cyst	graded 1
	Inflammation acute glandular	graded 1
Skeletal muscle	Oedema	graded 1
	Atrophy	graded 1
	Fatty cyst	graded 1
	Calcification	graded 1
	Mononuclear cells	graded 1
	Vacuolisation	graded 1
Spleen	Oedema	graded 1
	Fibrosis	graded 1
	Hyperplasia lymphoid	graded 1
	Haemorrhage	graded 1
	Pigmentation	graded 1
	Amyloid	graded 1
	Haematopoiesis	graded 1
	Atrophy	graded 1
	Congestion	graded 1
	Hypertrophy	graded 1
	Ectasia vascular	graded 1
	Haemorrhagic cyst	graded 1
	Hypoplasia lymphoid	graded 1
	Infarct	graded 1
Stomach	Calcification	graded 1
	Fibrosis	graded 1
	Inflammation chronic	graded 1
	Haemorrhage	graded 1
	Mononuclear cells	graded 1
	Pigmentation	graded 1
	Cysts	graded 1
	Mucoic cyst	graded 1
	Ectasia vascular	graded 1
	Hyperkeratosis	graded 1
	Ulceration	graded 1
	Papillomatous acanthosis	graded 1
	Hyperplasia papillomatous	graded 1
Testis	Testicular tumour	graded 3
	Atrophy seminiferous tubules	graded .
	Azoospermia	graded .
	Calcification	graded 1
	Inflammation chronic	graded 1
	Pigmentation	graded .
	Spermatocoele	graded .
	Cysts	graded 1

BEST COPY AVAILABLE

KWG 0518 - Mouse Chronic Toxicity Study
Histopathology Report

Thyroid/1	Thyroid tumour	graded 6
	Cysts	graded 1
Urinary bladder	Urinary bladder tumour	graded 3
	Hyperplasia	graded 1
	Necrosis	graded 1
	Inflammation chronic	graded 1
	Inflammation granulomatous	graded 1
	Haemorrhage	graded 1
	Mononuclear cells	graded 1
	Ectasia simple	graded 1
	Hypertrophy	graded 1
	Coagulum	graded 1
	Inflammation acute glandular	graded 1
	Hyperplasia papillomatous	graded 1
	Oedema	graded 1
	Periarteritis	graded 1
	Cysts	graded 1
	Haemorrhagic cysts	graded 1
Uterus	Uterine tumour	graded 12
	Thrombosis	graded 1
	Hyperplasia polyoid	graded 1
	Haemorrhage	graded 1
	Amyloid	graded 1
	Cystic endometrial hyperplasia	graded 1
	Squamous metaplasia	graded 1
	Ectasia simple	graded 1
	Endometriosis	graded 1
	Hyperplasia secretory	graded 1
	Endometritis	graded 1
	Haemorrhagic cyst	graded 1
	Hyperplasia papillomatous	graded 1
	Pus	graded 1
	Endometriasis	graded 1

BEST COPY AVAILABLE

KWG 0519 - Mouse Chronic Toxicity Study
Histopathology Report

The grading systems used are as follows:

Grading System	Level		Tumour Type
1	1	present (not graded)	
	2	(minimal)	
	3	(moderate)	
	4	(severe)	
2	1	fibroma	1
	2	alveogenic carcinoma	3
3	1	cystadenoma	1
	2	hepatocellular adenoma	1
	3	hepatocellular adenocarcinoma	3
	4	angiosarcoma	3
4	1	islet cell adenoma	1
5	1	papilloma	1
	2	carcinosarcoma	3
6	1	adenoma	1
	2	adenocarcinoma	3
7	1	cortical adenoma	1
	2	phaeochromocytoma	1
8	1	interstitial cell tumour	1
9	1	luteoma	1
	2	arrhenoblastoma	1
	3	cystadenoma	1
10	1	adenocarcinoma	3
	2	mesenchymal tumour	3
	3	histiocytic sarcoma	3
	4	leiomyosarcoma	3
	5	adenoma	1

BEST COPY AVAILABLE

Tumour grades and key to tumour incidence tables

Tumour	1	BENIGN TUMOUR	b
	2	DOUBTFULLY MALIGNANT TUMOUR	d
	3	MALIGNANT TUMOUR	m
	4	METASTASIS	s
	5	MALIGNANT LYMPHOMA	l
	6	MYELOID LEUKAEMIA	y
	7	RETICULUM CELL SARCOMA	r
	8	MULTICENTRIC (OTHER)	c

BEST COPY AVAILABLE

KWG 0519 - Mouse Chronic Toxicity Study
Summary Incidence Table
Neoplastic Lesions
Male

		Group 1 Control	Group 2 125ppm	Group 3 500ppm	Group 4 2000ppm
number of animals		50	50	50	50
Adrenal					
number of sections					
no section		4	2	3	3
Adrenal tumour					
absent		43	40	44	43
cortical adenoma	b	3	6	3	3
phaeochromocytoma	b	0	2	0	1
Secondary deposits					
malignant lymphoma	1	5	0	0	3
Bone (femur)					
number of sections					
no section		4	1	3	5
Bone tumour					
absent		46	49	45	45
osteoma	b	0	0	2	0
Heart					
number of sections					
no section		0	0	1	0
Secondary deposits					
malignant lymphoma	1	2	1	2	1
adenocarcinoma	s	0	1	0	0

BEST COPY AVAILABLE

AWE 0319 - Mouse Chronic Toxicity Study
Summary Incidence Table
Neoplastic Lesions
Male

		Group 1 Control	Group 2 125ppm	Group 3 500ppm	Group 4 2000ppm
number of animals		50	50	50	50
Kidney					
number of sections					
no section		0	0	1	0
Secondary deposits					
malignant lymphoma	l	9	2	2	6
myeloid leukaemia	y	0	0	0	1
adenocarcinoma	s	0	1	0	0
Liver					
number of sections					
no section		0	0	1	0
Liver tumour					
cystacenoma	b	1	0	0	0
hepatocellular adenoma	b	5	4	5	5
hepatocellular adenocarcinoma	m	3	0	0	1
Secondary deposits					
malignant lymphoma	l	9	5	4	6
myeloid leukaemia	y	0	0	0	1

BEST COPY AVAILABLE

NWG 85:9 - Mouse Chronic Toxicity Study
Summary Incidence Table
Neoplastic Lesions
Male

		Group 1 Control	Group 2 125ppm	Group 3 500ppm	Group 4 2000ppm
number of animals		50	50	50	50
			Lung		
number of sections					
no section		1	0	1	1
Lung tumour					
fibroma	b	0	0	0	1
alveogenic carcinoma	m	20	17	10	14
Secondary deposits					
malignant lymphoma	l	5	3	2	4
			Pancreas		
number of sections					
no section		4	1	6	0
Pancreatic tumour					
islet cell adenoma	a	1	0	1	0
Secondary deposits					
malignant lymphoma	l	4	2	1	2
			Sciatic nerve		
number of sections					
no section		5	5	11	7
Secondary deposits					
malignant lymphoma	l	1	0	0	0

BEST COPY AVAILABLE

AWS 0519 - Mouse Chronic Toxicity Study
Summary Incidence Table
Neoplastic Lesions
Male

		Group 1 Control	Group 2 125ppm	Group 3 500ppm	Group 4 2000ppm
number of animals		50	50	50	50
Skeletal muscle					
number of sections					
no section		1	1	2	5
Secondary depcsits					
malignant lymphoma	1	3	0	1	1
Spleen					
number of sections					
no section		0	0	1	0
Secondary deposits					
malignant lymphoma	1	14	4	4	8
myeloid leukaemia	g	0	0	0	1
Stomach					
number of sections					
no section		2	0	2	0
Secondary deposits					
malignant lymphoma	1	4	1	1	0
Testis					
number of sections					
no section		1	0	2	0
Testicular tumour					
absent		48	49	46	50
interstitial cell tumour	b	1	1	2	0
Secondary deposits					
malignant lymphoma	1	1	0	0	0

BEST COPY AVAILABLE

KWE 0519 - Mouse Chronic Toxicity Study
Summary Incidence Table
Neoplastic Lesions
Male

		Group 1 Control	Group 2 125ppm	Group 3 500ppm	Group 4 2000ppm
number of animals		50	50	50	50
Thyroid					
number of sections					
no section		22	26	16	11
Thyroid tumour					
absent		28	23	34	39
adenoma	b	0	1	0	0
Secondary deposits					
malignant lymphoma	l	1	0	0	0
Urinary bladder					
number of sections					
no section		4	0	2	0
Urinary bladder tumour					
absent		49	50	48	48
carcinosarcoma	m	0	0	0	2
Secondary deposits					
malignant lymphoma	l	3	2	0	1
myeloid leukaemia	y	0	0	0	1

BEST COPY AVAILABLE

AWG 0519 - Mouse Chronic Toxicity Study
Summary Incidence Table
Neoplastic Lesions
Male

		Group 1 Control	Group 2 125ppm	Group 3 500ppm	Group 4 2000ppm
number of animals		50	50	50	50
		Non-Protocol Organs			
Bone					
osteoma	b	1	0	1	1
Fat					
malignant lymphoma	l	0	1	0	0
lipoma	b	1	1	0	0
Lymph node					
malignant lymphoma	l	7	2	1	2
Mesentery					
malignant lymphoma	l	3	2	1	2
fibromyxoma	b	1	0	0	0
Seminal vesicle					
mesenchymal tumour	m	0	0	1	0
Skin					
squamous cell carcinoma	m	0	0	0	1
Thymus					
malignant lymphoma	l	3	1	1	2
Trachea					
malignant lymphoma	l	1	0	0	1
Unidentified tissue					
reticulum cell sarcoma	r	0	0	0	1

BEST COPY AVAILABLE

KWG 0519 - Mouse Chronic Toxicity Study
Summary Incidence Table
Neoplastic Lesions
Male

	Group 1 Control	Group 2 125ppm	Group 3 500ppm	Group 4 2000ppm
number of animals	50	50	50	50
	Overall Tumour Incidence			
PRIMARY TUMOURS				
BENIGN TUMOUR	4	9	9	7
MALIGNANT TUMOUR	32	22	16	25
MULTIPLE PRIMARY TUMOURS				
BENIGN TUMOUR	6	5	5	6
MALIGNANT TUMOUR	8	1	1	4
MALIGNANT LYMPHOMA	17	6	6	9
MYELOID LEUKAEMIA	0	0	0	1
RETICULUM CELL SARCOMA	0	0	0	1

BEST COPY AVAILABLE

RWG 351 - Mouse Chronic Toxicity Study
Summary Incidence Table
Neoplastic Lesions
Female

		Group 1 Control	Group 2 125ppm	Group 3 500ppm	Group 4 2000ppm
number of animals		50	50	50	50
Adrenal					
number of sections					
no section		2	1	1	3
Adrenal tumour					
absent		48	47	49	44
cortical adenoma	b	0	2	0	2
phaeochromocytoma	b	0	0	0	1
Secondary deposits					
malignant lymphoma	l	2	3	1	2
myeloid leukaemia	y	1	0	0	0
Bone (femur)					
number of sections					
no section		2	3	1	4
Bone tumour					
absent		47	47	47	44
osteoma	b	0	0	1	0
osteogenic sarcoma	m	1	0	1	2
Secondary deposits					
malignant lymphoma	l	0	0	0	1
Brain					
number of sections					
no section		2	5	5	2
Secondary deposits					
malignant lymphoma	l	0	1	0	0

BEST COPY AVAILABLE

HWG 0519 - Mouse Chronic Toxicity Study
Summary Incidence Table
Neoplastic Lesions
Female

		Group 1 Control	Group 2 125ppm	Group 3 500ppm	Group 4 2000ppm
number of animals		50	50	50	50
Heart					
number of sections					
no section		1	1	0	1
Secondary deposits					
malignant lymphoma	l	4	2	0	5
Kidney					
number of sections					
no section		1	1	0	1
Secondary deposits					
malignant lymphoma	l	3	12	11	11
myeloid leukaemia	y	2	0	1	0
Liver					
number of sections					
no section		2	1	0	1
Liver tumour					
absent		47	49	44	43
hepatocellular adenoma	b	0	0	4	6
hepatocellular adenocarcinoma	m	1	0	1	0
angiosarcoma	m	0	0	1	0
Secondary deposits					
malignant lymphoma	l	7	8	15	15
myeloid leukaemia	y	3	0	0	0

BEST COPY AVAILABLE

KW3 0519 - Mouse Chronic Toxicity Study
Summary Incidence Table
Neoplastic Lesions
Female

		Group 1 Control	Group 2 125ppm	Group 3 500ppm	Group 4 2000ppm
number of animals		50	50	50	50
Lung					
number of sections					
no section		1	1	0	1
Lung tumour					
absent		39	35	35	43
alveogenic carcinoma	m	10	14	15	6
Secondary deposits					
malignant lymphoma	l	5	9	6	11
myeloid leukaemia	y	1	0	0	0
osteogenic sarcoma	s	0	0	0	1
Ovary					
number of sections					
no section		2	2	1	4
Ovarian tumour					
absent		46	46	46	43
luteoma	b	1	1	3	2
arrhenoblastoma	b	0	0	0	1
cystadenoma	b	1	0	0	0
Secondary deposits					
malignant lymphoma	l	5	7	2	7
myeloid leukaemia	y	1	0	0	0
leiomyosarcoma	s	1	0	0	0

BEST COPY AVAILABLE

KWE 0519 - Mouse Chronic Toxicity Study
Summary Incidence Table
Neoplastic Lesions
Female

		Group 1 Control	Group 2 125ppm	Group 3 500ppm	Group 4 2000ppm
number of animals		50	50	50	50
Pancreas					
number of sections					
no section		2	1	2	2
Secondary deposits					
malignant lymphoma	1	1	7	6	6
myeloid leukaemia	g	1	0	0	0
Pituitary					
number of sections					
no section		14	10	15	13
Pituitary tumour					
absent		36	40	34	37
adenoma	b	0	0	1	0
Sciatic nerve					
number of sections					
no section		5	6	7	12
Secondary deposits					
malignant lymphoma	1	0	0	0	1
Skeletal muscle					
number of sections					
no section		3	3	2	4
Secondary deposits					
malignant lymphoma	1	3	3	3	2
myeloid leukaemia	g	1	0	0	0
fibrosarcoma	s	0	1	0	0
osteogenic sarcoma	s	0	0	0	1

BEST COPY AVAILABLE

KWG 0519 - Mouse Chronic Toxicity Study
Summary Incidence Table
Neoplastic Lesions
Female

		Group 1 Control	Group 2 125ppm	Group 3 500ppm	Group 4 2000ppm
number of animals		50	50	50	50
Spleen					
number of sections					
no section		1	1	0	2
Secondary deposits					
malignant lymphoma	1	10	10	17	16
myeloid leukaemia	9	3	0	1	0
Stomach					
number of sections					
no section		1	1	0	2
Secondary deposits					
malignant lymphoma	1	1	3	4	4
Thyroid					
number of sections					
no section		14	14	19	15
Secondary deposits					
malignant lymphoma	1	1	1	0	1
Urinary bladder					
number of sections					
no section		1	1	1	2
Urinary bladder tumour					
absent		48	49	49	48
papilloma	0	1	0	0	0
Secondary deposits					
malignant lymphoma	1	7	9	5	10
myeloic leukaemia	9	1	0	0	0

BEST COPY AVAILABLE

KWS 3519 - Mouse Chronic Toxicity Study
Summary Incidence Table
Neoplastic Lesions
Female

		Group 1 Control	Group 2 125ppm	Group 3 500ppm	Group 4 2000ppm
number of animals		50	50	50	50
		Non-Protocol Organs			
Body cavity					
osteogenic sarcoma	s	0	0	0	1
Body wall					
mesenchymal tumour	m	1	0	0	0
Bone					
osteoma	b	0	1	2	1
Cervix					
leiomyosarcoma	m	1	0	0	1
keratoacanthoma	b	0	1	0	0
Diaphragm					
malignant lymphoma	l	0	0	1	0
leiomyosarcoma	m	0	0	1	0
Fat					
malignant lymphoma	l	0	1	0	0
Hind limb (right)					
osteogenic sarcoma	s	0	0	0	1
Lymph node					
malignant lymphoma	l	7	5	11	3
myeloid leukaemia	y	1	0	0	0
Mammary gland					
adenocarcinoma	m	2	0	0	0
Mesentery					
malignant lymphoma	l	8	9	10	3
myeloid leukaemia	y	1	0	0	0
mesenchymal tumour	s	1	0	0	0
histiocytic sarcoma	s	1	0	0	0
Skull					
osteogenic sarcoma	s	1	0	0	0
osteoma	b	0	0	0	1
Subcutaneous tissue					
fibrosarcoma	m	0	1	0	0

BEST COPY AVAILABLE

KWS 0519 - Mouse Chronic Toxicity Study
Summary Incidence Table
Neoplastic Lesions
Female

		Group 1 Control	Group 2 125ppm	Group 3 500ppm	Group 4 2000ppm
number of animals		50	50	50	50
Non-Protocol Organs					
Thymus					
malignant lymphoma	l	4	3	2	5
thymoma	m	0	0	1	0
Trachea					
malignant lymphoma	l	0	0	0	2
Uterus					
adenocarcinoma	m	1	0	0	0
mesenchymal tumour	m	1	0	1	1
histiocytic sarcoma	m	1	0	0	0
leiomyosercoma	m	3	1	1	2
adenoma	b	0	0	0	1
malignant lymphoma	l	0	3	5	6
myeloic leukaemia	y	1	0	0	0

BEST COPY AVAILABLE

KWG 0519 - Mouse Chronic Toxicity Study
Summary Incidence Table
Neoplastic Lesions
Female

	Group 1 Control	Group 2 125ppm	Group 3 500ppm	Group 4 2000ppm
number of animals	50	50	50	50
Overall Tumour Incidence				
PRIMARY TUMOURS				
BENIGN TUMOUR	0	4	5	8
MALIGNANT TUMOUR	32	28	33	27
MULTIPLE PRIMARY TUMOURS				
BENIGN TUMOUR	3	1	3	7
MALIGNANT TUMOUR	7	5	12	3
MALIGNANT LYMPHOMA	15	17	23	18
MYELOID LEUKAEMIA	3	0	1	0

BEST COPY AVAILABLE

KWG 0519 - Mouse Chronic Toxicity Study
Summary Incidence Table
Non-neoplastic Lesions
Female

	Group 1 Control	Group 2 125ppm	Group 3 500ppm	Group 4 2000ppm
number of animals	50	50	50	50
Pancreas				
Haemorrhagic cyst				
absent	48	49	48	48
present	2	0	0	0
Fatty cyst				
absent	48	48	48	48
present	0	1	0	0
Pituitary				
number of sections				
no section	14	10	15	13
Cysts				
absent	34	40	35	37
present	2	0	0	0
Haemorrhagic cyst				
absent	36	40	35	36
present	0	0	0	1
Haemorrhage				
absent	35	40	34	37
present	1	0	1	0
Comments				
Unreadable	0	1	0	0
Sciatic nerve				
number of sections				
no section	6	6	7	12
No lesions observed				
Skeletal muscle				
number of sections				
no section	3	3	2	4
No lesions observed				

BEST COPY AVAILABLE

KWG 0519 - Mouse Chronic Toxicity Study
Summary Incidence Table
Non-neoplastic Lesions
Female

	Group 1 Control	Group 2 125ppm	Group 3 500ppm	Group 4 2000ppm
number of animals	50	50	50	50
		Spleen		
number of sections				
no section	1	1	0	2
Hyperplasia lymphoid				
absent	48	42	49	46
present	1	7	1	2
Haemorrhage				
absent	49	49	49	48
present	0	0	1	0
Pigmentation				
absent	48	49	50	48
(moderate)	1	0	0	0
Amyloid				
absent	48	49	50	48
present	1	0	0	0
Haematopoiesis				
absent	31	35	24	34
(minimal)	3	4	5	4
(moderate)	4	7	12	5
(severe)	11	3	9	5
Congestion				
absent	48	47	48	46
present	1	2	2	2
Hypertrophy				
absent	48	49	49	47
present	1	0	1	1
Haemorrhagic cyst				
absent	47	49	50	48
present	2	0	0	0
Infarct				
absent	49	49	50	47
present	0	0	0	1

BEST COPY AVAILABLE

KWG 0519 - Mouse Chronic Toxicity Study
Summary Incidence Table
Non-neoplastic Lesions
Female

	Group 1 Control	Group 2 125ppm	Group 3 500ppm	Group 4 2000ppm
number of animals	50	50	50	50
Stomach				
number of sections				
no section	1	1	0	2
Inflammation chronic				
absent	46	48	50	47
present	2	0	0	1
(severe)	1	1	0	0
Haemorrhage				
absent	49	46	48	48
present	0	3	2	0
Mucoid cyst				
absent	44	44	45	44
present	2	3	0	2
(minimal)	3	1	4	2
(moderate)	0	0	1	0
(severe)	0	1	0	0
Hyperkeratosis				
absent	47	49	50	46
present	2	1	0	2
Ulceration				
absent	49	49	50	45
present	0	0	0	3
Papillomatous acanthosis				
absent	49	49	50	47
present	0	0	0	1
Hyperplasia papillomatous				
absent	48	49	50	46
present	1	0	0	0
Comments				
Unreadable	2	0	0	1

BEST COPY AVAILABLE

KWG 0519 - Mouse Chronic Toxicity Study
Summary Incidence Table
Non-neoplastic Lesions
Female

	Group 1 Control	Group 2 125ppm	Group 3 500ppm	Group 4 2000ppm
number of animals	50	50	50	50
Thyroid				
number of sections				
no section	14	14	19	15
Cysts				
absent	33	33	30	32
present	3	3	1	0
(minimal)	0	0	0	3
Comments				
Unreadable	0	0	0	1

BEST COPY AVAILABLE

KWG 0519 - Mouse Chronic Toxicity Study
Summary Incidence Table
Non-neoplastic Lesions
Female

	Group 1 Control	Group 2 125ppm	Group 3 500ppm	Group 4 2000ppm
number of animals	50	50	50	50
	Urinary bladder			
number of sections				
no section	1	1	1	2
Inflammation chronic				
absent	42	44	47	41
present	7	3	1	7
(minimal)	3	2	0	0
(moderate)	0	0	1	0
Inflammation granulomatous				
absent	49	49	49	47
present	0	0	0	1
Hyperplasia papillomatous				
absent	42	44	48	46
present	7	5	1	2
Oedema				
absent	49	48	49	48
present	0	1	0	0
Periarteritis				
absent	49	49	49	46
present	0	0	0	2
Comments				
Unreadable	3	1	1	0

BEST COPY AVAILABLE

KWG 0519 - Mouse Chronic Toxicity Study
Summary Incidence Table
Non-neoplastic Lesions
Female

	Group 1 Control	Group 2 125ppm	Group 3 500ppm	Group 4 2000ppm
number of animals	50	50	50	50
Non-Protocol Organs				
Abdominal cavity				
Steatonecrosis	0	1	0	0
Cervical lymph node				
Hypertrophy	0	0	0	1
Lymph node				
Lymphatic ectasia	1	0	0	0
Lymphocoele	1	0	0	0
Hypertrophy	0	0	2	0
Congestion	0	0	1	0
Crystals	0	0	1	0
Mammary gland				
Hyperplasia secretory	0	1	0	0
Mesentery				
Inflammation chronic	5	0	2	1
Peritonitis	0	1	0	1
Steatonecrosis	0	1	0	0
Haemorrhage	0	0	1	0

BEST COPY AVAILABLE

KWG 0519 - Mouse Chronic Toxicity Study
Summary Incidence Table
Non-neoplastic Lesions
Female

	Group 1 Control	Group 2 125ppm	Group 3 500ppm	Group 4 2000ppm
number of animals	50	50	50	50
Non-Protocol Organs				
Skin				
Inflammation chronic (moderate)	0	0	1	0
Necrosis	0	0	1	0
Pus	0	0	1	0
Fibrosis	0	0	1	0
Subcutaneous tissue				
Necrosis	0	1	0	0
Thymus				
Necrosis	0	0	1	0
Trachea				
Inflammation chronic	0	0	0	1
Uterus				
Thrombosis	0	1	1	0
Hyperplasia polypoic	4	1	3	1
Haemorrhage	4	3	2	0
Amyloid	0	1	0	0
Cystic endometrial hyperplasia	5	14	7	11
Squamous metaplasia	0	0	1	0
Ectasia simple	0	0	0	1
Endometriosis	8	8	7	5
Hyperplasia secretory	7	8	7	8
Endometritis	3	2	0	4
Haemorrhagic cyst	1	1	1	0
Hyperplasia papillomatous	0	1	0	0
Pus	1	0	0	0
Unreadable	2	1	1	0

BEST COPY AVAILABLE

KWG 0519 - Mouse Chronic Toxicity Study
Summary Incidence Table
Non-neoplastic Lesions
Male

	Group 1 Control	Group 2 125ppm	Group 3 500ppm	Group 4 2000ppm
number of animals	50	50	50	50
		Adrenal		
number of sections				
no section	4	2	3	3
Calcification				
absent	46	48	47	46
(moderate)	0	0	0	1
Pigment				
absent	45	48	47	47
present	1	0	0	0
Pigmentation				
absent	44	43	41	45
(minimal)	2	2	4	0
(mocerate)	0	3	2	2
Amyloid				
absent	46	48	46	46
present	0	0	0	1
(moderate)	0	0	1	0
Hyperplastic nodule				
absent	45	47	47	47
present	1	1	0	0
Haemorrhagic cyst				
absent	46	48	46	46
present	0	0	1	1
Hyperplasia glomerulosa				
absent	46	47	47	46
present	0	1	0	0
(minimal)	0	0	0	1
Comments				
Unreadable	1	0	0	1

BEST COPY AVAILABLE

KWG 0519 - Mouse Chronic Toxicity Study
Summary Incidence Table
Non-neoplastic Lesions
Male

	Group 1 Control	Group 2 125ppm	Group 3 500ppm	Group 4 2000ppm
number of animals	50	50	50	50
Bone (femur)				
number of sections				
no section	4	1	3	5
No lesions observed				
Brain				
number of sections				
no section	6	9	8	4
Calcification				
absent	44	41	41	46
(moderate)	0	0	1	0
Fat vacuoles				
absent	44	37	37	46
(minimal)	0	4	2	0
(moderate)	0	0	3	0

BEST COPY AVAILABLE

KWG 0519 - Mouse Chronic Toxicity Study
Summary Incidence Table
Non-neoplastic Lesions
Male

	Group 1 Control	Group 2 125ppm	Group 3 500ppm	Group 4 2000ppm
number of animals	50	50	50	50
Brain				
Gliosis				
absent	42	36	41	46
present	2	4	1	0
(minimal)	0	1	0	0
Haemorrhage				
absent	44	41	42	45
(minimal)	0	0	0	1
Hydrocephalus				
absent	44	40	42	46
(minimal)	0	1	0	0
Congestion				
absent	44	41	42	45
(minimal)	0	0	0	1
Vacuolisation				
absent	44	41	41	46
(moderate)	0	0	1	0
Meningitis				
absent	43	41	42	46
(minimal)	1	0	0	0
Heart				
number of sections				
no section	0	0	1	0
Thrombosis				
absent	48	48	45	47
present	2	2	4	3
Fat vacuoles				
absent	50	50	48	50
(severe)	0	0	1	0
Fibrosis				
absent	46	50	48	47
present	0	0	1	0
(minimal)	3	0	0	2
(moderate)	1	0	0	1

KWG 0519 - Mouse Chronic Toxicity Study
Summary Incidence Table
Non-neoplastic Lesions
Male

	Group 1 Control	Group 2 125ppm	Group 3 500ppm	Group 4 2000ppm
number of animals	50	50	50	50
Heart				
Inflammation chronic				
absent	45	50	48	49
present	2	0	1	1
(minimal)	1	0	0	0
(moderate)	2	0	0	0
Haemorrhage				
absent	49	50	49	50
(minimal)	1	0	0	0
Mononuclear cells				
absent	49	50	49	46
(minimal)	1	0	0	3
(moderate)	0	0	0	1
Leukocytosis				
absent	50	50	48	50
(severe)	0	0	1	0
Congestion				
absent	35	41	37	41
present	14	9	11	7
(moderate)	0	0	0	1
(severe)	1	0	1	1
Dilated chamber				
absent	48	49	48	50
present	2	1	1	0
Periarteritis				
absent	50	49	49	50
(moderate)	0	1	0	0
Ventricular dilatation				
absent	50	50	49	49
present	0	0	0	1
Degeneration muscular				
absent	50	50	48	50
present	0	0	1	0

KWG 0519 - Mouse Chronic Toxicity Study
Summary Incidence Table
Non-neoplastic Lesions
Male

	Group 1 Control	Group 2 125ppm	Group 3 500ppm	Group 4 2000ppm
number of animals	50	50	50	50
Heart				
Pericarditis				
absent	50	49	47	50
present	0	0	1	0
(moderate)	0	1	0	0
(severe)	0	0	1	0
Thickening endocardium				
absent	49	50	49	50
(minimal)	1	0	0	0
Kidney				
number of sections				
no section	0	0	1	0
Calcification				
absent	48	43	46	47
present	2	0	1	0
(minimal)	0	4	2	2
(moderate)	0	3	0	1
Necrosis				
absent	50	49	49	50
(severe)	0	1	0	0
Fibrosis				
absent	50	43	49	49
(minimal)	0	6	0	1
(moderate)	0	1	0	0
Hydronephrosis				
absent	47	49	47	48
present	0	1	0	2
(minimal)	2	0	0	0
(moderate)	1	0	2	0
Haemorrhage				
absent	49	50	49	50
(severe)	1	0	0	0

KWG 0519 - Mouse Chronic Toxicity Study
Summary Incidence Table
Non-neoplastic Lesions
Male

	Group 1 Control	Group 2 125ppm	Group 3 500ppm	Group 4 2000ppm
number of animals	50	50	50	50
		Kidney		
Amyloid				
absent	50	50	49	48
present	0	0	0	2
Congestion				
absent	48	48	46	47
present	1	2	3	0
(moderate)	0	0	0	3
(severe)	1	0	0	0
Tubulopathy				
absent	48	37	38	45
(minimal)	1	10	9	3
(moderate)	1	2	2	2
(severe)	0	1	0	0
Interstitial nephritis				
absent	24	40	40	28
present	0	0	1	0
(minimal)	24	7	6	17
(moderate)	1	3	2	5
(severe)	1	0	0	0
Cysts				
absent	35	42	40	40
present	2	1	4	1
(minimal)	5	2	2	5
(moderate)	7	4	3	3
(severe)	1	1	0	1
Pyelonephritis				
absent	49	49	48	50
(minimal)	1	0	0	0
(moderate)	0	0	1	0
(severe)	0	1	0	0
Ectasia vascular				
absent	50	49	49	50
(moderate)	0	1	0	0
Dilatation glomerular loops				
absent	49	47	48	50
(minimal)	0	2	1	0
(moderate)	1	1	0	0

KWG 0519 - Mouse Chronic Toxicity Study
Summary Incidence Table
Non-neoplastic Lesions
Male

	Group 1 Control	Group 2 125ppm	Group 3 500ppm	Group 4 2000ppm
number of animals	50	50	50	50
		Kidney		
Dilatation renal pelvis				
absent	50	43	48	49
present	0	0	1	1
(minimal)	0	1	0	0
(moderate)	0	6	0	0
Progressive nephropathy				
absent	47	40	46	49
(minimal)	0	2	2	0
(moderate)	2	6	1	0
(severe)	1	2	0	1
Pyelitis				
absent	49	50	49	50
(moderate)	1	0	0	0

KWG 0519 - Mouse Chronic Toxicity Study
Summary Incidence Table
Non-neoplastic Lesions
Male

	Group 1 Control	Group 2 125ppm	Group 3 500ppm	Group 4 2000ppm
number of animals	50	50	50	50
		Liver		
number of sections				
no section	0	0	1	0
Hyperplasia				
absent	50	50	49	47
present	0	0	0	3
Infarct				
absent	50	49	47	50
present	0	0	1	0
(severe)	0	1	1	0
Calcification				
absent	49	49	48	45
present	0	1	0	2
(moderate)	0	0	1	1
(severe)	1	0	0	2
Fat vacuoles				
absent	50	43	45	50
present	0	1	0	0
(minimal)	0	2	1	0
(moderate)	0	0	2	0
(severe)	0	4	1	0

KWG 0519 - Mouse Chronic Toxicity Study
Summary Incidence Table
Non-neoplastic Lesions
Male

	Group 1 Control	Group 2 125ppm	Group 3 500ppm	Group 4 2000ppm
number of animals	50	50	50	50
Liver				
Necrosis				
absent	48	50	49	49
present	1	0	0	0
(minimal)	0	0	0	1
(severe)	1	0	0	0
Fibrosis				
absent	50	49	49	50
(severe)	0	1	0	0
Inflammation granulomatous				
absent	50	49	49	50
(moderate)	0	1	0	0
Haemorrhage				
absent	50	47	48	47
present	0	0	0	1
(moderate)	0	0	1	1
(severe)	0	3	0	1
Mononuclear cells				
absent	47	48	47	47
present	0	0	0	2
(minimal)	2	1	1	0
(moderate)	1	0	1	0
(severe)	0	1	0	1
Pigmentation				
absent	49	50	48	50
present	1	0	0	0
(moderate)	0	0	1	0
Amyloid				
absent	47	49	48	44
present	2	1	0	2
(moderate)	0	0	1	2
(severe)	1	0	0	2
Haematopoiesis				
absent	50	47	49	50
(moderate)	0	1	0	0
(severe)	0	2	0	0

KWG 0519 - Mouse Chronic Toxicity Study
Summary Incidence Table
Non-neoplastic Lesions
Male

	Group 1 Control	Group 2 125ppm	Group 3 500ppm	Group 4 2000ppm
number of animals	50	50	50	50
Liver				
Congestion				
absent	47	46	43	46
present	2	3	6	2
(severe)	1	1	0	2
Hyperplastic nodule				
absent	49	45	42	47
present	1	5	7	3
Hypertrophy				
absent	50	50	48	49
present	0	0	1	1
Vacuolisation				
absent	49	48	48	49
present	1	0	0	0
(minimal)	0	2	1	0
(severe)	0	0	0	1
Pericholangitis				
absent	50	49	49	50
(moderate)	0	1	0	0
Cysts				
absent	50	49	49	49
present	0	0	0	1
(moderate)	0	1	0	0
Inflammation portal				
absent	50	50	49	49
(severe)	0	0	0	1
Hyalinosis				
absent	50	49	49	49
present	0	0	0	1
(moderate)	0	1	0	0
Hepatocytic hyperpigmentation				
absent	46	50	49	41
present	3	0	0	8
(minimal)	1	0	0	0

KWG 0519 - Mouse Chronic Toxicity Study
Summary Incidence Table
Non-neoplastic Lesions
Male

	Group 1 Control	Group 2 125ppm	Group 3 500ppm	Group 4 2000ppm
number of animals	50	50	50	50
Liver				
Haemorrhagic cyst				
absent	50	50	44	50
(moderate)	0	0	1	0
(severe)	0	0	4	0
Hyperplastic nodules				
absent	43	49	47	43
present	7	1	2	7
Hyperplasia focal				
absent	48	50	49	48
present	2	0	0	2
Lung				
number of sections				
no section	1	0	1	1
Thrombosis				
absent	49	50	47	49
present	0	0	1	0
(severe)	0	0	1	0
Oedema				
absent	48	40	44	45
present	1	7	3	2
(minimal)	0	1	0	0
(moderate)	0	0	0	1
(severe)	0	2	2	1
Necrosis				
absent	49	50	48	49
(severe)	0	0	1	0
Fibrosis				
absent	49	50	48	49
(moderate)	0	0	1	0

KWG 0519 - Mouse Chronic Toxicity Study
Summary Incidence Table
Non-neoplastic Lesions
Male

	Group 1 Control	Group 2 125ppm	Group 3 500ppm	Group 4 2000ppm
number of animals	50	50	50	50
Lung				
Bronchopneumonia				
absent	49	49	47	49
(severe)	0	1	2	0
Haemorrhage				
absent	49	43	47	49
present	0	4	2	0
(minimal)	0	1	0	0
(moderate)	0	2	0	0
Adenomatosis				
absent	48	48	46	48
present	1	1	3	0
(minimal)	0	1	0	1
Pleuritis				
absent	48	50	49	49
(moderate)	1	0	0	0
Pigmentation				
absent	48	50	49	48
present	1	0	0	1
Pneumonia				
absent	39	36	25	44
present	0	9	14	0
(minimal)	1	2	1	1
(moderate)	8	0	1	3
(severe)	1	3	8	1
Leukocytosis				
absent	49	50	48	49
present	0	0	1	0
Congestion				
absent	44	38	33	36
present	2	10	8	4
(moderate)	0	0	0	3
(severe)	3	2	8	6

KWG 0519 - Mouse Chronic Toxicity Study
Summary Incidence Table
Non-neoplastic Lesions
Male

	Group 1 Control	Group 2 125ppm	Group 3 500ppm	Group 4 2000ppm
number of animals	50	50	50	50
Lung				
Atelectasis				
absent	43	47	48	47
present	6	1	0	1
(moderate)	0	2	1	0
(severe)	0	0	0	1
Emphysema				
absent	49	46	47	49
present	0	3	2	0
(moderate)	1	1	0	0
Mucoid cyst				
absent	50	50	49	48
present	0	0	0	1
Ectasia vascular				
absent	50	49	48	49
(severe)	0	1	1	0
Thickened alveolar walls				
absent	50	49	47	49
present	0	1	2	0
Pancreas				
number of sections				
no section	4	1	6	0
Fibrosis				
absent	46	49	44	49
(minimal)	0	0	0	1
Inflammation chronic				
absent	45	47	44	47
present	0	1	0	0
(minimal)	1	1	0	3

KWG 0519 - Mouse Chronic Toxicity Study
Summary Incidence Table
Non-neoplastic Lesions
Male

	Group 1 Control	Group 2 125ppm	Group 3 500ppm	Group 4 2000ppm
number of animals	50	50	50	50
		Pancreas		
Congestion				
absent	46	49	43	49
present	0	0	1	0
(severe)	0	0	0	1
Amyloid				
absent	46	49	43	49
present	0	0	0	1
(minimal)	0	0	1	0
Hyperplasia islets				
absent	44	49	44	50
present	2	0	0	0
Cystic dysplasia				
absent	46	48	44	50
present	0	1	0	0
Fatty cyst				
absent	46	46	44	50
present	0	3	0	0
Comments				
Unreadable	2	0	0	0

HWG C519 - Mouse Chronic Toxicity Study
Summary Incidence Table
Non-neoplastic Lesions
Male

	Group 1 Control	Group 2 125ppm	Group 3 500ppm	Group 4 2000ppm
number of animals	50	50	50	50
Pituitary				
number of sections				
no section	21	21	20	28
Cysts				
absent	29	28	30	22
present	0	1	0	0
Comments				
Unreadable	2	0	0	2
Sciatic nerve				
number of sections				
no section	5	5	11	7
Comments				
Unreadable	1	0	0	0

KWG 0519 - Mouse Chronic Toxicity Study
Summary Incidence Table
Non-neoplastic Lesions
Male

	Group 1 Control	Group 2 125ppm	Group 3 500ppm	Group 4 2000ppm
number of animals	50	50	50	50
Skeletal muscle				
number of sections				
no section	1	1	2	5
Oedema				
absent	49	49	48	44
(moderate)	0	0	0	1
Atrophy				
absent	49	48	48	45
(minimal)	0	1	0	0
Fatty cyst				
absent	49	49	46	45
present	0	0	2	0
Calcification				
absent	49	48	48	45
(minimal)	0	1	0	0
Mononuclear cells				
absent	49	49	48	42
(minimal)	0	0	0	2
(moderate)	0	0	0	1
Vacuolisation				
absent	49	48	48	45
(minimal)	0	1	0	0
Comments				
Unreadable	1	0	0	0
Spleen				
number of sections				
no section	0	0	1	0
Oedema				
absent	50	49	49	50
present	0	1	0	0

KWG 0519 - Mouse Chronic Toxicity Study
Summary Incidence Table
Non-neoplastic Lesions
Male

	Group 1 Control	Group 2 125ppm	Group 3 500ppm	Group 4 2000ppm
number of animals	50	50	50	50
Spleen				
Fibrosis				
absent	50	49	49	50
(moderate)	0	1	0	0
Hyperplasia lymphoid				
absent	47	48	47	48
present	3	1	2	2
(moderate)	0	1	0	0
Haemorrhage				
absent	49	48	49	50
present	1	0	0	0
(moderate)	0	1	0	0
(severe)	0	1	0	0
Pigmentation				
absent	47	50	49	47
present	3	0	0	3
Amyloid				
absent	50	50	48	49
present	0	0	0	1
(severe)	0	0	1	0
Haematopoiesis				
absent	37	28	34	38
present	1	0	0	0
(minimal)	1	5	5	2
(moderate)	5	4	5	4
(severe)	6	13	5	6
Atrophy				
absent	50	50	49	49
present	0	0	0	1
Congestion				
absent	49	48	46	50
present	0	2	3	0
(severe)	1	0	0	0

KWG 0519 - Mouse Chronic Toxicity Study
Summary Incidence Table
Non-neoplastic Lesions
Male

	Group 1 Control	Group 2 125ppm	Group 3 500ppm	Group 4 2000ppm
number of animals	50	50	50	50
Spleen				
Hypertrophy				
absent	50	50	48	49
present	0	0	0	1
(severe)	0	0	1	0
Ectasia vascular				
absent	50	49	49	50
present	0	1	0	0
Haemorrhagic cyst				
absent	49	50	49	50
(severe)	1	0	0	0
Hypoplasia lymphoid				
absent	50	50	49	49
(severe)	0	0	0	1
Stomach				
number of sections				
no section	2	0	2	0
Calcification				
absent	48	50	47	50
(minimal)	0	0	1	0
Fibrosis				
absent	48	50	47	50
(moderate)	0	0	1	0
Inflammation chronic				
absent	44	48	45	50
present	1	1	0	0
(minimal)	1	0	1	0
(moderate)	2	1	2	0
Haemorrhage				
absent	48	48	47	49
present	0	2	1	0
(minimal)	0	0	0	1

KWG 0519 - Mouse Chronic Toxicity Study
Summary Incidence Table
Non-neoplastic Lesions
Male

	Group 1 Control	Group 2 125ppm	Group 3 500ppm	Group 4 2000ppm
number of animals	50	50	50	50
Stomach				
Mononuclear cells				
absent	47	50	48	48
(minimal)	0	0	0	2
(moderate)	1	0	0	0
Cysts				
absent	48	50	48	49
(minimal)	0	0	0	1
Mucoid cyst				
absent	47	45	42	48
present	0	0	1	0
(minimal)	0	3	4	1
(moderate)	0	1	1	1
(severe)	1	1	0	0
Ectasia vascular				
absent	48	50	46	50
present	0	0	2	0
Comments				
Unreadable	1	0	1	1
Testis				
number of sections				
no section	1	0	2	0
Atrophy seminiferous tubules				
absent	40	42	42	45
present	2	0	2	0
(minimal)	3	3	0	0
(moderate)	4	4	4	5
(severe)	0	1	0	0
Azoospermia				
absent	49	50	46	50
present	0	0	2	0

KWG 0519 - Mouse Chronic Toxicity Study
Summary Incidence Table
Non-neoplastic Lesions
Male

	Group 1 Control	Group 2 125ppm	Group 3 500ppm	Group 4 2000ppm
number of animals	50	50	50	50
Testis				
Calcification				
absent	37	45	41	40
present	4	1	0	0
(minimal)	5	1	2	5
(moderate)	3	3	5	4
(severe)	0	0	0	1
Inflammation chronic				
absent	49	49	48	50
(minimal)	0	1	0	0
Pigmentation				
absent	48	50	48	50
(minimal)	1	0	0	0
Spermatocoele				
absent	45	46	47	39
present	2	0	1	3
(minimal)	2	3	0	5
(moderate)	0	1	0	3
Cysts				
absent	49	50	47	50
present	0	0	1	0
Thyroid				
number of sections				
no section	22	26	16	11
Cysts				
absent	26	22	32	29
present	0	1	2	6
(minimal)	1	1	0	4
(moderate)	1	0	0	0

KWG 0519 - Mouse Chronic Toxicity Study
Summary Incidence Table
Non-neoplastic Lesions
Male

	Group 1 Control	Group 2 125ppm	Group 3 500ppm	Group 4 2000ppm
number of animals	50	50	50	50
Urinary bladder				
number of sections				
no section	4	0	2	0
Hyperplasia				
absent	45	50	48	49
present	1	0	0	1
Necrosis				
absent	46	50	48	48
present	0	0	0	2
Inflammation chronic				
absent	45	49	46	49
present	0	1	0	0
(minimal)	0	0	1	0
(moderate)	1	0	1	0
(severe)	0	0	0	1
Inflammation granulomatous				
absent	46	50	46	50
present	0	0	2	0

KWG 0519 - Mouse Chronic Toxicity Study
Summary Incidence Table
Non-neoplastic Lesions
Male

	Group 1 Control	Group 2 125ppm	Group 3 500ppm	Group 4 2000ppm
number of animals	50	50	50	50
Urinary bladder				
Haemorrhage				
absent	46	50	48	49
present	0	0	0	1
Mononuclear cells				
absent	46	50	48	48
(minimal)	0	0	0	2
Ectasia simple				
absent	46	46	48	49
present	0	4	0	1
Hypertrophy				
absent	46	50	48	49
present	0	0	0	1
Coagulum				
absent	46	50	47	47
present	0	0	1	3
Inflammation acute glandular				
absent	46	49	48	50
present	0	1	0	0
Hyperplasia papillomatous				
absent	41	49	47	48
present	5	1	1	2
Comments				
Unreadable	0	0	0	2

KWG 0519 - Mouse Chronic Toxicity Study
Summary Incidence Table
Non-neoplastic Lesions
Male

	Group 1 Control	Group 2 125ppm	Group 3 500ppm	Group 4 2000ppm
number of animals	50	50	50	50
Non-Protocol Organs				
Bone marrow				
Hyperplasia megakaryocytic	1	0	0	0
Aplasia myeloid	0	0	1	0
Hyperplasia	0	0	0	1
Intestine				
Haemorrhage (minimal)	0	0	0	1
Lymph node				
Hyperplasia lymphoid	1	1	0	0
Oedema/lymphatic ectasia	0	0	1	0
Infarct	0	1	0	0
Mesentery				
Inflammation chronic	1	0	0	0
Prostate				
Coagulum	0	0	1	0
Salivary gland				
Calcification (minimal)	0	1	0	0
Inflammation chronic	0	0	1	0
Seminal vesicle				
Atrophy epithelial	5	0	0	3
Calcification	0	1	0	0
Haemorrhage	0	1	0	0
Ectasia simple	2	0	0	2
Coagulum	5	6	5	3

KWG 0519 - Mouse Chronic Toxicity Study
Summary Incidence Table
Non-neoplastic Lesions
Male

	Group 1 Control	Group 2 125ppm	Group 3 500ppm	Group 4 2000ppm
number of animals	50	50	50	50
Non-Protocol Organs				
Seminal vesicle				
Cysts	0	0	1	0
Haemorrhagic cyst	0	0	1	0
Inflammation acute glandular	0	1	0	0
Skin				
Inflammation chronic (moderate)	0	0	1	1
Necrosis (severe)	0	0	0	1
Mononuclear cells (severe)	0	0	0	1
Unidentified tissue				
Unreadable	0	0	0	1

KWG 0519 - Mouse Chronic Toxicity Study
Summary Incidence Table
Non-neoplastic Lesions
Female

	Group 1 Control	Group 2 125ppm	Group 3 500ppm	Group 4 2000ppm
number of animals	50	50	50	50
Adrenal				
number of sections				
no section	2	1	1	3
Calcification				
absent	48	49	48	47
present	0	0	1	0
Pigmentation				
absent	28	32	28	33
present	1	0	0	4
(minimal)	4	6	9	6
(moderate)	1	6	9	1
(severe)	14	5	3	3
Amyloid				
absent	47	49	49	47
present	1	0	0	0
Hyperplastic nodule				
absent	47	49	49	45
present	1	0	0	2
Haemorrhagic cyst				
absent	48	49	49	46
present	0	0	0	1
Hyperplasia glomerulosa				
absent	45	45	46	46
present	3	4	2	1
(moderate)	0	0	1	0
Fat vacuoles				
absent	47	49	48	46
present	1	0	1	1
Haematopoiesis				
absent	48	49	48	47
(minimal)	0	0	1	0

KWG 0519 - Mouse Chronic Toxicity Study
Summary Incidence Table
Non-neoplastic Lesions
Female

	Group 1 Control	Group 2 125ppm	Group 3 500ppm	Group 4 2000ppm
number of animals	50	50	50	50
Adrenal				
Congestion				
absent	48	49	49	46
present	0	0	0	1
Hypertrophy				
absent	48	49	49	46
present	0	0	0	1
Cysts				
absent	48	48	49	46
present	0	1	0	0
Bone (femur)				
number of sections				
no section	2	3	1	4
Inflammation chronic				
absent	48	47	48	46
present	0	0	1	0
Comments				
Unreadable	0	1	1	0

KWG 0519 - Mouse Chronic Toxicity Study
Summary Incidence Table
Non-neoplastic Lesions
Female

	Group 1 Control	Group 2 125ppm	Group 3 500ppm	Group 4 2000ppm
number of animals	50	50	50	50
Bone marrow (femur)				
Haematopoiesis				
absent	49	49	48	44
present	0	0	0	1
(moderate)	0	0	1	1
Hypoplasia				
absent	49	49	48	46
present	0	0	1	0
Brain				
number of sections				
no section	2	6	5	2
Calcification				
absent	48	44	45	47
present	0	0	0	1
Fat vacuoles				
absent	43	44	38	46
present	4	0	4	1
(minimal)	1	0	1	1
(moderate)	0	0	2	0
Gliosis				
absent	46	41	42	47
present	2	3	1	1
(minimal)	0	0	2	0
Haemorrhage				
absent	47	44	44	48
present	1	0	1	0

KWG 0519 - Mouse Chronic Toxicity Study
Summary Incidence Table
Non-neoplastic Lesions
Female

	Group 1 Control	Group 2 125ppm	Group 3 500ppm	Group 4 2000ppm
number of animals	50	50	50	50
Brain				
Congestion				
absent	47	43	44	48
present	1	1	1	0
Meningitis				
absent	48	44	44	48
(minimal)	0	0	1	0
Oedema				
absent	48	44	45	47
present	0	0	0	1
Ventricular dilatation				
absent	47	44	45	48
present	1	0	0	0
Heart				
number of sections				
no section	1	1	0	1
Thrombosis				
absent	47	48	50	47
present	2	1	0	2
Inflammation chronic				
absent	49	49	49	48
present	0	0	1	1
Leukocytosis				
absent	49	48	49	49
present	0	1	1	0
Congestion				
absent	35	41	35	44
present	12	7	15	4
(severe)	2	1	0	1
Dilated chamber				
absent	49	49	48	49
present	0	0	2	0

KWG 0519 - Mouse Chronic Toxicity Study
Summary Incidence Table
Non-neoplastic Lesions
Female

	Group 1 Control	Group 2 125ppm	Group 3 500ppm	Group 4 2000ppm
number of animals	50	50	50	50
Heart				
Pericarditis				
absent	49	48	48	48
present	0	1	2	1
Calcification				
absent	49	48	50	49
(moderate)	0	1	0	0
Hypertrophy				
absent	49	49	50	48
present	0	0	0	1
Kidney				
number of sections				
no section	1	1	0	1
Calcification				
absent	47	49	50	48
present	0	0	0	1
(minimal)	2	0	0	0
Fibrosis				
absent	49	49	49	48
present	0	0	0	1
(minimal)	0	0	1	0
Hydronephrosis				
absent	47	48	49	49
present	2	1	0	0
(severe)	0	0	1	0
Haemorrhage				
absent	49	48	50	49
present	0	1	0	0
(severe)	0	1	0	0

KWG 0519 - Mouse Chronic Toxicity Study
Summary Incidence Table
Non-neoplastic Lesions
Female

	Group 1 Control	Group 2 125ppm	Group 3 500ppm	Group 4 2000ppm
number of animals	50	50	50	50
Kidney				
Congestion				
absent	47	46	47	46
present	1	3	3	2
(minimal)	1	0	0	0
(severe)	0	0	0	1
Tubulopathy				
absent	45	44	46	44
present	2	1	1	5
(minimal)	1	2	1	0
(moderate)	0	1	1	0
(severe)	1	1	1	0
Interstitial nephritis				
absent	27	40	39	36
present	2	1	3	2
(minimal)	15	7	8	10
(moderate)	3	1	0	1
(severe)	2	0	0	0
Cysts				
absent	46	48	43	48
present	2	1	3	1
(minimal)	1	0	4	0
Pyelonephritis				
absent	49	46	49	46
present	0	0	0	2
(minimal)	0	2	0	0
(moderate)	0	1	1	1
Dilatation glomerular loops				
absent	47	46	50	49
present	1	1	0	0
(minimal)	1	1	0	0
(moderate)	0	1	0	0
Dilatation renal pelvis				
absent	48	49	50	49
present	1	0	0	0

KWG 0519 - Mouse Chronic Toxicity Study
Summary Incidence Table
Non-neoplastic Lesions
Female

	Group 1 Control	Group 2 125ppm	Group 3 500ppm	Group 4 2000ppm
number of animals	50	50	50	50
		Kidney		
Progressive nephropathy				
absent	43	46	48	49
present	2	0	0	0
(minimal)	2	2	1	0
(moderate)	0	1	0	0
(severe)	2	0	1	0
Pyelitis				
absent	48	48	50	49
present	1	0	0	0
(severe)	0	1	0	0

KW6 3519 - Mouse Chronic Toxicity Study
Summary Incidence Table
Non-neoplastic Lesions
Female

	Group 1 Control	Group 2 125ppm	Group 3 500ppm	Group 4 2000ppm
number of animals	50	50	50	50
Liver				
number of sections				
no section	2	1	0	1
Infarct				
absent	47	49	47	48
present	1	0	2	1
(severe)	0	0	1	0
Calcification				
absent	47	49	50	49
present	1	0	0	0
Fat vacuoles				
absent	42	49	50	44
present	2	0	0	2
(minimal)	4	0	0	2
(moderate)	0	0	0	1
Necrosis				
absent	48	49	49	49
present	0	0	1	0
Haemorrhage				
absent	48	48	50	49
present	0	1	0	0
Mononuclear cells				
absent	38	43	46	41
present	0	0	0	1
(minimal)	9	6	4	5
(moderate)	1	0	0	1
(severe)	0	0	0	1

KWG 0519 - Mouse Chronic Toxicity Study
Summary Incidence Table
Non-neoplastic Lesions
Female

	Group 1 Control	Group 2 125ppm	Group 3 500ppm	Group 4 2000ppm
number of animals	50	50	50	50
Liver				
Pigmentation				
absent	48	49	49	49
(moderate)	0	0	1	0
Amyloid				
absent	48	48	50	49
present	0	1	0	0
Haematopoiesis				
absent	47	49	50	49
(severe)	1	0	0	0
Congestion				
absent	38	42	40	43
present	9	7	10	5
(severe)	1	0	0	1
Hyperplastic nodule				
absent	46	48	49	45
present	2	1	1	4
Hypertrophy				
absent	47	47	49	48
present	1	2	1	1
Vacuolisation				
absent	42	45	43	49
present	5	1	1	0
(minimal)	1	3	5	0
(moderate)	0	0	1	0
Cysts				
absent	47	49	50	47
present	1	0	0	2
Hepatocytic hyperpigmentation				
absent	43	49	50	44
present	0	0	0	2
(minimal)	5	0	0	3
Haemorrhagic cyst				
absent	47	49	50	49
present	1	0	0	0

KWG 0519 - Mouse Chronic Toxicity Study
Summary Incidence Table
Non-neoplastic Lesions
Female

	Group 1 Control	Group 2 125ppm	Group 3 500ppm	Group 4 2000ppm
number of animals	50	50	50	50
Liver				
Hyperplastic nodules				
absent	48	49	50	46
present	0	0	0	3
Thrombosis				
absent	48	49	50	48
present	0	0	0	1
Periarteritis				
absent	48	49	50	48
present	0	0	0	1
Lung				
number of sections				
no section	1	1	0	1
Thrombosis				
absent	48	48	50	49
present	0	1	0	0
(severe)	1	0	0	0
Oedema				
absent	42	45	44	46
present	3	3	5	2
(severe)	4	1	1	1
Necrosis				
absent	49	48	49	49
present	0	1	1	0
Haemorrhage				
absent	43	48	44	49
present	4	1	5	0
(severe)	2	0	1	0
Adenomatosis				
absent	49	48	50	49
present	0	1	0	0

KWG 0519 - Mouse Chronic Toxicity Study
Summary Incidence Table
Non-neoplastic Lesions
Female

	Group 1 Control	Group 2 125ppm	Group 3 500ppm	Group 4 2000ppm
number of animals	50	50	50	50
		Lung		
Pleuritis				
absent	49	49	50	48
present	0	0	0	1
Pigmentation				
absent	48	49	50	49
(minimal)	1	0	0	0
Pneumonia				
absent	36	42	32	34
present	9	3	13	15
(minimal)	0	0	2	0
(moderate)	0	2	1	0
(severe)	4	2	2	0
Leukocytosis				
absent	49	49	46	49
present	0	0	2	0
(severe)	0	0	2	0
Congestion				
absent	34	40	42	40
present	8	8	7	6
(severe)	7	1	1	3
Atelectasis				
absent	47	44	46	45
present	2	3	2	4
(moderate)	0	0	2	0
(severe)	0	2	0	0
Emphysema				
absent	49	47	50	49
(minimal)	0	1	0	0
(severe)	0	1	0	0
Thickened alveolar walls				
absent	49	46	46	47
present	0	3	3	2
(moderate)	0	0	1	0
Hyperplasia lymphoid				
absent	48	49	50	49
present	1	0	0	0

KWG 0519 - Mouse Chronic Toxicity Study
Summary Incidence Table
Non-neoplastic Lesions
Female

	Group 1 Control	Group 2 125ppm	Group 3 500ppm	Group 4 2000ppm
number of animals	50	50	50	50
Lung				
Osseous metaplasia				
absent	49	48	50	49
present	0	1	0	0
Ovary				
number of sections				
no section	2	2	1	4
Thrombus				
absent	48	48	48	46
present	0	0	1	0
Inflammation acute				
absent	46	46	49	45
present	1	2	0	0
(severe)	1	0	0	1
Inflammation chronic				
absent	47	48	49	46
present	1	0	0	0
Hyperplasia polypoid				
absent	48	48	49	45
present	0	0	0	1
Haemorrhage				
absent	47	48	48	45
present	1	0	1	0
(severe)	0	0	0	1
Pigmentation				
absent	47	48	49	46
present	1	0	0	0
Atrophy				
absent	26	33	25	23
present	22	15	24	23

KWG 0519 - Mouse Chronic Toxicity Study
Summary Incidence Table
Non-neoplastic Lesions
Female

	Group 1 Control	Group 2 125ppm	Group 3 500ppm	Group 4 2000ppm
number of animals	50	50	50	50
		Ovary		
Arteritis				
absent	46	48	49	46
present	2	0	0	0
Cysts				
absent	28	25	25	35
present	20	23	24	11
Hypertrophic corpora lutea				
absent	42	37	47	44
present	6	11	2	2
Cystic follicle				
absent	48	48	49	45
present	0	0	0	1
Haemorrhagic cyst				
absent	45	48	45	40
present	1	0	4	6
(severe)	2	0	0	0
Hyperplasia papillomatous				
absent	48	48	49	45
present	0	0	0	1
Pus				
absent	47	46	49	46
present	1	2	0	0

KWG 3519 - Mouse Chronic Toxicity Study
Summary Incidence Table
Non-neoplastic Lesions
Female

	Group 1 Control	Group 2 125ppm	Group 3 500ppm	Group 4 2000ppm
number of animals	50	50	50	50
		Pancreas		
number of sections				
no section	2	1	2	2
Atrophy				
absent	47	45	47	46
present	1	3	0	2
(moderate)	0	0	1	0
(severe)	0	1	0	0
Oedema				
absent	48	49	47	48
present	0	0	1	0
Fibrosis				
absent	47	49	48	48
present	1	0	0	0
Inflammation chronic				
absent	47	48	45	44
present	1	1	2	4
(moderate)	0	0	1	0
Mononuclear cells				
absent	48	48	48	48
present	0	1	0	0
Congestion				
absent	48	48	48	48
present	0	1	0	0
Vacuolisation				
absent	48	49	47	48
(minimal)	0	0	1	0
Cysts				
absent	48	48	48	48
present	0	1	0	0
Periarteritis				
absent	46	49	47	47
present	2	0	1	1

KWG 0519 - Mouse Chronic Toxicity Study
Full Macro/Micro Report

Rat No: 1
SEX: Male
DOSE LEVEL: 0ppm KWG 0519

MACROSCOPIC FINDINGS

	Mode of death : Interim death
	Days under test : 635
	Date of death : 06/04/80
Lung	Dark red discolouration. Surface yellow areas

MICROSCOPIC FINDINGS

Heart	Congestion (severe)
Kidney/1	Interstitial nephritis (minimal)
	Cysts (moderate)
Kidney/2	Interstitial nephritis (minimal)
	Cysts (moderate)
Lung	Adenomatosis
	Pleuritis (moderate)
Pituitary	No tissue available
Seminal vesicle	Atrophy epithelial
	Coagulum
Testis/1	Calcification (moderate)
	Spermatocoele
Thyroid/1	No tissue available
Thyroid/2	No tissue available
Urinary bladder	Autolysis

KWG 0519 - Mouse Chronic Toxicity Study
Full Macro/Micro Report

Rat No: 2
SEX: Male
DOSE LEVEL: 0ppm KWG 0519

MACROSCOPIC FINDINGS

Mode of death	: Interim death
Days under test	: 715
Date of death	: 25/06/80
Condition at necropsy	Moribund
Cranium	Indurated
Lung	Loo. suc. extr: Grey hard nodule (0.3cm diam)
Seminal vesicle	Enlarged

MICROSCOPIC FINDINGS

Adrenal/1	Hyperplastic nodule
Kidney/1	Interstitial nephritis (minimal)
	Cysts (moderate)
Kidney/2	Interstitial nephritis (minimal)
	Cysts (moderate)
Lung	MALIGNANT TUMOUR alveogenic carcinoma
Pancreas	Hyperplasia islets
Spleen	Hyperplasia lymphoid
Testis/1	Atrophy seminiferous tubules (moderate)
	Calcification (minimal)
Testis/2	Atrophy seminiferous tubules (moderate)

KWG 0519 - Mouse Chronic Toxicity Study
Full Macro/Micro Report

Rat No: 3
SEX: Male
DOSE LEVEL: 0ppm KWG 0519

MACROSCOPIC FINDINGS

	Mode of death : Interim death
	Days under test : 720
	Date of death : 30/06/80
Kidney	Cysts
Liver	Enlarged
Lung	Lob. sin: Enlarged swollen hard Flesh coloured Lob. suo. dxtr: White hard nodule (0.4cm diam)

MICROSCOPIC FINDINGS

Kidney/1	Interstitial nephritis (minimal) Cysts (severe)
Kidney/2	Interstitial nephritis (minimal) Cysts (severe)
Liver	Necrosis (severe) Hepatocytic hyperpigmentation Hyperplastic nodules
Lung	MALIGNANT TUMOUR alveogenic carcinoma
Pituitary	No tissue available
Spleen	Haematopoiesis (moderate)
Stomach	Mononuclear cells (moderate)
Thyroid/1	No tissue available
Thyroid/2	No tissue available
Urinary bladder	Hyperplasia

KWG 0519 - Mouse Chronic Toxicity Study
Full Macro/Micro Report

Rat No: 4
SEX: Male
DOSE LEVEL: 0ppm KWG 0519

MACROSCOPIC FINDINGS

Mode of death : Interim death
Days under test : 709
Date of death : 19/06/80

Condition at necropsy	Autolysis (few organs)
Lung	Dark/red coloured

MICROSCOPIC FINDINGS

Adrenal/1	Unreadable
Adrenal/2	Unreadable
Heart	Congestion
Kidney/1	Cysts (minimal)
Liver	Hyperplastic nodules
Lung	Pneumonia (moderate)
Sciatic nerve	Unreadable
Skeletal muscle	Unreadable
Testis/1	Atrophy seminiferous tubules (minimal)
Thyroid/1	No tissue available
Thyroid/2	No tissue available

KWG 0519 - Mouse Chronic Toxicity Study
Full Macro/Micro Report

Rat No: 5
SEX: Male
DOSE LEVEL: 0ppm KWG 0519

MACROSCOPIC FINDINGS

	Mode of death : Terminal kill
	Days under test : 734
	Date of death : 14/07/80
Kidney	Cysts (0.1-0.2cm diam)
Lung	Loc. sin: Beige foci (0.1cm diam)

MICROSCOPIC FINDINGS

Brain	Gliosis
Kidney/1	Interstitial nephritis (minimal)
	Cysts (minimal)
Kidney/2	Interstitial nephritis (minimal)
	Cysts (minimal)
Liver	Hyperplastic nodules
Lung	Atelectasis
Seminal vesicle	Normal
Spleen	Haematopoiesis (moderate)
Stomach	Inflammation chronic (moderate)
	Mucoid cyst (severe)
Thyroid/1	No tissue available
Thyroid/2	No tissue available
Urinary bladder	No tissue available

KWG 0519 - Mouse Chronic Toxicity Study
Full Macro/Micro Report

Rat No: 6
SEX: Male
DOSE LEVEL: 0ppm KWG 0519

MACROSCOPIC FINDINGS

Mode of death	: Interim death
Days under test	: 715
Date of death	: 25/06/80
Condition at necropsy	Moribund
Adrenal gland	Left: Enlarged
Kidney	Left: Cysts
Liver	Clay coloured
Lung	Lob. sin: White area (0.1cm diam)
	Lob. dxtr: Reddish colouration
Seminal vesicle	Enlarged
Spleen	Mottled surface

MICROSCOPIC FINDINGS

Adrenal/1	MALIGNANT LYMPHOMA
Adrenal/2	MALIGNANT LYMPHOMA
Heart	Inflammation chronic
Kidney/1	Progressive nephropathy (moderate)
	MALIGNANT LYMPHOMA
Kidney/2	Progressive nephropathy (moderate)
	MALIGNANT LYMPHOMA
Liver	Amyloid (severe)
	Hyperplastic nodule
Lung	Atelectasis
Pituitary	No tissue available
Seminal vesicle	Atrophy epithelial
	Coagulum
Skeletal muscle	MALIGNANT LYMPHOMA
Spleen	Haemorrhagic cyst (severe)
	MALIGNANT LYMPHOMA
Urinary bladder	MALIGNANT LYMPHOMA
Bone marrow	Hyperplasia megakaryocytic

KWG 0519 - Mouse Chronic Toxicity Study
Full Macro/Micro Report

Rat No: 7
SEX: Male
DOSE LEVEL: Oppm KWG 0519

MACROSCOPIC FINDINGS

	Mode of death : Interim death
	Days under test : 666
	Date of death : 07/05/80
Liver	Clay coloured
Lung	Surrounded by blood clots
Pituitary	Watery cysts (0.3cm diam)
Seminal vesicle	Enlarged
Spleen	Enlarged (2.3 x 0.5cm)

MICROSCOPIC FINDINGS

Kidney/1	Interstitial nephritis (minimal)
Kidney/2	Interstitial nephritis (minimal)
Liver	Hyperplasia focal
	Hyperplastic nodules
Lung	Pneumonia (moderate)
Spleen	Hyperplasia lymphoid
	Haematopoiesis (moderate)
Testis/1	Atrophy seminiferous tubules (minimal)
	Calcification
Thyroid/1	Cysts (minimal)
Thyroid/2	Cysts (minimal)
Thymus	MALIGNANT LYMPHOMA

KWG 0519 - Mouse Chronic Toxicity Study
Full Macro/Micro Report

Rat No: 8
SEX: Male
DOSE LEVEL: 0ppm KWG 0519

MACROSCOPIC FINDINGS

	Mode of death : Interim death
	Days under test : 708
	Date of death : 18/06/80
Condition at necropsy	Autolysis (numerous organs)
Kidney	Increased and indurated peri renal adipose tissue
Seminal vesicle	Enlarged

MICROSCOPIC FINDINGS

Brain	No tissue available
Heart	Congestion
	Dilated chamber
Liver	Autolysis
Lung	MALIGNANT TUMOUR alveogenic carcinoma
Pancreas	No tissue available
Pituitary	No tissue available
Seminal vesicle	Autolysis (partial)
	Atrophy epithelial
	Coagulum
Spleen	Autolysis (partial)
Stomach	Autolysis (partial)
Testis/1	No tissue available
Testis/2	No tissue available
Thyroid/1	No tissue available
Thyroid/2	No tissue available
Urinary bladder	Autolysis (partial)
Mesentery	BENIGN TUMOUR fibromyxoma

KWG 0519 - Mouse Chronic Toxicity Study
Full Macro/Micro Report

Rat No: 9
SEX: Male
DOSE LEVEL: Oppm KWG 0519

MACROSCOPIC FINDINGS

	Mode of death : Interim death
	Days under test : 694
	Date of death : 04/06/90
Lung	Dark/red foci/areas
Spleen	Clay coloured
Urinary bladder	Enlarged (1.0cm diam) Haemorrhagic contents

MICROSCOPIC FINDINGS

Heart	Congestion
Kidney/1	Interstitial nephritis (minimal)
	Pyelitis (moderate)
Kidney/2	Interstitial nephritis (minimal)
Lung	Congestion (severe)
Spleen	Pigmentation
Stomach	Inflammation chronic (moderate)
Thyroid/1	Cysts (moderate)
Thyroid/2	Cysts (moderate)
Urinary bladder	No tissue available

KWG 0519 - Mouse Chronic Toxicity Study
Full Macro/Micro Report

Rat No: 10
SEX: Male
DOSE LEVEL: 0ppm KWG 0519

MACROSCOPIC FINDINGS

Mode of death	: Interim death
Days under test	: 441
Date of death	: 25/09/79
Condition at necropsy	Moribund
General observations	Skin above base of tail inflamed
Spleen	Enlarged (2.5 x 0.6cm)

MICROSCOPIC FINDINGS

Kidney/1	Interstitial nephritis (minimal)
Pituitary	No tissue available
Spleen	Haematopoiesis (moderate)
Urinary bladder	Hyperplasia papillomatous
Lymph node	Hyperplasia lymphoid

KWG 0519 - Mouse Chronic Toxicity Study
Full Macro/Micro Report

Rat No: 11
SEX: Male
DOSE LEVEL: 0ppm KWG 0519

MACROSCOPIC FINDINGS

	Mode of death : Interim death
	Days under test : 714
	Date of death : 24/06/80
Cranium	Indurated
	Hard white nodule base of cranium
Lung	Dark/red foci/areas

MICROSCOPIC FINDINGS

Heart	Inflammation chronic
	Congestion
Kidney/1	Calcification
	Interstitial nephritis (minimal)
Kidney/2	Calcification
	Interstitial nephritis (minimal)
Liver	Mononuclear cells (minimal)
Lung	Pneumonia (moderate)
	Congestion
Pancreas	Inflammation chronic (minimal)
Pituitary	No tissue available
Spleen	Hyperplasia lymphoid
Stomach	Unreadable
Testis/1	Spermatocoele
Urinary bladder	hyperplasia papillomatous
Bone	BENIGN TUMOUR osteoma
Thymus	MALIGNANT LYMPHOMA

KWG 0519 - Mouse Chronic Toxicity Study
Full Macro/Micro Report

Rat No: 12
SEX: Male
DOSE LEVEL: Oppa KWG 0519

MACROSCOPIC FINDINGS

	Mode of death : Interim death
	Days under test : 619
	Date of death : 21/03/80
Liver	Enlarged swollen grey-white-beige surface foci
Lung	Dark/red foci/areas
Spleen	Enlarged (2.4 x 0.5cm)

MICROSCOPIC FINDINGS

Heart	Haemorrhage (minimal)
	Mononuclear cells (minimal)
Kidney/1	Autolysis (partial)
Kidney/2	Autolysis (partial)
Liver	MALIGNANT LYMPHOMA
Lung	Congestion (severe)
Pancreas	Autolysis (partial)
Spleen	MALIGNANT LYMPHOMA
Stomach	Autolysis (partial)
Testis/1	Calcification (minimal)
	Spermatocoele (minimal)
Testis/2	Spermatocoele (minimal)
Urinary bladder	Autolysis (partial)

KWG 0519 - Mouse Chronic Toxicity Study
Full Macro/Micro Report

Rat No: 13
SEX: Male
DOSE LEVEL: 0ppm KWG 0519

MACROSCOPIC FINDINGS

	Mode of death : Terminal kill
	Days under test : 734
	Date of death : 14/07/80
Seminal vesicle	Enlarged (5.0cm diam)

MICROSCOPIC FINDINGS

Adrenal/1	Pigmentation (minimal)
Kidney/1	Interstitial nephritis (minimal)
	Cysts (minimal)
Kidney/2	Interstitial nephritis (minimal)
	Cysts (minimal)
Liver	Pigmentation
Lung	Atelectasis
Seminal vesicle	Atrophy epithelial
	Ectasia simple
	Coagulum
Testis/1	Atrophy seminiferous tubules (moderate)
	Calcification
Testis/2	Atrophy seminiferous tubules (moderate)
	Calcification
Thyroid/1	No tissue available
Thyroid/2	No tissue available

KWG 0519 - Mouse Chronic Toxicity Study
Full Macro/Micro Report

Rat No: 14
SEX: Male
DOSE LEVEL: 0ppm KWG 0519

MACROSCOPIC FINDINGS

	Mode of death : Interim death
	Days under test : 309
	Date of death : 16/05/79
Condition at necropsy	Autolysis (numerous organs)
Thymus	Grey hard nodule (1.4 x 0.6cm)

MICROSCOPIC FINDINGS

Adrenal/1	Autolysis (partial)
	Pigment
Adrenal/2	Autolysis (partial)
Brain	Autolysis
Heart	Autolysis (partial)
Kidney/1	Autolysis
Kidney/2	Autolysis
Liver	Autolysis
Lung	Autolysis
Pancreas	Autolysis
Pituitary	No tissue available
Sciatic nerve	Autolysis (partial)
Skeletal muscle	Autolysis (partial)
Spleen	Autolysis (partial)
	MALIGNANT LYMPHOMA
Stomach	Autolysis
Testis/1	Autolysis (partial)
Testis/2	Autolysis (partial)
Thyroid/1	No tissue available
Thyroid/2	No tissue available
Urinary bladder	Autolysis
Thymus	No tissue available

KWG 0519 - Mouse Chronic Toxicity Study
Full Macro/Micro Report

Rat No: 15
SEX: Male
DOSE LEVEL: 0ppm KWG 0519

MACROSCOPIC FINDINGS

	Mode of death : Interim death
	Days under test : 668
	Date of death : 09/05/80
Kidney	Left: Discoloured indurated area (0.3cm diam)
Lung	Flesh coloured
Testis	Right: Enlarged indurated

MICROSCOPIC FINDINGS

Heart	Fibrosis (minimal)
Kidney/1	Calcification
	Haemorrhage (severe)
	Interstitial nephritis (minimal)
	Cysts
	Dilatation glomerular loops (moderate)
Kidney/2	Interstitial nephritis (minimal)
	Dilatation glomerular loops (moderate)
Liver	Necrosis
	Congestion
Lung	Pneumonia (moderate)
Pituitary	No tissue available
Spleen	Haematopoiesis (severe)
	Congestion (severe)
Testis/1	BENIGN TUMOUR interstitial cell tumour
	Calcification
Thyroid/1	No tissue available
Thyroid/2	No tissue available
Urinary bladder	Inflammation chronic (moderate)

KWG 0519 - Mouse Chronic Toxicity Study
Full Macro/Micro Report

Rat No: 16
SEX: Male
DOSE LEVEL: 0ppm KWG 0519

MACROSCOPIC FINDINGS

	Mode of death : Terminal kill
	Days under test : 734
	Date of death : 14/07/80
Heart	Atrium thickened
Kidney	Clay coloured
	Cysts (0.1-0.7cm diam)
Liver	Lob. sin: Thickening (1.0cm diam)
	Lob. caud: Thickening (2.0 x 1.0cm)
Lung	Lob. sin: White hard area (0.3cm diam)

MICROSCOPIC FINDINGS

Bone (femur)	No tissue available
Heart	Fibrosis (minimal)
	Inflammation chronic (minimal)
Kidney/1	Progressive nephropathy (severe)
Kidney/2	Progressive nephropathy (severe)
Liver	BENIGN TUMOUR hepatocellular adenoma
	Hyperplastic nodules
Lung	MALIGNANT TUMOUR alveogenic carcinoma
	Pneumonia (moderate)
Spleen	Haematopoiesis (severe)
Testis/1	Atrophy seminiferous tubules (moderate)
	Calcification (moderate)
	Spermatocoele (minimal)
Testis/2	Atrophy seminiferous tubules (moderate)
	Spermatocoele (minimal)
Thyroid/1	No tissue available
Thyroid/2	No tissue available

KWG 0519 - Mouse Chronic Toxicity Study
Full Macro/Micro Report

Rat No: 17
SEX: Male
DOSE LEVEL: 0ppm KWG 0519

MACROSCOPIC FINDINGS

	Mode of death : Interim death
	Days under test : 267
	Date of death : 04/04/79
Lung	Lob. dxtr: Fleshy areas
Stomach	Mucosal bleeding

MICROSCOPIC FINDINGS

Heart	Congestion
Kidney/1	Congestion
Kidney/2	Congestion
Lung	Atelectasis
Pancreas	Autolysis (partial)
Stomach	No tissue available
Thyroid/1	No tissue available
Thyroid/2	No tissue available
Urinary bladder	Hyperplasia papillomatous

KWG 0519 - Mouse Chronic Toxicity Study
Full Macro/Micro Report

Rat No: 18
SEX: Male
DOSE LEVEL: 0ppm KWG 0519

MACROSCOPIC FINDINGS

Mode of death	: Interim death
Days under test	: 659
Date of death	: 30/04/80
Adrenal gland	Left: Pale, enlarged
Kidney	Pale
Liver	Enlarged
Lung	Dark/red coloured
Seminal vesicle	Enlarged
Spleen	Enlarged (2.3 x 0.6cm)
Urinary bladder	Enlarged (1.2cm diam)

MICROSCOPIC FINDINGS

Heart	Congestion
Kidney/1	Hydronephrosis (moderate)
	Progressive nephropathy (moderate)
Kidney/2	Hydronephrosis (moderate)
	Progressive nephropathy (moderate)
Liver	Normal
Lung	Congestion
Spleen	Haematopoiesis (severe)
Stomach	Autolysis (partial)
Urinary bladder	Autolysis (partial)
Lymph node	MALIGNANT LYMPHOMA

KWG 0519 - Mouse Chronic Toxicity Study
Full Macro/Micro Report

Rat No: 19
SEX: Male
DOSE LEVEL: 0ppm KWG 0519

MACROSCOPIC FINDINGS

	Mode of death : Terminal kill
	Days under test : 734
	Date of death : 14/07/80
Kidney	Cysts (0.1-0.3cm diam)

MICROSCOPIC FINDINGS

Adrenal/1	No tissue available
Adrenal/2	No tissue available
Heart	Fibrosis (moderate)
	Inflammation chronic (moderate)
Kidney/1	Cysts (moderate)
Kidney/2	Cysts (moderate)
Lung	Atelectasis
Thyroid/1	No tissue available
Thyroid/2	No tissue available

KWG 0519 - Mouse Chronic Toxicity Study
Full Macro/Micro Report

Rat No: 2C
SEX: Male
DOSE LEVEL: 0ppm KWG 0519

MACROSCOPIC FINDINGS

Mode of death	: Interim death
Days under test	: 612
Date of death	: 14/03/80
General observations	Obese

MICROSCOPIC FINDINGS

Heart	Congestion
Lung	MALIGNANT TUMOUR alveogenic carcinoma
Pituitary	No tissue available
Stomach	Autolysis
Thyroid/1	Autolysis (partial)
Thyroid/2	Autolysis (partial)
Urinary bladder	Autolysis

KWG 0519 - Mouse Chronic Toxicity Study
Full Macro/Micro Report

Rat No: 21
SEX: Male
DOSE LEVEL: Oppm KWG 0519

MACROSCOPIC FINDINGS

Mode of death	: Interim death
Days under test	: 64
Date of death	: 12/04/80
Condition at necropsy	Autolysis (few organs)
Adrenal gland	Left: Enlarged
Lung	Flesh coloured
Spleen	Enlarged (3.1-1.0cm) white-grey marbled surface

MICROSCOPIC FINDINGS

Adrenal/1	MALIGNANT LYMPHOMA
Adrenal/2	MALIGNANT LYMPHOMA
Kidney/1	Hydronephrosis (minimal)
	MALIGNANT LYMPHOMA
Kidney/2	MALIGNANT LYMPHOMA
Liver	MALIGNANT LYMPHOMA
Lung	Pneumonia (moderate)
Pancreas	Autolysis (partial)
Pituitary	No tissue available
Spleen	Haemorrhage
	MALIGNANT LYMPHOMA
Stomach	Autolysis (partial)
Thyroid/1	No tissue available
Thyroid/2	No tissue available
Urinary bladder	Autolysis (partial)
Lymph node	MALIGNANT LYMPHOMA
Mesentery	MALIGNANT LYMPHOMA

KWG 0519 - Mouse Chronic Toxicity Study
Full Macro/Micro Report

Rat No: 22
SEX: Male
DOSE LEVEL: Oppm KWG 0519

MACROSCOPIC FINDINGS

	Mode of death : Terminal kill
	Days under test : 734
	Date of death : 14/07/80
Kidney	Left: Cysts (0.2cm diam)
Lung	Lob. sin: Focal cysts

MICROSCOPIC FINDINGS

Adrenal/1	BENIGN TUMOUR cortical adenoma
Kidney/1	Interstitial nephritis (minimal)
	Cysts (moderate)
Kidney/2	Interstitial nephritis (minimal)
Lung	Atelectasis
Spleen	Haematopoiesis (minimal)
Testis/1	Atrophy seminiferous tubules (moderate)
Testis/2	Atrophy seminiferous tubules (moderate)
Thyroid/1	No tissue available
Thyroid/2	No tissue available

KWG 0519 - Mouse Chronic Toxicity Study
Full Macro/Micro Report

Rat No: 23
SEX: Male
DOSE LEVEL: Oppa KWG 0519

MACROSCOPIC FINDINGS

Mode of death	: Interim death
Days under test	: 678
Date of death	: 19/05/80
Condition at necropsy	Autolysis (few organs)
Intestine	Red-brown contents
Lung	Dark foci/areas
Stomach	Mucosal bleeding

MICROSCOPIC FINDINGS

Heart	Congestion
Kidney/1	Interstitial nephritis (minimal)
Lung	MALIGNANT TUMOUR alveogenic carcinoma
Spleen	Pigmentation
	MALIGNANT LYMPHOMA
Stomach	Normal
Thyroid/1	No tissue available
Thyroid/2	No tissue available
Intestine	Normal

KWG 0519 - Mouse Chronic Toxicity Study
Full Macro/Micro Report

Rat No: 24
SEX: Male
DOSE LEVEL: 0ppm KWG 0519

MACROSCOPIC FINDINGS

	Mode of death : Terminal kill
	Days under test : 734
	Date of death : 14/07/80
Kidney	Cysts (0.1-0.2cm diam)
Lung	Loo. inf. dxtr. lat: White thickening (0.5 x 0.3cm)
Pancreas	Indurated

MICROSCOPIC FINDINGS

Adrenal/1	No tissue available
Adrenal/2	No tissue available
Brain	Gliosis
Kidney/1	Interstitial nephritis (minimal)
	Cysts (minimal)
Kidney/2	Interstitial nephritis (minimal)
	Cysts (minimal)
Lung	MALIGNANT TUMOUR alveogenic carcinoma
Pancreas	Normal
Pituitary	No tissue available
Spleen	Haematopoiesis (severe)
Testis/1	Pigmentation (minimal)
Testis/2	Pigmentation (minimal)
Mesentery	Inflammation chronic

KWG 0519 - Mouse Chronic Toxicity Study
Full Macro/Micro Report

Rat No: 25
SEX: Male
DOSE LEVEL: Oppm KWG 0519

MACROSCOPIC FINDINGS

	Mode of death : Interim death
	Days under test : 573
	Date of death : 04/02/80
Liver	Enlarged
Lung	Lob. sin: Whitish brown nodule (1.2cm diam)
	Dark/red foci/areas
	Lob. inf. dxtr. lat: White hard nodule (0.2cm diam)

MICROSCOPIC FINDINGS

Brain	Autolysis (partial)
Kidney/1	Congestion (severe)
	Interstitial nephritis (minimal)
Kidney/2	Congestion (severe)
	Interstitial nephritis (minimal)
Liver	MALIGNANT TUMOUR hepatocellular adenocarcinoma
	BENIGN TUMOUR hepatocellular adenoma
Lung	MALIGNANT TUMOUR alveogenic carcinoma
	Congestion (severe)
Pancreas	Hyperplasia islets
Pituitary	Unreadable
Sciatic nerve	No tissue available
Skeletal muscle	No tissue available
Spleen	Haematopoiesis
Testis/1	Atrophy seminiferous tubules
Testis/2	Atrophy seminiferous tubules

KWG 0519 - Mouse Chronic Toxicity Study
Full Macro/Micro Report

Rat No: 26
SEX: Male
DOSE LEVEL: Oppm KWG 0519

MACROSCOPIC FINDINGS

	Mode of death : Terminal kill
	Days under test : 734
	Date of death : 14/07/80
Kidney	Left: Cysts, flattened

MICROSCOPIC FINDINGS

Adrenal/1	No tissue available
Adrenal/2	No tissue available
Heart	Fibrosis (minimal)
Kidney/1	Interstitial nephritis (minimal)
	Cysts (minimal)
Kidney/2	Interstitial nephritis (minimal)
	Cysts (minimal)
Pituitary	No tissue available
Sciatic nerve	No tissue available

KWG 0519 - Mouse Chronic Toxicity Study
Full Macro/Micro Report

Rat No: 27
SEX: Male
DOSE LEVEL: 0ppm KWG 0519

MACROSCOPIC FINDINGS

	Mode of death : Terminal kill
	Days under test : 734
	Date of death : 14/07/80
Liver	Proc. pap: Clay coloured conglomerate (0.5cm diam)
Lung	Lob. sin: Nodule (0.25cm diam)

MICROSCOPIC FINDINGS

Kidney/1	Interstitial nephritis (minimal)
Kidney/2	Interstitial nephritis (minimal)
Liver	BENIGN TUMOUR hepatocellular adenoma
	Mononuclear cells (moderate)
	Amyloid
Lung	MALIGNANT TUMOUR alveogenic carcinoma
	Pneumonia (minimal)
Pituitary	No tissue available
Spleen	Haematopoiesis (severe)
Stomach	Inflammation chronic (minimal)
Urinary bladder	Hyperplasia papillomatous

KWG 0519 - Mouse Chronic Toxicity Study
Full Macro/Micro Report

Rat No: 28
SEX: Male
DOSE LEVEL: 0ppm KWG 0519

MACROSCOPIC FINDINGS

Mode of death	: Interim death
Days under test	: 397
Date of death	: 28/02/80
General observations	Obese
Liver	Accentuated lobular marking
Urinary bladder	Enlarged (1.4cm diam)

MICROSCOPIC FINDINGS

Kidney/1	Interstitial nephritis (minimal)
Kidney/2	Interstitial nephritis (minimal)
Lung*	No tissue available
Urinary bladder	No tissue available

KWG 0519 - Mouse Chronic Toxicity Study
Full Macro/Micro Report

Rat No: 29
SEX: Male
DOSE LEVEL: Oppm KWG 0519

MACROSCOPIC FINDINGS

Mode of death	: Interim death
Days under test	: 200
Date of death	: 27/01/79
Lung	Fleshy
Cervical lymph node	Enlarged

MICROSCOPIC FINDINGS

Heart	Congestion
Kidney/1	Autolysis (partial)
Kidney/2	Autolysis (partial)
Liver	Congestion
	Hepatocytic hyperpigmentation
Lung	Oedema
	MALIGNANT LYMPHOMA
Pancreas	No tissue available
Spleen	MALIGNANT LYMPHOMA
Stomach	Autolysis (partial)
Urinary bladder	No tissue available
Lymph node	MALIGNANT LYMPHOMA

KWG 0519 - Mouse Chronic Toxicity Study
Full Macro/Micro Report

Rat No: 30
SEX: Male
DOSE LEVEL: 0ppm KWG 0519

MACROSCOPIC FINDINGS

	Mode of death : Interim death
	Days under test : 584
	Date of death : 15/02/80
Lung	Flesh coloured
	Lob. sin: White hard nodule (0.2cm diam)
	Lob. sup. dxtr: White hard
Spleen	Enlarged (3.6 x 1.1cm)
Lymph nodes	Enlarged

MICROSCOPIC FINDINGS

Bone (femur)	No tissue available
Heart	MALIGNANT LYMPHOMA
Kicney/1	MALIGNANT LYMPHOMA
Kidney/2	MALIGNANT LYMPHOMA
Liver	MALIGNANT LYMPHOMA
Lung	MALIGNANT TUMOUR alveogenic carcinoma
	Pigmentation
	MALIGNANT LYMPHOMA
Pancreas	MALIGNANT LYMPHOMA
Pituitary	No tissue available
Sciatic nerve	No tissue available
Skeletal muscle	MALIGNANT LYMPHOMA
Spleen	MALIGNANT LYMPHOMA
Stomach	MALIGNANT LYMPHOMA
Lymph node	MALIGNANT LYMPHOMA
Mesentery	MALIGNANT LYMPHOMA

KWG 0519 - Mouse Chronic Toxicity Study
Full Macro/Micro Report

Rat No: 31
SEX: Male
DOSE LEVEL: Oppm KWG 0519

MACROSCOPIC FINDINGS

	Mode of death : Terminal kill
	Days under test : 734
	Date of death : 14/07/80
Adrenal gland	Right: Enlarged (0.3cm diam)
Kidney	Left: Soft yellowish nodule (0.3cm) in adjacent adipose tissue
Liver	Clay coloured

MICROSCOPIC FINDINGS

Adrenal/1	BENIGN TUMOUR cortical adenoma
Heart	Thickening endocardium (minimal)
Kidney/1	Interstitial nephritis (minimal)
	Cysts
Kidney/2	Interstitial nephritis (minimal)
Liver	Hyperplastic nodules
Lung	MALIGNANT TUMOUR alveogenic carcinoma
Pituitary	Unreadable
Stomach	Inflammation chronic
Testis/1	Calcification (minimal)
Testis/2	Calcification (minimal)
Fat	BENIGN TUMOUR lipoma

KWG 0519 - Mouse Chronic Toxicity Study
Full Macro/Micro Report

Rat No: 32
SEX: Male
DOSE LEVEL: Oppm KWG 0519

MACROSCOPIC FINDINGS

Mode of death	: Interim death
Days under test	: 573
Date of death	: 04/02/80
General observations	Obese
Liver	Accentuated lobular marking
Lung	Lob. sup. dxtr: White hard nodule (0.2cm diam)
Pituitary	Enlarged (0.25cm diam)

MICROSCOPIC FINDINGS

Heart	Congestion
Kidney/i	Hydronephrosis (minimal)
Lung	MALIGNANT TUMOUR alveogenic carcinoma
Pituitary	Normal
Urinary bladder	Autolysis (partial)

KWG 0519 - Mouse Chronic Toxicity Study
Full Macro/Micro Report

Rat No: 33
SEX: Male
DOSE LEVEL: Oppm KWG 0519

MACROSCOPIC FINDINGS

	Mode of death : Terminal kill
	Days under test : 734
	Date of death : 14/07/80
Kidney	Surface raised areas
Liver	Proc. pap: Soft discoloured conglomerate
Spleen	Discoloured hardening (0.4cm diam)

MICROSCOPIC FINDINGS

Adrenal/1	Pigmentation (minimal)
Kidney/1	Interstitial nephritis (severe)
Kidney/2	Interstitial nephritis (severe)
Liver	BENIGN TUMOUR hepatocellular adenoma
	Mononuclear cells (minimal)
	Hyperplastic nodules
Pancreas	No tissue available
Spleen	Haematopoiesis (moderate)
Stomach	No tissue available
Testis/1	Calcification (moderate)
Testis/2	Calcification (moderate)

KWG 0519 - Mouse Chronic Toxicity Study
Full Macro/Micro Report

Rat No: 34
SEX: Male
DOSE LEVEL: Oppm KWG 0519

MACROSCOPIC FINDINGS

	Mode of death : Interim death
	Days under test : 715
	Date of death : 25/06/80
Condition at necropsy	Moribund
Liver	Clay coloured
Lung	Lob. inf. dxtr. lat: Hard grey nodule (0.4cm diam)
Seminal vesicle	Right: Hard to soft haemorrhagic nodule soft brown and green mass (1.6cm diam)

MICROSCOPIC FINDINGS

Kidney/1	Interstitial nephritis (minimal)
	Cysts (moderate)
Kidney/2	Interstitial nephritis (minimal)
	Cysts (moderate)
Liver	MALIGNANT TUMOUR hepatocellular adenocarcinoma
	Calcification (severe)
	Vacuolisation
	Hepatocytic hyperpigmentation
Lung	MALIGNANT TUMOUR alveogenic carcinoma
Seminal vesicle	Atrophy epithelial
	Ectasia simple
	Coagulum
Testis/1	Atrophy seminiferous tubules (minimal)
Thyroid/1	No tissue available
Thyroid/2	No tissue available

KWG 0519 - Mouse Chronic Toxicity Study
Full Macro/Micro Report

Rat No: 35
SEX: Male
DOSE LEVEL: 0ppm KWG 0519

MACROSCOPIC FINDINGS

	Mode of death : Terminal kill
	Days under test : 734
	Date of death : 14/07/80
Lung	Lob. sin: Light beige thickening (0.2cm diam) with several dark foci (0.1-0.2cm diam)
Pancreas	Thickened
Spleen	Reduced in size (1.2 x 0.2cm)

MICROSCOPIC FINDINGS

Adrenal/1	No tissue available
Adrenal/2	No tissue available
Kidney/1	Interstitial nephritis (minimal)
Kidney/2	Interstitial nephritis (minimal)
Lung	MALIGNANT TUMOUR alveogenic carcinoma
Pancreas	Normal
Thyroid/1	No tissue available
Thyroid/2	No tissue available

KWG 0519 - Mouse Chronic Toxicity Study
Full Macro/Micro Report

Rat No: 36
SEX: Male
DOSE LEVEL: 0ppm KWG 0519

MACROSCOPIC FINDINGS

	Mode of death : Interim death
	Days under test : 671
	Date of death : 12/05/80
Condition at necropsy	Autolysis (numerous organs)
Lung	Lob. dxtr: Soft yellow nodule (0.8cm diam)

MICROSCOPIC FINDINGS

Brain	No tissue available
Kidney/1	Interstitial nephritis (moderate)
Kidney/2	Interstitial nephritis (moderate)
Liver	Autolysis (partial)
	MALIGNANT TUMOUR hepatocellular adenocarcinoma
Lung	MALIGNANT TUMOUR alveogenic carcinoma
Pancreas	Autolysis (partial)
	Unreadable
Pituitary	No tissue available
Spleen	Pigmentation
Stomach	Autolysis (partial)
Thyroid/1	Autolysis (partial)
Thyroid/2	Autolysis (partial)
Urinary bladder	Autolysis (partial)

KWG 0519 - Mouse Chronic Toxicity Study
Full Macro/Micro Report

Rat No: 37
SEX: Male
DOSE LEVEL: Oppm KWG 0519

MACROSCOPIC FINDINGS

	Mode of death : Interim death
	Days under test : 85
	Date of death : 04/10/78
Condition at necropsy	Autolysis (numerous organs)
	No significant findings noted

MICROSCOPIC FINDINGS

Adrenal/1	Autolysis
Adrenal/2	Autolysis
Brain	No tissue available
Heart	Autolysis
Kidney/1	Autolysis
Kidney/2	Autolysis
Liver	Autolysis
Lung	Autolysis
Pancreas	Autolysis
Pituitary	No tissue available
Sciatic nerve	Autolysis
Skeletal muscle	Autolysis
Spleen	Autolysis
Stomach	Autolysis
Testis/1	Autolysis
Testis/2	Autolysis
Thyroid/1	Autolysis
Thyroid/2	Autolysis
Urinary bladder	Autolysis

KWG 0519 - Mouse Chronic Toxicity Study
Full Macro/Micro Report

Rat No: 38
SEX: Male
DOSE LEVEL: 0ppm KWG 0519

MACROSCOPIC FINDINGS

Mode of death	: Interim death
Days under test	: 639
Date of death	: 10/04/80
Abdominal cavity	Haemorrhagic fluid
Lung	Dark/red coloured
Pancreas	Nodular hardening
Spleen	Enlarged (3.3 x 0.9cm) mottled
Thymus	Enlarged

MICROSCOPIC FINDINGS

Adrenal/1	MALIGNANT LYMPHOMA
Acrenal/2	MALIGNANT LYMPHOMA
Bone (femur)	No tissue available
Kidney/1	MALIGNANT LYMPHOMA
Kidney/2	MALIGNANT LYMPHOMA
Liver	MALIGNANT LYMPHOMA
Lung	MALIGNANT LYMPHOMA
Pancreas	MALIGNANT LYMPHOMA
Pituitary	No tissue available
Spleen	MALIGNANT LYMPHOMA
Stomach	MALIGNANT LYMPHOMA
Testis/1	Atrophy seminiferous tubules
	Calcification
Urinary bladder	MALIGNANT LYMPHOMA
Thymus	MALIGNANT LYMPHOMA

KWG 0519 - Mouse Chronic Toxicity Study
Full Macro/Micro Report

Rat No: 39
SEX: Male
DOSE LEVEL: 0ppm KWG 0519

MACROSCOPIC FINDINGS

	Mode of death : Interim death
	Days under test : 696
	Date of death : 06/06/80
Condition at necropsy	Autolysis (numerous organs)
Lung	Black discolouration

MICROSCOPIC FINDINGS

Brain	No tissue available
Heart	Autolysis (partial)
	Thrombosis
	Congestion
Kidney/1	Interstitial nephritis (minimal)
Kidney/2	Interstitial nephritis (minimal)
Liver	Autolysis (partial)
Lung	Autolysis (partial)
	MALIGNANT TUMOUR alveogenic carcinoma
Pancreas	Unreadable
Pituitary	No tissue available
Spleen	Autolysis (partial)
Stomach	Autolysis (partial)
Thyroid/1	No tissue available
Thyroid/2	No tissue available
Urinary bladder	Autolysis (partial)

KWG 0519 - Mouse Chronic Toxicity Study
Full Macro/Micro Report

Rat No: 40
SEX: Male
DOSE LEVEL: 0ppm KWG 0519

MACROSCOPIC FINDINGS

	Mode of death : Terminal kill
	Days under test : 734
	Date of death : 14/07/80
Kidney	Cysts (0.1cm diam)
Lung	Lob. mec. dxtr: Beige thickening (0.2cm diam)
Spleen	Reduced in size (1.4 x 0.2cm diam)

MICROSCOPIC FINDINGS

Adrenal/1	BENIGN TUMOUR cortical adenoma
Brain	No tissue available
Heart	Inflammation chronic (moderate)
Kidney/1	Interstitial nephritis (minimal)
	Cysts (moderate)
Kidney/2	Interstitial nephritis (minimal)
	Cysts (moderate)
Lung	MALIGNANT TUMOUR alveogenic carcinoma
Pancreas	No tissue available
Spleen	Normal

KWG 0519 - Mouse Chronic Toxicity Study
Full Macro/Micro Report

Rat No: 41
SEX: Male
DOSE LEVEL: Oppa KWG 0519

MACROSCOPIC FINDINGS

Mode of death : Interim death
Days under test : 448
Date of death : 02/10/79
No significant findings noted

MICROSCOPIC FINDINGS

Kidney/1	Interstitial nephritis (minimal)
Kidney/2	Interstitial nephritis (minimal)
Liver	Congestion (severe)
Lung	Pneumonia (severe)
Pituitary	No tissue available
Urinary bladder	Autolysis (partial)

KWG 0519 - Mouse Chronic Toxicity Study
Full Macro/Micro Report

Rat No: 42
SEX: Male
DOSE LEVEL: Oppm KWG 0519

MACROSCOPIC FINDINGS

	Mode of death : Interim death
	Days under test : 594
	Date of death : 25/02/80
Kidney	Isololated crateriform lesions (0.1cm diam)
Liver	Enlarged
	Accentuated lobular marking
Lung	Pale
Spleen	Lob. inf. dxtr. med: Hard brown nodule (0.5cm diam)
	Enlarged (3.6 x 0.9cm)

MICROSCOPIC FINDINGS

Kidney/1	MALIGNANT LYMPHOMA
Kidney/2	MALIGNANT LYMPHOMA
Liver	MALIGNANT LYMPHOMA
Lung	MALIGNANT TUMOUR alveogenic carcinoma
Pancreas	BENIGN TUMOUR islet cell adenoma
Sciatic nerve	No tissue available
Spleen	MALIGNANT LYMPHOMA
Testis/1	Calcification (minimal)
Thyroid/1	No tissue available
Thyroid/2	No tissue available
Urinary bladder	MALIGNANT LYMPHOMA

KWG 0519 - Mouse Chronic Toxicity Study
Full Macro/Micro Report

Rat No: 43
SEX: Male
DOSE LEVEL: Oppm KWG 0519

MACROSCOPIC FINDINGS

Mode of death	: Interim death
Days under test	: 715
Date of death	: 25/06/80
Condition at necropsy	Moribund
Adrenal gland	Left: Enlarged
Pituitary	Haemorrhagic
Spleen	Enlarged (3.6 x0.6cm)

MICROSCOPIC FINDINGS

Adrenal/1	MALIGNANT LYMPHOMA
Adrenal/2	MALIGNANT LYMPHOMA
Brain	Meningitis (minimal)
Heart	MALIGNANT LYMPHOMA
Kidney/1	MALIGNANT LYMPHOMA
Kidney/2	MALIGNANT LYMPHOMA
Liver	MALIGNANT LYMPHOMA
Lung	MALIGNANT LYMPHOMA
Pancreas	MALIGNANT LYMPHOMA
Pituitary	Normal
Sciatic nerve	MALIGNANT LYMPHOMA
Skeletal muscle	MALIGNANT LYMPHOMA
Spleen	MALIGNANT LYMPHOMA
Stomach	MALIGNANT LYMPHOMA
Testis/1	MALIGNANT LYMPHOMA
Testis/2	MALIGNANT LYMPHOMA
Thyroid/1	MALIGNANT LYMPHOMA
Thyroid/2	MALIGNANT LYMPHOMA
Urinary bladder	MALIGNANT LYMPHOMA

KWG 0519 - Mouse Chronic Toxicity Study
Full Macro/Micro Report

Rat No: 44
SEX: Male
DOSE LEVEL: 0ppm KWG 0519

MACROSCOPIC FINDINGS

	Mode of death : Interim death
	Days under test : 448
	Date of death : 02/10/79
Condition at necropsy	Autolysis (few organs)
	No significant findings noted

MICROSCOPIC FINDINGS

Adrenal/1	Autolysis (partial)
Adrenal/2	Autolysis (partial)
Brain	Autolysis (partial)
Kidney/1	Pyelonephritis (minimal)
Kidney/2	Pyelonephritis (minimal)
Liver	Autolysis (partial)
	BENIGN TUMOUR cystadenoma
	Hepatocytic hyperpigmentation (minimal)
Lung	Pneumonia (moderate)
Pancreas	Autolysis
Pituitary	No tissue available
Sciatic nerve	Autolysis (partial)
Skeletal muscle	Autolysis (partial)
Spleen	Autolysis
Stomach	Autolysis
Testis/1	Autolysis (partial)
Testis/2	Autolysis (partial)
Thyroid/1	No tissue available
Thyroid/2	No tissue available
Urinary bladder	Autolysis

KWG 0519 - Mouse Chronic Toxicity Study
Full Macro/Micro Report

Rat No: 45
SEX: Male
DOSE LEVEL: Oppm KWG 0519

MACROSCOPIC FINDINGS

	Mode of death : Interim death
	Days under test : 630
	Date of death : 01/04/80
Condition at necropsy	Autolysis (few organs)
General observations	Obese
Kidney	Left: Cysts
Liver	Accentuated lobular marking
Lung	Dark/red foci/areas

MICROSCOPIC FINDINGS

Heart	Congestion
	Dilated chamber
Kidney/1	Tubulopathy (minimal)
	Interstitial nephritis (minimal)
Kidney/2	Tubulopathy (minimal)
	Interstitial nephritis (minimal)
Spleen	Haematopoiesis (severe)
Urinary bladder	Autolysis (partial)

KWG 0519 - Mouse Chronic Toxicity Study
Full Macro/Micro Report

Rat No: 46
SEX: Male
DOSE LEVEL: 0ppm KWG 0519

MACROSCOPIC FINDINGS

	Mode of death : Interim death
	Days under test : 386
	Date of death : 01/08/79
Liver	Accentuated lobular marking
Lung	Lob. sup. dxtr. and Lob. inf. dxtr. med: Flesh coloured

MICROSCOPIC FINDINGS

Brain	Autolysis (partial)
Kidney/1	Autolysis (partial)
Kidney/2	Autolysis (partial)
Liver	Normal
Lung	Autolysis (partial)
	Pneumonia (moderate)
Pituitary	No tissue available
Stomach	Autolysis
Thyroid/1	No tissue available
Thyroid/2	No tissue available
Urinary bladder	Autolysis

KWG 0519 - Mouse Chronic Toxicity Study
Full Macro/Micro Report

Rat No: 47
SEX: Male
DOSE LEVEL: Oppm KWG 0519

MACROSCOPIC FINDINGS

	Mode of death : Interim death
	Days under test : 551
	Date of death : 13/01/80
Liver	Grey-red discolouration with dark-red foci (0.2cm diam)
Lung	Pale
Spleen	Enlarged (3.1 x 0.6cm)
Mesenteric lymph node	Enlarged

MICROSCOPIC FINDINGS

Bone (femur)	No tissue available
Heart	Congestion
Kidney/1	Tubulopathy (moderate)
	MALIGNANT LYMPHOMA
Kidney/2	Tubulopathy (moderate)
	MALIGNANT LYMPHOMA
Liver	Amyloid
	Hyperplasia focal
	MALIGNANT LYMPHOMA
Lung	Emphysema (moderate)
Spleen	MALIGNANT LYMPHOMA
Stomach	Autolysis
Testis/1	Calcification (minimal)
Testis/2	Calcification (minimal)
Urinary bladder	Hyperplasia papillomatous
Lymph node	MALIGNANT LYMPHOMA
Mesentery	MALIGNANT LYMPHOMA

KWG 0519 - Mouse Chronic Toxicity Study
Full Macro/Micro Report

Rat No: 48
SEX: Male
DOSE LEVEL: Oppm KWG 0519

MACROSCOPIC FINDINGS

	Mode of death : Interim death
	Days under test : 425
	Date of death : 09/09/79
Liver	Enlarged
Lung	Lob. sup. dxtr: Grey and hard
	Lob. sin: White foci
Spleen	Enlarged (3.0 x 1.0cm)
Lymph nodes	Enlarged

MICROSCOPIC FINDINGS

Adrenal/1	MALIGNANT LYMPHOMA
Adrenal/2	MALIGNANT LYMPHOMA
Kidney/1	MALIGNANT LYMPHOMA
Kidney/2	MALIGNANT LYMPHOMA
Liver	MALIGNANT LYMPHOMA
Lung	MALIGNANT TUMOUR alveogenic carcinoma
	MALIGNANT LYMPHOMA
Pancreas	MALIGNANT LYMPHOMA
Sciatic nerve	No tissue available
Spleen	MALIGNANT LYMPHOMA
Stomach	MALIGNANT LYMPHOMA
Urinary bladder	MALIGNANT LYMPHOMA
Lymph node	MALIGNANT LYMPHOMA
Trachea	MALIGNANT LYMPHOMA

KWG 0519 - Mouse Chronic Toxicity Study
Full Macro/Micro Report

Rat No: 49
SEX: Male
DOSE LEVEL: 0ppm KWG 0519

MACROSCOPIC FINDINGS

Mode of death	: Interim death
Days under test	: 651
Date of death	: 22/04/80
Adrenal gland	Left: Enlarged
Condition at necropsy	Autolysis (numerous organs)
Liver	Lob. sin: Swollen
Lung	Lob. sin: White hard area (0.3cm diam)
Spleen	Enlarged (3.2 x 0.7cm)

MICROSCOPIC FINDINGS

Brain	No tissue available
Heart	Autolysis (partial)
	Congestion
Kidney/1	MALIGNANT LYMPHOMA
Kidney/2	MALIGNANT LYMPHOMA
Liver	BENIGN TUMOUR hepatocellular adenoma
	MALIGNANT LYMPHOMA
Lung	Autolysis (partial)
	MALIGNANT TUMOUR alveogenic carcinoma
Pancreas	Autolysis
Pituitary	Autolysis (partial)
Spleen	Autolysis (partial)
	MALIGNANT LYMPHOMA
Stomach	Autolysis
Thyroid/1	No tissue available
Thyroid/2	No tissue available
Urinary bladder	Autolysis
Lymph node	MALIGNANT LYMPHOMA

KWG 0519 - Mouse Chronic Toxicity Study
Full Macro/Micro Report

Rat No: 50
SEX: Male
DOSE LEVEL: 0ppm KWG 0519

MACROSCOPIC FINDINGS

	Mode of death : Interim death
	Days under test : 512
	Date of death : 05/12/79
Condition at necropsy	Autolysis (few organs)
Spleen	Enlarged (4.3 x 1.4cm)

MICROSCOPIC FINDINGS

Adrenal/1	Autolysis (partial)
Adrenal/2	Autolysis (partial)
Brain	Autolysis (partial)
Heart	Autolysis (partial)
	Thrombosis
Kidney/1	Autolysis (partial)
	Cysts (moderate)
Kidney/2	Autolysis (partial)
	Cysts (moderate)
Liver	Autolysis
Lung	Autolysis (partial)
Pancreas	Autolysis
Pituitary	Autolysis (partial)
Spleen	Autolysis (partial)
	MALIGNANT LYMPHOMA
Stomach	Autolysis
Thyroid/1	No tissue available
Thyroid/2	No tissue available
Urinary bladder	Autolysis

KWG 0519 - Mouse Chronic Toxicity Study
Full Macro/Micro Report

Rat No: 51
SEX: Female
DOSE LEVEL: 0ppm KWG 0519

MACROSCOPIC FINDINGS

	Mode of death : Terminal kill
	Days under test : 735
	Date of death : 15/07/80
General observations	No significant findings noted

MICROSCOPIC FINDINGS

Kidney/1	Cysts
	Pyelitis
Kidney/2	Cysts
Liver	Mononuclear cells (minimal)
	Hepatocytic hyperpigmentation (minimal)
Lung	Pneumonia
Ovary/1	Pigmentation
	Atrophy
	Cysts
Ovary/2	Pigmentation
	Atrophy
	Cysts
Pituitary	No tissue available
Spleen	Haematopoiesis (moderate)
Stomach	Hyperplasia papillomatous
Thyroid/1	No tissue available
Thyroid/2	No tissue available
Urinary bladder	Inflammation chronic
Uterus	Hyperplasia polypoid
	Haemorrhage
	Cystic endometrial hyperplasia (severe)

KWG 0519 - Mouse Chronic Toxicity Study
Full Macro/Micro Report

Rat No: 52
SEX: Female
DOSE LEVEL: Oppm KWG 0519

MACROSCOPIC FINDINGS

	Mode of death : Terminal kill
	Days under test : 735
	Date of death : 15/07/80
Kidney	Both: White nodules (0.3 and 0.5cm diam)
Lung	Lob. inf. dxtr. lat: White nodule
Spleen	Enlarged (0.2 x 7.0cm)

MICROSCOPIC FINDINGS

Adrenal/1	Pigment (minimal)
Kidney/1	Interstitial nephritis (severe)
Kidney/2	Interstitial nephritis (severe)
Liver	Mononuclear cells (minimal)
	Hyperplastic nodule
Ovary/1	Cysts
Spleen	Haematopoiesis (severe)
Thyroid/1	No tissue available
Thyroid/2	No tissue available
Urinary bladder	Inflammation chronic
Uterus	Hyperplasia polypoid

KWG 0519 - Mouse Chronic Toxicity Study
Full Macro/Micro Report

Rat No: 53
SEX: Female
DOSE LEVEL: Oppm KWG 0519

MACROSCOPIC FINDINGS

Mode of death	: Interim death
Days under test	: 479
Date of death	: 02/11/79
General observations	Obese
Adrenal gland	Left: Enlarged
Liver	Enlarged
Lung	Dark/red coloured
Spleen	Enlarged (2.5 x 0.6cm)
Thoracic cavity	Filled with blood clots

MICROSCOPIC FINDINGS

Brain	Fat vacuoles
Heart	Congestion
Kidney/1	MALIGNANT LYMPHOMA
Kidney/2	MALIGNANT LYMPHOMA
Liver	MALIGNANT LYMPHOMA
Lung	Oedema (severe)
	Congestion (severe)
	MALIGNANT LYMPHOMA
Ovary/1	MALIGNANT LYMPHOMA
Ovary/2	MALIGNANT LYMPHOMA
Pancreas	MALIGNANT LYMPHOMA
Spleen	MALIGNANT LYMPHOMA
Urinary bladder	MALIGNANT LYMPHOMA
Uterus	MALIGNANT LYMPHOMA
Lymph node	MALIGNANT LYMPHOMA
Mesentery	MALIGNANT LYMPHOMA

KWG 0519 - Mouse Chronic Toxicity Study
Full Macro/Micro Report

Rat No: 54
SEX: Female
DOSE LEVEL: 0ppm KWG 0519

MACROSCOPIC FINDINGS

Mode of death	: Interim death
Days under test	: 515
Date of death	: 08/12/79
General observations	Obese
Adrenal gland	Pale
Lung	Filled with blood
Stomach	Enlarged

MICROSCOPIC FINDINGS

Adrenal/1	Pigmentation (minimal)
Heart	Congestion
Kidney/1	Calcification (minimal)
	Interstitial nephritis (minimal)
Kidney/2	Calcification (minimal)
	Interstitial nephritis (minimal)
Liver	Congestion
Lung	Haemorrhage (severe)
	Congestion (severe)
Ovary/1	Hypertrophic corpora lutea
Ovary/2	Hypertrophic corpora lutea
Spleen	Haematopoiesis (severe)
Stomach	Normal
Thyroid/1	Cysts
Uterus	Normal

KWG 0519 - Mouse Chronic Toxicity Study
Full Macro/Micro Report

Rat No: 55
SEX: Female
DOSE LEVEL: Oppm KWG 0519

MACROSCOPIC FINDINGS

	Mode of death : Terminal kill
	Days under test : 735
	Date of death : 15/07/80
Lung	Lob. sin: White foci (0.2-0.3cm diam)
Ovary	Both: Cysts (0.3 and 0.5cm diam)

MICROSCOPIC FINDINGS

Adrenal/1	Pigmentation
Adrenal/2	Pigmentation
Liver	Vacuolisation
Lung	MALIGNANT TUMOUR alveogenic carcinoma
Ovary/1	BENIGN TUMOUR luteoma
Pancreas	No tissue available
Spleen	Haematopoiesis (moderate)
Urinary bladder	Hyperplasia papillomatous
Uterus	Endometriosis
	Hyperplasia secretory

KWG 0519 - Mouse Chronic Toxicity Study
Full Macro/Micro Report

Rat No: 56
SEX: Female
DOSE LEVEL: Oppm KWG 0519

MACROSCOPIC FINDINGS

	Mode of death : Interim death
	Days under test : 547
	Date of death : 09/01/80
Condition at necropsy	Autolysis (numerous organs)
Adrenal gland	Left: Enlarged
Spleen	Enlarged (4.2 x 1.2cm)

MICROSCOPIC FINDINGS

Adrenal/1	Autolysis
Adrenal/2	Autolysis
Brain	Autolysis
Heart	Congestion
Kidney/1	Autolysis
Kidney/2	Autolysis
Liver	Autolysis (partial)
	MALIGNANT LYMPHOMA
Lung	Congestion
Ovary/1	Autolysis
Ovary/2	Autolysis
Pancreas	Autolysis
Pituitary	Autolysis
Sciatic nerve	Autolysis
Skeletal muscle	Autolysis
Spleen	MALIGNANT LYMPHOMA
Stomach	Autolysis
Thyroid/1	Autolysis
Thyroid/2	Autolysis
Urinary bladder	Autolysis
Lymph node	MALIGNANT LYMPHOMA
	Autolysis (partial)

KWG 0519 - Mouse Chronic Toxicity Study
Full Macro/Micro Report

Rat No: 57
SEX: Female
DOSE LEVEL: Oppm KWG 0519

MACROSCOPIC FINDINGS

	Mode of death : Terminal kill
	Days under test : 735
	Date of death : 15/07/80
Inguinal region	Right: Hard white nodule (1.0cm diam)
Lung	Lob. inf. dxtr. lat: Hard yellow nodule (0.3cm diam)
Ovary	Left: Cysts (1.0cm diam)

MICROSCOPIC FINDINGS

Adrenal/1	Pigmentation (severe)
Adrenal/2	Pigmentation (severe)
Kidney/1	Interstitial nephritis
	Cysts
Kidney/2	Interstitial nephritis
	Cysts
Liver	Hypertrophy
Lung	MALIGNANT TUMOUR alveogenic carcinoma
Ovary/1	Atrophy
	Cysts
Ovary/2	Atrophy
Spleen	Haematopoiesis (severe)
	Haemorrhagic cyst
Thyroid/1	No tissue available
Thyroid/2	No tissue available
Urinary bladder	Inflammation chronic
	Hyperplasia papillomatous
Mammary gland	MALIGNANT TUMOUR adenocarcinoma

KWG 0519 - Mouse Chronic Toxicity Study
Full Macro/Micro Report

Rat No: 58
SEX: Female
DOSE LEVEL: Oppm KWG 0519

MACROSCOPIC FINDINGS

	Mode of death : Interim death
	Days under test : 594
	Date of death : 25/02/80
Liver	Clay coloured areas
	Accentuated lobular marking
Lung	Flesh coloured
Thoracic cavity	3ml milky opaque fluid
Thymus	Soft beige growth (1.2 x 0.8cm)
Uterus	Horns thickened (0.4cm diam)

MICROSCOPIC FINDINGS

Heart	Congestion
	MALIGNANT LYMPHOMA
Kidney/1	Autolysis (partial)
	Interstitial nephritis (minimal)
Kidney/2	Autolysis (partial)
	Interstitial nephritis (minimal)
Liver	Autolysis (partial)
	Hyperplastic nodule
Lung	Normal
Ovary/1	Cysts
Pancreas	Autolysis (partial)
Spleen	Autolysis (partial)
Stomach	Autolysis
Urinary bladder	Autolysis
Uterus	Hyperplasia secretory
	MALIGNANT LYMPHOMA
Mesentery	MALIGNANT LYMPHOMA
Thymus	MALIGNANT LYMPHOMA

KWG 0519 - Mouse Chronic Toxicity Study
Full Macro/Micro Report

Rat No: 59
SEX: Female
DOSE LEVEL: Oppm KWG 0519

MACROSCOPIC FINDINGS

	Mode of death : Interim death
	Days under test : 594
	Date of death : 25/02/80
Condition at necropsy	Autolysis (few organs)
Lung	Dark/red foci/areas
Ovary	Left: Cysts (0.6cm diam)
Uterus	Neck thickened (1.2cm diam) hard

MICROSCOPIC FINDINGS

Brain	Fat vacuoles
Kidney/1	Congestion
Kidney/2	Congestion
Liver	Autolysis (partial)
	Haematopoiesis (severe)
	Congestion
Lung	Oedema (severe)
	Haemorrhage
	Congestion (severe)
Ovary/1	Cysts
	METASTASIS leiomyosarcoma
Pancreas	Autolysis (partial)
Spleen	Autolysis
Uterus	Endometriosis
Cervix	MALIGNANT TUMOUR leiomyosarcoma

KWG 0519 - Mouse Chronic Toxicity Study
Full Macro/Micro Report

Rat No: 60
SEX: Female
DOSE LEVEL: 0ppm KWG 0519

MACROSCOPIC FINDINGS

	Mode of death : Interim death
	Days under test : 691
	Date of death : 01/06/80
Abdominal cavity	7ml dark red fluid
Liver	Portal: Reddish soft nodule (2.6cm diam)
Ovary	Right: Haemorrhagic cyst (1.0cm diam)
Pancreas	Haemorrhagic cyst (1.0cm diam)

MICROSCOPIC FINDINGS

Heart	Congestion
Liver	MALIGNANT TUMOUR hepatocellular adenocarcinoma
	Infarct
	Congestion
	Haemorrhagic cyst
Lung	Oedema (severe)
	Congestion (severe)
Ovary/1	Atrophy
	Haemorrhagic cyst
Pancreas	Haemorrhagic cyst
Spleen	Haematopoiesis (severe)
Urinary bladder	Unreadable
Uterus	Unreadable

KWG 0519 - Mouse Chronic Toxicity Study
Full Macro/Micro Report

Rat No: 61
SEX: Female
DOSE LEVEL: 0ppm KWG 0519

MACROSCOPIC FINDINGS

	Mode of death : Interim death
	Days under test : 505
	Date of death : 28/11/79
Condition at necropsy	Moribund
Uterus	Horn enlarged (0.3cm diam)

MICROSCOPIC FINDINGS

Adrenal/1	Pigmentation (severe)
Adrenal/2	Pigmentation (severe)
Kidney/1	Interstitial nephritis (minimal)
Liver	No tissue available
Lung	Pneumonia
Ovary/1	Atrophy
Ovary/2	Atrophy
Uterus	Hyperplasia polypoid

KWG 0519 - Mouse Chronic Toxicity Study
Full Macro/Micro Report

Rat No: 62
SEX: Female
DOSE LEVEL: Oppm KWG 0519

MACROSCOPIC FINDINGS

	Mode of death : Interim death
	Days under test : 556
	Date of death : 18/01/80
Adrenal gland	Left: Enlarged
Liver	Accentuated lobular marking
Lung	Increased air and moisture content
Spleen	Enlarged (3.3 x 0.6cm)
Stomach	Mucosal bleeding
Urinary bladder	0.3ml haemorrhagic fluid

MICROSCOPIC FINDINGS

Heart	MALIGNANT LYMPHOMA
Kidney/1	Hydronephrosis
	Interstitial nephritis (minimal)
Kidney/2	Hydronephrosis
	Interstitial nephritis (minimal)
Liver	Mononuclear cells (minimal)
	Congestion
	Hepatocytic hyperpigmentation (minimal)
Lung	Congestion
	MALIGNANT LYMPHOMA
Ovary/1	MALIGNANT LYMPHOMA
Ovary/2	MALIGNANT LYMPHOMA
Pancreas	MALIGNANT LYMPHOMA
Pituitary	No tissue available
Sciatic nerve	No tissue available
Skeletal muscle	No tissue available
Spleen	Hypertrophy
Urinary bladder	MALIGNANT LYMPHOMA
Uterus	MALIGNANT LYMPHOMA
Lymph node	MALIGNANT LYMPHOMA
	Lymphocoele

KWG 0519 - Mouse Chronic Toxicity Study
Full Macro/Micro Report

Rat No: 63
SEX: Female
DOSE LEVEL: Oppm KWG 0519

MACROSCOPIC FINDINGS

	Mode of death : Interim death
	Days under test : 714
	Date of death : 24/06/80
Condition at necropsy	Moribund
General observations	Apathetic/listless
Spleen	Enlarged (2.7 x 1.0cm)
Uterus	Left horn red beige hard nodule (1.6 x 2.0cm)

MICROSCOPIC FINDINGS

Adrenal/1	Hyperplasia glomerulosa
Adrenal/2	Hyperplasia glomerulosa
Brain	Gliosis
Kidney/1	Progressive nephropathy (severe)
Kidney/2	Progressive nephropathy (severe)
Ovary/1	Atrophy
	Cysts
Ovary/2	Atrophy
Sciatic nerve	No tissue available
Spleen	Haematopoiesis (severe)
Thyroid/1	No tissue available
Thyroid/2	No tissue available
Uterus	MALIGNANT TUMOUR adenocarcinoma
	Haemorrhage (severe)
	Hyperplasia secretory

KWG 0519 - Mouse Chronic Toxicity Study
Full Macro/Micro Report

Rat No: 64
SEX: Female
DOSE LEVEL: Oppm KWG 0519

MACROSCOPIC FINDINGS

	Mode of death : Interim death
	Days under test : 682
	Date of death : 23/05/80
Adrenal gland	Left: Pale, enlarged
Condition at necropsy	Moribund
Kidney	Pale
Liver	Enlarged
Lung	Lob. sup. dxtr: Flesh coloured
Pituitary	Pale
Spleen	Enlarged (4.0 x 1.2cm) grey-white marbled surface

MICROSCOPIC FINDINGS

Heart	Congestion
Kidney/1	Progressive nephropathy
	MALIGNANT LYMPHOMA
Kidney/2	Progressive nephropathy
	MALIGNANT LYMPHOMA
Liver	MALIGNANT LYMPHOMA
Lung	MALIGNANT TUMOUR alveogenic carcinoma
	Oedema
	Congestion
Ovary/1	Atrophy
Ovary/2	Atrophy
Skeletal muscle	MALIGNANT LYMPHOMA
Spleen	MALIGNANT LYMPHOMA
Stomach	MALIGNANT LYMPHOMA
Thyroid/1	MALIGNANT LYMPHOMA
Thyroid/2	MALIGNANT LYMPHOMA
Urinary bladder	MALIGNANT LYMPHOMA
Uterus	Hyperplasia secretory
Lymph node	MALIGNANT LYMPHOMA
Mesentery	MALIGNANT LYMPHOMA

KWG 0519 - Mouse Chronic Toxicity Study
Full Macro/Micro Report

Rat No: 65
SEX: Female
DOSE LEVEL: Oppm KWG 0519

MACROSCOPIC FINDINGS

Condition at necropsy	Mode of death : Interim death Days under test : 431 Date of death : 26/01/80 Autolysis (complete) Evaluation not possible

MICROSCOPIC FINDINGS

Adrenal/1	No tissue available
Adrenal/2	No tissue available
Bone (femur)	No tissue available
Brain	No tissue available
Heart	No tissue available
Kidney/1	No tissue available
Kidney/2	No tissue available
Liver	No tissue available
Lung	No tissue available
Ovary/1	No tissue available
Ovary/2	No tissue available
Pancreas	No tissue available
Pituitary	No tissue available
Sciatic nerve	No tissue available
Skeletal muscle	No tissue available
Spleen	No tissue available
Stomach	No tissue available
Thyroid/1	No tissue available
Thyroid/2	No tissue available
Urinary bladder	No tissue available

KWG 0519 - Mouse Chronic Toxicity Study
Full Macro/Micro Report

Rat No: 66
SEX: Female
DOSE LEVEL: Oppm KWG 0519

MACROSCOPIC FINDINGS

	Mode of death : Terminal kill
	Days under test : 735
	Date of death : 15/07/80
Lung	Lob. sin: White foci (0.1-0.2cm diam)

MICROSCOPIC FINDINGS

Adrenal/1	No tissue available
Adrenal/2	No tissue available
Brain	Haemorrhage
Liver	Fat vacuoles
	Cysts
Lung	MALIGNANT TUMOUR alveogenic carcinoma
Ovary/1	Atrophy
Ovary/2	Atrophy
Pancreas	Atrophy
	Periarteritis
Pituitary	Cysts
Spleen	Haematopoiesis (severe)
Thyroid/1	No tissue available
Thyroid/2	No tissue available
Uterus	Cystic endometrial hyperplasia
Mesentery	Inflammation chronic

KWG 0519 - Mouse Chronic Toxicity Study
Full Macro/Micro Report

Rat No: 67
SEX: Female
DOSE LEVEL: Oppm KWG 0519

MACROSCOPIC FINDINGS

	Mode of death : Interim death
	Days under test : 399
	Date of death : 14/08/79
Adrenal gland	Left: Enlarged
Liver	Enlarged
Spleen	Enlarged (4.6 x 1.4cm)
Stomach	Mucosal bleeding

MICROSCOPIC FINDINGS

Adrenal/1	Pigmentation (minimal)
Kidney/1	Tubulopathy
	Interstitial nephritis
Kidney/2	Tubulopathy
	Interstitial nephritis
Liver	Autolysis (partial)
	MALIGNANT LYMPHOMA
Ovary/1	Hypertrophic corpora lutea
Ovary/2	Hypertrophic corpora lutea
Pancreas	Autolysis
Spleen	MALIGNANT LYMPHOMA
Stomach	Autolysis
Urinary bladder	Autolysis

KWG 0519 - Mouse Chronic Toxicity Study
Full Macro/Micro Report

Rat No: 68
SEX: Female
DOSE LEVEL: 0ppm KWG 0519

MACROSCOPIC FINDINGS

	Mode of death : Interim death
	Days under test : 526
	Date of death : 19/12/79
Kidney	Right: Cysts
Lung	Flesh coloured areas
Pituitary	Enlarged, glassy
Spleen	Enlarged (2.6 x 0.7cm)
Thoracic cavity	4ml clear fluid
Thymus	Hard beige nodule (1.8cm diam)

MICROSCOPIC FINDINGS

Adrenal/1	Pigmentation (severe)
Heart	MALIGNANT LYMPHOMA
Kidney/1	Normal
Kidney/2	Normal
Liver	Normal
Lung	MALIGNANT LYMPHOMA
Ovary/1	Hypertrophic corpora lutea
Ovary/2	Atrophy
	Cysts
Pituitary	Cysts
Spleen	Normal
Uterus	Endometriosis
Thymus	MALIGNANT LYMPHOMA

KWG 0519 - Mouse Chronic Toxicity Study
Full Macro/Micro Report

Rat No: 69
SEX: Female
DOSE LEVEL: 0ppm KWG 0519

MACROSCOPIC FINDINGS

	Mode of death : Interim death
	Days under test : 602
	Date of death : 04/03/80
Condition at necropsy	Autolysis (few organs)
Hypogastrium	Subcutaneous beige-red hard and soft nodule (3.0 x 2.3cm)
Spleen	Enlarged (2.2 x 0.4cm)
Uterus	Horns thickened (0.3cm diam)

MICROSCOPIC FINDINGS

Heart	Congestion (severe)
Kidney/1	Interstitial nephritis (moderate)
Kidney/2	Interstitial nephritis (moderate)
Liver	Congestion
Lung	Thrombosis (severe)
	Pneumonia (severe)
	Congestion (severe)
Ovary/1	Atrophy
Ovary/2	Atrophy
Pancreas	Autolysis
Spleen	Haematopoiesis (severe)
Uterus	Autolysis (partial)
Body wall	Autolysis (partial)
	MALIGNANT TUMOUR mesenchymal tumour
Mesentery	METASTASIS mesenchymal tumour

KWG 0519 - Mouse Chronic Toxicity Study
Full Macro/Micro Report

Rat No: 70
SEX: Female
DOSE LEVEL: Oppm KWG 0519

MACROSCOPIC FINDINGS

	Mode of death : Interim death
	Days under test : 110
	Date of death : 29/10/78
Stomach	Mucosal bleeding

MICROSCOPIC FINDINGS

Liver	Congestion (severe)
Lung	Haemorrhage (severe)
	Congestion (severe)
Ovary/1	Cysts
	Hypertrophic corpora lutea
Ovary/2	Cysts
	Hypertrophic corpora lutea
Pituitary	No tissue available
Stomach	Unreadable
Thyroid/1	No tissue available
Thyroid/2	No tissue available
Urinary bladder	Autolysis

KWG 0519 - Mouse Chronic Toxicity Study
Full Macro/Micro Report

Rat No: 71
SEX: Female
DOSE LEVEL: Oppa KWG 0519

MACROSCOPIC FINDINGS

	Mode of death : Interim death
	Days under test : 665
	Date of death : 06/05/80
Liver	Clay coloured
Lung	Dark/red foci/areas
Ovary	Left: Cysts (0.7cm diam)
Spleen	Enlarged (3.2 x 0.8cm)

MICROSCOPIC FINDINGS

Adrenal/1	MALIGNANT LYMPHOMA
Heart	Thrombosis
Kidney/1	Interstitial nephritis (minimal)
Liver	Mononuclear cells (minimal)
Lung	Pneumonia
Ovary/1	Atrophy
	Cysts
Ovary/2	Atrophy
Spleen	MALIGNANT LYMPHOMA
Urinary bladder	MALIGNANT LYMPHOMA
Mesentery	MALIGNANT LYMPHOMA

KWG 0519 - Mouse Chronic Toxicity Study
Full Macro/Micro Report

Rat No: 72
SEX: Female
DOSE LEVEL: Oppm KWG 0519

MACROSCOPIC FINDINGS

	Mode of death : Interim death
	Days under test : 700
	Date of death : 10/06/80
Adrenal gland	Left: Enlarged
Liver	Enlarged
Lung	Flesh coloured
Spleen	Enlarged (3.3 x 0.7cm)
Stomach	A watery cyst (1.3cm diam) and a hard nodule (1.4cm diam) involving intestines, spleen, pancreas, left kidney, left adrenal, uterus and ovary

MICROSCOPIC FINDINGS

Brain	Gliosis
Heart	Congestion
Kidney/1	Progressive nephropathy (minimal)
Kidney/2	Progressive nephropathy (minimal)
Liver	MYELOID LEUKAEMIA
Lung	Pneumonia (severe)
Ovary/1	Pus
Ovary/2	Pus
Pancreas	Haemorrhagic cyst
Spleen	Haemorrhagic cyst
	MYELOID LEUKAEMIA
Stomach	Hyperkeratosis
Uterus	Endometriosis (severe)
	Endometritis (severe)
	Pus (severe)
Mesentery	MYELOID LEUKAEMIA

KWG 0519 - Mouse Chronic Toxicity Study
Full Macro/Micro Report

Rat No: 73
SEX: Female
DOSE LEVEL: Oppm KWG 0519

MACROSCOPIC FINDINGS

	Mode of death : Interim death
	Days under test : 681
	Date of death : 22/05/80
Dorsal neck region	Skin inflammed between ears
Liver	Clay coloured
Ovary	Cysts (0.6cm diam) green-white nodules (0.3-0.6cm diam)
Spleen	Enlarged (2.7 x 0.7cm)
Uterus	Thickened (0.5cm diam) indurated

MICROSCOPIC FINDINGS

Adrenal/1	Pigmentation (severe)
Adrenal/2	Pigmentation (severe)
Kidney/1	Interstitial nephritis (minimal)
Kidney/2	Interstitial nephritis (minimal)
Liver	Normal
Lung	Pneumonia
Ovary/1	Cysts
Ovary/2	Cysts
Pituitary	No tissue available
Spleen	Haematopoiesis (severe)
Stomach	Mucoid cyst
Urinary bladder	Inflammation chronic
Uterus	MALIGNANT TUMOUR mesenchymal tumour

KWG 0519 - Mouse Chronic Toxicity Study
Full Macro/Micro Report

Rat No: 74
SEX: Female
DOSE LEVEL: Oppm KWG 0519

MACROSCOPIC FINDINGS

	Mode of death : Terminal kill
	Days under test : 735
	Date of death : 15/07/80
Kidney	Right: White-beige nodule (0.4-0.5cm diam)
Ovary	Right: Cysts (0.3cm diam) haemorrhagic fluid

MICROSCOPIC FINDINGS

Adrenal/1	Pigmentation (severe)
Adrenal/2	Pigmentation (severe)
Kidney/1	Interstitial nephritis (minimal)
	Dilatation renal pelvis
Kidney/2	Interstitial nephritis (minimal)
	Dilatation renal pelvis
Liver	Fat vacuoles
	Mononuclear cells (minimal)
Lung	Atelectasis
Ovary/1	Atrophy
Ovary/2	Atrophy
Spleen	Haematopoiesis (minimal)
Thyroid/1	No tissue available
Thyroid/2	No tissue available
Uterus	Endometriosis

KWG 0519 - Mouse Chronic Toxicity Study
Full Macro/Micro Report

Rat No: 75
SEX: Female
DOSE LEVEL: Oppa KWG 0519

MACROSCOPIC FINDINGS

	Mode of death : Interim death
	Days under test : 198
	Date of death : 25/01/79
Condition at necropsy	Autolysis (complete)
	Evaluation not possible

MICROSCOPIC FINDINGS

Adrenal/1	Autolysis
Adrenal/2	Autolysis
Brain	Autolysis
Heart	Congestion (severe)
Kidney/1	Autolysis
Kidney/2	Autolysis
Liver	Autolysis
Lung	Autolysis
Ovary/1	Autolysis
Ovary/2	Autolysis
Pancreas	Autolysis
Pituitary	Autolysis
Sciatic nerve	Autolysis
Skeletal muscle	Autolysis
Spleen	Autolysis
Stomach	Autolysis
Thyroid/1	Autolysis
Thyroid/2	Autolysis
Urinary bladder	Autolysis

KWG 0519 - Mouse Chronic Toxicity Study
Full Macro/Micro Report

Rat No: 76
SEX: Female
DOSE LEVEL: Oppm KWG 0519

MACROSCOPIC FINDINGS

	Mode of death : Terminal kill
	Days under test : 735
	Date of death : 15/07/80
Pituitary	Enlarged (0.2 x 0.4cm) haemorrhagic

MICROSCOPIC FINDINGS

Adrenal/1	Pigmentation (severe)
Adrenal/2	Pigmentation (severe)
Brain	Ventricular dilatation
Kidney/1	Interstitial nephritis (minimal)
Kidney/2	Interstitial nephritis (minimal)
Liver	Vacuolisation
	Hepatocytic hyperpigmentation (minimal)
Lung	Pneumonia
Ovary/1	Atrophy
Ovary/2	Atrophy
Pituitary	Haemorrhage
Stomach	Inflammation chronic
	Mucoid cyst
	Hyperkeratosis
Thyroid/1	No tissue available
Thyroid/2	No tissue available
Uterus	Hyperplasia secretory
Mesentery	Inflammation chronic

KWG 0519 - Mouse Chronic Toxicity Study
Full Macro/Micro Report

Rat No: 77
SEX: Female
DOSE LEVEL: 0ppm KWG 0519

MACROSCOPIC FINDINGS

Mode of death : Interim death
Days under test : 360
Date of death : 06/07/79

Condition at necropsy	
Lung	Autolysis (few organs)
Spleen	Fleshy areas
Thymus	Enlarged (3.0 x 0.8cm)
	Hard beige nodule (1.0 x 1.2cm)

MICROSCOPIC FINDINGS

Brain	Fat vacuoles
Heart	MALIGNANT LYMPHOMA
Kidney/1	MALIGNANT LYMPHOMA
Kidney/2	MALIGNANT LYMPHOMA
Liver	Autolysis
Lung	MALIGNANT LYMPHOMA
Ovary/1	Cysts
	MALIGNANT LYMPHOMA
Ovary/2	Cysts
	MALIGNANT LYMPHOMA
Pancreas	Autolysis
Spleen	MALIGNANT LYMPHOMA
Stomach	Autolysis
Thyroid/1	Autolysis
Thyroid/2	Autolysis
Urinary bladder	Autolysis
Thymus	MALIGNANT LYMPHOMA

KWG 0519 - Mouse Chronic Toxicity Study
Full Macro/Micro Report

Rat No: 78
SEX: Female
DOSE LEVEL: 0ppm KWG 0519

MACROSCOPIC FINDINGS

	Mode of death : Terminal kill
	Days under test : 735
	Date of death : 15/07/80
Lung	Isolated beige foci (0.1-0.3cm diam)
Pancreas	Hardened

MICROSCOPIC FINDINGS

Adrenal/1	Pigmentation (moderate)
Adrenal/2	Pigmentation (moderate)
Bone (femur)	No tissue available
Liver	Mononuclear cells (minimal)
	Vacuolisation ·
Lung	Pigmentation (minimal)
	Pneumonia
Ovary/1	Atrophy
Ovary/2	Atrophy
Pancreas	Normal
Sciatic nerve	No tissue available
Skeletal muscle	No tissue available
Spleen	Haematopoiesis (severe)
Urinary bladder	BENIGN TUMOUR papilloma
Mammary gland	MALIGNANT TUMOUR adenocarcinoma

KWG 0519 - Mouse Chronic Toxicity Study
Full Macro/Micro Report

Rat No: 79
SEX: Female
DOSE LEVEL: Oppm KWG 0519

MACROSCOPIC FINDINGS

Condition at necropsy	
	Mode of death : Interim death
	Days under test : 678
	Date of death : 19/05/80
Adrenal gland	Autolysis (few organs)
Kidney	Left: Enlarged
Liver	Cysts
	Enlarged
Lung	Swollen soft marbled surface
Spleen	Reddish
Uterus	Enlarged (2.7 x 0.6cm diam)
	Horns neck and ovaries coalesced into hard and soft nodule filled with yellowish paste (3.5 x 1.4cm)

MICROSCOPIC FINDINGS

Heart	Congestion
Kidney/1	MYELOID LEUKAEMIA
Kidney/2	MYELOID LEUKAEMIA
Liver	MYELOID LEUKAEMIA
Lung	Congestion
	MYELOID LEUKAEMIA
Ovary/1	Autolysis
Ovary/2	Autolysis
Pancreas	MYELOID LEUKAEMIA
Pituitary	No tissue available
Spleen	MYELOID LEUKAEMIA
Urinary bladder	MYELOID LEUKAEMIA
Uterus	MALIGNANT TUMOUR histiocytic sarcoma
Mesentery	METASTASIS histiocytic sarcoma

KWG 0519 - Mouse Chronic Toxicity Study
Full Macro/Micro Report

Rat No: 80
SEX: Female
DOSE LEVEL: Oppm KWG 0519

MACROSCOPIC FINDINGS

	Mode of death : Interim death
	Days under test : 709
	Date of death : 19/06/80
Adrenal gland	Left: Enlarged
Cranium	Indurated
Kidney	Clay coloured
Liver	Marbled surface
Lung	Flesh coloured
Spleen	Enlarged (4.5 x 0.8cm)
Stomach	Mucosal bleeding

MICROSCOPIC FINDINGS

Adrenal/1	Hyperplasia glomerulosa
Adrenal/2	Hyperplasia glomerulosa
Kidney/1	Interstitial nephritis (moderate)
Kidney/2	Interstitial nephritis (moderate)
Liver	MALIGNANT LYMPHOMA
Lung	Pneumonia (severe)
Ovary/1	Atrophy
	Cysts
Ovary/2	Atrophy
Pituitary	No tissue available
Spleen	MALIGNANT LYMPHOMA
Stomach	Unreadable
Urinary bladder	Unreadable
Uterus	Haemorrhage (severe)
	Cystic endometrial hyperplasia (severe)
Lymph node	MALIGNANT LYMPHOMA

156

KWG 0519 - Mouse Chronic Toxicity Study
Full Macro/Micro Report

Rat No: 81
SEX: Female
DOSE LEVEL: Oppm KWG 0519

MACROSCOPIC FINDINGS

	Mode of death : Terminal kill
	Days under test : 735
	Date of death : 15/07/80
Lung	Lob. sin: White hard nodule (0.2cm diam)
	Lob. sup. dxtr: Yellow hard nodule (0.3cm diam)
Ovary	Lob. inf. dxtr. lat: Yellow soft nodule (0.1cm diam)
	Left: Thickened. Soft haemorrhagic nodule (0.3cm diam) adherent left uterine horn

MICROSCOPIC FINDINGS

Adrenal/1	Pigmentation (severe)
Adrenal/2	Pigmentation (severe)
Kidney/1	Hydronephrosis
	Interstitial nephritis (minimal)
Kidney/2	Interstitial nephritis (minimal)
Liver	Fat vacuoles (minimal)
Lung	MALIGNANT TUMOUR alveogenic carcinoma
Ovary/1	Atrophy
	Cysts
Ovary/2	Atrophy
Sciatic nerve	No tissue available
Urinary bladder	Hyperplasia papillomatous
Uterus	Endometriosis
	Haemorrhagic cyst

KWG 0519 - Mouse Chronic Toxicity Study
Full Macro/Micro Report

Rat No: 82
SEX: Female
DOSE LEVEL: Oppa KWG 0519

MACROSCOPIC FINDINGS

	Mode of death : Terminal kill
	Days under test : 735
	Date of death : 15/07/80
Lung	Isolated black foci
Ovary	Both: Cysts (0.3cm diam)
Pancreas	Hardened

MICROSCOPIC FINDINGS

Adrenal/1	Pigmentation (severe)
Adrenal/2	Pigmentation (severe)
Kidney/1	Interstitial nephritis (severe)
Kidney/2	Interstitial nephritis (severe)
Lung	Atelectasis
Ovary/1	Atrophy
Ovary/2	Atrophy
Pancreas	Periarteritis
Thyroid/1	No tissue available
Thyroid/2	No tissue available
Urinary bladder	Inflammation chronic
Mesentery	Inflammation chronic

KWG 0519 - Mouse Chronic Toxicity Study
Full Macro/Micro Report

Rat No: 83
SEX: Female
DOSE LEVEL: Oppm KWG 0519

MACROSCOPIC FINDINGS

	Mode of death : Terminal kill
	Days under test : 735
	Date of death : 15/07/80
Ovary	Both: Enlarged (1.0cm diam) filled with clear/haemorrhagic fluid, gelatinous

MICROSCOPIC FINDINGS

Adrenal/1	Pigmentation (severe)
	Fat vacuoles
Adrenal/2	Pigmentation (severe)
Kidney/1	Interstitial nephritis (minimal)
	Cysts (minimal)
Kidney/2	Interstitial nephritis (minimal)
	Cysts (minimal)
Liver	Fat vacuoles (minimal)
Lung	Pneumonia
Ovary/1	Inflammation acute (severe)
	Haemorrhagic cyst (severe)
Ovary/2	Atrophy
Sciatic nerve	No tissue available
Spleen	Haematopoiesis (moderate)
Urinary bladder	Inflammation chronic
Uterus	Hyperplasia secretory
Mesentery	Inflammation chronic

KWG 0519 - Mouse Chronic Toxicity Study
Full Macro/Micro Report

Rat No: 84
SEX: Female
DOSE LEVEL: Oppm KWG 0519

MACROSCOPIC FINDINGS

Mode of death	: Terminal kill
Days under test	: 735
Date of death	: 15/07/80
Brain	Pale
Kidney	Clay coloured
Liver	Clay coloured
Ovary	Left: Enlarged (5.0cm diam) haemorrhagic, gelatinous
Pituitary	Pale
Spleen	Enlarged (2.6 x 0.7cm)

MICROSCOPIC FINDINGS

Adrenal/1	Pigmentation (minimal)
Adrenal/2	Pigmentation (minimal)
Kidney/1	Normal
Kidney/2	Normal
Liver	Fat vacuoles (minimal)
	Hepatocytic hyperpigmentation (minimal)
Lung	Normal
Ovary/1	Haemorrhagic cyst (severe)
Ovary/2	Haemorrhagic cyst (severe)
Spleen	Hyperplasia lymphoid
Thyroid/1	No tissue available
Thyroid/2	No tissue available
Uterus	Normal

KWG 0519 - Mouse Chronic Toxicity Study
Full Macro/Micro Report

Rat No: 85
SEX: Female
DOSE LEVEL: Oppm KWG 0519

MACROSCOPIC FINDINGS

	Mode of death : Interim death
	Days under test : 666
	Date of death : 07/05/80
Abdominal cavity	5ml haemorrhagic fluid
Kidney	Left: Cysts
Lung	White-grey hard areas (0.3cm diam)

MICROSCOPIC FINDINGS

Brain	Fat vacuoles
Heart	Congestion
Kidney/1	Progressive nephropathy (minimal)
Kidney/2	Progressive nephropathy (minimal)
Liver	Congestion
Lung	Haemorrhage
	Congestion
Ovary/1	Atrophy
Ovary/2	Atrophy
Spleen	Haematopoiesis (severe)
Uterus	Hyperplasia polypoid
Mesentery	Inflammation chronic

KWG 0519 - Mouse Chronic Toxicity Study
Full Macro/Micro Report

Rat No: 86
SEX: Female
DOSE LEVEL: Oppm KWG 0519

MACROSCOPIC FINDINGS

	Mode of death : Interim death
	Days under test : 668
	Date of death : 09/05/80
Condition at necropsy	Moribund
General observations	Loss of weight
Lung	Lob. inf. dxtr. lat: Dark red discolouration
	Lob. inf. dxtr. med: Dark red discolouration

MICROSCOPIC FINDINGS

Kidney/1	Tubulopathy (severe)
Kidney/2	Tubulopathy (severe)
Lung	Haemorrhage
	Congestion (severe)
Ovary/1	Hypertrophic corpora lutea
Ovary/2	Hypertrophic corpora lutea
Stomach	Inflammation chronic
	Mucoid cyst (minimal)
Uterus	Hyperplasia secretory

KWG 0519 - Mouse Chronic Toxicity Study
Full Macro/Micro Report

Rat No: 87
SEX: Female
DOSE LEVEL: Oppm KWG 0519

MACROSCOPIC FINDINGS

	Mode of death : Interim death
	Days under test : 562
	Date of death : 24/01/80
Condition at necropsy	Autolysis (few organs)
Intestine	Reddish contents
Lung	Lob. sup. dxtr: Flesh coloured
Spleen	Enlarged (3.2 x 0.7cm)
Stomach	Mucosal bleeding

MICROSCOPIC FINDINGS

Adrenal/1	Pigmentation (severe)
Adrenal/2	Pigmentation (severe)
Heart	Congestion
Kidney/1	Autolysis (partial)
	Interstitial nephritis (minimal)
	Dilatation glomerular loops
Kidney/2	Autolysis (partial)
	Interstitial nephritis (minimal)
	Dilatation glomerular loops
Liver	Autolysis (partial)
	MALIGNANT LYMPHOMA
Lung	Pneumonia
	Congestion
Ovary/1	MALIGNANT LYMPHOMA
Ovary/2	MALIGNANT LYMPHOMA
Pituitary	No tissue available
Skeletal muscle	MALIGNANT LYMPHOMA
Spleen	Autolysis (partial)
	MALIGNANT LYMPHOMA
Stomach	Normal
Urinary bladder	MALIGNANT LYMPHOMA
Uterus	MALIGNANT LYMPHOMA
Duodenum	Autolysis
Mesentery	MALIGNANT LYMPHOMA

KWG 0519 - Mouse Chronic Toxicity Study
Full Macro/Micro Report

Rat No: 88
SEX: Female
DOSE LEVEL: Oppa KWG 0519

MACROSCOPIC FINDINGS

	Mode of death : Interim death
	Days under test : 460
	Date of death : 14/10/79
Abdominal cavity	Hard partly soft nodule (2.5cm diam) containing haemorrhagic fluid and mass adherent to spleen and stomach
Condition at necropsy	Autolysis (few organs)

MICROSCOPIC FINDINGS

Brain	Congestion
Heart	Congestion
Kidney/1	Calcification (minimal)
	Congestion (minimal)
	Interstitial nephritis (minimal)
Kidney/2	Calcification (minimal)
	Congestion (minimal)
	Interstitial nephritis (minimal)
Liver	Calcification
	Congestion
Lung	Congestion
Ovary/1	Atrophy
	Cysts
Ovary/2	Atrophy
	Cysts
Pancreas	Autolysis
Spleen	Pigmentation (moderate)
Stomach	Autolysis
Urinary bladder	Autolysis
Uterus	MALIGNANT TUMOUR leiomyosarcoma
	Haemorrhage

KWG 0519 - Mouse Chronic Toxicity Study
Full Macro/Micro Report

Rat No: 89
SEX: Female
DOSE LEVEL: 0ppm KWG 0519

MACROSCOPIC FINDINGS

	Mode of death : Terminal kill
	Days under test : 735
	Date of death : 15/07/80
Lung	Lob. inf. dxtr. lat: Beige nodule (0.7cm diam)
Spleen	Lob. sin: Dark red focus (0.4cm diam)
	Enlarged (2.3 x 0.7cm)

MICROSCOPIC FINDINGS

Liver	Vacuolisation (minimal)
Lung	MALIGNANT TUMOUR alveogenic carcinoma
	Oedema
	Haemorrhage
	MALIGNANT LYMPHOMA
Ovary/1	Cysts
	Hypertrophic corpora lutea
Ovary/2	Hypertrophic corpora lutea
Spleen	Normal
Stomach	Inflammation chronic (severe)
Thyroid/1	No tissue available
Thyroid/2	No tissue available
Thymus	MALIGNANT LYMPHOMA

KWG 0519 - Mouse Chronic Toxicity Study
Full Macro/Micro Report

Rat No: 90
SEX: Female
DOSE LEVEL: 0ppm KWG 0519

MACROSCOPIC FINDINGS

Condition at necropsy

Mode of death : Interim death
Days under test : 428
Date of death : 12/09/79
Autolysis (complete)
Evaluation not possible

MICROSCOPIC FINDINGS

Adrenal/1	Autolysis
Adrenal/2	Autolysis
Bone (femur)	Autolysis
Brain	Autolysis
Kidney/1	Autolysis
Kidney/2	Autolysis
Liver	Autolysis
Lung	Autolysis
Ovary/1	Autolysis
Ovary/2	Autolysis
Pancreas	Autolysis
Pituitary	Autolysis
Sciatic nerve	Autolysis
Skeletal muscle	Autolysis
Spleen	Autolysis
Stomach	Autolysis
Thyroid/1	Autolysis
Thyroid/2	Autolysis
Urinary bladder	Autolysis

KWG 0519 - Mouse Chronic Toxicity Study
Full Macro/Micro Report

Rat No: 91
SEX: Female
DOSE LEVEL: 0ppm KWG 0519

MACROSCOPIC FINDINGS

	Mode of death : Interim death
	Days under test : 611
	Date of death : 13/03/80
Lung	Dark foci/areas
	Lob. sup. dxtr: White-grey nodule (0.3cm diam)
Spleen	Enlarged (2.5 x 0.6cm)
Uterus	Horns thickened (0.4cm diam)

MICROSCOPIC FINDINGS

Kidney/1	Interstitial nephritis (moderate)
Kidney/2	Interstitial nephritis (moderate)
Liver	Congestion
Lung	MALIGNANT TUMOUR alveogenic carcinoma
	Hyperplasia lymphoid
Ovary/1	No tissue available
Ovary/2	No tissue available
Pancreas	Inflammation chronic
Pituitary	No tissue available
Spleen	Congestion
Urinary bladder	MALIGNANT LYMPHOMA
Uterus	Cystic endometrial hyperplasia
	Endometritis
Lymph node	MALIGNANT LYMPHOMA
Mesentery	MALIGNANT LYMPHOMA

KWG 0519 - Mouse Chronic Toxicity Study
Full Macro/Micro Report

Rat No: 92
SEX: Female
DOSE LEVEL: Oppm KWG 0519

MACROSCOPIC FINDINGS

	Mode of death : Terminal kill
	Days under test : 735
	Date of death : 15/07/80
Lung	White-beige foci (0.2-0.3cm diam)
Ovary	Both: Fluid filled (0.8-1.1cm diam)

MICROSCOPIC FINDINGS

Kidney/1	Interstitial nephritis (minimal)
Kidney/2	Interstitial nephritis (minimal)
Liver	Vacuolisation
Lung	MALIGNANT TUMOUR alveogenic carcinoma
Ovary/1	BENIGN TUMOUR cystadenoma
Ovary/2	Cysts (severe)
Pituitary	No tissue available
Spleen	Haematopoiesis (moderate)
Thyroid/1	Cysts
Thyroid/2	Cysts
Urinary bladder	Inflammation chronic
Uterus	Hyperplasia papillomatous Cystic endometrial hyperplasia

KWG 0519 - Mouse Chronic Toxicity Study
Full Macro/Micro Report

Rat No: 93
SEX: Female
DOSE LEVEL: Oppm KWG 0519

MACROSCOPIC FINDINGS

	Mode of death : Interim death
	Days under test : 712
	Date of death : 22/06/80
Condition at necropsy	Autolysis (few organs)
Lung	Lob. dxtr: White hard nodule (0.7cm diam)
Neck and thoracic region	Skin inflammed
Ovary	Left: Cysts (0.7cm diam) haemorrhagic
Spleen	Enlarged (2.6 x 0.5)

MICROSCOPIC FINDINGS

Adrenal/1	Amyloid
Adrenal/2	Amyloid
Kidney/1	Progressive nephropathy (severe)
Kidney/2	Progressive nephropathy (severe)
Liver	Autolysis (partial)
	Mononuclear cells (moderate)
Lung	MALIGNANT TUMOUR alveogenic carcinoma
Ovary/1	Haemorrhage
	Arteritis
Ovary/2	Atrophy
Pancreas	Autolysis (partial)
Spleen	Amyloid
Thyroid/1	Cysts
Urinary bladder	Unreadable

KWG 0519 - Mouse Chronic Toxicity Study
Full Macro/Micro Report

Rat No: 94
SEX: Female
DOSE LEVEL: Oppm KWG 0519

MACROSCOPIC FINDINGS

Mode of death	: Interim death
Days under test	: 651
Date of death	: 22/04/80
Condition at necropsy	Moribund
Adrenal gland	Left: Enlarged
General observations	Apathetic/listless
Intestine	Red-brown contents
Kidney	Pale
	Surface raised areas
Liver	Enlarged
Lung	Dark foci/areas
	Lob. inf. dxtr. lat: White area (0.4cm diam)
Spleen	Enlarged (3.2 x 1.0cm) grey-white mottled surface
Stomach	Mucosal bleeding
Uterus	Left horn: Beige hard nodule (0.7cm diam)

MICROSCOPIC FINDINGS

Adrenal/1	MYELOID LEUKAEMIA
Kidney/1	MYELOID LEUKAEMIA
Kidney/2	MYELOID LEUKAEMIA
Liver	MYELOID LEUKAEMIA
Lung	MALIGNANT TUMOUR alveogenic carcinoma
Ovary/1	MYELOID LEUKAEMIA
Ovary/2	MYELOID LEUKAEMIA
Pituitary	No tissue available
Skeletal muscle	MYELOID LEUKAEMIA
Spleen	MYELOID LEUKAEMIA
Uterus	MALIGNANT TUMOUR leiomyosarcoma
	MYELOID LEUKAEMIA
Lymph node	MYELOID LEUKAEMIA
	Lymphatic ectasia

KWG 0519 - Mouse Chronic Toxicity Study
Full Macro/Micro Report

Rat No: 95
SEX: Female
DOSE LEVEL: Oppm KWG 0519

MACROSCOPIC FINDINGS

	Mode of death : Interim death
	Days under test : 659
	Date of death : 30/04/80
Kidney	Clay coloured
Liver	Accentuated lobular marking
Lung	Flesh coloured
Ovary	Right: Yellow hard nodule (0.8cm diam)
Spleen	Enlarged (2.4 x 0.5cm)
Stomach	Mucosal bleeding
Uterus	Horns thickened (0.6cm diam)

MICROSCOPIC FINDINGS

Adrenal/1	Pigmentation (severe)
Adrenal/2	Pigmentation (severe)
	Hyperplastic nodule
Kidney/1	Progressive nephropathy
Kidney/2	Progressive nephropathy
Liver	Congestion
Lung	Normal
Ovary/1	Arteritis
Ovary/2	Arteritis
Pancreas	Autolysis (partial)
Spleen	MALIGNANT LYMPHOMA
Stomach	Normal
Thyroid/1	Autolysis (partial)
Thyroid/2	Autolysis (partial)
Urinary bladder	MALIGNANT LYMPHOMA
Uterus	MALIGNANT TUMOUR leiomyosarcoma
	Endometriosis
	Endometritis
	MALIGNANT LYMPHOMA
Mesentery	MALIGNANT LYMPHOMA

KWG 0519 - Mouse Chronic Toxicity Study
Full Macro/Micro Report

Rat No: 96
SEX: Female
DOSE LEVEL: 0ppm KWG 0519

MACROSCOPIC FINDINGS

	Mode of death : Terminal kill
	Days under test : 735
	Date of death : 15/07/80
Ovary	Right: Fluid filled, Left: Enlarged yellow hard mass (0.8cm diam)

MICROSCOPIC FINDINGS

Adrenal/1	Pigmentation (severe)
Adrenal/2	Pigmentation (severe)
Liver	Mononuclear cells (minimal)
	Vacuolisation
	Hepatocytic hyperpigmentation (minimal)
Lung	Pneumonia (severe)
Ovary/1	Inflammation acute
	Cysts
Ovary/2	Cysts
Pancreas	Fibrosis
Spleen	Haematopoiesis (minimal)
Stomach	Mucoid cyst (minimal)
Thyroid/1	No tissue available
Thyroid/2	No tissue available
Urinary bladder	Hyperplasia papilliomatous
Uterus	Endometriosis (severe)

KWG 0519 - Mouse Chronic Toxicity Study
Full Macro/Micro Report

Rat No: 97
SEX: Female
DOSE LEVEL: Oppm KWG 0519

MACROSCOPIC FINDINGS

Mode of death	: Interim death
Days under test	: 652
Date of death	: 29/04/80
Adrenal gland	Left: Enlarged
Liver	Enlarged
Lung	Flesh coloured
Spleen	Enlarged (3.4 x 0.6cm diam)

MICROSCOPIC FINDINGS

Adrenal/1	MALIGNANT LYMPHOMA
Adrenal/2	MALIGNANT LYMPHOMA
Heart	Congestion
Liver	MALIGNANT LYMPHOMA
Lung	Oedema
	Congestion
Ovary/1	MALIGNANT LYMPHOMA
Ovary/2	MALIGNANT LYMPHOMA
Pancreas	Autolysis
Pituitary	No tissue available
Skeletal muscle	MALIGNANT LYMPHOMA
Spleen	Autolysis (partial)
	MALIGNANT LYMPHOMA
Uterus	MALIGNANT LYMPHOMA
Lymph node	MALIGNANT LYMPHOMA
Mesentery	MALIGNANT LYMPHOMA

KWG 0519 - Mouse Chronic Toxicity Study
Full Macro/Micro Report

Rat No: 98
SEX: Female
DOSE LEVEL: Oppm KWG 0519

MACROSCOPIC FINDINGS

	Mode of death : Interim death
	Days under test : 535
	Date of death : 28/12/79
Condition at necropsy	Autolysis (numerous organs)
Ovary	Both: Grey, hard nodules (1.2cm diam)
Spleen	Enlarged (4.5 x 0.8cm)

MICROSCOPIC FINDINGS

Brain	No tissue available
Heart	Thrombosis
Kidney/1	Autolysis
Kidney/2	Autolysis
Liver	Autolysis
Lung	Oedema (severe)
Pancreas	Autolysis
Spleen	Autolysis
Stomach	Autolysis
Urinary bladder	Autolysis

KWG 0519 - Mouse Chronic Toxicity Study
Full Macro/Micro Report

Rat No: 99
SEX: Female
DOSE LEVEL: Oppm KWG 0519

MACROSCOPIC FINDINGS

	Mode of death : Interim death
	Days under test : 505
	Date of death : 28/11/79
Condition at necropsy	Moribund
Adrenal gland	Enlarged (0.2cm diam)
Cranium	Indurated
	Hard nodule (0.25cm diam) base of cranium
Femur	Right: Head osseous induration (0.8cm diam)
Ovary	Left: Cysts (0.3cm diam)
Pelvis	Left under spinal column, hard thickening (2.0 x 1.0cm)
Uterus	Horns swollen (0.35cm diam)

MICROSCOPIC FINDINGS

Adrenal/1	Pigmentation (severe)
Adrenal/2	Pigmentation (severe)
	Hyperplasia glomerulosa
Bone (femur)	MALIGNANT TUMOUR osteogenic sarcoma
Kidney/1	Tubulopathy
	Interstitial nephritis (minimal)
	Dilatation glomerular loops (minimal)
Kidney/2	Tubulopathy
	Interstitial nephritis (minimal)
	Dilatation glomerular loops (minimal)
Liver	Mononuclear cells (minimal)
Lung	Pneumonia
Ovary/1	Atrophy
Ovary/2	Cysts
Pituitary	No tissue available
Spleen	Haematopoiesis (minimal)
Urinary bladder	Hyperplasia papillomatous
Uterus	Unreadable
Skull	METASTASIS osteogenic sarcoma

KWG 0519 - Mouse Chronic Toxicity Study
Full Macro/Micro Report

Rat No: 100
SEX: Female
DOSE LEVEL: Oppm KWG 0519

MACROSCOPIC FINDINGS

	Mode of death : Terminal kill
	Days under test :.735
	Date of death : 15/07/80
Ovary	Cysts (0.3cm diam)

MICROSCOPIC FINDINGS

Adrenal/1	Pigmentation (severe)
Brain	Fat vacuoles (minimal)
Kidney/1	Tubulopathy (minimal)
	Interstitial nephritis (minimal)
Kidney/2	Tubulopathy (minimal)
	Interstitial nephritis (minimal)
Liver	Fat vacuoles (minimal)
	Mononuclear cells (minimal)
Ovary/1	Inflammation chronic
	Cysts
Ovary/2	Cysts
Pituitary	No tissue available
Spleen	Haematopoiesis (severe)
Stomach	Mucoid cyst (minimal)
Urinary bladder	Hyperplasia papillomatous

KWG 0519 - Mouse Chronic Toxicity Study
Full Macro/Micro Report

Rat No: 101
SEX: Male
DOSE LEVEL: 125ppm KWG 0519

MACROSCOPIC FINDINGS

	Mode of death : Interim death
	Days under test : 168
	Date of death : 26/12/78
Intestine	Haemorrhagic contents
Stomach	Mucosal bleeding

MICROSCOPIC FINDINGS

Brain	Fat vacuoles (minimal)
Kidney/1	Calcification (minimal)
Liver	Autolysis (partial)
Lung	Oedema
	Pneumonia
	Congestion
Pancreas	Autolysis (partial)
Pituitary	No tissue available
Stomach	Normal
Testis/1	Autolysis (partial)
Testis/2	Autolysis (partial)
Thyroid/1	No tissue available
Thyroid/2	No tissue available
Intestine	Normal

KWG 0519 - Mouse Chronic Toxicity Study
Full Macro/Micro Report

Rat No: 102
SEX: Male
DOSE LEVEL: 125ppm KWG 0519

MACROSCOPIC FINDINGS

	Mode of death : Interim death
	Days under test : 665
	Date of death : 06/05/80
Kidney	Multiple dark foci
Liver	Lob. dxtr: Soft, beige-brown nodule (2.4 x 1.5cm)
Lung	Dark foci/areas
Spleen	Clay coloured

MICROSCOPIC FINDINGS

Adrenal/1	BENIGN TUMOUR phaeochromocytoma
Kidney/1	Calcification (moderate)
	Cysts (moderate)
	Dilatation renal pelvis (moderate)
Kidney/2	Calcification (moderate)
Liver	BENIGN TUMOUR hepatocellular adenoma
	Fat vacuoles (severe)
	Fibrosis (severe)
	Haemorrhage (severe)
Lung	Congestion (severe)
Pancreas	Fatty cyst. No pancreatic tissue
Spleen	Haematopoiesis (moderate)
Urinary bladder	Autolysis (partial)
	Ectasia simple

KWG 0519 - Mouse Chronic Toxicity Study
Full Macro/Micro Report

Rat No: 103
SEX: Male
DOSE LEVEL: 125ppm KWG 0519

MACROSCOPIC FINDINGS

	Mode of death : Interim death
	Days under test : 540
	Date of death : 02/01/80
Intestine	Red-brown contents
Lung	Dark foci/areas
Stomach	Mucosal bleeding

MICROSCOPIC FINDINGS

Kidney/1	Congestion
Kidney/2	Congestion
Liver	Fat vacuoles (minimal)
Lung	Pneumonia (severe)
	Congestion (severe)
Pancreas	Autolysis (partial)
Stomach	Haemorrhage
Testis/1	Spermatocoele (minimal)
Urinary bladder	Autolysis (partial)

KWG 0519 - Mouse Chronic Toxicity Study
Full Macro/Micro Report

Rat No: 104
SEX: Male
DOSE LEVEL: 125ppm KWG 0519

MACROSCOPIC FINDINGS

	Mode of death : Interim death
	Days under test : 482
	Date of death : 05/11/79
Liver	Lob. sin: Slight induration (1.4 x 1.0cm)
Seminal vesicle	Left: Indurated red and grey discolouration

MICROSCOPIC FINDINGS

Brain	No tissue available
Heart	Congestion
Kidney/1	Autolysis (partial)
Kidney/2	Autolysis (partial)
Liver	Autolysis (partial)
	Calcification
	Fat vacuoles
	Hyperplastic nodules
Lung	Oedema
Pancreas	Autolysis
Pituitary	No tissue available
Seminal vesicle	Calcification
	Coagulum
Spleen	Autolysis
Stomach	Autolysis
Testis/1	Calcification (moderate)
Thyroid/1	Autolysis (partial)
Thyroid/2	Autolysis (partial)
Urinary bladder	Autolysis

KWG 0519 - Mouse Chronic Toxicity Study
Full Macro/Micro Report

Rat No: 105
SEX: Male
DOSE LEVEL: 125ppm KWG 0519

MACROSCOPIC FINDINGS

	Mode of death : Interim death
	Days under test : 682
	Date of death : 23/05/80
Condition at necropsy	Moribund
Liver	Lob. sin: Enlarged swollen
	Portal: Dark red soft nodule (1.4cm diam)

MICROSCOPIC FINDINGS

Kidney/1	Tubulopathy (moderate)
Liver	BENIGN TUMOUR hepatocellular adenoma
	Haemorrhage (severe)
	Congestion (severe)
Lung	Haemorrhage (moderate)
	Congestion
	Atelectasis (moderate)
Pituitary	No tissue available
Spleen	Haematopoiesis (severe)
Testis/1	Spermatocoele (minimal)

KWG 0519 - Mouse Chronic Toxicity Study
Full Macro/Micro Report

Rat No: 106
SEX: Male
DOSE LEVEL: 125ppm KWG 0519

MACROSCOPIC FINDINGS

	Mode of death : Interim death
	Days under test : 546
	Date of death : 08/01/80
Abdominal cavity	10ml haemorrhagic fluid
Spleen	Enlarged (6.4 x 2.0) beige-white discolouration hard
Thoracic cavity	4ml haemorrhagic-serous fluid
Mesenteric lymph node	Enlarged

MICROSCOPIC FINDINGS

Kidney/1	Dilatation glomerular loops (minimal)
Kidney/2	Dilatation glomerular loops (minimal)
Liver	MALIGNANT LYMPHOMA
Lung	Pneumonia (minimal)
Spleen	MALIGNANT LYMPHOMA
Lymph node	MALIGNANT LYMPHOMA

KWG 0519 - Mouse Chronic Toxicity Study
Full Macro/Micro Report

Rat No: 107
SEX: Male
DOSE LEVEL: 125ppm KWG 0519

MACROSCOPIC FINDINGS

	Mode of death : Terminal kill
	Days under test : 734
	Date of death : 14/07/80
Kidney	Both: Cysts (0.1cm diam)
Lung	Lob. inf. dxtr. med: Flesh coloured
	Lob. sin: Dark beige foci (0.1-0.2cm diam)
	Lob. med. dxtr: Enlarged (1.5 x 0.4cm) light beige hardened
Pancreas	Light coloured hardened

MICROSCOPIC FINDINGS

Heart	Periarteritis (moderate)
Kidney/1	Tubulopathy (minimal)
	Cysts (moderate)
Kidney/2	Tubulopathy (minimal)
	Cysts (moderate)
Lung	MALIGNANT TUMOUR alveogenic carcinoma
Pancreas	Normal
Spleen	Hyperplasia lymphoid (moderate)
	Haematopoiesis (severe)
Thyroid/1	No tissue available
Thyroid/2	No tissue available

KWG 0519 - Mouse Chronic Toxicity Study
Full Macro/Micro Report

Rat No: 108
SEX: Male
DOSE LEVEL: 125ppm KWG 0519

MACROSCOPIC FINDINGS

	Mode of death : Interim death
	Days under test : 699
	Date of death : 09/06/80
Condition at necropsy	Autolysis (few organs)
Lung	Lob. dxtr:
	Dark/red foci/areas
Stomach	Mucosa covered with grey-green mucus

MICROSCOPIC FINDINGS

Kidney/1	Tubulopathy (minimal)
	Interstitial nephritis (minimal)
Kidney/2	Tubulopathy (minimal)
	Interstitial nephritis (minimal)
Lung	Normal
Spleen	Haematopoiesis (minimal)
Stomach	Normal
Testis/1	Atrophy seminiferous tubules (minimal)

KWG 0519 - Mouse Chronic Toxicity Study
Full Macro/Micro Report

Rat No: 109
SEX: Male
DOSE LEVEL: 125ppm KWG 0519

MACROSCOPIC FINDINGS

	Mode of death : Interim death
	Days under test : 573
	Date of death : 04/02/80
Lung	Dark/red foci/areas
Stomach	Enlarged

MICROSCOPIC FINDINGS

Heart	Congestion
Kidney/1	Interstitial nephritis (moderate)
Kidney/2	Interstitial nephritis (moderate)
Liver	Autolysis (partial)
Lung	Haemorrhage
	Congestion
	Atelectasis
Pancreas	Autolysis (partial)
Spleen	Autolysis (partial)
Stomach	Inflammation chronic (moderate)
Thyroid/1	Cysts (minimal)

KWG 0519 - Mouse Chronic Toxicity Study
Full Macro/Micro Report

Rat No: 110
SEX: Male
DOSE LEVEL: 125ppm KWG 0519

MACROSCOPIC FINDINGS

	Mode of death : Terminal kill
	Days under test : 734
	Date of death : 14/07/80
Kidney	Left: Cysts (0.15-0.2cm diam),raised areas on surface
Liver	Proc. pap: Coalesced conglomerate (1.4 x 0.9cm) partly soft beige coloured

MICROSCOPIC FINDINGS

Kidney/1	Fibrosis (minimal)
	Cysts (severe)
	Dilatation renal pelvis (moderate)
Kidney/2	Fibrosis (minimal)
	Cysts (severe)
Liver	Hyperplastic nodule
Spleen	Haematopoiesis (severe)
Testis/1	Atrophy seminiferous tubules (minimal)
	Inflammation chronic (minimal)
Testis/2	Atrophy seminiferous tubules (minimal)
	Inflammation chronic (minimal)
Thyroid/1	No tissue available
Thyroid/2	No tissue available

KWG 0519 - Mouse Chronic Toxicity Stuay
Full Macro/Micro Report

Rat No: 111
SEX: Male
DOSE LEVEL: 125ppm KWG 0519

MACROSCOPIC FINDINGS

	Mode of death : Interim death
	Days under test : 499
	Date of death : 22/11/79
Condition at necropsy	Autolysis (few organs)
Femur	Right: Soft nodule (0.7cm diam) cut surface white soft
Hypogastrium	Hard whitish nodule (0.6cm diam) cut surface whitish
Kidney	Right: Cranial pole soft white thickening (0.1cm diam), Left: At neck soft caseous nodule (0.3cm diam)
Lung	Lob. sup. dxtr: Hard white nodule (0.8 x 0.4cm)
	Lob. inf. dxtr. med. lat: Multiple hard white nodules (0.1cm diam)

MICROSCOPIC FINDINGS

Adrenal/1	BENIGN TUMOUR cortical adenoma
Heart	METASTASIS adenocarcinoma
Kidney/1	METASTASIS adenocarcinoma
Lung	MALIGNANT TUMOUR alveogenic carcinoma
Stomach	Mucoid cyst (moderate)
Thyroid/1	No tissue available
Thyroid/2	No tissue available

KWG 0519 - Mouse Chronic Toxicity Study
Full Macro/Micro Report

Rat No: 112
SEX: Male
DOSE LEVEL: 125ppm KWG 0519

MACROSCOPIC FINDINGS

	Mode of death : Interim death
	Days under test : 607
	Date of death : 09/03/80
Lung	Dark/red foci/areas
	Lob. sup. dxtr: Hard white-grey nodule (1.2cm diam)
	Lob. inf. dxtr. lat: Hard white-grey nodule (0.4cm diam)
Seminal vesicle	Enlarged

MICROSCOPIC FINDINGS

Adrenal/1	Hyperplasia glomerulosa
Heart	Dilated chamber
Kidney/1	Calcification (minimal)
	Tubulopathy (minimal)
	Interstitial nephritis (minimal)
Kidney/2	Calcification (minimal)
	Tubulopathy (minimal)
	Interstitial nephritis (minimal)
Liver	Mononuclear cells (minimal)
Lung	MALIGNANT TUMOUR alveogenic carcinoma
Seminal vesicle	Coagulum
Spleen	Congestion
Thyroid/1	No tissue available
Thyroid/2	No tissue available

KWG 0519 - Mouse Chronic Toxicity Study
Full Macro/Micro Report

Rat No: 113
SEX: Male
DOSE LEVEL: 125ppm KWG 0519

MACROSCOPIC FINDINGS

	Mode of death : Interim death
	Days under test : 576
	Date of death : 07/02/80
Condition at necropsy	Autolysis (few organs)
Liver	Clay coloured areas
Lung	Dark foci/areas

MICROSCOPIC FINDINGS

Heart	Congestion
Kidney/1	Calcification (minimal)
	Interstitial nephritis (minimal)
Kidney/2	Calcification (minimal)
	Interstitial nephritis (minimal)
Lung	Bronchopneumonia (severe)
	Congestion
Spleen	Haematopoiesis (moderate)
Testis/1	Calcification (moderate)
	Spermatocoele (moderate)
Testis/2	Calcification (moderate)

KWG 0519 - Mouse Chronic Toxicity Study
Full Macro/Micro Report

Rat No: 114
SEX: Male
DOSE LEVEL: 125ppm KWG 0519

MACROSCOPIC FINDINGS

	Mode of death : Interim death
	Days under test : 560
	Date of death : 22/01/80
Spleen	Enlarged (2.2 x 0.5cm)
Abdomen	Skin of chest fore extremities and abdomen inflamed and coalesced

MICROSCOPIC FINDINGS

Kidney/1	Autolysis (partial)
	Calcification (moderate)
Kidney/2	Autolysis (partial)
Lung	MALIGNANT TUMOUR alveogenic carcinoma
	Pneumonia
Pancreas	Autolysis
Sciatic nerve	No tissue available
Spleen	Autolysis
Stomach	Autolysis
Thyroid/1	Autolysis (partial)
	Cysts
Thyroid/2	Autolysis (partial)
Urinary bladder	Autolysis

KWG 0519 - Mouse Chronic Toxicity Study
Full Macro/Micro Report

Rat No: 115
SEX: Male
DOSE LEVEL: 125ppm KWG 0519

MACROSCOPIC FINDINGS

	Mode of death : Interim death
	Days under test : 628
	Date of death : 30/03/80
Lung	Lob. sin: Indurated white area (0.2cm diam)
	Lob. dxtr: Indurated beige nodule (0.6cm diam)
Spleen	Enlarged (3.2 x 0.6cm)

MICROSCOPIC FINDINGS

Brain	Fat vacuoles (minimal)
Kidney/1	Tubulopathy (minimal)
Liver	Autolysis (partial)
Lung	MALIGNANT TUMOUR alveogenic carcinoma
Pancreas	Inflammation chronic (minimal)
Pituitary	No tissue available
Seminal vesicle	Coagulum
Spleen	Haemorrhage (severe)
	Haematopoiesis (severe)
Thyroid/1	Autolysis (partial)
Thyroid/2	Autolysis (partial)
Urinary bladder	Ectasia simple

KWG 0519 - Mouse Chronic Toxicity Study
Full Macro/Micro Report

Rat No: 116
SEX: Male
DOSE LEVEL: 125ppm KWG 0519

MACROSCOPIC FINDINGS

	Mode of death : Interim death
	Days under test : 553
	Date of death : 15/01/80
Adrenal gland	Left: Enlarged
Liver	Yellow mottled
Lung	Dark foci/areas
Spleen	Enlarged (2.7 x 0.6cm) yellow mottled

MICROSCOPIC FINDINGS

Kidney/1	Tubulopathy (severe)
Kidney/2	Tubulopathy (severe)
Liver	Amyloid
	MALIGNANT LYMPHOMA
Lung	Pneumonia (severe)
Spleen	Hyperplasia lymphoid
Urinary bladder	Ectasia simple
Lymph node	MALIGNANT LYMPHOMA Infarct

KWG 0519 - Mouse Chronic Toxicity Study
Full Macro/Micro Report

Rat No: 117
SEX: Male
DOSE LEVEL: 125ppm KWG 0519

MACROSCOPIC FINDINGS

	Mode of death : Terminal kill
	Days under test : 734
	Date of death : 14/07/80
Adrenal gland	Right: Beige coloured foci
Lung	Lob. sin: Dark red focus (0.2cm diam)

MICROSCOPIC FINDINGS

Adrenal/1	BENIGN TUMOUR cortical adenoma
	Pigmentation (moderate)
Kidney/1	Interstitial nephritis (minimal)
	Cysts
Kidney/2	Interstitial nephritis (minimal)
Lung	Haemorrhage (minimal)
	Atelectasis (moderate)
Pituitary	No tissue available
Spleen	Haemorrhage (moderate)
	Haematopoiesis (severe)

KWG 0519 - Mouse Chronic Toxicity Study
Full Macro/Micro Report

Rat No: 118
SEX: Male
DOSE LEVEL: 125ppm KWG 0519

MACROSCOPIC FINDINGS

	Mode of death : Interim death
	Days under test : 548
	Date of death : 10/01/80
General observations	Obese

MICROSCOPIC FINDINGS

Kidney/1	Necrosis (severe)
	Pyelonephritis (severe)
Kidney/2	Necrosis (severe)
	Pyelonephritis (severe)
Liver	Congestion
Lung	Oedema (minimal)
Pituitary	No tissue available
Sciatic nerve	No tissue available
Spleen	Haematopoiesis (severe)
Urinary bladder	Inflammation acute glandular

KWG 0519 - Mouse Chronic Toxicity Study
Full Macro/Micro Report

Rat No: 119
SEX: Male
DOSE LEVEL: 125ppm KWG 0519

MACROSCOPIC FINDINGS

	Mode of death : Terminal kill
	Days under test : 734
	Date of death : 14/07/80
Liver	Enlarged
	Swollen marbled surface
Lung	Hard foci, thickened (0.2cm diam)
Spleen	Enlarged (3.0cm diam)
Urinary bladder	Enlarged (1.8 x 2.0cm)

MICROSCOPIC FINDINGS

Adrenal/1	Pigmentation (moderate)
Adrenal/2	Pigmentation (moderate)
Brain	Gliosis
Kidney/1	Cysts (minimal)
Kidney/2	Cysts (minimal)
Liver	Haematopoiesis (severe)
Lung	MALIGNANT TUMOUR alveogenic carcinoma
	Pneumonia
Pituitary	No tissue available
Spleen	Haematopoiesis (severe)
Stomach	Mucoid cyst (severe)
Urinary bladder	Normal

KWG 0519 - Mouse Chronic Toxicity Study
Full Macro/Micro Report

Rat No: 120
SEX: Male
DOSE LEVEL: 125ppm KWG 0519

MACROSCOPIC FINDINGS

	Mode of death : Interim death
	Days under test : 535
	Date of death : 28/12/79
Condition at necropsy	Autolysis (few organs)
Liver	Accentuated lobular marking

MICROSCOPIC FINDINGS

Adrenal/1	BENIGN TUMOUR cortical adenoma
Heart	Congestion
Kidney/1	Dilatation renal pelvis (moderate)
	Progressive nephropathy (moderate)
Kidney/2	Progressive nephropathy (moderate)
Liver	Congestion
Lung	Pneumonia
	Congestion
	Emphysema
Pancreas	Autolysis (partial)
Spleen	Haematopoiesis (severe)
Stomach	Autolysis (partial)
Urinary bladder	Autolysis (partial)

KWG 0519 - Mouse Chronic Toxicity Study
Full Macro/Micro Report

Rat No: 121
SEX: Male
DOSE LEVEL: 125ppm KWG 0519

MACROSCOPIC FINDINGS

	Mode of death : Interim death
	Days under test : 491
	Date of death : 14/11/79
Condition at necropsy	Moribund
General observations	Abdomen hairless
Kidney	Enlarged
	Right: (1.2 x 0.8cm) focal gelatinous cyst
Spleen	Enlarged (2.8 x 0.6cm)
Testis	Right: Atrophic (0.3cm diam)
Thymus	Yellow-grey hard nodule (0.5cm diam)

MICROSCOPIC FINDINGS

Kidney/1	Tubulopathy (minimal)
Kidney/2	Tubulopathy (minimal)
Lung	MALIGNANT TUMOUR alveogenic carcinoma
Spleen	Haematopoiesis (severe)
Testis/1	Atrophy seminiferous tubules (moderate)
	Calcification (moderate)
Testis/2	Atrophy seminiferous tubules (moderate)
	Calcification (moderate)
Thyroid/1	No tissue available
Thyroid/2	No tissue available
Thymus	No tissue available

KWG 0519 - Mouse Chronic Toxicity Study
Full Macro/Micro Report

Rat No: 122
SEX: Male
DOSE LEVEL: 125ppm KWG 0519

MACROSCOPIC FINDINGS

	Mode of death : Interim death
	Days under test : 696
	Date of death : 06/06/80
Condition at necropsy	Autolysis (few organs)
Lung	Reddish

MICROSCOPIC FINDINGS

Adrenal/1	No tissue available
Adrenal/2	No tissue available
Heart	Thrombosis
Kidney/1	Autolysis (partial)
	Fibrosis (minimal)
	Tubulopathy (minimal)
Kidney/2	Autolysis (partial)
Liver	Autolysis (partial)
	Cysts (moderate)
Lung	Normal
Pancreas	Autolysis
Spleen	Autolysis
Stomach	Autolysis (partial)
Urinary bladder	Autolysis (partial)

KWG 0519 - Mouse Chronic Toxicity Study
Full Macro/Micro Report

Rat No: 123
SEX: Male
DOSE LEVEL: 125ppm KWG 0519

MACROSCOPIC FINDINGS

	Mode of death : Terminal kill
	Days under test : 734
	Date of death : 14/07/80
Liver	Lob. sin: Beige hardening (0.7 x 0.6cm diam)
Lung	Lob. sup. dxtr: Beige thickening hardened (0.3cm diam)

MICROSCOPIC FINDINGS

Adrenal/1	Pigmentation (minimal)
Brain	Gliosis
Kidney/1	Tubulopathy (minimal)
Kidney/2	Dilatation glomerular loops (minimal)
Liver	Fat vacuoles (severe)
	Hyperplastic nodule
	Pericholangitis (moderate)
Lung	MALIGNANT TUMOUR alveogenic carcinoma
Pituitary	No tissue available
Skeletal muscle	Vacuolisation (minimal)
Spleen	Haematopoiesis (minimal)
Testis/1	Atrophy seminiferous tubules (severe)
Thyroid/1	No tissue available
Thyroid/2	No tissue available

KWG 0519 - Mouse Chronic Toxicity Study
Full Macro/Micro Report

Rat No: 124
SEX: Male
DOSE LEVEL: 125ppm KWG 0519

MACROSCOPIC FINDINGS

Condition at necropsy	Mode of death : Interim death Days under test : 671 Date of death : 12/05/80 Autolysis (complete) Evaluation not possible

MICROSCOPIC FINDINGS

Brain	No tissue available
Kidney/1	Fibrosis (minimal)
	Cysts (minimal)
Kidney/2	Fibrosis (minimal)
Liver	Autolysis (partial)
Lung	Pneumonia
Pancreas	Autolysis
Spleen	Autolysis (partial)
Stomach	Autolysis (partial)
Thyroid/1	No tissue available
Thyroid/2	No tissue available
Urinary bladder	Autolysis (partial)

KWG 0519 - Mouse Chronic Toxicity Study
Full Macro/Micro Report

Rat No: 125
SEX: Male
DOSE LEVEL: 125ppm KWG 0519

MACROSCOPIC FINDINGS

	Mode of death : Interim death
	Days under test : 425
	Date of death : 09/09/79
Condition at necropsy	Autolysis (numerous organs)
Liver	Lob. sin: Soft brown nodule (1.5cm diam)

MICROSCOPIC FINDINGS

Brain	No tissue available
Kidney/1	Autolysis (partial)
Kidney/2	Autolysis (partial)
Liver	Autolysis (partial)
	BENIGN TUMOUR hepatocellular adenoma
Lung	Oedema
	Emphysema
Pancreas	No tissue available
Pituitary	No tissue available
Spleen	Oedema
Stomach	Autolysis (partial)
Thyroid/1	No tissue available
Thyroid/2	No tissue available
Urinary bladder	Autolysis (partial)

KWG 0519 - Mouse Chronic Toxicity Study
Full Macro/Micro Report

Rat No: 126
SEX: Male
DOSE LEVEL: 125ppm KWG 0519

MACROSCOPIC FINDINGS

	Mode of death	: Interim death
	Days under test	: 698
	Date of death	: 08/06/80
General observations	Obese	
Kidney	Pale	
	Crateriform foci	
Liver	Enlarged	
Lung	Dark/red coloured	

MICROSCOPIC FINDINGS

Kidney/1	Progressive nephropathy (minimal)
Kidney/2	Progressive nephropathy (minimal)
Liver	Inflammation granulomatous (moderate)
	Haematopoiesis (severe)
Lung	MALIGNANT TUMOUR alveogenic carcinoma
Pituitary	No tissue available
Soleen	Haematopoiesis (severe)
Thyroid/1	Autolysis (partial)
Thyroid/2	Autolysis (partial)
Urinary bladder	Autolysis (partial)

KWG 0519 - Mouse Chronic Toxicity Study
Full Macro/Micro Report

Rat No: 127
SEX: Male
DOSE LEVEL: 125ppm KWG 0519

MACROSCOPIC FINDINGS

	Mode of death : Terminal kill
	Days under test : 734
	Date of death : 14/07/80
Kidney	Both: Cysts (0.1-0.2cm diam)

MICROSCOPIC FINDINGS

Adrenal/1	BENIGN TUMOUR phaeochromocytoma
Kidney/1	Tubulopathy (minimal)
	Interstitial nephritis (minimal)
Kidney/2	Interstitial nephritis (minimal)
Liver	Vacuolisation (minimal)
Lung	Pneumonia (minimal)
Pituitary	No tissue available
Spleen	Haematopoiesis (minimal)
Thyroid/1	No tissue available
Thyroid/2	No tissue available

KWG 0519 - Mouse Chronic Toxicity Study
Full Macro/Micro Report

Rat No: 128
SEX: Male
DOSE LEVEL: 125ppm KWG 0519

MACROSCOPIC FINDINGS

	Mode of death : Terminal kill
	Days under test : 734
	Date of death : 14/07/80
Kidney	Cysts
Lung	Lob. med. dxtr: Swollen indurated

MICROSCOPIC FINDINGS

Adrenal/1	BENIGN TUMOUR cortical adenoma
	Pigmentation (minimal)
Adrenal/2	Pigmentation (minimal)
Kidney/1	Interstitial nephritis (moderate)
	Cysts (moderate)
Kidney/2	Interstitial nephritis (moderate)
Lung	MALIGNANT TUMOUR alveogenic carcinoma
Pituitary	No tissue available
Spleen	Fibrosis (moderate)
Stomach	Mucoid cyst (minimal)
Testis/1	BENIGN TUMOUR interstitial cell tumour
Thyroid/1	No tissue available
Thyroid/2	No tissue available

KWG 0519 - Mouse Chronic Toxicity Study
Full Macro/Micro Report

Rat No: 129
SEX: Male
DOSE LEVEL: 125ppm KWG 0519

MACROSCOPIC FINDINGS

	Mode of death : Interim death
	Days under test : 369
	Date of death : 15/07/79
Liver	Accentuated lobular marking
Lung	Fleshy areas
Thoracic cavity	2ml clear-serous fluid

MICROSCOPIC FINDINGS

Brain	Gliosis (minimal)
Heart	Pericarditis (moderate)
Kidney/1	Fibrosis (moderate)
	Tubulopathy (minimal)
Kidney/2	Tubulopathy (minimal)
Liver	Congestion
Lung	MALIGNANT TUMOUR alveogenic carcinoma
	Thickened alveolar walls
Pancreas	Autolysis (partial)
Thyroid/1	Autolysis (partial)
Thyroid/2	Autolysis (partial)
Urinary bladder	Autolysis (partial)

KWG 0519 - Mouse Chronic Toxicity Study
Full Macro/Micro Report

Rat No: 130
SEX: Male
DOSE LEVEL: 125ppm KWG 0519

MACROSCOPIC FINDINGS

	Mode of death : Interim death
	Days under test : 580
	Date of death : 11/02/80
Condition at necropsy	Autolysis (complete)
	Evaluation not possible

MICROSCOPIC FINDINGS

Brain	No tissue available
Kidney/1	MALIGNANT LYMPHOMA
Kidney/2	MALIGNANT LYMPHOMA
Liver	Autolysis (partial)
	MALIGNANT LYMPHOMA
Lung	Autolysis (partial)
	MALIGNANT LYMPHOMA
Pancreas	Autolysis
Sciatic nerve	No tissue available
Spleen	MALIGNANT LYMPHOMA
Stomach	Autolysis (partial)
	Haemorrhage
Thyroid/1	No tissue available
Thyroid/2	No tissue available
Urinary bladder	Autolysis (partial)
	MALIGNANT LYMPHOMA
Mesentery	MALIGNANT LYMPHOMA

KWG 0519 - Mouse Chronic Toxicity Study
Full Macro/Micro Report

Rat No: 131
SEX: Male
DOSE LEVEL: 125ppm KWG 0519

MACROSCOPIC FINDINGS

	Mode of death : Interim death
	Days under test : 583
	Date of death : 14/02/80
Adrenal gland	Both: Pale
Kidney	Both: Pale
Liver	Sand coloured
	Accentuated lobular marking
Lung	Lob. sin: White hard nodule (0.4cm diam)
Stomach	Black discolouration mucosa

MICROSCOPIC FINDINGS

Adrenal/1	Normal
Adrenal/2	Normal
Brain	Fat vacuoles (minimal)
Kidney/1	MALIGNANT LYMPHOMA
Kidney/2	MALIGNANT LYMPHOMA
Liver	Fat vacuoles (severe)
	MALIGNANT LYMPHOMA
Lung	MALIGNANT TUMOUR alveogenic carcinoma
	Pneumonia (severe)
	MALIGNANT LYMPHOMA
Pancreas	MALIGNANT LYMPHOMA
Pituitary	No tissue available
Spleen	MALIGNANT LYMPHOMA
Stomach	MALIGNANT LYMPHOMA
Thyroid/1	No tissue available
Thyroid/2	No tissue available
Urinary bladder	MALIGNANT LYMPHOMA

KWG 0519 - Mouse Chronic Toxicity Study
Full Macro/Micro Report

Rat No: 132
SEX: Male
DOSE LEVEL: 125ppm KWG 0519

MACROSCOPIC FINDINGS

Mode of death	: Interim death
Days under test	: 622
Date of death	: 24/03/80
General observations	Obese
Liver	Clay coloured
Lung	Flesh coloured areas
Thoracic cavity	Filled with blood clots

MICROSCOPIC FINDINGS

Brain	Hydrocephalus (minimal)
Kidney/1	Fibrosis (minimal)
	Tubulopathy (minimal)
	Interstitial nephritis (minimal)
Kidney/2	Fibrosis (minimal)
	Tubulopathy (minimal)
	Interstitial nephritis (minimal)
Liver	Fat vacuoles (minimal)
Lung	Haemorrhage
Pituitary	No tissue available
Spleen	Haematopoiesis (minimal)
Testis/1	Atrophy seminiferous tubules (moderate)
Thyroid/1	No tissue available
Thyroid/2	No tissue available

KWG 0519 - Mouse Chronic Toxicity Study
Full Macro/Micro Report

Rat No: 133
SEX: Male
DOSE LEVEL: 125ppm KWG 0519

MACROSCOPIC FINDINGS

	Mode of death : Interim death
	Days under test : 715
	Date of death : 25/06/80
Condition at necropsy	Moribund
Kidney	Clay coloured
	Cysts
Liver	Enlarged
	Hard marbled surface
Testis	Coalesced with epididymides scrotum and adipose tissue
Adipose tissue	Coalesced hard

MICROSCOPIC FINDINGS

Adrenal/1	BENIGN TUMOUR cortical adenoma
Adrenal/2	BENIGN TUMOUR cortical adenoma
Kidney/1	Dilatation renal pelvis (moderate)
	Progressive nephropathy (moderate)
Kidney/2	Progressive nephropathy (moderate)
Liver	Infarct (severe)
	MALIGNANT LYMPHOMA
Pancreas	MALIGNANT LYMPHOMA
Pituitary	No tissue available
Sciatic nerve	No tissue available
Spleen	MALIGNANT LYMPHOMA
Fat	MALIGNANT LYMPHOMA
Mesentery	MALIGNANT LYMPHOMA

KWG 0519 - Mouse Chronic Toxicity Study
Full Macro/Micro Report

Rat No: 134
SEX: Male
DOSE LEVEL: 125ppm KWG 0519

MACROSCOPIC FINDINGS

	Mode of death : Interim death
	Days under test : 523
	Date of death : 16/12/79
Condition at necropsy	Autolysis (numerous organs)
Urinary bladder	Enlarged (1.2cm diam) haemorrhagic contents

MICROSCOPIC FINDINGS

Brain	No tissue available
Heart	Congestion
Kidney/1	Progressive nephropathy (moderate)
Kidney/2	Progressive nephropathy (moderate)
Liver	Autolysis (partial)
Lung	Oedema
	Pneumonia
	Congestion
Pancreas	Cystic dysplasia
Spleen	Autolysis (partial)
	Ectasia vascular
Stomach	Autolysis (partial)
Thyroid/1	Autolysis
Thyroid/2	Autolysis
Urinary bladder	Autolysis (partial)

KWG 0519 - Mouse Chronic Toxicity Study
Full Macro/Micro Report

Rat No: 135
SEX: Male
DOSE LEVEL: 125ppm KWG 0519

MACROSCOPIC FINDINGS

	Mode of death : Interim death
	Days under test : 625
	Date of death : 27/03/80
General observations	Obese
Lung	Dark foci/areas

MICROSCOPIC FINDINGS

Adrenal/l	Hyperplastic nodule
Heart	Congestion
Kidney/l	Dilatation renal pelvis (moderate)
Lung	Haemorrhage
	Congestion
Testis/l	Spermatocoele (minimal)
Urinary bladder	Ectasia simple

KWG 0519 - Mouse Chronic Toxicity Study
Full Macro/Micro Report

Rat No: 136
SEX: Male
DOSE LEVEL: 125ppm KWG 0519

MACROSCOPIC FINDINGS

	Mode of death : Interim death
	Days under test : 714
	Date of death : 24/06/80
Condition at necropsy	Moribund
Abdominal cavity	Adipose tissue hard yellowish coalesced with intestine and accessory reproductive glands
Lung	Flesh coloured

MICROSCOPIC FINDINGS

Kidney/1	Calcification (moderate)
	Progressive nephropathy (moderate)
Kidney/2	Progressive nephropathy (moderate)
Liver	Vacuolisation (minimal)
Spleen	Haematopoiesis (moderate)
Thyroid/1	No tissue available
Thyroid/2	No tissue available
Urinary bladder	Hyperplasia papillomatous
Fat	BENIGN TUMOUR lipoma

KWG 0519 - Mouse Chronic Toxicity Study
Full Macro/Micro Report

Rat No: 137
SEX: Male
DOSE LEVEL: 125ppm KWG 0519

MACROSCOPIC FINDINGS

	Mode of death : Interim death
	Days under test : 715
	Date of death : 25/06/80
Lung	Reddish discolouration
	Lob. sin: Grey hard area (0.1cm diam)
	Lob. sup. dxtr: Enlarged beige-red hard
	Lob. inf. dxtr. lat: Grey hard nodule (0.2cm diam)

MICROSCOPIC FINDINGS

Liver	Haemorrhage (severe)
	Mononuclear cells (severe)
Lung	MALIGNANT TUMOUR alveogenic carcinoma
Pituitary	No tissue available
Spleen	Haematopoiesis (moderate)
	Congestion
Thyroid/1	No tissue available
Thyroid/2	No tissue available

KWG 0519 - Mouse Chronic Toxicity Study
Full Macro/Micro Report

Rat No: 138
SEX: Male
DOSE LEVEL: 125ppm KWG 0519

MACROSCOPIC FINDINGS

	Mode of death : Interim death
	Days under test : 552
	Date of death : 14/01/80
Condition at necropsy	Autolysis (few organs)
General observations	Obese
Liver	Clay coloured areas
	Accentuated lobular marking
Seminal vesicle	Enlarged
Urinary bladder	Enlarged (1.0cm diam)

MICROSCOPIC FINDINGS

Adrenal/1	BENIGN TUMOUR cortical adenoma
Brain	Fat vacuoles (minimal)
Heart	Thrombosis
	Congestion
Kidney/1	Dilatation renal pelvis (minimal)
	Progressive nephropathy (severe)
Kidney/2	Dilatation renal pelvis (minimal)
	Progressive nephropathy (severe)
Liver	Autolysis (partial)
Lung	Haemorrhage
	Adenomatosis
	Congestion
Seminal vesicle	Haemorrhage
	Coagulum
Spleen	Haematopoiesis (severe)
Stomach	Autolysis (partial)
Urinary bladder	Autolysis (partial)

KWG 0519 - Mouse Chronic Toxicity Study
Full Macro/Micro Report

Rat No: 139
SEX: Male
DOSE LEVEL: 125ppm KWG 0519

MACROSCOPIC FINDINGS

	Mode of death : Interim death
	Days under test : 464
	Date of death : 18/10/79
Condition at necropsy	Autolysis (numerous organs)
Lung	Fleshy
Thymus	Soft grey nodule (1.0cm diam)

MICROSCOPIC FINDINGS

Brain	No tissue available
Heart	MALIGNANT LYMPHOMA
Kidney/1	Autolysis (partial)
Kidney/2	Autolysis (partial)
Liver	Autolysis (partial)
Lung	MALIGNANT LYMPHOMA
Pancreas	Autolysis
Pituitary	No tissue available
Sciatic nerve	No tissue available
Spleen	Autolysis (partial)
Stomach	Autolysis (partial)
Thyroid/1	Autolysis (partial)
Thyroid/2	Autolysis (partial)
Urinary bladder	Autolysis (partial)
Thymus	MALIGNANT LYMPHOMA

KWG 0519 - Mouse Chronic Toxicity Stucy
Full Macro/Micro Report

Rat No: 140
SEX: Male
DOSE LEVEL: 125ppm KWG 0519

MACROSCOPIC FINDINGS

	Mode of death : Interim death
	Days under test : 680
	Date of death : 21/05/80
Liver	Clay coloured
	Soft
Lung	Surrounded by blood clots

MICROSCOPIC FINDINGS

Kidney/1	Calcification (minimal)
	Interstitial nephritis (minimal)
Kidney/2	Calcification (minimal)
	Interstitial nephritis (minimal)
Liver	Autolysis (partial)
	Normal
Lung	Adenomatosis (minimal)
Pituitary	No tissue available
Thyroid/1	BENIGN TUMOUR adenoma

KWG 0519 - Mouse Chronic Toxicity Study
Full Macro/Micro Report

Rat No: 141
SEX: Male
DOSE LEVEL: 125ppm KWG 0519

MACROSCOPIC FINDINGS

	Mode of death : Terminal kill
	Days under test : 734
	Date of death : 14/07/80
Liver	Proc. pap: Enlarged (1.7cm diam) beige soft coalesced to form conglomerate
Lung	Lob. sin: Pale thickening (0.5cm diam)

MICROSCOPIC FINDINGS

Kidney/1	Cysts (moderate)
	Ectasia vascular (moderate)
	Dilatation renal pelvis (moderate)
Kidney/2	Cysts (moderate)
	Ectasia vascular (moderate)
	Dilatation renal pelvis (moderate)
Liver	Hyperplastic nodule
	Hyalinosis (moderate)
Lung	MALIGNANT TUMOUR alveogenic carcinoma
Spleen	Haematopoiesis (minimal)
Stomach	Mucoid cyst (minimal)
Testis/1	Atrophy seminiferous tubules (moderate)
Thyroid/1	No tissue available
Thyroid/2	No tissue available

KWG 0519 - Mouse Chronic Toxicity Study
Full Macro/Micro Report

Rat No: 142
SEX: Male
DOSE LEVEL: 125ppm KWG 0519

MACROSCOPIC FINDINGS

	Mode of death : Terminal kill
	Days under test : 734
	Date of death : 14/07/80
Liver	Lob. sin: Swollen/enlarged
	Lob. caud: Pink coloured indurated
Pancreas	Cyst (0.7 x 0.3cm diam)

MICROSCOPIC FINDINGS

Adrenal/1	No tissue available
Adrenal/2	No tissue available
Kidney/1	Fibrosis (minimal)
	Congestion
Kidney/2	Congestion
	Tubulopathy (minimal)
Liver	Hyperplastic nodule
Lung	MALIGNANT TUMOUR alveogenic carcinoma
Pancreas	Fatty cyst
Spleen	Haematopoiesis (severe)
Stomach	Mucoid cyst (minimal)
Testis/1	Atrophy seminiferous tubules (moderate)
Testis/2	Atrophy seminiferous tubules (moderate)
Thyroid/1	No tissue available
Thyroid/2	No tissue available

KWG 0519 - Mouse Chronic Toxicity Study
Full Macro/Micro Report

Rat No: 143
SEX: Male
DOSE LEVEL: 125ppm KWG 0519

MACROSCOPIC FINDINGS

	Mode of death : Interim death
	Days under test : 331
	Date of death : 07/06/79
Condition at necropsy	Autolysis (complete)
	Evaluation not possible

MICROSCOPIC FINDINGS

Adrenal/1	Autolysis (partial)
Adrenal/2	Autolysis (partial)
Brain	No tissue available
Kidney/1	Autolysis (partial)
Kidney/2	Autolysis (partial)
Liver	Autolysis
Lung	Autolysis (partial)
	Oedema (severe)
	Ectasia vascular (severe)
Pancreas	Autolysis
Pituitary	Autolysis (partial)
Spleen	Autolysis
Stomach	Autolysis (partial)
Testis/1	Autolysis
Testis/2	Autolysis
Thyroid/1	No tissue available
Thyroid/2	No tissue available
Urinary bladder	Autolysis (partial)

KWG 0519 - Mouse Chronic Toxicity Study
Full Macro/Micro Report

Rat No: 144
SEX: Male
DOSE LEVEL: 125ppm KWG 0519

MACROSCOPIC FINDINGS

Mode of death : Interim death
Days under test : 482
Date of death : 05/11/79
No significant findings noted

MICROSCOPIC FINDINGS

Brain	Gliosis
Heart	Congestion
Kidney/1	Autolysis (partial)
	Interstitial nephritis (moderate)
Kidney/2	Autolysis (partial)
	Interstitial nephritis (moderate)
Lung	Oedema
	Pneumonia
Pancreas	Autolysis (partial)
Seminal vesicle	Coagulum
Spleen	Autolysis (partial)
Testis/1	Calcification
Thyroid/1	No tissue available
Thyroid/2	No tissue available
Urinary bladder	Autolysis (partial)

KWG 0519 - Mouse Chronic Toxicity Study
Full Macro/Micro Report

Rat No: 145
SEX: Male
DOSE LEVEL: 125ppm KWG 0519

MACROSCOPIC FINDINGS

	Mode of death : Interim death
	Days under test : 614
	Date of death : 16/03/80
Condition at necropsy	Autolysis (numerous organs)
General observations	Obese

MICROSCOPIC FINDINGS

Brain	No tissue available
Heart	Congestion
Kidney/1	Progressive nephropathy (minimal)
Kidney/2	Progressive nephropathy (minimal)
Liver	Autolysis (partial)
Lung	Haemorrhage (moderate)
	Congestion
	Emphysema (moderate)
Pancreas	Fatty cyst. No pancreatic tissue
Pituitary	No tissue available
Stomach	Autolysis (partial)
Thyroid/1	No tissue available
Thyroid/2	No tissue available
Urinary bladder	Autolysis (partial)

KWG 0519 - Mouse Chronic Toxicity Study
Full Macro/Micro Report

Rat No: 146
SEX: Male
DOSE LEVEL: 125ppm KWG 0519

MACROSCOPIC FINDINGS

Mode of death	: Interim death
Days under test	: 377
Date of death	: 23/07/79
General observations	Obese
Liver	Filled with blood

MICROSCOPIC FINDINGS

Kidney/1	Autolysis (partial)
Kidney/2	Autolysis (partial)
Liver	Normal
Lung	Oedema
	Congestion
Pituitary	No tissue available
Thyroid/1	No tissue available
Thyroid/2	No tissue available

KWG 0519 - Mouse Chronic Toxicity Study
Full Macro/Micro Report

Rat No: 147
SEX: Male
DOSE LEVEL: 125ppm KWG 0519

MACROSCOPIC FINDINGS

	Mode of death : Interim death
	Days under test : 497
	Date of death : 20/11/79
Condition at necropsy	Autolysis (few organs)
Adrenal gland	Both: Enlarged (0.25cm diam)
Kidney	Both: Clay coloured
Lung	Enlarged with grey/black foci (left 1.8 x 0.9cm right 1.4 x 0.7cm)
	Flesh coloured
Seminal vesicle	Lob. inf. dxtr. med: Soft grey nodule (0.25cm diam)
Stomach	Yellowish
Urinary bladder	Mucosal bleeding
Salivary gland	Enlarged (1.2cm diam)
	Enlarged (0.6-0.8cm diam)

MICROSCOPIC FINDINGS

Bone (femur)	No tissue available
Kidney/1	Progressive nephropathy (moderate)
Kidney/2	Progressive nephropathy (moderate)
Lung	MALIGNANT TUMOUR alveogenic carcinoma
	Oedema
	Pneumonia
Pancreas	Autolysis (partial)
Stomach	Normal
Thyroid/1	No tissue available
Thyroid/2	No tissue available
Urinary bladder	Normal
Salivary gland	Normal

KWG 0519 - Mouse Chronic Toxicity Study
Full Macro/Micro Report

Rat No: 148
SEX: Male
DOSE LEVEL: 125ppm KWG 0519

MACROSCOPIC FINDINGS

	Mode of death : Terminal kill
	Days under test : 734
	Date of death : 14/07/80
Kidney	Cysts (0.1-0.2cm diam)
	Surface raised areas
Lung	Pale
Seminal vesicle	Enlarged
	Yellowish mucous mass
Spleen	Enlarged (2.7 x 0.9)
Testis	Left: Reduced in size

MICROSCOPIC FINDINGS

Kidney/1	Fibrosis (minimal)
	Progressive nephropathy (moderate)
Kidney/2	Progressive nephropathy (moderate)
Liver	Haematopoiesis (moderate)
Lung	Pneumonia
	Emphysema
Seminal vesicle	Coagulum
	Inflammation acute glandular
Skeletal muscle	Atrophy (minimal)
Spleen	Haematopoiesis (severe)
Testis/1	Normal
Testis/2	Normal
Thyroid/1	No tissue available
Thyroid/2	No tissue available
Urinary bladder	Inflammation chronic
Lymph node	Hyperplasia lymphoid

KWG 0519 - Mouse Chronic Toxicity Study
Full Macro/Micro Report

Rat No: 149
SEX: Male
DOSE LEVEL: 125ppm KWG 0519

MACROSCOPIC FINDINGS

	Mode of death : Terminal kill
	Days under test : 734
	Date of death : 14/07/80
Kidney	Cysts (0.1-0.2cm diam)
Liver	Lob. sin. and Lob. sin. access: Enlarged hardened and coalesced
	Lob. dxtr. access: Light beige thickening (0.6 x 1.1cm)
Lung	Lob. sin: Brown/beige induration (0.7cm diam)
Pituitary	Enlarged
Spleen	Reduced in size

MICROSCOPIC FINDINGS

Adrenal/1	Pigmentation (moderate)
Adrenal/2	Pigmentation (moderate)
Brain	Gliosis
Kidney/1	Hydronephrosis
	Progressive nephropathy (severe)
Kidney/2	Progressive nephropathy (severe)
Liver	BENIGN TUMOUR hepatocellular adenoma
	Fat vacuoles (severe)
	Hyperplastic nodule
Lung	MALIGNANT TUMOUR alveogenic carcinoma
Pancreas	Inflammation chronic
Pituitary	Cysts
Spleen	Normal
Stomach	Inflammation chronic
Testis/1	Atrophy seminiferous tubules (minimal)
Testis/2	Atrophy seminiferous tubules (minimal)
Thyroid/1	No tissue available
Thyroid/2	No tissue available

KWG 0519 - Mouse Chronic Toxicity Study
Full Macro/Micro Report

Rat No: 150
SEX: Male
DOSE LEVEL: 125ppm KWG 0519

MACROSCOPIC FINDINGS

	Mode of death : Interim death
	Days under test : 657
	Date of death : 28/04/80
Condition at necropsy	Autolysis (complete)
	Evaluation not possible

MICROSCOPIC FINDINGS

Adrenal/1	Autolysis (partial)
Adrenal/2	Autolysis (partial)
Brain	No tissue available
Kidney/1	Autolysis (partial)
	Tubulopathy (moderate)
	Dilatation glomerular loops (moderate)
Kidney/2	Autolysis (partial)
	Tubulopathy (moderate)
	Dilatation glomerular loops (moderate)
Liver	Autolysis
Lung	Autolysis (partial)
	Oedema (severe)
Pancreas	Autolysis
Pituitary	No tissue available
Skeletal muscle	Calcification (minimal)
Spleen	Autolysis
Stomach	Autolysis (partial)
Testis/1	Calcification (minimal)
Testis/2	Calcification (minimal)
Thyroid/1	No tissue available
Thyroid/2	No tissue available
Urinary bladder	Autolysis (partial)
Salivary gland	Calcification (minimal)

KWG 0519 - Mouse Chronic Toxicity Study
Full Macro/Micro Report

Rat No: 151
SEX: Female
DOSE LEVEL: 125ppm KWG 0519

MACROSCOPIC FINDINGS

	Mode of death : Interim death
	Days under test : 680
	Date of death : 21/05/80
Condition at necropsy	Autolysis (few organs)
Liver	Clay coloured
Lung	Lob. sin. and Lob. sup. dxtr: Flesh coloured areas
	Lob. inf. dxtr. lat: Enlarged beige white indurated

MICROSCOPIC FINDINGS

Adrenal/1	Pigmentation (moderate)
Adrenal/2	Pigmentation (moderate)
Liver	Autolysis (partial)
	Haemorrhage
	Congestion
Lung	MALIGNANT TUMOUR alveogenic carcinoma
Ovary/1	Hypertrophic corpora lutea
Ovary/2	Hypertrophic corpora lutea
Spleen	Congestion
Urinary bladder	Autolysis (partial)
Uterus	Cystic endometrial hyperplasia

KWG 0519 - Mouse Chronic Toxicity Study
Full Macro/Micro Report

Rat No: 152
SEX: Female
DOSE LEVEL: 125ppm KWG 0519

MACROSCOPIC FINDINGS

	Mode of death : Interim death
	Days under test : 439
	Date of death : 23/09/79
Abdominal cavity	10ml brownish opaque fluid
Lung	Fleshy
Thoracic cavity	2ml brownish opaque fluid
Adipose tissue	Coalesced hard reddish

MICROSCOPIC FINDINGS

Adrenal/1	MALIGNANT LYMPHOMA
Bone (femur)	No tissue available
Heart	Congestion
Lung	Pneumonia (severe)
	MALIGNANT LYMPHOMA
Ovary/1	MALIGNANT LYMPHOMA
Ovary/2	MALIGNANT LYMPHOMA
Pancreas	Autolysis (partial)
	MALIGNANT LYMPHOMA
Sciatic nerve	No tissue available
Skeletal muscle	No tissue available
Spleen	Hyperplasia lymphoid
Stomach	MALIGNANT LYMPHOMA
Thyroid/1	Autolysis (partial)
Thyroid/2	Autolysis (partial)
Urinary bladder	MALIGNANT LYMPHOMA
Fat	MALIGNANT LYMPHOMA
Lymph node	MALIGNANT LYMPHOMA
Mesentery	MALIGNANT LYMPHOMA

KWG 0519 - Mouse Chronic Toxicity Study
Full Macro/Micro Report

Rat No: 153
SEX: Female
DOSE LEVEL: 125ppm KWG 0519

MACROSCOPIC FINDINGS

	Mode of death : Interim death
	Days under test : 288
	Date of death : 25/04/79
Intestine	Haemorrhagic contents
Stomach	Mucosal bleeding

MICROSCOPIC FINDINGS

Brain	Congestion
Heart	Congestion
Kidney/1	Cysts
Liver	Autolysis (partial)
Lung	Congestion
Ovary/1	Hypertrophic corpora lutea
Ovary/2	Hypertrophic corpora lutea
Pancreas	Autolysis (partial)
Stomach	Haemorrhage
Thyroid/1	No tissue available
Thyroid/2	No tissue available
Intestine	Autolysis

KWG 0519 - Mouse Chronic Toxicity Study
Full Macro/Micro Report

Rat No: 154
SEX: Female
DOSE LEVEL: 125ppm KWG 0519

MACROSCOPIC FINDINGS

	Mode of death : Interim death
	Days under test : 433
	Date of death : 17/09/79
Condition at necropsy	Autolysis (few organs)
Ovary	Left: Cysts haemorrhagic (0.6cm diam)
Uterus	Horns thickened (0.3cm diam)

MICROSCOPIC FINDINGS

Kidney/1	Progressive nephropathy (moderate)
Ovary/1	Atrophy
	Cysts
Ovary/2	Cysts
	Hypertrophic corpora lutea
Sciatic nerve	No tissue available
Spleen	Haematopoiesis (moderate)
Urinary bladder	Inflammation chronic (minimal)
Uterus	Hyperplasia secretory

KWG 0519 - Mouse Chronic Toxicity Study
Full Macro/Micro Report

Rat No: 155
SEX: Female
DOSE LEVEL: 125ppm KWG 0519

MACROSCOPIC FINDINGS

	Mode of death : Interim death
	Days under test : 274
	Date of death : 11/04/79
Intestine	Haemorrhagic contents
Stomach	Mucosal bleeding

MICROSCOPIC FINDINGS

Adrenal/1	BENIGN TUMOUR cortical adenoma
Kidney/1	Congestion
Kidney/2	Congestion
Liver	Congestion
Ovary/1	Hypertrophic corpora lutea
Ovary/2	Hypertrophic corpora lutea
Stomach	Haemorrhage
Urinary bladder	Inflammation chronic
Uterus	Normal

KWG 0519 - Mouse Chronic Toxicity Study
Full Macro/Micro Report

Rat No: 156
SEX: Female
DOSE LEVEL: 125ppm KWG 0519

MACROSCOPIC FINDINGS

Mode of death : Interim death
Days under test : 368
Date of death : 14/07/79
No significant findings noted

MICROSCOPIC FINDINGS

Heart	Congestion
Kidney/1	Autolysis (partial)
	Interstitial nephritis (minimal)
Kidney/2	Autolysis (partial)
	Interstitial nephritis (minimal)
Liver	Autolysis (partial)
Lung	Oedema
Ovary/1	Hypertrophic corpora lutea
Ovary/2	Hypertrophic corpora lutea
Pancreas	Autolysis (partial)
Pituitary	No tissue available
Spleen	Hyperplasia lymphoid
Thyroid/1	No tissue available
Thyroid/2	No tissue available
Urinary bladder	Autolysis (partial)

KWG 0519 - Mouse Chronic Toxicity Study
Full Macro/Micro Report

Rat No: 157
SEX: Female
DOSE LEVEL: 125ppm KWG 0519

MACROSCOPIC FINDINGS

	Mode of death : Interim death
	Days under test : 724
	Date of death : 04/07/80
Condition at necropsy	Moribund
	No significant findings noted

MICROSCOPIC FINDINGS

Liver	Mononuclear cells (minimal)
	Vacuolisation (minimal)
Lung	MALIGNANT TUMOUR alveogenic carcinoma

KWG 0519 - Mouse Chronic Toxicity Study
Full Macro/Micro Report

Rat No: 158
SEX: Female
DOSE LEVEL: 125ppm KWG 0519

MACROSCOPIC FINDINGS

	Mode of death : Terminal kill
	Days under test : 735
	Date of death : 15/07/80
Lung	Lob. sin: White hard nodule (0.5cm diam)

MICROSCOPIC FINDINGS

Brain	Gliosis
Lung	MALIGNANT TUMOUR alveogenic carcinoma
Ovary/1	Atrophy
	Cysts
Ovary/2	Atrophy
Spleen	Haematopoiesis (moderate)
Uterus	Endometriosis

KWG 0519 - Mouse Chronic Toxicity Study
Full Macro/Micro Report

Rat No: 159
SEX: Female
DOSE LEVEL: 125ppm KWG 0519

MACROSCOPIC FINDINGS

	Mode of death : Interim death
	Days under test : 428
	Date of death : 12/09/79
Condition at necropsy	Autolysis (numerous organs)
Thymus	Soft beige nodule (1.0cm diam)

MICROSCOPIC FINDINGS

Brain	No tissue available
Heart	MALIGNANT LYMPHOMA
Kidney/1	Autolysis (partial)
	MALIGNANT LYMPHOMA
Kidney/2	Autolysis (partial)
	MALIGNANT LYMPHOMA
Liver	Autolysis
Lung	Autolysis (partial)
	MALIGNANT LYMPHOMA
Pancreas	Autolysis
Pituitary	No tissue available
Skeletal muscle	MALIGNANT LYMPHOMA
Spleen	Autolysis
Stomach	Autolysis (partial)
Thyroid/1	Autolysis (partial)
Thyroid/2	Autolysis (partial)
Urinary bladder	Autolysis (partial)
Mesentery	MALIGNANT LYMPHOMA
Thymus	MALIGNANT LYMPHOMA

KWG 0519 - Mouse Chronic Toxicity Study
Full Macro/Micro Report

Rat No: 160
SEX: Female
DOSE LEVEL: 125ppm KWG 0519

MACROSCOPIC FINDINGS

	Mode of death : Interim death
	Days under test : 459
	Date of death : 13/10/79
Liver	Lob. sin: Enlarged swollen soft
Lung	Fleshy
Spleen	Enlarged (3.2 x 0.7cm)
Thymus	Hard beige nodule (1.5 x 1.0cm)

MICROSCOPIC FINDINGS

Heart	Congestion
Kidney/1	Autolysis (partial)
	Congestion
	MALIGNANT LYMPHOMA
Kidney/2	Autolysis (partial)
	Congestion
	MALIGNANT LYMPHOMA
Liver	Autolysis (partial)
	Congestion
	MALIGNANT LYMPHOMA
Lung	Oedema
	Congestion
	MALIGNANT LYMPHOMA
Ovary/1	MALIGNANT LYMPHOMA
Ovary/2	MALIGNANT LYMPHOMA
Pancreas	Autolysis (partial)
	Congestion
	MALIGNANT LYMPHOMA
Skeletal muscle	MALIGNANT LYMPHOMA
Spleen	Hyperplasia lymphoid
Stomach	MALIGNANT LYMPHOMA
Urinary bladder	MALIGNANT LYMPHOMA
Mesentery	MALIGNANT LYMPHOMA
Thymus	MALIGNANT LYMPHOMA

KWG 0519 - Mouse Chronic Toxicity Study
Full Macro/Micro Report

Rat No: 161
SEX: Female
DOSE LEVEL: 125ppm KWG 0519

MACROSCOPIC FINDINGS

	Mode of death : Terminal kill
	Days under test : 735
	Date of death : 15/07/80
Ovary	Both: Cysts (0.3cm diam)

MICROSCOPIC FINDINGS

Kidney/1	Interstitial nephritis (minimal)
Kidney/2	Interstitial nephritis (minimal)
Liver	Mononuclear cells (minimal)
Lung	Adenomatosis
	Pneumonia
Ovary/1	Atrophy
	Cysts
Ovary/2	Atrophy
	Cysts
Spleen	Haematopoiesis (minimal)
Urinary bladder	Inflammation chronic
Uterus	Endometriosis

KWG 0519 - Mouse Chronic Toxicity Study
Full Macro/Micro Report

Rat No: 162
SEX: Female
DOSE LEVEL: 125ppm KWG 0519

MACROSCOPIC FINDINGS

	Mode of death : Interim death
	Days under test : 678
	Date of death : 19/05/80
Adrenal gland	Pale
	Left: Enlarged
Brain	Pale
Kidney	Pale
Liver	Enlarged swollen indurated
Lung	Pale
Pituitary	Pale
Spleen	Enlarged (3.7 x 1.0cm)
Stomach	Mucosal bleeding
Uterus	Pale

MICROSCOPIC FINDINGS

Adrenal/1	MALIGNANT LYMPHOMA
Adrenal/2	MALIGNANT LYMPHOMA
Kidney/1	MALIGNANT LYMPHOMA
Kidney/2	MALIGNANT LYMPHOMA
Liver	MALIGNANT LYMPHOMA
Lung	MALIGNANT LYMPHOMA
Ovary/1	Atrophy
	Cysts
Ovary/2	Atrophy
Pancreas	MALIGNANT LYMPHOMA
Spleen	MALIGNANT LYMPHOMA
Thyroid/1	Cysts
Urinary bladder	MALIGNANT LYMPHOMA
Uterus	Cystic endometrial hyperplasia

KWG 0519 - Mouse Chronic Toxicity Study
Full Macro/Micro Report

Rat No: 163
SEX: Female
DOSE LEVEL: 125ppm KWG 0519

MACROSCOPIC FINDINGS

	Mode of death : Terminal kill
	Days under test : 735
	Date of death : 15/07/80
Lung	Lob. sin: Beige area (0.3cm diam)
	Lob. inf. dxtr. med: Enlarged hardened swollen
Uterus	Both horns: Thickened (0.8cm diam)
	Right horn: Cyst (1.0cm diam)

MICROSCOPIC FINDINGS

Adrenal/1	Hyperplasia glomerulosa
Kidney/1	Interstitial nephritis (minimal)
Lung	MALIGNANT TUMOUR alveogenic carcinoma
Ovary/1	Atrophy
	Cysts
Ovary/2	Atrophy
Pituitary	No tissue available
Spleen	Haematopoiesis (moderate)
Uterus	Unreadable

KWG 0519 - Mouse Chronic Toxicity Study
Full Macro/Micro Report

Rat No: 164
SEX: Female
DOSE LEVEL: 125ppm KWG 0519

MACROSCOPIC FINDINGS

	Mode of death : Terminal kill
	Days under test : 735
	Date of death : 15/07/80
Lung	Several foci (0.2-0.3cm diam)
Uterus	Horns thickened (0.6cm diam)

MICROSCOPIC FINDINGS

Brain	Gliosis
Lung	Atelectasis (severe)
	Emphysema (minimal)
Ovary/1	Atrophy
	Cysts
Ovary/2	Atrophy
Spleen	Haematopoiesis (severe)
Thyroid/1	No tissue available
Thyroid/2	No tissue available
Urinary bladder	Hyperplasia papillomatous
Uterus	Endometriosis

KWG 0519 - Mouse Chronic Toxicity Study
Full Macro/Micro Report

Rat No: 165
SEX: Female
DOSE LEVEL: 125ppm KWG 0519

MACROSCOPIC FINDINGS

	Mode of death : Interim death
	Days under test : 333
	Date of death : 09/06/79
Spleen	Enlarged (3.3 x 0.6cm)
Uterus	Horns thickened (0.3cm diam)

MICROSCOPIC FINDINGS

Kidney/1	Congestion
	MALIGNANT LYMPHOMA
Kidney/2	Congestion
	MALIGNANT LYMPHOMA
Liver	Autolysis (partial)
Lung	Congestion
Pancreas	Autolysis (partial)
Pituitary	No tissue available
Spleen	Autolysis (partial)
	MALIGNANT LYMPHOMA
Urinary bladder	Autolysis (partial)
Uterus	Normal

KWG 0519 - Mouse Chronic Toxicity Study
Full Macro/Micro Report

Rat No: 166
SEX: Female
DOSE LEVEL: 125ppm KWG 0519

MACROSCOPIC FINDINGS

	Mode of death : Interim death
	Days under test : 629
	Date of death : 31/03/80
Condition at necropsy	Autolysis (numerous organs)
Adrenal gland	Left: Enlarged
Liver	Enlarged
Spleen	Enlarged (4.7 x 0.8cm)

MICROSCOPIC FINDINGS

Adrenal/1	MALIGNANT LYMPHOMA
Adrenal/2	MALIGNANT LYMPHOMA
Brain	No tissue available
Kidney/1	Autolysis (partial)
	MALIGNANT LYMPHOMA
Kidney/2	Autolysis (partial)
	MALIGNANT LYMPHOMA
Liver	Autolysis (partial)
	MALIGNANT LYMPHOMA
Lung	Oedema
	Congestion
	MALIGNANT LYMPHOMA
Ovary/1	No tissue available
Ovary/2	No tissue available
Pancreas	Autolysis (partial)
	MALIGNANT LYMPHOMA
Pituitary	No tissue available
Spleen	Autolysis (partial)
	MALIGNANT LYMPHOMA
Thyroid/1	Autolysis (partial)
Thyroid/2	Autolysis (partial)
Lymph node	MALIGNANT LYMPHOMA
Mesentery	MALIGNANT LYMPHOMA

KWG 0519 - Mouse Chronic Toxicity Study
Full Macro/Micro Report

Rat No: 167
SEX: Female
DOSE LEVEL: 125ppm KWG 0519

MACROSCOPIC FINDINGS

	Mode of death : Interim death
	Days under test : 715
	Date of death : 25/06/80
Condition at necropsy	Moribund
Lung	Dark/red foci/areas
Ovary	Lob. inf. dxtr. lat: Enlarged beige indurated
	Left: Cysts (0.4cm diam) yellow soft nodule (0.3cm diam)

MICROSCOPIC FINDINGS

Adrenal/1	Pigmentation (moderate)
	Hyperplasia glomerulosa
Adrenal/2	Pigmentation (moderate)
	Hyperplasia glomerulosa
Bone (femur)	Unreadable
Kidney/1	Tubulopathy (moderate)
	Dilatation glomerular loops (moderate)
Kidney/2	Tubulopathy (moderate)
	Dilatation glomerular loops (moderate)
Lung	MALIGNANT TUMOUR alveogenic carcinoma
Ovary/1	Inflammation acute
	Cysts
	Pus
Ovary/2	Cysts
Urinary bladder	Unreadable
Uterus	Cystic endometrial hyperplasia

KWG 0519 - Mouse Chronic Toxicity Study
Full Macro/Micro Report

Rat No: 168
SEX: Female
DOSE LEVEL: 125ppm KWG 0519

MACROSCOPIC FINDINGS

	Mode of death : Terminal kill
	Days under test : 735
	Date of death : 15/07/80
Ovary	Left: Cysts (0.2cm diam)

MICROSCOPIC FINDINGS

Adrenal/1	Pigmentation (severe)
Adrenal/2	Pigmentation (severe)
Brain	Gliosis
Kidney/1	Tubulopathy (minimal)
	Interstitial nephritis (minimal)
Kidney/2	Tubulopathy (minimal)
	Interstitial nephritis (minimal)
Liver	Mononuclear cells (minimal)
	Vacuolisation (minimal)
Lung	Pneumonia
Ovary/1	Cysts
Ovary/2	Cysts
Pancreas	Fatty cyst
Urinary bladder	Hyperplasia papillomatous
Uterus	Hyperplasia polypoid
	Hyperplasia secretory

KWG 0519 - Mouse Chronic Toxicity Study
Full Macro/Micro Report

Rat No: 169
SEX: Female
DOSE LEVEL: 125ppm KWG 0519

MACROSCOPIC FINDINGS

	Mode of death : Interim death
	Days under test : 233
	Date of death : 01/03/79
Condition at necropsy	Autolysis (numerous organs)
Stomach	Mucosal bleeding fundic region

MICROSCOPIC FINDINGS

Adrenal/1	Autolysis (partial)
Adrenal/2	Autolysis (partial)
Heart	Autolysis (partial)
Kidney/1	Autolysis (partial)
Kidney/2	Autolysis (partial)
Lung	Autolysis (partial)
Ovary/1	Hypertrophic corpora lutea
Ovary/2	Hypertrophic corpora lutea
Pancreas	Autolysis (partial)
Pituitary	Unreadable
Stomach	Normal
Urinary bladder	Oedema

KWG 0519 - Mouse Chronic Toxicity Study
Full Macro/Micro Report

Rat No: 170
SEX: Female
DOSE LEVEL: 125ppm KWG 0519

MACROSCOPIC FINDINGS

	Mode of death : Terminal kill
	Days under test : 735
	Date of death : 15/07/80
Uterus	Horns multiple cysts containing gelatinous material

MICROSCOPIC FINDINGS

Adrenal/1	Pigmentation (minimal)
Adrenal/2	Pigmentation (minimal)
Lung	Pneumonia (moderate)
Ovary/1	Hypertrophic corpora lutea
Ovary/2	Hypertrophic corpora lutea
Spleen	Haematopoiesis (minimal)
Uterus	Cystic endometrial hyperplasia
	Endometriosis
	Hyperplasia papillomatous

KWG 0519 - Mouse Chronic Toxicity Study
Full Macro/Micro Report

Rat No: 171
SEX: Female
DOSE LEVEL: 125ppm KWG 0519

MACROSCOPIC FINDINGS

	Mode of death : Terminal kill
	Days under test : 735
	Date of death : 15/07/80
Cranium	Indurated
Liver	Enlarged
	Surface raised areas
Lung	Lob. sin: Beige focus (0.1cm diam)
Spleen	Enlarged (4.4 x 2.1)

MICROSCOPIC FINDINGS

Adrenal/1	Pigmentation (moderate)
Adrenal/2	Pigmentation (moderate)
Kidney/1	Interstitial nephritis
Kidney/2	Interstitial nephritis
Liver	MALIGNANT LYMPHOMA
Lung	MALIGNANT TUMOUR alveogenic carcinoma
Ovary/1	Hypertrophic corpora lutea
Ovary/2	Hypertrophic corpora lutea
Spleen	MALIGNANT LYMPHOMA
Thyroid/1	No tissue available
Thyroid/2	No tissue available
Urinary bladder	Inflammation chronic (minimal)
Uterus	Hyperplasia secretory
Bone	BENIGN TUMOUR osteoma

KWG 0519 - Mouse Chronic Toxicity Study
Full Macro/Micro Report

Rat No: 172
SEX: Female
DOSE LEVEL: 125ppm KWG 0519

MACROSCOPIC FINDINGS

	Mode of death : Interim death
	Days under test : 647
	Date of death : 18/04/80
Intestine	Red-brown contents
Spleen	Enlarged (3.2 x 0.5cm)
Stomach	Mucosal bleeding
Uterus	Right horn: Grey-white hard nodule (0.8cm diam)

MICROSCOPIC FINDINGS

Adrenal/1	Pigmentation (moderate)
Adrenal/2	Pigmentation (moderate)
Heart	Calcification (moderate)
Lung	Thickened alveolar walls
Ovary/1	Atrophy
Ovary/2	Atrophy
Spleen	Congestion
Stomach	Normal
Urinary bladder	Hyperplasia papillomatous
Uterus	MALIGNANT TUMOUR leiomyosarcoma
Duodenum	Normal

KWG 0519 - Mouse Chronic Toxicity Study
Full Macro/Micro Report

Rat No: 173
SEX: Female
DOSE LEVEL: 125ppm KWG 0519

MACROSCOPIC FINDINGS

	Mode of death : Interim death
	Days under test : 574
	Date of death : 05/02/80
Liver	Enlarged
	Surface raised areas
Lung	Dark/red foci/areas
Spleen	Lob. inf. dxtr. lat: White hard nodule (0.3cm diam)
	Enlarged (3.6 x0.6cm)

MICROSCOPIC FINDINGS

Adrenal/1	Hyperplasia glomerulosa
Adrenal/2	Hyperplasia glomerulosa
Heart	Congestion
Kidney/1	MALIGNANT LYMPHOMA
Kidney/2	MALIGNANT LYMPHOMA
Liver	Hypertrophy
	MALIGNANT LYMPHOMA
Lung	MALIGNANT TUMOUR alveogenic carcinoma
	Congestion
Ovary/1	Cysts
Ovary/2	Hypertrophic corpora lutea
Spleen	MALIGNANT LYMPHOMA
Thyroid/1	No tissue available
Thyroid/2	No tissue available
Uterus	Cystic endometrial hyperplasia

KWG 0519 - Mouse Chronic Toxicity Study
Full Macro/Micro Report

Rat No: 174
SEX: Female
DOSE LEVEL: 125ppm KWG 0519

MACROSCOPIC FINDINGS

Condition at necropsy

Mode of death : Interim death
Days under test : 386
Date of death : 01/08/79
Autolysis (complete)
Evaluation not possible

MICROSCOPIC FINDINGS

Adrenal/1	Autolysis
Adrenal/2	Autolysis
Brain	No tissue available
Heart	Autolysis (partial)
	Pericarditis
Kidney/1	Autolysis
Kidney/2	Autolysis
Liver	Autolysis
Lung	Autolysis (partial)
Pancreas	Autolysis
Spleen	Autolysis
Stomach	Autolysis
Urinary bladder	Autolysis

KWG 0519 - Mouse Chronic Toxicity Study
Full Macro/Micro Report

Rat No: 175
SEX: Female
DOSE LEVEL: 125ppm KWG 0519

MACROSCOPIC FINDINGS

	Mode of death : Interim death
	Days under test : 574
	Date of death : 05/02/80
Condition at necropsy	Moribund
General observations	Fore limb (left): Mutilated/bleeding
Lung	Lob. sin: Hard grey nodule (0.2cm diam)
Spleen	Enlarged (2.8 x 0.6cm)
Uterus	Right horn: Central hard dark nodule (1.1 x 0.6cm)

MICROSCOPIC FINDINGS

Adrenal/1	Pigmentation (severe)
Adrenal/2	Pigmentation (severe)
Kidney/1	Progressive nephropathy (minimal)
Kidney/2	Progressive nephropathy (minimal)
Liver	Amyloid
Lung	MALIGNANT TUMOUR alveogenic carcinoma
Ovary/1	Atrophy
Ovary/2	Atrophy
Sciatic nerve	No tissue available
Spleen	MALIGNANT LYMPHOMA
Stomach	Mucoid cyst
Thyroid/1	No tissue available
Thyroid/2	No tissue available
Uterus	Thrombosis (severe)
	Haemorrhage (severe)

KWG 0519 - Mouse Chronic Toxicity Study
Full Macro/Micro Report

Rat No: 176
SEX: Female
DOSE LEVEL: 125ppm KWG 0519

MACROSCOPIC FINDINGS

	Mode of death : Interim death
	Days under test : 165
	Date of death : 23/12/78
Condition at necropsy	Autolysis (complete)
	Evaluation not possible

MICROSCOPIC FINDINGS

Adrenal/1	Autolysis
Adrenal/2	Autolysis
Brain	Autolysis
Heart	Autolysis
Kidney/1	Autolysis
Kidney/2	Autolysis
Liver	Autolysis
Lung	Autolysis
Ovary/1	Autolysis
Ovary/2	Autolysis
Pancreas	Autolysis
Pituitary	Autolysis
Spleen	Autolysis
Stomach	Autolysis
Thyroid/1	Autolysis
Thyroid/2	Autolysis
Urinary bladder	Autolysis

KWG 0519 - Mouse Chronic Toxicity Study
Full Macro/Micro Report

Rat No: 177
SEX: Female
DOSE LEVEL: 125ppm KWG 0519

MACROSCOPIC FINDINGS

	Mode of death : Terminal kill
	Days under test : 735
	Date of death : 15/07/80
Lung	Lob. dxtr: Flesh coloured
Ovary	Lob. sin: Infiltrating white nodule (1.2cm diam)
	Filled with clear fluid

MICROSCOPIC FINDINGS

Adrenal/1	Pigmentation (severe)
Adrenal/2	Pigmentation (severe)
Kidney/1	Interstitial nephritis (minimal)
Kidney/2	Interstitial nephritis (minimal)
Lung	MALIGNANT TUMOUR alveogenic carcinoma
Ovary/1	Cysts
Ovary/2	Cysts
Spleen	Haematopoiesis (minimal)
Thyroid/1	No tissue available
Thyroid/2	No tissue available
Uterus	Haemorrhage
	Amyloid
	Hyperplasia secretory

KWG 0519 - Mouse Chronic Toxicity Study
Full Macro/Micro Report

Rat No: 178
SEX: Female
DOSE LEVEL: 125ppm KWG 0519

MACROSCOPIC FINDINGS

Mode of death : Terminal kill
Days under test : 735
Date of death : 15/07/80
No significant findings noted

MICROSCOPIC FINDINGS

Kidney/1	Interstitial nephritis (minimal)
Kidney/2	Interstitial nephritis (minimal)
Lung	Atelectasis
Ovary/1	Atrophy
Ovary/2	Atrophy
Spleen	Haematopoiesis (moderate)
Uterus	Hyperplasia secretory

KWG 0519 - Mouse Chronic Toxicity Study
Full Macro/Micro Report

Rat No: 179
SEX: Female
DOSE LEVEL: 125ppm KWG 0519

MACROSCOPIC FINDINGS

	Mode of death : Terminal kill
	Days under test : 735
	Date of death : 15/07/80
Ovary	Both: Cysts fluid filled (left: 1.5 x 1.8cm right: 1.3 x 1.1cm)

MICROSCOPIC FINDINGS

Adrenal/1	BENIGN TUMOUR cortical adenoma
Kidney/1	Pyelonephritis (minimal)
Kidney/2	Pyelonephritis (minimal)
Liver	Mononuclear cells (minimal)
Lung	Atelectasis
Ovary/1	BENIGN TUMOUR luteoma
	Cysts
Ovary/2	Cysts
Spleen	Haematopoiesis (moderate)
Thyroid/1	No tissue available
Thyroid/2	No tissue available
Urinary bladder	Inflammation chronic
	Hyperplasia papillomatous
Uterus	Endometriosis

KWG 0519 - Mouse Chronic Toxicity Study
Full Macro/Micro Report

Rat No: 180
SEX: Female
DOSE LEVEL: 125ppm KWG 0519

MACROSCOPIC FINDINGS

	Mode of death : Interim death
	Days under test : 671
	Date of death : 12/05/80
Condition at necropsy	Moribund
General observations	Genital and perianal regions: Inflammation of skin extending to top part of femur
Lung	Lob. sin: White hard nodule (0.4cm diam)
Ovary	Right: Cysts (0.7cm diam)
Spleen	Enlarged (3.0 x 0.5cm)

MICROSCOPIC FINDINGS

Adrenal/1	Pigmentation (minimal)
Adrenal/2	Pigmentation (minimal)
Liver	Hyperplastic nodule
Lung	MALIGNANT TUMOUR alveogenic carcinoma
Ovary/1	Atrophy
	Cysts
Ovary/2	Atrophy
Spleen	Hyperplasia lymphoid
Mammary gland	Hyperplasia secretory

KWG 0519 - Mouse Chronic Toxicity Study
Full Macro/Micro Report

Rat No: 181
SEX: Female
DOSE LEVEL: 125ppm KWG 0519

MACROSCOPIC FINDINGS

	Mode of death : Interim death
	Days under test : 724
	Date of death : 04/07/80
Kidney	Left: Enlarged dark red
Ovary	Left: Hard beige nodule (0.6cm diam)
Uterus	Neck thickened (0.8cm diam) indurated

MICROSCOPIC FINDINGS

Heart	Thrombosis
Kidney/1	Hydronephrosis
	Progressive nephropathy (minimal)
Kidney/2	Haemorrhage
	Progressive nephropathy (minimal)
Liver	Vacuolisation (minimal)
Ovary/1	Atrophy
	Cysts
Ovary/2	Atrophy
Spleen	Haematopoiesis (moderate)
Uterus	Haemorrhage (severe)
	Cystic endometrial hyperplasia (severe)
	Endometriosis (severe)

KWG 0519 - Mouse Chronic Toxicity Study
Full Macro/Micro Report

Rat No: 182
SEX: Female
DOSE LEVEL: 125ppm KWG 0519

MACROSCOPIC FINDINGS

	Mode of death : Interim death
	Days under test : 321
	Date of death : 28/05/79
Condition at necropsy	Autolysis (numerous organs)
Ovary	Right: Soft nodule (1.2 x 1.0cm)
	Left: Soft nodule (1.5 x 1.3cm)
Spleen	Enlarged (3.3 x 0.5cm)

MICROSCOPIC FINDINGS

Brain	No tissue available
Kidney/1	Autolysis (partial)
	MALIGNANT LYMPHOMA
Kidney/2	Autolysis (partial)
	MALIGNANT LYMPHOMA
Liver	Autolysis (partial)
Lung	MALIGNANT LYMPHOMA
Ovary/1	MALIGNANT LYMPHOMA
Ovary/2	MALIGNANT LYMPHOMA
Pancreas	Autolysis
Spleen	Autolysis (partial)
	MALIGNANT LYMPHOMA
Stomach	Autolysis
Thyroid/1	No tissue available
Thyroid/2	No tissue available
Urinary bladder	Autolysis (partial)
	MALIGNANT LYMPHOMA

KWG 0519 - Mouse Chronic Toxicity Study
Full Macro/Micro Report

Rat No: 183
SEX: Female
DOSE LEVEL: 125ppm KWG 0519

MACROSCOPIC FINDINGS

Mode of death : Interim death
Days under test : 451
Date of death : 05/10/79

Condition at necropsy	
Adrenal gland	Autolysis (few organs)
Intestine	Left: Enlarged
Lung	Black contents
Spleen	Pale
Stomach	Enlarged (2.7 x 0.5cm)
	Mucosal bleeding

MICROSCOPIC FINDINGS

Adrenal/1	MALIGNANT LYMPHOMA
Adrenal/2	MALIGNANT LYMPHOMA
Brain	MALIGNANT LYMPHOMA
Heart	MALIGNANT LYMPHOMA
Kidney/1	MALIGNANT LYMPHOMA
Kidney/2	MALIGNANT LYMPHOMA
Liver	MALIGNANT LYMPHOMA
Lung	MALIGNANT LYMPHOMA
Ovary/1	MALIGNANT LYMPHOMA
Ovary/2	MALIGNANT LYMPHOMA
Pancreas	MALIGNANT LYMPHOMA
Sciatic nerve	No tissue available
Spleen	Hyperplasia lymphoid
Stomach	MALIGNANT LYMPHOMA
Urinary bladder	MALIGNANT LYMPHOMA
Uterus	MALIGNANT LYMPHOMA
Lymph node	MALIGNANT LYMPHOMA
Mesentery	MALIGNANT LYMPHOMA

KWG 0519 - Mouse Chronic Toxicity Study
Full Macro/Micro Report

Rat No: 184
SEX: Female
DOSE LEVEL: 125ppm KWG 0519

MACROSCOPIC FINDINGS

	Mode of death : Interim death
	Days under test : 715
	Date of death : 25/06/80
Ovary	Left: Cysts haemorrhagic (1.4cm)
Posterior extremities	Left: Skin inflamed
Spleen	Enlarged (2.0 x 0.5cm)

MICROSCOPIC FINDINGS

Adrenal/1	Pigmentation (severe)
Adrenal/2	Pigmentation (severe)
Liver	Congestion
Lung	Congestion
Ovary/1	Atrophy
	Cysts
Ovary/2	Atrophy
	Cysts
Spleen	Haematopoiesis (severe)
Stomach	Mucoid cyst
Uterus	Cystic endometrial hyperplasia (severe)

KWG 0519 - Mouse Chronic Toxicity Study
Full Macro/Micro Report

Rat No: 185
SEX: Female
DOSE LEVEL: 125ppm KWG 0519

MACROSCOPIC FINDINGS

	Mode of death : Interim death
	Days under test : 681
	Date of death : 22/05/80
Condition at necropsy	Moribund
Lung	Lob. sin: Enlarged soft containing greenish paste and hard beige nodule (0.7cm diam)
Ovary	Right: Soft yellow nodule (0.6cm diam)

MICROSCOPIC FINDINGS

Adrenal/1	Pigmentation (minimal)
Adrenal/2	Pigmentation (minimal)
Kidney/1	Tubulopathy
	Dilatation glomerular loops
Lung	MALIGNANT TUMOUR alveogenic carcinoma
	Necrosis
	Haemorrhage
Ovary/1	Inflammation acute
	Pus
Pancreas	Atrophy
	Inflammation chronic
Uterus	Cystic endometrial hyperplasia
Mesentery	Peritonitis

KWG 0519 - Mouse Chronic Toxicity Study
Full Macro/Micro Report

Rat No: 186
SEX: Female
DOSE LEVEL: 125ppm KWG 0519

MACROSCOPIC FINDINGS

	Mode of death : Terminal kill
	Days under test : 735
	Date of death : 15/07/80
Adrenal gland	Both: Enlarged (0.3cm diam)
Spleen	Enlarged (3.5 x 1.0cm)
Uterus	Horns enlarged (0.5cm diam)

MICROSCOPIC FINDINGS

Adrenal/1	Cysts
Adrenal/2	Normal
Kidney/1	MALIGNANT LYMPHOMA
Kidney/2	MALIGNANT LYMPHOMA
Liver	Mononuclear cells (minimal)
Lung	Pneumonia
	MALIGNANT LYMPHOMA
Ovary/1	Hypertrophic corpora lutea
Ovary/2	Hypertrophic corpora lutea
Pancreas	MALIGNANT LYMPHOMA
Spleen	Hyperplasia lymphoid
Stomach	Mucoid cyst
Thyroid/1	Cysts
Thyroid/2	Cysts
Urinary bladder	MALIGNANT LYMPHOMA
Uterus	Cystic endometrial hyperplasia
Lymph node	MALIGNANT LYMPHOMA
Mesentery	MALIGNANT LYMPHOMA

KWG 0519 - Mouse Chronic Toxicity Study
Full Macro/Micro Report

Rat No: 187
SEX: Female
DOSE LEVEL: 125ppm KWG 0519

MACROSCOPIC FINDINGS

Mode of death	: Interim death
Days under test	: 422
Date of death	: 06/09/79
Condition at necropsy	Moribund
Abdomen	Skin thickened red

MICROSCOPIC FINDINGS

Heart	Congestion
Kidney/1	Tubulopathy (minimal)
Lung	Congestion
Ovary/1	Cysts
	Hypertrophic corpora lutea
Ovary/2	Hypertrophic corpora lutea
Abdominal cavity	Steatonecrosis

KWG 0519 - Mouse Chronic Toxicity Study
Full Macro/Micro Report

Rat No: 188
SEX: Female
DOSE LEVEL: 125ppm KWG 0519

MACROSCOPIC FINDINGS

	Mode of death : Terminal kill
	Days under test : 735
	Date of death : 15/07/80
Lung	Multiple white hard areas (0.2-0.3cm)
Ovary	Right: Cysts (0.2-0.3cm diam)
Pancreas	Cyst (0.2cm diam)

MICROSCOPIC FINDINGS

Adrenal/1	Pigmentation (severe)
Adrenal/2	Pigmentation (severe)
Kidney/1	Pyelonephritis (moderate)
Kidney/2	Pyelonephritis (moderate)
Lung	Osseous metaplasia
Ovary/1	Cysts
Ovary/2	Cysts
Pancreas	Atrophy (severe)
	Cysts
Stomach	Inflammation chronic (severe)
	Mucoid cyst (severe)
Thyroid/1	No tissue available
Thyroid/2	No tissue available
Uterus	Hyperplasia secretory

KWG 0519 - Mouse Chronic Toxicity Study
Full Macro/Micro Report

Rat No: 189
SEX: Female
DOSE LEVEL: 125ppm KWG 0519

MACROSCOPIC FINDINGS

	Mode of death : Interim death
	Days under test : 602
	Date of death : 04/03/80
Adrenal gland	Left: Enlarged
Intestine	Red-brown contents
Kidney	Both: Clay coloured blister like lesions
Ovary	Left: Cysts (0.6cm diam)
Stomach	Mucosal bleeding and haemorrhagic contents
Uterus	Horns thickened (0.4cm diam)

MICROSCOPIC FINDINGS

Adrenal/1	Hyperplasia glomerulosa
Adrenal/2	Hyperplasia glomerulosa
Heart	Congestion
Kidney/1	Haemorrhage (severe)
	MALIGNANT LYMPHOMA
Kidney/2	Haemorrhage (severe)
	MALIGNANT LYMPHOMA
Liver	Congestion
Lung	Congestion
	Thickened alveolar walls
Ovary/1	Cysts
	MALIGNANT LYMPHOMA
Ovary/2	Cysts
	MALIGNANT LYMPHOMA
Pancreas	Autolysis
Spleen	Hyperplasia lymphoid
Stomach	Haemorrhage
Thyroid/1	No tissue available
Thyroid/2	No tissue available
Urinary bladder	MALIGNANT LYMPHOMA
Uterus	MALIGNANT LYMPHOMA
Lymph node	MALIGNANT LYMPHOMA
Mesentery	MALIGNANT LYMPHOMA

KWG 0519 - Mouse Chronic Toxicity Study
Full Macro/Micro Report

Rat No: 190
SEX: Female
DOSE LEVEL: 125ppm KWG 0519

MACROSCOPIC FINDINGS

	Mode of death : Interim death
	Days under test : 714
	Date of death : 24/06/80
Condition at necropsy	Moribund
Lung	Lob. inf. dxtr. lat: Enlarged hard white
	Remaining lobes: Multiple pale glassy foci

MICROSCOPIC FINDINGS

Adrenal/1	Pigmentation (minimal)
Adrenal/2	Pigmentation (minimal)
Lung	MALIGNANT TUMOUR alveogenic carcinoma
Ovary/1	Atrophy
	Cysts
Ovary/2	Atrophy
	Cysts
Uterus	Cystic endometrial hyperplasia

KWG 0519 - Mouse Chronic Toxicity Study
Full Macro/Micro Report

Rat No: 191
SEX: Female
DOSE LEVEL: 125ppm KWG 0519

MACROSCOPIC FINDINGS

Mode of death	: Interim death
Days under test	: 637
Date of death	: 08/04/80
Condition at necropsy	Moribund
Kidney	Pale
Lung	Lob. sin: Dark red foci/areas
	Lob. dxtr: Dark red foci/areas
Spleen	Enlarged (3.3 x 0.8cm)
Stomach	Reddened mucosa

MICROSCOPIC FINDINGS

Heart	Leukocytosis
Kidney/1	MALIGNANT LYMPHOMA
Kidney/2	MALIGNANT LYMPHOMA
Liver	MALIGNANT LYMPHOMA
Lung	Thrombosis
	Atelectasis
Ovary/1	Cysts
	MALIGNANT LYMPHOMA
Ovary/2	Cysts
	MALIGNANT LYMPHOMA
Pituitary	No tissue available
Spleen	MALIGNANT LYMPHOMA
Stomach	MALIGNANT LYMPHOMA
Thyroid/1	No tissue available
Thyroid/2	No tissue available

KWG 0519 - Mouse Chronic Toxicity Study
Full Macro/Micro Report

Rat No: 192
SEX: Female
DOSE LEVEL: 125ppm KWG 0519

MACROSCOPIC FINDINGS

	Mode of death : Interim death
	Days under test : 717
	Date of death : 27/06/80
Liver	Enlarged
Spleen	Clay coloured
Uterus	Neck thickened (1.2cm diam) hard contains yellowish paste

MICROSCOPIC FINDINGS

Adrenal/1	Pigmentation (minimal)
Kidney/1	Autolysis (partial)
	Tubulopathy (severe)
	Pyelitis (severe)
Kidney/2	Autolysis (partial)
	Tubulopathy (severe)
	Pyelitis (severe)
Liver	Mononuclear cells (minimal)
Lung	Thickened alveolar walls
Ovary/1	Atrophy
Ovary/2	Atrophy
Pancreas	Atrophy
Spleen	Haematopoiesis (severe)
Stomach	Mucoid cyst (minimal)
Thyroid/1	No tissue available
Thyroid/2	No tissue available
Urinary bladder	Autolysis (partial)
Uterus	Cystic endometrial hyperplasia (severe)
	Endometritis (severe)
Cervix	BENIGN TUMOUR keratoacanthoma

KWG 0519 - Mouse Chronic Toxicity Study
Full Macro/Micro Report

Rat No: 193
SEX: Female
DOSE LEVEL: 125ppm KWG 0519

MACROSCOPIC FINDINGS

	Mode of death : Interim death
	Days under test : 562
	Date of death : 24/01/80
Condition at necropsy	Autolysis (few organs)
Lung	Dark foci/areas
Ovary	Left: Cysts (0.7cm diam)
Pituitary	Watery cysts
Spleen	Enlarged (2.4 x 0.5cm)
Stomach	Mucosal bleeding
Uterus	Right horn: Soft grey nodule (0.4cm diam)

MICROSCOPIC FINDINGS

Adrenal/1	MALIGNANT LYMPHOMA
Adrenal/2	MALIGNANT LYMPHOMA
Heart	Congestion (severe)
Kidney/1	MALIGNANT LYMPHOMA
Kidney/2	MALIGNANT LYMPHOMA
Liver	Autolysis (partial)
	Congestion
Lung	Oedema (severe)
	Congestion (severe)
	Emphysema (severe)
Ovary/1	Autolysis (partial)
	MALIGNANT LYMPHOMA
Ovary/2	Autolysis (partial)
	MALIGNANT LYMPHOMA
Pancreas	MALIGNANT LYMPHOMA
Pituitary	No tissue available
Skeletal muscle	MALIGNANT LYMPHOMA
Spleen	Autolysis (partial)
	MALIGNANT LYMPHOMA
Stomach	Autolysis (partial)
Thyroid/1	Autolysis (partial)
Thyroid/2	Autolysis (partial)
Urinary bladder	MALIGNANT LYMPHOMA
Uterus	MALIGNANT LYMPHOMA
Mesentery	MALIGNANT LYMPHOMA
	Steatonecrosis

KWG 0519 - Mouse Chronic Toxicity Study
Full Macro/Micro Report

Rat No: 194
SEX: Female
DOSE LEVEL: 125ppm KWG 0519

MACROSCOPIC FINDINGS

	Mode of death : Terminal kill
	Days under test : 735
	Date of death : 15/07/80
Ovary	Right: Cysts (1.1cm diam)
Uterus	Right horn: Upper area thickened (0.8cm diam) dark red gelatinous-fluid contents

MICROSCOPIC FINDINGS

Adrenal/1	Pigmentation (moderate)
Adrenal/2	No tissue available
Kidney/1	Interstitial nephritis (minimal)
Kidney/2	Interstitial nephritis (minimal)
Lung	Pneumonia (severe)
Ovary/1	Atrophy
	Cysts
Ovary/2	Atrophy
	Cysts
Urinary bladder	Hyperplasia papillomatous
Uterus	Hyperplasia secretory
	Haemorrhagic cyst

KWG 0519 - Mouse Chronic Toxicity Study
Full Macro/Micro Report

Rat No: 195
SEX: Female
DOSE LEVEL: 125ppm KWG 0519

MACROSCOPIC FINDINGS

	Mode of death : Interim death
	Days under test : 638
	Date of death : 09/04/80
Condition at necropsy	Moribund
Gall bladder	Enlarged
Ovary	Right: Cysts (0.4cm diam)
Stomach	Mucosal bleeding

MICROSCOPIC FINDINGS

Adrenal/1	Pigmentation (moderate)
Adrenal/2	Pigmentation (moderate)
Bone (femur)	No tissue available
Kidney/1	Dilatation glomerular loops (minimal)
Kidney/2	Dilatation glomerular loops (minimal)
Ovary/1	Cysts
Pancreas	Atrophy
Pituitary	No tissue available
Sciatic nerve	No tissue available
Skeletal muscle	No tissue available
Stomach	Normal
Uterus	Cystic endometrial hyperplasia (severe)

KWG 0519 - Mouse Chronic Toxicity Study
Full Macro/Micro Report

Rat No: 196
SEX: Female
DOSE LEVEL: 125ppm KWG 0519

MACROSCOPIC FINDINGS

	Mode of death : Terminal kill
	Days under test : 735
	Date of death : 15/07/80
Liver	Enlarged
Spleen	Enlarged (2.0 x 0.5cm)
Uterus	Horns enlarged (0.4cm diam)
	Left: Area of thickening (0.8cm diam)
	adjacent to ovary containing hard mass
Abdomen	Right groin region hard beige-grey thickening (2.0cm diam)

MICROSCOPIC FINDINGS

Heart	Normal
Kidney/1	Interstitial nephritis (moderate)
Kidney/2	Interstitial nephritis (moderate)
Liver	Hypertrophy
Lung	MALIGNANT TUMOUR alveogenic carcinoma
Ovary/1	Cysts
Ovary/2	Cysts
Pituitary	No tissue available
Skeletal muscle	METASTASIS fibrosarcoma
Spleen	Haematopoiesis (moderate)
Stomach	Hyperkeratosis
Uterus	Cystic endometrial hyperplasia
	Endometriosis
Subcutaneous tissue	Necrosis
	MALIGNANT TUMOUR fibrosarcoma

KWG 0519 - Mouse Chronic Toxicity Study
Full Macro/Micro Report

Rat No: 197
SEX: Female
DOSE LEVEL: 125ppm KWG 0519

MACROSCOPIC FINDINGS

	Mode of death : Terminal kill
	Days under test : 735
	Date of death : 15/07/80
Ovary	Left: Enlarged hard (0.7cm diam)
Uterus	Multiple gelatinous cysts (0.2-0.4cm diam)

MICROSCOPIC FINDINGS

Kidney/1	Pyelonephritis (minimal)
Kidney/2	Pyelonephritis (minimal)
Liver	Congestion
	Vacuolisation
Lung	Pneumonia (moderate)
	Atelectasis (severe)
Ovary/1	BENIGN TUMOUR luteoma
Pancreas	Mononuclear cells
Spleen	Haematopoiesis (minimal)
Uterus	Endometriosis
	Hyperplasia secretory

KWG 0519 - Mouse Chronic Toxicity Study
Full Macro/Micro Report

Rat No: 198
SEX: Female
DOSE LEVEL: 125ppm KWG 0519

MACROSCOPIC FINDINGS

	Mode of death : Terminal kill
	Days under test : 735
	Date of death : 15/07/80
Liver	Clay coloured. Pale
	Lob. sin: Multiple foci
Spleen	Enlarged (3.6 x 0.1cm)
Uterus	Right horn: Upper region hardened (1.0cm diam)

MICROSCOPIC FINDINGS

Adrenal/1	Pigmentation (minimal)
Adrenal/2	Pigmentation (minimal)
Liver	MALIGNANT LYMPHOMA
Lung	MALIGNANT TUMOUR alveogenic carcinoma
Spleen	MALIGNANT LYMPHOMA
Stomach	MALIGNANT LYMPHOMA
Thyroid/1	Cysts
Urinary bladder	MALIGNANT LYMPHOMA
Uterus	Cystic endometrial hyperplasia (severe)
	Endometritis (severe)
Mesentery	MALIGNANT LYMPHOMA

KWG 0519 - Mouse Chronic Toxicity Study
Full Macro/Micro Report

Rat No: 199
SEX: Female
DOSE LEVEL: 125ppm KWG 0519

MACROSCOPIC FINDINGS

Condition at necropsy	Mode of death	: Interim death
	Days under test	: 431
	Date of death	: 15/09/79
	Autolysis (complete)	
	Evaluation not possible	

MICROSCOPIC FINDINGS

Adrenal/1	No tissue available
Adrenal/2	No tissue available
Bone (femur)	No tissue available
Brain	No tissue available
Heart	No tissue available
Kidney/1	No tissue available
Kidney/2	No tissue available
Liver	No tissue available
Lung	No tissue available
Ovary/1	No tissue available
Ovary/2	No tissue available
Pancreas	No tissue available
Pituitary	No tissue available
Sciatic nerve	No tissue available
Skeletal muscle	No tissue available
Spleen	No tissue available
Stomach	No tissue available
Thyroid/1	No tissue available
Thyroid/2	No tissue available
Urinary bladder	No tissue available

KWG 0519 - Mouse Chronic Toxicity Study
Full Macro/Micro Report

Rat No: 200
SEX: Female
DOSE LEVEL: 125ppm KWG 0519

MACROSCOPIC FINDINGS

	Mode of death : Interim death
	Days under test : 232
	Date of death : 28/02/79
Condition at necropsy	Autolysis (few organs)
Lung	Dark with light areas
Spleen	Enlarged (3.9 x 0.9cm
Thymus	Proliferation

MICROSCOPIC FINDINGS

Adrenal/1	Autolysis (partial)
Adrenal/2	Autolysis (partial)
Brain	No tissue available
Kidney/1	Autolysis
Kidney/2	Autolysis
Liver	Autolysis
Lung	Autolysis (partial) MALIGNANT LYMPHOMA
Ovary/1	Autolysis
Ovary/2	Autolysis
Pancreas	Autolysis
Spleen	Autolysis
Stomach	Autolysis
Thyroid/1	MALIGNANT LYMPHOMA
Thyroid/2	MALIGNANT LYMPHOMA
Urinary bladder	Autolysis
Thymus	MALIGNANT LYMPHOMA

KWG 0519 - Mouse Chronic Toxicity Study
Full Macro/Micro Report

Rat No: 201
SEX: Male
DOSE LEVEL: 500ppm KWG 0519

MACROSCOPIC FINDINGS

	Mode of death : Interim death
	Days under test : 682
	Date of death : 23/05/80
Condition at necropsy	Moribund
Kidney	Left: Reduced in size
Liver	Lob. sin: Soft dark red nodule (1.4cm diam)
Lung	Lob. dxtr: Enlarged hard white

MICROSCOPIC FINDINGS

Bone (femur)	Unreadable
Kidney/1	Tubulopathy (moderate)
Kidney/2	Tubulopathy (moderate)
Liver	BENIGN TUMOUR hepatocellular adenoma
Lung	MALIGNANT TUMOUR alveogenic carcinoma
Spleen	Congestion
Testis/1	BENIGN TUMOUR interstitial cell tumour

KWG 0519 - Mouse Chronic Toxicity Study
Full Macro/Micro Report

Rat No: 202
SEX: Male
DOSE LEVEL: 500ppm KWG 0519

MACROSCOPIC FINDINGS

	Mode of death : Terminal kill
	Days under test : 734
	Date of death : 14/07/80
Liver	Lob. dxtr. access: Beige nodule (1.5 x 1.3cm diam)
	Lob. caud: Cyst (0.3cm diam)

MICROSCOPIC FINDINGS

Kidney/1	Tubulopathy (minimal)
Kidney/2	Tubulopathy (minimal)
Liver	Hyperplastic nodule
Lung	Atelectasis (moderate)
Spleen	Haematopoiesis (moderate)
Stomach	Mucoid cyst (minimal)
Testis/1	BENIGN TUMOUR interstitial cell tumour
Testis/2	BENIGN TUMOUR interstitial cell tumour
Urinary bladder	Hyperplasia papillomatous
Bone marrow	Aplasia myeloid

KWG 0519 - Mouse Chronic Toxicity Study
Full Macro/Micro Report

Rat No: 203
SEX: Male
DOSE LEVEL: 500ppm KWG 0519

MACROSCOPIC FINDINGS

	Mode of death : Interim death
	Days under test : 668
	Date of death : 09/05/80
Intestine	Red-brown contents
Liver	Clay coloured areas
Stomach	Mucosal bleeding

MICROSCOPIC FINDINGS

Adrenal/1	Pigmentation (minimal)
Adrenal/2	Pigmentation (minimal)
Heart	Congestion
Kidney/1	Tubulopathy (minimal)
Kidney/2	Tubulopathy (minimal)
Liver	Autolysis (partial)
Lung	MALIGNANT TUMOUR alveogenic carcinoma
	Congestion
Spleen	Hyperplasia lymphoid
Testis/1	Calcification (minimal)
Urinary bladder	Inflammation chronic (moderate)

KWG 0519 - Mouse Chronic Toxicity Study
Full Macro/Micro Report

Rat No: 204
SEX: Male
DOSE LEVEL: 500ppm KWG 0519

MACROSCOPIC FINDINGS

Mode of death	: Interim death
Days under test	: 574
Date of death	: 05/02/80
General observations	Apathetic/listless
Condition at necropsy	Moribund
Cranium	Indurated
Spleen	Enlarged (3.4 x 1.0cm)

MICROSCOPIC FINDINGS

Adrenal/1	No tissue available
Adrenal/2	No tissue available
Kidney/1	Tubulopathy (minimal)
Kidney/2	Tubulopathy (minimal)
Liver	MALIGNANT LYMPHOMA
Lung	Pneumonia
Pituitary	No tissue available
Spleen	MALIGNANT LYMPHOMA
Bone	BENIGN TUMOUR osteoma

KWG 0519 - Mouse Chronic Toxicity Study
Full Macro/Micro Report

Rat No: 205
SEX: Male
DOSE LEVEL: 500ppm KWG 0519

MACROSCOPIC FINDINGS

Mode of death : Terminal kill
Days under test : 734
Date of death : 14/07/80
No significant findings noted

MICROSCOPIC FINDINGS

Kidney/1	Interstitial nephritis (minimal)
	Cysts (minimal)
Kidney/2	Interstitial nephritis (minimal)
	Cysts (minimal)
Liver	Fat vacuoles (minimal)
Lung	Thickened alveolar walls
Pancreas	No tissue available
Spleen	Haematopoiesis (minimal)
Stomach	Mucoid cyst (moderate)
Thyroid/1	No tissue available
Thyroid/2	No tissue available
Urinary bladder	Inflammation granulomatous

KWG 0519 - Mouse Chronic Toxicity Study
Full Macro/Micro Report

Rat No: 206
SEX: Male
DOSE LEVEL: 500ppm KWG 0519

MACROSCOPIC FINDINGS

	Mode of death : Terminal kill
	Days under test : 734
	Date of death : 14/07/80
Brain	Pale
Heart	Beige-grey hard growth (1.0cm diam)
Intestine	Mesentery coalesced conglomerate hard (3.0 x 1.5cm)
Kidney	Left: Pale
	Perirenal adipose tissue nodular hardened yellowish
Pancreas	Coalesced conglomerate pale (1.3cm diam)
Pituitary	Pale
Spleen	Pale
	Areas of nodular hardening (0.3cm diam)

MICROSCOPIC FINDINGS

Adrenal/1	Normal
Adrenal/2	Normal
Brain	Fat vacuoles (minimal)
	Gliosis
Heart	MALIGNANT LYMPHOMA
Kidney/1	MALIGNANT LYMPHOMA
Kidney/2	MALIGNANT LYMPHOMA
Liver	Normal
Lung	MALIGNANT LYMPHOMA
Pancreas	MALIGNANT LYMPHOMA
Skeletal muscle	MALIGNANT LYMPHOMA
Spleen	Hyperplasia lymphoid
	Haematopoiesis (severe)
	Hypertrophy (severe)
Stomach	Mucoid cyst
Testis/1	Atrophy seminiferous tubules
	Azoospermia
Thyroid/1	Normal
Thyroid/2	Normal
Intestine	Normal
Lymph node	MALIGNANT LYMPHOMA
Mesentery	MALIGNANT LYMPHOMA

KWG 0519 - Mouse Chronic Toxicity Study
Full Macro/Micro Report

Rat No: 207
SEX: Male
DOSE LEVEL: 500ppm KWG 0519

MACROSCOPIC FINDINGS

	Mode of death : Interim death
	Days under test : 398
	Date of death : 13/08/79
Condition at necropsy	Autolysis (complete)
General observations	Obese

MICROSCOPIC FINDINGS

Adrenal/1	Autolysis (partial)
Adrenal/2	Autolysis (partial)
Brain	No tissue available
Kidney/1	Autolysis (partial)
Kidney/2	Autolysis (partial)
Lung	Autolysis (partial)
	Oedema
	Emphysema
Pancreas	No tissue available
Pituitary	No tissue available
Skeletal muscle	Fatty cyst
Spleen	Autolysis
Stomach	Autolysis (partial)
Testis/1	Autolysis (partial)
Testis/2	Autolysis (partial)
Thyroid/1	No tissue available
Thyroid/2	No tissue available
Urinary bladder	Autolysis

KWG 0519 - Mouse Chronic Toxicity Stuoy
Full Macro/Micro Report

Rat No: 208
SEX: Male
DOSE LEVEL: 500ppm KWG 0519

MACROSCOPIC FINDINGS

	Mode of death : Interim death
	Days under test : 641
	Date of death : 12/04/80
Condition at necropsy	Autolysis (few organs)
Liver	Portal: Soft dark red-brown nodule (2.0cm diam)
Lung	Flesh coloured

MICROSCOPIC FINDINGS

Adrenal/1	Haemorrhagic cyst
Brain	Fat vacuoles (moderate)
Heart	Congestion
Kidney/1	Autolysis (partial)
	Congestion
	Interstitial nephritis (minimal)
Kidney/2	Autolysis (partial)
	Congestion
	Interstitial nephritis (minimal)
Liver	Autolysis (partial)
	BENIGN TUMOUR hepatocellular adenoma
	Calcification (moderate)
	Haemorrhage (moderate)
Lung	Pneumonia (severe)
	Congestion (severe)
Pancreas	Autolysis
Spleen	Autolysis (partial)
	Haematopoiesis (moderate)
Stomach	Autolysis (partial)
Thyroid/1	No tissue available
Thyroid/2	No tissue available

KWG 0519 - Mouse Chronic Toxicity Study
Full Macro/Micro Report

Rat No: 209
SEX: Male
DOSE LEVEL: 500ppm KWG 0519

MACROSCOPIC FINDINGS

Mode of death	: Interim death
Days under test	: 457
Date of death	: 11/10/79
Condition at necropsy	Autolysis (few organs)
General observations	Obese
Lung	Dark/red foci/areas
Urinary bladder	Enlarged (1.2cm diam)

MICROSCOPIC FINDINGS

Heart	Congestion
Kidney/1	Autolysis (partial)
Kidney/2	Autolysis (partial)
Liver	Autolysis (partial)
	Haemorrhagic cyst (moderate)
Lung	Pneumonia
	Congestion
Pancreas	Autolysis (partial)
Sciatic nerve	No tissue available
Spleen	Autolysis
Stomach	Autolysis (partial)
Thyroid/1	Autolysis (partial)
Thyroid/2	Autolysis (partial)
Urinary bladder	Autolysis (partial)
	Normal

KWG 0519 - Mouse Chronic Toxicity Study
Full Macro/Micro Report

Rat No: 210
SEX: Male
DOSE LEVEL: 500ppm KWG 0519

MACROSCOPIC FINDINGS

	Mode of death : Interim death
	Days under test : 566
	Date of death : 28/01/80
General observations	All organs reddish
Lung	Dark/red coloured
	Lob. inf. dxtr. lat: White hard nodule (1.2cm diam)

MICROSCOPIC FINDINGS

Brain	Fat vacuoles (minimal)
Kidney/1	Congestion
Kidney/2	Congestion
Liver	Congestion
Lung	Autolysis (partial)
	MALIGNANT TUMOUR alveogenic carcinoma
Pancreas	Autolysis (partial)
Spleen	Autolysis (partial)
Testis/1	Calcification (moderate)
Testis/2	Calcification (moderate)
Thyroid/1	Autolysis (partial)
Thyroid/2	Autolysis (partial)
Urinary bladder	Autolysis (partial)

KWG 0519 - Mouse Chronic Toxicity Study
Full Macro/Micro Report

Rat No: 211
SEX: Male
DOSE LEVEL: 500ppm KWG 0519

MACROSCOPIC FINDINGS

	Mode of death : Interim death
	Days under test : 630
	Date of death : 01/04/80
Abdominal cavity	Organs reddish colouration
Intestine	Red-brown contents
Liver	Clay coloured
Lung	Flesh coloured
Seminal vesicle	Right:
	Hard dark red nodule (1.6cm diam)
Stomach	Fundic region reddened

MICROSCOPIC FINDINGS

Adrenal/1	Pigmentation (minimal)
Kidney/1	Progressive nephropathy (minimal)
Kidney/2	Progressive nephropathy (minimal)
Liver	Autolysis (partial)
Lung	Pneumonia (severe)
Pancreas	Autolysis
Seminal vesicle	Autolysis (partial)
	MALIGNANT TUMOUR mesenchymal
Spleen	Autolysis (partial)
Stomach	Calcification (minimal)
	Ectasia vascular
Testis/1	Calcification (moderate)
	Spermatocoele
Testis/2	Calcification (moderate)
Thyroid/1	No tissue available
Thyroid/2	No tissue available
Urinary bladder	Autolysis (partial)
Lymph node	No tissue available

KWG 0519 - Mouse Chronic Toxicity Study
Full Macro/Micro Report

Rat No: 212
SEX: Male
DOSE LEVEL: 500ppm KWG 0519

MACROSCOPIC FINDINGS

	Mode of death : Interim death
	Days under test : 681
	Date of death : 22/05/80
Adrenal gland	Left: Enlarged
Epididymis	Reduced in size
Intestine	Red-brown contents
Liver	Enlarged
Lung	Lob. sup. dxtr: White hard area (0.3cm diam)
Stomach	Mucosal bleeding
Testis	Reduced in size

MICROSCOPIC FINDINGS

Kidney/1	Hydronephrosis (moderate)
	Progressive nephropathy (minimal)
Kidney/2	Progressive nephropathy (minimal)
Liver	Hyperplastic nodules
Lung	MALIGNANT TUMOUR alveogenic carcinoma
	Pneumonia
Pituitary	No tissue available
Stomach	Normal
Testis/1	Atrophy seminiferous tubules
	Azoospermia
Testis/2	Atrophy seminiferous tubules
	Azoospermia
Epididymis	No tissue available
Lymph node	Oedema. Lymphatic ectasia

KWG 0519 - Mouse Chronic Toxicity Study
Full Macro/Micro Report

Rat No: 213
SEX: Male
DOSE LEVEL: 500ppm KWG 0519

MACROSCOPIC FINDINGS

Mode of death	: Interim death
Days under test	: 609
Date of death	: 11/03/80
General observations	Obese
Lung	Red foci

MICROSCOPIC FINDINGS

Heart	Congestion
Kidney/1	Autolysis (partial)
Kidney/2	Autolysis (partial)
Liver	Autolysis (partial)
	Hyperplastic nodule
Lung	Oedema
	Congestion
Pancreas	Autolysis (partial)
Spleen	Haematopoiesis (minimal)
Stomach	Autolysis (partial)
	Ectasia vascular
Thyroid/1	Autolysis (partial)
Thyroid/2	Autolysis (partial)
Urinary bladder	Autolysis

KWG 0519 - Mouse Chronic Toxicity Study
Full Macro/Micro Report

Rat No: 214
SEX: Male
DOSE LEVEL: 500ppm KWG 0519

MACROSCOPIC FINDINGS

	Mode of death : Interim death
	Days under test : 677
	Date of death : 18/05/80
Condition at necropsy	Autolysis (few organs)
General observations	Obese
Liver	Accentuated lobular marking
Lung	Dark red foci/areas

MICROSCOPIC FINDINGS

Heart	Thrombosis
	Congestion
Liver	Normal
Lung	Adenomatosis
	Pneumonia (severe)
	Congestion (severe)
Pancreas	Autolysis (partial)
Pituitary	No tissue available
Skeletal muscle	Fatty cyst
Stomach	Autolysis (partial)
Thyroid/1	Autolysis (partial)
	Cysts
Thyroid/2	Autolysis (partial)
Urinary bladder	Autolysis (partial)

290

KWG 0519 - Mouse Chronic Toxicity Study
Full Macro/Micro Report

Rat No: 215
SEX: Male
DOSE LEVEL: 500ppm KWG 0519

MACROSCOPIC FINDINGS

	Mode of death : Terminal kill
	Days under test : 734
	Date of death : 14/07/80
Liver	Lob. dxtr. access: Swollen thickened hardened
Seminal vesicle	Enlarged (3.0cm diam)

MICROSCOPIC FINDINGS

Brain	Calcification (moderate)
Heart	Degeneration muscular
Kidney/1	Dilatation renal pelvis
Liver	BENIGN TUMOUR hepatocellular adenoma
	Infarct (severe)
	Fat vacuoles (severe)
Lung	Pneumonia (minimal)
Sciatic nerve	No tissue available
Seminal vesicle	Haemorrhagic cyst
Spleen	Haematopoiesis (severe)

KWG 0519 - Mouse Chronic Toxicity Study
Full Macro/Micro Report

Rat No: 216
SEX: Male
DOSE LEVEL: 500ppm KWG 0519

MACROSCOPIC FINDINGS

Mode of death	: Interim death
Days under test	: 503
Date of death	: 26/11/79
Condition at necropsy	Autolysis (numerous organs)
Seminal vesicle	Yellowish
Urinary bladder	Red brown fluid contents
Salivary gland	Enlarged (0.8cm diam)

MICROSCOPIC FINDINGS

Adrenal/1	Pigmentation (minimal)
Adrenal/2	Pigmentation (minimal)
Brain	No tissue available
Kidney/1	Autolysis (partial)
	Calcification (minimal)
Kidney/2	Autolysis (partial)
Liver	Haemorrhagic cyst (severe)
Lung	Bronchopneumonia (severe)
	Congestion (severe)
Pancreas	No tissue available
Pituitary	No tissue available
Seminal vesicle	Coagulum
Spleen	Autolysis
Stomach	Autolysis (partial)
Testis/1	Cysts
Thyroid/1	Autolysis (partial)
Thyroid/2	Autolysis (partial)
Urinary bladder	Autolysis (partial)
	Normal
Salivary gland	Inflammation chronic

KWG 0519 - Mouse Chronic Toxicity Study
Full Macro/Micro Report

Rat No: 217
SEX: Male
DOSE LEVEL: 500ppm KWG 0519

MACROSCOPIC FINDINGS

	Mode of death : Terminal kill
	Days under test : 734
	Date of death : 14/07/80
Lung	Lab. sin: Beige cyst (0.2cm diam)

MICROSCOPIC FINDINGS

Adrenal/1	Pigmentation (minimal)
Kidney/1	Tubulopathy (minimal)
Liver	Vacuolisation (minimal)
Lung	MALIGNANT TUMOUR alveogenic carcinoma
	Pneumonia
Testis/1	Atrophy seminiferous tubules (moderate)
Testis/2	Atrophy seminiferous tubules (moderate)

KWG 0519 - Mouse Chronic Toxicity Study
Full Macro/Micro Report

Rat No: 218
SEX: Male
DOSE LEVEL: 500ppm KWG 0519

MACROSCOPIC FINDINGS

	Mode of death : Terminal kill
	Days under test : 734
	Date of death : 14/07/80
Liver	Lob. sin. and Lob. dxtr. access: Coalesced swollen thickened
Lung	Lob. sin: Enlarged beige nodules (1.2 x 0.9cm)

MICROSCOPIC FINDINGS

Bone (femur)	BENIGN TUMOUR osteoma
Kidney/1	Tubulopathy (minimal)
Kidney/2	Tubulopathy (minimal)
Liver	Fat vacuoles (moderate)
	Hyperplastic nodule
Lung	MALIGNANT TUMOUR alveogenic carcinoma
Spleen	Haematopoiesis (moderate)
Stomach	Mucoid cyst (minimal)
Testis/1	No tissue available
Testis/2	No tissue available
Thyroid/1	No tissue available
Thyroid/2	No tissue available
Urinary bladder	Inflammation granulomatous

KWG 0519 - Mouse Chronic Toxicity Study
Full Macro/Micro Report

Rat No: 219
SEX: Male
DOSE LEVEL: 500ppm KWG 0519

MACROSCOPIC FINDINGS

	Mode of death : Terminal kill
	Days under test : 734
	Date of death : 14/07/80
Kidney	Right: Cysts (0.1cm diam).
	Left: Surface raised areas
Liver	Lob. dxtr. access: Thickening (0.8cm)

MICROSCOPIC FINDINGS

Kidney/1	Calcification
Kidney/2	Calcification
Liver	Hyperplastic nodule
	Hypertrophy
Lung	Pneumonia
	Emphysema
Stomach	Mucoid cyst (minimal)
Testis/1	Atrophy seminiferous tubules (moderate)

KWG 0519 - Mouse Chronic Toxicity Study
Full Macro/Micro Report

Rat No: 220
SEX: Male
DOSE LEVEL: 500ppm KWG 0519

MACROSCOPIC FINDINGS

	Mode of death : Interim death
	Days under test : 673
	Date of death : 14/05/80
General observations	Obese
Liver	Lob. sin: Soft beige-brown nodule (1.5cm diam)
Lung	Reddish areas
Spleen	Clay coloured

MICROSCOPIC FINDINGS

Heart	Congestion
Kidney/1	Tubulopathy (moderate)
Kidney/2	Tubulopathy (moderate)
Liver	Fat vacuoles (moderate)
	Congestion
	Hyperplastic nodule
Lung	Adenomatosis
	Congestion
Sciatic nerve	No tissue available
Spleen	Haematopoiesis (severe)
Stomach	Fibrosis (moderate)
	Inflammation chronic (moderate)

KWG 0519 - Mouse Chronic Toxicity Study
Full Macro/Micro Report

Rat No: 221
SEX: Male
DOSE LEVEL: 500ppm KWG 0519

MACROSCOPIC FINDINGS

	Mode of death : Interim death
	Days under test : 397
	Date of death : 12/08/79
Condition at necropsy	Autolysis (numerous organs)
Spleen	Enlarged (2.7 x 0.4)
Urinary bladder	Enlarged (1.2cm diam) red fluid contents

MICROSCOPIC FINDINGS

Adrenal/1	Autolysis (partial)
Adrenal/2	Autolysis (partial)
Brain	No tissue available
Heart	Fat vacuoles (severe)
Kidney/1	Autolysis (partial)
	Cysts
Kidney/2	Autolysis (partial)
Liver	Autolysis (partial)
	Haemorrhagic cyst (severe)
Lung	Oedema (severe)
	Pneumonia (severe)
Pancreas	Autolysis
Pituitary	No tissue available
Spleen	Autolysis
Stomach	Autolysis
Testis/1	Autolysis (partial)
Testis/2	Autolysis (partial)
Thyroid/1	No tissue available
Thyroid/2	No tissue available
Urinary bladder	No tissue available

KWG 0519 - Mouse Chronic Toxicity Study
Full Macro/Micro Report

Rat No: 222
SEX: Male
DOSE LEVEL: 500ppm KWG 0519

MACROSCOPIC FINDINGS

Mode of death	: Interim death
Days under test	: 99
Date of death	: 18/10/78
Condition at necropsy	Moribund
Hypogastrium	Skin inflammation
Spleen	Enlarged (2.2 x 0.6)
Stomach	Mucosal bleeding fundic region

MICROSCOPIC FINDINGS

Adrenal/1	Amyloid (moderate)
Adrenal/2	Amyloid (moderate)
Liver	Amyloid (moderate)
Pancreas	Amyloid (minimal)
Seminal vesicle	Coagulum
Spleen	Amyloid (severe)
Stomach	Unreadable
Body wall	No tissue available

KWG 0519 - Mouse Chronic Toxicity Study
Full Macro/Micro Report

Rat No: 223
SEX: Male
DOSE LEVEL: 500ppm KWG 0519

MACROSCOPIC FINDINGS

Mode of death	: Interim death
Days under test	: 664
Date of death	: 05/05/80
Condition at necropsy	Moribund
Brain	Pale
Kidney	Left: Cysts
Lung	Pale
Pituitary	Pale
Spleen	Enlarged (2.4 x 0.5cm)
Abdomen	Skin inflamed extending to thorax

MICROSCOPIC FINDINGS

Kidney/1	Interstitial nephritis (minimal)
Kidney/2	Interstitial nephritis (minimal)
Spleen	Haematopoiesis (severe)
Skin	Inflammation chronic (moderate)

KWG 0519 - Mouse Chronic Toxicity Study
Full Macro/Micro Report

Rat No: 224
SEX: Male
DOSE LEVEL: 500ppm KWG 0519

MACROSCOPIC FINDINGS

Mode of death	: Interim death
Days under test	: 675
Date of death	: 16/05/80
Condition at necropsy	Autolysis (few organs)
Abdominal cavity	Organs haemorhagic
Lung	Flesh coloured
Thoracic cavity	2ml haemorrhagic fluid

MICROSCOPIC FINDINGS

Heart	Thrombosis
	Pericarditis
Lung	Pneumonia (severe)
	Congestion (severe)
Pancreas	Congestion
Sciatic nerve	No tissue available
Testis/1	Calcification (moderate)
Thyroid/1	Cysts
Urinary bladder	Inflammation chronic (minimal)

KWG 0519 - Mouse Chronic Toxicity Study
Full Macro/Micro Report

Rat No: 225
SEX: Male
DOSE LEVEL: 500ppm KWG 0519

MACROSCOPIC FINDINGS

	Mode of death : Interim death
	Days under test : 99
	Date of death : 18/10/78
Condition at necropsy	Autolysis (numerous organs)
Seminal vesicle	Enlarged
	Yellowish
Stomach	Mucosal bleeding fundic region

MICROSCOPIC FINDINGS

Heart	Congestion
Kidney/1	Autolysis (partial)
	Cysts
Kidney/2	Autolysis (partial)
Liver	Congestion
Lung	Pneumonia
	Congestion
Pituitary	No tissue available
Seminal vesicle	Coagulum
	Cysts
Stomach	Normal
Urinary bladder	Coagulum
Prostate	Coagulum

KWG 0519 - Mouse Chronic Toxicity Study
Full Macro/Micro Report

Rat No: 226
SEX: Male
DOSE LEVEL: 500ppm KWG 0519

MACROSCOPIC FINDINGS

	Mode of death : Terminal kill
	Days under test : 734
	Date of death : 14/07/80
Liver	Lob. sin: Soft conglomerate mass at periphery (1.4cm diam)
Lung	Lob. sin: Flesh coloured with red foci
Pituitary	Pale

MICROSCOPIC FINDINGS

Kidney/1	Interstitial nephritis (minimal)
Kidney/2	Interstitial nephritis (minimal)
Liver	BENIGN TUMOUR hepatocellular adenoma
Lung	Thickened alveolar walls
Pituitary	Normal
Spleen	Haematopoiesis (moderate)

KWG 0519 - Mouse Chronic Toxicity Study
Full Macro/Micro Report

Rat No: 227
SEX: Male
DOSE LEVEL: 500ppm KWG 0519

MACROSCOPIC FINDINGS

	Mode of death : Interim death
	Days under test : 482
	Date of death : 05/11/79
Stomach	Mucosal bleeding fundic region

MICROSCOPIC FINDINGS

Kidney/1	Congestion
Kidney/2	Congestion
Stomach	Normal

KWG 0519 - Mouse Chronic Toxicity Study
Full Macro/Micro Report

Rat No: 228
SEX: Male
DOSE LEVEL: 500ppm KWG 0519

MACROSCOPIC FINDINGS

Condition at necropsy	Mode of death	: Terminal kill
	Days under test	: 734
	Date of death	: 14/07/80
	Autolysis (few organs)	
	No significant findings noted	

MICROSCOPIC FINDINGS

Kidney/1	Tubulopathy (minimal)
Kidney/2	Interstitial nephritis (minimal)
Spleen	Haematopoiesis (minimal)
Stomach	Mucoid cyst (minimal)

KWG 0519 - Mouse Chronic Toxicity Study
Full Macro/Micro Report

Rat No: 229
SEX: Male
DOSE LEVEL: 500ppm KWG 0519

MACROSCOPIC FINDINGS

	Mode of death : Interim death
	Days under test : 357
	Date of death : 03/07/79
Intestine	Haemorrhagic contents
Stomach	Mucosal bleeding

MICROSCOPIC FINDINGS

Liver	Autolysis (partial)
Lung	Pneumonia (severe)
	Congestion (severe)
Pancreas	Autolysis (partial)
Pituitary	No tissue available
Stomach	Haemorrhage

KWG 0519 - Mouse Chronic Toxicity Study
Full Macro/Micro Report

Rat No: 230
SEX: Male
DOSE LEVEL: 500ppm KWG 0519

MACROSCOPIC FINDINGS

	Mode of death : Terminal kill
	Days under test : 734
	Date of death : 14/07/80
Adrenal gland	Right: Enlarged
Kidney	Cysts (0.1-0.2cm diam)
Pancreas	Hardened

MICROSCOPIC FINDINGS

Adrenal/1	BENIGN TUMOUR cortical adenoma
Adrenal/2	Pigmentation (moderate)
Kidney/1	Cysts
Lung	Pneumonia
Pancreas	Normal
Pituitary	No tissue available
Spleen	Haematopoiesis (moderate)
Thyroid/1	No tissue available
Thyroid/2	No tissue available

KWG 0519 - Mouse Chronic Toxicity Study
Full Macro/Micro Report

Rat No: 231
SEX: Male
DOSE LEVEL: 500ppm KWG 0519

MACROSCOPIC FINDINGS

Condition at necropsy	Mode of death : Interim death Days under test : 369 Date of death : 15/07/79 Autolysis (complete) Evaluation not possible

MICROSCOPIC FINDINGS

Adrenal/1	Autolysis
Adrenal/2	Autolysis
Brain	No tissue available
Kidney/1	Autolysis (partial)
Kidney/2	Autolysis (partial)
Liver	Autolysis (partial) MALIGNANT LYMPHOMA
Lung	Autolysis (partial) MALIGNANT TUMOUR alveogenic carcinoma Oedema (severe)
Pancreas	Autolysis
Pituitary	Autolysis
Spleen	Autolysis (partial) MALIGNANT LYMPHOMA
Stomach	Autolysis (partial)
Testis/1	Autolysis (partial)
Testis/2	Autolysis (partial)
Thyroid/1	Autolysis
Thyroid/2	Autolysis
Urinary bladder	Autolysis (partial)

307

KWG 0519 - Mouse Chronic Toxicity Study
Full Macro/Micro Report

Rat No: 232
SEX: Male
DOSE LEVEL: 500ppm KWG 0519

MACROSCOPIC FINDINGS

	Mode of death : Interim death
	Days under test : 718
	Date of death : 28/06/80
Condition at necropsy	Autolysis (few organs)
Liver	Lob. sin: Swollen hard yellowish discolouration
Lung	Flesh coloured
	Enlarged

MICROSCOPIC FINDINGS

Heart	Dilated chamber
Liver	BENIGN TUMOUR hepatocellular adenoma
	Infarct
Lung	Thrombosis (severe)
	Congestion (severe)
	Ectasia vascular (severe)
Pancreas	Autolysis (partial)
Pituitary	No tissue available
Sciatic nerve	No tissue available
Spleen	Congestion
Thyroid/1	Autolysis (partial)
Thyroid/2	Autolysis (partial)

KWG 0519 - Mouse Chronic Toxicity Study
Full Macro/Micro Report

Rat No: 233
SEX: Male
DOSE LEVEL: 500ppm KWG 0519

MACROSCOPIC FINDINGS

Mode of death : Terminal kill
Days under test : 734
Date of death : 14/07/80
No significant findings noted

MICROSCOPIC FINDINGS

Kidney/1	Interstitial nephritis (moderate)
Kidney/2	Interstitial nephritis (moderate)
Lung	Pneumonia (severe)
Pancreas	BENIGN TUMOUR islet cell adenoma
Pituitary	No tissue available
Stomach	Inflammation chronic (moderate)

KWG 0519 - Mouse Chronic Toxicity Study
Full Macro/Micro Report

Rat No: 234
SEX: Male
DOSE LEVEL: 500ppm KWG 0519

MACROSCOPIC FINDINGS

	Mode of death : Interim death
	Days under test : 602
	Date of death : 04/03/80
Condition at necropsy	Autolysis (few organs)
Lung	Lob. sin: Beige-grey induration (0.2cm diam)
Spleen	Reduced in size

MICROSCOPIC FINDINGS

Heart	Congestion
Kidney/1	Tubulopathy (minimal)
Kidney/2	Tubulopathy (minimal)
Lung	MALIGNANT TUMOUR alveogenic carcinoma
	Congestion (severe)
Urinary bladder	Autolysis (partial)

KWG 0519 - Mouse Chronic Toxicity Study
Full Macro/Micro Report

Rat No: 235
SEX: Male
DOSE LEVEL: 500ppm KWG 0519

MACROSCOPIC FINDINGS

	Mode of death : Interim death
	Days under test : 688
	Date of death : 29/05/80
Kidney	Clay coloured
Liver	Clay coloured
Lung	Portal: Dark red soft nodule (3.6 x 1.8cm)
	Loo. sup. dxtr:
	Two hard white nodules (0.1 and 0.3cm diam)
Seminal vesicle	Enlarged
Spleen	Enlarged (2.4 x 0.5cm)

MICROSCOPIC FINDINGS

Bone (femur)	BENIGN TUMOUR osteoma
Brain	Fat vacuoles (moderate)
Heart	Thrombosis
	Fibrosis
	Inflammation chronic
Kidney/1	Interstitial nephritis (minimal)
Kidney/2	Interstitial nephritis (minimal)
Liver	Hyperplastic nodule
	Haemorrhagic cyst (severe)
Lung	MALIGNANT TUMOUR alveogenic carcinoma
	Pneumonia
Pancreas	Autolysis (partial)
Pituitary	No tissue available
Seminal vesicle	Coagulum
Spleen	Normal
Testis/1	Calcification (minimal)
Testis/2	Calcification (minimal)
Thyroid/1	Autolysis (partial)
Thyroid/2	Autolysis (partial)
Urinary bladder	Autolysis (partial)

KWG 0519 - Mouse Chronic Toxicity Study
Full Macro/Micro Report

Rat No: 236
SEX: Male
DOSE LEVEL: 500ppm KWG 0519

MACROSCOPIC FINDINGS

	Mode of death : Interim death
	Days under test : 715
	Date of death : 25/06/80
Condition at necropsy	Moribund
Kidney	Left: Cysts
Lung	Dark foci/areas
	Lob. inf. dxtr. lat: White hard nodule (0.2cm diam)

MICROSCOPIC FINDINGS

Kidney/1	Cysts (moderate)
Kidney/2	Cysts (moderate)
Lung	Necrosis (severe)
	Bronchopneumonia (severe)
Pituitary	No tissue available
Spleen	Haematopoiesis (minimal)
Thyroid/1	No tissue available
Thyroid/2	No tissue available

KWG 0519 - Mouse Chronic Toxicity Study
Full Macro/Micro Report

Rat No: 237
SEX: Male
DOSE LEVEL: 500ppm KWG 0519

MACROSCOPIC FINDINGS

	Mode of death : Interim death
	Days under test : 535
	Date of death : 28/12/79
Adrenal gland	Surface white foci
Lung	Lob. sin: White hard nodule (0.2cm diam)

MICROSCOPIC FINDINGS

Adrenal/1	BENIGN TUMOUR cortical adenoma
Heart	Congestion
Kidney/1	Tubulopathy (minimal)
Liver	Congestion
Lung	Pneumonia
	Congestion
Pituitary	No tissue available

KWG 0519 - Mouse Chronic Toxicity Study
Full Macro/Micro Report

Rat No: 238
SEX: Male
DOSE LEVEL: 500ppm KWG 0519

MACROSCOPIC FINDINGS

	Mode of death : Interim death
	Days under test : 638
	Date of death : 09/04/80
Condition at necropsy	Moribund
Spleen	Enlarged (2.9 x 0.7cm) marbled surface

MICROSCOPIC FINDINGS

Bone (femur)	No tissue available
Kidney/1	Cysts (minimal)
Kidney/2	Cysts (minimal)
Liver	Hyperplastic nodule
Lung	Haemorrhage
Pituitary	No tissue available
Sciatic nerve	No tissue available
Seminal vesicle	Coagulum
Spleen	Haematopoiesis (severe)
Thyroid/1	No tissue available
Thyroid/2	No tissue available

KWG 0519 - Mouse Chronic Toxicity Study
Full Macro/Micro Report

Rat No: 239
SEX: Male
DOSE LEVEL: 500ppm KWG 0519

MACROSCOPIC FINDINGS

	Mode of death : Terminal kill
	Days under test : 734
	Date of death : 14/07/80
Pancreas	Hardened

MICROSCOPIC FINDINGS

Adrenal/1	BENIGN TUMOUR cortical adenoma
Lung	Pneumonia (moderate)
Pancreas	Normal
Pituitary	No tissue available
Sciatic nerve	No tissue available
Stomach	Inflammation chronic (minimal)
Testis/1	Atrophy seminiferous tubules (moderate)

KWG 0519 - Mouse Chronic Toxicity Study
Full Macro/Micro Report

Rat No: 240
SEX: Male
DOSE LEVEL: 500ppm KWG 0519

MACROSCOPIC FINDINGS

	Mode of death : Interim death
	Days under test : 636
	Date of death : 07/04/80
Condition at necropsy	Autolysis (complete)
	Evaluation not possible

MICROSCOPIC FINDINGS

Adrenal/1	Autolysis
Adrenal/2	Autolysis
Bone (femur)	No tissue available
Brain	No tissue available
Heart	Autolysis (partial)
Kidney/1	Autolysis
Kidney/2	Autolysis
Liver	Autolysis
Lung	Autolysis
Pancreas	No tissue available
Pituitary	Autolysis
Sciatic nerve	No tissue available
Skeletal muscle	No tissue available
Spleen	Autolysis
Stomach	Autolysis
Testis/1	Autolysis
Testis/2	Autolysis
Thyroid/1	Autolysis
Thyroid/2	Autolysis
Urinary bladder	Autolysis

KWG 0519 - Mouse Chronic Toxicity Study
Full Macro/Micro Report

Rat No: 241
SEX: Male
DOSE LEVEL: 500ppm KWG 0519

MACROSCOPIC FINDINGS

	Mode of death : Interim death
	Days under test : 386
	Date of death : 01/08/79
Intestine	Haemorrhagic contents
Lung	Fleshy areas
Spleen	Enlarged (4.0 x 0.7cm)
Stomach	Mucosal bleeding

MICROSCOPIC FINDINGS

Adrenal/1	Pigmentation (moderate)
Adrenal/2	Pigmentation (moderate)
Heart	Pericarditis (severe)
Kidney/1	Autolysis (partial)
	Tubulopathy (minimal)
Kidney/2	Autolysis (partial)
Liver	Mononuclear cells (moderate)
Lung	Pneumonia (severe)
	Congestion (severe)
Pancreas	No tissue available
Spleen	Autolysis
Testis/1	Autolysis (partial)
Testis/2	Autolysis (partial)
Thyroid/1	No tissue available
Thyroid/2	No tissue available
Intestine	Autolysis

KWG 0519 - Mouse Chronic Toxicity Study
Full Macro/Micro Report

Rat No: 242
SEX: Male
DOSE LEVEL: 500ppm KWG 0519

MACROSCOPIC FINDINGS

	Mode of death : Interim death
	Days under test : 715
	Date of death : 25/06/80
Condition at necropsy	Autolysis (few organs)
Liver	Accentuated lobular marking
Spleen	Clay coloured

MICROSCOPIC FINDINGS

Adrenal/1	No tissue available
Adrenal/2	No tissue available
Heart	Thrombosis
Kidney/1	Hydronephrosis (moderate)
	Progressive nephropathy (moderate)
Kidney/2	Hydronephrosis (moderate)
	Progressive nephropathy (moderate)
Liver	Normal
Pituitary	No tissue available
Spleen	Normal

KWG 0519 - Mouse Chronic Toxicity Study
Full Macro/Micro Report

Rat No: 243
SEX: Male
DOSE LEVEL: 500ppm KWG 0519

MACROSCOPIC FINDINGS

	Mode of death : Interim death
	Days under test : 657
	Date of death : 28/04/80
Condition at necropsy	Autolysis (numerous organs)
Spleen	Enlarged (3.6 x 0.5cm)

MICROSCOPIC FINDINGS

Brain	No tissue available
Heart	Leukocytosis (severe)
	Congestion (severe)
Kidney/1	Autolysis (partial)
	Cysts (moderate)
	MALIGNANT LYMPHOMA
Kidney/2	Autolysis (partial)
	Cysts (moderate)
	MALIGNANT LYMPHOMA
Liver	Autolysis (partial)
	MALIGNANT LYMPHOMA
Lung	Oedema
	Adenomatosis
	Pneumonia
	Leukocytosis
Pancreas	Autolysis
Pituitary	No tissue available
Spleen	Autolysis (partial)
	MALIGNANT LYMPHOMA
Stomach	Autolysis
Testis/1	Calcification (moderate)
Thyroid/1	No tissue available
Thyroid/2	No tissue available
Urinary bladder	Autolysis

KWG 0519 - Mouse Chronic Toxicity Study
Full Macro/Micro Report

Rat No: 244
SEX: Male
DOSE LEVEL: 500ppm KWG 0519

MACROSCOPIC FINDINGS

	Mode of death : Terminal kill
	Days under test : 734
	Date of death : 14/07/80
Epididymis	Left: Dark
Kidney	Left: Cysts (0.2cm diam)
Lung	Lob. sin: Beige foci (0.2cm diam)

MICROSCOPIC FINDINGS

Kidney/1	Interstitial nephritis (moderate)
	Cysts
Kidney/2	Interstitial nephritis (moderate)
Lung	MALIGNANT TUMOUR alveogenic carcinoma
	Pneumonia
Sciatic nerve	No tissue available
Testis/1	Atrophy seminiferous tubules (moderate)
	Calcification (moderate)
Testis/2	Atrophy seminiferous tubules (moderate)
	Calcification (moderate)
Epididymis	No tissue available

KWG 0519 - Mouse Chronic Toxicity Study
Full Macro/Micro Report

Rat No: 245
SEX: Male
DOSE LEVEL: 500ppm KWG 0519

MACROSCOPIC FINDINGS

Mode of death	: Interim death
Days under test	: 630
Date of death	: 01/04/80
Condition at necropsy	Autolysis (few organs)
Liver	Accentuated lobular marking
Lung	Flesh coloured
Spleen	Enlarged (3.3 x 0.6cm)
Mesenteric lymph node	Enlarged

MICROSCOPIC FINDINGS

Adrenal/1	No tissue available
Adrenal/2	No tissue available
Bone (femur)	No tissue available
Brain	No tissue available
Heart	No tissue available
Kidney/1	No tissue available
Kidney/2	No tissue available
Liver	No tissue available
Lung	No tissue available
Pancreas	No tissue available
Pituitary	No tissue available
Sciatic nerve	No tissue available
Skeletal muscle	No tissue available
Spleen	No tissue available
Stomach	No tissue available
Testis/1	No tissue available
Testis/2	No tissue available
Thyroid/1	No tissue available
Thyroid/2	No tissue available
Urinary bladder	No tissue available

KWG 0519 - Mouse Chronic Toxicity Study
Full Macro/Micro Report

Rat No: 246
SEX: Male
DOSE LEVEL: 500ppm KWG 0519

MACROSCOPIC FINDINGS

	Mode of death : Interim death
	Days under test : 632
	Date of death : 03/04/80
Liver	Enlarged
	Gritty surface
Lung	Dark/red coloured
Spleen	Enlarged (2.7 x 0.8cm)
Thoracic cavity	3ml clear fluid

MICROSCOPIC FINDINGS

Brain	Fat vacuoles (moderate)
Heart	Congestion
Kidney/1	Interstitial nephritis
Liver	Congestion
	MALIGNANT LYMPHOMA
Lung	Haemorrhage
	Pneumonia
	Congestion
Sciatic nerve	No tissue available
Spleen	MALIGNANT LYMPHOMA
Stomach	No tissue available
Thyroid/1	No tissue available
Thyroid/2	No tissue available

KWG 0519 - Mouse Chronic Toxicity Study
Full Macro/Micro Report

Rat No: 247
SEX: Male
DOSE LEVEL: 500ppm KWG 0519

MACROSCOPIC FINDINGS

	Mode of death : Interim death
	Days under test : 562
	Date of death : 24/01/80
Condition at necropsy	Autolysis (complete)
	Evaluation not possible

MICROSCOPIC FINDINGS

Adrenal/1	Autolysis
Adrenal/2	Autolysis
Brain	No tissue available
Kidney/1	Autolysis
	Cysts (moderate)
Kidney/2	Autolysis
	Cysts (moderate)
Liver	Autolysis (partial)
	Haemorrhagic cyst (severe)
Lung	Autolysis
Pancreas	Autolysis
Pituitary	Autolysis
Spleen	Autolysis
Stomach	Autolysis
Testis/1	Autolysis
Testis/2	Autolysis
Thyroid/1	No tissue available
Thyroid/2	No tissue available
Urinary bladder	Autolysis

KWG 0519 - Mouse Chronic Toxicity Study
Full Macro/Micro Report

Rat No: 248
SEX: Male
DOSE LEVEL: 500ppm KWG 0519

MACROSCOPIC FINDINGS

	Mode of death : Interim death
	Days under test : 471
	Date of death : 25/10/79
Condition at necropsy	Autolysis (few organs)
General observations	Obese

MICROSCOPIC FINDINGS

Brain	Vacuolisation (moderate)
Heart	Congestion
Kidney/1	Pyelonephritis (moderate)
Kidney/2	Pyelonephritis (moderate)
Liver	Hyperplastic nodules
Lung	Thrombosis
	Pneumonia
	Congestion
Pancreas	Autolysis (partial)
Spleen	Congestion
Thyroid/1	No tissue available
Thyroid/2	No tissue available

KWG 0519 - Mouse Chronic Toxicity Study
Full Macro/Micro Report

Rat No: 249
SEX: Male
DOSE LEVEL: 500ppm KWG 0519

MACROSCOPIC FINDINGS

	Mode of death : Interim death
	Days under test : 405
	Date of death : 20/08/79
Thymus	Hard beige-grey nodule (1.2 x 0.7cm)

MICROSCOPIC FINDINGS

Heart	MALIGNANT LYMPHOMA
Liver	Congestion
Lung	MALIGNANT LYMPHOMA
Stomach	MALIGNANT LYMPHOMA
Thymus	MALIGNANT LYMPHOMA

KWG 0519 - Mouse Chronic Toxicity Study
Full Macro/Micro Report

Rat No: 250
SEX: Male
DOSE LEVEL: 500ppm KWG 0519

MACROSCOPIC FINDINGS

	Mode of death : Interim death
	Days under test : 501
	Date of death : 24/11/79
Condition at necropsy	Autolysis (few organs)
Liver	Enlarged
Lung	Flesh coloured
	Lob. inf. dxtr. lat: Soft grey nodule (0.4cm diam)

MICROSCOPIC FINDINGS

Kidney/1	Calcification (minimal)
	Dilatation glomerular loops (minimal)
Kidney/2	Dilatation glomerular loops (minimal)
Liver	Mononuclear cells (minimal)
	Pigmentation (moderate)
Lung	Fibrosis (moderate)
	Pneumonia
Pituitary	No tissue available
Spleen	Haematopoiesis (minimal)
Thyroid/1	No tissue available
Thyroid/2	No tissue available

KWG 0519 - Mouse Chronic Toxicity Study
Full Macro/Micro Report

Rat No: 251
SEX: Female
DOSE LEVEL: 500ppm KWG 0519

MACROSCOPIC FINDINGS

Mode of death	: Interim death
Days under test	: 546
Date of death	: 08/01/80
Condition at necropsy	Autolysis (few organs)
Adrenal gland	Left: Enlarged
Cranium	Indurated
Intestine	Black-brown contents
Liver	Enlarged
Lung	Dark foci/areas
Spleen	Enlarged (3.3 x 0.8cm)
Stomach	Mucosal bleeding

MICROSCOPIC FINDINGS

Adrenal/1	Calcification
	Pigmentation (moderate)
Adrenal/2	Pigmentation (moderate)
Kidney/1	MALIGNANT LYMPHOMA
Kidney/2	MALIGNANT LYMPHOMA
Liver	MALIGNANT LYMPHOMA
Lung	Haemorrhage
Spleen	Congestion
	MALIGNANT LYMPHOMA
Stomach	Normal
Urinary bladder	Autolysis (partial)
Lymph node	Autolysis (partial)
	Hypertrophy
	Congestion

KWG 0519 - Mouse Chronic Toxicity Study
Full Macro/Micro Report

Rat No: 252
SEX: Female
DOSE LEVEL: 500ppm KWG 0519

MACROSCOPIC FINDINGS

	Mode of death : Interim death
	Days under test : 618
	Date of death : 20/03/80
Lung	Lob. sin: Two white grey areas (0.2cm diam) on median and periphery
Spleen	Enlarged (3.2 x 0.5cm)
Mesenteric lymph node	Enlarged

MICROSCOPIC FINDINGS

Brain	Fat vacuoles
Kidney/1	Interstitial nephritis (minimal)
	Cysts (minimal)
Liver	Autolysis (partial)
	MALIGNANT LYMPHOMA
Lung	MALIGNANT TUMOUR alveogenic carcinoma
	Leukocytosis (severe)
	MALIGNANT LYMPHOMA
Ovary/1	Atrophy
Ovary/2	Atrophy
Pituitary	No tissue available
Spleen	MALIGNANT LYMPHOMA
Urinary bladder	Autolysis (partial)
Uterus	Hyperplasia polypoid
	MALIGNANT LYMPHOMA
Lymph node	MALIGNANT LYMPHOMA

KWG 0519 - Mouse Chronic Toxicity Study
Full Macro/Micro Report

Rat No: 253
SEX: Female
DOSE LEVEL: 500ppm KWG 0519

MACROSCOPIC FINDINGS

	Mode of death : Terminal kill
	Days under test : 735
	Date of death : 15/07/80
Ovary	Left: Watery fluid contents
Uterus	Horns enlarged thickened (0.5cm diam)

MICROSCOPIC FINDINGS

Adrenal/1	Pigmentation (minimal)
Adrenal/2	Pigmentation (minimal)
Brain	Gliosis
Kidney/1	Interstitial nephritis
Kidney/2	Interstitial nephritis
Lung	Atelectasis (moderate)
	Thickened alveolar walls (moderate)
Ovary/1	Atrophy
	Cysts
Ovary/2	Atrophy
Spleen	Haematopoiesis (moderate)
Uterus	Thrombosis (severe)
	Haemorrhage (severe)
	Cystic endometrial hyperplasia (severe)
	Hyperplasia secretory (severe)

KWG 0519 - Mouse Chronic Toxicity Study
Full Macro/Micro Report

Rat No: 254
SEX: Female
DOSE LEVEL: 500ppm KWG 0519

MACROSCOPIC FINDINGS

	Mode of death : Interim death
	Days under test : 633
	Date of death : 24/04/80
Condition at necropsy	Autolysis (few organs)
Femur	Right: Soft beige nodule (1.1cm diam)
Lung	Lob. sup. dxtr: White hard nodule (0.4cm diam)
	Lob. med. dxtr: White hard nodule (1.0cm diam)

MICROSCOPIC FINDINGS

Bone (femur)	Normal
Kidney/1	Pyelonephritis (moderate)
Kidney/2	Pyelonephritis (moderate)
Liver	Autolysis (partial)
Lung	MALIGNANT TUMOUR alveogenic carcinoma
	MALIGNANT LYMPHOMA
Ovary/1	Atrophy
Ovary/2	Atrophy
Pancreas	Autolysis (partial)
Spleen	Haematopoiesis (severe)
Thyroid/1	Autolysis (partial)
Thyroid/2	Autolysis (partial)
Urinary bladder	Autolysis (partial)
Lymph node	MALIGNANT LYMPHOMA

KWG 0519 - Mouse Chronic Toxicity Study
Full Macro/Micro Report

Rat No: 255
SEX: Female
DOSE LEVEL: 500ppm KWG 0519

MACROSCOPIC FINDINGS

Mode of death	: Interim death
Days under test	: 572
Date of death	: 03/02/80
Adrenal gland	Left: Enlarged
Condition at necropsy	Autolysis (few organs)
Liver	Enlarged
Lung	Pale
Spleen	Enlarged (3.5 x 0.8cm)

MICROSCOPIC FINDINGS

Adrenal/1	Pigmentation (minimal)
Heart	Congestion
Kidney/1	MALIGNANT LYMPHOMA
Kidney/2	MALIGNANT LYMPHOMA
Liver	MALIGNANT LYMPHOMA
Lung	MALIGNANT LYMPHOMA
Ovary/1	MALIGNANT LYMPHOMA
Ovary/2	MALIGNANT LYMPHOMA
Pancreas	MALIGNANT LYMPHOMA
Skeletal muscle	MALIGNANT LYMPHOMA
Spleen	MALIGNANT LYMPHOMA
Stomach	MALIGNANT LYMPHOMA
Thyroid/1	No tissue available
Thyroid/2	No tissue available
Urinary bladder	MALIGNANT LYMPHOMA
Lymph node	MALIGNANT LYMPHOMA
Mesentery	MALIGNANT LYMPHOMA

KWG 0519 - Mouse Chronic Toxicity Study
Full Macro/Micro Report

Rat No: 256
SEX: Female
DOSE LEVEL: 500ppm KWG 0519

MACROSCOPIC FINDINGS

	Mode of death : Interim death
	Days under test : 475
	Date of death : 29/10/79
Lung	Flesh coloured areas
Thymus	Hard beige nodule (1.1cm diam)
Uterus	Horns thickened (0.3cm diam)

MICROSCOPIC FINDINGS

Heart	Congestion
	Pericarditis
Kidney/1	Autolysis (partial)
	Congestion
Kidney/2	Autolysis (partial)
	Congestion
Liver	Autolysis (partial)
	Congestion
	Vacuolisation (minimal)
Lung	Oedema
	Haemorrhage
	Congestion
Pancreas	Autolysis (partial)
Spleen	Haematopoiesis (moderate)
Stomach	Autolysis (partial)
Thyroid/1	No tissue available
Thyroid/2	No tissue available
Urinary bladder	Autolysis (partial)
Uterus	Hyperplasia secretory (moderate)
Thymus	MALIGNANT LYMPHOMA

KWG 0519 - Mouse Chronic Toxicity Study
Full Macro/Micro Report

Rat No: 257
SEX: Female
DOSE LEVEL: 500ppm KWG 0519

MACROSCOPIC FINDINGS

	Mode of death : Interim death
	Days under test : 626
	Date of death : 28/03/80
Adrenal gland	Left: White focus
Femur	Left: Hard white nodule (1.0cm diam)
Kidney	Right: White-beige areas (0.05-0.1cm diam)
Spleen	Enlarged (2.6 x 0.6cm)

MICROSCOPIC FINDINGS

Bone (femur)	MALIGNANT TUMOUR osteogenic sarcoma
Kidney/1	Tubulopathy (moderate)
	MALIGNANT LYMPHOMA
Kidney/2	Tubulopathy (moderate)
	MALIGNANT LYMPHOMA
Liver	MALIGNANT LYMPHOMA
Ovary/1	Atrophy
	Cysts
Ovary/2	Atrophy
	Cysts
Pancreas	Autolysis (partial)
Pituitary	No tissue available
Skeletal muscle	MALIGNANT LYMPHOMA
Spleen	Haematopoiesis (severe)
	MALIGNANT LYMPHOMA
Stomach	Autolysis (partial)
Thyroid/1	No tissue available
Thyroid/2	No tissue available
Urinary bladder	MALIGNANT LYMPHOMA
Lymph node	MALIGNANT LYMPHOMA

KWG 0519 - Mouse Chronic Toxicity Study
Full Macro/Micro Report

Rat No: 258
SEX: Female
DOSE LEVEL: 500ppm KWG 0519

MACROSCOPIC FINDINGS

	Mode of death : Terminal kill
	Days under test : 735
	Date of death : 15/07/80
Kidney	Right: Cysts (0.2cm diam)

MICROSCOPIC FINDINGS

Adrenal/1	Pigmentation (minimal)
Adrenal/2	Pigmentation (minimal)
Kidney/1	Cysts
	Progressive nephropathy (minimal)
Liver	Vacuolisation (minimal)
Lung	Pneumonia (minimal)
Ovary/1	BENIGN TUMOUR luteoma
Ovary/2	Hypertrophic corpora lutea
Spleen	Haematopoiesis (minimal)
Stomach	Mucoid cyst (minimal)
Thyroid/1	Cysts

KWG 0519 - Mouse Chronic Toxicity Study
Full Macro/Micro Report

Rat No: 259
SEX: Female
DOSE LEVEL: 500ppm KWG 0519

MACROSCOPIC FINDINGS

	Mode of death : Interim death
	Days under test : 560
	Date of death : 22/01/80
Condition at necropsy	Autolysis (numerous organs)
Kidney	Enlarged
Liver	Enlarged
Spleen	Enlarged

MICROSCOPIC FINDINGS

Adrenal/1	Autolysis (partial)
Adrenal/2	Autolysis (partial)
Brain	No tissue available
Kidney/1	Autolysis (partial)
	MALIGNANT LYMPHOMA
Kidney/2	Autolysis (partial)
	MALIGNANT LYMPHOMA
Liver	Autolysis (partial)
	MALIGNANT LYMPHOMA
Lung	Autolysis (partial)
	Leukocytosis
Ovary/1	Autolysis
Ovary/2	Autolysis
Pancreas	Autolysis
Pituitary	No tissue available
Skeletal muscle	Autolysis (partial)
Spleen	Autolysis (partial)
	MALIGNANT LYMPHOMA
Stomach	Autolysis
Thyroid/1	No tissue available
Thyroid/2	No tissue available
Urinary bladder	Autolysis
Mesentery	MALIGNANT LYMPHOMA

KWG 0519 - Mouse Chronic Toxicity Study
Full Macro/Micro Report

Rat No: 260
SEX: Female
DOSE LEVEL: 500ppm KWG 0519

MACROSCOPIC FINDINGS

	Mode of death : Interim death
	Days under test : 721
	Date of death : 01/07/80
Liver	Enlarged
Lung	Flesh coloured
Ovary	Lob. sin: White hard nodule (1.0cm diam)
	Both: Cysts (0.5-0.7cm diam)

MICROSCOPIC FINDINGS

Heart	Congestion
	Dilated chamber
Kidney/1	Tubulopathy (minimal)
Kidney/2	Tubulopathy (minimal)
Liver	BENIGN TUMOUR hepatocellular adenoma
	Congestion
Lung	MALIGNANT TUMOUR alveogenic carcinoma
Ovary/1	Atrophy
	Cysts
	MALIGNANT LYMPHOMA
Ovary/2	Atrophy
	Cysts
	MALIGNANT LYMPHOMA
Pancreas	MALIGNANT LYMPHOMA
Spleen	MALIGNANT LYMPHOMA
Uterus	Squamous metaplasia
	Endometriosis
	MALIGNANT LYMPHOMA
Mesentery	MALIGNANT LYMPHOMA

KWG 0519 - Mouse Chronic Toxicity Study
Full Macro/Micro Report

Rat No: 261
SEX: Female
DOSE LEVEL: 500ppm KWG 0519

MACROSCOPIC FINDINGS

	Mode of death : Interim death
	Days under test : 636
	Date of death : 07/04/80
Condition at necropsy	Autolysis (few organs)
Liver	Enlarged
	Indurated purulent infiltration

MICROSCOPIC FINDINGS

Adrenal/1	Pigmentation (moderate)
Adrenal/2	Pigmentation (moderate)
Bone (femur)	No tissue available
Liver	Necrosis
	Hyperplastic nodule
	MALIGNANT LYMPHOMA
Lung	Pneumonia
Ovary/1	Atrophy
	Cysts
Ovary/2	Atrophy
Pancreas	Autolysis (partial)
Sciatic nerve	No tissue available
Skeletal muscle	No tissue available
Spleen	Haematopoiesis (severe)
Stomach	MALIGNANT LYMPHOMA
Urinary bladder	No tissue available
Uterus	Hyperplasia polypoid
Lymph node	MALIGNANT LYMPHOMA

KWG 0519 - Mouse Chronic Toxicity Study
Full Macro/Micro Report

Rat No: 262
SEX: Female
DOSE LEVEL: 500ppm KWG 0519

MACROSCOPIC FINDINGS

	Mode of death : Interim death
	Days under test : 486
	Date of death : 09/11/79
Abdominal cavity	Red nodule with light foci (2.5 x 0.7cm) mesentery
Liver	Lob. sin: Multiple white to reddish foci
Lung	Lob. sin: White hard nodule (0.5cm diam)
Ovary	Right: Cysts (0.5cm diam)
Spleen	Enlarged (2.4 x 0.8cm)
Stomach	Mucosal bleeding fundic region

MICROSCOPIC FINDINGS

Brain	Fat vacuoles (moderate)
Heart	Congestion
Kidney/1	MALIGNANT LYMPHOMA
Kidney/2	MALIGNANT LYMPHOMA
Liver	Infarct
	MALIGNANT LYMPHOMA
Lung	MALIGNANT TUMOUR alveogenic carcinoma
	Necrosis
Ovary/1	Cysts
Pancreas	Atrophy (moderate)
	Inflammation chronic (moderate)
Pituitary	No tissue available
Spleen	Congestion
	MALIGNANT LYMPHOMA
Stomach	Autolysis (partial)
	Haemorrhage
	MALIGNANT LYMPHOMA
Thyroid/1	No tissue available
Thyroid/2	No tissue available
Urinary bladder	MALIGNANT LYMPHOMA
Uterus	Unreadable
Mesentery	MALIGNANT LYMPHOMA

KWG 0519 - Mouse Chronic Toxicity Study
Full Macro/Micro Report

Rat No: 263
SEX: Female
DOSE LEVEL: 500ppm KWG 0519

MACROSCOPIC FINDINGS

	Mode of death : Terminal kill
	Days under test : 735
	Date of death : 15/07/80
Lung	Flesh coloured
Ovary	Right: Cysts (0.4cm diam) glassy
Uterus	Horns: Enlarged (0.5cm diam)

MICROSCOPIC FINDINGS

Adrenal/1	Pigmentation (moderate)
Adrenal/2	Pigmentation (moderate)
Bone (femur)	Unreadable
Liver	Mononuclear cells (minimal)
Lung	Atelectasis (moderate)
Ovary/1	Normal
Ovary/2	Normal
Spleen	Haematopoiesis (minimal)
Stomach	Mucoid cyst (minimal)
Thyroid/1	No tissue available
Thyroid/2	No tissue available
Uterus	Endometriosis (severe)
	Haemorrhagic cyst

KWG 0519 - Mouse Chronic Toxicity Study
Full Macro/Micro Report

Rat No: 264
SEX: Female
DOSE LEVEL: 500ppm KWG 0519

MACROSCOPIC FINDINGS

	Mode of death : Interim death
	Days under test : 651
	Date of death : 22/04/80
Condition at necropsy	Autolysis (numerous organs)
Lung	Enlarged swollen with adhesions to diaphragm

MICROSCOPIC FINDINGS

Adrenal/1	Pigmentation (moderate)
Adrenal/2	Pigmentation (moderate)
Brain	No tissue available
Kidney/1	Autolysis (partial)
Kidney/2	Autolysis (partial)
Liver	Autolysis (partial)
Lung	Autolysis (partial)
	Oedema
Ovary/1	Autolysis
Ovary/2	Autolysis
Pancreas	Autolysis
Pituitary	No tissue available
Spleen	Autolysis
Stomach	Autolysis (partial)
Thyroid/1	Autolysis (partial)
Thyroid/2	Autolysis (partial)
Urinary bladder	Autolysis (partial)
Diaphragm	MALIGNANT TUMOUR leiomyosarcoma

KWG 0519 - Mouse Chronic Toxicity Study
Full Macro/Micro Report

Rat No: 265
SEX: Female
DOSE LEVEL: 500ppm KWG 0519

MACROSCOPIC FINDINGS

	Mode of death : Interim death
	Days under test : 613
	Date of death : 15/03/80
Condition at necropsy	Autolysis (few organs)
General observations	Increased body girth
Abdominal cavity	Filled with dark red fluid. Adipose tissue increased
Intestine	Reddish contents
Kidney	Left: Flaccid filled with milky fluid
	Right: Surface white-grey areas
Liver	Lob. sin: Soft dark brown nodule (1.4cm diam)
	Portal: Soft dark brown
	nodule (1.5cm diam). Adhesions all lobes
Lung	Increased fluid content
Spleen	Enlarged
Stomach	Mucosal bleeding fundic region

MICROSCOPIC FINDINGS

Bone marrow (femur)	Haematopoiesis (moderate)
Heart	Congestion
Kidney/1	Hydronephrosis (severe)
	MALIGNANT LYMPHOMA
Kidney/2	MALIGNANT LYMPHOMA
Liver	MALIGNANT TUMOUR hepatocellular adenocarcinoma
	Infarct
Lung	Haemorrhage (severe)
	Pneumonia (severe)
Ovary/1	MALIGNANT LYMPHOMA
Ovary/2	MALIGNANT LYMPHOMA
Pancreas	Autolysis (partial)
	Oedema
	Inflammation chronic
Spleen	MALIGNANT LYMPHOMA
Thyroid/1	Autolysis (partial)
Thyroid/2	Autolysis (partial)
Mesentery	MALIGNANT LYMPHOMA

KWG 0519 - Mouse Chronic Toxicity Study
Full Macro/Micro Report

Rat No: 266
SEX: Female
DOSE LEVEL: 500ppm KWG 0519

MACROSCOPIC FINDINGS

	Mode of death : Terminal kill
	Days under test : 735
	Date of death : 15/07/80
Adrenal gland	Left: Enlarged
Liver	Lob. dxtr: Two soft brown nodules
Spleen	Enlarged (1.0 x 3.0cm)

MICROSCOPIC FINDINGS

Adrenal/1	Pigmentation (minimal)
Adrenal/2	Pigmentation (minimal)
Kidney/1	MALIGNANT LYMPHOMA
Kidney/2	MALIGNANT LYMPHOMA
Liver	BENIGN TUMOUR hepatocellular adenoma
	MALIGNANT LYMPHOMA
Lung	MALIGNANT LYMPHOMA
Ovary/1	Atrophy
	Cysts
Pancreas	MALIGNANT LYMPHOMA
Spleen	MALIGNANT LYMPHOMA
Thyroid/1	No tissue available
Thyroid/2	No tissue available
Uterus	Hyperplasia secretory
Lymph node	No tissue available

KWG 0519 - Mouse Chronic Toxicity Study
Full Macro/Micro Report

Rat No: 267
SEX: Female
DOSE LEVEL: 500ppm KWG 0519

MACROSCOPIC FINDINGS

	Mode of death : Terminal kill
	Days under test : 735
	Date of death : 15/07/80
Liver	Reduced in size.
	Portal regions greenish yellow coloured

MICROSCOPIC FINDINGS

Adrenal/1	Pigmentation (moderate)
Adrenal/2	Pigmentation (moderate)
Kidney/1	Interstitial nephritis
Kidney/2	Interstitial nephritis
Liver	MALIGNANT TUMOUR angiosarcoma
	Pigmentation (moderate)
Lung	Pneumonia
Ovary/1	Atrophy
	Cysts
Ovary/2	Atrophy
Pancreas	Inflammation chronic
Spleen	Haematopoiesis (severe)
Thyroid/1	No tissue available
Thyroid/2	No tissue available
Urinary bladder	Inflammation chronic
Uterus	Hyperplasia secretory

KWG 0519 - Mouse Chronic Toxicity Study
Full Macro/Micro Report

Rat No: 268
SEX: Female
DOSE LEVEL: 500ppm KWG 0519

MACROSCOPIC FINDINGS

	Mode of death : Terminal kill
	Days under test : 735
	Date of death : 15/07/80
Ovary	Right: Cysts (1.8cm)

MICROSCOPIC FINDINGS

Brain	Gliosis (minimal)
Kidney/1	Cysts
Liver	Vacuolisation (moderate)
Lung	Pneumonia
Ovary/1	Cysts
	Hypertrophic corpora lutea
Ovary/2	Hypertrophic corpora lutea
Pituitary	No tissue available
Sciatic nerve	No tissue available
Spleen	Haematopoiesis (moderate)
Mesentery	Inflammation chronic

KWG 0519 - Mouse Chronic Toxicity Study
Full Macro/Micro Report

Rat No: 269
SEX: Female
DOSE LEVEL: 500ppm KWG 0519

MACROSCOPIC FINDINGS

	Mode of death : Interim death
	Days under test : 574
	Date of death : 05/02/80
Cranium	Indurated
Femur	Right: White hard nodule (0.4cm diam)
Intestine	Black-brown contents
Ovary	Left: Dark red hard nodule (0.8cm diam)
Stomach	Mucosal bleeding

MICROSCOPIC FINDINGS

Adrenal/1	Hyperplasia glomerulosa
Bone (femur)	Normal
Brain	Fat vacuoles
Kidney/1	Cysts (minimal)
Kidney/2	Cysts (minimal)
Liver	Congestion
Lung	Congestion
	Thickened alveolar walls
Ovary/1	Thrombus
	Haemorrhagic cyst
Pituitary	No tissue available
Thyroid/1	No tissue available
Thyroid/2	No tissue available
Urinary bladder	Autolysis (partial)
Uterus	Hyperplasia secretory
Bone	BENIGN TUMOUR osteoma
Duodenum	Autolysis (partial)

KWG 0519 - Mouse Chronic Toxicity Study
Full Macro/Micro Report

Rat No: 270
SEX: Female
DOSE LEVEL: 500ppm KWG 0519

MACROSCOPIC FINDINGS

	Mode of death : Terminal kill
	Days under test : 735
	Date of death : 15/07/80
Lung	Lob. sin: Thickening (0.3cm diam)
Uterus	Horns thickened (0.6cm diam)

MICROSCOPIC FINDINGS

Kidney/1	Interstitial nephritis (minimal)
Kidney/2	Interstitial nephritis (minimal)
Liver	Vacuolisation (minimal)
Lung	MALIGNANT TUMOUR alveogenic carcinoma
	Pneumonia
Ovary/1	Atrophy
	Haemorrhagic cyst
Ovary/2	Atrophy
Spleen	Haematopoiesis (moderate)
Uterus	Endometriosis

KWG 0519 - Mouse Chronic Toxicity Study
Full Macro/Micro Report

Rat No: 271
SEX: Female
DOSE LEVEL: 500ppm KWG 0519

MACROSCOPIC FINDINGS

Mode of death	: Terminal kill
Days under test	: 735
Date of death	: 15/07/80
Adrenal gland	Right: Enlarged (0.2cm diam)
Liver	Clay coloured
Lung	Flesh coloured
Ovary	Right: Enlarged (0.5cm)
Uterus	Enlarged (0.4cm diam)

MICROSCOPIC FINDINGS

Bone marrow (femur)	Hypoplasia
Liver	BENIGN TUMOUR hepatocellular adenoma
	Vacuolisation
Lung	Pneumonia
Ovary/1	Cysts
Spleen	Haematopoiesis (moderate)
Uterus	No tissue available

KWG 0519 - Mouse Chronic Toxicity Study
Full Macro/Micro Report

Rat No: 272
SEX: Female
DOSE LEVEL: 500ppm KWG 0519

MACROSCOPIC FINDINGS

	Mode of death : Terminal kill
	Days under test : 735
	Date of death : 15/07/80
Ovary	Left: Cysts (0.3cm diam)
Uterus	Horns: Two hard thickenings lower part

MICROSCOPIC FINDINGS

Brain	Meningitis (minimal)
Kidney/1	Tubulopathy
	Interstitial nephritis (minimal)
Kidney/2	Interstitial nephritis (minimal)
Lung	Pneumonia
Ovary/1	Atrophy
	Cysts
Spleen	Haematopoiesis (moderate)
Stomach	Mucoid cyst (minimal)
Uterus	MALIGNANT TUMOUR leiomyosarcoma
	Cystic endometrial hyperplasia (severe)
Mesentery	Inflammation chronic

KWG 0519 - Mouse Chronic Toxicity Study
Full Macro/Micro Report

Rat No: 273
SEX: Female
DOSE LEVEL: 500ppm KWG 0519

MACROSCOPIC FINDINGS

	Mode of death : Terminal kill
	Days under test : 735
	Date of death : 15/07/80
Uterus	Horns: Both thickened (0.5cm diam) multiple cysts (0.5-0.7cm diam)

MICROSCOPIC FINDINGS

Adrenal/1	Pigmentation (severe)
Lung	Haemorrhage
	Pneumonia
Ovary/1	Atrophy
	Cysts
Ovary/2	Atrophy
Spleen	Haematopoiesis (moderate)
Urinary bladder	Hyperplasia papillomatous
Uterus	Endometriosis (moderate)

KWG 0519 - Mouse Chronic Toxicity Study
Full Macro/Micro Report

Rat No: 274
SEX: Female
DOSE LEVEL: 500ppm KWG 0519

MACROSCOPIC FINDINGS

	Mode of death : Interim death
	Days under test : 286
	Date of death : 23/04/79
Condition at necropsy	Autolysis (complete)
	Evaluation not possible

MICROSCOPIC FINDINGS

Adrenal/1	No tissue available
Adrenal/2	No tissue available
Brain	No tissue available
Kidney/1	Autolysis (partial)
Kidney/2	Autolysis (partial)
Liver	Autolysis
Lung	Oedema
	MALIGNANT LYMPHOMA
Ovary/1	Autolysis (partial)
Ovary/2	Autolysis (partial)
Pancreas	Autolysis
Pituitary	No tissue available
Spleen	Autolysis (partial)
	MALIGNANT LYMPHOMA
Stomach	Autolysis
Thyroid/1	Autolysis (partial)
Thyroid/2	Autolysis (partial)
Urinary bladder	Autolysis

KWG 0519 - Mouse Chronic Toxicity Study
Full Macro/Micro Report

Rat No: 275
SEX: Female
DOSE LEVEL: 500ppm KWG 0519

MACROSCOPIC FINDINGS

	Mode of death : Interim death
	Days under test : 658
	Date of death : 29/04/80
Condition at necropsy	Autolysis (few organs)
Lung	Dark/red foci/areas
	Lob. inf. dxtr. lat: White hard nodule (0.2cm diam)
Ovary	Left: Cysts haemorrhagic (1.3cm diam)

MICROSCOPIC FINDINGS

Adrenal/1	Pigmentation (minimal)
Liver	Infarct (severe)
Lung	MALIGNANT TUMOUR alveogenic carcinoma
	Pneumonia
	Congestion
Ovary/1	Atrophy
	Cysts
Ovary/2	Atrophy
Pancreas	No tissue available
Spleen	Haematopoiesis (severe)
Stomach	Haemorrhage
Uterus	Hyperplasia secretory (moderate)

KWG 0519 - Mouse Chronic Toxicity Study
Full Macro/Micro Report

Rat No: 276
SEX: Female
DOSE LEVEL: 500ppm KWG 0519

MACROSCOPIC FINDINGS

	Mode of death : Terminal kill
	Days under test : 735
	Date of death : 15/07/80
Uterus	Horns thickened (0.5cm diam)

MICROSCOPIC FINDINGS

Kidney/1	Interstitial nephritis (minimal)
Kidney/2	Interstitial nephritis (minimal)
Lung	Pneumonia
Ovary/1	Atrophy
Ovary/2	Atrophy
Spleen	Haematopoiesis (minimal)
Thyroid/1	No tissue available
Thyroid/2	No tissue available
Uterus	Endometriosis

KWG 0519 - Mouse Chronic Toxicity Study
Full Macro/Micro Report

Rat No: 277
SEX: Female
DOSE LEVEL: 500ppm KWG 0519

MACROSCOPIC FINDINGS

	Mode of death : Terminal kill
	Days under test : 728
	Date of death : 08/07/80
Cranium	Indurated
Femur	Right: Thickened (1.5 x 1.0cm) white hard
Liver	Enlarged
Lung	Lob. sup. dxtr: Hard beige nodule (0.3cm diam)
Spleen	Enlarged (4.5 x 1.0cm)
Stomach	Mucosal bleeding

MICROSCOPIC FINDINGS

Bone (femur)	BENIGN TUMOUR osteoma
Heart	Congestion
Liver	MALIGNANT LYMPHOMA
Lung	MALIGNANT TUMOUR alveogenic carcinoma
Ovary/1	Atrophy
Ovary/2	Atrophy
Pancreas	MALIGNANT LYMPHOMA
Pituitary	No tissue available
Spleen	MALIGNANT LYMPHOMA
Bone	Normal
Lymph node	MALIGNANT LYMPHOMA

KWG 0519 - Mouse Chronic Toxicity Study
Full Macro/Micro Report

Rat No: 278
SEX: Female
DOSE LEVEL: 500ppm KWG 0519

MACROSCOPIC FINDINGS

	Mode of death : Interim death
	Days under test : 548
	Date of death : 10/01/80
Condition at necropsy	Autolysis (numerous organs)
Intestine	Black-brown contents
Lung	Flesh coloured areas
Spleen	Enlarged (3.2 x 0.5cm)
Stomach	Mucosal bleeding
Uterus	Left horn: Thickened (0.4cm diam)
Mesenteric lymph node	Enlarged

MICROSCOPIC FINDINGS

Brain	No tissue available
Heart	Congestion
Kidney/1	Cysts
	MALIGNANT LYMPHOMA
Kidney/2	MALIGNANT LYMPHOMA
Liver	Autolysis (partial)
	Hypertrophy
	MALIGNANT LYMPHOMA
Lung	Haemorrhage
	Congestion
Pancreas	Autolysis (partial)
Pituitary	No tissue available
Sciatic nerve	No tissue available
Skeletal muscle	No tissue available
Spleen	MALIGNANT LYMPHOMA
Stomach	Normal
Urinary bladder	MALIGNANT LYMPHOMA
Uterus	MALIGNANT TUMOUR mesenchymal tumour
	MALIGNANT LYMPHOMA
Lymph node	MALIGNANT LYMPHOMA
	Crystals
Mesentery	MALIGNANT LYMPHOMA

KWG 0519 - Mouse Chronic Toxicity Study
Full Macro/Micro Report

Rat No: 279
SEX: Female
DOSE LEVEL: 500ppm KWG 0519

MACROSCOPIC FINDINGS

	Mode of death : Terminal kill
	Days under test : 735
	Date of death : 15/07/80
Lung	Lob. dxtr: Enlarged swollen hardened discoloured

MICROSCOPIC FINDINGS

Brain	Fat vacuoles
Lung	MALIGNANT TUMOUR alveogenic carcinoma
Ovary/1	Haemorrhagic cyst
Pancreas	Periarteritis
Spleen	Haematopoiesis (moderate)
Stomach	Mucoid cyst (moderate)
Thyroid/1	No tissue available
Thyroid/2	No tissue available
Urinary bladder	Inflammation chronic (moderate)
Uterus	Endometriosis
	Hyperplasia secretory

KWG 0519 - Mouse Chronic Toxicity Study
Full Macro/Micro Report

Rat No: 280
SEX: Female
DOSE LEVEL: 500ppm KWG 0519

MACROSCOPIC FINDINGS

Mode of death	: Interim death
Days under test	: 499
Date of death	: 22/11/79
Ovary	Enlarged (0.2cm diam), Cysts
Spleen	Enlarged (2.4 x 0.5cm)

MICROSCOPIC FINDINGS

Adrenal/1	Pigmentation (moderate)
Kidney/1	Interstitial nephritis (minimal)
Kidney/2	Interstitial nephritis (minimal)
Liver	Congestion
Lung	Atelectasis
Ovary/1	Atrophy
	Cysts
Ovary/2	Atrophy
	Cysts
Spleen	Haematopoiesis (severe)
	Hypertrophy
Uterus	Hyperplasia polypoid

KWG 0519 - Mouse Chronic Toxicity Study
Full Macro/Micro Report

Rat No: 281
SEX: Female
DOSE LEVEL: 500ppm KWG 0519

MACROSCOPIC FINDINGS

	Mode of death : Terminal kill
	Days under test : 735
	Date of death : 15/07/80
Lung	Flesh coloured
Uterus	Enlarged (0.4cm diam)

MICROSCOPIC FINDINGS

Adrenal/1	Pigmentation (minimal)
Adrenal/2	Pigmentation (minimal)
Kidney/1	Interstitial nephritis
Lung	Thickened alveolar walls
Ovary/1	Hypertrophic corpora lutea
Ovary/2	Hypertrophic corpora lutea
Pituitary	No tissue available
Spleen	Haematopoiesis (minimal)
Uterus	Cystic endometrial hyperplasia (severe)
	Endometriosis (severe)

KWG 0519 - Mouse Chronic Toxicity Study
Full Macro/Micro Report

Rat No: 282
SEX: Female
DOSE LEVEL: 500ppm KWG 0519

MACROSCOPIC FINDINGS

	Mode of death : Interim death
	Days under test : 484
	Date of death : 07/11/79
General observations	Ear injury accumulations of purulent material in the maxillary sinus
Kidney	Surface raised areas and pale areas
Spleen	Enlarged (2.5 x 0.6cm) covered with grey-beige foci
Stomach	Fundic region reddened

MICROSCOPIC FINDINGS

Adrenal/1	Hyperplasia glomerulosa
Brain	Fat vacuoles (minimal)
Heart	Leukocytosis
	Congestion
Kidney/1	MYELOID LEUKAEMIA
Kidney/2	MYELOID LEUKAEMIA
Liver	Mononuclear cells (minimal)
	Congestion
Lung	Oedema (severe)
	Pneumonia (severe)
	Leukocytosis (severe)
	Congestion (severe)
Ovary/1	Atrophy
Ovary/2	Atrophy
Pituitary	Haemorrhage
Spleen	MYELOID LEUKAEMIA
Skin	Necrosis
	Pus

KWG 0519 - Mouse Chronic Toxicity Study
Full Macro/Micro Report

Rat No: 283
SEX: Female
DOSE LEVEL: 500ppm KWG 0519

MACROSCOPIC FINDINGS

	Mode of death : Interim death
	Days under test : 471
	Date of death : 25/10/79
Condition at necropsy	Autolysis (few organs)
Intestine	Reddish contents
Spleen	Reduced in size

MICROSCOPIC FINDINGS

Brain	Congestion
Heart	Congestion
Kidney/1	Congestion
Kidney/2	Congestion
Liver	Congestion
Lung	Congestion
Ovary/1	Atrophy
Ovary/2	Atrophy
Pituitary	No tissue available
Spleen	Normal
Urinary bladder	Autolysis (partial)
Uterus	Cystic endometrial hyperplasia (minimal)

KWG 0519 - Mouse Chronic Toxicity Study
Full Macro/Micro Report

Rat No: 284
SEX: Female
DOSE LEVEL: 500ppm KWG 0519

MACROSCOPIC FINDINGS

	Mode of death : Interim death
	Days under test : 723
	Date of death : 03/07/80
Kidney	Clay coloured
Lung	Grey/black areas
Ovary	Left: Cysts (0.2cm diam)

MICROSCOPIC FINDINGS

Brain	Haemorrhage
Heart	Congestion
	Dilated chamber
Kidney/1	Progressive nephropathy (severe)
Kidney/2	Progressive nephropathy (severe)
Liver	Vacuolisation (minimal)
Lung	MALIGNANT TUMOUR alveogenic carcinoma
Ovary/1	Atrophy
	Cysts
Ovary/2	Atrophy
	Cysts
Spleen	Haematopoiesis (severe)
Mesentery	Haemorrhage

KWG 0519 - Mouse Chronic Toxicity Study
Full Macro/Micro Report

Rat No: 285
SEX: Female
DOSE LEVEL: 500ppm KWG 0519

MACROSCOPIC FINDINGS

Mode of death : Interim death
Days under test : 392
Date of death : 07/08/79
No significant findings noted

MICROSCOPIC FINDINGS

Adrenal/1	Pigmentation (minimal)
Brain	Fat vacuoles (moderate)
Kidney/1	Interstitial nephritis (minimal)
Liver	Mononuclear cells (minimal)
	Congestion
Lung	Congestion
	Thickened alveolar walls
Ovary/1	No tissue available
Ovary/2	No tissue available
Sciatic nerve	No tissue available

KWG 0519 - Mouse Chronic Toxicity Study
Full Macro/Micro Report

Rat No: 296
SEX: Female
DOSE LEVEL: 500ppm KWG 0519

MACROSCOPIC FINDINGS

	Mode of death : Interim death
	Days under test : 679
	Date of death : 20/05/80
Liver	Clay coloured
Lung	Surrounded by blood clots
Ovary	Both: Cysts (Right 1.1cm, Left 0.7cm)
Pituitary	Enlarged (0.3cm diam) pale

MICROSCOPIC FINDINGS

Adrenal/1	Pigmentation (severe)
Adrenal/2	No tissue available
Kidney/1	Fibrosis (minimal)
Liver	Congestion
Lung	Pneumonia (moderate)
Ovary/1	Cysts
Ovary/2	Cysts
Pituitary	BENIGN TUMOUR adenoma
Spleen	Haematopoiesis (moderate)
Urinary bladder	Autolysis (partial)

KWG 0519 - Mouse Chronic Toxicity Study
Full Macro/Micro Report

Rat No: 267
SEX: Female
DOSE LEVEL: 500ppm KWG 0519

MACROSCOPIC FINDINGS

	Mode of death : Interim death
	Days under test : 434
	Date of death : 19/09/79
Condition at necropsy	Autolysis (few organs)
Adrenal gland	Enlarged (0.2-0.3cm diam)
Liver	Enlarged
Lung	Fleshy
Ovary	Left: Dark soft nodule (0.7cm diam)
Spleen	Enlarged (3.6 x 1.0cm)
Uterus	Right horn: Thickened soft (0.7cm diam)

MICROSCOPIC FINDINGS

Adrenal/1	Haematopoiesis (minimal)
Heart	Congestion
Kidney/1	Autolysis (partial)
	MALIGNANT LYMPHOMA
Kidney/2	Autolysis (partial)
	MALIGNANT LYMPHOMA
Liver	Autolysis (partial)
	MALIGNANT LYMPHOMA
Lung	Autolysis (partial)
	MALIGNANT TUMOUR alveogenic carcinoma
	Oedema
Ovary/1	Cysts
Ovary/2	MALIGNANT LYMPHOMA
Pancreas	No tissue available
Spleen	MALIGNANT LYMPHOMA
Stomach	Autolysis
Urinary bladder	Autolysis
Uterus	Autolysis (partial)
	MALIGNANT LYMPHOMA
Lymph node	MALIGNANT LYMPHOMA
	Autolysis (partial)

KWG 0519 - Mouse Chronic Toxicity Study
Full Macro/Micro Report

Rat No: 288
SEX: Female
DOSE LEVEL: 500ppm KWG 0519

MACROSCOPIC FINDINGS

	Mode of death : Interim death
	Days under test : 712
	Date of death : 22/06/80
Condition at necropsy	Autolysis (few organs)
Adrenal gland	Left: Enlarged
Lung	Flesh coloured
Spleen	Enlarged (4.2 x 0.8)

MICROSCOPIC FINDINGS

Adrenal/1	MALIGNANT LYMPHOMA
Adrenal/2	MALIGNANT LYMPHOMA
Brain	Fat vacuoles
Kidney/1	MALIGNANT LYMPHOMA
Kidney/2	MALIGNANT LYMPHOMA
Liver	MALIGNANT LYMPHOMA
Lung	MALIGNANT TUMOUR alveogenic carcinoma
Ovary/1	Atrophy
	Haemorrhagic cyst
Ovary/2	Atrophy
Pancreas	Autolysis
Sciatic nerve	No tissue available
Spleen	Autolysis (partial)
	Haemorrhage
	MALIGNANT LYMPHOMA
Stomach	Autolysis (partial)
Urinary bladder	Autolysis (partial)
Uterus	MALIGNANT LYMPHOMA
Lymph node	MALIGNANT LYMPHOMA
Mesentery	MALIGNANT LYMPHOMA

KWG 0519 - Mouse Chronic Toxicity Study
Full Macro/Micro Report

Rat No: 299
SEX: Female
DOSE LEVEL: 500ppm KWG 0519

MACROSCOPIC FINDINGS

Mode of death	: Interim death
Days under test	: 679
Date of death	: 20/05/80
Abdominal cavity	Adipose tissue hard yellowish discolouration
Adrenal gland	Clay coloured
Kidney	Clay coloured
Liver	Clay coloured
Lung	Dark/red foci/areas
Ovary	Left: Cysts (0.6cm diam)
Spleen	Enlarged (2.6 x 0.5)

MICROSCOPIC FINDINGS

Adrenal/1	Pigmentation (moderate)
Heart	Inflammation chronic
	Pericarditis
Liver	BENIGN TUMOUR hepatocellular adenoma
Lung	MALIGNANT LYMPHOMA
Ovary/1	Atrophy
	Cysts
Ovary/2	Atrophy
Pancreas	MALIGNANT LYMPHOMA
Pituitary	No tissue available
Sciatic nerve	No tissue available
Spleen	Autolysis (partial)
	MALIGNANT LYMPHOMA
Stomach	MALIGNANT LYMPHOMA
Urinary bladder	Autolysis (partial)
Lymph node	MALIGNANT LYMPHOMA
Mesentery	MALIGNANT LYMPHOMA

KWG 0519 - Mouse Chronic Toxicity Study
Full Macro/Micro Report

Rat No: 290
SEX: Female
DOSE LEVEL: 500ppm KWG 0519

MACROSCOPIC FINDINGS

	Mode of death : Interim death
	Days under test : 622
	Date of death : 24/03/80
Cranium	Indurated
Lung	Lob. sin: Flesh coloured
	Lob. dxtr: Red foci
Spleen	Enlarged (3.5 x 1.2cm)
Thymus	Hard beige nodule (1.0cm diam)

MICROSCOPIC FINDINGS

Adrenal/1	Pigmentation (minimal)
Adrenal/2	Pigmentation (minimal)
Kidney/1	Interstitial nephritis (minimal)
Liver	MALIGNANT LYMPHOMA
Lung	MALIGNANT TUMOUR alveogenic carcinoma
	Pneumonia
Ovary/1	Atrophy
	Cysts
Ovary/2	Atrophy
Pancreas	Autolysis (partial)
	Vacuolisation (minimal)
Spleen	Hyperplasia lymphoid
	Haematopoiesis (severe)
Stomach	Mucoid cyst (minimal)
Bone	BENIGN TUMOUR osteoma
Thymus	MALIGNANT TUMOUR Thymoma
	Necrosis

KWG 0519 - Mouse Chronic Toxicity Study
Full Macro/Micro Report

Rat No: 291
SEX: Female
DOSE LEVEL: 500ppm KWG 0519

MACROSCOPIC FINDINGS

	Mode of death : Terminal kill
	Days under test : 735
	Date of death : 15/07/80
Adrenal gland	Left: Enlarged
Ovary	Right: Cysts (0.6 and 0.3cm diam)
Spleen	Enlarged (2.2 x 0.8cm) white grey areas (0.7cm diam)

MICROSCOPIC FINDINGS

Adrenal/1	Pigmentation (minimal)
	Hyperplasia glomerulosa (moderate)
Kidney/1	Cysts (minimal)
Lung	Atelectasis
Ovary/1	Cysts
Spleen	MALIGNANT LYMPHOMA
Thyroid/1	No tissue available
Thyroid/2	No tissue available
Urinary bladder	MALIGNANT LYMPHOMA
Lymph node	Hypertrophy

KWG 0519 - Mouse Chronic Toxicity Study
Full Macro/Micro Report

Rat No: 292
SEX: Female
DOSE LEVEL: 500ppm KWG 0519

MACROSCOPIC FINDINGS

	Mode of death : Interim death
	Days under test : 595
	Date of death : 26/02/80
Spleen	Enlarged (2.5 x 0.5cm)
Tail	Skin inflamed at base

MICROSCOPIC FINDINGS

Bone (femur)	Inflammation chronic
Heart	Congestion
Kidney/1	Interstitial nephritis (minimal)
Kidney/2	Interstitial nephritis (minimal)
Liver	Mononuclear cells (minimal)
Ovary/1	BENIGN TUMOUR luteoma
Ovary/2	Atrophy
	Cysts
Spleen	Haematopoiesis (severe)
Urinary bladder	Unreadable
Skin	Inflammation chronic (moderate)
	Fibrosis

KWG 0519 - Mouse Chronic Toxicity Study
Full Macro/Micro Report

Rat No: 293
SEX: Female
DOSE LEVEL: 500ppm KWG 0519

MACROSCOPIC FINDINGS

	Mode of death : Interim death
	Days under test : 70
	Date of death : 19/09/78
Condition at necropsy	Autolysis (few organs)
Stomach	Mucosal bleeding

MICROSCOPIC FINDINGS

Heart	Congestion
Kidney/1	Autolysis (partial)
Kidney/2	Autolysis (partial)
Liver	Congestion
Lung	Haemorrhage
	Congestion
Pancreas	Autolysis (partial)
Spleen	Haematopoiesis (minimal)
Stomach	Autolysis (partial)
Thyroid/1	No tissue available
Thyroid/2	No tissue available
Urinary bladder	Autolysis (partial)
Thymus	MALIGNANT LYMPHOMA

KWG 0519 - Mouse Chronic Toxicity Study
Full Macro/Micro Report

Rat No: 294
SEX: Female
DOSE LEVEL: 500ppm KWG 0519

MACROSCOPIC FINDINGS

	Mode of death : Interim death
	Days under test : 551
	Date of death : 13/01/80
Condition at necropsy	Autolysis (few organs)
Intestine	Black-brown contents
Stomach	Haemorrhagic contents mucosal bleeding

MICROSCOPIC FINDINGS

Brain	No tissue available
Kidney/1	Autolysis (partial)
	MALIGNANT LYMPHOMA
Kidney/2	Autolysis (partial)
	MALIGNANT LYMPHOMA
Liver	Autolysis (partial)
	MALIGNANT LYMPHOMA
Lung	Oedema
	Leukocytosis
Ovary/1	Autolysis (partial)
Ovary/2	Autolysis (partial)
Pancreas	Autolysis
Spleen	Autolysis (partial)
	MALIGNANT LYMPHOMA
Stomach	Autolysis (partial)
Thyroid/1	No tissue available
Thyroid/2	No tissue available
Urinary bladder	Autolysis (partial)
Mesentery	MALIGNANT LYMPHOMA

KWG 0519 - Mouse Chronic Toxicity Study
Full Macro/Micro Report

Rat No: 295
SEX: Female
DOSE LEVEL: 500ppm KWG 0519

MACROSCOPIC FINDINGS

	Mode of death : Terminal kill
	Days under test : 735
	Date of death : 15/07/80
Ovary	Left: Cysts (0.5cm) red fluid filled

MICROSCOPIC FINDINGS

Liver	Vacuolisation (minimal)
Lung	Pneumonia
Ovary/1	Cysts
Sciatic nerve	No tissue available
Spleen	Haematopoiesis (moderate)
Thyroid/1	No tissue available
Thyroid/2	No tissue available
Uterus	Cystic endometrial hyperplasia

KWG 0519 - Mouse Chronic Toxicity Study
Full Macro/Micro Report

Rat No: 296
SEX: Female
DOSE LEVEL: 500ppm KWG 0519

MACROSCOPIC FINDINGS

	Mode of death : Terminal kill
	Days under test : 735
	Date of death : 15/07/80
Lung	Lob. dxtr: Thickening (0.8cm diam)
Ovary	Left: Cysts (1.0 and 0.4cm diam) yellow fluid filled
Uterus	Horns thickened (0.5cm diam)

MICROSCOPIC FINDINGS

Adrenal/1	Pigmentation (severe)
	Fat vacuoles
Adrenal/2	Pigmentation (severe)
Kidney/1	Cysts (minimal)
Lung	MALIGNANT TUMOUR alveogenic carcinoma
	Pneumonia
Ovary/1	BENIGN TUMOUR luteoma
Ovary/2	Cysts
Spleen	Haematopoiesis (moderate)
Thyroid/1	No tissue available
Thyroid/2	No tissue available
Uterus	Cystic endometrial hyperplasia (severe)

KWG 0519 - Mouse Chronic Toxicity Study
Full Macro/Micro Report

Rat No: 297
SEX: Female
DOSE LEVEL: 500ppm KWG 0519

MACROSCOPIC FINDINGS

Condition at necropsy	Mode of death : Interim death Days under test : 545 Date of death : 07/01/80 Autolysis (complete) Evaluation not possible

MICROSCOPIC FINDINGS

Adrenal/1	Autolysis
Adrenal/2	Autolysis
Brain	Autolysis
Heart	Congestion
Kidney/1	Autolysis (partial)
Kidney/2	Autolysis (partial)
Liver	Autolysis
Lung	Autolysis
Ovary/1	Autolysis
Ovary/2	Autolysis
Pancreas	Autolysis
Pituitary	Autolysis
Spleen	Autolysis
Stomach	Autolysis
Thyroid/1	No tissue available
Thyroid/2	No tissue available
Urinary bladder	Autolysis

KWG 0519 - Mouse Chronic Toxicity Study
Full Macro/Micro Report

Rat No: 298
SEX: Female
DOSE LEVEL: 500ppm KWG 0519

MACROSCOPIC FINDINGS

	Mode of death : Interim death
	Days under test : 569
	Date of death : 31/01/80
Abdominal cavity	8ml milky opaque fluid
Lung	Flesh coloured
Spleen	Enlarged (2.2 x 0.6)
Thoracic cavity	3ml milky-opaque fluid
Diaphragm	Soft beige covering

MICROSCOPIC FINDINGS

Kidney/1	Tubulopathy (severe)
Kidney/2	Tubulopathy (severe)
Liver	MALIGNANT LYMPHOMA
Lung	MALIGNANT TUMOUR alveogenic carcinoma
	Pneumonia
Ovary/1	Cysts
Pancreas	MALIGNANT LYMPHOMA
Pituitary	No tissue available
Skeletal muscle	MALIGNANT LYMPHOMA
Spleen	Normal
Thyroid/1	No tissue available
Thyroid/2	No tissue available
Diaphragm	MALIGNANT LYMPHOMA
Lymph node	MALIGNANT LYMPHOMA
Mesentery	MALIGNANT LYMPHOMA

KWG 0519 - Mouse Chronic Toxicity Study
Full Macro/Micro Report

Rat No: 300
SEX: Female
DOSE LEVEL: 500ppm KWG 0519

MACROSCOPIC FINDINGS

	Mode of death : Interim death
	Days under test : 713
	Date of death : 23/06/80
Condition at necropsy	Autolysis (few organs)
Lung	Dark/red coloured
	Lob. sup. dxtr: Enlarged hard white - grey-red

MICROSCOPIC FINDINGS

Adrenal/1	Pigmentation (moderate)
Adrenal/2	Pigmentation (moderate)
Brain	Gliosis (minimal)
Heart	Congestion
Kidney/1	Congestion
Kidney/2	Congestion
Liver	Congestion
Lung	MALIGNANT TUMOUR alveogenic carcinoma
Ovary/1	Haemorrhage
	Atrophy
Ovary/2	Haemorrhage
	Atrophy
Pituitary	No tissue available
Urinary bladder	Autolysis (partial)

KWG 0519 - Mouse Chronic Toxicity Stuay
Full Macro/Micro Report

Rat No: 301
SEX: Male
DOSE LEVEL: 2000ppm KWG 0519

MACROSCOPIC FINDINGS

	Mode of death : Interim death
	Days under test : 727
	Date of death : 07/07/80
Adrenal gland	Enlarged
Condition at necropsy	Died after taking blood
Kidney	Left: Enlarged soft discoloured isolated red areas
Spleen	Enlarged (3.6 x 0.9cm)

MICROSCOPIC FINDINGS

Adrenal/1	MALIGNANT LYMPHOMA
Adrenal/2	MALIGNANT LYMPHOMA
Heart	MALIGNANT LYMPHOMA
Kidney/1	MALIGNANT LYMPHOMA
Kidney/2	MALIGNANT LYMPHOMA
Liver	MALIGNANT LYMPHOMA
Lung	MALIGNANT TUMOUR alveogenic carcinoma
Pancreas	MALIGNANT LYMPHOMA
Pituitary	No tissue available
Spleen	MALIGNANT LYMPHOMA
Stomach	Unreadable
Testis/1	Atrophy seminiferous tubules (moderate)
	Calcification (moderate)
	Spermatocoele (moderate)
Testis/2	Atrophy seminiferous tubules (moderate)
Thyroid/1	No tissue available
Thyroid/2	No tissue available
Lymph node	MALIGNANT LYMPHOMA

KWG 0519 - Mouse Chronic Toxicity Study
Full Macro/Micro Report

Rat No: 302
SEX: Male
DOSE LEVEL: 2000ppm KWG 0519

MACROSCOPIC FINDINGS

	Mode of death : Interim death
	Days under test : 639
	Date of death : 10/04/80
Liver	Enlarged
	Light coloured foci
Stomach	Mucosal bleeding

MICROSCOPIC FINDINGS

Adrenal/1	No tissue available
Adrenal/2	No tissue available
Bone (femur)	No tissue available
Heart	Congestion
Kidney/1	Interstitial nephritis (minimal)
	Cysts (minimal)
Kidney/2	Interstitial nephritis (minimal)
	Cysts (minimal)
Liver	BENIGN TUMOUR hepatocellular adenoma
	Calcification (moderate)
	Congestion (severe)
	Hyalinosis
	Hepatocytic hyperpigmentation
Lung	BENIGN TUMOUR fibroma
Pancreas	Inflammation chronic (minimal)
Pituitary	No tissue available
Sciatic nerve	No tissue available
Seminal vesicle	Atrophy epithelial
	Coagulum
Skeletal muscle	No tissue available
Spleen	Haematopoiesis (severe)
Stomach	Haemorrhage (minimal)
Thyroid/1	Cysts
Thyroid/2	Cysts

KWG 3519 - Mouse Chronic Toxicity Study
Full Macro/Micro Report

Rat No: 303
SEX: Male
DOSE LEVEL: 2000ppm KWG 0519

MACROSCOPIC FINDINGS

Mode of death	: Interim death
Days under test	: 377
Date of death	: 23/07/79
Condition at necropsy	Moribund
Kidney	Filled with blood
Liver	Filled with blood
Lung	Filled with blood
Neck and thoracic region	Right side of thorax skin inflamed
Spleen	Enlarged (2.7 x 0.6cm)

MICROSCOPIC FINDINGS

Heart	Congestion (moderate)
Kidney/1	Tubulopathy (moderate)
	Interstitial nephritis (minimal)
Kidney/2	Tubulopathy (moderate)
	Interstitial nephritis (minimal)
Liver	Congestion
Lung	Oedema
	Congestion (severe)
Spleen	Haematopoiesis (severe)
Testis/1	Spermatocoele (moderate)
Urinary bladder	Unreadable
Skin	Inflammation chronic (moderate)

KWG 0519 - Mouse Chronic Toxicity Study
Full Macro/Micro Report

Rat No: 304
SEX: Male
DOSE LEVEL: 2000ppm KWG 0519

MACROSCOPIC FINDINGS

	Mode of death	: Interim death
	Days under test	: 638
	Date of death	: 09/04/80
Condition at necropsy	Moribund	
	No significant findings noted	

MICROSCOPIC FINDINGS

Bone (femur)	No tissue available
Heart	Fibrosis (moderate)
	Mononuclear cells (moderate)
Kidney/1	Interstitial nephritis (minimal)
Pituitary	No tissue available
Sciatic nerve	No tissue available
Skeletal muscle	No tissue available
Thyroid/1	No tissue available
Thyroid/2	No tissue available

KWG 0519 - Mouse Chronic Toxicity Study
Full Macro/Micro Report

Rat No: 305
SEX: Male
DOSE LEVEL: 2000ppm KWG 0519

MACROSCOPIC FINDINGS

	Mode of death : Interim death
	Days under test : 369
	Date of death : 15/07/80
Condition at necropsy	Autolysis (few organs)
Lung	Disintegrated not available, Greenish glossy pleura

MICROSCOPIC FINDINGS

Adrenal/1	Autolysis (partial)
Adrenal/2	Autolysis (partial)
Brain	Autolysis (partial)
Heart	Autolysis (partial)
Kidney/1	Autolysis
Kidney/2	Autolysis
Liver	Autolysis
Lung	No tissue available
Pancreas	Autolysis
Pituitary	No tissue available
Spleen	Autolysis
Stomach	Autolysis
Thyroid/1	No tissue available
Thyroid/2	No tissue available
Urinary bladder	Autolysis (partial)

KWG 0519 - Mouse Chronic Toxicity Study
Full Macro/Micro Report

Rat No: 306
SEX: Male
DOSE LEVEL: 2000ppm KWG 0519

MACROSCOPIC FINDINGS

	Mode of death : Terminal kill
	Days under test : 734
	Date of death : 14/07/80
Kidney	Surface raised areas
Liver	Lob. dxtr: Beige brown nodular mass
Lung	Lob. sup. dxtr: White hard nodule (0.5 x 0.4cm)

MICROSCOPIC FINDINGS

Kidney/1	Interstitial nephritis (minimal)
	Cysts (moderate)
Kidney/2	Interstitial nephritis (minimal)
	Cysts (moderate)
Liver	BENIGN TUMOUR hepatocellular adenoma
	Hyperplasia
	Vacuolisation (severe)
Lung	MALIGNANT TUMOUR alveogenic carcinoma
Spleen	Haematopoiesis (severe)
Thyroid/1	No tissue available
Thyroid/2	No tissue available

KWG 0519 - Mouse Chronic Toxicity Study
Full Macro/Micro Report

Rat No: 307
SEX: Male
DOSE LEVEL: 2000ppm KWG 0519

MACROSCOPIC FINDINGS

	Mode of death : Interim death
	Days under test : 639
	Date of death : 10/04/80
Condition at necropsy	Moribund
Kidney	Left: Surface raised areas
	Right: Pale
Spleen	Marbled surface

MICROSCOPIC FINDINGS

Adrenal/1	Amyloid
Adrenal/2	Amyloid
Bone (femur)	No tissue available
Heart	Fibrosis (minimal)
	Mononuclear cells (minimal)
Kidney/1	Amyloid
	Interstitial nephritis (moderate)
Kidney/2	Amyloid
	Interstitial nephritis (moderate)
Liver	Amyloid
	Hyperplasia focal
Pancreas	Amyloid
Pituitary	No tissue available
Sciatic nerve	No tissue available
Skeletal muscle	No tissue available
Spleen	Hyperplasia lymphoid
	Amyloid
Thyroid/1	No tissue available
Thyroid/2	No tissue available

KWG 0519 - Mouse Chronic Toxicity Study
Full Macro/Micro Report

Rat No: 308
SEX: Male
DOSE LEVEL: 2000ppm KWG 0519

MACROSCOPIC FINDINGS

	Mode of death : Terminal kill
	Days under test : 734
	Date of death : 14/07/80
Kidney	Cysts (0.1-0.3cm diam)
Liver	Proc. pap: Swollen enlarged
	Lob. caud: Thickened white foci
Lung	White foci (0.2-0.3cm diam)

MICROSCOPIC FINDINGS

Adrenal/1	BENIGN TUMOUR phaeochromocytoma
Kidney/1	Cysts (minimal)
Kidney/2	Cysts (minimal)
Liver	Hyperplasia
	Mononuclear cells
	Hyperplastic nodules
Lung	MALIGNANT TUMOUR alveogenic carcinoma
Testis/1	Calcification (minimal)
Thyroid/1	Cysts

KWG 0519 - Mouse Chronic Toxicity Study
Full Macro/Micro Report

Rat No: 309
SEX: Male
DOSE LEVEL: 2000ppm KWG 0519

MACROSCOPIC FINDINGS

Mode of death : Interim death
Days under test : 627
Date of death : 29/03/80

Condition at necropsy	
Kidney	Autolysis (few organs)
Lung	Left: Enlarged, marbled surface
Spleen	Dark/red foci/areas
Urinary bladder	Enlarged (2.6 x 0.6cm)
	Enlarged (1.2cm diam)

MICROSCOPIC FINDINGS

Heart	Thrombosis
Kidney/1	MYELOID LEUKAEMIA
Kidney/2	MYELOID LEUKAEMIA
Liver	Congestion
	MYELOID LEUKAEMIA
Lung	Pneumonia (severe)
	Congestion (severe)
Pancreas	Autolysis
Spleen	MYELOID LEUKAEMIA
Thyroid/1	No tissue available
Thyroid/2	No tissue available
Urinary bladder	Necrosis
	MYELOID LEUKAEMIA

KWG 0519 - Mouse Chronic Toxicity Study
Full Macro/Micro Report

Rat No: 310
SEX: Male
DOSE LEVEL: 2000ppm KWG 0519

MACROSCOPIC FINDINGS

	Mode of death : Terminal kill
	Days under test : 734
	Date of death : 14/07/80
Liver	Swollen/enlarged/hardened
Lung	Lob. sup. dxtr: White nodule (0.3cm diam)
Pancreas	Hardened

MICROSCOPIC FINDINGS

Kidney/1	Interstitial nephritis (minimal)
	Cysts (minimal)
Kidney/2	Cysts (minimal)
Liver	Hyperplasia
	Calcification (severe)
	Mononuclear cells
	Hyperolastic nodules
Lung	MALIGNANT TUMOUR alveogenic carcinoma
Pancreas	Normal
Pituitary	No tissue available
Spleen	Haematopoiesis (severe)
Thyroid/1	No tissue available
Thyroid/2	No tissue available
Urinary bladder	Hyperplasia papillomatous

KWG 0519 - Mouse Chronic Toxicity Study
Full Macro/Micro Report

Rat No: 311
SEX: Male
DOSE LEVEL: 2000ppm KWG 0519

MACROSCOPIC FINDINGS

Mode of death : Interim death
Days under test : 331
Date of death : 07/06/79
No significant findings noted

MICROSCOPIC FINDINGS

Brain	Autolysis (partial)
Heart	Congestion
Kidney/1	Autolysis (partial) Congestion (moderate)
Kidney/2	Autolysis (partial) Congestion (moderate)
Lung	Congestion
Pituitary	No tissue available
Sciatic nerve	No tissue available
Stomach	Autolysis (partial)
Urinary bladder	Autolysis (partial)

KWG 0519 - Mouse Chronic Toxicity Study
Full Macro/Micro Report

Rat No: 312
SEX: Male
DOSE LEVEL: 2000ppm KWG 0519

MACROSCOPIC FINDINGS

	Mode of death : Terminal kill
	Days under test : 734
	Date of death : 14/07/80
Kidney	Surface raised areas

MICROSCOPIC FINDINGS

Kidney/1	Interstitial nephritis (moderate)
	Cysts (moderate)
Kidney/2	Interstitial nephritis (moderate)
Lung	Atelectasis
Pituitary	No tissue available
Spleen	Haematopoiesis (moderate)
Testis/1	Calcification (severe)
	Spermatocoele
Urinary bladder	Hyperplasia papillomatous

KWG 0519 - Mouse Chronic Toxicity Study
Full Macro/Micro Report

Rat No: 313
SEX: Male
DOSE LEVEL: 2000ppm KWG 0519

MACROSCOPIC FINDINGS

	Mode of death : Interim death
	Days under test : 720
	Date of death : 30/06/80
Liver	Enlarged
Lung	Enlarged
Spleen	Lob. inf. extr. lat: Enlarged white hard Marbled surface

MICROSCOPIC FINDINGS

Kidney/1	Cysts (moderate)
Kidney/2	Cysts (moderate)
Liver	Hyperplastic nodules
Lung	MALIGNANT TUMOUR alveogenic carcinoma
Pituitary	Unreadable
Spleen	Normal
Testis/1	Atrophy seminiferous tubules (moderate) Spermatocoele (minimal)
Testis/2	Atrophy seminiferous tubules (moderate)

KWG 0519 - Mouse Chronic Toxicity Study
Full Macro/Micro Report

Rat No: 314
SEX: Male
DOSE LEVEL: 2000ppm KWG 0519

MACROSCOPIC FINDINGS

	Mode of death : Interim death
	Days under test : 594
	Date of death : 25/02/80
Condition at necropsy	Autolysis (complete)
	Evaluation not possible

MICROSCOPIC FINDINGS

Adrenal/1	Autolysis
Adrenal/2	Autolysis
Bone (femur)	Autolysis (partial)
Heart	Autolysis (partial)
Kidney/1	Autolysis (partial)
Kidney/2	Autolysis (partial)
Liver	Autolysis
Lung	Autolysis (partial)
Pancreas	Autolysis
Pituitary	No tissue available
Sciatic nerve	Autolysis (partial)
Skeletal muscle	Autolysis (partial)
Spleen	Autolysis
Stomach	Autolysis
Testis/1	Autolysis (partial)
	Spermatocoele (minimal)
Testis/2	Autolysis (partial)
Thyroid/1	No tissue available
Thyroid/2	No tissue available
Urinary bladder	Autolysis
Unidentified tissue	Unreadable

KWG 0519 - Mouse Chronic Toxicity Study
Full Macro/Micro Report

Rat No: 315
SEX: Male
DOSE LEVEL: 2000ppm KWG 0519

MACROSCOPIC FINDINGS

	Mode of death : Terminal kill
	Days under test : 734
	Date of death : 14/07/80
Kidney	Cysts (0.1-0.2cm) surface raised areas
Liver	Lob. caud: Enlarged/nodular

MICROSCOPIC FINDINGS

Adrenal/1	BENIGN TUMOUR cortical adenoma
Kidney/1	Hydronephrosis
	Interstitial nephritis (minimal)
	Cysts (severe)
Kidney/2	Interstitial nephritis (minimal)
	Cysts (severe)
Liver	BENIGN TUMOUR hepatocellular adenoma
	Hyperplastic nodules
Stomach	Mucoid cyst (moderate)
Thyroid/1	Cysts

KWG 0519 - Mouse Chronic Toxicity Study
Full Macro/Micro Report

Rat No: 316
SEX: Male
DOSE LEVEL: 2000ppm KWG 0519

MACROSCOPIC FINDINGS

	Mode of death : Interim death
	Days under test : 642
	Date of death : 13/04/80
General observations	All organs haemorrhagic
Liver	Enlarged/soft
Lung	Flesh coloured

MICROSCOPIC FINDINGS

Kidney/1	Interstitial nephritis (moderate)
	Progressive nephropathy (severe)
Kidney/2	Interstitial nephritis (moderate)
	Progressive nephropathy (severe)
Liver	Necrosis (minimal)
	Haemorrhage (moderate)
	Hepatocytic hyperpigmentation
	Hyperplastic nodules
Lung	Oedema (moderate)
	Pneumonia (moderate)
Pancreas	Congestion (severe)
Pituitary	No tissue available
Spleen	Pigmentation
Thyroid/1	Cysts
Thyroid/2	Cysts
Urinary bladder	Inflammation chronic (severe)

KWG 0519 - Mouse Chronic Toxicity Study
Full Macro/Micro Report

Rat No: 317
SEX: Male
DOSE LEVEL: 2000ppm KWG 0519

MACROSCOPIC FINDINGS

	Mode of death : Interim death
	Days under test : 219
	Date of death : 15/02/79
Condition at necropsy	Moribund
General observations	Loss of hair and inflammation of skin from right posterior limb over right abdomen up to thorax. Right posterior limb adherent to abdominal skin
Liver	White areas
Spleen	Enlarged (3.3 x 0.7cm)

MICROSCOPIC FINDINGS

Kidney/1	Interstitial nephritis (minimal)
Kidney/2	Interstitial nephritis (minimal)
Liver	Amyloid (moderate)
Skeletal muscle	Oedema (moderate)
	Mononuclear cells (minimal)
Spleen	Hyperplasia lymphoid
Bone marrow	Hyperplasia
Skin	Necrosis (severe) Mononuclear cells (severe)

KWG 0519 - Mouse Chronic Toxicity Study
Full Macro/Micro Report

Rat No: 318
SEX: Male
DOSE LEVEL: 2000ppm KWG 0519

MACROSCOPIC FINDINGS

	Mode of death : Interim death
	Days under test : 675
	Date of death : 16/05/80
Condition at necropsy	Autolysis (few organs)
General observations	Obese
Lung	Dark foci/areas

MICROSCOPIC FINDINGS

Adrenal/1	Unreadable
Adrenal/2	Unreadable
Brain	Autolysis (partial)
Heart	Congestion
Kidney/1	Congestion (moderate)
Kidney/2	Congestion (moderate)
Liver	Congestion (severe)
Lung	Congestion (moderate)
Pancreas	Autolysis
Pituitary	No tissue available
Spleen	Autolysis (partial)
	Atrophy
Stomach	Autolysis
Urinary bladder	Autolysis

KWG 0519 - Mouse Chronic Toxicity Study
Full Macro/Micro Report

Rat No: 319
SEX: Male
DOSE LEVEL: 2000ppm KWG 0519

MACROSCOPIC FINDINGS

	Mode of death : Interim death
	Days under test : 644
	Date of death : 15/04/80
Condition at necropsy	Autolysis (few organs)
Liver	Enlarged
	Discoloured
Lung	Dark foci/areas

MICROSCOPIC FINDINGS

Heart	Mononuclear cells (minimal)
	Congestion
Kidney/1	Congestion (moderate)
	Tubulopathy (moderate)
	Dilatation renal pelvis
Kidney/2	Congestion (moderate)
	Tubulopathy (moderate)
Liver	BENIGN TUMOUR hepatocellular adenoma
	Amyloid (moderate)
Lung	Oedema
	Congestion (severe)
Pancreas	Autolysis (partial)
Pituitary	No tissue available
Urinary bladder	Autolysis (partial)
	Unreadable

KWG 0519 - Mouse Chronic Toxicity Study
Full Macro/Micro Report

Rat No: 320
SEX: Male
DOSE LEVEL: 2000ppm KWG 0519

MACROSCOPIC FINDINGS

	Mode of death : Interim death
	Days under test : 576
	Date of death : 07/02/80
Intestine	Red-brown contents
Liver	Enlarged
Stomach	Mucosal bleeding

MICROSCOPIC FINDINGS

Heart	Congestion
Liver	BENIGN TUMOUR hepatocellular adenoma
	Calcification
	Haemorrhage (severe)
	Amyloid
	Hepatocytic hyperpigmentation
Lung	MALIGNANT TUMOUR alveogenic carcinoma
Sciatic nerve	No tissue available
Skeletal muscle	No tissue available
Stomach	Normal
Testis/1	Calcification (moderate)
Urinary bladder	MALIGNANT TUMOUR carcinosarcoma
Intestine	Haemorrhage (minimal)

KWG 0519 - Mouse Chronic Toxicity Study
Full Macro/Micro Report

Rat No: 321
SEX: Male
DOSE LEVEL: 2000ppm KWG 0519

MACROSCOPIC FINDINGS

	Mode of death : Interim death
	Days under test : 369
	Date of death : 15/07/79
Condition at necropsy	Autolysis (numerous organs)
Spleen	Enlarged (3.0 x 0.6cm)
Thymus	Hard grey nodule (1.1cm diam)

MICROSCOPIC FINDINGS

Adrenal/1	Autolysis (partial)
	MALIGNANT LYMPHOMA
Adrenal/2	Autolysis (partial)
	MALIGNANT LYMPHOMA
Brain	No tissue available
Kidney/1	Autolysis (partial)
	MALIGNANT LYMPHOMA
Kidney/2	Autolysis (partial)
	MALIGNANT LYMPHOMA
Liver	Autolysis (partial)
	MALIGNANT LYMPHOMA
Lung	Autolysis (partial)
	MALIGNANT LYMPHOMA
Pancreas	Autolysis
Pituitary	Autolysis
	Haemorrhage no data
Spleen	Autolysis (partial)
	MALIGNANT LYMPHOMA
Stomach	Autolysis
Thyroid/1	Autolysis
Thyroid/2	Autolysis
Urinary bladder	Autolysis
Mesentery	MALIGNANT LYMPHOMA
Thymus	MALIGNANT LYMPHOMA

KWG 0519 - Mouse Chronic Toxicity Study
Full Macro/Micro Report

Rat No: 322
SEX: Male
DOSE LEVEL: 2000ppm KWG 0519

MACROSCOPIC FINDINGS

	Mode of death : Terminal kill
	Days under test : 734
	Date of death : 14/07/80
Kidney	Left: Cysts (0.1cm diam)
Lung	Red foci
Seminal vesicle	Enlarged (4.0 x 2.0cm)

MICROSCOPIC FINDINGS

Kidney/1	Interstitial nephritis (minimal)
Kidney/2	Interstitial nephritis (minimal)
Lung	Congestion
Pancreas	Fibrosis (minimal)
Pituitary	No tissue available
Seminal vesicle	Atrophy epithelial
	Ectasia simple
	Coagulum
Spleen	Haematopoiesis (moderate)
Urinary bladder	MALIGNANT TUMOUR carcinosarcoma

KWG 0519 - Mouse Chronic Toxicity Study
Full Macro/Micro Report

Rat No: 323
SEX: Male
DOSE LEVEL: 2000ppm KWG 0519

MACROSCOPIC FINDINGS

	Mode of death : Interim death
	Days under test : 638
	Date of death : 09/04/80
Condition at necropsy	Moribund
Liver	Loo. sin:
	Swollen purulent
Lung	Dark/red coloured

MICROSCOPIC FINDINGS

Kidney/1	Tubulopathy (minimal)
Liver	MALIGNANT TUMOUR hepatocellular adenocarcinoma
	Calcification (severe)
	Amyloid (severe)
	Hepatocytic hyperpigmentation
	Hyperplastic nodules
Lung	MALIGNANT TUMOUR alveogenic carcinoma
Spleen	Haematopoiesis (moderate)

KWG 0519 - Mouse Chronic Toxicity Study
Full Macro/Micro Report

Rat No: 324
SEX: Male
DOSE LEVEL: 2000ppm KWG 0519

MACROSCOPIC FINDINGS

	Mode of death : Interim death
	Days under test : 571
	Date of death : 02/02/80
Lung	Flesh coloured
Thoracic cavity	3ml haemorrhagic fluid
Thymus	Hard beige nodule (1.2cm diam)

MICROSCOPIC FINDINGS

Adrenal/1	Haemorrhagic cyst
Adrenal/2	Haemorrhagic cyst
Liver	Calcification
	Hyperplastic nodule
Lung	MALIGNANT LYMPHOMA
Pituitary	No tissue available
Stomach	Cysts (minimal)
Urinary bladder	Hypertrophy
	Coagulum
Thymus	MALIGNANT LYMPHOMA

KWG 0519 - Mouse Chronic Toxicity Study
Full Macro/Micro Report

Rat No: 325
SEX: Male
DOSE LEVEL: 2000ppm KWG 0519

MACROSCOPIC FINDINGS

Mode of death	: Interim death
Days under test	: 510
Date of death	: 13/12/79
Condition at necropsy	Autolysis (numerous organs)
Intestine	Brownish contents
Stomach	Mucosal bleeding

MICROSCOPIC FINDINGS

Adrenal/1	Autolysis (partial)
Adrenal/2	Autolysis (partial)
Brain	No tissue available
Heart	Congestion (severe)
Kidney/1	Calcification (minimal) Interstitial nephritis (minimal)
Kidney/2	Calcification (minimal) Interstitial nephritis (minimal)
Liver	Autolysis (partial)
Lung	Autolysis (partial) Oedema (severe)
Pancreas	Autolysis (partial)
Pituitary	No tissue available
Spleen	Autolysis (partial)
Stomach	Autolysis
Testis/1	Autolysis (partial)
Testis/2	Autolysis (partial)
Thyroid/1	Autolysis (partial)
Thyroid/2	Autolysis (partial)
Urinary bladder	Autolysis

KWG 0519 - Mouse Chronic Toxicity Study
Full Macro/Micro Report

Rat No: 326
SEX: Male
DOSE LEVEL: 2000ppm KWG 0519

MACROSCOPIC FINDINGS

	Mode of death : Interim death
	Days under test : 468
	Date of death : 22/10/79
Condition at necropsy	Autolysis (numerous organs)
Spleen	Enlarged (2.2 x 0.5cm)

MICROSCOPIC FINDINGS

Brain	No tissue available
Kidney/1	Autolysis (partial)
	Amyloid
Kidney/2	Autolysis (partial)
	Amyloid
Liver	Autolysis (partial)
	Hepatocytic hyperpigmentation
Lung	Autolysis (partial)
	MALIGNANT TUMOUR alveogenic carcinoma
Pancreas	Autolysis
Pituitary	No tissue available
Spleen	Autolysis (partial)
	Hypertrophy
Stomach	Autolysis
Testis/1	Autolysis (partial)
Testis/2	Autolysis (partial)
Thyroid/1	Autolysis (partial)
Thyroid/2	Autolysis (partial)
Urinary bladder	Autolysis (partial)
	Mononuclear cells (minimal)
	Coagulum

KWG 0519 - Mouse Chronic Toxicity Study
Full Macro/Micro Report

Rat No: 327
SEX: Male
DOSE LEVEL: 2000ppm KWG 0519

MACROSCOPIC FINDINGS

Mode of death : Terminal kill
Days under test : 734
Date of death : 14/07/80
No significant findings noted

MICROSCOPIC FINDINGS

Kidney/1	MALIGNANT LYMPHOMA
Kidney/2	MALIGNANT LYMPHOMA
Lung	Pneumonia (moderate)
Sciatic nerve	No tissue available
Spleen	MALIGNANT LYMPHOMA
Testis/1	Calcification (moderate)
	Spermatocoele

KWG 0519 - Mouse Chronic Toxicity Study
Full Macro/Micro Report

Rat No: 328
SEX: Male
DOSE LEVEL: 2000ppm KWG 0519

MACROSCOPIC FINDINGS

	Mode of death : Interim death
	Days under test : 609
	Date of death : 11/03/80
Lung	Dark red foci/areas

MICROSCOPIC FINDINGS

Heart	Fibrosis (minimal)
	Mononuclear cells (minimal)
	Congestion
Kidney/1	Interstitial nephritis (minimal)
Kidney/2	Cysts
Lung	Congestion
Pancreas	Inflammation chronic (minimal)
Testis/1	Spermatocoele (minimal)
Urinary bladder	Autolysis (partial)

KWG 0519 - Mouse Chronic Toxicity Study
Full Macro/Micro Report

Rat No: 329
SEX: Male
DOSE LEVEL: 2000ppm KWG 0519

MACROSCOPIC FINDINGS

	Mode of death : Interim death
	Days under test : 545
	Date of death : 07/01/80
Condition at necropsy	Autolysis (numerous organs)
General observations	Right side of neck soft grey-black nodule (1.4cm diam)

MICROSCOPIC FINDINGS

Adrenal/1	Autolysis
Adrenal/2	Autolysis
Bone (femur)	Autolysis (partial)
Brain	No tissue available
Heart	Autolysis (partial)
Kidney/1	Autolysis (partial)
	Interstitial nephritis (moderate)
Kidney/2	Autolysis (partial)
	Interstitial nephritis (moderate)
Liver	Autolysis (partial)
Lung	Autolysis (partial)
	MALIGNANT TUMOUR alveogenic carcinoma
	Pneumonia (moderate)
Pancreas	Autolysis
Pituitary	Autolysis
Skeletal muscle	Autolysis (partial)
	Mononuclear cells (minimal)
Spleen	Autolysis
Stomach	Autolysis
Testis/1	Autolysis (partial)
Testis/2	Autolysis (partial)
Thyroid/1	No tissue available
Thyroid/2	No tissue available
Urinary bladder	Autolysis
Unidentified tissue	RETICULUM CELL SARCOMA

KWG 0519 - Mouse Chronic Toxicity Study
Full Macro/Micro Report

Rat No: 330
SEX: Male
DOSE LEVEL: 2000ppm KWG 0519

MACROSCOPIC FINDINGS

	Mode of death : Interim death
	Days under test : 170
	Date of death : 28/12/78
Intestine	Haemorrhagic contents, Caecum contains haemorrhagic mass
Liver	Clay coloured areas
Stomach	Mucosal bleeding

MICROSCOPIC FINDINGS

Liver	Amyloid (severe)
Pituitary	Unreadable
Seminal vesicle	Atrophy epithelial
	Ectasia simple
	Coagulum
Stomach	Normal
Intestine	Autolysis

KWG 0519 - Mouse Chronic Toxicity Study
Full Macro/Micro Report

Rat No: 331
SEX: Male
DOSE LEVEL: 2000ppm KWG 0519

MACROSCOPIC FINDINGS

	Mode of death : Terminal kill
	Days under test : 734
	Date of death : 14/07/80
Kidney	Surface raised areas
Liver	Lob. dxtr. access: Enlarged/nodular

MICROSCOPIC FINDINGS

Adrenal/l	Hyperplasia glomerulosa (minimal)
Bone (femur)	No tissue available
Liver	Hyperplastic nodule
Pituitary	No tissue available
Spleen	Haematopoiesis (moderate)
Testis/l	Spermatocoele

KWG 0519 - Mouse Chronic Toxicity Study
Full Macro/Micro Report

Rat No: 332
SEX: Male
DOSE LEVEL: 2000ppm KWG 0519

MACROSCOPIC FINDINGS

	Mode of death : Terminal kill
	Days under test : 734
	Date of death : 14/07/80
Liver	Proc. pap: Cyst (3.0 x 2.3cm)
Lung	Lob. sin: White nodule (0.3cm diam)

MICROSCOPIC FINDINGS

Adrenal/1	No tissue available
Adrenal/2	No tissue available
Liver	Cysts
Lung	MALIGNANT TUMOUR alveogenic carcinoma
Pituitary	No tissue available

KWG 0519 - Mouse Chronic Toxicity Study
Full Macro/Micro Report

Rat No: 333
SEX: Male
DOSE LEVEL: 2000ppm KWG 0519

MACROSCOPIC FINDINGS

	Mode of death : Interim death
	Days under test : 673
	Date of death : 14/05/80
Liver	Clay coloured
Lung	Surrounded by blood clots
Stomach	Cyst (0.8cm diam)

MICROSCOPIC FINDINGS

Kidney/1	Fibrosis (minimal)
Kidney/2	Fibrosis (minimal)
Liver	Normal
Lung	Congestion (severe)
	Atelectasis (severe)
Pituitary	No tissue available
Stomach	Mucoid cyst (minimal)

KWG 0519 - Mouse Chronic Toxicity Study
Full Macro/Micro Report

Rat No: 334
SEX: Male
DOSE LEVEL: 2000ppm KWG 0519

MACROSCOPIC FINDINGS

	Mode of death : Terminal kill
	Days under test : 734
	Date of death : 14/07/80
Kidney	Right: Cysts (0.1cm diam)
Liver	Lob. caud: Cyst (0.3cm diam)
Pancreas	Hardened

MICROSCOPIC FINDINGS

Adrenal/1	BENIGN TUMOUR cortical adenoma
Liver	Hypertrophy
Lung	Pigmentation
	Mucoid cyst
Pancreas	Normal
Testis/1	Calcification (minimal)
Thyroid/1	Cysts
Thyroid/2	Cysts

KWG 0519 - Mouse Chronic Toxicity Study
Full Macro/Micro Report

Rat No: 335
SEX: Male
DOSE LEVEL: 2000ppm KWG 0519

MACROSCOPIC FINDINGS

	Mode of death : Terminal kill
	Days under test : 734
	Date of death : 14/07/80
Heart	Atrium enlarged
Kidney	Surface raised areas
Lung	Lob. inf. dxtr. lat: Flesh coloured
Pancreas	Hardened

MICROSCOPIC FINDINGS

Heart	Ventricular dilatation
Kidney/1	Interstitial nephritis (minimal)
Liver .	Hepatocytic hyperpigmentation
Lung	MALIGNANT TUMOUR alveogenic carcinoma
Pancreas	Normal
Spleen	Haematopoiesis (minimal)
Urinary bladder	Hyperplasia
	Coagulum

KWG 0519 - Mouse Chronic Toxicity Study
Full Macro/Micro Report

Rat No: 336
SEX: Male
DOSE LEVEL: 2000ppm KWG 0519

MACROSCOPIC FINDINGS

	Mode of death : Terminal kill
	Days under test : 734
	Date of death : 14/07/80
Kidney	Left: Surface raised areas
	Right: Cyst (0.1cm diam) swollen
Lung	Lob. sup. dxtr: White nodule (0.6cm diam)

MICROSCOPIC FINDINGS

Adrenal/1	BENIGN TUMOUR cortical adenoma
	Calcification (moderate)
	Pigmentation (moderate)
Adrenal/2	Pigmentation (moderate)
Kidney/1	Calcification (minimal)
	Hydronephrosis
Liver	Hyperplasia focal
Lung	MALIGNANT TUMOUR alveogenic carcinoma
Pancreas	Inflammation chronic (minimal)
Pituitary	No tissue available

KWG 0519 - Mouse Chronic Toxicity Study
Full Macro/Micro Report

Rat No: 337
SEX: Male
DOSE LEVEL: 2000ppm KWG 0519

MACROSCOPIC FINDINGS

	Mode of death : Interim death
	Days under test : 639
	Date of death : 10/04/80
Lung	Lob. sin: Light coloured nodule (0.2cm diam)
Stomach	Mucosal bleeding

MICROSCOPIC FINDINGS

Bone (femur)	No tissue available
Kidney/1	Interstitial nephritis (minimal)
Kidney/2	Interstitial nephritis (minimal)
Lung	MALIGNANT TUMOUR alveogenic carcinoma
Pituitary	No tissue available
Sciatic nerve	No tissue available
Skeletal muscle	No tissue available
Stomach	Mononuclear cells (minimal)
Testis/1	Calcification (minimal)
	Spermatocoele (minimal)
Thyroid/1	Autolysis (partial)
Thyroid/2	Autolysis (partial)
Urinary bladder	Mononuclear cells (minimal)

KWG 0519 - Mouse Chronic Toxicity Study
Full Macro/Micro Report

Rat No: 338
SEX: Male
DOSE LEVEL: 2000ppm KWG 0519

MACROSCOPIC FINDINGS

	Mode of death : Terminal kill
	Days under test : 734
	Date of death : 14/07/80
Liver	Enlarged
	Lob. sin: Enlarged/nodular
Pancreas	Hardened

MICROSCOPIC FINDINGS

Kidney/1	Interstitial nephritis (minimal)
Liver	Hyperplastic nodules
Pancreas	Normal
Testis/1	Atrophy seminiferous tubules (moderate)
	Spermatocoele (moderate)
Thyroid/1	Cysts (minimal)
Thyroid/2	Cysts (minimal)

KWG 0519 - Mouse Chronic Toxicity Study
Full Macro/Micro Report

Rat No: 339
SEX: Male
DOSE LEVEL: 2000ppm KWG 0519

MACROSCOPIC FINDINGS

	Mode of death : Interim death
	Days under test : 713
	Date of death : 13/06/80
Condition at necropsy	Autolysis (few organs)
Lung	Lob. sin: White hard focus (0.1cm diam)

MICROSCOPIC FINDINGS

Kidney/1	Calcification (moderate)
Lung	MALIGNANT TUMOUR alveogenic carcinoma
Pituitary	No tissue available
Stomach	Mononuclear cells (minimal)
Thyroid/1	Cysts (minimal)
Urinary bladder	Autolysis

KWG 0519 - Mouse Chronic Toxicity Study
Full Macro/Micro Report

Rat No: 340
SEX: Male
DOSE LEVEL: 2000ppm KWG 0519

MACROSCOPIC FINDINGS

	Mode of death : Interim death
	Days under test : 321
	Date of death : 28/05/79
Lung	Focal increased air content
Spleen	Enlarged (2.5 x 0.4cm)

MICROSCOPIC FINDINGS

Brain	Haemorrhage (minimal)
Kidney/1	Interstitial nephritis (minimal)
	Cysts (minimal)
Lung	Congestion
Spleen	Hypoplasia lymphoid (severe)
	MALIGNANT LYMPHOMA

KWG 0519 - Mouse Chronic Toxicity Study
Full Macro/Micro Report

Rat No: 341
SEX: Male
DOSE LEVEL: 2000ppm KWG 0519

MACROSCOPIC FINDINGS

	Mode of death : Interim death
	Days under test : 494
	Date of death : 17/11/79
Condition at necropsy	Autolysis (few organs)
General observations	Right eye greatly encrusted
Adrenal gland	Dark/red coloured
Lung	Flesh coloured
Stomach	Distended

MICROSCOPIC FINDINGS

Adrenal/1	Normal
Adrenal/2	Normal
Heart	Thrombosis
Lung	Congestion (moderate)
Pancreas	Autolysis (partial)
Pituitary	No tissue available
Spleen	Haematopoiesis (severe)
Stomach	Autolysis (partial)
Thyroid/1	Autolysis (partial)
Thyroid/2	Autolysis (partial)
Urinary bladder	Autolysis (partial)
Skin	MALIGNANT TUMOUR squamous cell carcinoma

KWG 0519 - Mouse Chronic Toxicity Study
Full Macro/Micro Report

Rat No: 342
SEX: Male
DOSE LEVEL: 2000ppm KWG 0519

MACROSCOPIC FINDINGS

	Mode of death : Terminal kill
	Days under test : 734
	Date of death : 14/07/80
Liver	Lob. caud: Enlarged/nodular (1.5 x 1.2cm)
	Lob. sin: Marbled nodule (1.0 x 0.7cm)

MICROSCOPIC FINDINGS

Adrenal/1	MALIGNANT LYMPHOMA
Adrenal/2	MALIGNANT LYMPHOMA
Kidney/1	MALIGNANT LYMPHOMA
Kidney/2	MALIGNANT LYMPHOMA
Liver	BENIGN TUMOUR hepatocellular adenoma
	Hepatocytic hyperpigmentation
	MALIGNANT LYMPHOMA
Spleen	MALIGNANT LYMPHOMA
Thyroid/1	No tissue available
Thyroid/2	No tissue available
Urinary bladder	MALIGNANT LYMPHOMA

KWG 0519 - Mouse Chronic Toxicity Study
Full Macro/Micro Report

Rat No: 343
SEX: Male
DOSE LEVEL: 2000ppm KWG 0519

MACROSCOPIC FINDINGS

	Mode of death : Terminal kill
	Days under test : 734
	Date of death : 14/07/80
Liver	Lob. dxtr: Enlarged/nodular (2.0cm diam)

MICROSCOPIC FINDINGS

Adrenal/1	Pigmentation (moderate)
Kidney/1	Interstitial nephritis (minimal)
Kidney/2	Interstitial nephritis (minimal)
Liver	BENIGN TUMOUR hepatocellular adenoma
	Mononuclear cells (severe)
	Hepatocytic hyperpigmentation
Lung	Pneumonia (minimal)
Pituitary	No tissue available
Spleen	Pigmentation
Testis/1	Atrophy seminiferous tubules (moderate)
	Calcification (minimal)
Testis/2	Calcification (minimal)

KWG 0519 - Mouse Chronic Toxicity Study
Full Macro/Micro Report

Rat No: 344
SEX: Male
DOSE LEVEL: 2000ppm KWG 0519

MACROSCOPIC FINDINGS

Mode of death	: Interim death
Days under test	: 416
Date of death	: 31/08/79
Adrenal gland	Left: Enlarged
Liver	Enlarged
Lung	Pale and fleshy surface areas
Spleen	Enlarged (4.2 x 1.5cm)

MICROSCOPIC FINDINGS

Kidney/1	Autolysis
Kidney/2	Autolysis
Liver	MALIGNANT LYMPHOMA
Lung	MALIGNANT LYMPHOMA
Pancreas	MALIGNANT LYMPHOMA
Pituitary	No tissue available
Spleen	Autolysis (partial)
	MALIGNANT LYMPHOMA
Stomach	Autolysis (partial)
Thyroid/1	Autolysis
Thyroid/2	Autolysis
Urinary bladder	Autolysis
Lymph node	MALIGNANT LYMPHOMA
Mesentery	MALIGNANT LYMPHOMA

KWG 0519 - Mouse Chronic Toxicity Study
Full Macro/Micro Report

Rat No: 345
SEX: Male
DOSE LEVEL: 2000ppm KWG 0519

MACROSCOPIC FINDINGS

	Mode of death : Terminal kill
	Days under test : 734
	Date of death : 14/07/80
Liver	Hardened with red foci
	Lob. sin. and Lob. sin. access: Multiple nodules (0.2-1.2cm diam)

MICROSCOPIC FINDINGS

Heart	Inflammation chronic
Kidney/1	Interstitial nephritis (moderate)
	Cysts (minimal)
Kidney/2	Interstitial nephritis (moderate)
Liver	BENIGN TUMOUR hepatocellular adenoma
	Haemorrhage
Testis/1	Calcification (minimal)
Thyroid/1	Cysts
Thyroid/2	Cysts

KWG 0519 - Mouse Chronic Toxicity Study
Full Macro/Micro Report

Rat No: 346
SEX: Male
DOSE LEVEL: 2000ppm KWG 0519

MACROSCOPIC FINDINGS

	Mode of death	: Interim death
	Days under test	: 566
	Date of death	: 28/01/80
Condition at necropsy	Autolysis (complete)	
	Evaluation not possible	

MICROSCOPIC FINDINGS

Adrenal/1	Autolysis (partial)
Adrenal/2	Autolysis (partial)
Heart	Autolysis (partial)
	Thrombosis
Kidney/1	Autolysis (partial)
	MALIGNANT LYMPHOMA
Kidney/2	Autolysis (partial)
	MALIGNANT LYMPHOMA
Liver	Autolysis (partial)
	Hyperplastic nodule
	MALIGNANT LYMPHOMA
Lung	Autolysis (partial)
	MALIGNANT LYMPHOMA
Pancreas	Autolysis
Pituitary	No tissue available
Skeletal muscle	MALIGNANT LYMPHOMA
Spleen	Autolysis (partial)
	MALIGNANT LYMPHOMA
Stomach	Autolysis
Testis/1	Autolysis (partial)
Testis/2	Autolysis (partial)
Thyroid/1	Autolysis
Thyroid/2	Autolysis
Urinary bladder	Autolysis

KWG 0519 - Mouse Chronic Toxicity Study
Full Macro/Micro Report

Rat No: 347
SEX: Male
DOSE LEVEL: 2000ppm KWG 0519

MACROSCOPIC FINDINGS

	Mode of death : Interim death
	Days under test : 668
	Date of death : 09/05/80
Spleen	Enlarged (2.5 x 0.7cm)
Urinary bladder	Enlarged (2.6 x 1.3cm)

MICROSCOPIC FINDINGS

Brain	Congestion (minimal)
Kidney/1	Interstitial nephritis (minimal)
Kidney/2	Interstitial nephritis (minimal)
Liver	Inflammation portal (severe)
Lung	Congestion (moderate)
Pituitary	No tissue available
Skeletal muscle	Mononuclear cells (moderate)
Spleen	Haematopoiesis (severe)
Urinary bladder	Autolysis (partial)
	Ectasia simple

KWG 0519 - Mouse Chronic Toxicity Study
Full Macro/Micro Report

Rat No: 348
SEX: Male
DOSE LEVEL: 2000ppm KWG 0519

MACROSCOPIC FINDINGS

Mode of death : Terminal kill
Days under test : 734
Date of death : 14/07/80
No significant findings noted

MICROSCOPIC FINDINGS

Kidney/1	Tubulopathy (minimal)
	Interstitial nephritis (minimal)
Kidney/2	Tubulopathy (minimal)
	Interstitial nephritis (minimal)
Spleen	Haematopoiesis (minimal)
Testis/1	Calcification (moderate)
Testis/2	Atrophy seminiferous tubules (moderate)
	Spermatocoele (minimal)
Thyroid/1	No tissue available
Thyroid/2	No tissue available

KWG 0519 - Mouse Chronic Toxicity Study
Full Macro/Micro Report

Rat No: 349
SEX: Male
DOSE LEVEL: 2000ppm KWG 0519

MACROSCOPIC FINDINGS

	Mode of death : Interim death
	Days under test : 471
	Date of death : 25/10/79
General observations	Hard white nodule right side of neck (1.2cm diam)
Intestine	Haemorrhagic contents
Stomach	Mucosal bleeding

MICROSCOPIC FINDINGS

Adrenal/1	No tissue available
Adrenal/2	No tissue available
Heart	Congestion
Kidney/1	Tubulopathy (minimal)
Kidney/2	Tubulopathy (minimal)
Liver	Hepatocytic hyperpigmentation
Lung	Congestion (severe)
Pancreas	Autolysis (partial)
Pituitary	No tissue available
Spleen	Pigmentation
Stomach	Autolysis (partial)
	Normal
Thyroid/1	Cysts (minimal)
Urinary bladder	Autolysis (partial)
Bone	BENIGN TUMOUR osteoma
Intestine	Autolysis (partial) Normal

KWG 0519 - Mouse Chronic Toxicity Study
Full Macro/Micro Report

Rat No: 350
SEX: Male
DOSE LEVEL: 2000ppm KWG 0519

MACROSCOPIC FINDINGS

Mode of death	: Interim death
Days under test	: 574
Date of death	: 05/02/80
General observations	Obese
Lung	Dark red foci/areas
	Lob. sin: Hard grey area (0.1cm diam)
Urinary bladder	Enlarged (1.4cm diam) reddish discolouration

MICROSCOPIC FINDINGS

Kidney/1	MALIGNANT LYMPHOMA
Kidney/2	MALIGNANT LYMPHOMA
Liver	MALIGNANT LYMPHOMA
Lung	Adenomatosis (minimal)
	Congestion (severe)
Spleen	MALIGNANT LYMPHOMA
Thyroid/1	Cysts (minimal)
Thyroid/2	Cysts (minimal)
Urinary bladder	Necrosis
	Haemorrhage

KWG 0519 - Mouse Chronic Toxicity Stucy
Full Macro/Micro Report

Rat No: 351
SEX: Female
DOSE LEVEL: 2000ppm KWG 0519

MACROSCOPIC FINDINGS

	Mode of death : Terminal kill
	Days under test : 735
	Date of death : 15/07/80
Liver	Proc. pap: Swollen/enlarged
Ovary	Right: Cysts (0.1cm diam)

MICROSCOPIC FINDINGS

Adrenal/1	Pigmentation (minimal)
Adrenal/2	Pigmentation (minimal)
Liver	Fat vacuoles
	Mononuclear cells
	Hepatocytic hyperpigmentation
	Hyperplastic nodules
Lung	Pneumonia
Ovary/1	Atrophy
	Cysts
Ovary/2	Atrophy
Pancreas	Inflammation chronic
Spleen	Haematopoiesis (moderate)
Uterus	Hyperplasia secretory

KWG 0519 - Mouse Chronic Toxicity Study
Full Macro/Micro Report

Rat No: 352
SEX: Female
DOSE LEVEL: 2000ppm KWG 0519

MACROSCOPIC FINDINGS

	Mode of death : Interim death
	Days under test : 278
	Date of death : 15/04/79
Lung	Fleshy
Thymus	Beige hard nodule (1.5cm diam)

MICROSCOPIC FINDINGS

Liver	Congestion
Lung	MALIGNANT LYMPHOMA
Pituitary	No tissue available
Spleen	Hyperplasia lymphoid
Thyroid/1	No tissue available
Thyroid/2	No tissue available
Thymus	MALIGNANT LYMPHOMA

KW6 0519 - Mouse Chronic Toxicity Study
Full Macro/Micro Report

Rat No: 353
SEX: Female
DOSE LEVEL: 2000ppm KW6 0519

MACROSCOPIC FINDINGS

	Mode of death : Interim death
	Days under test : 517
	Date of death : 10/12/79
General observations	Subcutaneous bleeding forehead
Cranium	Indurated
Liver	Enlarged
	Surface cysts
Lung	Pale
	Dark red foci/areas
Spleen	Enlarged (4.7 x 1.2cm)
Stomach	Mucosal bleeding

MICROSCOPIC FINDINGS

Liver	MALIGNANT LYMPHOMA
Lung	Congestion (severe)
Ovary/1	MALIGNANT LYMPHOMA
Ovary/2	MALIGNANT LYMPHOMA
Pancreas	Autolysis
Sciatic nerve	No tissue available
Spleen	MALIGNANT LYMPHOMA
Thyroid/1	No tissue available
Thyroid/2	No tissue available
Uterus	MALIGNANT LYMPHOMA
Bone	BENIGN TUMOUR osteoma
Mesentery	MALIGNANT LYMPHOMA

KWG 0519 - Mouse Chronic Toxicity Study
Full Macro/Micro Report

Rat No: 354
SEX: Female
DOSE LEVEL: 2000ppm KWG 0519

MACROSCOPIC FINDINGS

	Mode of death : Terminal kill
	Days under test : 735
	Date of death : 15/07/80
Ovary	Right: Cysts (0.3cm diam)

MICROSCOPIC FINDINGS

Lung	Atelectasis
	Thickened alveolar walls
Ovary/1	Atrophy
	Cysts
Ovary/2	Atrophy
Spleen	Haematopoiesis (moderate)
Thyroid/1	No tissue available
Thyroid/2	No tissue available
Urinary bladder	Inflammation chronic
Uterus	Cystic endometrial hyperplasia

KWG 0519 - Mouse Chronic Toxicity Study
Full Macro/Micro Report

Rat No: 355
SEX: Female
DOSE LEVEL: 2000ppm KWG 0519

MACROSCOPIC FINDINGS

Condition at necropsy	Mode of death : Interim death Days under test : 480 Date of death : 03/11/79 Autolysis (complete) Evaluation not possible

MICROSCOPIC FINDINGS

Adrenal/1	No tissue available
Adrenal/2	No tissue available
Bone (femur)	No tissue available
Brain	No tissue available
Heart	No tissue available
Kidney/1	No tissue available
Kidney/2	No tissue available
Liver	No tissue available
Lung	No tissue available
Ovary/1	No tissue available
Ovary/2	No tissue available
Pancreas	No tissue available
Pituitary	No tissue available
Sciatic nerve	No tissue available
Skeletal muscle	No tissue available
Spleen	No tissue available
Stomach	No tissue available
Thyroid/1	No tissue available
Thyroid/2	No tissue available
Urinary bladder	No tissue available

KWG 0519 - Mouse Chronic Toxicity Study
Full Macro/Micro Report

Rat No: 356
SEX: Female
DOSE LEVEL: 2000ppm KWG 0519

MACROSCOPIC FINDINGS

Mode of death	: Interim death
Days under test	: 624
Date of death	: 26/03/80
Condition at necropsy	Moribund
General observations	Tail fallen off due to mechanical injury. Skin at base of tail inflammed
Liver	Enlarged
Lung	Dark red foci/areas
Spleen	Enlarged (2.2 x 0.7cm)*

MICROSCOPIC FINDINGS

Adrenal/1	Haemorrhagic cyst
Kidney/1	Cysts
Kidney/2	Cysts
Liver	Mononuclear cells (minimal)
	Perarteritis
Lung	Pleuritis
Ovary/1	Atrophy
Ovary/2	Atrophy
Pituitary	No tissue available
Spleen	Hyperplasia lymphoid
	Congestion
Thyroid/1	No tissue available
Thyroid/2	No tissue available
Urinary bladder	Inflammation chronic
Uterus	Endometritis
Skin	Normal

KWG 0519 - Mouse Chronic Toxicity Study
Full Macro/Micro Report

Rat No: 357
SEX: Female
DOSE LEVEL: 2000ppm KWG 0519

MACROSCOPIC FINDINGS

	Mode of death : Terminal kill
	Days under test : 735
	Date of death : 15/07/80
Lung	Flesh coloured
Ovary	Left: Cysts (0.3cm diam) focal haemorrhage and hard beige thickening (0.4cm diam)
Spleen	Enlarged (2.5 x 0.6cm)
Uterus	Both horns enlarged. (Right 0.8cm diam Left 0.4cm diam)

MICROSCOPIC FINDINGS

Kidney/1	Interstitial nephritis
Kidney/2	Interstitial nephritis
Lung	Pneumonia
Ovary/1	Haemorrhagic cyst
Pituitary	No tissue available
Spleen	Haematopoiesis (minimal)
	Congestion
Urinary bladder	Inflammation chronic
Uterus	MALIGNANT TUMOUR mesenchymal tumour
	Cystic endometrial hyperplasia

KWG 0519 - Mouse Chronic Toxicity Study
Full Macro/Micro Report

Rat No: 358
SEX: Female
DOSE LEVEL: 2000ppm KWG 0519

MACROSCOPIC FINDINGS

Mode of death	: Interim death
Days under test	: 669
Date of death	: 10/05/80
Condition at necropsy	Autolysis (few organs)
Liver	Clay coloured
Lung	Surrounded by blood clots

MICROSCOPIC FINDINGS

Adrenal/1	BENIGN TUMOUR cortical adenoma
	Pigmentation (minimal)
Adrenal/2	Pigmentation (minimal)
Kidney/1	Tubulopathy
Kidney/2	Tubulopathy
Liver	Hyperplastic nodule
Lung	Pneumonia
Ovary/1	Haemorrhagic cyst
Pancreas	Autolysis (partial)
Pituitary	No tissue available
Sciatic nerve	No tissue available
Thyroid/1	No tissue available
Thyroid/2	No tissue available
Urinary bladder	Inflammation chronic
Uterus	Hyperplasia secretory

KWG 0519 - Mouse Chronic Toxicity Study
Full Macro/Micro Report

Rat No: 359
SEX: Female
DOSE LEVEL: 2000ppm KWG 0519

MACROSCOPIC FINDINGS

	Mode of death : Terminal kill
	Days under test : 735
	Date of death : 15/07/80
Lung	Flesh coloured
Uterus	Thickened (0.4cm diam)

MICROSCOPIC FINDINGS

Adrenal/1	Pigmentation (minimal)
Adrenal/2	Pigmentation (minimal)
Kidney/1	Tubulopathy
Liver	Fat vacuoles (minimal)
Lung	Pneumonia
Ovary/1	Atrophy
	Haemorrhagic cyst
Ovary/2	Atrophy
Pancreas	Inflammation chronic
Spleen	Haematopoiesis (severe)
Stomach	Mucoid cyst
Uterus	Hyperplasia secretory

KWG 0519 - Mouse Chronic Toxicity Study
Full Macro/Micro Report

Rat No: 360
SEX: Female
DOSE LEVEL: 2000ppm KWG 0519

MACROSCOPIC FINDINGS

	Mode of death : Terminal kill
	Days under test : 735
	Date of death : 15/07/80
Ovary	Cysts (1.0cm diam)
Uterus	Left horn thickened (1.0cm diam) filled with gelatinous beige mass

MICROSCOPIC FINDINGS

Bone marrow (femur)	Haematopoiesis
Kidney/1	Interstitial nephritis (minimal)
Kidney/2	Interstitial nephritis (minimal)
Liver	Mononuclear cells (minimal)
Lung	Thickened alveolar walls
Ovary/1	Cysts
Spleen	Haematopoiesis (severe)
Stomach	No tissue available
Thyroid/1	Cysts (minimal)
Thyroid/2	Cysts (minimal)
Urinary bladder	Inflammation chronic
Uterus	MALIGNANT TUMOUR leiomyosarcoma
	Cystic endometrial hyperplasia

KWE 0519 - Mouse Chronic Toxicity Study
Full Macro/Micro Report

Rat No: 361
SEX: Female
DOSE LEVEL: 2000ppm KWG 0519

MACROSCOPIC FINDINGS

	Mode of death : Interim death
	Days under test : 497
	Date of death : 20/11/79
Condition at necropsy	Autolysis (few organs)
Intestine	Adhesions to liver, stomach, kidneys and adrenals
Lung	Dark/red coloured
Ovary	Enlarged (0.3cm diam)
Thoracic cavity	Filled with milky-opaque fluid

MICROSCOPIC FINDINGS

Adrenal/1	No tissue available
Adrenal/2	No tissue available
Heart	Thrombosis
Kidney/1	MALIGNANT LYMPHOMA
Kidney/2	MALIGNANT LYMPHOMA
Liver	MALIGNANT LYMPHOMA
Lung	MALIGNANT LYMPHOMA
Ovary/1	MALIGNANT LYMPHOMA
Ovary/2	MALIGNANT LYMPHOMA
Spleen	MALIGNANT LYMPHOMA
Thyroid/1	No tissue available
Thyroid/2	No tissue available
Urinary bladder	MALIGNANT LYMPHOMA
Uterus	MALIGNANT LYMPHOMA
Lymph node	MALIGNANT LYMPHOMA
Trachea	MALIGNANT LYMPHOMA

KWG 0519 - Mouse Chronic Toxicity Stuay
Full Macro/Micro Report

Rat No: 362
SEX: Female
DOSE LEVEL: 2000ppm KWG 0519

MACROSCOPIC FINDINGS

Mode of death	: Interim death
Days under test	: 730
Date of death	: 10/07/80
Adrenal gland	Clay coloured
Cranium	Indurated
Kidney	Clay coloured
Spleen	Enlarged (3.1 x 0.8cm)
	Pale
Stomach	Mucosal bleeding

MICROSCOPIC FINDINGS

Heart	Congestion
Kidney/1	Autolysis (partial)
	MALIGNANT LYMPHOMA
Kidney/2	Autolysis (partial)
	MALIGNANT LYMPHOMA
Liver	MALIGNANT LYMPHOMA
Lung	Congestion
	Atelectasis
Ovary/1	MALIGNANT LYMPHOMA
Ovary/2	MALIGNANT LYMPHOMA
Pancreas	MALIGNANT LYMPHOMA
Spleen	MALIGNANT LYMPHOMA
Stomach	Mucoid cyst
	Papillomatous acanthosis
Urinary bladder	MALIGNANT LYMPHOMA
Mesentery	MALIGNANT LYMPHOMA
Skull	BENIGN TUMOUR osteoma

KWG 0519 - Mouse Chronic Toxicity Study
Full Macro/Micro Report

Rat No: 363
SEX: Female
DOSE LEVEL: 2000ppm KWG 0519

MACROSCOPIC FINDINGS

	Mode of death : Interim death
	Days under test : 536
	Date of death : 29/12/79
Liver	Clay coloured
Lung	Flesh coloured
Spleen	Enlarged (3.8 x 0.6cm)
Thymus	Hard beige nodule (1.2cm diam)

MICROSCOPIC FINDINGS

Heart	MALIGNANT LYMPHOMA
Kidney/1	MALIGNANT LYMPHOMA
Kidney/2	MALIGNANT LYMPHOMA
Liver	MALIGNANT LYMPHOMA
Lung	MALIGNANT LYMPHOMA
Ovary/1	MALIGNANT LYMPHOMA
Ovary/2	MALIGNANT LYMPHOMA
Pancreas	MALIGNANT LYMPHOMA
Sciatic nerve	MALIGNANT LYMPHOMA
Spleen	MALIGNANT LYMPHOMA
Thyroid/1	Autolysis (partial)
Thyroid/2	Autolysis (partial)
Urinary bladder	MALIGNANT LYMPHOMA
Uterus	MALIGNANT LYMPHOMA
Thymus	MALIGNANT LYMPHOMA

KWG 0519 - Mouse Chronic Toxicity Study
Full Macro/Micro Report

Rat No: 364
SEX: Female
DOSE LEVEL: 2000ppm KWG 0519

MACROSCOPIC FINDINGS

Mode of death	: Interim death
Days under test	: 496
Date of death	: 19/11/79
Condition at necropsy	Autolysis (few organs)
Lung	Dark/brown-red coloured
Thoracic cavity	Full of dark-brown fluid

MICROSCOPIC FINDINGS

Bone (femur)	No tissue available
Kidney/1	Congestion (severe)
Kidney/2	Congestion (severe)
Liver	Congestion
Lung	Oedema (severe)
	Congestion (severe)
Ovary/1	Atrophy
Ovary/2	Atrophy
Pancreas	Autolysis
Sciatic nerve	No tissue available
Skeletal muscle	No tissue available
Spleen	Autolysis
Stomach	Unreadable
Thyroid/1	No tissue available
Thyroid/2	No tissue available
Uterus	Normal

KWG 0519 - Mouse Chronic Toxicity Study
Full Macro/Micro Report

Rat No: 365
SEX: Female
DOSE LEVEL: 2000ppm KWG 0519

MACROSCOPIC FINDINGS

	Mode of death : Interim death
	Days under test : 721
	Date of death : 01/07/80
Liver	Lob. dxtr: Hard brown nodule (1.4cm diam)
Ovary	Right: Cyst (1.4cm diam) haemorrhagic
	Left: Hard nodule (0.6cm diam)
Spleen	Enlarged (2.7 x 0.7cm)

MICROSCOPIC FINDINGS

Adrenal/1	Pigmentation (severe)
Adrenal/2	Pigmentation (severe)
Kidney/1	Interstitial nephritis (moderate)
Kidney/2	Interstitial nephritis (moderate)
Liver	BENIGN TUMOUR hepatocellular adenoma
	Mononuclear cells (moderate)
Lung	Congestion
Ovary/1	Inflammation acute (severe)
	Haemorrhage (severe)
Ovary/2	Inflammation acute (severe)
	Haemorrhage (severe)
Pancreas	Inflammation chronic
Spleen	Haematopoiesis (severe)
Urinary bladder	Hyperplasia papillomatous
Uterus	Endometritis (severe)

KWG 0519 - Mouse Chronic Toxicity Study
Full Macro/Micro Report

Rat No: 366
SEX: Female
DOSE LEVEL: 2000ppm KWG 0519

MACROSCOPIC FINDINGS

	Mode of death : Interim death
	Days under test : 712
	Date of death : 22/06/80
Condition at necropsy	Autolysis (few organs)
Adrenal gland	Left: Enlarged
Kidney	Dark-red foci
Lung	Flesh coloured
	Dark red foci/areas
Spleen	Enlarged (3.1 x 0.9cm)
Stomach	Mucosal bleeding

MICROSCOPIC FINDINGS

Adrenal/1	MALIGNANT LYMPHOMA
Adrenal/2	MALIGNANT LYMPHOMA
Brain	Oedema
Heart	MALIGNANT LYMPHOMA
Kidney/1	MALIGNANT LYMPHOMA
Kidney/2	MALIGNANT LYMPHOMA
Liver	MALIGNANT LYMPHOMA
Lung	MALIGNANT LYMPHOMA
Ovary/1	MALIGNANT LYMPHOMA
Ovary/2	MALIGNANT LYMPHOMA
Pancreas	MALIGNANT LYMPHOMA
Spleen	MALIGNANT LYMPHOMA
Stomach	MALIGNANT LYMPHOMA
Urinary bladder	MALIGNANT LYMPHOMA
Lymph node	MALIGNANT LYMPHOMA

KWG 0519 - Mouse Chronic Toxicity Study
Full Macro/Micro Report

Rat No: 367
SEX: Female
DOSE LEVEL: 2000ppm KWG 0519

MACROSCOPIC FINDINGS

	Mode of death : Terminal kill
	Days under test : 735
	Date of death : 15/07/80
Liver	Enlarged/nodular
Spleen	Enlarged (2.2 x 0.7cm)

MICROSCOPIC FINDINGS

Adrenal/1	Pigmentation
	Fat vacuoles
Adrenal/2	Pigmentation
Kidney/1	Interstitial nephritis (minimal)
Kidney/2	Interstitial nephritis (minimal)
Liver	BENIGN TUMOUR hepatocellular adenoma
Lung	Pneumonia
Ovary/1	Atrophy
	Haemorrhagic cyst
Ovary/2	Atrophy
Sciatic nerve	No tissue available
Spleen	Haematopoiesis (severe)
Urinary bladder	Inflammation granulomatous
Uterus	Cystic endometrial hyperplasia (minimal)

KWG 0519 - Mouse Chronic Toxicity Study
Full Macro/Micro Report

Rat No: 368
SEX: Female
DOSE LEVEL: 2000ppm KWG 0519

MACROSCOPIC FINDINGS

	Mode of death : Terminal kill
	Days under test : 735
	Date of death : 15/07/80
Lung	Flesh coloured
Ovary	Right: Cysts (0.3cm diam)
Spleen	Enlarged (1.8 x 0.4cm)
Uterus	Enlarged (0.4cm diam)

MICROSCOPIC FINDINGS

Lung	Pneumonia
Ovary/1	Atrophy
	Cystic follicle
Ovary/2	Atrophy
Spleen	Haematopoiesis (minimal)
Uterus	Hyperplasia secretory

KWG 0519 - Mouse Chronic Toxicity Study
Full Macro/Micro Report

Rat No: 369
SEX: Female
DOSE LEVEL: 2000ppm KWG 0519

MACROSCOPIC FINDINGS

Mode of death	: Interim death
Days under test	: 502
Date of death	: 25/11/79
Condition at necropsy	Autolysis (numerous organs)
Adrenal gland	Enlarged (left 0.3cm diam, right 0.2cm diam)
Liver	Enlarged
Lung	Flesh coloured
Ovary	Enlarged (left 0.6cm diam, right 0.3cm diam)
Spleen	Enlarged (3.4 x 1.0cm) nodular
Stomach	Brown-red mucous contents
Thymus	Soft greyish thickening (0.6cm diam)
Uterus	Horns slightly enlarged

MICROSCOPIC FINDINGS

Kidney/1	MALIGNANT LYMPHOMA
Kidney/2	MALIGNANT LYMPHOMA
Liver	MALIGNANT LYMPHOMA
Lung	MALIGNANT LYMPHOMA
Ovary/1	Cysts
Ovary/2	Cysts
Pancreas	Autolysis
Spleen	MALIGNANT LYMPHOMA
Stomach	MALIGNANT LYMPHOMA
Urinary bladder	MALIGNANT LYMPHOMA
Uterus	MALIGNANT LYMPHOMA
Thymus	MALIGNANT LYMPHOMA

KWG 0519 - Mouse Chronic Toxicity Study
Full Macro/Micro Report

Rat No: 370
SEX: Female
DOSE LEVEL: 2000ppm KWG 0519

MACROSCOPIC FINDINGS

Mode of death	: Interim death
Days under test	: 537
Date of death	: 30/12/79
Liver	Enlarged
Lung	Brownish glossy surface
Spleen	Enlarged (5.1 x 1.3cm)
Stomach	Mucosal bleeding

MICROSCOPIC FINDINGS

Kidney/1	Tubulopathy
Kidney/2	Tubulopathy
Liver	MALIGNANT LYMPHOMA
Lung	MALIGNANT LYMPHOMA
Ovary/1	BENIGN TUMOUR luteoma
Pancreas	Atrophy
Spleen	MALIGNANT LYMPHOMA
Stomach	Normal
Urinary bladder	MALIGNANT LYMPHOMA
Uterus	Cystic endometrial hyperplasia

KWG 0519 - Mouse Chronic Toxicity Study
Full Macro/Micro Report

Rat No: 371
SEX: Female
DOSE LEVEL: 2000ppm KWG 0519

MACROSCOPIC FINDINGS

	Mode of death : Interim death
	Days under test : 374
	Date of death : 20/07/79
Lung	Fleshy
Thymus	Beige soft nodule (0.6cm diam)

MICROSCOPIC FINDINGS

Heart	MALIGNANT LYMPHOMA
Kidney/1	Tubulopathy
	Pyelonephritis
Kidney/2	Tubulopathy
	Pyelonephritis
Liver	Congestion
Lung	MALIGNANT LYMPHOMA
Ovary/1	BENIGN TUMOUR luteoma
Pancreas	Inflammation chronic
Spleen	Autolysis (partial)
Thyroid/1	No tissue available
Thyroid/2	No tissue available
Uterus	Normal
Thymus	MALIGNANT LYMPHOMA

KWG 0519 - Mouse Chronic Toxicity Study
Full Macro/Micro Report

Rat No: 372
SEX: Female
DOSE LEVEL: 2000ppm KWG 0519

MACROSCOPIC FINDINGS

	Mode of death : Interim death
	Days under test : 567
	Date of death : 29/01/80
Kidney	Left: Soft pale containing clear fluid
Lung	Dark red foci/areas

MICROSCOPIC FINDINGS

Adrenal/1	Pigmentation
Adrenal/2	Pigmentation
Heart	Congestion
Kidney/1	Calcification
Kidney/2	Hydronephrosis
Liver	Congestion
Lung	Oedema
	Congestion
Ovary/1	Atrophy
Ovary/2	Atrophy
Stomach	Autolysis
Urinary bladder	Autolysis
Uterus	Endometriosis

KWG 0519 - Mouse Chronic Toxicity Study
Full Macro/Micro Report

Rat No: 373
SEX: Female
DOSE LEVEL: 2000ppm KWG 0519

MACROSCOPIC FINDINGS

	Mode of death : Interim death
	Days under test : 714
	Date of death : 24/06/80
Condition at necropsy	Moribund
Femur	Left: Thickened (1.2cm diam) containing greyish gelatinous mass

MICROSCOPIC FINDINGS

Adrenal/1	Pigmentation (minimal)
Adrenal/2	Pigmentation (minimal)
Bone (femur)	MALIGNANT TUMOUR osteogenic sarcoma
Brain	Fat vacuoles (minimal)
Liver	Mononuclear cells (minimal)
Lung	METASTASIS osteogenic sarcoma
Ovary/1	Atrophy
Ovary/2	Atrophy
Skeletal muscle	METASTASIS osteogenic sarcoma
Spleen	Haematopoiesis (moderate)
Thyroid/1	No tissue available
Thyroid/2	No tissue available
Uterus	Hyperplasia polypoid
	Cystic endometrial hyperplasia

KWG 0519 - Mouse Chronic Toxicity Study
Full Macro/Micro Report

Rat No: 374
SEX: Female
DOSE LEVEL: 2000ppm KWG 0519

MACROSCOPIC FINDINGS

Mode of death	: Interim death
Days under test	: 601
Date of death	: 03/03/80
Abdominal cavity	White hard nodule (0.8cm diam) on spinal column adjacent to kidney
Cranium	Indurated
Liver	Enlarged
Lung	Lob. dxtr: Dark red foci/areas
Posterior extremities	Right side two white hard nodules (0.3cmdiam)
Spleen	Enlarged (3.2 x 0.5cm)

MICROSCOPIC FINDINGS

Bone (femur)	MALIGNANT TUMOUR osteogenic sarcoma
Brain	No tissue available
Heart	Thrombosis
Kidney/1	Interstitial nephritis (minimal)
Kidney/2	Interstitial nephritis (minimal)
Liver	MALIGNANT LYMPHOMA
Lung	Pneumonia
Ovary/1	Atrophy
Ovary/2	Atrophy
Pancreas	MALIGNANT LYMPHOMA
Sciatic nerve	No tissue available
Spleen	MALIGNANT LYMPHOMA
Thyroid/1	Unreadable
Thyroid/2	Unreadable
Uterus	MALIGNANT LYMPHOMA
Body cavity	METASTASIS osteogenic sarcoma
Hind limb (right)	METASTASIS osteogenic sarcoma

KWG 0519 - Mouse Chronic Toxicity Study
Full Macro/Micro Report

Rat No: 375
SEX: Female
DOSE LEVEL: 2000ppm KWG 0519

MACROSCOPIC FINDINGS

	Mode of death : Terminal kill
	Days under test : 735
	Date of death : 15/07/80
Liver	Enlarged/nodular
	Beige and yellow coloured
Spleen	Enlarged (2.0 x 0.7cm)

MICROSCOPIC FINDINGS

Adrenal/1	Pigmentation
Adrenal/2	Pigmentation
Kidney/1	Interstitial nephritis (minimal)
Kidney/2	Interstitial nephritis (minimal)
Liver	BENIGN TUMOUR hepatocellular adenoma
	Infarct
	Congestion
	Thrombosis
Lung	Pneumonia
Ovary/1	Atrophy
Ovary/2	Atrophy
Pituitary	No tissue available
Spleen	Haematopoiesis (severe)
Urinary bladder	No tissue available

KWG 0519 - Mouse Chronic Toxicity Study
Full Macro/Micro Report

Rat No: 376
SEX: Female
DOSE LEVEL: 2000ppm KWG 0519

MACROSCOPIC FINDINGS

	Mode of death : Interim death
	Days under test : 501
	Date of death : 24/11/79
Condition at necropsy	Autolysis (few organs)
Liver	Lob. dxtr. access: Lower edge soft spongy nodule (1.2cm diam)
	Lob. sin: Visceral surface grey-brown thickening (0.4cm diam)
Lung	Diaphragmatic surface slight thickening (0.25cm diam)
Ovary	Flesh coloured
Thoracic cavity	Enlarged (0.5cm diam)'
Uterus	0.5ml reddish-clear fluid pleural cavity
	Enlarged

MICROSCOPIC FINDINGS

Adrenal/1	Hyperplastic nodule
Kidney/1	Pyelonephritis
Kidney/2	Pyelonephritis
Liver	BENIGN TUMOUR hepatocellular adenoma
	Hyperplastic nodule
	Cysts
Lung	Oedema
Ovary/1	Hyperplasia polypoid
	Hypertrophic corpora lutea
Ovary/2	Hypertrophic corpora lutea

KWG 0519 - Mouse Chronic Toxicity Study
Full Macro/Micro Report

Rat No: 377
SEX: Female
DOSE LEVEL: 2000ppm KWG 0519

MACROSCOPIC FINDINGS

	Mode of death : Terminal kill
	Days under test : 735
	Date of death : 15/07/80
Liver	Lob. sin: Brown-beige nodules (0.6cm diam)
Ovary	Right: Cysts (0.5cm diam)

MICROSCOPIC FINDINGS

Adrenal/1	Pigmentation (severe)
Adrenal/2	Pigmentation (severe)
Kidney/1	Interstitial nephritis (minimal)
Kidney/2	Interstitial nephritis (minimal)
Liver	BENIGN TUMOUR hepatocellular adenoma
Lung	Pneumonia
Ovary/1	Atrophy
	Cysts
Ovary/2	Atrophy
	Cysts
Uterus	Endometriosis

KWG 0519 - Mouse Chronic Toxicity Study
Full Macro/Micro Report

Rat No: 378
SEX: Female
DOSE LEVEL: 2000ppm KWG 0519

MACROSCOPIC FINDINGS

	Mode of death : Terminal kill
	Days under test : 735
	Date of death : 15/07/80
Lung	Lob. sin:
	Grey hard area (0.2cm diam)
	Lob. inf. dxtr. med: White hard nodule (0.4cm diam)
Uterus	Horns thickened (0.4cm diam)

MICROSCOPIC FINDINGS

Lung	MALIGNANT TUMOUR alveogenic carcinoma
	Pneumonia
Ovary/1	Cysts
Ovary/2	Cysts
Uterus	Hyperplasia secretory

KWG 0519 - Mouse Chronic Toxicity Study
Full Macro/Micro Report

Rat No: J79
SEX: Female
DOSE LEVEL: 2000ppm KWG 0519

MACROSCOPIC FINDINGS

	Mode of death : Terminal kill
	Days under test : 735
	Date of death : 15/07/80
Lung	Two whitish thickenings (0.3cm diam)
Ovary	Right: Enlarged contains clear fluid
Uterus	Left horn: Cyst (0.1cm diam)

MICROSCOPIC FINDINGS

Adrenal/1	Pigmentation (severe)
Adrenal/2	Pigmentation (severe)
Bone (femur)	No tissue available
Liver	Hepatocytic hyperpigmentation (minimal)
Lung	Atelectasis
Ovary/1	Cysts
Spleen	Haematopoiesis (minimal)
Stomach	Inflammation chronic
Uterus	Hyperplasia secretory

KWG 0519 - Mouse Chronic Toxicity Study
Full Macro/Micro Report

Rat No: 38C
SEX: Female
DOSE LEVEL: 2000ppm KWG 0519

MACROSCOPIC FINDINGS

Mode of death	: Interim death
Days under test	: 734
Date of death	: 14/07/80
Condition at necropsy	Autolysis (few organs)
Adrenal gland	Left: Enlarged
Liver	Enlarged
	Yellow black discolouration
Lung	Flesh coloured
Spleen	Enlarged (4.2 x 1.0cm)

MICROSCOPIC FINDINGS

Kidney/1	MALIGNANT LYMPHOMA
Liver	MALIGNANT LYMPHOMA
Lung	Normal
Ovary/1	MALIGNANT LYMPHOMA
Ovary/2	MALIGNANT LYMPHOMA
Pancreas	MALIGNANT LYMPHOMA
Spleen	MALIGNANT LYMPHOMA
Thyroid/1	No tissue available
Thyroid/2	No tissue available
Urinary bladder	MALIGNANT LYMPHOMA
Lymph node	MALIGNANT LYMPHOMA

KWG 0519 - Mouse Chronic Toxicity Study
Full Macro/Micro Report

Rat No: 381
SEX: Female
DOSE LEVEL: 2000ppm KWG 0519

MACROSCOPIC FINDINGS

	Mode of death : Interim death
	Days under test : 706
	Date of death : 16/06/80
Adrenal gland	Left: Enlarged
Liver	Enlarged
	Multiple dark brown nodules (1.2cm diam)
Lung	Flesh coloured
Spleen	Enlarged (2.2 x 0.7cm)
Adipose tissue	Compacted

MICROSCOPIC FINDINGS

Adrenal/1	Hyperplastic nodule
	Congestion
Adrenal/2	Congestion
Bone marrow (femur)	Haematopoiesis (moderate)
Brain	Fat vacuoles
Heart	MALIGNANT LYMPHOMA
Kidney/1	Congestion
	Interstitial nephritis (minimal)
Kidney/2	Congestion
	Interstitial nephritis (minimal)
Liver	BENIGN TUMOUR hepatocellular adenoma
	Hyperplastic nodules
Lung	Pneumonia
	Congestion
Ovary/1	Hyperplasia papillomatous
Pancreas	Autolysis
Skeletal muscle	MALIGNANT LYMPHOMA
Spleen	MALIGNANT LYMPHOMA
Thyroid/1	No tissue available
Thyroid/2	No tissue available
Urinary bladder	MALIGNANT LYMPHOMA
Uterus	Normal
Lymph node	No tissue available
Mesentery	MALIGNANT LYMPHOMA
Trachea	Inflammation chronic

KWG 0519 - Mouse Chronic Toxicity Study
Full Macro/Micro Report

Rat No: 332
SEX: Female
DOSE LEVEL: 2000ppm KWG 0519

MACROSCOPIC FINDINGS

	Mode of death : Interim death
	Days under test : 591
	Date of death : 22/02/80
Lung	Lob. inf. dxtr. lat: Flesh coloured
Spleen	Enlarged (2.8 x 0.5cm)
Thymus	Beige hard nodule (1.3cm diam)
Uterus	Horns thickened (0.3cm diam)

MICROSCOPIC FINDINGS

Adrenal/1	BENIGN TUMOUR cortical adenoma
Heart	MALIGNANT LYMPHOMA
Kidney/1	MALIGNANT LYMPHOMA
Kidney/2	MALIGNANT LYMPHOMA
Liver	MALIGNANT LYMPHOMA
Lung	MALIGNANT LYMPHOMA
Ovary/1	Atrophy
	Haemorrhagic cyst
Ovary/2	Atrophy
Spleen	MALIGNANT LYMPHOMA
Uterus	Hyperplasia secretory
Thymus	MALIGNANT LYMPHOMA

KWG 0519 - Mouse Chronic Toxicity Study
Full Macro/Micro Report

Rat No: 383
SEX: Female
DOSE LEVEL: 2000ppm KWG 0519

MACROSCOPIC FINDINGS

	Mode of death : Terminal kill
	Days under test : 735
	Date of death : 15/07/80
Lung	Lob. dxtr: Multiple dark red areas (0.1-0.3cm diam) and a hard area (0.4cm diam)
Uterus	Right horn: Cyst (0.3cm diam)

MICROSCOPIC FINDINGS

Kidney/1	Interstitial nephritis (minimal)
Kidney/2	Interstitial nephritis (minimal)
Lung	MALIGNANT TUMOUR alveogenic carcinoma
	Pneumonia
Ovary/1	Atrophy
Ovary/2	Atrophy
Uterus	Cystic endometrial hyperplasia

KWG 0519 - Mouse Chronic Toxicity Study
Full Macro/Micro Report

Rat No: 384
SEX: Female
DOSE LEVEL: 2000ppm KWG 0519

MACROSCOPIC FINDINGS

	Mode of death : Terminal kill
	Days under test : 735
	Date of death : 15/07/80
Lung	Lob. sin: Two white hard nodules (0.2 and 0.1cm diam)
Ovary	Right: Cysts (0.5cm diam)
Uterus	Enlarged (1.0 x 0.8cm)

MICROSCOPIC FINDINGS

Kidney/1	Interstitial nephritis (minimal)
Kidney/2	Interstitial nephritis (minimal)
Lung	MALIGNANT TUMOUR alveogenic carcinoma
Ovary/1	Cysts
Pituitary	No tissue available
Urinary bladder	Periarteritis
Uterus	Endometriosis

KWG 0519 - Mouse Chronic Toxicity Study
Full Macro/Micro Report

Rat No: 385
SEX: Female
DOSE LEVEL: 2000ppm KWG 0519

MACROSCOPIC FINDINGS

	Mode of death : Interim death
	Days under test : 612
	Date of death : 14/03/80
Lung	Dark foci/areas
Spleen	Enlarged (3.6 x 0.8cm)

MICROSCOPIC FINDINGS

Adrenal/1	Pigmentation (minimal)
Adrenal/2	Pigmentation (minimal)
Heart	Congestion (severe)
Kidney/1	MALIGNANT LYMPHOMA
Kidney/2	MALIGNANT LYMPHOMA
Liver	MALIGNANT LYMPHOMA
Lung	MALIGNANT LYMPHOMA
Ovary/1	MALIGNANT LYMPHOMA
Ovary/2	MALIGNANT LYMPHOMA
Pancreas	Autolysis
Pituitary	No tissue available
Spleen	MALIGNANT LYMPHOMA
Stomach	MALIGNANT LYMPHOMA
Thyroid/1	MALIGNANT LYMPHOMA
Thyroid/2	MALIGNANT LYMPHOMA
Urinary bladder	MALIGNANT LYMPHOMA
Uterus	MALIGNANT LYMPHOMA

KWG 0519 - Mouse Chronic Toxicity Study
Full Macro/Micro Report

Rat No: 386
SEX: Female
DOSE LEVEL: 2000ppm KWG 0519

MACROSCOPIC FINDINGS

	Mode of death : Interim death
	Days under test : 627
	Date of death : 29/03/80
Condition at necropsy	Moribund
	No significant findings noted

MICROSCOPIC FINDINGS

Bone (femur)	No tissue available
Kidney/1	Pyelonephritis (moderate)
Kidney/2	Pyelonephritis (moderate)
Liver	Mononuclear cells (severe)
	Congestion (severe)
Lung	Congestion (severe)
Ovary/1	No tissue available
Ovary/2	No tissue available
Pituitary	No tissue available
Sciatic nerve	No tissue available
Skeletal muscle	No tissue available
Thyroid/1	No tissue available
Thyroid/2	No tissue available
Uterus	Cystic endometrial hyperplasia

KWG 0519 - Mouse Chronic Toxicity Study
Full Macro/Micro Report

Rat No: 387
SEX: Female
DOSE LEVEL: 2000ppm KWG 0519

MACROSCOPIC FINDINGS

	Mode of death : Interim death
	Days under test : 640
	Date of death : 11/04/80
Gall bladder	Enlarged (0.5cm diam)
Kidney	Marbled surface
Stomach	Mucosal bleeding

MICROSCOPIC FINDINGS

Adrenal/1	Pigmentation (moderate)
Adrenal/2	Pigmentation (moderate)
Brain	Gliosis
Heart	Pericarditis
Kidney/1	Interstitial nephritis
Kidney/2	Interstitial nephritis
Liver	Fat vacuoles
Ovary/1	No tissue available
Ovary/2	No tissue available
Spleen	Haematopoiesis (moderate)
Stomach	Mucoid cyst (minimal)
	Hyperkeratosis
	Ulceration
Uterus	Cystic endometrial hyperplasia
Mesentery	Inflammation chronic

KWG 0519 - Mouse Chronic Toxicity Study
Full Macro/Micro Report

Rat No: 388
SEX: Female
DOSE LEVEL: 2000ppm KWG 0519

MACROSCOPIC FINDINGS

	Mode of death : Terminal kill
	Days under test : 735
	Date of death : 15/07/80
Ovary	Left: Cysts (0.4cm diam)
Spleen	Enlarged (2.4 x 0.6cm)
Uterus	Both horns thickened (0.4cm)
	Left horn: Cyst (0.3cm diam)

MICROSCOPIC FINDINGS

Brain	Calcification
Kidney/1	Interstitial nephritis (minimal)
Kidney/2	Interstitial nephritis (minimal)
Liver	Mononuclear cells (minimal)
Lung	Pneumonia
Ovary/1	Cysts
Ovary/2	Cysts
Sciatic nerve	No tissue available
Spleen	Hypertrophy
Urinary bladder	Inflammation chronic
Uterus	BENIGN TUMOUR adenoma
Mesentery	Peritonitis

KWG 0519 - Mouse Chronic Toxicity Study
Full Macro/Micro Report

Rat No: 389
SEX: Female
DOSE LEVEL: 2000ppm KWG 0519

MACROSCOPIC FINDINGS

	Mode of death : Terminal kill
	Days under test : 735
	Date of death : 15/07/80
Liver	Nodular
Ovary	Right: Cysts (0.3cm diam)

MICROSCOPIC FINDINGS

Liver	Hyperplastic nodule
Lung	Atelectasis
Ovary/1	Atrophy
Ovary/2	Atrophy
Pituitary	Haemorrhagic cyst
Thyroid/1	No tissue available
Thyroid/2	No tissue available
Uterus	Hyperplasia secretory

KWG 0519 - Mouse Chronic Toxicity Study
Full Macro/Micro Report

Rat No: 390
SEX: Female
DOSE LEVEL: 2000ppm KWG 0519

MACROSCOPIC FINDINGS

	Mode of death : Interim death
	Days under test : 554
	Date of death : 16/01/80
Cranium	Indurated
Femur	Right: Hard nodule (0.5cm diam)
Intestine	Reddish contents
Liver	Enlarged
Spleen	Enlarged (4.6 x 1.2cm), soft, isolated yellow/beige foci/areas
Stomach	Mucosal bleeding
Uterus	Body enlarged (1.1cm diam) hard

MICROSCOPIC FINDINGS

Kidney/1	MALIGNANT LYMPHOMA
Kidney/2	MALIGNANT LYMPHOMA
Liver	MALIGNANT LYMPHOMA
Ovary/1	Atrophy
	Cysts
Ovary/2	Atrophy
	Cysts
Pancreas	Autolysis
Pituitary	No tissue available
Spleen	Infarct
	MALIGNANT LYMPHOMA
Stomach	Normal
Uterus	MALIGNANT TUMOUR leiomyosarcoma

KWG 0519 - Mouse Chronic Toxicity Study
Full Macro/Micro Report

Rat No: 391
SEX: Female
DOSE LEVEL: 2000ppm KWG 0519

MACROSCOPIC FINDINGS

	Mode of death : Terminal kill
	Days under test : 735
	Date of death : 15/07/80
Lung	Isolated beige foci (0.2cm diam)
Pancreas	Hardened
Uterus	Enlarged (0.4cm diam)

MICROSCOPIC FINDINGS

Liver	Mononuclear cells (minimal)
	Hyperplastic nodule
	Hepatocytic hyperpigmentation
Lung	MALIGNANT TUMOUR alveogenic carcinoma
Ovary/1	Atrophy
Ovary/2	Atrophy
Pancreas	Normal
Sciatic nerve	No tissue available
Stomach	Mucoid cyst (minimal)
Thyroid/1	Cysts (minimal)
Thyroid/2	Cysts (minimal)
Uterus	Endometriosis

KWG 0519 - Mouse Chronic Toxicity Study
Full Macro/Micro Report

Rat No: 392
SEX: Female
DOSE LEVEL: 2000ppm KWG 0519

MACROSCOPIC FINDINGS

	Mode of death : Interim death
	Days under test : 395
	Date of death : 10/08/79
Intestine	Haemorrhagic contents
Stomach	Mucosal bleeding

MICROSCOPIC FINDINGS

Adrenal/1	No tissue available
Adrenal/2	No tissue available
Kidney/1	Congestion
Kidney/2	Congestion
Liver	Autolysis (partial)
Ovary/1	Atrophy
Ovary/2	Atrophy
Pancreas	Autolysis (partial)
Spleen	Autolysis (partial)
Stomach	Ulceration
Uterus	Normal
Intestine	Autolysis

KWG 0519 - Mouse Chronic Toxicity Study
Full Macro/Micro Report

Rat No: 393
SEX: Female
DOSE LEVEL: 2000ppm KWG 0519

MACROSCOPIC FINDINGS

	Mode of death : Interim death
	Days under test : 369
	Date of death : 15/07/79
Intestine	Haemorrhagic contents
Stomach	Mucosal bleeding

MICROSCOPIC FINDINGS

Adrenal/1	Hyperplasia glomerulosa
Adrenal/2	Hyperplasia glomerulosa
Heart	Congestion
Lung	Congestion
Ovary/1	Hypertrophic corpora lutea
Ovary/2	Hypertrophic corpora lutea
Pancreas	Autolysis (partial)
Pituitary	No tissue available
Stomach	Hyperkeratosis
Uterus	Normal
Intestine	Autolysis

KWG 0519 - Mouse Chronic Toxicity Study
Full Macro/Micro Report

Rat No: 394
SEX: Female
DOSE LEVEL: 2000ppm KWG 0519

MACROSCOPIC FINDINGS

	Mode of death : Interim death
	Days under test : 682
	Date of death : 23/05/80
Condition at necropsy	Moribund
Kidney	Right: Beige-white areas (0.4cm diam)
Liver	Enlarged
Lung	Dark red foci/areas
Spleen	Enlarged (4.6 x 1.1cm)
Uterus	Right horn: Thickened (0.6cm diam) contains watery fluid
	Left horn: Thickened (1.5cm diam) hard contains yellow paste

MICROSCOPIC FINDINGS

Heart	Congestion
Kidney/1	MALIGNANT LYMPHOMA
Kidney/2	MALIGNANT LYMPHOMA
Liver	MALIGNANT LYMPHOMA
Lung	MALIGNANT TUMOUR alveogenic carcinoma
	Congestion
Ovary/1	Atrophy
Ovary/2	Atrophy
Pancreas	No tissue available
Pituitary	No tissue available
Spleen	MALIGNANT LYMPHOMA
Urinary bladder	Periarteritis
Uterus	Ectasia simple
	Endometritis

KWG 0519 - Mouse Chronic Toxicity Study
Full Macro/Micro Report

Rat No: 395
SEX: Female
DOSE LEVEL: 2000ppm KWG 0519

MACROSCOPIC FINDINGS

	Mode of death : Interim death
	Days under test : 618
	Date of death : 20/03/80
Condition at necropsy	Autolysis (few organs)
Liver	Enlarged
	Black-white foci
Lung	Sand coloured
Spleen	Enlarged (2.4 x 0.6cm)
Uterus	Neck: Thickened and hard (1.5cm diam)
	Right horn: Thickened (0.4cm diam)

MICROSCOPIC FINDINGS

Heart	Hypertrophy
Kidney/1	Autolysis (partial)
Kidney/2	Autolysis (partial)
Liver	Autolysis
	Hypertrophy
Lung	Normal
Ovary/1	Atrophy
Ovary/2	Atrophy
Pancreas	Autolysis
Pituitary	Autolysis
Spleen	No tissue available
Urinary bladder	Autolysis
Uterus	Normal
Cervix	MALIGNANT TUMOUR leiomyosarcoma

KWG 0519 - Mouse Chronic Toxicity Study
Full Macro/Micro Report

Rat No: 396
SEX: Female
DOSE LEVEL: 2000ppm KWG 0519

MACROSCOPIC FINDINGS

Mode of death	: Interim death
Days under test	: 652
Date of death	: 23/04/80
Condition at necropsy	Moribund
General observations	Periphery of eye inflammed
Kidney	Right: Soft beige area (0.7cm diam) adjacent to hilus
Liver	Enlarged
Lung	Dark red foci/areas
Spleen	Enlarged (2.5 x 0.6cm)

MICROSCOPIC FINDINGS

Adrenal/1	MALIGNANT LYMPHOMA
Adrenal/2	MALIGNANT LYMPHOMA
Bone (femur)	MALIGNANT LYMPHOMA
Heart	Inflammation chronic
Kidney/1	MALIGNANT LYMPHOMA
Kidney/2	MALIGNANT LYMPHOMA
Liver	MALIGNANT LYMPHOMA
Lung	MALIGNANT LYMPHOMA
Ovary/1	No tissue available
Ovary/2	No tissue available
Pancreas	MALIGNANT LYMPHOMA
Skeletal muscle	MALIGNANT LYMPHOMA
Spleen	MALIGNANT LYMPHOMA
Stomach	MALIGNANT LYMPHOMA
Thyroid/1	MALIGNANT LYMPHOMA
Thyroid/2	MALIGNANT LYMPHOMA
Urinary bladder	MALIGNANT LYMPHOMA
Trachea	MALIGNANT LYMPHOMA

KWG 0519 - Mouse Chronic Toxicity Study
Full Macro/Micro Report

Rat No: 397
SEX: Female
DOSE LEVEL: 2000ppm KWG 0519

MACROSCOPIC FINDINGS

	Mode of death : Interim death
	Days under test : 355
	Date of death : 01/07/79
Condition at necropsy	Autolysis (few organs)
Liver	Enlarged (3.5cm diam)
Lung	Dark/red coloured
Spleen	Enlarged (4.6 x 1.5cm, weight 2.4g)
Stomach	Mucosal bleeding

MICROSCOPIC FINDINGS

Adrenal/1	Pigmentation (minimal)
Adrenal/2	Pigmentation (minimal)
Kidney/1	Fibrosis
	Tubulopathy
Kidney/2	Fibrosis
	Tubulopathy
Liver	MALIGNANT LYMPHOMA
Lung	MALIGNANT LYMPHOMA
Ovary/1	Atrophy
Ovary/2	Atrophy
Pituitary	No tissue available
Sciatic nerve	No tissue available
Skeletal muscle	No tissue available
Spleen	MALIGNANT LYMPHOMA
Stomach	Ulceration
Urinary bladder	Inflammation chronic
Uterus	Normal
Cervical lymph node	Hypertrophy

KWG 0519 - Mouse Chronic Toxicity Study
Full Macro/Micro Report

Rat No: 398
SEX: Female
DOSE LEVEL: 2000ppm KWG 0519

MACROSCOPIC FINDINGS

	Mode of death : Terminal kill
	Days under test : 735
	Date of death : 15/07/80
Uterus	Cysts (0.1cm diam)

MICROSCOPIC FINDINGS

Adrenal/1	BENIGN TUMOUR phaeochromocytoma
Lung	Pneumonia
Ovary/1	Atrophy
	Haemorrhagic cyst
Ovary/2	Atrophy
Spleen	Haematopoiesis (minimal)
Thyroid/1	Cysts (minimal)
Thyroid/2	Cysts (minimal)
Urinary bladder	Hyperplasia papillomatous
Uterus	Cystic endometrial hyperplasia

KWG 0519 - Mouse Chronic Toxicity Stuoy
Full Macro/Micro Report

Rat No: 399
SEX: Female
DOSE LEVEL: 2000ppm KWG 0519

MACROSCOPIC FINDINGS

	Mode of death : Terminal kill
	Days under test : 735
	Date of death : 15/07/80
Lung	Lab. sin: Grey thickening (0.2cm diam)
Ovary	Left: Cysts (0.3cm diam)
Uterus	Enlarged (0.4cm diam)

MICROSCOPIC FINDINGS

Liver	Fat vacuoles (minimal)
	Hepatocytic hyperpigmentation (minimal)
Lung	MALIGNANT TUMOUR alveogenic carcinoma
Ovary/1	BENIGN TUMOUR arrhenoblastoma
Ovary/2	BENIGN TUMOUR arrhenoblastoma
Sciatic nerve	No tissue available
Uterus	Cystic endometrial hyperplasia

KWG 0519 - Mouse Chronic Toxicity Study
Full Macro/Micro Report

Rat No: 400
SEX: Female
DOSE LEVEL: 2000ppm KWG 0519

MACROSCOPIC FINDINGS

	Mode of death : Terminal kill
	Days under test : 735
	Date of death : 15/07/80
Liver	Lob. sin: Clay coloured nodular
	Proc. pap: Cyst (0.3cm diam)
	Lob. caud: Cyst (0.2cm diam)
Lung	Flesh coloured
Uterus	Enlarged nodular multiple cysts (0.5cm diam)

MICROSCOPIC FINDINGS

Adrenal/1	Pigmentation
	Hypertrophy
Kidney/1	Interstitial nephritis (minimal)
Kidney/2	Interstitial nephritis (minimal)
Liver	Fat vacuoles (moderate)
	Cysts
	Hepatocytic hyperpigmentation (minimal)
	Hyperplastic nodules
Lung	Pneumonia
Ovary/1	Atrophy
	Cysts
Ovary/2	Atrophy
Pancreas	Atrophy
	Periarteritis
Sciatic nerve	No tissue available
Spleen	Haematopoiesis (moderate)
Thyroid/1	No tissue available
Thyroid/2	No tissue available
Uterus	Endometriosis
	Endometritis

Vertraulich
Eigentum der Firma Bayer AG
Benutzung, Verwertung oder Weitergabe nur mit Einwilligung der Bayer AG gestattet

Contains NO CBD
377

PERIARTERITIS :		0	1	0	0
VENTRICULAR DILATATION :		0	0	0	1
DEGENERATION MUSCULAR :		0	0	1	0
PERICARDITIS :		0	1	2	0
THICKENING ENDOCARDIUM :		1	0	0	0
TRACHEA	EXAMINED	1	0	0	0
LEUKEMIC DEPOSITS :		1	0	0	0
LUNG	EXAMINED	49	50	49	49
AUTOLYSIS :		2	0	2	0
THROMBOSIS :		0	0	2	0
EDEMA :		1	10	5	4
NECROSIS :		0	0	1	0
FIBROSIS :		0	0	1	0
BRONCHOPNEUMONIA :		0	1	2	0
HEMORRHAGE :		0	7	2	0
ADENOMATOSIS :		1	2	3	1
PLEURITIS :		1	0	0	0
PIGMENTATION :		1	0	0	0
PNEUMONIA :		10	14	24	5
LEUKOCYTOSIS :		0	0	1	0
CONGESTION :		5	12	16	13
ATELECTASIS :		6	3	1	2
EMPHYSEMA :		1	4	2	0
ABSENT :		1	0	0	1
MUCOID CYST :		0	0	0	1
LEUKEMIC DEPOSITS :		5	3	2	4
AUTOLYSIS PARTIAL :		4	3	3	6
ECTASIA VASCULAR :		0	1	1	0
THICKENED ALVEOLAR WALLS :		0	1	2	0
NORMAL :		0	2	0	0

SALIVARY GLAND	EXAMINED	0	2	1	0
CALCIFICATION :		0	1	0	0
INFLAMMATION CHRONIC :		0	0	1	0
NORMAL :		0	1	0	0
STOMACH	EXAMINED	48	50	48	50
AUTOLYSIS :		8	2	4	8
CALCIFICATION :		0	0	1	0
FIBROSIS :		0	0	1	0
INFLAMMATION CHRONIC :		0	1	1	0
INFLAMMATION CHRONIC :		4	2	2	0
HEMORRHAGE :		0	2	1	1
MONONUCLEAR CELLS :		1	0	0	2
PIGMENTATION :		0	0	0	1
UNREADABLE :		1	0	1	1
ABSENT :		2	0	1	0
CYSTS :		0	0	0	1
MUCOID CYST :		1	5	6	2
LEUKEMIC DEPOSITS :		4	1	1	0
AUTOLYSIS PARTIAL :		7	11	7	4
ECTASIA VASCULAR :		0	0	2	0
NORMAL :		1	3	3	3
LIVER	EXAMINED	50	50	49	50
HYPERPLASIA :		0	0	0	3
AUTOLYSIS :		4	2	1	3
INFARCT :		0	1	2	0
CALCIFICATION :		1	1	1	5
FAT VACUOLES :		0	7	4	0
NECROSIS :		2	0	0	1
FIBROSIS :		0	1	0	0
INFLAMMATION GRANULOMATOUS :		0	1	0	0
HEMORRHAGE :		0	3	1	3
MONONUCLEAR CELLS :		3	2	2	3
PIGMENTATION :		1	0	1	0

BAYER AG

AMYLOID :		3	1	1	6
HEMATOPOIESIS :		0	3	0	0
CONGESTION :		3	4	6	4
HYPERPLASTIC NODULE :		1	5	7	3
HYPERTROPHY :		0	0	1	1
VACUOLIZATION :		1	2	1	1
PERICHOLANGITIS :		0	1	0	0
CYSTS :		0	1	0	1
LEUKEMIC DEPOSITS :		9	5	4	7
INFLAMMATION PORTAL :		0	0	0	1
AUTOLYSIS PARTIAL :		3	13	10	5
HYALINOSIS :		0	1	0	1
HEPATOCYTIC HYPERPIGMENTATION		4	0	0	9
HEMORRAGIC CYST :		0	0	5	0
HYPERPLASTIC NODULES :		7	1	2	7
HYPERPLASIA FOCAL :		2	0	0	2
NORMAL :		2	2	3	1
PANCREAS	EXAMINED	46	47	44	50
AUTOLYSIS :		5	8	7	9
FIBROSIS :		0	0	0	1
INFLAMMATION CHRONIC :		1	2	0	3
AMYLOID :		0	0	1	1
HYPERPLASIA ISLETS :		2	0	0	0
CONGESTION :		0	0	1	1
UNREADABLE :		2	0	0	0
ABSENT :		4	3	5	0
LEUKEMIC DEPOSITS :		4	2	1	2
AUTOLYSIS PARTIAL :		4	7	7	4
CYSTIC DYSPLASIA :		0	1	0	0
FATTY CYST :		0	3	0	0
NORMAL :		2	1	2	4

THYMUS	EXAMINED	3	1	1	2
ABSENT :		1	1	0	0
AUTOLYSIS PARTIAL :		0	0	0	1
SPLEEN	EXAMINED	50	50	49	50
AUTOLYSIS :		2	5	7	9
EDEMA :		0	1	0	0
FIBROSIS :		0	1	0	0
HYPERPLASIA LYMPHOID :		3	2	2	2
HEMORRHAGE :		1	0	0	0
PIGMENTATION :		3	0	0	3
AMYLOID :		0	0	1	1
HEMATOPOIESIS :		13	22	15	12
ATROPHY :		0	0	0	1
CONGESTION :		1	2	3	0
HYPERTROPHY :		0	0	1	1
AUTOLYSIS PARTIAL :		5	5	5	6
ECTASIA VASCULAR :		0	1	0	0
HEMORRAGIC CYST :		1	0	0	0
HYPOPLASIA LYMPHOID :		0	0	0	1
NORMAL :		1	1	2	1
BONE MARROW	EXAMINED	1	0	1	1
HYPERPLASIA :		0	0	0	1
APLASIA MYELOID :		0	0	1	0
HYPERPLASIA MEGAKARYOCYTE :		1	0	0	0
KIDNEYS	EXAMINED	50	50	49	50
AUTOLYSIS :		2	0	2	2
CALCIFICATION :		2	7	3	3
NECROSIS :		0	1	0	0
FIBROSIS :		0	7	0	1
PYELITIS :		1	0	0	0
HYDRONEPHROSIS :		3	1	2	2
HEMORRHAGE :		1	0	0	0
AMYLOID :		0	0	0	2

BAYER AG BAYER AG BAYER AG

CONGESTION :	2	2	3	3
TUBULOPATHY :	2	14	11	5
INTERSTITIAL NEPHRITIS :	26	10	9	22
CYSTS :	15	8	9	10
LEUKEMIC DEPOSITS :	9	2	2	7
PYELONEPHRITIS :	1	1	1	0
AUTOLYSIS PARTIAL :	4	9	10	6
ECTASIA VASCULAR :	0	1	0	0
DILATATION OF GLOMERULAR LOOPS	1	3	1	0
DILATATION OF RENAL PELVIS :	0	7	1	1
PROGRESSIVE NEPHROPATHY :	3	10	3	1
BLADDER EXAMINED	46	50	48	50
HYPERPLASIA:	1	0	0	1
AUTOLYSIS :	8	2	5	8
NECROSIS :	0	0	0	2
INFLAMMATION CHRONIC :	0	1	0	0
INFLAMMATION GRANULOMATOUS :	0	0	2	0
INFLAMMATION CHRONIC :	1	0	2	1
HEMORRHAGE :	0	0	0	1
MONONUCLEAR CELLS :	0	0	0	2
ECTASIA SIMPLE :	0	4	0	1
HYPERTROPHY :	0	0	0	1
UNREADABLE :	0	0	0	2
ABSENT :	4	0	1	0
COAGULUM :	0	0	1	3
LEUKEMIC DEPOSITS :	5	2	0	2
AUTOLYSIS PARTIAL :	9	16	8	8
INFLAMMATION ACUTE GLANDULAR :	0	1	0	0
HYPERPLASIA PAPILLOMATOUS :	5	1	1	2
NORMAL :	0	2	2	0

PITUITARY	EXAMINED	29	29	29	22
AUTOLYSIS :		0	0	3	2
UNREADABLE :		2	0	0	2
ABSENT :		21	21	19	28
CYSTS :		0	1	0	0
AUTOLYSIS PARTIAL :		2	1	0	0
NORMAL :		2	0	1	0
THYROIDS	EXAMINED	28	24	34	39
AUTOLYSIS :		1	0	2	3
ABSENT :		22	26	15	11
CYSTS :		2	2	2	10
LEUKEMIC DEPOSITS :		1	0	0	0
AUTOLYSIS PARTIAL :		2	6	7	4
NORMAL :		0	0	1	0
ADRENALS	EXAMINED	46	48	47	47
AUTOLYSIS :		1	0	3	2
CALCIFICATION :		0	0	0	1
PIGMENT :		1	0	0	0
PIGMENTATION :		2	5	6	2
AMYLOID :		0	0	1	1
HYPERPLASTIC NODULE :		1	1	0	0
UNREADABLE :		1	0	0	1
ABSENT :		4	2	2	3
LEUKEMIC DEPOSITS :		5	0	0	3
AUTOLYSIS PARTIAL :		3	2	2	4
HEMORRAGIC CYST :		0	0	1	1
HYPERPLASIA OF THE GLOMERULAR		0	1	0	1
NORMAL :		0	1	1	1
SKELETAL MUSCLE	EXAMINED	49	50	48	45
AUTOLYSIS :		1	0	0	0
EDEMA :		0	0	0	1
CALCIFICATION :		0	1	0	0
MONONUCLEAR CELLS :		0	0	0	3

BAYER AG BAYER AG BAYER AG

ATROPHY :		0	1	0	0
UNREADABLE :		1	0	0	0
ABSENT :		1	0	1	5
VACUOLIZATION :		0	1	0	0
LEUKEMIC DEPOSITS :		3	0	1	1
AUTOLYSIS PARTIAL :		2	0	0	2
FATTY CYST :		0	0	2	0
SKIN	EXAMINED	0	0	1	3
NECROSIS :		0	0	0	1
INFLAMMATION CHRONIC :		0	0	1	1
MONONUCLEAR CELLS :		0	0	0	1
SCIATIC NERVE	EXAMINED	45	45	38	42
AUTOLYSIS :		1	0	0	0
UNREADABLE :		1	0	0	0
ABSENT :		5	5	10	7
LEUKEMIC DEPOSITS :		1	0	0	0
AUTOLYSIS PARTIAL :		2	0	0	1
BONE	EXAMINED	1	0	1	1
MESENTERY	EXAMINED	5	2	1	2
INFLAMMATION CHRONIC :		1	0	0	0
LEUKEMIC DEPOSITS :		3	2	1	2
TESTES	EXAMINED	49	50	48	50
ATROPHY SEMINIFEROUS :		9	8	6	5
AZOOSPERMIA :		0	0	2	0
AUTOLYSIS :		1	1	2	0
CALCIFICATION :		12	5	7	10
INFLAMMATION CHRONIC :		0	1	0	0
PIGMENTATION :		1	0	0	0
SPERMATOCELE :		4	4	1	11
ABSENT :		1	0	1	0
CYSTS :		0	0	1	0
LEUKEMIC DEPOSITS :		1	0	0	0
AUTOLYSIS PARTIAL :		2	1	4	5

NORMAL :		0	1	0	0
PROSTATE	EXAMINED	0	0	1	0
COAGULUM :		0	0	1	0
SEMINAL VESICLES	EXAMINED	6	6	7	3
ATROPHY EPITHELIAL :		5	0	0	3
CALCIFICATION :		0	1	0	0
HEMORRHAGE :		0	1	0	0
ECTASIA SIMPLE :		2	0	0	2
COAGULUM :		5	6	5	3
CYSTS :		0	0	1	0
AUTOLYSIS PARTIAL :		1	0	1	0
HEMORRAGIC CYST :		0	0	1	0
INFLAMMATION ACUTE GLANDULAR :		0	1	0	0
NORMAL :		1	0	0	0
FAT	EXAMINED	1	2	0	0
LEUKEMIC DEPOSITS :		0	1	0	0
PARATHYROIDS	EXAMINED	0	0	1	0
INTESTINE	EXAMINED	1	1	2	3
AUTOLYSIS :		0	0	0	1
HEMORRHAGE :		0	0	0	1
AUTOLYSIS PARTIAL :		0	0	0	1
NORMAL :		1	1	0	1
FEMUR	EXAMINED	45	49	47	44
ABSENT :		4	1	0	5
AUTOLYSIS PARTIAL :		0	0	0	2
LYMPH NODE	EXAMINED	8	3	2	2
INFARCT :		0	1	0	0
HYPERPLASIA LYMPHOID :		1	1	0	0
AUTOLYSIS PARTIAL :		1	0	0	0

BAYER AG

IMN.10

UNKNOWN TISSUE OR ANY OT EXAMINED	0	0	0	2
UNREADABLE :	0	0	0	1
AUTOLYSIS PARTIAL :	0	0	0	1

SFN. 1 CHRONIC TOXICITY STUDY IN MICE: SYSTEMATIC HISTOPATOLOGY

PRODUCT : KWG 0519 TIME : 105 WEEKS
ROUTE : DIETARY

FREQUENCY OF ALTERATIONS

TABLE 10 NONTUMOR. LESIONS
SYSTEMATIC - FEMALES

GROUP		CONTROL	I	II	III
DOSE IN PPM		0	125	500	2000
EXAMINED		16	16	17	19
BRAIN	EXAMINED	16	16	17	19
CALCIFICATION :		0	0	0	1
FAT VACUOLES :		1	0	1	0
GLIOSIS :		0	3	2	0
HEMORRHAGE :		1	0	0	0
VENTRICULAR DILATATION :		1	0	0	0
MENINGITIS :		0	0	1	0
HEART	EXAMINED	16	16	17	19
NORMAL :		0	1	0	0
LUNG	EXAMINED	16	16	17	19
EDEMA :		1	0	0	0
HEMORRHAGE :		1	0	1	0
ADENOMATOSIS :		0	1	0	0
PIGMENTATION :		1	0	0	0
PNEUMONIA :		5	6	11	12
ATELECTASIS :		2	4	3	3
EMPHYSEMA :		0	1	0	0
OSSEOUS METAPLASIA :		0	1	0	0
LEUKEMIC DEPOSITS :		1	1	1	0
THICKENED ALVEOLAR WALLS :		0	0	2	2
NORMAL :		1	0	0	0
STOMACH	EXAMINED	16	16	17	18
HYPERKERATOSIS :		1	1	0	0
INFLAMMATION CHRONIC :		2	1	0	1
ABSENT :		0	0	0	1

BAYER AG

MUCOID CYST :		3	2	4	2
LEUKEMIC DEPOSITS :		0	1	0	0
HYPERPLASIA PAPILLOMATOUS :		1	0	0	0
LIVER	EXAMINED	16	16	17	19
INFARCT :		0	0	0	1
THROMBOSIS :		0	0	0	1
FAT VACUOLES :		6	0	0	4
MONONUCLEAR CELLS :		6	4	1	4
PIGMENTATION :		0	0	1	0
CONGESTION :		0	1	0	1
HYPERPLASTIC NODULE :		1	0	0	2
HYPERTROPHY :		1	1	0	0
VACUOLIZATION :		6	2	5	0
CYSTS :		1	0	0	1
LEUKEMIC DEPOSITS :		0	2	1	0
HEPATOCYTIC HYPERPIGMENTATION		4	0	0	5
HYPERPLASTIC NODULES :		0	0	0	2
PANCREAS	EXAMINED	15	16	17	19
ATROPHY EPITHELIAL :		1	0	0	0
FIBROSIS :		1	0	0	0
INFLAMMATION CHRONIC :		0	0	1	2
MONONUCLEAR CELLS :		0	1	0	0
ATROPHY :		0	1	0	1
ABSENT :		1	0	0	0
CYSTS :		0	1	0	0
LEUKEMIC DEPOSITS :		0	1	1	0
PERIARTERITIS :		2	0	1	1
FATTY CYST :		0	1	0	0
NORMAL :		1	0	0	1
THYMUS	EXAMINED	1	0	0	0

SPLEEN	EXAMINED	16	16	17	19
HYPERPLASIA LYMPHOID :		1	1	0	0
HEMATOPOIESIS :		11	10	15	11
CONGESTION :		0	0	0	1
HYPERTROPHY :		0	0	0	1
HEMORRAGIC CYST :		1	0	0	0
NORMAL :		1	0	0	0
KIDNEYS	EXAMINED	16	16	17	19
PYELITIS :		1	0	0	0
HYDRONEPHROSIS :		1	0	0	0
TUBULOPATHY :		1	1	1	1
INTERSTITIAL NEPHRITIS :		9	8	6	9
CYSTS :		3	0	4	0
LEUKEMIC DEPOSITS :		0	1	1	0
PYELONEPHRITIS :		0	3	0	0
DILATATION OF RENAL PELVIS :		1	0	0	0
PROGRESSIVE NEPHROPATHY :		0	0	1	0
NORMAL :		1	0	0	0
BLADDER	EXAMINED	16	16	17	18
INFLAMMATION GRANULOMATOUS :		0	0	0	1
INFLAMMATION CHRONIC :		6	3	2	4
ABSENT :		0	0	0	1
LEUKEMIC DEPOSITS :		0	2	1	0
PERIARTERITIS :		0	0	0	1
HYPERPLASIA PAPILLOMATOUS :		6	4	1	1
PITUITARY	EXAMINED	13	14	15	16
HEMORRHAGE :		1	0	0	0
ABSENT :		3	2	2	3
CYSTS :		1	0	0	0
HEMORRAGIC CYST :		0	0	0	1

BAYER BAYER BAYER BAYER

THYROIDS	EXAMINED	6	11	8	16
ABSENT :		10	5	9	3
CYSTS :		1	2	1	3
ADRENALS	EXAMINED	15	16	17	19
FAT VACUOLES :		1	0	1	1
PIGMENTATION :		12	7	10	7
HYPERTROPHY :		0	0	0	1
ABSENT :		1	0	0	0
CYSTS :		0	1	0	0
HYPERPLASIA OF THE GLOMERULAR		0	1	1	0
NORMAL :		0	1	0	0
SKELETAL MUSCLE	EXAMINED	15	16	17	19
ABSENT :		1	0	0	0
SCIATIC NERVE	EXAMINED	13	16	14	14
ABSENT :		3	0	2	5
BONE	EXAMINED	0	1	0	0
MESENTERY	EXAMINED	4	2	2	1
INFLAMMATION CHRONIC :		4	0	2	0
PERITONITIS :		0	0	0	1
LEUKEMIC DEPOSITS :		0	2	0	0
MAMMARY GLAND	EXAMINED	2	0	0	0
OVARIES	EXAMINED	16	16	17	19
INFLAMMATION ACUTE :		2	0	0	0
INFLAMMATION CHRONIC :		1	0	0	0
PIGMENTATION :		1	0	0	0
ATROPHY :		9	6	8	12
CYSTS :		9	10	11	9
HYPERTROPHIC CORPORA LUTEA :		1	3	3	0
CYSTIC FOLLICLE :		0	0	0	1
HEMORRAGIC CYST :		2	0	2	4
NORMAL :		0	0	1	0

UTERUS	EXAMINED	11	16	14	18
THROMBOSIS :		0	0	1	0
HYPERPLASIA POLYPOID:		2	1	0	0
HEMORRHAGE :		1	1	2	0
AMYLOID :		0	1	0	0
CYSTIC ENDOMETRIAL HYPERPLASIA		3	4	6	7
ENDOMETRIUSIS :		4	7	6	4
UNREADABLE :		0	1	0	0
ABSENT :		0	0	1	0
HYPERPLASIA SECRETORY :		3	7	4	6
ENDOMETRITIS :		0	1	0	1
HEMORRAGIC CYST :		1	1	1	0
HYPERPLASIA PAPILLOMATOUS :		0	1	0	0
NORMAL :		1	0	0	0
FEMUR	EXAMINED	15	16	17	18
HEMATOPOIESIS :		0	0	0	1
HYPOPLASIA :		0	0	1	0
UNREADABLE :		0	0	1	0
ABSENT :		1	0	0	1
LYMPH NODE	EXAMINED	0	1	1	0
HYPERTROPHY :		0	0	1	0
ABSENT :		0	0	1	0
SUBCUTANEOUS TISSUE	EXAMINED	0	1	0	0
NECROSIS :		0	1	0	0

BAYER AG

NFN. 1 CHRONIC TOXICITY STUDY IN MICE: NONSYSTEMATIC HISTOPATOLOGY

PRODUCT : KWG 0519 TIME : 105 WEEKS
ROUTE : DIETARY

FREQUENCY OF ALTERATIONS

TABLE 11 NONTUMOR. LESIONS NONSYSTEMATIC - FEMALES

GROUP		CONTROL	I	II	III
DOSE IN PPM		0	125	500	2000
EXAMINED		33	33	33	30
BRAIN	EXAMINED	32	28	28	29
AUTOLYSIS :		3	1	1	0
EDEMA :		0	0	0	1
FAT VACUOLES :		4	0	6	2
GLIOSIS :		2	0	1	1
HEMORRHAGE :		0	0	1	0
CONGESTION :		1	1	1	0
ABSENT :		1	5	5	1
LEUKEMIC DEPOSITS :		0	1	0	0
HEART	EXAMINED	33	32	33	30
AUTOLYSIS :		0	1	0	0
THROMBOSIS :		2	1	0	2
CALCIFICATION :		0	1	0	0
INFLAMMATION CHRONIC :		0	0	1	1
LEUKOCYTOSIS :		0	1	1	0
CONGESTION :		14	8	15	5
DILATED CHAMBER :		0	0	2	0
HYPERTROPHY :		0	0	0	1
LEUKEMIC DEPOSITS :		4	2	0	5
AUTOLYSIS PARTIAL :		0	2	0	0
PERICARDITIS :		0	1	2	1
TRACHEA	EXAMINED	0	0	0	3
INFLAMMATION CHRONIC :		0	0	0	1
LEUKEMIC DEPOSITS :		0	0	0	2

LUNG	EXAMINED	33	33	33	30
AUTOLYSIS :		2	1	1	0
THROMBOSIS :		1	1	0	0
EDEMA :		6	4	6	3
NECROSIS :		0	1	1	0
HYPERPLASIA LYMPHOID :		1	0	0	0
PERITONITIS :		0	0	0	1
HEMORRHAGE :		5	1	5	0
PNEUMONIA :		8	1	7	3
LEUKOCYTOSIS :		0	0	4	0
CONGESTION :		15	9	8	9
ATELECTASIS :		0	1	1	1
EMPHYSEMA :		0	1	0	0
LEUKEMIC DEPOSITS :		5	8	5	11
AUTOLYSIS PARTIAL :		0	4	3	0
THICKENED ALVEOLAR WALLS :		0	3	2	0
NORMAL :		2	0	0	2
STOMACH	EXAMINED	33	33	33	30
HYPERKERATOSIS :		1	0	0	2
AUTOLYSIS :		8	4	4	1
ULCERATION :		0	0	0	3
INFLAMMATION CHRONIC :		1	0	0	0
HEMORRHAGE :		0	3	2	0
UNREADABLE :		2	0	0	1
PAPILLOMATOUS ACANTHOSIS :		0	0	0	1
MUCOID CYST :		2	3	1	2
LEUKEMIC DEPOSITS :		1	4	4	4
AUTOLYSIS PARTIAL :		0	2	7	0
NORMAL :		3	3	2	2
DUODENUM	EXAMINED	1	1	1	0
AUTOLYSIS :		1	0	0	0
AUTOLYSIS PARTIAL :		0	0	1	0
NORMAL :		0	1	0	0

BAYER AG

LIVER	EXAMINED	32	33	33	30
AUTOLYSIS :		4	4	2	1
INFARCT :		1	0	3	0
CALCIFICATION :		1	0	0	0
FAT VACUOLES :		0	0	0	1
NECROSIS :		0	0	1	0
HEMORRHAGE :		0	1	0	0
MONONUCLEAR CELLS :		4	2	3	4
AMYLOID :		0	1	0	0
HEMATOPOIESIS :		1	0	0	0
CONGESTION :		10	6	10	5
HYPERPLASTIC NODULE :		1	1	1	2
HYPERTROPHY :		0	1	1	1
ABSENT :		1	0	0	0
VACUOLIZATION :		0	2	2	0
CYSTS :		0	0	0	1
LEUKEMIC DEPOSITS :		10	6	14	15
AUTOLYSIS PARTIAL :		6	8	8	1
HEPATOCYTIC HYPERPIGMENTATION		1	0	0	0
PERIARTERITIS :		0	0	0	1
HEMORRAGIC CYST :		1	0	0	0
HYPERPLASTIC NODULES :		0	0	0	1
NORMAL :		2	0	0	0
PANCREAS	EXAMINED	33	33	31	29
AUTOLYSIS :		9	6	6	7
EDEMA :		0	0	1	0
INFLAMMATION CHRONIC :		1	1	2	2
ATROPHY :		0	3	1	1
CONGESTION :		0	1	0	0
ABSENT :		0	0	2	1
VACUOLIZATION :		0	0	1	0
LEUKEMIC DEPOSITS :		3	6	5	6
AUTOLYSIS PARTIAL :		4	7	8	3

HEMORRAGIC CYST :		2	0	0	0
THYMUS	EXAMINED	3	3	3	5
NECROSIS :		0	0	1	0
SPLEEN	EXAMINED	33	33	33	29
AUTOLYSIS :		4	4	2	1
INFARCT :		0	0	0	1
HYPERPLASIA LYMPHOID :		0	6	1	2
HEMORRHAGE :		0	0	0	0
PIGMENTATION :		1	0	0	0
AMYLOID :		1	0	0	0
HEMATOPOIESIS :		7	4	11	3
CONGESTION :		1	2	2	1
HYPERTROPHY :		1	0	1	0
ABSENT :		0	0	0	1
AUTOLYSIS PARTIAL :		3	4	5	2
HEMORRAGIC CYST :		1	0	0	0
NORMAL :		1	0	2	0
KIDNEYS	EXAMINED	33	33	33	30
AUTOLYSIS :		4	3	0	0
CALCIFICATION :		2	0	0	1
FIBROSIS :		0	0	1	1
PYELITIS :		0	1	0	0
HYDRONEPHROSIS :		1	1	1	1
HEMORRHAGE :		0	2	0	0
CONGESTION :		2	3	3	3
TUBULOPATHY :		3	4	3	4
INTERSTITIAL NEPHRITIS :		13	1	5	4
CYSTS :		0	1	3	1
LEUKEMIC DEPOSITS :		5	11	11	11
PYELONEPHRITIS :		0	0	1	3
AUTOLYSIS PARTIAL :		2	7	8	2
DILATATION OF GLOMERULAR LOOPS		2	3	0	0
PROGRESSIVE NEPHROPATHY :		6	3	1	0

BAYER AG

NORMAL :		1	0	0	0
BLADDER	EXAMINED	33	33	32	30
AUTOLYSIS :		9	3	4	2
EDEMA :		0	1	0	0
INFLAMMATION CHRONIC :		1	2	0	3
UNREADABLE :		3	1	1	0
ABSENT :		0	0	1	0
LEUKEMIC DEPOSITS :		8	7	4	10
AUTOLYSIS PARTIAL :		0	6	13	0
PERIARTERITIS :		0	0	0	1
HYPERPLASIA PAPILLOMATOUS :		1	1	0	1
PITUITARY	EXAMINED	23	26	20	21
AUTOLYSIS :		3	1	1	1
HEMORRHAGE :		0	0	1	0
UNREADABLE :		0	1	0	0
ABSENT :		10	7	13	9
CYSTS :		1	0	0	0
THYROIDS	EXAMINED	31	25	23	19
AUTOLYSIS :		4	1	0	0
UNREADABLE :		0	0	0	1
ABSENT :		2	8	10	11
CYSTS :		2	1	0	0
LEUKEMIC DEPOSITS :		1	1	0	2
AUTOLYSIS PARTIAL :		1	4	4	1
ADRENALS	EXAMINED	33	33	32	28
AUTOLYSIS :		3	2	1	0
CALCIFICATION :		0	0	1	0
PIGMENTATION :		8	10	11	7
AMYLOID :		1	0	0	0
HEMATOPOIESIS :		0	0	1	0
CONGESTION :		0	0	0	1
HYPERPLASTIC NODULE :		1	0	0	2
ABSENT :		0	0	1	2

LEUKEMIC DEPOSITS :		3	5	1	2
AUTOLYSIS PARTIAL :		0	2	1	0
HEMORRAGIC CYST :		0	0	0	1
HYPERPLASIA OF THE GLOMERULAR		3	3	2	1
SKELETAL MUSCLE	EXAMINED	32	31	31	27
AUTOLYSIS :		3	0	0	0
ABSENT :		1	2	2	3
LEUKEMIC DEPOSITS :		4	3	3	2
AUTOLYSIS PARTIAL :		0	0	1	0
SKIN	EXAMINED	0	0	2	1
NECROSIS :		0	0	1	0
FIBROSIS :		0	0	1	0
INFLAMMATION CHRONIC :		0	0	1	0
PUS :		0	0	1	0
NORMAL :		0	0	0	1
SCIATIC NERVE	EXAMINED	30	28	28	24
AUTOLYSIS :		3	0	0	0
ABSENT :		2	5	5	6
LEUKEMIC DEPOSITS :		0	0	0	1
BONE	EXAMINED	0	0	3	1
NORMAL :		0	0	1	0
MESENTERY	EXAMINED	12	8	11	4
STEATONECROSIS :		0	1	0	0
INFLAMMATION CHRONIC :		1	0	0	1
PERITONITIS :		0	1	0	0
HEMORRHAGE :		0	0	1	0
LEUKEMIC DEPOSITS :		9	7	10	3
MAMMARY GLAND	EXAMINED	0	1	0	0
HYPERPLASIA SECRETORY :		0	1	0	0
OVARIES	EXAMINED	32	32	32	27
AUTOLYSIS :		4	2	3	0
THROMBOSIS :		0	0	1	0
INFLAMMATION ACUTE :		0	2	0	1

BAYER AG BAYER AG BAYER AG

	HYPERPLASIA POLYPOID:	0	0	0	1
	HEMORRHAGE :	1	0	1	1
	ATROPHY :	13	9	16	11
	ABSENT :	1	1	1	3
	ARTERITIS :	2	0	0	0
	CYSTS :	11	13	13	2
	LEUKEMIC DEPOSITS :	6	7	4	7
	HYPERTROPHIC CORPORA LUTEA :	5	8	0	2
	AUTOLYSIS PARTIAL :	0	1	2	0
	HEMORRAGIC CYST :	1	0	2	2
	HYPERPLASIA PAPILLOMATOUS :	0	0	0	1
	PUS :	1	2	0	0
UTERUS	EXAMINED	24	22	19	24
	THROMBOSIS :	0	1	0	0
	HYPERPLASIA POLYPOID:	2	0	3	1
	HEMORRHAGE :	3	2	0	0
	CYSTIC ENDOMETRIAL HYPERPLASIA	2	10	1	4
	SQUAMOUS METAPLASIA :	0	0	1	0
	ECTASIA SIMPLE :	0	0	0	1
	ENDOMETRIOSIS :	4	1	1	1
	UNREADABLE :	2	0	1	0
	HYPERPLASIA SECRETORY :	4	1	3	2
	LEUKEMIC DEPOSITS :	7	3	5	6
	AUTOLYSIS PARTIAL :	1	0	1	0
	ENDOMETRITIS :	3	1	0	3
	PUS :	1	0	0	0
	NORMAL :	1	2	0	7
CEREBRUM	EXAMINED	0	1	0	0
CERVICAL LYMPH NODE	EXAMINED	1	0	0	1
	HYPERTROPHY :	0	0	0	1

FAT	EXAMINED	0	1	0	0
LEUKEMIC DEPOSITS :		0	1	0	0
DIAPHRAGM	EXAMINED	0	0	2	0
LEUKEMIC DEPOSITS :		0	0	1	0
INTESTINE	EXAMINED	0	1	0	2
AUTOLYSIS :		0	1	0	2
RIGHT HIND EXTREMITY	EXAMINED	0	0	0	1
FEMUR	EXAMINED	33	31	32	28
AUTOLYSIS :		1	0	0	0
INFLAMMATION CHRONIC :		0	0	1	0
HEMATOPOIESIS :		0	0	1	1
UNREADABLE :		0	1	0	0
ABSENT :		0	2	1	2
LEUKEMIC DEPOSITS :		0	0	0	1
NORMAL :		0	0	2	0
SKULL	EXAMINED	1	0	0	1
CERVIX	EXAMINED	1	1	0	1
BODY CAVITY	EXAMINED	0	0	0	1
LYMPH NODE	EXAMINED	8	4	12	3
CRYSTALS :		0	0	1	0
CONGESTION :		0	0	1	0
HYPERTROPHY :		0	0	1	0
ABSENT :		0	0	0	1
LYMPHOCELE :		1	0	0	0
LYMPHATIC ECTASIA :		1	0	0	0
LEUKEMIC DEPOSITS :		1	0	0	0
AUTOLYSIS PARTIAL :		1	0	2	0
ABDOMINAL CAVITY	EXAMINED	0	1	0	0
STEATONECROSIS :		0	1	0	0
BODY WALL	EXAMINED	1	0	0	0
AUTOLYSIS PARTIAL :		1	0	0	0

BAYER AG

IFN. 1 CHRONIC TOXICITY STUDY IN MICE: GROUP INCIDENCE

HISTOPATOLOGY

PRODUCT : KMG 0519 TIME : 105 WEEKS
ROUTE : DIETARY

FREQUENCY OF ALTERATIONS

TABLE 12 NONTUMOR. LESIONS
GROUP INCIDENCE - FEMALES

GROUP		CONTROL	I	II	III
DOSE IN PPM		0	125	500	2000
EXAMINED		49	49	50	49
BRAIN	EXAMINED	48	44	45	48
AUTOLYSIS :		3	1	1	0
EDEMA :		0	0	0	1
CALCIFICATION :		0	0	0	1
FAT VACUOLES :		5	0	7	2
GLIOSIS :		2	3	3	1
HEMORRHAGE :		1	0	1	0
CONGESTION :		1	1	1	0
ABSENT :		1	5	5	1
LEUKEMIC DEPOSITS :		0	1	0	0
VENTRICULAR DILATATION :		1	0	0	0
MENINGITIS :		0	0	1	0
HEART	EXAMINED	49	48	50	49
AUTOLYSIS :		0	1	0	0
THROMBOSIS :		2	1	0	2
CALCIFICATION :		0	1	0	0
INFLAMMATION CHRONIC :		0	0	1	1
LEUKOCYTOSIS :		0	1	1	0
CONGESTION :		14	8	15	5
DILATED CHAMBER :		0	0	2	0
HYPERTROPHY :		0	0	0	1
LEUKEMIC DEPOSITS :		4	2	0	5
AUTOLYSIS PARTIAL :		0	2	0	0
PERICARDITIS :		0	1	2	1
NORMAL :		0	1	0	0

TRACHEA	EXAMINED	0	0	0	3
INFLAMMATION CHRONIC :		0	0	0	1
LEUKEMIC DEPOSITS :		0	0	0	2
LUNG	EXAMINED	49	49	50	49
AUTOLYSIS :		2	1	1	0
THROMBOSIS :		1	1	0	0
EDEMA :		7	4	6	3
NECROSIS :		0	1	1	0
HYPERPLASIA LYMPHOID :		1	0	0	0
PERITONITIS :		0	0	0	1
HEMORRHAGE :		6	1	6	0
ADENOMATOSIS :		0	1	0	0
PIGMENTATION :		1	0	0	0
PNEUMONIA :		13	7	18	15
LEUKOCYTOSIS :		0	0	4	0
CONGESTION :		15	9	8	9
ATELECTASIS :		2	5	4	4
EMPHYSEMA :		0	2	0	0
OSSEOUS METAPLASIA :		0	1	0	0
LEUKEMIC DEPOSITS :		6	9	6	11
AUTOLYSIS PARTIAL :		0	4	3	0
THICKENED ALVEOLAR WALLS :		0	3	4	2
NORMAL :		3	0	0	2
STOMACH	EXAMINED	49	49	50	48
HYPERKERATOSIS :		2	1	0	2
AUTOLYSIS :		8	4	4	1
ULCERATION :		0	0	0	3
INFLAMMATION CHRONIC :		3	1	0	1
HEMORRHAGE :		0	3	2	0
UNREADABLE :		2	0	0	1
ABSENT :		0	0	0	1
PAPILLOMATOUS ACANTHOSIS :		0	0	0	1
MUCOID CYST :		5	5	5	4

BAYER AG

LEUKEMIC DEPOSITS :		1	5	4	4
AUTOLYSIS PARTIAL :		0	2	7	0
HYPERPLASIA PAPILLOMATOUS :		1	0	0	0
NORMAL :		3	3	2	2
DUODENUM	EXAMINED	1	1	1	0
AUTOLYSIS :		1	0	0	0
AUTOLYSIS PARTIAL :		0	0	1	0
NORMAL :		0	1	0	0
LIVER	EXAMINED	48	49	50	49
AUTOLYSIS :		4	4	2	1
INFARCT :		1	0	3	1
THROMBOSIS :		0	0	0	1
CALCIFICATION :		1	0	0	0
FAT VACUOLES :		6	0	0	5
NECROSIS :		0	0	1	0
HEMORRHAGE :		0	1	0	0
MONONUCLEAR CELLS :		10	6	4	8
PIGMENTATION :		0	0	1	0
AMYLOID :		0	1	0	0
HEMATOPOIESIS :		1	0	0	0
CONGESTION :		10	7	10	6
HYPERPLASTIC NODULE :		2	1	1	4
HYPERTROPHY :		1	2	1	1
ABSENT :		1	0	0	0
VACUOLIZATION :		6	4	7	0
CYSTS :		1	0	0	2
LEUKEMIC DEPOSITS :		10	8	15	15
AUTOLYSIS PARTIAL :		6	8	8	1
HEPATOCYTIC HYPERPIGMENTATION		5	0	0	5
PERIARTERITIS :		0	0	0	1
HEMORRAGIC CYST :		1	0	0	0
HYPERPLASTIC NODULES :		0	0	0	3
NORMAL :		2	0	0	0

PANCREAS	EXAMINED	48	49	48	48
ATROPHY EPITHELIAL :		1	0	0	0
AUTOLYSIS :		9	6	6	7
EDEMA :		0	0	1	0
FIBROSIS :		1	0	0	0
INFLAMMATION CHRONIC :		1	1	3	4
MONONUCLEAR CELLS :		0	1	0	0
ATROPHY :		0	4	1	2
CONGESTION :		0	1	0	0
ABSENT :		1	0	2	1
VACUOLIZATION :		0	0	1	0
CYSTS :		0	1	0	0
LEUKEMIC DEPOSITS :		3	7	6	6
AUTOLYSIS PARTIAL :		4	7	8	3
PERIARTERITIS :		2	0	1	1
HEMORRAGIC CYST :		2	0	0	0
FATTY CYST :		0	1	0	0
NORMAL :		1	0	0	1
THYMUS	EXAMINED	4	3	3	5
NECROSIS :		0	0	1	0
SPLEEN	EXAMINED	49	49	50	48
AUTOLYSIS :		4	4	2	1
INFARCT :		0	0	0	1
HYPERPLASIA LYMPHOID :		1	7	1	2
HEMORRHAGE :		0	0	1	0
PIGMENTATION :		1	0	0	0
AMYLOID :		1	0	0	0
HEMATOPOIESIS :		18	14	26	14
CONGESTION :		1	2	2	2
HYPERTROPHY :		1	0	1	1
ABSENT :		0	0	0	1
AUTOLYSIS PARTIAL :		3	4	5	2
HEMORRAGIC CYST :		2	0	0	0

BAYER AG

NORMAL :		2	0	2	0
KIDNEYS	EXAMINED	49	49	50	49
AUTOLYSIS :		4	3	0	0
CALCIFICATION :		2	0	0	1
FIBROSIS :		0	0	1	1
PYELITIS :		1	1	0	0
HYDRONEPHROSIS :		2	1	1	1
HEMORRHAGE :		0	2	0	0
CONGESTION :		2	3	3	3
TUBULOPATHY :		4	5	4	5
INTERSTITIAL NEPHRITIS :		22	9	11	13
CYSTS :		3	1	7	1
LEUKEMIC DEPOSITS :		5	12	12	11
PYELONEPHRITIS :		0	3	1	3
AUTOLYSIS PARTIAL :		2	7	8	2
DILATATION OF GLOMERULAR LOOPS		2	3	0	0
DILATATION OF RENAL PELVIS :		1	0	0	0
PROGRESSIVE NEPHROPATHY :		6	3	2	0
NORMAL :		2	0	0	0
BLADDER	EXAMINED	49	49	49	48
AUTOLYSIS :		9	3	4	2
EDEMA :		0	1	0	0
INFLAMMATION GRANULOMATOUS :		0	0	0	1
INFLAMMATION CHRONIC :		7	5	2	7
UNREADABLE :		3	1	1	0
ABSENT :		0	0	1	1
LEUKEMIC DEPOSITS :		8	9	5	10
AUTOLYSIS PARTIAL :		0	6	13	0
PERIARTERITIS :		0	0	0	2
HYPERPLASIA PAPILLOMATOUS :		7	5	1	2

PITUITARY	EXAMINED	36	40	35	37
AUTOLYSIS :		3	1	1	1
HEMORRHAGE :		1	0	1	0
UNREADABLE :		0	1	0	0
ABSENT :		13	9	15	12
CYSTS :		2	0	0	0
HEMORRAGIC CYST :		0	0	0	1
THYROIDS	EXAMINED	37	36	31	35
AUTOLYSIS :		4	1	0	0
UNREADABLE :		0	0	0	1
ABSENT :		12	13	19	14
CYSTS :		3	3	1	3
LEUKEMIC DEPOSITS :		1	1	0	2
AUTOLYSIS PARTIAL :		1	4	4	1
ADRENALS	EXAMINED	48	49	49	47
AUTOLYSIS :		3	2	1	0
CALCIFICATION :		0	0	1	0
FAT VACUOLES :		1	0	1	1
PIGMENTATION :		20	17	21	14
AMYLOID :		1	0	0	0
HEMATOPOIESIS :		0	0	1	0
CONGESTION :		0	0	0	1
HYPERPLASTIC NODULE :		1	0	0	2
HYPERTROPHY :		0	0	0	1
ABSENT :		1	1	1	2
CYSTS :		0	1	0	0
LEUKEMIC DEPOSITS :		3	5	1	2
AUTOLYSIS PARTIAL :		0	2	1	0
HEMORRAGIC CYST :		0	0	0	1
HYPERPLASIA OF THE GLOMERULAR		3	4	3	1
NORMAL :		0	1	0	0

BAYER AG

SKELETAL MUSCLE	EXAMINED	47	47	48	46
AUTOLYSIS :		3	0	0	0
ABSENT :		2	2	2	3
LEUKEMIC DEPOSITS :		4	3	3	2
AUTOLYSIS PARTIAL :		0	0	1	0
SKIN	EXAMINED	0	0	2	1
NECROSIS :		0	0	1	0
FIBROSIS :		0	0	1	0
INFLAMMATION CHRONIC :		0	0	1	0
PUS :		0	0	1	0
NORMAL :		0	0	0	1
SCIATIC NERVE	EXAMINED	43	44	42	38
AUTOLYSIS :		3	0	0	0
ABSENT :		5	5	7	11
LEUKEMIC DEPOSITS :		0	0	0	1
BONE	EXAMINED	0	1	3	1
NORMAL :		0	0	1	0
MESENTERY	EXAMINED	16	10	13	5
STEATONECROSIS :		0	1	0	0
INFLAMMATION CHRONIC :		5	0	2	1
PERITONITIS :		0	1	0	1
HEMORRHAGE :		0	0	1	0
LEUKEMIC DEPOSITS :		9	9	10	3
MAMMARY GLAND	EXAMINED	2	1	0	0
HYPERPLASIA SECRETORY :		0	1	0	0
OVARIES	EXAMINED	48	48	49	46
AUTOLYSIS :		4	2	3	0
THROMBOSIS :		0	0	1	0
INFLAMMATION ACUTE :		2	2	0	1
INFLAMMATION CHRONIC :		1	0	0	0
HYPERPLASIA POLYPOID:		0	0	0	1
HEMORRHAGE :		1	0	1	1
PIGMENTATION :		1	0	0	0

ATROPHY :	22	15	24	23
ABSENT :	1	1	1	3
ARTERITIS :	2	0	0	0
CYSTS :	20	23	24	11
LEUKEMIC DEPOSITS :	6	7	4	7
HYPERTROPHIC CORPORA LUTEA :	6	11	3	2
AUTOLYSIS PARTIAL :	0	1	2	0
CYSTIC FOLLICLE :	0	0	0	1
HEMORRAGIC CYST :	3	0	4	6
HYPERPLASIA PAPILLOMATOUS :	0	0	0	1
PUS :	1	2	0	0
NORMAL :	0	0	1	0
UTERUS EXAMINED	35	38	33	42
THROMBOSIS :	0	1	1	0
HYPERPLASIA POLYPOID:	4	1	3	1
HEMORRHAGE :	4	3	2	0
AMYLOID :	0	1	0	0
CYSTIC ENDOMETRIAL HYPERPLASIA	5	14	7	11
SQUAMOUS METAPLASIA :	0	0	1	0
ECTASIA SIMPLE :	0	0	0	1
ENDOMETRIOSIS :	8	8	7	5
UNREADABLE :	2	1	1	0
ABSENT :	0	0	1	0
HYPERPLASIA SECRETORY :	7	8	7	8
LEUKEMIC DEPOSITS :	7	3	5	6
AUTOLYSIS PARTIAL :	1	0	1	0
ENDOMETRITIS :	3	2	0	4
HEMORRAGIC CYST :	1	1	1	0
HYPERPLASIA PAPILLOMATOUS :	0	1	0	0
PUS :	1	0	0	0
NORMAL :	2	2	0	7

BAYER AG

CEREBRUM	EXAMINED	0	1	0	0
CERVICAL LYMPH NODE	EXAMINED	1	0	0	1
HYPERTROPHY :		0	0	0	1
FAT	EXAMINED	0	1	0	0
LEUKEMIC DEPOSITS :		0	1	0	0
DIAPHRAGM	EXAMINED	0	0	2	0
LEUKEMIC DEPOSITS :		0	0	1	0
INTESTINE	EXAMINED	0	1	0	2
AUTOLYSIS :		0	1	0	2
RIGHT HIND EXTREMITY	EXAMINED	0	0	0	1
FEMUR	EXAMINED	48	47	49	46
AUTOLYSIS :		1	0	0	0
INFLAMMATION CHRONIC :		0	0	1	0
HEMATOPOIESIS :		0	0	1	2
HYPOPLASIA :		0	0	1	0
UNREADABLE :		0	1	1	0
ABSENT :		1	2	1	3
LEUKEMIC DEPOSITS :		0	0	0	1
NORMAL :		0	0	2	0
SKULL	EXAMINED	1	0	0	1
CERVIX	EXAMINED	1	1	0	1
BODY CAVITY	EXAMINED	0	0	0	1
LYMPH NODE	EXAMINED	8	5	13	3
CRYSTALS :		0	0	1	0
CONGESTION :		0	0	1	0
HYPERTROPHY :		0	0	2	0
ABSENT :		0	0	1	1
LYMPHOCELE :		1	0	0	0
LYMPHATIC ECTASIA :		1	0	0	0
LEUKEMIC DEPOSITS :		1	0	0	0
AUTOLYSIS PARTIAL :		1	0	2	0

SUBCUTANEOUS TISSUE	EXAMINED	0	1	0	0
NECROSIS :		0	1	0	0
ABDOMINAL CAVITY	EXAMINED	0	1	0	0
STEATONECROSIS :		0	1	0	0
BODY WALL	EXAMINED	1	0	0	0
AUTOLYSIS PARTIAL :		1	0	0	0

BAYER AG BAYER AG BAYER AG BAYER AG

APPENDIX II

INDIVIDUAL HISTOLOGICAL DATA

BAYER AG BAYER AG BAYER AG BAYER AG

SMG. 1 CHRONIC TOXICITY STUDY IN MICE: SYSTEMATIC

HISTOPATHOLOGY

PRODUCT : CWG 0519 GROUP : CONTROL
ROUTE : DIETARY
TIME : 105 WEEKS DOSE : 0 PPM
THIS GROUP COMPRISED : 11 MALES

THE FOLLOWING ORGANS WERE EXAMINED SYSTEMATICALLY :

HEART	LUNG	LIVER
PANCREAS	SPLEEN	KIDNEYS
BLADDER	STOMACH	TESTES
THYROIDS	ADRENALS	PITUITARY
BRAIN	SKELETAL MUSCLE	SCIATIC NERVE
FEMUR		

THESE ORGANS WERE EXAMINED IN 11 MALES

INDIVIDUAL RESULTS

IN THE ANIMALS SHOWN BELOW THE HISTOLOGICAL EXAMINATION OF THE ORGANS LISTED OR OF THE ANOMALIES FOUND AT AUTOPSY GAVE THE FOLLOWING RESULTS :

MALE 5 (1466/80)

BRAIN

GLIOSIS :
FOCAL
THERE IS PROLIFERATION OF GLIAL CELLS.

LUNG

ATELECTASIS :
MULTIFOCAL
THERE IS COLLAPSE OF ALVEOLI.

STOMACH

INFLAMMATION, CHRONIC :
MODERATE
THERE IS AN INFILTRATION BY MONONUCLEAR CELLS IN THE MUCOSA AND SUBMUCOSA.

MUCOID CYST :
SEVERE MULTIFOCAL
ONE OR MORE CYSTS CONTAINING MUCOID MATERIAL ARE OBSERVED.

LIVER

HYPERPLASTIC NODULES :
MULTIFOCAL
WELL DEFINED ROUNDED FOCI OF HYPERPLASTIC AND HYPERTROPHIC CELLS ARE OBSERVED WITHIN THIS OTHERWISE NORMAL TISSUE.

SNC. 2 MALE 5 CONTINUED

SPLEEN

HEMATOPOIESIS :
MODERATE
THE HEMATOPOIESIS IS EVIDENT.

KIDNEYS

INTERSTITIAL NEPHRITIS :
BILATERAL MINIMAL MULTIFOCAL
INFLAMMATORY CELLS FIBROSIS AND SOME TUBULAR ALTERATIONS ARE ASSOCIATED.

CYSTS :
BILATERAL MINIMAL MULTIFOCAL
ONE OR MORE CYSTS FILLED WITH CLEAR LIQUID ARE SEEN.

BLADDER

ABSENT :
ORGAN OR TISSUE NOT REMOVED FROM ANIMAL OR NOT FOUND IN FIXATIVE.

THYROIDS

ABSENT :
ORGAN OR TISSUE NOT REMOVED FROM ANIMAL OR NOT FOUND IN FIXATIVE.

SEMINAL VESICLES

NORMAL :
HISTOLOGICAL ASPECT WITHIN NORMAL LIMITS.

MALE 13 (1469/80)

LUNG

ATELECTASIS :
MULTIFOCAL
THERE IS COLLAPSE OF ALVEOLI.

LIVER

PIGMENTATION :
NUMEROUS MACROPHAGES CONTAIN A GRANULAR BROWN CYTOPLASMIC PIGMENT.

KIDNEYS

INTERSTITIAL NEPHRITIS :
BILATERAL MINIMAL MULTIFOCAL
INFLAMMATORY CELLS FIBROSIS AND SOME TUBULAR ALTERATIONS ARE ASSOCIATED.

CYSTS :
BILATERAL MINIMAL MULTIFOCAL

BAYER AG

SMC. 3 MALE 13 CONTINUED

KIDNEYS CONTINUED
ONE OR MORE CYSTS FILLED WITH CLEAR LIQUID ARE SEEN.

THYROIDS

ABSENT :
ORGAN OR TISSUE NOT REMOVED FROM ANIMAL OR NOT FOUND IN FIXATIVE.

ADRENALS

PIGMENTATION :
UNILATERAL MINIMAL MULTIFOCAL
NUMEROUS MACROPHAGES CONTAIN A GRANULAR BROWN CYTOPLASMIC PIGMENT.

TESTES

ATROPHY SEMINIFEROUS :
BILATERAL MODERATE MULTIFOCAL
THERE IS ATROPHY OF SEMINIFEROUS TUBULES WITH DIMINISHED SPERMATOGENIC ACTIVITY.

CALCIFICATION :
BILATERAL
THERE ARE MINERAL DEPOSITS.

SEMINAL VESICLES

ATROPHY EPITHELIAL :
THE EPITHELIAL TISSUE IS ATROPHIC AND SCANTY WITH INCREASED FIBROUS STROMA.

ECTASIA SIMPLE :
THE LUMEN OF THE ORGAN IS ABNORMALLY ENLARGED.

COAGULUM :
AN ACIDOPHILIC STRUCTURE RESEMBLING COAGULATED PROTEIN IS PRESENT IN THE LUMEN.

MALE 10 (1470/60)

HEART

FIBROSIS :
MINIMAL MULTIFOCAL
THERE IS AN INCREASE IN INTERSTITIAL FIBROUS TISSUE.

INFLAMMATION CHRONIC :
MINIMAL MULTIFOCAL
THE INTERSTITIAL TISSUES SHOW INFILTRATION BY MONONUCLEAR CELLS AND INCREASE IN FIBROUS STROMA.

SMC. 4 MALE 16 CONTINUED

LUNG

PNEUMONIA :
MODERATE
THE ALVEOLAR WALLS ARE THICKENED AND ALVEOLI CONTAIN INFLAMMATORY CELLS AND FOAMY MACROPHAGES. PERIVASCULAR AND PERIBRONCHIAL LYMPHOCYTIC ACCUMULATIONS MAY BE PRESENT.

*** ALVEOLOGENIC CARCINOMA :
A MALIGNANT TUMOR OF THE LUNG TISSUE WITH SYNONYMS IN MICE FOR ADENOMA, CARCINOMA, ALVEOLOGENIC PAPILLARY CARCINOMA, PAPILLARY CYSTADENOMA, ADENOCARCINOMA, BRONCHIOLAR CELL CARCINOMA, BRONCHIOLAR-ALVEOLAR TUMOR, TYPE A TUMOR, TYPE B TUMOR, INTERMEDIATE TYPE I TUMOR AND COMMON PULMONARY TUMOR OF THE MOUSE.

LIVER

*** ADENOMA HEPATIC BENIGN :
DISTINCT NODULES COMPRESS THE ADJACENT LIVER PARENCHYMA, ARE CHARACTERIZED BY WELL DIFFERENTIATED HEPATOCYTES AND DO NOT SHOW PORTAL TRIADS.

HYPERPLASTIC NODULES :
MULTIFOCAL
WELL DEFINED ROUNDED FOCI OF HYPERPLASTIC AND HYPERTROPHIC CELLS ARE OBSERVED WITHIN THIS OTHERWISE NORMAL TISSUE.

SPLEEN

HEMATOPOIESIS :
SEVERE
THE HEMATOPOIESIS IS EVIDENT.

KIDNEYS

PROGRESSIVE NEPHROPATHY :
BILATERAL SEVERE MULTIFOCAL
AN AGE ASSOCIATED KIDNEY LESION CONSISTING OF CYSTIC TUBULES WITH COLLOID OR HYALINE CASTS CHRONIC INTERSTITIAL NEPHRITIS AND DILATATION OF BOWMAN'S CAPSULE WITH GLOMERULAR DEGENERATION .

THYROIDS

ABSENT :
ORGAN OR TISSUE NOT REMOVED FROM ANIMAL OR NOT FOUND IN FIXATIVE.

TESTES

ATROPHY SEMINIFEROUS :
BILATERAL MODERATE MULTIFOCAL
THERE IS ATROPHY OF SEMINIFEROUS TUBULES WITH DIMINISHED SPERMATOGENIC ACTIVITY.

CALCIFICATION :
UNILATERAL MODERATE MULTIFOCAL
THERE ARE MINERAL DEPOSITS.

SPERMATOCELE :
BILATERAL MINIMAL

BAYER AG

SNC. 5 MALE 16 CONTINUED

TESTES CONTINUED
FOCAL CYSTIC DILATATION CONTAINING SPERMATOZOA IS PRESENT.

FEMUR

ABSENT :
ORGAN OR TISSUE NOT REMOVED FROM ANIMAL OR NOT FOUND IN FIXATIVE.

MALE 19 (1471/80)

HEART

FIBROSIS :
MODERATE MULTIFOCAL
THERE IS AN INCREASE IN INTERSTITIAL FIBROUS TISSUE.

INFLAMMATION CHRONIC :
MODERATE MULTIFOCAL
THE INTERSTITIAL TISSUES SHOW INFILTRATION BY MONONUCLEAR CELLS AND INCREASE IN FIBROUS STROMA.

LUNG

ATELECTASIS :
FOCAL
THERE IS COLLAPSE OF ALVEOLI.

KIDNEYS

CYSTS :
BILATERAL MODERATE MULTIFOCAL
ONE OR MORE CYSTS FILLED WITH CLEAR LIQUID ARE SEEN.

THYROIDS

ABSENT :
ORGAN OR TISSUE NOT REMOVED FROM ANIMAL OR NOT FOUND IN FIXATIVE.

ADRENALS

ABSENT :
ORGAN OR TISSUE NOT REMOVED FROM ANIMAL OR NOT FOUND IN FIXATIVE.

MALE 22 (1472/80)

SMC. 6 MALE 22 CONTINUED

LUNG

ATELECTASIS :
THERE IS COLLAPSE OF ALVEOLI.

SPLEEN

HEMATOPOIESIS :
MINIMAL
THE HEMATOPOIESIS IS EVIDENT.

KIDNEYS

INTERSTITIAL NEPHRITIS :
BILATERAL MINIMAL MULTIFOCAL
INFLAMMATORY CELLS FIBROSIS AND SOME TUBULAR ALTERATIONS ARE ASSOCIATED.

CYSTS :
UNILATERAL MODERATE MULTIFOCAL
ONE OR MORE CYSTS FILLED WITH CLEAR LIQUID ARE SEEN.

THYROIDS

ABSENT :
ORGAN OR TISSUE NOT REMOVED FROM ANIMAL OR NOT FOUND IN FIXATIVE.

ADRENALS

*** ADENOMA :
UNILATERAL
THIS IS BENIGN GLANDULAR EPITHELIAL TUMOR.

TESTES

ATROPHY SEMINIFEROUS :
BILATERAL MODERATE MULTIFOCAL
THERE IS ATROPHY OF SEMINIFEROUS TUBULES WITH DIMINISHED SPERMATOGENIC ACTIVITY.

MALE 24 (1473/60)

BRAIN

GLIOSIS :
FOCAL
THERE IS PROLIFERATION OF GLIAL CELLS.

LUNG

*** ALVEOLOGENIC CARCINOMA :
MULTIFOCAL
A MALIGNANT TUMOR OF THE LUNG TISSUE WITH SYNONYMS IN MICE FOR ADENOMA, CARCINOMA,

BAYER AG

Vertraulich
Eigentum der Firma Bayer AG
Benutzung, Verwertung oder Weitergabe nur mit Einwilligung der Bayer AG gestattet

SMC. 7 MALE 24 CONTINUED

LUNG CONTINUED

ALVEOLOGENIC PAPILLARY CARCINOMA, PAPILLARY CYSTADENOMA, ADENOCARCINOMA, BRONCHIOLAR CELL CARCINOMA, BRONCHIOLAR-ALVEOLAR TUMOR, TYPE A TUMOR, TYPE B TUMOR, INTERMEDIATE TYPE I TUMOR AND COMMON PULMONARY TUMOR OF THE MOUSE.

PANCREAS

NORMAL :
HISTOLOGICAL ASPECT WITHIN NORMAL LIMITS.

SPLEEN

HEMATOPOIESIS :
SEVERE
THE HEMATOPOIESIS IS EVIDENT.

KIDNEYS

INTERSTITIAL NEPHRITIS :
BILATERAL MINIMAL MULTIFOCAL
INFLAMMATORY CELLS FIBROSIS AND SOME TUBULAR ALTERATIONS ARE ASSOCIATED.

CYSTS :
BILATERAL MINIMAL MULTIFOCAL
ONE OR MORE CYSTS FILLED WITH CLEAR LIQUID ARE SEEN.

PITUITARY

ABSENT :
ORGAN OR TISSUE NOT REMOVED FROM ANIMAL OR NOT FOUND IN FIXATIVE.

ADRENALS

ABSENT :
ORGAN OR TISSUE NOT REMOVED FROM ANIMAL OR NOT FOUND IN FIXATIVE.

MESENTERY

INFLAMMATION CHRONIC :
THE INTERSTITIAL TISSUES SHOW INFILTRATION BY MONONUCLEAR CELLS AND INCREASE IN FIBROUS STROMA.

TESTES

PIGMENTATION :
BILATERAL MINIMAL MULTIFOCAL
NUMEROUS MACROPHAGES CONTAIN A GRANULAR BROWN CYTOPLASMIC PIGMENT.

MALE 26 (1474/80)

SMC. 8 MALE 26 CONTINUED

HEART

FIBROSIS :
MINIMAL FOCAL
THERE IS AN INCREASE IN INTERSTITIAL FIBROUS TISSUE.

KIDNEYS

INTERSTITIAL NEPHRITIS :
BILATERAL MINIMAL MULTIFOCAL
INFLAMMATORY CELLS FIBROSIS AND SOME TUBULAR ALTERATIONS ARE ASSOCIATED.

CYSTS :
BILATERAL MINIMAL MULTIFOCAL
ONE OR MORE CYSTS FILLED WITH CLEAR LIQUID ARE SEEN.

PITUITARY

ABSENT :
ORGAN OR TISSUE NOT REMOVED FROM ANIMAL OR NOT FOUND IN FIXATIVE.

ADRENALS

ABSENT :
ORGAN OR TISSUE NOT REMOVED FROM ANIMAL OR NOT FOUND IN FIXATIVE.

SCIATIC NERVE

ABSENT :
ORGAN OR TISSUE NOT REMOVED FROM ANIMAL OR NOT FOUND IN FIXATIVE.

MALE 36 (1475/80)

THICKENING ENDOCARDIUM :
MINIMAL
ENDOCARDIUM IS THICKER THAN NORMAL.

LUNG

*** ALVEOLOGENIC CARCINOMA :
A MALIGNANT TUMOR OF THE LUNG TISSUE WITH SYNONYMS IN MICE FOR ADENOMA, CARCINOMA, ALVEOLOGENIC PAPILLARY CARCINOMA, PAPILLARY CYSTADENOMA, ADENOCARCINOMA, BRONCHIOLAR CELL CARCINOMA, BRONCHIOLAR-ALVEOLAR TUMOR, TYPE A TUMOR, TYPE B TUMOR, INTERMEDIATE TYPE I TUMOR AND COMMON PULMONARY TUMOR OF THE MOUSE.

BAYER AG

SMC. 9 MALE 51 CONTINUED

STOMACH

INFLAMMATION CHRONIC :
THERE IS AN INFILTRATION BY MONONUCLEAR CELLS IN THE MUCOSA AND SUBMUCOSA.

LIVER

HYPERPLASTIC NODULES :
MULTIFOCAL
WELL DEFINED ROUNDED FOCI OF HYPERPLASTIC AND HYPERTROPHIC CELLS ARE OBSERVED WITHIN THIS OTHERWISE NORMAL TISSUE.

KIDNEYS

INTERSTITIAL NEPHRITIS :
BILATERAL MINIMAL MULTIFOCAL
INFLAMMATORY CELLS FIBROSIS AND SOME TUBULAR ALTERATIONS ARE ASSOCIATED.

CYSTS :
UNILATERAL
ONE OR MORE CYSTS FILLED WITH CLEAR LIQUID ARE SEEN.

PITUITARY

UNREADABLE :
IT IS NOT POSSIBLE TO INTERPRET THE SECTION DUE TO AN ARTIFACT CAUSED BY SAMPLING OR HISTOLOGICAL TECHNIQUE.

ADRENALS

*** ADENOMA :
UNILATERAL
THIS IS BENIGN GLANDULAR EPITHELIAL TUMOR.

TESTES

CALCIFICATION :
BILATERAL MINIMAL
THERE ARE MINERAL DEPOSITS.

FAT

*** LIPOMA :
THE BENIGN TUMOR IS COMPOSED OF NORMAL FAT CELLS WITH SOME VASCULAR FIBROUS STROMA.

MALE 33 (1476/80)

STOMACH

ABSENT :
ORGAN OR TISSUE NOT REMOVED FROM ANIMAL OR NOT FOUND IN FIXATIVE.

SMC•10 MALE 33 CONTINUED

LIVER

*** ADENOMA HEPATIC BENIGN :
DISTINCT NODULES COMPRESS THE ADJACENT LIVER PARENCHYMA, ARE CHARACTERIZED BY WELL DIFFERENTIATED HEPATOCYTES AND DO NOT SHOW PORTAL TRIADS.

MONONUCLEAR CELLS :
MINIMAL MULTIFOCAL
FOCAL COLLECTIONS OF MONONUCLEAR CELLS ARE PRESENT.

HYPERPLASTIC NODULES :
MULTIFOCAL
WELL DEFINED ROUNDED FOCI OF HYPERPLASTIC AND HYPERTROPHIC CELLS ARE OBSERVED WITHIN THIS OTHERWISE NORMAL TISSUE.

PANCREAS

ABSENT :
ORGAN OR TISSUE NOT REMOVED FROM ANIMAL OR NOT FOUND IN FIXATIVE.

SPLEEN

HEMATOPOIESIS :
MODERATE
THE HEMATOPOIESIS IS EVIDENT.

KIDNEYS

INTERSTITIAL NEPHRITIS :
BILATERAL SEVERE MULTIFOCAL
INFLAMMATORY CELLS FIBROSIS AND SOME TUBULAR ALTERATIONS ARE ASSOCIATED.

ADRENALS

PIGMENTATION :
UNILATERAL MINIMAL
NUMEROUS MACROPHAGES CONTAIN A GRANULAR BROWN CYTOPLASMIC PIGMENT.

TESTES

CALCIFICATION :
BILATERAL MODERATE
THERE ARE MINERAL DEPOSITS.

BAYER AG

MALE 35 (1477/80)

LUNG

*** ALVEOLOGENIC CARCINOMA :
A MALIGNANT TUMOR OF THE LUNG TISSUE WITH SYNONYMS IN MICE FOR ADENOMA, CARCINOMA,

SMC.11 MALE 35 CONTINUED

LUNG CONTINUED

ALVEOLOGENIC PAPILLARY CARCINOMA, PAPILLARY CYSTADENOMA, ADENOCARCINOMA, BRONCHIOLAR CELL CARCINOMA, BRONCHIOLAR-ALVEOLAR TUMOR, TYPE A TUMOR, TYPE B TUMOR, INTERMEDIATE TYPE I TUMOR AND COMMON PULMONARY TUMOR OF THE MOUSE.

PANCREAS

NORMAL :
HISTOLOGICAL ASPECT WITHIN NORMAL LIMITS.

KIDNEYS

INTERSTITIAL NEPHRITIS :
BILATERAL MINIMAL MULTIFOCAL
INFLAMMATORY CELLS FIBROSIS AND SOME TUBULAR ALTERATIONS ARE ASSOCIATED.

THYROIDS

ABSENT :
ORGAN OR TISSUE NOT REMOVED FROM ANIMAL OR NOT FOUND IN FIXATIVE.

ADRENALS

ABSENT :
ORGAN OR TISSUE NOT REMOVED FROM ANIMAL OR NOT FOUND IN FIXATIVE.

MALE 40 (1478/60)

BRAIN

ABSENT :
ORGAN OR TISSUE NOT REMOVED FROM ANIMAL OR NOT FOUND IN FIXATIVE.

HEART

INFLAMMATION CHRONIC :
MODERATE
THE INTERSTITIAL TISSUES SHOW INFILTRATION BY MONONUCLEAR CELLS AND INCREASE IN FIBROUS STROMA.

LUNG

*** ALVEOLOGENIC CARCINOMA :
A MALIGNANT TUMOR OF THE LUNG TISSUE WITH SYNONYMS IN MICE FOR ADENOMA, CARCINOMA, ALVEOLOGENIC PAPILLARY CARCINOMA, PAPILLARY CYSTADENOMA, ADENOCARCINOMA, BRONCHIOLAR CELL CARCINOMA, BRONCHIOLAR-ALVEOLAR TUMOR,

SMC.12 MALE 40 CONTINUED

LUNG CONTINUED

TYPE A TUMOR, TYPE B TUMOR, INTERMEDIATE TYPE I TUMOR AND COMMON PULMONARY TUMOR OF THE MOUSE.

PANCREAS

ABSENT :
ORGAN OR TISSUE NOT REMOVED FROM ANIMAL OR NOT FOUND IN FIXATIVE.

SPLEEN

NORMAL :
HISTOLOGICAL ASPECT WITHIN NORMAL LIMITS.

KIDNEYS

INTERSTITIAL NEPHRITIS :
BILATERAL MINIMAL MULTIFOCAL
INFLAMMATORY CELLS FIBROSIS AND SOME TUBULAR ALTERATIONS ARE ASSOCIATED.

CYSTS :
BILATERAL MODERATE MULTIFOCAL
ONE OR MORE CYSTS FILLED WITH CLEAR LIQUID ARE SEEN.

ADRENALS

*** ADENOMA :
UNILATERAL
THIS IS BENIGN GLANDULAR EPITHELIAL TUMOR.

BAYER AG BAYER AG BAYER AG

NMC. 1 CHRONIC TOXICITY STUDY IN MICE: NONSYSTEMATIC

HISTOPATHOLOGY

PRODUCT : XWG 0519 CD GROUP : CONTROL
ROUTE : DIETARY
TIME : 105 WEEKS DOSE : 0 PPM
THIS GROUP COMPRISED : 39 MALES

THE FOLLOWING ORGANS WERE EXAMINED SYSTEMATICALLY :

HEART	LUNG	LIVER
PANCREAS	SPLEEN	KIDNEYS
BLADDER	STOMACH	TESTES
THYROIDS	ADRENALS	PITUITARY
BRAIN	SKELETAL MUSCLE	SCIATIC NERVE
FEMUR		

THESE ORGANS WERE EXAMINED IN 39 MALES

INDIVIDUAL RESULTS

IN THE ANIMALS SHOWN BELOW THE HISTOLOGICAL EXAMINATION OF THE ORGANS LISTED OR OF THE ANOMALIES FOUND AT AUTOPSY GAVE THE FOLLOWING RESULTS :

MALE 1 (1606/80)

HEART

CONGESTION :
SEVERE
VESSELS OR SINUSOIDS ARE MARKEDLY DISTENDED WITH ERYTHROCYTES.

LUNG

ADENOMATOSIS :
FOCAL
THE PULMONARY ALVEOLI APPEAR GLANDULAR DUE TO METAPLASTIC TRANSFORMATION OF LINING CELLS INTO CUBOIDAL OR COLUMNAR CELLS

PLEURITIS :
MODERATE MULTIFOCAL
THE PLEURA IS INFLAMMED AND COVERED WITH EXUDATE.

KIDNEYS

INTERSTITIAL NEPHRITIS :
BILATERAL MINIMAL MULTIFOCAL
INFLAMMATORY CELLS FIBROSIS AND SOME TUBULAR ALTERATIONS ARE ASSOCIATED.

CYSTS :
BILATERAL MODERATE MULTIFOCAL
ONE OR MORE CYSTS FILLED WITH CLEAR LIQUID ARE SEEN.

NMC. 2 MALE 1 CONTINUED

BLADDER

AUTOLYSIS :
THE TISSUES EXHIBIT AUTOLYSIS AND THEY ARE NOT INTERPRETABLE.

PITUITARY

ABSENT :
ORGAN OR TISSUE NOT REMOVED FROM ANIMAL OR NOT FOUND IN FIXATIVE.

THYROIDS

ABSENT :
ORGAN OR TISSUE NOT REMOVED FROM ANIMAL OR NOT FOUND IN FIXATIVE.

TESTES

CALCIFICATION :
UNILATERAL MODERATE
THERE ARE MINERAL DEPOSITS.

SPERMATOCELE :
UNILATERAL FOCAL
FOCAL CYSTIC DILATATION CONTAINING SPERMATOZOA IS PRESENT.

SEMINAL VESICLES

ATROPHY EPITHELIAL :
THE EPITHELIUM IS THINNED.

COAGULUM :
AN ACIDOPHILIC STRUCTURE RESEMBLING COAGULATED PROTEIN IS PRESENT IN THE LUMEN.

MALE A2 (1640/80)

LUNG

*** ALVEOLOGENIC CARCINOMA :
A MALIGNANT TUMOR OF THE LUNG TISSUE WITH SYNONYMS IN MICE FOR ADENOMA, CARCINOMA, ALVEOLOGENIC PAPILLARY CARCINOMA, PAPILLARY CYSTADENOMA, ADENOCARCINOMA, BRONCHIOLAR CELL CARCINOMA, BRONCHIOLAR-ALVEOLAR TUMOR, TYPE A TUMOR, TYPE B TUMOR, INTERMEDIATE TYPE I TUMOR AND COMMON PULMONARY TUMOR OF THE MOUSE.

PANCREAS

HYPERPLASIA ISLETS :
THE ISLETS ARE INCREASED IN NUMBER AND SIZE.

NMC. 3 MALE 2 CONTINUED

SPLEEN

HYPERPLASIA LYMPHOID :
THE LYMPHOID FOLLICLES ARE INCREASED IN SIZE.

KIDNEYS

INTERSTITIAL NEPHRITIS :
BILATERAL MINIMAL MULTIFOCAL
INFLAMMATORY CELLS FIBROSIS AND SOME TUBULAR ALTERATIONS ARE ASSOCIATED.

CYSTS :
BILATERAL MODERATE MULTIFOCAL
ONE OR MORE CYSTS FILLED WITH CLEAR LIQUID ARE SEEN.

ADRENALS

HYPERPLASTIC NODULE :
UNILATERAL
A NODULE OF HYPERPLASTIC TISSUE IS PRESENT.

TESTES

ATROPHY SEMINIFEROUS :
BILATERAL MODERATE
THERE IS ATROPHY OF SEMINIFEROUS TUBULES WITH DIMINISHED SPERMATOGENIC ACTIVITY.

CALCIFICATION :
UNILATERAL MINIMAL
THERE ARE MINERAL DEPOSITS.

MALE 3 (1641/80)

LUNG

*** ALVEOLOGENIC CARCINOMA :
A MALIGNANT TUMOR OF THE LUNG TISSUE WITH SYNONYMS IN MICE FOR ADENOMA, CARCINOMA, ALVEOLOGENIC PAPILLARY CARCINOMA, PAPILLARY CYSTADENOMA, ADENOCARCINOMA, BRONCHIOLAR CELL CARCINOMA, BRONCHIOLAR-ALVEOLAR TUMOR, TYPE A TUMOR, TYPE B TUMOR, INTERMEDIATE TYPE I TUMOR AND COMMON PULMONARY TUMOR OF THE MOUSE.

STOMACH

MONONUCLEAR CELLS :
MODERATE
FOCAL COLLECTIONS OF MONONUCLEAR CELLS ARE PRESENT.

LIVER

NECROSIS :
SEVERE
THE TISSUE HAS LOST ITS NORMAL STRUCTURE DUE TO CELL DEATH WHICH MAY BE OF VARIOUS ORIGIN.

HEPATOCYTIC HYPERPIGMENTATION :
HEPATOCYTES ARE LADEN WITH GRANULES OF HEMOSIDERIN OR BILE OR OTHER PIGMENT.

HYPERPLASTIC NODULES :
WELL DEFINED ROUNDED FOCI OF HYPERPLASTIC AND HYPERTROPHIC CELLS ARE OBSERVED WITHIN THIS OTHERWISE NORMAL TISSUE.

SPLEEN

HEMATOPOIESIS :
MODERATE
THE HEMATOPOIESIS IS EVIDENT.

KIDNEYS

INTERSTITIAL NEPHRITIS :
BILATERAL MINIMAL MULTIFOCAL
INFLAMMATORY CELLS FIBROSIS AND SOME TUBULAR ALTERATIONS ARE ASSOCIATED.

CYSTS :
BILATERAL SEVERE MULTIFOCAL
ONE OR MORE CYSTS FILLED WITH CLEAR LIQUID ARE SEEN.

BLADDER

HYPERPLASIA :
THERE IS AN EXAGGERATED INCREASE/DEVELOPMENT OF THE NORMAL TISSUE/GLAND IN THE ORGAN.

PITUITARY

ABSENT :
ORGAN OR TISSUE NOT REMOVED FROM ANIMAL OR NOT FOUND IN FIXATIVE.

THYROIDS

ABSENT :
ORGAN OR TISSUE NOT REMOVED FROM ANIMAL OR NOT FOUND IN FIXATIVE.

BAYER BAYER BAYER BAYER BAYER

MALE 4 (1618/80)

HEART

CONGESTION :

NMC. 5 MALE 4 CONTINUED

HEART CONTINUED

VESSELS OR SINUSOIDS ARE MARKEDLY DISTENDED WITH ERYTHROCYTES.

LUNG

PNEUMONIA :
MODERATE
THE ALVEOLAR WALLS ARE THICKENED AND ALVEOLI CONTAIN INFLAMMATORY CELLS AND FOAMY MACROPHAGES.PERIVASCULAR AND PERIBRONCHIAL LYMPHOCYTIC ACCUMULATIONS MAY BE PRESENT.

LIVER

HYPERPLASTIC NODULES :
WELL DEFINED ROUNDED FOCI OF HYPERPLASTIC AND HYPERTROPHIC CELLS ARE OBSERVED WITHIN THIS OTHERWISE NORMAL TISSUE.

KIDNEYS

CYSTS :
UNILATERAL MINIMAL MULTIFOCAL
ONE OR MORE CYSTS FILLED WITH CLEAR LIQUID ARE SEEN.

THYROIDS

ABSENT :
ORGAN OR TISSUE NOT REMOVED FROM ANIMAL OR NOT FOUND IN FIXATIVE.

ADRENALS

UNREADABLE :
IT IS NOT POSSIBLE TO INTERPRET THE SECTION DUE TO AN ARTIFACT CAUSED BY SAMPLING OR HISTOLOGICAL TECHNIQUE.

SKELETAL MUSCLE

UNREADABLE :
IT IS NOT POSSIBLE TO INTERPRET THE SECTION DUE TO AN ARTIFACT CAUSED BY SAMPLING OR HISTOLOGICAL TECHNIQUE.

SCIATIC NERVE

UNREADABLE :
IT IS NOT POSSIBLE TO INTERPRET THE SECTION DUE TO AN ARTIFACT CAUSED BY SAMPLING OR HISTOLOGICAL TECHNIQUE.

TESTES

ATROPHY SEMINIFEROUS :
UNILATERAL MINIMAL
THERE IS ATROPHY OF SEMINIFEROUS TUBULES WITH DIMINISHED SPERMATOGENIC ACTIVITY.

MALE 6 (102n/dO)

NMC. 6 MALE 6 CONTINUED

HEART

INFLAMMATION CHRONIC :
THE INTERSTITIAL TISSUES SHOW INFILTRATION BY MONONUCLEAR CELLS AND INCREASE IN FIBROUS STROMA.

LUNG

ATELECTASIS :
FOCAL
THERE IS COLLAPSE OF ALVEOLI.

LIVER

AMYLOID :
SEVERE MULTIFOCAL
HOMOGENEOUS ACIDOPHILIC MATERIAL IS DEPOSITED.

HYPERPLASTIC NODULE :
A NODULE OF HYPERPLASTIC TISSUE IS PRESENT.

SPLEEN

*** LYMPHOMA LYMPHOCYTIC :
THE NEOPLASM OF THE RETICULAR SYSTEM ORIGINATES FROM LYMPHOCYTES.

HEMORRAGIC CYST :
SEVERE MULTIFOCAL
ONE OR SEVERAL CAVITIES FILLED WITH BLOOD.

BONE MARROW

HYPERPLASIA MEGAKARYOCYTE :
THE ORGAN SHOWS AN INCREASED NUMBER OF MEGAKARYOCYTES.

KIDNEYS

LEUKEMIC DEPOSITS :
ORGAN AND THE BLOOD ARE INVADED BY LEUKEMIC CELLS.

PROGRESSIVE NEPHROPATHY :
BILATERAL MODERATE
AN AGE ASSOCIATED KIDNEY LESION CONSISTING OF CYSTIC TUBULES WITH COLLOID OR HYALINE CASTS CHRONIC INTERSTITIAL NEPHRITIS AND DILATATION OF BOWMAN'S CAPSULE WITH GLOMERULAR DEGENERATION .

BLADDER

LEUKEMIC DEPOSITS :
ORGAN AND THE BLOOD ARE INVADED BY LEUKEMIC CELLS.

PITUITARY

ABSENT :
ORGAN OR TISSUE NOT REMOVED FROM ANIMAL OR NOT FOUND IN FIXATIVE.

BAYER AG

NMC. 7 MALE 6 CONTINUED

ADRENALS

LEUKEMIC DEPOSITS :
CONTRALATERAL
ORGAN AND THE BLOOD ARE INVADED BY LEUKEMIC CELLS.

SKELETAL MUSCLE

LEUKEMIC DEPOSITS :
ORGAN AND THE BLOOD ARE INVADED BY LEUKEMIC CELLS.

SEMINAL VESICLES

ATROPHY EPITHELIAL :
THE EPITHELIAL TISSUE IS ATROPHIC AND SCANTY WITH INCREASED FIBROUS STROMA.

COAGULUM :
AN ACIDOPHILIC STRUCTURE RESEMBLING COAGULATED PROTEIN IS PRESENT IN THE LUMEN.

MALE 7 (1611/80)

LUNG

PNEUMONIA :
MODERATE
THE ALVEOLAR WALLS ARE THICKENED AND ALVEOLI CONTAIN INFLAMMATORY CELLS AND FOAMY MACROPHAGES.PERIVASCULAR AND PERIBRONCHIAL LYMPHOCYTIC ACCUMULATIONS MAY BE PRESENT.

LIVER

HYPERPLASTIC NODULES :
WELL DEFINED ROUNDED FOCI OF HYPERPLASTIC AND HYPERTROPHIC CELLS ARE OBSERVED WITHIN THIS OTHERWISE NORMAL TISSUE.

HYPERPLASIA FOCAL :
WELL DEFINED ROUND FOCUS OF HYPERPLASTIC CELLS IS OBSERVED WITHIN THIS OTHERWISE NORMAL TISSUE.

THYMUS

*** LYMPHOMA LYMPHOCYTIC :
THE NEOPLASM OF THE RETICULAR SYSTEM ORIGINATES FROM LYMPHOCYTES.

SPLEEN

HYPERPLASIA LYMPHOID :
THE LYMPHOID FOLLICLES ARE INCREASED IN SIZE.

HEMATOPOIESIS :
MODERATE

NMC. 8 MALE 7 CONTINUED

SPLEEN CONTINUED
THE HEMATOPOIESIS IS EVIDENT.

KIDNEYS

INTERSTITIAL NEPHRITIS :
BILATERAL MINIMAL MULTIFOCAL
INFLAMMATORY CELLS FIBROSIS AND SOME TUBULAR ALTERATIONS ARE ASSOCIATED.

THYROIDS

CYSTS :
MINIMAL
ONE OR MORE CYSTS FILLED WITH CLEAR LIQUID ARE SEEN.

TESTES

ATROPHY SEMINIFEROUS :
UNILATERAL MINIMAL MULTIFOCAL
THERE IS ATROPHY OF SEMINIFEROUS TUBULES WITH DIMINISHED SPERMATOGENIC ACTIVITY.

CALCIFICATION :
UNILATERAL FOCAL
THERE ARE MINERAL DEPOSITS.

MALE 8 (1617/80)

BRAIN

ABSENT :
ORGAN OR TISSUE NOT REMOVED FROM ANIMAL OR NOT FOUND IN FIXATIVE.

HEART

CONGESTION :
VESSELS OR SINUSOIDS ARE MARKEDLY DISTENDED WITH ERYTHROCYTES.

DILATED CHAMBER :
ONE OR MORE OF THE CHAMBERS OF THE HEART ARE DILATED.

LUNG

*** ALVEOLOGENIC CARCINOMA :
A MALIGNANT TUMOR OF THE LUNG TISSUE WITH SYNONYMS IN MICE FOR ADENOMA, CARCINOMA, ALVEOLOGENIC PAPILLARY CARCINOMA, PAPILLARY CYSTADENOMA, ADENOCARCINOMA, BRONCHIOLAR CELL CARCINOMA, BRONCHIOLAR-ALVEOLAR TUMOR, TYPE A TUMOR, TYPE B TUMOR, INTERMEDIATE TYPE I TUMOR AND COMMON PULMONARY TUMOR OF THE MOUSE.

BAYER AG

STOMACH

AUTOLYSIS PARTIAL :
NO OTHER CHANGES ARE SEEN. TISSUES ARE ALTERED.
BY POST-MORTEM MODIFICATIONS AND
DIAGNOSIS IS GIVEN WITH RESERVATION.

LIVER

AUTOLYSIS :
THE TISSUES EXHIBIT AUTOLYSIS AND THEY ARE NOT
INTERPRETABLE.

PANCREAS

ABSENT :
ORGAN OR TISSUE NOT REMOVED FROM ANIMAL OR NOT FOUND IN
FIXATIVE.

SPLEEN

AUTOLYSIS PARTIAL :
NO OTHER CHANGES ARE SEEN. TISSUES ARE ALTERED.
BY POST-MORTEM MODIFICATIONS AND
DIAGNOSIS IS GIVEN WITH RESERVATION.

BLADDER

AUTOLYSIS PARTIAL :
NO OTHER CHANGES ARE SEEN. TISSUES ARE ALTERED.
BY POST-MORTEM MODIFICATIONS AND
DIAGNOSIS IS GIVEN WITH RESERVATION.

PITUITARY

ABSENT :
ORGAN OR TISSUE NOT REMOVED FROM ANIMAL OR NOT FOUND IN
FIXATIVE.

THYROIDS

ABSENT :
ORGAN OR TISSUE NOT REMOVED FROM ANIMAL OR NOT FOUND IN
FIXATIVE.

MESENTERY

*** FIBROMYXOMA :
MALIGNANT TUMOR MADE OF SPINDLE-SHAPED CELLS SCATTERED IN A
MUCOID-LIKE STROMA; MAY OR MAY NOT BE PARTIALLY CALCIFIED.

TESTES

ABSENT :
ORGAN OR TISSUE NOT REMOVED FROM ANIMAL OR NOT FOUND IN
FIXATIVE.

SEMINAL VESICLES

ATROPHY EPITHELIAL :
THE EPITHELIUM IS THINNED.

COAGULUM :

I.MC.10 MALE 8 CONTINUED

SEMINAL VESICLES CONTINUED
AN ACIDOPHILIC STRUCTURE RESEMBLING COAGULATED PROTEIN IS PRESENT IN THE LUMEN.

AUTOLYSIS PARTIAL :
NO OTHER CHANGES ARE SEEN. TISSUES ARE ALTERED.
BY POST-MORTEM MODIFICATIONS AND
DIAGNOSIS IS GIVEN WITH RESERVATION.

MALE 9 (1615/80)

HEART

CONGESTION :
VESSELS OR SINUSOIDS ARE MARKEDLY DISTENDED WITH ERYTHROCYTES.

LUNG

CONGESTION :
SEVERE
VESSELS OR SINUSOIDS ARE MARKEDLY DISTENDED WITH ERYTHROCYTES.

STOMACH

INFLAMMATION CHRONIC :
MODERATE
THERE IS AN INFILTRATION BY MONONUCLEAR CELLS IN THE MUCOSA AND SUBMUCOSA.

SPLEEN

PIGMENTATION :
NUMEROUS MACROPHAGES CONTAIN A GRANULAR BROWN CYTOPLASMIC PIGMENT.

KIDNEYS

PYELITIS :
UNILATERAL MODERATE
INFLAMMATORY CELL INFILTRATION IN THE RENAL PELVIS IS PRESENT.

INTERSTITIAL NEPHRITIS :
BILATERAL MINIMAL MULTIFOCAL
INFLAMMATORY CELLS FIBROSIS AND SOME TUBULAR ALTERATIONS ARE ASSOCIATED.

BLADDER

ABSENT :
ORGAN OR TISSUE NOT REMOVED FROM ANIMAL OR NOT FOUND IN FIXATIVE.

BAYER AG

NMC.11 MALE 9 CONTINUED

THYROIDS

CYSTS :
BILATERAL MODERATE
ONE OR MORE CYSTS FILLED WITH CLEAR LIQUID ARE SEEN.

MALE 10 (1628/80)

SPLEEN

HEMATOPOIESIS :
MODERATE
THE HEMATOPOIESIS IS EVIDENT.

KIDNEYS

INTERSTITIAL NEPHRITIS :
UNILATERAL MINIMAL MULTIFOCAL
INFLAMMATORY CELLS FIBROSIS AND SOME TUBULAR ALTERATIONS ARE ASSOCIATED.

BLADDER

HYPERPLASIA PAPILLOMATOUS :
THE THICKNESS OF THE MUCOSA IS INCREASED MAKING UNUSUALLY HIGH AND NUMEROUS FOLDS.

PITUITARY

ABSENT :
ORGAN OR TISSUE NOT REMOVED FROM ANIMAL OR NOT FOUND IN FIXATIVE.

LYMPH NODE

HYPERPLASIA LYMPHOID :
THE LYMPHOID FOLLICLES ARE INCREASED IN SIZE.

MALE 11 (1619/80)

HEART

INFLAMMATION CHRONIC :
THE INTERSTITIAL TISSUES SHOW INFILTRATION BY MONONUCLEAR CELLS AND INCREASE IN FIBROUS STROMA.

CONGESTION :
VESSELS OR SINUSOIDS ARE MARKEDLY DISTENDED WITH

NMC•12 MALE 11 CONTINUED

HEART CONTINUED

ERYTHROCYTES.

LUNG

PNEUMONIA :
MODERATE
THE ALVEOLAR WALLS ARE THICKENED AND ALVEOLI CONTAIN INFLAMMATORY CELLS AND FOAMY MACROPHAGES.PERIVASCULAR AND PERIBRONCHIAL LYMPHOCYTIC ACCUMULATIONS MAY BE PRESENT.

CONGESTION :
VESSELS OR SINUSOIDS ARE MARKEDLY DISTENDED WITH ERYTHROCYTES.

STOMACH

UNREADABLE :
IT IS NOT POSSIBLE TO INTERPRET THE SECTION DUE TO AN ARTIFACT CAUSED BY SAMPLING OR HISTOLOGICAL TECHNIQUE.

LIVER

MONONUCLEAR CELLS :
MINIMAL MULTIFOCAL
FOCAL COLLECTIONS OF MONONUCLEAR CELLS ARE PRESENT.

PANCREAS

INFLAMMATION CHRONIC :
MINIMAL MULTIFOCAL
THERE IS AN INFILTRATION BY MONONUCLEAR CELLS IN THE MUCOSA AND SUBMUCOSA.

THYMUS

*** LYMPHOMA LYMPHOCYTIC :
THE NEOPLASM OF THE RETICULAR SYSTEM ORIGINATES FROM LYMPHOCYTES.

SPLEEN

HYPERPLASIA LYMPHOID :
THE LYMPHOID FOLLICLES ARE INCREASED IN SIZE.

KIDNEYS

CALCIFICATION :
BILATERAL FOCAL
THERE ARE MINERAL DEPOSITS.

INTERSTITIAL NEPHRITIS :
BILATERAL MINIMAL MULTIFOCAL
INFLAMMATORY CELLS FIBROSIS AND SOME TUBULAR ALTERATIONS ARE ASSOCIATED.

BLADDER

HYPERPLASIA PAPILLOMATOUS :
THE THICKNESS OF THE MUCOSA IS INCREASED MAKING UNUSUALLY HIGH AND NUMEROUS FOLDS.

BAYER BAYER BAYER BAYER

PITUITARY

ABSENT :
ORGAN OR TISSUE NOT REMOVED FROM ANIMAL OR NOT FOUND IN FIXATIVE.

BONE

*** OSTEOMA :
THIS BENIGN WELL CIRCUMSCRIBED TUMOR IS COMPOSED OF WELL-DEVELOPED BONE.

TESTES

SPERMATOCELE :
UNILATERAL
FOCAL CYSTIC DILATATION CONTAINING SPERMATOZOA IS PRESENT.

MALE 12 (1604/80)

HEART

HEMORRHAGE :
MINIMAL MULTIFOCAL
THERE IS EXTRAVASATION OF BLOOD.

MONONUCLEAR CELLS :
MINIMAL MULTIFOCAL
FOCAL COLLECTIONS OF MONONUCLEAR CELLS ARE PRESENT.

LUNG

CONGESTION :
SEVERE
VESSELS OR SINUSOIDS ARE MARKEDLY DISTENDED WITH ERYTHROCYTES.

STOMACH

AUTOLYSIS PARTIAL :
NO OTHER CHANGES ARE SEEN. TISSUES ARE ALTERED.
BY POST-MORTEM MODIFICATIONS AND
DIAGNOSIS IS GIVEN WITH RESERVATION.

LIVER

LEUKEMIC DEPOSITS :
ORGAN AND THE BLOOD ARE INVADED BY LEUKEMIC CELLS.

PANCREAS

AUTOLYSIS PARTIAL :
NO OTHER CHANGES ARE SEEN. TISSUES ARE ALTERED.
BY POST-MORTEM MODIFICATIONS AND

NMC.14 MALE 12 CONTINUED

PANCREAS CONTINUED
DIAGNOSIS IS GIVEN WITH RESERVATION.

SPLEEN

*** LYMPHOMA STEM CELLS :
THE NEOPLASM OF THE RETICULAR SYSTEM ORIGINATES FROM STEM CELLS.

KIDNEYS

AUTOLYSIS PARTIAL :
NO OTHER CHANGES ARE SEEN. TISSUES ARE ALTERED.
BY POST-MORTEM MODIFICATIONS AND
DIAGNOSIS IS GIVEN WITH RESERVATION.

BLADDER

AUTOLYSIS PARTIAL :
NO OTHER CHANGES ARE SEEN. TISSUES ARE ALTERED.
BY POST-MORTEM MODIFICATIONS AND
DIAGNOSIS IS GIVEN WITH RESERVATION.

TESTES

CALCIFICATION :
UNILATERAL MINIMAL MULTIFOCAL
THERE ARE MINERAL DEPOSITS.

SPERMATOCELE :
BILATERAL MINIMAL MULTIFOCAL
FOCAL CYSTIC DILATATION CONTAINING SPERMATOZOA IS PRESENT.

MALE 14 (1625/80)

BRAIN

AUTOLYSIS :
THE TISSUES EXHIBIT AUTOLYSIS AND THEY ARE NOT INTERPRETABLE.

HEART

AUTOLYSIS PARTIAL :
NO OTHER CHANGES ARE SEEN. TISSUES ARE ALTERED.
BY POST-MORTEM MODIFICATIONS AND
DIAGNOSIS IS GIVEN WITH RESERVATION.

LUNG

AUTOLYSIS :
THE TISSUES EXHIBIT AUTOLYSIS AND THEY ARE NOT INTERPRETABLE.

BAYER AG

STOMACH

AUTOLYSIS :
THE TISSUES EXHIBIT AUTOLYSIS AND THEY ARE NOT INTERPRETABLE.

LIVER

AUTOLYSIS :
THE TISSUES EXHIBIT AUTOLYSIS AND THEY ARE NOT INTERPRETABLE.

PANCREAS

AUTOLYSIS :
THE TISSUES EXHIBIT AUTOLYSIS AND THEY ARE NOT INTERPRETABLE.

THYMUS

ABSENT :
ORGAN OR TISSUE NOT REMOVED FROM ANIMAL OR NOT FOUND IN FIXATIVE.

SPLEEN

*** LYMPHOMA LYMPHOCYTIC :
THE NEOPLASM OF THE RETICULAR SYSTEM ORIGINATES FROM LYMPHOCYTES.

AUTOLYSIS PARTIAL :
NO OTHER CHANGES ARE SEEN. TISSUES ARE ALTERED.
BY POST-MORTEM MODIFICATIONS AND
DIAGNOSIS IS GIVEN WITH RESERVATION.

KIDNEYS

AUTOLYSIS :
THE TISSUES EXHIBIT AUTOLYSIS AND THEY ARE NOT INTERPRETABLE.

BLADDER

AUTOLYSIS :
THE TISSUES EXHIBIT AUTOLYSIS AND THEY ARE NOT INTERPRETABLE.

PITUITARY

ABSENT :
ORGAN OR TISSUE NOT REMOVED FROM ANIMAL OR NOT FOUND IN FIXATIVE.

THYROIDS

ABSENT :
ORGAN OR TISSUE NOT REMOVED FROM ANIMAL OR NOT FOUND IN FIXATIVE.

ADRENALS

PIGMENT :
UNILATERAL

NMC.16 MALE 14 CONTINUED

ADRENALS CONTINUED

MANY OF THE CELLS CONTAIN BROWN CYTOPLASMIC PIGMENT.

AUTOLYSIS PARTIAL :
NO OTHER CHANGES ARE SEEN. TISSUES ARE ALTERED.
BY POST-MORTEM MODIFICATIONS AND
DIAGNOSIS IS GIVEN WITH RESERVATION.

SKELETAL MUSCLE

AUTOLYSIS PARTIAL :
NO OTHER CHANGES ARE SEEN. TISSUES ARE ALTERED.
BY POST-MORTEM MODIFICATIONS AND
DIAGNOSIS IS GIVEN WITH RESERVATION.

SCIATIC NERVE

AUTOLYSIS PARTIAL :
NO OTHER CHANGES ARE SEEN. TISSUES ARE ALTERED.
BY POST-MORTEM MODIFICATIONS AND
DIAGNOSIS IS GIVEN WITH RESERVATION.

TESTES

AUTOLYSIS PARTIAL :
NO OTHER CHANGES ARE SEEN. TISSUES ARE ALTERED.
BY POST-MORTEM MODIFICATIONS AND
DIAGNOSIS IS GIVEN WITH RESERVATION.

MALE 15 (1612/80

HEART

FIBROSIS :
MINIMAL MULTIFOCAL
THERE IS AN INCREASE IN INTERSTITIAL FIBROUS TISSUE.

LUNG

PNEUMONIA :
MODERATE
THE ALVEOLAR WALLS ARE THICKENED AND ALVEOLI CONTAIN INFLAMMATORY CELLS AND FOAMY MACROPHAGES. PERIVASCULAR AND PERIBRONCHIAL LYMPHOCYTIC ACCUMULATIONS MAY BE PRESENT.

LIVER

NECROSIS :
MULTIFOCAL
THE TISSUE HAS LOST ITS NORMAL STRUCTURE DUE TO CELL DEATH WHICH MAY BE OF VARIOUS ORIGIN.

CONGESTION :
VESSELS OR SINUSOIDS ARE MARKEDLY DISTENDED WITH ERYTHROCYTES.

BAYER AG

SPLEEN

HEMATOPOIESIS :
SEVERE
THE HEMATOPOIESIS IS EVIDENT.

CONGESTION :
SEVERE
VESSELS OR SINUSOIDS ARE MARKEDLY DISTENDED WITH ERYTHROCYTES.

KIDNEYS

CALCIFICATION :
UNILATERAL MULTIFOCAL
THERE ARE MINERAL DEPOSITS.

HEMORRHAGE :
UNILATERAL SEVERE
THERE IS EXTRAVASATION OF BLOOD.

INTERSTITIAL NEPHRITIS :
BILATERAL MINIMAL MULTIFOCAL
INFLAMMATORY CELLS FIBROSIS AND SOME TUBULAR ALTERATIONS ARE ASSOCIATED.

CYSTS :
UNILATERAL
ONE OR MORE CYSTS FILLED WITH CLEAR LIQUID ARE SEEN.

DILATATION OF GLOMERULAR LOOPS :
BILATERAL MODERATE
GLOMERULAR LOOPS APPEAR UNUSUALLY ENLARGED AND THIN.

BLADDER

INFLAMMATION CHRONIC :
MODERATE
THERE IS AN INFILTRATION BY MONONUCLEAR CELLS IN THE MUCOSA AND SUBMUCOSA.

PITUITARY

ABSENT :
ORGAN OR TISSUE NOT REMOVED FROM ANIMAL OR NOT FOUND IN FIXATIVE.

THYROIDS

ABSENT :
ORGAN OR TISSUE NOT REMOVED FROM ANIMAL OR NOT FOUND IN FIXATIVE.

TESTES

CALCIFICATION :
UNILATERAL
THERE ARE MINERAL DEPOSITS.

*** INTERSTITIAL CELL TUMOR :
UNILATERAL
THIS BENIGN TUMOR IS COMPOSED OF LARGE EPITHELIAL CELLS

NMC•18 MALE 15 CONTINUED

TESTES CONTINUED
WITH ABUNDANT ACIDOPHILIC CYTOPLASM.

MALE 17 (1624/80)

HEART

CONGESTION :
VESSELS OR SINUSOIDS ARE MARKEDLY DISTENDED WITH ERYTHROCYTES.

LUNG

ATELECTASIS :
MULTIFOCAL
THERE IS COLLAPSE OF ALVEOLI.

STOMACH

ABSENT :
ORGAN OR TISSUE NOT REMOVED FROM ANIMAL OR NOT FOUND IN FIXATIVE.

PANCREAS

AUTOLYSIS PARTIAL :
NO OTHER CHANGES ARE SEEN. TISSUES ARE ALTERED.
BY POST-MORTEM MODIFICATIONS AND
DIAGNOSIS IS GIVEN WITH RESERVATION.

KIDNEYS

CONGESTION :
VESSELS OR SINUSOIDS ARE MARKEDLY DISTENDED WITH ERYTHROCYTES.

BLADDER

HYPERPLASIA PAPILLOMATOUS :
THE THICKNESS OF THE MUCOSA IS INCREASED MAKING UNUSUALLY HIGH AND NUMEROUS FOLDS.

THYROIDS

ABSENT :
ORGAN OR TISSUE NOT REMOVED FROM ANIMAL OR NOT FOUND IN FIXATIVE.

MALE 18 (1010/80)

BAYER AG

HEART

CONGESTION :
VESSELS OR SINUSOIDS ARE MARKEDLY DISTENDED WITH ERYTHROCYTES.

LUNG

CONGESTION :
VESSELS OR SINUSOIDS ARE MARKEDLY DISTENDED WITH ERYTHROCYTES.

STOMACH

AUTOLYSIS PARTIAL :
NO OTHER CHANGES ARE SEEN. TISSUES ARE ALTERED.
BY POST-MORTEM MODIFICATIONS AND
DIAGNOSIS IS GIVEN WITH RESERVATION.

LIVER

NORMAL :
HISTOLOGICAL ASPECT WITHIN NORMAL LIMITS.

SPLEEN

HEMATOPOIESIS :
SEVERE
THE HEMATOPOIESIS IS EVIDENT.

KIDNEYS

HYDRONEPHROSIS :
BILATERAL MODERATE
THE RENAL PELVIS IS DILATED AND THE ADJACENT PARENCHYMA IS REDUCED.

PROGRESSIVE NEPHROPATHY :
BILATERAL MODERATE
AN AGE ASSOCIATED KIDNEY LESION CONSISTING OF CYSTIC TUBULES WITH COLLOID OR HYALINE CASTS CHRONIC INTERSTITIAL NEPHRITIS AND DILATATION OF BOWMAN'S CAPSULE WITH GLOMERULAR DEGENERATION .

BLADDER

AUTOLYSIS PARTIAL :
NO OTHER CHANGES ARE SEEN. TISSUES ARE ALTERED.
BY POST-MORTEM MODIFICATIONS AND
DIAGNOSIS IS GIVEN WITH RESERVATION.

LYMPH NODE

*** LYMPHOMA STEM CELLS :
THE NEOPLASM OF THE RETICULAR SYSTEM ORIGINATES FROM STEM CELLS.

MALE 20 (1638/80)

HEART

CONGESTION :
VESSELS OR SINUSOIDS ARE MARKEDLY DISTENDED WITH ERYTHROCYTES.

LUNG

*** ALVEOLOGENIC CARCINOMA :
MULTIFOCAL
A MALIGNANT TUMOR OF THE LUNG TISSUE WITH SYNONYMS IN MICE FOR ADENOMA, CARCINOMA, ALVEOLOGENIC PAPILLARY CARCINOMA, PAPILLARY CYSTADENOMA, ADENOCARCINOMA, BRONCHIOLAR CELL CARCINOMA, BRONCHIOLAR-ALVEOLAR TUMOR, TYPE A TUMOR, TYPE B TUMOR, INTERMEDIATE TYPE I TUMOR AND COMMON PULMONARY TUMOR OF THE MOUSE.

STOMACH

AUTOLYSIS :
THE TISSUES EXHIBIT AUTOLYSIS AND THEY ARE NOT INTERPRETABLE.

BLADDER

AUTOLYSIS :
THE TISSUES EXHIBIT AUTOLYSIS AND THEY ARE NOT INTERPRETABLE.

PITUITARY

ABSENT :
ORGAN OR TISSUE NOT REMOVED FROM ANIMAL OR NOT FOUND IN FIXATIVE.

THYROIDS

AUTOLYSIS PARTIAL :
NO OTHER CHANGES ARE SEEN. TISSUES ARE ALTERED BY POST-MORTEM MODIFICATIONS AND DIAGNOSIS IS GIVEN WITH RESERVATION.

MALE 21 (1608/80)

BAYER AG

LUNG

PNEUMONIA :
MODERATE
THE ALVEOLAR WALLS ARE THICKENED AND ALVEOLI CONTAIN INFLAMMATORY CELLS AND FOAMY MACROPHAGES.PERIVASCULAR AND PERIBRONCHIAL LYMPHOCYTIC ACCUMULATIONS MAY BE PRESENT.

STOMACH

AUTOLYSIS PARTIAL :
NO OTHER CHANGES ARE SEEN. TISSUES ARE ALTERED. BY POST-MORTEM MODIFICATIONS AND DIAGNOSIS IS GIVEN WITH RESERVATION.

LIVER

LEUKEMIC DEPOSITS :
ORGAN AND THE BLOOD ARE INVADED BY LEUKEMIC CELLS.

PANCREAS

AUTOLYSIS PARTIAL :
NO OTHER CHANGES ARE SEEN. TISSUES ARE ALTERED. BY POST-MORTEM MODIFICATIONS AND DIAGNOSIS IS GIVEN WITH RESERVATION.

SPLEEN

HEMORRHAGE :
THERE IS EXTRAVASATION OF BLOOD.

*** LYMPHOMA STEM CELLS :
THE NEOPLASM OF THE RETICULAR SYSTEM ORIGINATES FROM STEM CELLS.

KIDNEYS

HYDRONEPHROSIS :
UNILATERAL MINIMAL
THE RENAL PELVIS IS DILATED AND THE ADJACENT PARENCHYMA IS REDUCED.

LEUKEMIC DEPOSITS :
BILATERAL
ORGAN AND THE BLOOD ARE INVADED BY LEUKEMIC CELLS.

BLADDER

AUTOLYSIS PARTIAL :
NO OTHER CHANGES ARE SEEN. TISSUES ARE ALTERED. BY POST-MORTEM MODIFICATIONS AND DIAGNOSIS IS GIVEN WITH RESERVATION.

PITUITARY

ABSENT :
ORGAN OR TISSUE NOT REMOVED FROM ANIMAL OR NOT FOUND IN FIXATIVE.

THYROIDS

ABSENT :
ORGAN OR TISSUE NOT REMOVED FROM ANIMAL OR NOT FOUND IN FIXATIVE.

ADRENALS

LEUKEMIC DEPOSITS :
ORGAN AND THE BLOOD ARE INVADED BY LEUKEMIC CELLS.

MESENTERY

LEUKEMIC DEPOSITS :
ORGAN AND THE BLOOD ARE INVADED BY LEUKEMIC CELLS.

LYMPH NODE

*** LYMPHOMA STEM CELLS :
THE NEOPLASM OF THE RETICULAR SYSTEM ORIGINATES FROM STEM CELLS.

MALE 23 (1614/80)

HEART

CONGESTION :
VESSELS OR SINUSOIDS ARE MARKEDLY DISTENDED WITH ERYTHROCYTES.

LUNG

*** ALVEOLOGENIC CARCINOMA :
A MALIGNANT TUMOR OF THE LUNG TISSUE WITH SYNONYMS IN MICE FOR ADENOMA, CARCINOMA, ALVEOLOGENIC PAPILLARY CARCINOMA, PAPILLARY CYSTADENOMA, ADENOCARCINOMA, BRONCHIOLAR CELL CARCINOMA, BRONCHIOLAR-ALVEOLAR TUMOR, TYPE A TUMOR, TYPE B TUMOR, INTERMEDIATE TYPE I TUMOR AND COMMON PULMONARY TUMOR OF THE MOUSE.

STOMACH

NORMAL :
HISTOLOGICAL ASPECT WITHIN NORMAL LIMITS.

SPLEEN

PIGMENTATION :
NUMEROUS MACROPHAGES CONTAIN A GRANULAR BROWN CYTOPLASMIC PIGMENT.

*** LYMPHOMA LYMPHOCYTIC :

BAYER AG BAYER AG BAYER AG

NMC.23 MALE 23 CONTINUED

SPLEEN CONTINUED

THE NEOPLASM OF THE RETICULAR SYSTEM ORIGINATES FROM LYMPHOCYTES.

KIDNEYS

INTERSTITIAL NEPHRITIS :
UNILATERAL MINIMAL MULTIFOCAL
INFLAMMATORY CELLS FIBROSIS AND SOME TUBULAR ALTERATIONS ARE ASSOCIATED.

THYROIDS

ABSENT :
ORGAN OR TISSUE NOT REMOVED FROM ANIMAL OR NOT FOUND IN FIXATIVE.

INTESTINE

NORMAL :
HISTOLOGICAL ASPECT WITHIN NORMAL LIMITS.

MALE 25 (1634/80)

BRAIN

AUTOLYSIS PARTIAL :
NO OTHER CHANGES ARE SEEN. TISSUES ARE ALTERED. BY POST-MORTEM MODIFICATIONS AND DIAGNOSIS IS GIVEN WITH RESERVATION.

LUNG

*** ALVEOLOGENIC CARCINOMA :
A MALIGNANT TUMOR OF THE LUNG TISSUE WITH SYNONYMS IN MICE FOR ADENOMA, CARCINOMA, ALVEOLOGENIC PAPILLARY CARCINOMA, PAPILLARY CYSTADENOMA, ADENOCARCINOMA, BRONCHIOLAR CELL CARCINOMA, BRONCHIOLAR-ALVEOLAR TUMOR, TYPE A TUMOR, TYPE B TUMOR, INTERMEDIATE TYPE I TUMOR AND COMMON PULMONARY TUMOR OF THE MOUSE.

CONGESTION :
SEVERE
VESSELS OR SINUSOIDS ARE MARKEDLY DISTENDED WITH ERYTHROCYTES.

LIVER

*** ADENOMA HEPATIC BENIGN :
DISTINCT NODULES COMPRESS THE ADJACENT LIVER PARENCHYMA, ARE CHARACTERIZED BY WELL DIFFERENTIATED HEPATOCYTES AND DO NOT SHOW PORTAL TRIADS.

*** METASTASIS :

NMC•24 MALE 25 CONTINUED

LIVER CONTINUED

A SECONDARY MALIGNANT TUMOR DEVELOPED AWAY FROM THE INITIAL GROWTH.

PANCREAS

HYPERPLASIA ISLETS :
THE ISLETS ARE INCREASED IN NUMBER AND SIZE.

SPLEEN

HEMATOPOIESIS :
THE HEMATOPOIESIS IS EVIDENT.

KIDNEYS

CONGESTION :
SEVERE
VESSELS OR SINUSOIDS ARE MARKEDLY DISTENDED WITH ERYTHROCYTES.

INTERSTITIAL NEPHRITIS :
BILATERAL MINIMAL MULTIFOCAL
INFLAMMATORY CELLS FIBROSIS AND SOME TUBULAR ALTERATIONS ARE ASSOCIATED.

PITUITARY

UNREADABLE :
IT IS NOT POSSIBLE TO INTERPRET THE SECTION DUE TO AN ARTIFACT CAUSED BY SAMPLING OR HISTOLOGICAL TECHNIQUE.

SKELETAL MUSCLE

ABSENT :
ORGAN OR TISSUE NOT REMOVED FROM ANIMAL OR NOT FOUND IN FIXATIVE.

SCIATIC NERVE

ABSENT :
ORGAN OR TISSUE NOT REMOVED FROM ANIMAL OR NOT FOUND IN FIXATIVE.

TESTES

ATROPHY SEMINIFEROUS :
BILATERAL MULTIFOCAL
THERE IS ATROPHY OF SEMINIFEROUS TUBULES WITH DIMINISHED SPERMATOGENIC ACTIVITY.

BAYER AG

MALE 27 (0261/81)

LUNG

PNEUMONIA :
MINIMAL
THE ALVEOLAR WALLS ARE THICKENED AND ALVEOLI CONTAIN INFLAMMATORY CELLS AND FOAMY MACROPHAGES.PERIVASCULAR AND PERIBRONCHIAL LYMPHOCYTIC ACCUMULATIONS MAY BE PRESENT.

*** ALVEOLOGENIC CARCINOMA :
A MALIGNANT TUMOR OF THE LUNG TISSUE WITH SYNONYMS IN MICE FOR ADENOMA, CARCINOMA, ALVEOLOGENIC PAPILLARY CARCINOMA, PAPILLARY CYSTADENOMA, ADENOCARCINOMA, BRONCHIOLAR CELL CARCINOMA, BRONCHIOLAR-ALVEOLAR TUMOR, TYPE A TUMOR, TYPE B TUMOR, INTERMEDIATE TYPE I TUMOR AND COMMON PULMONARY TUMOR OF THE MOUSE.

STOMACH

INFLAMMATION CHRONIC :
MINIMAL FOCAL
THERE IS AN INFILTRATION BY MONONUCLEAR CELLS IN THE MUCOSA AND SUBMUCOSA.

LIVER

*** ADENOMA HEPATIC BENIGN :
DISTINCT NODULES COMPRESS THE ADJACENT LIVER PARENCHYMA, ARE CHARACTERIZED BY WELL DIFFERENTIATED HEPATOCYTES AND DO NOT SHOW PORTAL TRIADS.

MONONUCLEAR CELLS :
MODERATE
FOCAL COLLECTIONS OF MONONUCLEAR CELLS ARE PRESENT.

AMYLOID :
MULTIFOCAL
HOMOGENEOUS ACIDOPHILIC MATERIAL IS DEPOSITED.

SPLEEN

HEMATOPOIESIS :
SEVERE
THE HEMATOPOIESIS IS EVIDENT.

KIDNEYS

INTERSTITIAL NEPHRITIS :
BILATERAL MINIMAL MULTIFOCAL
INFLAMMATORY CELLS FIBROSIS AND SOME TUBULAR ALTERATIONS ARE ASSOCIATED.

BLADDER

HYPERPLASIA PAPILLOMATOUS :
THE THICKNESS OF THE MUCOSA IS INCREASED MAKING UNUSUALLY HIGH AND NUMEROUS FOLDS.

PITUITARY

ABSENT :

NMC.26 MALE 27 CONTINUED

PITUITARY CONTINUED
ORGAN OR TISSUE NOT REMOVED FROM ANIMAL OR NOT FOUND IN FIXATIVE.

MALE 28 (1637/80)

LUNG

ABSENT :
ORGAN OR TISSUE NOT REMOVED FROM ANIMAL OR NOT FOUND IN FIXATIVE.

KIDNEYS

INTERSTITIAL NEPHRITIS :
BILATERAL MINIMAL MULTIFOCAL
INFLAMMATORY CELLS FIBROSIS AND SOME TUBULAR ALTERATIONS ARE ASSOCIATED.

BLADDER

ABSENT :
ORGAN OR TISSUE NOT REMOVED FROM ANIMAL OR NOT FOUND IN FIXATIVE.

MALE 29 (1623/80)

HEART

CONGESTION :
VESSELS OR SINUSOIDS ARE MARKEDLY DISTENDED WITH ERYTHROCYTES.

LUNG

EDEMA :
THE INTERSTITIAL TISSUES CONTAIN AN INCREASED AMOUNT OF FLUID.

LEUKEMIC DEPOSITS :
ORGAN AND THE BLOOD ARE INVADED BY LEUKEMIC CELLS.

STOMACH

AUTOLYSIS PARTIAL :
NO OTHER CHANGES ARE SEEN. TISSUES ARE ALTERED.
BY POST-MORTEM MODIFICATIONS AND

BAYER AG

STOMACH CONTINUED
DIAGNOSIS IS GIVEN WITH RESERVATION.

LIVER

CONGESTION :
VESSELS OR SINUSOIDS ARE MARKEDLY DISTENDED WITH ERYTHROCYTES.

HEPATOCYTIC HYPERPIGMENTATION :
HEPATOCYTES ARE LADEN WITH GRANULES OF HEMOSIDERIN OR BILE OR OTHER PIGMENT.

PANCREAS

ABSENT :
ORGAN OR TISSUE NOT REMOVED FROM ANIMAL OR NOT FOUND IN FIXATIVE.

SPLEEN

*** LYMPHOMA LYMPHOCYTIC :
THE NEOPLASM OF THE RETICULAR SYSTEM ORIGINATES FROM LYMPHOCYTES.

KIDNEYS

AUTOLYSIS PARTIAL :
NO OTHER CHANGES ARE SEEN. TISSUES ARE ALTERED.
BY POST-MORTEM MODIFICATIONS AND
DIAGNOSIS IS GIVEN WITH RESERVATION.

BLADDER

ABSENT :
ORGAN OR TISSUE NOT REMOVED FROM ANIMAL OR NOT FOUND IN FIXATIVE.

LYMPH NODE

*** LYMPHOMA LYMPHOCYTIC :
THE NEOPLASM OF THE RETICULAR SYSTEM ORIGINATES FROM LYMPHOCYTES.

MALE 30 (1635/80)

HEART

LEUKEMIC DEPOSITS :
ORGAN AND THE BLOOD ARE INVADED BY LEUKEMIC CELLS.

LUNG

PIGMENTATION :

NMC.28 MALE 30 CONTINUED

LUNG CONTINUED

NUMEROUS MACROPHAGES CONTAIN A GRANULAR BROWN CYTOPLASMIC PIGMENT.

*** ALVEOLOGENIC CARCINOMA :
A MALIGNANT TUMOR OF THE LUNG TISSUE WITH SYNONYMS IN MICE FOR ADENOMA, CARCINOMA, ALVEOLOGENIC PAPILLARY CARCINOMA, PAPILLARY CYSTADENOMA, ADENOCARCINOMA, BRONCHIOLAR CELL CARCINOMA, BRONCHIOLAR-ALVEOLAR TUMOR, TYPE A TUMOR, TYPE B TUMOR, INTERMEDIATE TYPE I TUMOR AND COMMON PULMONARY TUMOR OF THE MOUSE.

LEUKEMIC DEPOSITS :
ORGAN AND THE BLOOD ARE INVADED BY LEUKEMIC CELLS.

STOMACH

LEUKEMIC DEPOSITS :
ORGAN AND THE BLOOD ARE INVADED BY LEUKEMIC CELLS.

LIVER

LEUKEMIC DEPOSITS :
ORGAN AND THE BLOOD ARE INVADED BY LEUKEMIC CELLS.

PANCREAS

LEUKEMIC DEPOSITS :
ORGAN AND THE BLOOD ARE INVADED BY LEUKEMIC CELLS.

SPLEEN

*** LYMPHOMA LYMPHOCYTIC :
THE NEOPLASM OF THE RETICULAR SYSTEM ORIGINATES FROM LYMPHOCYTES.

KIDNEYS

LEUKEMIC DEPOSITS :
ORGAN AND THE BLOOD ARE INVADED BY LEUKEMIC CELLS.

PITUITARY

ABSENT :
ORGAN OR TISSUE NOT REMOVED FROM ANIMAL OR NOT FOUND IN FIXATIVE.

SKELETAL MUSCLE

LEUKEMIC DEPOSITS :
ORGAN AND THE BLOOD ARE INVADED BY LEUKEMIC CELLS.

BAYER AG

SCIATIC NERVE

ABSENT :
ORGAN OR TISSUE NOT REMOVED FROM ANIMAL OR NOT FOUND IN FIXATIVE.

MESENTERY

LEUKEMIC DEPOSITS :
ORGAN AND THE BLOOD ARE INVADED BY LEUKEMIC CELLS.

FEMUR

ABSENT :
ORGAN OR TISSUE NOT REMOVED FROM ANIMAL OR NOT FOUND IN FIXATIVE.

LYMPH NODE

*** LYMPHOMA LYMPHOCYTIC :
THE NEOPLASM OF THE RETICULAR SYSTEM ORIGINATES FROM LYMPHOCYTES.

MALE 32 (1633/80)

HEART

CONGESTION :
VESSELS OR SINUSOIDS ARE MARKEDLY DISTENDED WITH ERYTHROCYTES.

LUNG

*** ALVEOLOGENIC CARCINOMA :
A MALIGNANT TUMOR OF THE LUNG TISSUE WITH SYNONYMS IN MICE FOR ADENOMA, CARCINOMA, ALVEOLOGENIC PAPILLARY CARCINOMA, PAPILLARY CYSTADENOMA, ADENOCARCINOMA, BRONCHIOLAR CELL CARCINOMA, BRONCHIOLAR-ALVEOLAR TUMOR, TYPE A TUMOR, TYPE B TUMOR, INTERMEDIATE TYPE I TUMOR AND COMMON PULMONARY TUMOR OF THE MOUSE.

KIDNEYS

HYDRONEPHROSIS :
UNILATERAL MINIMAL MULTIFOCAL
THE RENAL PELVIS IS DILATED AND THE ADJACENT PARENCHYMA IS REDUCED.

BLADDER

AUTOLYSIS PARTIAL :
NO OTHER CHANGES ARE SEEN. TISSUES ARE ALTERED.

NMC•30 MALE 32 CONTINUED

BLADDER CONTINUED
BY POST-MORTEM MODIFICATIONS AND
DIAGNOSIS IS GIVEN WITH RESERVATION.

PITUITARY

NORMAL :
HISTOLOGICAL ASPECT WITHIN NORMAL LIMITS.

MALE 34 (1621/80)

LUNG

*** ALVEOLOGENIC CARCINOMA :
A MALIGNANT TUMOR OF THE LUNG TISSUE WITH
SYNONYMS IN MICE FOR ADENOMA, CARCINOMA,
ALVEOLOGENIC PAPILLARY CARCINOMA, PAPILLARY
CYSTADENOMA, ADENOCARCINOMA, BRONCHIOLAR
CELL CARCINOMA, BRONCHIOLAR-ALVEOLAR TUMOR,
TYPE A TUMOR, TYPE B TUMOR, INTERMEDIATE
TYPE I TUMOR AND COMMON PULMONARY TUMOR OF
THE MOUSE.

LIVER

CALCIFICATION :
SEVERE MULTIFOCAL
THERE ARE MINERAL DEPOSITS.

*** ADENOCARCINOMA
MALIGNANT EPITHELIAL TUMOR SHOWING VARIOUS WELL
DIFFERENTIATED MORPHOLOGICAL ASPECTS.

VACUOLIZATION :
IN THESE CELLS THERE ARE CLEAR VACUOLES GREATER IN NUMBER
AND SIZE THAN NORMALLY FOUND.

HEPATOCYTIC HYPERPIGMENTATION :
HEPATOCYTES ARE LADEN WITH GRANULES OF HEMOSIDERIN OR BILE
OR OTHER PIGMENT.

KIDNEYS

INTERSTITIAL NEPHRITIS :
BILATERAL MINIMAL MULTIFOCAL
INFLAMMATORY CELLS FIBROSIS AND SOME TUBULAR ALTERATIONS
ARE ASSOCIATED.

CYSTS :
BILATERAL MODERATE MULTIFOCAL
ONE OR MORE CYSTS FILLED WITH CLEAR LIQUID ARE SEEN.

THYROIDS

ABSENT :

BAYER AG

NMC.31 MALE 34 CONTINUED

THYROIDS CONTINUED

ORGAN OR TISSUE NOT REMOVED FROM ANIMAL OR NOT FOUND IN FIXATIVE.

TESTES

ATROPHY SEMINIFEROUS :
UNILATERAL MINIMAL
THERE IS ATROPHY OF SEMINIFEROUS TUBULES WITH DIMINISHED SPERMATOGENIC ACTIVITY.

SEMINAL VESICLES

ATROPHY EPITHELIAL :
THE EPITHELIUM IS THINNED.

ECTASIA SIMPLE :
THE LUMEN OF THE ORGAN IS ABNORMALLY ENLARGED.

COAGULUM :
AN ACIDOPHILIC STRUCTURE RESEMBLING COAGULATED PROTEIN IS PRESENT IN THE LUMEN.

MALE 36 (1613/80)

BRAIN

ABSENT :
ORGAN OR TISSUE NOT REMOVED FROM ANIMAL OR NOT FOUND IN FIXATIVE.

LUNG

*** ALVEOLOGENIC CARCINOMA :
A MALIGNANT TUMOR OF THE LUNG TISSUE WITH SYNONYMS IN MICE FOR ADENOMA, CARCINOMA, ALVEOLOGENIC PAPILLARY CARCINOMA, PAPILLARY CYSTADENOMA, ADENOCARCINOMA, BRONCHIOLAR CELL CARCINOMA, BRONCHIOLAR-ALVEOLAR TUMOR, TYPE A TUMOR, TYPE B TUMOR, INTERMEDIATE TYPE I TUMOR AND COMMON PULMONARY TUMOR OF THE MOUSE.

STOMACH

AUTOLYSIS PARTIAL :
NO OTHER CHANGES ARE SEEN. TISSUES ARE ALTERED. BY POST-MORTEM MODIFICATIONS AND DIAGNOSIS IS GIVEN WITH RESERVATION.

LIVER

*** ADENOCARCINOMA :
MALIGNANT EPITHELIAL TUMOR SHOWING VARIOUS WELL DIFFERENTIATED MORPHOLOGICAL ASPECTS.

AUTOLYSIS PARTIAL :

NMC.39 MALE 36 CONTINUED

LIVER CONTINUED

NO OTHER CHANGES ARE SEEN. TISSUES ARE ALTERED.
BY POST-MORTEM MODIFICATIONS AND
DIAGNOSIS IS GIVEN WITH RESERVATION.

PANCREAS

UNREADABLE :
IT IS NOT POSSIBLE TO INTERPRET THE SECTION DUE TO AN
ARTIFACT CAUSED BY SAMPLING OR HISTOLOGICAL TECHNIQUE.

AUTOLYSIS PARTIAL :
NO OTHER CHANGES ARE SEEN. TISSUES ARE ALTERED.
BY POST-MORTEM MODIFICATIONS AND
DIAGNOSIS IS GIVEN WITH RESERVATION.

SPLEEN

PIGMENTATION :
NUMEROUS MACROPHAGES CONTAIN A GRANULAR BROWN CYTOPLASMIC
PIGMENT.

KIDNEYS

INTERSTITIAL NEPHRITIS :
BILATERAL MODERATE MULTIFOCAL
INFLAMMATORY CELLS FIBROSIS AND SOME TUBULAR ALTERATIONS
ARE ASSOCIATED.

BLADDER

AUTOLYSIS PARTIAL :
NO OTHER CHANGES ARE SEEN. TISSUES ARE ALTERED.
BY POST-MORTEM MODIFICATIONS AND
DIAGNOSIS IS GIVEN WITH RESERVATION.

PITUITARY

ABSENT :
ORGAN OR TISSUE NOT REMOVED FROM ANIMAL OR NOT FOUND IN
FIXATIVE.

THYROIDS

AUTOLYSIS PARTIAL :
NO OTHER CHANGES ARE SEEN. TISSUES ARE ALTERED.
BY POST-MORTEM MODIFICATIONS AND
DIAGNOSIS IS GIVEN WITH RESERVATION.

MALE 37 (1022/60)

BRAIN

ABSENT :
ORGAN OR TISSUE NOT REMOVED FROM ANIMAL OR NOT FOUND IN

BAYER AG

NMC•33 MALE 37 CONTINUED

BRAIN CONTINUED

FIXATIVE.

HEART

AUTOLYSIS :
THE TISSUES EXHIBIT AUTOLYSIS AND THEY ARE NOT INTERPRETABLE.

LUNG

AUTOLYSIS :
THE TISSUES EXHIBIT AUTOLYSIS AND THEY ARE NOT INTERPRETABLE.

STOMACH

AUTOLYSIS :
THE TISSUES EXHIBIT AUTOLYSIS AND THEY ARE NOT INTERPRETABLE.

LIVER

AUTOLYSIS :
THE TISSUES EXHIBIT AUTOLYSIS AND THEY ARE NOT INTERPRETABLE.

PANCREAS

AUTOLYSIS :
THE TISSUES EXHIBIT AUTOLYSIS AND THEY ARE NOT INTERPRETABLE.

SPLEEN

AUTOLYSIS :
THE TISSUES EXHIBIT AUTOLYSIS AND THEY ARE NOT INTERPRETABLE.

KIDNEYS

AUTOLYSIS :
THE TISSUES EXHIBIT AUTOLYSIS AND THEY ARE NOT INTERPRETABLE.

BLADDER

AUTOLYSIS :
THE TISSUES EXHIBIT AUTOLYSIS AND THEY ARE NOT INTERPRETABLE.

PITUITARY

ABSENT :
ORGAN OR TISSUE NOT REMOVED FROM ANIMAL OR NOT FOUND IN FIXATIVE.

THYROIDS

AUTOLYSIS :
THE TISSUES EXHIBIT AUTOLYSIS AND THEY ARE NOT INTERPRETABLE.

ADRENALS

AUTOLYSIS :
THE TISSUES EXHIBIT AUTOLYSIS AND THEY ARE NOT INTERPRETABLE.

SKELETAL MUSCLE

AUTOLYSIS :
THE TISSUES EXHIBIT AUTOLYSIS AND THEY ARE NOT INTERPRETABLE.

SCIATIC NERVE

AUTOLYSIS :
THE TISSUES EXHIBIT AUTOLYSIS AND THEY ARE NOT INTERPRETABLE.

TESTES

AUTOLYSIS :
THE TISSUES EXHIBIT AUTOLYSIS AND THEY ARE NOT INTERPRETABLE.

MALE 38 (1607/80)

LUNG

LEUKEMIC DEPOSITS :
ORGAN AND THE BLOOD ARE INVADED BY LEUKEMIC CELLS.

STOMACH

LEUKEMIC DEPOSITS :
ORGAN AND THE BLOOD ARE INVADED BY LEUKEMIC CELLS.

LIVER

LEUKEMIC DEPOSITS :
ORGAN AND THE BLOOD ARE INVADED BY LEUKEMIC CELLS.

PANCREAS

LEUKEMIC DEPOSITS :
ORGAN AND THE BLOOD ARE INVADED BY LEUKEMIC CELLS.

THYMUS

*** LYMPHOMA LYMPHOCYTIC :
THE NEOPLASM OF THE RETICULAR SYSTEM ORIGINATES FROM LYMPHOCYTES.

BAYER AG

SPLEEN

*** LYMPHOMA LYMPHOCYTIC :
THE NEOPLASM OF THE RETICULAR SYSTEM ORIGINATES FROM LYMPHOCYTES.

KIDNEYS

LEUKEMIC DEPOSITS :
BILATERAL
ORGAN AND THE BLOOD ARE INVADED BY LEUKEMIC CELLS.

BLADDER

LEUKEMIC DEPOSITS :
ORGAN AND THE BLOOD ARE INVADED BY LEUKEMIC CELLS.

PITUITARY

ABSENT :
ORGAN OR TISSUE NOT REMOVED FROM ANIMAL OR NOT FOUND IN FIXATIVE.

ADRENALS

LEUKEMIC DEPOSITS :
BILATERAL
ORGAN AND THE BLOOD ARE INVADED BY LEUKEMIC CELLS.

TESTES

ATROPHY SEMINIFEROUS :
UNILATERAL
THERE IS ATROPHY OF SEMINIFEROUS TUBULES WITH DIMINISHED SPERMATOGENIC ACTIVITY.

CALCIFICATION :
UNILATERAL MULTIFOCAL
THERE ARE MINERAL DEPOSITS.

FEMUR

ABSENT :
ORGAN OR TISSUE NOT REMOVED FROM ANIMAL OR NOT FOUND IN FIXATIVE.

MALE 39 (1616/80)

BRAIN

ABSENT :
ORGAN OR TISSUE NOT REMOVED FROM ANIMAL OR NOT FOUND IN

NMC•36 MALE 39 CONTINUED

BRAIN CONTINUED

FIXATIVE.

HEART

THROMBOSIS :
THE VASCULAR LUMEN CONTAINS AN ATTACHED ANTE MORTEM BLOOD CLOT.

CONGESTION :
VESSELS OR SINUSOIDS ARE MARKEDLY DISTENDED WITH ERYTHROCYTES.

AUTOLYSIS PARTIAL :
NO OTHER CHANGES ARE SEEN. TISSUES ARE ALTERED. BY POST-MORTEM MODIFICATIONS AND DIAGNOSIS IS GIVEN WITH RESERVATION.

LUNG

*** ALVEOLOGENIC CARCINOMA :
A MALIGNANT TUMOR OF THE LUNG TISSUE WITH SYNONYMS IN MICE FOR ADENOMA, CARCINOMA, ALVEOLOGENIC PAPILLARY CARCINOMA, PAPILLARY CYSTADENOMA, ADENOCARCINOMA, BRONCHIOLAR CELL CARCINOMA, BRONCHIOLAR-ALVEOLAR TUMOR, TYPE A TUMOR, TYPE B TUMOR, INTERMEDIATE TYPE I TUMOR AND COMMON PULMONARY TUMOR OF THE MOUSE.

AUTOLYSIS PARTIAL :
NO OTHER CHANGES ARE SEEN. TISSUES ARE ALTERED. BY POST-MORTEM MODIFICATIONS AND DIAGNOSIS IS GIVEN WITH RESERVATION.

STOMACH

AUTOLYSIS PARTIAL :
NO OTHER CHANGES ARE SEEN. TISSUES ARE ALTERED. BY POST-MORTEM MODIFICATIONS AND DIAGNOSIS IS GIVEN WITH RESERVATION.

LIVER

AUTOLYSIS PARTIAL :
NO OTHER CHANGES ARE SEEN. TISSUES ARE ALTERED. BY POST-MORTEM MODIFICATIONS AND DIAGNOSIS IS GIVEN WITH RESERVATION.

PANCREAS

UNREADABLE :
IT IS NOT POSSIBLE TO INTERPRET THE SECTION DUE TO AN ARTIFACT CAUSED BY SAMPLING OR HISTOLOGICAL TECHNIQUE.

SPLEEN

AUTOLYSIS PARTIAL :
NO OTHER CHANGES ARE SEEN. TISSUES ARE ALTERED. BY POST-MORTEM MODIFICATIONS AND DIAGNOSIS IS GIVEN WITH RESERVATION.

BAYER AG

KIDNEYS

INTERSTITIAL NEPHRITIS :
BILATERAL MINIMAL MULTIFOCAL
INFLAMMATORY CELLS FIBROSIS AND SOME TUBULAR ALTERATIONS ARE ASSOCIATED.

BLADDER

AUTOLYSIS PARTIAL :
NO OTHER CHANGES ARE SEEN. TISSUES ARE ALTERED. BY POST-MORTEM MODIFICATIONS AND DIAGNOSIS IS GIVEN WITH RESERVATION.

PITUITARY

ABSENT :
ORGAN OR TISSUE NOT REMOVED FROM ANIMAL OR NOT FOUND IN FIXATIVE.

THYROIDS

ABSENT :
ORGAN OR TISSUE NOT REMOVED FROM ANIMAL OR NOT FOUND IN FIXATIVE.

MALE 41 (1029/80)

LUNG

PNEUMONIA :
SEVERE
THE ALVEOLAR WALLS ARE THICKENED AND ALVEOLI CONTAIN INFLAMMATORY CELLS AND FOAMY MACROPHAGES.PERIVASCULAR AND PERIBRONCHIAL LYMPHOCYTIC ACCUMULATIONS MAY BE PRESENT.

LIVER

CONGESTION :
SEVERE
VESSELS OR SINUSOIDS ARE MARKEDLY DISTENDED WITH ERYTHROCYTES.

KIDNEYS

INTERSTITIAL NEPHRITIS :
BILATERAL MINIMAL MULTIFOCAL
INFLAMMATORY CELLS FIBROSIS AND SOME TUBULAR ALTERATIONS ARE ASSOCIATED.

BLADDER

AUTOLYSIS PARTIAL :
NO OTHER CHANGES ARE SEEN. TISSUES ARE ALTERED. BY POST-MORTEM MODIFICATIONS AND

NMC.38 MALE 41 CONTINUED

BLADDER CONTINUED
DIAGNOSIS IS GIVEN WITH RESERVATION.

PITUITARY

ABSENT :
ORGAN OR TISSUE NOT REMOVED FROM ANIMAL OR NOT FOUND IN FIXATIVE.

MALE 42 (1636/80)

LUNG

*** ALVEOLOGENIC CARCINOMA :
MULTIFOCAL
A MALIGNANT TUMOR OF THE LUNG TISSUE WITH SYNONYMS IN MICE FOR ADENOMA, CARCINOMA, ALVEOLOGENIC PAPILLARY CARCINOMA, PAPILLARY CYSTADENOMA, ADENOCARCINOMA, BRONCHIOLAR CELL CARCINOMA, BRONCHIOLAR-ALVEOLAR TUMOR, TYPE A TUMOR, TYPE B TUMOR, INTERMEDIATE TYPE I TUMOR AND COMMON PULMONARY TUMOR OF THE MOUSE.

LIVER

LEUKEMIC DEPOSITS :
ORGAN AND THE BLOOD ARE INVADED BY LEUKEMIC CELLS.

PANCREAS

*** ISLET CELL ADENOMA :
THIS IS A BENIGN GLANDULAR TUMOR ARISING FROM THE ISLET CELLS.

SPLEEN

*** LYMPHOMA STEM CELLS :
THE NEOPLASM OF THE RETICULAR SYSTEM ORIGINATES FROM STEM CELLS.

KIDNEYS

LEUKEMIC DEPOSITS :
ORGAN AND THE BLOOD ARE INVADED BY LEUKEMIC CELLS.

BLADDER

LEUKEMIC DEPOSITS :
ORGAN AND THE BLOOD ARE INVADED BY LEUKEMIC CELLS.

BAYER AG

THYROIDS

ABSENT :
ORGAN OR TISSUE NOT REMOVED FROM ANIMAL OR NOT FOUND IN FIXATIVE.

SCIATIC NERVE

ABSENT :
ORGAN OR TISSUE NOT REMOVED FROM ANIMAL OR NOT FOUND IN FIXATIVE.

TESTES

CALCIFICATION :
UNILATERAL MINIMAL MULTIFOCAL
THERE ARE MINERAL DEPOSITS.

MALE 43 (1639/80)

BRAIN

MENINGITIS :
MINIMAL
CHRONIC INFLAMMATION OF THE MENINGES.

HEART

LEUKEMIC DEPOSITS :
ORGAN AND THE BLOOD ARE INVADED BY LEUKEMIC CELLS.

LUNG

LEUKEMIC DEPOSITS :
ORGAN AND THE BLOOD ARE INVADED BY LEUKEMIC CELLS.

STOMACH

LEUKEMIC DEPOSITS :
ORGAN AND THE BLOOD ARE INVADED BY LEUKEMIC CELLS.

LIVER

LEUKEMIC DEPOSITS :
ORGAN AND THE BLOOD ARE INVADED BY LEUKEMIC CELLS.

PANCREAS

LEUKEMIC DEPOSITS :
ORGAN AND THE BLOOD ARE INVADED BY LEUKEMIC CELLS.

SPLEEN

*** LYMPHOMA LYMPHOCYTIC :
THE NEOPLASM OF THE RETICULAR SYSTEM ORIGINATES FROM LYMPHOCYTES.

KIDNEYS

LEUKEMIC DEPOSITS :
ORGAN AND THE BLOOD ARE INVADED BY LEUKEMIC CELLS.

BLADDER

LEUKEMIC DEPOSITS :
ORGAN AND THE BLOOD ARE INVADED BY LEUKEMIC CELLS.

PITUITARY

NORMAL :
HISTOLOGICAL ASPECT WITHIN NORMAL LIMITS.

THYROIDS

LEUKEMIC DEPOSITS :
ORGAN AND THE BLOOD ARE INVADED BY LEUKEMIC CELLS.

ADRENALS

LEUKEMIC DEPOSITS :
ORGAN AND THE BLOOD ARE INVADED BY LEUKEMIC CELLS.

SKELETAL MUSCLE

LEUKEMIC DEPOSITS :
ORGAN AND THE BLOOD ARE INVADED BY LEUKEMIC CELLS.

SCIATIC NERVE

LEUKEMIC DEPOSITS :
ORGAN AND THE BLOOD ARE INVADED BY LEUKEMIC CELLS.

TESTES

LEUKEMIC DEPOSITS :
ORGAN AND THE BLOOD ARE INVADED BY LEUKEMIC CELLS.

BAYER AG BAYER AG BAYER AG BAYER AG

MALE 44 (1630/80)

NMC.41 MALE 44 CONTINUED

BRAIN

AUTOLYSIS PARTIAL :
NO OTHER CHANGES ARE SEEN. TISSUES ARE ALTERED.
BY POST-MORTEM MODIFICATIONS AND
DIAGNOSIS IS GIVEN WITH RESERVATION.

LUNG

PNEUMONIA :
MODERATE
THE ALVEOLAR WALLS ARE THICKENED AND ALVEOLI CONTAIN
INFLAMMATORY CELLS AND FOAMY MACROPHAGES.PERIVASCULAR AND
PERIBRONCHIAL LYMPHOCYTIC ACCUMULATIONS MAY BE PRESENT.

STOMACH

AUTOLYSIS :
THE TISSUES EXHIBIT AUTOLYSIS AND THEY ARE NOT
INTERPRETABLE.

LIVER

AUTOLYSIS PARTIAL :
NO OTHER CHANGES ARE SEEN. TISSUES ARE ALTERED.
BY POST-MORTEM MODIFICATIONS AND
DIAGNOSIS IS GIVEN WITH RESERVATION.

HEPATOCYTIC HYPERPIGMENTATION :
MINIMAL
HEPATOCYTES ARE LADEN WITH GRANULES OF HEMOSIDERIN OR BILE
OR OTHER PIGMENT.

*** CYSTADENOMA :
CYSTIC AND ADENOMATOUS CHANGE WITH CYSTIC HYPERPLASIA.

PANCREAS

AUTOLYSIS :
THE TISSUES EXHIBIT AUTOLYSIS AND THEY ARE NOT
INTERPRETABLE.

SPLEEN

AUTOLYSIS :
THE TISSUES EXHIBIT AUTOLYSIS AND THEY ARE NOT
INTERPRETABLE.

KIDNEYS

PYELONEPHRITIS :
BILATERAL MINIMAL FOCAL
INFLAMMATION OF RENAL PARENCHYMA WITH OR WITHOUT
NECROSIS EXTENDED TO RENAL PELVIS.

BLADDER

AUTOLYSIS :
THE TISSUES EXHIBIT AUTOLYSIS AND THEY ARE NOT
INTERPRETABLE.

NMC.42 MALE 44 CONTINUED

PITUITARY

ABSENT :
ORGAN OR TISSUE NOT REMOVED FROM ANIMAL OR NOT FOUND IN FIXATIVE.

THYROIDS

ABSENT :
ORGAN OR TISSUE NOT REMOVED FROM ANIMAL OR NOT FOUND IN FIXATIVE.

ADRENALS

AUTOLYSIS PARTIAL :
NO OTHER CHANGES ARE SEEN. TISSUES ARE ALTERED. BY POST-MORTEM MODIFICATIONS AND DIAGNOSIS IS GIVEN WITH RESERVATION.

SKELETAL MUSCLE

AUTOLYSIS PARTIAL :
NO OTHER CHANGES ARE SEEN. TISSUES ARE ALTERED. BY POST-MORTEM MODIFICATIONS AND DIAGNOSIS IS GIVEN WITH RESERVATION.

SCIATIC NERVE

AUTOLYSIS PARTIAL :
NO OTHER CHANGES ARE SEEN. TISSUES ARE ALTERED. BY POST-MORTEM MODIFICATIONS AND DIAGNOSIS IS GIVEN WITH RESERVATION.

TESTES

AUTOLYSIS PARTIAL :
NO OTHER CHANGES ARE SEEN. TISSUES ARE ALTERED. BY POST-MORTEM MODIFICATIONS AND DIAGNOSIS IS GIVEN WITH RESERVATION.

MALE 45 (1605/80)

HEART

CONGESTION :
VESSELS OR SINUSOIDS ARE MARKEDLY DISTENDED WITH ERYTHROCYTES.

DILATED CHAMBER :
ONE OR MORE OF THE CHAMBERS OF THE HEART ARE DILATED.

SPLEEN

HEMATOPOIESIS :
SEVERE

NMC•43 MALE 45 CONTINUED

SPLEEN CONTINUED
THE HEMATOPOIESIS IS EVIDENT.

KIDNEYS

TUBULOPATHY :
BILATERAL MINIMAL MULTIFOCAL
TUBULAR DEGENERATIVE CHANGES ARE PRESENT
WHICH MAY BE ASSOCIATED WITH TUBULAR DILATATION.

INTERSTITIAL NEPHRITIS :
BILATERAL MINIMAL MULTIFOCAL
INFLAMMATORY CELLS FIBROSIS AND SOME TUBULAR ALTERATIONS
ARE ASSOCIATED.

BLADDER

AUTOLYSIS PARTIAL :
NO OTHER CHANGES ARE SEEN. TISSUES ARE ALTERED.
BY POST-MORTEM MODIFICATIONS AND
DIAGNOSIS IS GIVEN WITH RESERVATION.

MALE 46 (1626/80)

BRAIN

AUTOLYSIS PARTIAL :
NO OTHER CHANGES ARE SEEN. TISSUES ARE ALTERED.
BY POST-MORTEM MODIFICATIONS AND
DIAGNOSIS IS GIVEN WITH RESERVATION.

LUNG

PNEUMONIA :
MODERATE
THE ALVEOLAR WALLS ARE THICKENED AND ALVEOLI CONTAIN
INFLAMMATORY CELLS AND FOAMY MACROPHAGES.PERIVASCULAR AND
PERIBRONCHIAL LYMPHOCYTIC ACCUMULATIONS MAY BE PRESENT.

AUTOLYSIS PARTIAL :
NO OTHER CHANGES ARE SEEN. TISSUES ARE ALTERED.
BY POST-MORTEM MODIFICATIONS AND
DIAGNOSIS IS GIVEN WITH RESERVATION.

STOMACH

AUTOLYSIS :
THE TISSUES EXHIBIT AUTOLYSIS AND THEY ARE NOT
INTERPRETABLE.

LIVER

NORMAL :
HISTOLOGICAL ASPECT WITHIN NORMAL LIMITS.

KIDNEYS

AUTOLYSIS PARTIAL :
NO OTHER CHANGES ARE SEEN. TISSUES ARE ALTERED.
BY POST-MORTEM MODIFICATIONS AND
DIAGNOSIS IS GIVEN WITH RESERVATION.

BLADDER

AUTOLYSIS :
THE TISSUES EXHIBIT AUTOLYSIS AND THEY ARE NOT
INTERPRETABLE.

PITUITARY

ABSENT :
ORGAN OR TISSUE NOT REMOVED FROM ANIMAL OR NOT FOUND IN
FIXATIVE.

THYROIDS

ABSENT :
ORGAN OR TISSUE NOT REMOVED FROM ANIMAL OR NOT FOUND IN
FIXATIVE.

MALE 47 (1639/80)

HEART

CONGESTION :
VESSELS OR SINUSOIDS ARE MARKEDLY DISTENDED WITH
ERYTHROCYTES.

LUNG

EMPHYSEMA :
MODERATE
THERE IS A EMPHYSEMATOUS CHANGE IN THE ALVEOLAR WALLS.

STOMACH

AUTOLYSIS :
THE TISSUES EXHIBIT AUTOLYSIS AND THEY ARE NOT
INTERPRETABLE.

LIVER

AMYLOID :
MULTIFOCAL
HOMOGENEOUS ACIDOPHILIC MATERIAL IS DEPOSITED.

LEUKEMIC DEPOSITS :
ORGAN AND THE BLOOD ARE INVADED BY LEUKEMIC
CELLS.

HYPERPLASIA FOCAL :

BAYER AG

NMC•45 MALE 47 CONTINUED

LIVER CONTINUED

WELL DEFINED ROUND FOCUS OF HYPERPLASTIC CELLS IS OBSERVED WITHIN THIS OTHERWISE NORMAL TISSUE.

SPLEEN

*** LYMPHOMA STEM CELLS :
THE NEOPLASM OF THE RETICULAR SYSTEM ORIGINATES FROM STEM CELLS.

KIDNEYS

TUBULOPATHY :
BILATERAL MODERATE
TUBULAR DEGENERATIVE CHANGES ARE PRESENT WHICH MAY BE ASSOCIATED WITH TUBULAR DILATATION.

LEUKEMIC DEPOSITS :
BILATERAL MINIMAL MULTIFOCAL
ORGAN AND THE BLOOD ARE INVADED BY LEUKEMIC CELLS.

BLADDER

HYPERPLASIA PAPILLOMATOUS :
THE THICKNESS OF THE MUCOSA IS INCREASED MAKING UNUSUALLY HIGH AND NUMEROUS FOLDS.

MESENTERY

LEUKEMIC DEPOSITS :
ORGAN AND THE BLOOD ARE INVADED BY LEUKEMIC CELLS.

TESTES

CALCIFICATION :
BILATERAL MINIMAL MULTIFOCAL
THERE ARE MINERAL DEPOSITS.

FEMUR

ABSENT :
ORGAN OR TISSUE NOT REMOVED FROM ANIMAL OR NOT FOUND IN FIXATIVE.

LYMPH NODE

*** LYMPHOMA STEM CELLS :
THE NEOPLASM OF THE RETICULAR SYSTEM ORIGINATES FROM STEM CELLS.

MALE 48 (1627/60)

TRACHEA

LEUKEMIC DEPOSITS :
ORGAN AND THE BLOOD ARE INVADED BY LEUKEMIC CELLS.

LUNG

*** ALVEOLOGENIC CARCINOMA :
MULTIFOCAL
A MALIGNANT TUMOR OF THE LUNG TISSUE WITH SYNONYMS IN MICE FOR ADENOMA, CARCINOMA, ALVEOLOGENIC PAPILLARY CARCINOMA, PAPILLARY CYSTADENOMA, ADENOCARCINOMA, BRONCHIOLAR CELL CARCINOMA, BRONCHIOLAR-ALVEOLAR TUMOR, TYPE A TUMOR, TYPE B TUMOR, INTERMEDIATE TYPE I TUMOR AND COMMON PULMONARY TUMOR OF THE MOUSE.

LEUKEMIC DEPOSITS :
ORGAN AND THE BLOOD ARE INVADED BY LEUKEMIC CELLS.

STOMACH

LEUKEMIC DEPOSITS :
ORGAN AND THE BLOOD ARE INVADED BY LEUKEMIC CELLS.

LIVER

LEUKEMIC DEPOSITS :
ORGAN AND THE BLOOD ARE INVADED BY LEUKEMIC CELLS.

PANCREAS

LEUKEMIC DEPOSITS :
ORGAN AND THE BLOOD ARE INVADED BY LEUKEMIC CELLS.

SPLEEN

*** LYMPHOMA LYMPHOCYTIC :
THE NEOPLASM OF THE RETICULAR SYSTEM ORIGINATES FROM LYMPHOCYTES.

KIDNEYS

LEUKEMIC DEPOSITS :
BILATERAL
ORGAN AND THE BLOOD ARE INVADED BY LEUKEMIC CELLS.

BLADDER

LEUKEMIC DEPOSITS :
ORGAN AND THE BLOOD ARE INVADED BY LEUKEMIC CELLS.

BAYER AG

ADRENALS

LEUKEMIC DEPOSITS :
BILATERAL
ORGAN AND THE BLOOD ARE INVADED BY LEUKEMIC CELLS.

SCIATIC NERVE

ABSENT :
ORGAN OR TISSUE NOT REMOVED FROM ANIMAL OR NOT FOUND IN FIXATIVE.

LYMPH NODE

*** LYMPHOMA LYMPHOCYTIC :
THE NEOPLASM OF THE RETICULAR SYSTEM ORIGINATES FROM LYMPHOCYTES.

MALE 49 (1609/80)

BRAIN

ABSENT :
ORGAN OR TISSUE NOT REMOVED FROM ANIMAL OR NOT FOUND IN FIXATIVE.

HEART

CONGESTION :
VESSELS OR SINUSOIDS ARE MARKEDLY DISTENDED WITH ERYTHROCYTES.

AUTOLYSIS PARTIAL :
NO OTHER CHANGES ARE SEEN. TISSUES ARE ALTERED. BY POST-MORTEM MODIFICATIONS AND DIAGNOSIS IS GIVEN WITH RESERVATION.

LUNG

*** ALVEOLOGENIC CARCINOMA :
A MALIGNANT TUMOR OF THE LUNG TISSUE WITH SYNONYMS IN MICE FOR ADENOMA, CARCINOMA, ALVEOLOGENIC PAPILLARY CARCINOMA, PAPILLARY CYSTADENOMA, ADENOCARCINOMA, BRONCHIOLAR CELL CARCINOMA, BRONCHIOLAR-ALVEOLAR TUMOR, TYPE A TUMOR, TYPE B TUMOR, INTERMEDIATE TYPE I TUMOR AND COMMON PULMONARY TUMOR OF THE MOUSE.

AUTOLYSIS PARTIAL :
NO OTHER CHANGES ARE SEEN. TISSUES ARE ALTERED. BY POST-MORTEM MODIFICATIONS AND DIAGNOSIS IS GIVEN WITH RESERVATION.

STOMACH

AUTOLYSIS :
THE TISSUES EXHIBIT AUTOLYSIS AND THEY ARE NOT INTERPRETABLE.

LIVER

*** ADENOMA HEPATIC BENIGN :
DISTINCT NODULES COMPRESS THE ADJACENT LIVER PARENCHYMA, ARE CHARACTERIZED BY WELL DIFFERENTIATED HEPATOCYTES AND DO NOT SHOW PORTAL TRIADS.

LEUKEMIC DEPOSITS :
ORGAN AND THE BLOOD ARE INVADED BY LEUKEMIC CELLS.

PANCREAS

AUTOLYSIS :
THE TISSUES EXHIBIT AUTOLYSIS AND THEY ARE NOT INTERPRETABLE.

SPLEEN

*** LYMPHOMA STEM CELLS :
THE NEOPLASM OF THE RETICULAR SYSTEM ORIGINATES FROM STEM CELLS.

AUTOLYSIS PARTIAL :
NO OTHER CHANGES ARE SEEN. TISSUES ARE ALTERED. BY POST-MORTEM MODIFICATIONS AND DIAGNOSIS IS GIVEN WITH RESERVATION.

KIDNEYS

LEUKEMIC DEPOSITS :
BILATERAL
ORGAN AND THE BLOOD ARE INVADED BY LEUKEMIC CELLS.

BLADDER

AUTOLYSIS :
THE TISSUES EXHIBIT AUTOLYSIS AND THEY ARE NOT INTERPRETABLE.

PITUITARY

AUTOLYSIS PARTIAL :
NO OTHER CHANGES ARE SEEN. TISSUES ARE ALTERED. BY POST-MORTEM MODIFICATIONS AND DIAGNOSIS IS GIVEN WITH RESERVATION.

THYROIDS

ABSENT :
ORGAN OR TISSUE NOT REMOVED FROM ANIMAL OR NOT FOUND IN FIXATIVE.

BAYER AG

NMC.49 MALE 49 CONTINUED

LYMPH NODE

*** LYMPHOMA STEM CELLS :
THE NEOPLASM OF THE RETICULAR SYSTEM ORIGINATES FROM STEM CELLS.

AUTOLYSIS PARTIAL :
NO OTHER CHANGES ARE SEEN. TISSUES ARE ALTERED.
BY POST-MORTEM MODIFICATIONS AND
DIAGNOSIS IS GIVEN WITH RESERVATION.

MALE 50 (1631/80)

BRAIN

AUTOLYSIS PARTIAL :
NO OTHER CHANGES ARE SEEN. TISSUES ARE ALTERED.
BY POST-MORTEM MODIFICATIONS AND
DIAGNOSIS IS GIVEN WITH RESERVATION.

HEART

THROMBOSIS :
THE VASCULAR LUMEN CONTAINS AN ATTACHED ANTE MORTEM BLOOD CLOT.

AUTOLYSIS PARTIAL :
NO OTHER CHANGES ARE SEEN. TISSUES ARE ALTERED.
BY POST-MORTEM MODIFICATIONS AND
DIAGNOSIS IS GIVEN WITH RESERVATION.

LUNG

AUTOLYSIS PARTIAL :
NO OTHER CHANGES ARE SEEN. TISSUES ARE ALTERED.
BY POST-MORTEM MODIFICATIONS AND
DIAGNOSIS IS GIVEN WITH RESERVATION.

STOMACH

AUTOLYSIS :
THE TISSUES EXHIBIT AUTOLYSIS AND THEY ARE NOT INTERPRETABLE.

LIVER

AUTOLYSIS :
THE TISSUES EXHIBIT AUTOLYSIS AND THEY ARE NOT INTERPRETABLE.

PANCREAS

AUTOLYSIS :
THE TISSUES EXHIBIT AUTOLYSIS AND THEY ARE NOT INTERPRETABLE.

SPLEEN

*** LYMPHOMA LYMPHOCYTIC :
THE NEOPLASM OF THE RETICULAR SYSTEM ORIGINATES FROM LYMPHOCYTES.

AUTOLYSIS PARTIAL :
NO OTHER CHANGES ARE SEEN. TISSUES ARE ALTERED.
BY POST-MORTEM MODIFICATIONS AND
DIAGNOSIS IS GIVEN WITH RESERVATION.

KIDNEYS

CYSTS :
BILATERAL MODERATE MULTIFOCAL
ONE OR MORE CYSTS FILLED WITH CLEAR LIQUID ARE SEEN.

AUTOLYSIS PARTIAL :
NO OTHER CHANGES ARE SEEN. TISSUES ARE ALTERED.
BY POST-MORTEM MODIFICATIONS AND
DIAGNOSIS IS GIVEN WITH RESERVATION.

BLADDER

AUTOLYSIS :
THE TISSUES EXHIBIT AUTOLYSIS AND THEY ARE NOT INTERPRETABLE.

PITUITARY

AUTOLYSIS PARTIAL :
NO OTHER CHANGES ARE SEEN. TISSUES ARE ALTERED.
BY POST-MORTEM MODIFICATIONS AND
DIAGNOSIS IS GIVEN WITH RESERVATION.

THYROIDS

ABSENT :
ORGAN OR TISSUE NOT REMOVED FROM ANIMAL OR NOT FOUND IN FIXATIVE.

ADRENALS

AUTOLYSIS PARTIAL :
NO OTHER CHANGES ARE SEEN. TISSUES ARE ALTERED.
BY POST-MORTEM MODIFICATIONS AND
DIAGNOSIS IS GIVEN WITH RESERVATION.

BAYER AG

SM1. 1 CHRONIC TOXICITY STUDY IN MICE: SYSTEMATIC

HISTOPATHOLOGY

PRODUCT : CWG 0519 GROUP : 1
ROUTE : DIETARY
TIME : 105 WEEKS DOSE : 125 PPM
THIS GROUP COMPRISED : 11 MALES

THE FOLLOWING ORGANS WERE EXAMINED SYSTEMATICALLY :

HEART	LUNG	LIVER
PANCREAS	SPLEEN	KIDNEYS
BLADDER	STOMACH	TESTES
THYROIDS	ADRENALS	PITUITARY
BRAIN	SKELETAL MUSCLE	SCIATIC NERVE
FEMUR		

THESE ORGANS WERE EXAMINED IN 11 MALES

INDIVIDUAL RESULTS

IN THE ANIMALS SHOWN BELOW THE HISTOLOGICAL EXAMINATION OF THE ORGANS LISTED OR OF THE ANOMALIES FOUND AT AUTOPSY GAVE THE FOLLOWING RESULTS :

MALE 107 (1495/80)

HEART

PERIARTERITIS :
MODERATE FOCAL
NON SPECIFIC INFLAMMATION (ACUTE SUBACUTE OR CHRONIC) OF THE TUNICA ADVENTITIA (PERIVASCULAR GRANULOMA).

LUNG

*** ALVEOLOGENIC CARCINOMA :
MULTIFOCAL
A MALIGNANT TUMOR OF THE LUNG TISSUE WITH SYNONYMS IN MICE FOR ADENOMA, CARCINOMA, ALVEOLOGENIC PAPILLARY CARCINOMA, PAPILLARY CYSTADENOMA, ADENOCARCINOMA, BRONCHIOLAR CELL CARCINOMA, BRONCHIOLAR-ALVEOLAR TUMOR, TYPE A TUMOR, TYPE B TUMOR, INTERMEDIATE TYPE I TUMOR AND COMMON PULMONARY TUMOR OF THE MOUSE.

PANCREAS

NORMAL :
HISTOLOGICAL ASPECT WITHIN NORMAL LIMITS.

SPLEEN

HYPERPLASIA LYMPHOID :
MODERATE

SM1. 2 MALE 107 CONTINUED

SPLEEN CONTINUED
THE LYMPHOID FOLLICLES ARE INCREASED IN SIZE.

HEMATOPOIESIS :
SEVERE
THE HEMATOPOIESIS IS EVIDENT.

KIDNEYS

TUBULOPATHY :
BILATERAL MINIMAL FOCAL
TUBULAR DEGENERATIVE CHANGES ARE PRESENT
WHICH MAY BE ASSOCIATED WITH TUBULAR DILATATION.

CYSTS :
BILATERAL MODERATE MULTIFOCAL
ONE OR MORE CYSTS FILLED WITH CLEAR LIQUID ARE SEEN.

THYROIDS

ABSENT :
ORGAN OR TISSUE NOT REMOVED FROM ANIMAL OR NOT FOUND IN FIXATIVE.

MALE 110 (1496/80)

LIVER

HYPERPLASTIC NODULE :
A NODULE OF HYPERPLASTIC TISSUE IS PRESENT.

SPLEEN

HEMATOPOIESIS :
SEVERE
THE HEMATOPOIESIS IS EVIDENT.

KIDNEYS

FIBROSIS :
BILATERAL MINIMAL FOCAL
THERE IS AN INCREASE IN INTERSTITIAL FIBROUS TISSUE.

CYSTS :
BILATERAL SEVERE MULTIFOCAL
ONE OR MORE CYSTS FILLED WITH CLEAR LIQUID ARE SEEN.

DILATATION OF RENAL PELVIS :
UNILATERAL MODERATE
THE RENAL CAVITIES ARE MORE OR LESS ENLARGED.

THYROIDS

ABSENT :
ORGAN OR TISSUE NOT REMOVED FROM ANIMAL OR NOT FOUND IN

BAYER AG BAYER AG BAYER AG

SM1. 3 MALE 110 CONTINUED

THYROIDS CONTINUED
FIXATIVE.

TESTES

ATROPHY SEMINIFEROUS :
BILATERAL MINIMAL MULTIFOCAL
THERE IS ATROPHY OF SEMINIFEROUS TUBULES WITH DIMINISHED SPERMATOGENIC ACTIVITY.

INFLAMMATION CHRONIC :
BILATERAL MINIMAL
THERE IS AN INFILTRATION BY MONONUCLEAR CELLS IN THE MUCOSA AND SUBMUCOSA.

MALE 117 (1497/80)

LUNG

HEMORRHAGE :
MINIMAL FOCAL
THERE IS EXTRAVASATION OF BLOOD.

ATELECTASIS :
MODERATE MULTIFOCAL
THERE IS COLLAPSE OF ALVEOLI.

SPLEEN

HEMORRHAGE :
MODERATE MULTIFOCAL
THERE IS EXTRAVASATION OF BLOOD.

HEMATOPOIESIS :
SEVERE
THE HEMATOPOIESIS IS EVIDENT.

KIDNEYS

INTERSTITIAL NEPHRITIS :
BILATERAL MINIMAL MULTIFOCAL
INFLAMMATORY CELLS FIBROSIS AND SOME TUBULAR ALTERATIONS ARE ASSOCIATED.

CYSTS :
UNILATERAL FOCAL
ONE OR MORE CYSTS FILLED WITH CLEAR LIQUID ARE SEEN.

PITUITARY

ABSENT :
ORGAN OR TISSUE NOT REMOVED FROM ANIMAL OR NOT FOUND IN FIXATIVE.

ADRENALS

PIGMENTATION :
UNILATERAL MODERATE
NUMEROUS MACROPHAGES CONTAIN A GRANULAR BROWN CYTOPLASMIC PIGMENT.

*** ADENOMA :
UNILATERAL
THIS IS BENIGN GLANDULAR EPITHELIAL TUMOR.

MALE 119 (1498/80)

BRAIN

GLIOSIS :
FOCAL
THERE IS PROLIFERATION OF GLIAL CELLS.

LUNG

PNEUMONIA :
THE ALVEOLAR WALLS ARE THICKENED AND ALVEOLI CONTAIN INFLAMMATORY CELLS AND FOAMY MACROPHAGES.PERIVASCULAR AND PERIBRONCHIAL LYMPHOCYTIC ACCUMULATIONS MAY BE PRESENT.

*** ALVEOLOGENIC CARCINOMA :
A MALIGNANT TUMOR OF THE LUNG TISSUE WITH SYNONYMS IN MICE FOR ADENOMA, CARCINOMA, ALVEOLOGENIC PAPILLARY CARCINOMA, PAPILLARY CYSTADENOMA, ADENOCARCINOMA, BRONCHIOLAR CEL. CARCINOMA, BRONCHIOLAR-ALVEOLAR TUMOR, TYPE A TUMOR, TYPE B TUMOR, INTERMEDIATE TYPE I TUMOR AND COMMON PULMONARY TUMOR OF THE MOUSE.

STOMACH

MUCOID CYST :
SEVERE
ONE OR MORE CYSTS CONTAINING MUCOID MATERIAL ARE OBSERVED.

LIVER

HEMATOPOIESIS :
SEVERE
THE HEMATOPOIESIS IS EVIDENT.

SPLEEN

HEMATOPOIESIS :
SEVERE
THE HEMATOPOIESIS IS EVIDENT.

BAYER AG

KIDNEYS

CYSTS :
BILATERAL MINIMAL MULTIFOCAL
ONE OR MORE CYSTS FILLED WITH CLEAR LIQUID ARE SEEN.

BLADDER

NORMAL :
HISTOLOGICAL ASPECT WITHIN NORMAL LIMITS.

PITUITARY

ABSENT :
ORGAN OR TISSUE NOT REMOVED FROM ANIMAL OR NOT FOUND IN FIXATIVE.

ADRENALS

PIGMENTATION :
BILATERAL MODERATE
NUMEROUS MACROPHAGES CONTAIN A GRANULAR BROWN CYTOPLASMIC PIGMENT.

MALE 123 (1499/80)

BRAIN

GLIOSIS :
FOCAL
THERE IS PROLIFERATION OF GLIAL CELLS.

LUNG

*** ALVEOLOGENIC CARCINOMA :
A MALIGNANT TUMOR OF THE LUNG TISSUE WITH SYNONYMS IN MICE FOR ADENOMA, CARCINOMA, ALVEOLOGENIC PAPILLARY CARCINOMA, PAPILLARY CYSTADENOMA, ADENOCARCINOMA, BRONCHIOLAR CELL CARCINOMA, BRONCHIOLAR-ALVEOLAR TUMOR, TYPE A TUMOR, TYPE B TUMOR, INTERMEDIATE TYPE I TUMOR AND COMMON PULMONARY TUMOR OF THE MOUSE.

LIVER

FAT VACUOLES :
SEVERE
THE CELLS ARE DISTENDED BY CLEAR CYTOPLASMIC VACUOLES WHICH FREQUENTLY DISPLACE THE NUCLEI.

HYPERPLASTIC NODULE :
A NODULE OF HYPERPLASTIC TISSUE IS PRESENT.

PERICHOLANGITIS :
MODERATE MULTIFOCAL

SM1. 6 MALE 123 CONTINUED

LIVER CONTINUED

INFLAMMATORY REACTION IS NOTED AROUND BILE DUCTS.

SPLEEN

HEMATOPOIESIS :
MINIMAL
THE HEMATOPOIESIS IS EVIDENT.

KIDNEYS

TUBULOPATHY :
UNILATERAL MINIMAL
TUBULAR DEGENERATIVE CHANGES ARE PRESENT WHICH MAY BE ASSOCIATED WITH TUBULAR DILATATION.

DILATATION OF GLOMERULAR LOOPS :
CONTRALATERAL MINIMAL FOCAL
GLOMERULAR LOOPS APPEAR UNUSUALLY ENLARGED AND THIN.

PITUITARY

ABSENT :
ORGAN OR TISSUE NOT REMOVED FROM ANIMAL OR NOT FOUND IN FIXATIVE.

THYROIDS

ABSENT :
ORGAN OR TISSUE NOT REMOVED FROM ANIMAL OR NOT FOUND IN FIXATIVE.

ADRENALS

PIGMENTATION :
UNILATERAL MINIMAL
NUMEROUS MACROPHAGES CONTAIN A GRANULAR BROWN CYTOPLASMIC PIGMENT.

SKELETAL MUSCLE

VACUOLIZATION :
MINIMAL FOCAL
IN THESE CELLS THERE ARE CLEAR VACUOLES GREATER IN NUMBER AND SIZE THAN NORMALLY FOUND.

TESTES

ATROPHY SEMINIFEROUS :
UNILATERAL SEVERE
THERE IS ATROPHY OF SEMINIFEROUS TUBULES WITH DIMINISHED SPERMATOGENIC ACTIVITY.

BAYER AG

MALE 127 (1500/60)

LUNG

PNEUMONIA :
MINIMAL
THE ALVEOLAR WALLS ARE THICKENED AND ALVEOLI CONTAIN INFLAMMATORY CELLS AND FOAMY MACROPHAGES.PERIVASCULAR AND PERIBRONCHIAL LYMPHOCYTIC ACCUMULATIONS MAY BE PRESENT.

LIVER

VACUOLIZATION :
MINIMAL MULTIFOCAL
IN THESE CELLS THERE ARE CLEAR VACUOLES GREATER IN NUMBER AND SIZE THAN NORMALLY FOUND.

SPLEEN

HEMATOPOIESIS :
MINIMAL
THE HEMATOPOIESIS IS EVIDENT.

KIDNEYS

TUBULOPATHY :
UNILATERAL MINIMAL MULTIFOCAL
TUBULAR DEGENERATIVE CHANGES ARE PRESENT WHICH MAY BE ASSOCIATED WITH TUBULAR DILATATION.

INTERSTITIAL NEPHRITIS :
BILATERAL MINIMAL MULTIFOCAL
INFLAMMATORY CELLS FIBROSIS AND SOME TUBULAR ALTERATIONS ARE ASSOCIATED.

PITUITARY

ABSENT :
ORGAN OR TISSUE NOT REMOVED FROM ANIMAL OR NOT FOUND IN FIXATIVE.

THYROIDS

ABSENT :
ORGAN OR TISSUE NOT REMOVED FROM ANIMAL OR NOT FOUND IN FIXATIVE.

ADRENALS

*** PHEOCHROMOCYTOMA :
UNILATERAL
THIS TUMOR IS COMPOSED OF POLYHEDRAL CELLS WHICH ARISE FROM THE CHROMAFFIN CELLS OF THE ADRENAL MEDULLA AND FORM LOBULES SEPARATED BY VASCULAR CONNECTIVE TISSUE SEPTA.

MALE 128 (1501/80)

LUNG

*** ALVEOLOGENIC CARCINOMA :
A MALIGNANT TUMOR OF THE LUNG TISSUE WITH SYNONYMS IN MICE FOR ADENOMA, CARCINOMA, ALVEOLOGENIC PAPILLARY CARCINOMA, PAPILLARY CYSTADENOMA, ADENOCARCINOMA, BRONCHIOLAR CEL. CARCINOMA, BRONCHIOLAR-ALVEOLAR TUMOR, TYPE A TUMOR, TYPE B TUMOR, INTERMEDIATE TYPE I TUMOR AND COMMON PULMONARY TUMOR OF THE MOUSE.

STOMACH

MUCOID CYST :
MINIMAL FOCAL
ONE OR MORE CYSTS CONTAINING MUCOID MATERIAL ARE OBSERVED.

SPLEEN

FIBROSIS :
MODERATE
THERE IS AN INCREASE IN INTERSTITIAL FIBROUS TISSUE.

KIDNEYS

INTERSTITIAL NEPHRITIS :
BILATERAL MODERATE MULTIFOCAL
INFLAMMATORY CELLS FIBROSIS AND SOME TUBULAR ALTERATIONS ARE ASSOCIATED.

CYSTS :
UNILATERAL MODERATE MULTIFOCAL
ONE OR MORE CYSTS FILLED WITH CLEAR LIQUID ARE SEEN.

PITUITARY

ABSENT :
ORGAN OR TISSUE NOT REMOVED FROM ANIMAL OR NOT FOUND IN FIXATIVE.

THYROIDS

ABSENT :
ORGAN OR TISSUE NOT REMOVED FROM ANIMAL OR NOT FOUND IN FIXATIVE.

ADRENALS

PIGMENTATION :
BILATERAL MINIMAL
NUMEROUS MACROPHAGES CONTAIN A GRANULAR BROWN CYTOPLASMIC PIGMENT.

*** ADENOMA :
UNILATERAL
THIS IS BENIGN GLANDULAR EPITHELIAL TUMOR.

TESTES

*** INTERSTITIAL CELL TUMOR :
UNILATERAL FOCAL

BAYER AG

SM1. 9 MALE 128 CONTINUED

TESTES CONTINUED

THIS BENIGN TUMOR IS COMPOSED OF LARGE EPITHELIAL CELLS WITH ABUNDANT ACIDOPHILIC CYTOPLASM.

MALE 141 (1502/60)

LUNG

*** ALVEOLOGENIC CARCINOMA :
A MALIGNANT TUMOR OF THE LUNG TISSUE WITH SYNONYMS IN MICE FOR ADENOMA, CARCINOMA, ALVEOLUGENIC PAPILLARY CARCINOMA, PAPILLARY CYSTADENOMA, ADENOCARCINOMA, BRONCHIOLAR CELL CARCINOMA, BRONCHIOLAR-ALVEOLAR TUMOR, TYPE A TUMOR, TYPE B TUMOR, INTERMEDIATE TYPE I TUMOR AND COMMON PULMONARY TUMOR OF THE MOUSE.

STOMACH

MUCOID CYST :
MINIMAL MULTIFOCAL
ONE OR MORE CYSTS CONTAINING MUCOID MATERIAL ARE OBSERVED.

LIVER

HYPERPLASTIC NODULE :
A NODULE OF HYPERPLASTIC TISSUE IS PRESENT.

HYALINOSIS :
MODERATE
DEPOSITS OF HYALINIC MATERIAL IS OBSERVED IN THE TISSUE.

SPLEEN

HEMATOPOIESIS :
MINIMAL
THE HEMATOPOIESIS IS EVIDENT.

KIDNEYS

CYSTS :
BILATERAL MODERATE
ONE OR MORE CYSTS FILLED WITH CLEAR LIQUID ARE SEEN.

ECTASIA VASCULAR :
BILATERAL MODERATE
THE LUMEN OF BLOOD VESSELS IS ABNORMALLY ENLARGED.

DILATATION OF RENAL PELVIS :
BILATERAL MODERATE
THE RENAL CAVITIES ARE MORE OR LESS ENLARGED.

THYROIDS

ABSENT :
ORGAN OR TISSUE NOT REMOVED FROM ANIMAL OR NOT FOUND IN FIXATIVE.

TESTES

ATROPHY SEMINIFEROUS :
UNILATERAL MODERATE MULTIFOCAL
THERE IS ATROPHY OF SEMINIFEROUS TUBULES WITH DIMINISHED SPERMATOGENIC ACTIVITY.

MALE 142 (1503/60)

LUNG

*** ALVEOLOGENIC CARCINOMA :
A MALIGNANT TUMOR OF THE LUNG TISSUE WITH SYNONYMS IN MICE FOR ADENOMA, CARCINOMA, ALVEOLOGENIC PAPILLARY CARCINOMA, PAPILLARY CYSTADENOMA, ADENOCARCINOMA, BRONCHIOLAR CELL CARCINOMA, BRONCHIOLAR-ALVEOLAR TUMOR, TYPE A TUMOR, TYPE B TUMOR, INTERMEDIATE TYPE I TUMOR AND COMMON PULMONARY TUMOR OF THE MOUSE.

STOMACH

MUCOID CYST :
MINIMAL
ONE OR MORE CYSTS CONTAINING MUCOID MATERIAL ARE OBSERVED.

LIVER

HYPERPLASTIC NODULE :
A NODULE OF HYPERPLASTIC TISSUE IS PRESENT.

PANCREAS

FATTY CYST :
ACCUMULATION OF FAT CELLS IS PRESENT.

SPLEEN

HEMATOPOIESIS :
SEVERE
THE HEMATOPOIESIS IS EVIDENT.

KIDNEYS

FIBROSIS :
UNILATERAL MINIMAL FOCAL
THERE IS AN INCREASE IN INTERSTITIAL FIBROUS TISSUE.

CONGESTION :
BILATERAL

BAYER AG

KIDNEYS CONTINUED
VESSELS OR SINUSOIDS ARE MARKEDLY DISTENDED WITH ERYTHROCYTES.

TUBULOPATHY :
CONTRALATERAL MINIMAL MULTIFOCAL
TUBULAR DEGENERATIVE CHANGES ARE PRESENT WHICH MAY BE ASSOCIATED WITH TUBULAR DILATATION.

THYROIDS

ABSENT :
ORGAN OR TISSUE NOT REMOVED FROM ANIMAL OR NOT FOUND IN FIXATIVE.

ADRENALS

ABSENT :
ORGAN OR TISSUE NOT REMOVED FROM ANIMAL OR NOT FOUND IN FIXATIVE.

TESTES

ATROPHY SEMINIFEROUS :
BILATERAL MODERATE MULTIFOCAL
THERE IS ATROPHY OF SEMINIFEROUS TUBULES WITH DIMINISHED SPERMATOGENIC ACTIVITY.

MALE 148 (1504/80)

LUNG

PNEUMONIA :
THE ALVEOLAR WALLS ARE THICKENED AND ALVEOLI CONTAIN INFLAMMATORY CELLS AND FOAMY MACROPHAGES.PERIVASCULAR AND PERIBRONCHIAL LYMPHOCYTIC ACCUMULATIONS MAY BE PRESENT.

EMPHYSEMA :
FOCAL
THERE IS A EMPHYSEMATOUS CHANGE IN THE ALVEOLAR WALLS.

LIVER

HEMATOPOIESIS :
MODERATE
THE HEMATOPOIESIS IS EVIDENT.

SPLEEN

HEMATOPOIESIS :
SEVERE
THE HEMATOPOIESIS IS EVIDENT.

KIDNEYS

FIBROSIS :
UNILATERAL MINIMAL MULTIFOCAL
THERE IS AN INCREASE IN INTERSTITIAL FIBROUS TISSUE.

PROGRESSIVE NEPHROPATHY :
BILATERAL MODERATE MULTIFOCAL
AN AGE ASSOCIATED KIDNEY LESION CONSISTING OF CYSTIC TUBULES WITH COLLOID OR HYALINE CASTS CHRONIC INTERSTITIAL NEPHRITIS AND DILATATION OF BOWMAN'S CAPSULE WITH GLOMERULAR DEGENERATION .

BLADDER

INFLAMMATION CHRONIC :
THE INTERSTITIAL TISSUES SHOW INFILTRATION BY MONONUCLEAR CELLS AND INCREASE IN FIBROUS STROMA.

THYROIDS

ABSENT :
ORGAN OR TISSUE NOT REMOVED FROM ANIMAL OR NOT FOUND IN FIXATIVE.

SKELETAL MUSCLE

ATROPHY :
MINIMAL MULTIFOCAL
THE ORGAN IS REDUCED IN SIZE.

TESTES

NORMAL :
HISTOLOGICAL ASPECT WITHIN NORMAL LIMITS.

SEMINAL VESICLES

COAGULUM :
AN ACIDOPHILIC STRUCTURE RESEMBLING COAGULATED PROTEIN IS PRESENT IN THE LUMEN.

INFLAMMATION ACUTE GLANDULAR :
NUMEROUS LEUCOCYTES ARE SEEN IN THE LUMEN.

LYMPH NODE

HYPERPLASIA LYMPHOID :
THE LYMPHOID FOLLICLES ARE INCREASED IN SIZE.

BAYER AG

MALE 149 (1505/80)

BRAIN

GLIOSIS :
FOCAL

SM1.13 MALE 149 CONTINUED

BRAIN CONTINUED

THERE IS PROLIFERATION OF GLIAL CELLS.

LUNG

*** ALVEOLOGENIC CARCINOMA :
A MALIGNANT TUMOR OF THE LUNG TISSUE WITH SYNONYMS IN MICE FOR ADENOMA, CARCINOMA, ALVEOLOGENIC PAPILLARY CARCINOMA, PAPILLARY CYSTADENOMA, ADENOCARCINOMA, BRONCHIOLAR CELL CARCINOMA, BRONCHIOLAR-ALVEOLAR TUMOR, TYPE A TUMOR, TYPE B TUMOR, INTERMEDIATE TYPE I TUMOR AND COMMON PULMONARY TUMOR OF THE MOUSE.

STOMACH

INFLAMMATION CHRONIC :
THERE IS AN INFILTRATION BY MONONUCLEAR CELLS IN THE MUCOSA AND SUBMUCOSA.

LIVER

FAT VACUOLES :
SEVERE
THE CELLS ARE DISTENDED BY CLEAR CYTOPLASMIC VACUOLES WHICH FREQUENTLY DISPLACE THE NUCLEI.

*** ADENOMA HEPATIC BENIGN :
DISTINCT NODULES COMPRESS THE ADJACENT LIVER PARENCHYMA, ARE CHARACTERIZED BY WELL DIFFERENTIATED HEPATOCYTES AND DO NOT SHOW PORTAL TRIADS.

HYPERPLASTIC NODULE :
A NODULE OF HYPERPLASTIC TISSUE IS PRESENT.

PANCREAS

INFLAMMATION CHRONIC :
MINIMAL FOCAL
THE INTERSTITIAL TISSUES SHOW INFILTRATION BY MONONUCLEAR CELLS AND INCREASE IN FIBROUS STROMA.

SPLEEN

NORMAL :
HISTOLOGICAL ASPECT WITHIN NORMAL LIMITS.

KIDNEYS

HYDRONEPHROSIS :
UNILATERAL
THE RENAL PELVIS IS DILATED AND THE ADJACENT PARENCHYMA IS REDUCED.

PROGRESSIVE NEPHROPATHY :
BILATERAL SEVERE
AN AGE ASSOCIATED KIDNEY LESION CONSISTING OF CYSTIC TUBULES WITH COLLOID OR HYALINE CASTS CHRONIC INTERSTITIAL NEPHRITIS AND DILATATION OF BOWMAN'S CAPSULE WITH GLOMERULAR DEGENERATION .

PITUITARY

CYSTS :
ONE OR MORE CYSTS FILLED WITH CLEAR LIQUID ARE SEEN.

THYROIDS

ABSENT :
ORGAN OR TISSUE NOT REMOVED FROM ANIMAL OR NOT FOUND IN FIXATIVE.

ADRENALS

PIGMENTATION :
BILATERAL MODERATE
NUMEROUS MACROPHAGES CONTAIN A GRANULAR BROWN CYTOPLASMIC PIGMENT.

TESTES

ATROPHY SEMINIFEROUS :
BILATERAL MINIMAL MULTIFOCAL
THERE IS ATROPHY OF SEMINIFEROUS TUBULES WITH DIMINISHED SPERMATOGENIC ACTIVITY.

BAYER AG BAYER AG BAYER AG BAYER AG

NM1. 1 CHRONIC TOXICITY STUDY IN MICE: NONSYSTEMATIC

HISTOPATHOLOGY

PRODUCT : CWG 05.9 GROUP : 1
ROUTE : DIETARY
TIME : 105 WEEKS DOSE : 125 PPM
THIS GROUP COMPRISED : 39 MALES

THE FOLLOWING ORGANS WERE EXAMINED SYSTEMATICALLY :

HEART	LUNG	LIVER
PANCREAS	SPLEEN	KIDNEYS
BLADDER	STOMACH	TESTES
THYROIDS	ADRENALS	PITUITARY
BRAIN	SKELETAL MUSCLE	SCIATIC NERVE
FEMUR		

THESE ORGANS WERE EXAMINED IN 39 MALES

INDIVIDUAL RESULTS

IN THE ANIMALS SHOWN BELOW THE HISTOLOGICAL EXAMINATION OF THE ORGANS LISTED OR OF THE ANOMALIES FOUND AT AUTOPSY GAVE THE FOLLOWING RESULTS :

MALE 101 (1692/80)

BRAIN

FAT VACUOLES :
MINIMAL FOCAL
THE CELLS ARE DISTENDED BY CLEAR CYTOPLASMIC VACUOLES WHICH FREQUENTLY DISPLACE THE NUCLEI.

LUNG

EDEMA :
THE INTERSTITIAL TISSUES CONTAIN AN INCREASED AMOUNT OF FLUID.

PNEUMONIA :
THE ALVEOLAR WALLS ARE THICKENED AND ALVEOLI CONTAIN INFLAMMATORY CELLS AND FOAMY MACROPHAGES.PERIVASCULAR AND PERIBRONCHIAL LYMPHOCYTIC ACCUMULATIONS MAY BE PRESENT.

CONGESTION :
VESSELS OR SINUSOIDS ARE MARKEDLY DISTENDED WITH ERYTHROCYTES.

STOMACH

NORMAL :
HISTOLOGICAL ASPECT WITHIN NORMAL LIMITS.

K.M1. 2 MALE 101 CONTINUED

LIVER

AUTOLYSIS PARTIAL :
NO OTHER CHANGES ARE SEEN. TISSUES ARE ALTERED.
BY POST-MORTEM MODIFICATIONS AND
DIAGNOSIS IS GIVEN WITH RESERVATION.

PANCREAS

AUTOLYSIS PARTIAL :
NO OTHER CHANGES ARE SEEN. TISSUES ARE ALTERED.
BY POST-MORTEM MODIFICATIONS AND
DIAGNOSIS IS GIVEN WITH RESERVATION.

KIDNEYS

CALCIFICATION :
UNILATERAL MINIMAL MULTIFOCAL
THERE ARE MINERAL DEPOSITS.

PITUITARY

ABSENT :
ORGAN OR TISSUE NOT REMOVED FROM ANIMAL OR NOT FOUND IN
FIXATIVE.

THYROIDS

ABSENT :
ORGAN OR TISSUE NOT REMOVED FROM ANIMAL OR NOT FOUND IN
FIXATIVE.

TESTES

AUTOLYSIS PARTIAL :
NO OTHER CHANGES ARE SEEN. TISSUES ARE ALTERED.
BY POST-MORTEM MODIFICATIONS AND
DIAGNOSIS IS GIVEN WITH RESERVATION.

INTESTINE

NORMAL :
HISTOLOGICAL ASPECT WITHIN NORMAL LIMITS.

MALE 102 (1737/80)

LUNG

CONGESTION :
SEVERE
VESSELS OR SINUSOIDS ARE MARKEDLY DISTENDED WITH
ERYTHROCYTES.

BAYER AG

LIVER

FAT VACUOLES :
SEVERE
THE CELLS ARE DISTENDED BY CLEAR CYTOPLASMIC VACUOLES WHICH FREQUENTLY DISPLACE THE NUCLEI.

FIBROSIS :
SEVERE
THERE IS AN INCREASE IN INTERSTITIAL FIBROUS TISSUE.

*** ADENOMA HEPATIC BENIGN :
SEVERE
DISTINCT NODULES COMPRESS THE ADJACENT LIVER PARENCHYMA, ARE CHARACTERIZED BY WELL DIFFERENTIATED HEPATOCYTES AND DO NOT SHOW PORTAL TRIADS.

HEMORRHAGE :
SEVERE
THERE IS EXTRAVASATION OF BLOOD.

PANCREAS

ABSENT :
ORGAN OR TISSUE NOT REMOVED FROM ANIMAL OR NOT FOUND IN FIXATIVE.

FATTY CYST :
ACCUMULATION OF FAT CELLS IS PRESENT.

SPLEEN

HEMATOPOIESIS :
MODERATE
THE HEMATOPOIESIS IS EVIDENT.

KIDNEYS

CALCIFICATION :
BILATERAL MODERATE MULTIFOCAL
THERE ARE MINERAL DEPOSITS.

CYSTS :
UNILATERAL MODERATE
ONE OR MORE CYSTS FILLED WITH CLEAR LIQUID ARE SEEN.

DILATATION OF RENAL PELVIS :
UNILATERAL MODERATE
THE RENAL CAVITIES ARE MORE OR LESS ENLARGED.

BLADDER

ECTASIA SIMPLE :
THE LUMEN OF THE ORGAN IS ABNORMALLY ENLARGED.

AUTOLYSIS PARTIAL :
NO OTHER CHANGES ARE SEEN. TISSUES ARE ALTERED. BY POST-MORTEM MODIFICATIONS AND DIAGNOSIS IS GIVEN WITH RESERVATION.

ADRENALS

*** PHEOCHROMOCYTOMA :
THIS TUMOR IS COMPOSED OF POLYHEDRAL CELLS WHICH ARISE FROM THE CHROMAFFIN CELLS OF THE ADRENAL MEDULLA AND FORM LOBULES SEPARATED BY VASCULAR CONNECTIVE TISSUE SEPTA.

MALE 103 (1705/80)

LUNG

PNEUMONIA :
SEVERE
THE ALVEOLAR WALLS ARE THICKENED AND ALVEOLI CONTAIN INFLAMMATORY CELLS AND FOAMY MACROPHAGES.PERIVASCULAR AND PERIBRONCHIAL LYMPHOCYTIC ACCUMULATIONS MAY BE PRESENT.

CONGESTION :
SEVERE
VESSELS OR SINUSOIDS ARE MARKEDLY DISTENDED WITH ERYTHROCYTES.

STOMACH

HEMORRHAGE :
FOCAL
THERE IS EXTRAVASATION OF BLOOD.

LIVER

FAT VACUOLES :
MINIMAL MULTIFOCAL
THE CELLS ARE DISTENDED BY CLEAR CYTOPLASMIC VACUOLES WHICH FREQUENTLY DISPLACE THE NUCLEI.

PANCREAS

AUTOLYSIS PARTIAL :
NO OTHER CHANGES ARE SEEN. TISSUES ARE ALTERED. BY POST-MORTEM MODIFICATIONS AND DIAGNOSIS IS GIVEN WITH RESERVATION.

KIDNEYS

CONGESTION :
VESSELS OR SINUSOIDS ARE MARKEDLY DISTENDED WITH ERYTHROCYTES.

BLADDER

AUTOLYSIS PARTIAL :
NO OTHER CHANGES ARE SEEN. TISSUES ARE ALTERED. BY POST-MORTEM MODIFICATIONS AND DIAGNOSIS IS GIVEN WITH RESERVATION.

BAYER AG

TESTES

SPERMATOCELE :
UNILATERAL MINIMAL MULTIFOCAL
FOCAL CYSTIC DILATATION CONTAINING SPERMATOZOA IS PRESENT.

MALE 104 (169R/80)

BRAIN

ABSENT :
ORGAN OR TISSUE NOT REMOVED FROM ANIMAL OR NOT FOUND IN FIXATIVE.

HEART

CONGESTION :
VESSELS OR SINUSOIDS ARE MARKEDLY DISTENDED WITH ERYTHROCYTES.

LUNG

EDEMA :
THE INTERSTITIAL TISSUES CONTAIN AN INCREASED AMOUNT OF FLUID.

STOMACH

AUTOLYSIS :
THE TISSUES EXHIBIT AUTOLYSIS AND THEY ARE NOT INTERPRETABLE.

LIVER

CALCIFICATION :
THERE ARE MINERAL DEPOSITS.

FAT VACUOLES :
THE CELLS ARE DISTENDED BY CLEAR CYTOPLASMIC VACUOLES WHICH FREQUENTLY DISPLACE THE NUCLEI.

AUTOLYSIS PARTIAL :
NO OTHER CHANGES ARE SEEN. TISSUES ARE ALTERED. BY POST-MORTEM MODIFICATIONS AND DIAGNOSIS IS GIVEN WITH RESERVATION.

HYPERPLASTIC NODULES :
MULTIFOCAL
WELL DEFINED ROUNDED FOCI OF HYPERPLASTIC AND HYPERTROPHIC CELLS ARE OBSERVED WITHIN THIS OTHERWISE NORMAL TISSUE.

PANCREAS

AUTOLYSIS :
THE TISSUES EXHIBIT AUTOLYSIS AND THEY ARE NOT

PANCREAS CONTINUED
INTERPRETABLE.

SPLEEN

AUTOLYSIS :
THE TISSUES EXHIBIT AUTOLYSIS AND THEY ARE NOT INTERPRETABLE.

KIDNEYS

AUTOLYSIS PARTIAL :
NO OTHER CHANGES ARE SEEN. TISSUES ARE ALTERED. BY POST-MORTEM MODIFICATIONS AND DIAGNOSIS IS GIVEN WITH RESERVATION.

BLADDER

AUTOLYSIS :
THE TISSUES EXHIBIT AUTOLYSIS AND THEY ARE NOT INTERPRETABLE.

PITUITARY

ABSENT :
ORGAN OR TISSUE NOT REMOVED FROM ANIMAL OR NOT FOUND IN FIXATIVE.

THYROIDS

AUTOLYSIS PARTIAL :
NO OTHER CHANGES ARE SEEN. TISSUES ARE ALTERED. BY POST-MORTEM MODIFICATIONS AND DIAGNOSIS IS GIVEN WITH RESERVATION.

TESTES

CALCIFICATION :
UNILATERAL MODERATE MULTIFOCAL
THERE ARE MINERAL DEPOSITS.

SEMINAL VESICLES

CALCIFICATION :
THERE ARE MINERAL DEPOSITS.

COAGULUM :
AN ACIDOPHILIC STRUCTURE RESEMBLING COAGULATED PROTEIN IS PRESENT IN THE LUMEN.

BAYER AG

MALE 105 (1740/60)

LUNG

HEMORRHAGE :
MODERATE FOCAL

NM1. 7 MALE 105 CONTINUED

LUNG CONTINUED

THERE IS EXTRAVASATION OF BLOOD.

CONGESTION :
VESSELS OR SINUSOIDS ARE MARKEDLY DISTENDED WITH ERYTHROCYTES.

ATELECTASIS :
MODERATE FOCAL
THERE IS COLLAPSE OF ALVEOLI.

LIVER

*** ADENOMA HEPATIC BENIGN :
MULTIFOCAL
DISTINCT NODULES COMPRESS THE ADJACENT LIVER PARENCHYMA, ARE CHARACTERIZED BY WELL DIFFERENTIATED HEPATOCYTES AND DO NOT SHOW PORTAL TRIADS.

HEMORRHAGE :
SEVERE
THERE IS EXTRAVASATION OF BLOOD.

CONGESTION :
SEVERE
VESSELS OR SINUSOIDS ARE MARKEDLY DISTENDED WITH ERYTHROCYTES.

SPLEEN

HEMATOPOIESIS :
SEVERE
THE HEMATOPOIESIS IS EVIDENT.

KIDNEYS

TUBULOPATHY :
BILATERAL MODERATE MULTIFOCAL
TUBULAR DEGENERATIVE CHANGES ARE PRESENT WHICH MAY BE ASSOCIATED WITH TUBULAR DILATATION.

PITUITARY

ABSENT :
ORGAN OR TISSUE NOT REMOVED FROM ANIMAL OR NOT FOUND IN FIXATIVE.

TESTES

SPERMATOCELE :
UNILATERAL MINIMAL FOCAL
FOCAL CYSTIC DILATATION CONTAINING SPERMATOZOA IS PRESENT.

MALE 106 (1706/80)

LUNG

PNEUMONIA :
MINIMAL
THE ALVEOLAR WALLS ARE THICKENED AND ALVEOLI CONTAIN INFLAMMATORY CELLS AND FOAMY MACROPHAGES.PERIVASCULAR AND PERIBRONCHIAL LYMPHOCYTIC ACCUMULATIONS MAY BE PRESENT.

LIVER

LEUKEMIC DEPOSITS :
ORGAN AND THE BLOOD ARE INVADED BY LEUKEMIC CELLS.

SPLEEN

*** LYMPHOMA LYMPHOCYTIC :
THE NEOPLASM OF THE RETICULAR SYSTEM ORIGINATES FROM LYMPHOCYTES.

KIDNEYS

DILATATION OF GLOMERULAR LOOPS :
BILATERAL MINIMAL MULTIFOCAL
GLOMERULAR LOOPS APPEAR UNUSUALLY ENLARGED AND THIN.

LYMPH NODE

*** LYMPHOMA LYMPHOCYTIC :
THE NEOPLASM OF THE RETICULAR SYSTEM ORIGINATES FROM LYMPHOCYTES.

MALE 108 (167A/80)

LUNG

NORMAL :
HISTOLOGICAL ASPECT WITHIN NORMAL LIMITS.

STOMACH

NORMAL :
HISTOLOGICAL ASPECT WITHIN NORMAL LIMITS.

SPLEEN

HEMATOPOIESIS :
MINIMAL
THE HEMATOPOIESIS IS EVIDENT.

KIDNEYS

TUBULOPATHY :
BILATERAL MINIMAL MULTIFOCAL
TUBULAR DEGENERATIVE CHANGES ARE PRESENT

BAYER AG

NMI. 9 MALE 108 CONTINUED

KIDNEYS CONTINUED

WHICH MAY BE ASSOCIATED WITH TUBULAR DILATATION.

INTERSTITIAL NEPHRITIS :
BILATERAL MINIMAL MULTIFOCAL
INFLAMMATORY CELLS FIBROSIS AND SOME TUBULAR ALTERATIONS ARE ASSOCIATED.

TESTES

ATROPHY SEMINIFEROUS :
UNILATERAL MINIMAL MULTIFOCAL
THERE IS ATROPHY OF SEMINIFEROUS TUBULES WITH DIMINISHED SPERMATOGENIC ACTIVITY.

MALE 109 (1727/80)

HEART

CONGESTION :
VESSELS OR SINUSOIDS ARE MARKEDLY DISTENDED WITH ERYTHROCYTES.

LUNG

HEMORRHAGE :
THERE IS EXTRAVASATION OF BLOOD.

CONGESTION :
VESSELS OR SINUSOIDS ARE MARKEDLY DISTENDED WITH ERYTHROCYTES.

ATELECTASIS :
THERE IS COLLAPSE OF ALVEOLI.

STOMACH

INFLAMMATION CHRONIC :
MODERATE MULTIFOCAL
THERE IS AN INFILTRATION BY MONONUCLEAR CELLS IN THE MUCOSA AND SUBMUCOSA.

LIVER

AUTOLYSIS PARTIAL :
NO OTHER CHANGES ARE SEEN. TISSUES ARE ALTERED. BY POST-MORTEM MODIFICATIONS AND DIAGNOSIS IS GIVEN WITH RESERVATION.

PANCREAS

AUTOLYSIS PARTIAL :
NO OTHER CHANGES ARE SEEN. TISSUES ARE ALTERED. BY POST-MORTEM MODIFICATIONS AND DIAGNOSIS IS GIVEN WITH RESERVATION.

SPLEEN

AUTOLYSIS PARTIAL :
NO OTHER CHANGES ARE SEEN. TISSUES ARE ALTERED.
BY POST-MORTEM MODIFICATIONS AND
DIAGNOSIS IS GIVEN WITH RESERVATION.

KIDNEYS

INTERSTITIAL NEPHRITIS :
BILATERAL MODERATE MULTIFOCAL
INFLAMMATORY CELLS FIBROSIS AND SOME TUBULAR ALTERATIONS
ARE ASSOCIATED.

THYROIDS

CYSTS :
UNILATERAL MINIMAL FOCAL
ONE OR MORE CYSTS FILLED WITH CLEAR LIQUID ARE SEEN.

MALE 111 (1701/80)

HEART

*** METASTASIS :
A SECONDARY MALIGNANT TUMOR DEVELOPED AWAY FROM THE INITIAL
GROWTH.

LUNG

*** ALVEOLOGENIC CARCINOMA :
MULTIFOCAL
A MALIGNANT TUMOR OF THE LUNG TISSUE WITH
SYNONYMS IN MICE FOR ADENOMA, CARCINOMA,
ALVEOLOGENIC PAPILLARY CARCINOMA, PAPILLARY
CYSTADENOMA, ADENOCARCINOMA, BRONCHIOLAR
CELL CARCINOMA, BRONCHIOLAR-ALVEOLAR TUMOR,
TYPE A TUMOR, TYPE B TUMOR, INTERMEDIATE
TYPE I TUMOR AND COMMON PULMONARY TUMOR OF
THE MOUSE.

STOMACH

MUCOID CYST :
MODERATE
ONE OR MORE CYSTS CONTAINING MUCOID MATERIAL ARE OBSERVED.

KIDNEYS

*** METASTASIS :
UNILATERAL
A SECONDARY MALIGNANT TUMOR DEVELOPED AWAY FROM THE INITIAL
GROWTH.

BAYER AG

THYROIDS

ABSENT :
ORGAN OR TISSUE NOT REMOVED FROM ANIMAL OR NOT FOUND IN FIXATIVE.

ADRENALS

*** ADENOMA :
UNILATERAL
THIS IS BENIGN GLANDULAR EPITHELIAL TUMOR.

MALE 112 (1731/80)

HEART

DILATED CHAMBER :
ONE OR MORE OF THE CHAMBERS OF THE HEART ARE DILATED.

LUNG

*** ALVEOLOGENIC CARCINOMA :
MULTIFOCAL
A MALIGNANT TUMOR OF THE LUNG TISSUE WITH SYNONYMS IN MICE FOR ADENOMA, CARCINOMA, ALVEOLOGENIC PAPILLARY CARCINOMA, PAPILLARY CYSTADENOMA, ADENOCARCINOMA, BRONCHIOLAR CELL CARCINOMA, BRONCHIOLAR-ALVEOLAR TUMOR, TYPE A TUMOR, TYPE B TUMOR, INTERMEDIATE TYPE I TUMOR AND COMMON PULMONARY TUMOR OF THE MOUSE.

LIVER

MONONUCLEAR CELLS :
MINIMAL FOCAL
FOCAL COLLECTIONS OF MONONUCLEAR CELLS ARE PRESENT.

SPLEEN

CONGESTION :
VESSELS OR SINUSOIDS ARE MARKEDLY DISTENDED WITH ERYTHROCYTES.

KIDNEYS

CALCIFICATION :
BILATERAL MINIMAL FOCAL
THERE ARE MINERAL DEPOSITS.

TUBULOPATHY :
BILATERAL MINIMAL MULTIFOCAL
TUBULAR DEGENERATIVE CHANGES ARE PRESENT WHICH MAY BE ASSOCIATED WITH TUBULAR DILATATION.

INTERSTITIAL NEPHRITIS :
BILATERAL MINIMAL MULTIFOCAL

KIDNEYS CONTINUED

INFLAMMATORY CELLS FIBROSIS AND SOME TUBULAR ALTERATIONS ARE ASSOCIATED.

THYROIDS

ABSENT :
ORGAN OR TISSUE NOT REMOVED FROM ANIMAL OR NOT FOUND IN FIXATIVE.

ADRENALS

HYPERPLASIA OF THE GLOMERULAR LAYER :
UNILATERAL FOCAL
THE GLOMERULAR LAYER IS THICKER THAN NORMAL.

SEMINAL VESICLES

COAGULUM :
AN ACIDOPHILIC STRUCTURE RESEMBLING COAGULATED PROTEIN IS PRESENT IN THE LUMEN.

MALE 113 (1728/80)

HEART

CONGESTION :
VESSELS OR SINUSOIDS ARE MARKEDLY DISTENDED WITH ERYTHROCYTES.

LUNG

BRONCHOPNEUMONIA :
SEVERE
MULTIFOCAL INFLAMMATION OF THE BRONCHI AND SURROUNDING ALVEULI ARE PRESENT.

CONGESTION :
VESSELS OR SINUSOIDS ARE MARKEDLY DISTENDED WITH ERYTHROCYTES.

SPLEEN

HEMATOPOIESIS :
MODERATE
THE HEMATOPOIESIS IS EVIDENT.

KIDNEYS

CALCIFICATION :
BILATERAL MINIMAL MULTIFOCAL
THERE ARE MINERAL DEPOSITS.

INTERSTITIAL NEPHRITIS :
BILATERAL MINIMAL MULTIFOCAL

BAYER AG

NM1•13 MALE 113 CONTINUED

KIDNEYS CONTINUED
INFLAMMATORY CELLS FIBROSIS AND SOME TUBULAR ALTERATIONS ARE ASSOCIATED.

TESTES

CALCIFICATION :
BILATERAL MODERATE MULTIFOCAL
THERE ARE MINERAL DEPOSITS.

SPERMATOCELE :
UNILATERAL MODERATE MULTIFOCAL
FOCAL CYSTIC DILATATION CONTAINING SPERMATOZOA IS PRESENT.

MALE 114 (1726/80)

LUNG

PNEUMONIA :
THE ALVEOLAR WALLS ARE THICKENED AND ALVEOLI CONTAIN INFLAMMATORY CELLS AND FOAMY MACROPHAGES.PERIVASCULAR AND PERIBRONCHIAL LYMPHOCYTIC ACCUMULATIONS MAY BE PRESENT.

*** ALVEOLOGENIC CARCINOMA :
A MALIGNANT TUMOR OF THE LUNG TISSUE WITH SYNONYMS IN MICE FOR ADENOMA, CARCINOMA, ALVEOLOGENIC PAPILLARY CARCINOMA, PAPILLARY CYSTADENOMA, ADENOCARCINOMA, BRONCHIOLAR CELL CARCINOMA, BRONCHIOLAR-ALVEOLAR TUMOR, TYPE A TUMOR, TYPE B TUMOR, INTERMEDIATE TYPE I TUMOR AND COMMON PULMONARY TUMOR OF THE MOUSE.

STOMACH

AUTOLYSIS :
THE TISSUES EXHIBIT AUTOLYSIS AND THEY ARE NOT INTERPRETABLE.

PANCREAS

AUTOLYSIS :
THE TISSUES EXHIBIT AUTOLYSIS AND THEY ARE NOT INTERPRETABLE.

SPLEEN

AUTOLYSIS :
THE TISSUES EXHIBIT AUTOLYSIS AND THEY ARE NOT INTERPRETABLE.

KIDNEYS

CALCIFICATION :
UNILATERAL MODERATE FOCAL

KIDNEYS CONTINUED

THERE ARE MINERAL DEPOSITS.

AUTOLYSIS PARTIAL :
BILATERAL
NO OTHER CHANGES ARE SEEN. TISSUES ARE ALTERED.
BY POST-MORTEM MODIFICATIONS AND
DIAGNOSIS IS GIVEN WITH RESERVATION.

BLADDER

AUTOLYSIS :
THE TISSUES EXHIBIT AUTOLYSIS AND THEY ARE NOT
INTERPRETABLE.

THYROIDS

CYSTS :
UNILATERAL
ONE OR MORE CYSTS FILLED WITH CLEAR LIQUID ARE SEEN.

AUTOLYSIS PARTIAL :
BILATERAL
NO OTHER CHANGES ARE SEEN. TISSUES ARE ALTERED.
BY POST-MORTEM MODIFICATIONS AND
DIAGNOSIS IS GIVEN WITH RESERVATION.

SCIATIC NERVE

ABSENT :
ORGAN OR TISSUE NOT REMOVED FROM ANIMAL OR NOT FOUND IN
FIXATIVE.

MALE 115 (1735/80)

BRAIN

FAT VACUOLES :
MINIMAL FOCAL
THE CELLS ARE DISTENDED BY CLEAR CYTOPLASMIC
VACUOLES WHICH FREQUENTLY DISPLACE THE NUCLEI.

LUNG

*** ALVEOLOGENIC CARCINOMA :
MULTIFOCAL
A MALIGNANT TUMOR OF THE LUNG TISSUE WITH
SYNONYMS IN MICE FOR ADENOMA, CARCINOMA,
ALVEOLOGENIC PAPILLARY CARCINOMA, PAPILLARY
CYSTADENOMA, ADENOCARCINOMA, BRONCHIOLAR
CELL CARCINOMA, BRONCHIOLAR-ALVEOLAR TUMOR,
TYPE A TUMOR, TYPE B TUMOR, INTERMEDIATE
TYPE I TUMOR AND COMMON PULMONARY TUMOR OF
THE MOUSE.

BAYER AG

LIVER

AUTOLYSIS PARTIAL :
NO OTHER CHANGES ARE SEEN. TISSUES ARE ALTERED.
BY POST-MORTEM MODIFICATIONS AND
DIAGNOSIS IS GIVEN WITH RESERVATION.

PANCREAS

INFLAMMATION CHRONIC :
MINIMAL FOCAL
THE INTERSTITIAL TISSUES SHOW INFILTRATION BY MONONUCLEAR
CELLS AND INCREASE IN FIBROUS STROMA.

SPLEEN

HEMORRHAGE :
SEVERE FOCAL
THERE IS EXTRAVASATION OF BLOOD.

HEMATOPOIESIS :
SEVERE
THE HEMATOPOIESIS IS EVIDENT.

KIDNEYS

TUBULOPATHY :
UNILATERAL MINIMAL
TUBULAR DEGENERATIVE CHANGES ARE PRESENT
WHICH MAY BE ASSOCIATED WITH TUBULAR DILATATION.

BLADDER

ECTASIA SIMPLE :
THE LUMEN OF THE ORGAN IS ABNORMALLY ENLARGED.

PITUITARY

ABSENT :
ORGAN OR TISSUE NOT REMOVED FROM ANIMAL OR NOT FOUND IN
FIXATIVE.

THYROIDS

AUTOLYSIS PARTIAL :
NO OTHER CHANGES ARE SEEN. TISSUES ARE ALTERED.
BY POST-MORTEM MODIFICATIONS AND
DIAGNOSIS IS GIVEN WITH RESERVATION.

SEMINAL VESICLES

COAGULUM :
AN ACIDOPHILIC STRUCTURE RESEMBLING COAGULATED PROTEIN IS
PRESENT IN THE LUMEN.

MALE 116 (1725/80)

LUNG

PNEUMONIA :
SEVERE
THE ALVEOLAR WALLS ARE THICKENED AND ALVEOLI CONTAIN INFLAMMATORY CELLS AND FOAMY MACROPHAGES.PERIVASCULAR AND PERIBRONCHIAL LYMPHOCYTIC ACCUMULATIONS MAY BE PRESENT.

LIVER

AMYLOID :
MULTIFOCAL
HOMOGENEOUS ACIDOPHILIC MATERIAL IS DEPOSITED.

LEUKEMIC DEPOSITS :
ORGAN AND THE BLOOD ARE INVADED BY LEUKEMIC CELLS.

SPLEEN

HYPERPLASIA LYMPHOID :
THE LYMPHOID FOLLICLES ARE INCREASED IN SIZE.

KIDNEYS

TUBULOPATHY :
BILATERAL SEVERE MULTIFOCAL
TUBULAR DEGENERATIVE CHANGES ARE PRESENT WHICH MAY BE ASSOCIATED WITH TUBULAR DILATATION.

BLADDER

ECTASIA SIMPLE :
THE LUMEN OF THE ORGAN IS ABNORMALLY ENLARGED.

LYMPH NODE

INFARCT :
AN AREA OF ISCHEMIC NECROSIS DUE TO VASCULAR OCCLUSION IS PRESENT.

*** LYMPHOMA LYMPHOCYTIC :
THE NEOPLASM OF THE RETICULAR SYSTEM ORIGINATES FROM LYMPHOCYTES.

MALE 118 (1707/80)

LUNG

EDEMA :
MINIMAL
THE INTERSTITIAL TISSUES CONTAIN AN INCREASED AMOUNT OF FLUID.

BAYER AG

LIVER

CONGESTION :
VESSELS OR SINUSOIDS ARE MARKEDLY DISTENDED WITH ERYTHROCYTES.

SPLEEN

HEMATOPOIESIS :
SEVERE
THE HEMATOPOIESIS IS EVIDENT.

KIDNEYS

NECROSIS :
BILATERAL SEVERE MULTIFOCAL
THE TISSUE HAS LOST ITS NORMAL STRUCTURE DUE TO CELL DEATH WHICH MAY BE OF VARIOUS ORIGIN.

PYELONEPHRITIS :
BILATERAL SEVERE MULTIFOCAL
INFLAMMATION OF RENAL PARENCHYMA WITH OR WITHOUT NECROSIS EXTENDED TO RENAL PELVIS.

BLADDER

INFLAMMATION ACUTE GLANDULAR :
NUMEROUS LEUCOCYTES ARE SEEN IN THE LUMEN.

PITUITARY

ABSENT :
ORGAN OR TISSUE NOT REMOVED FROM ANIMAL OR NOT FOUND IN FIXATIVE.

SCIATIC NERVE

ABSENT :
ORGAN OR TISSUE NOT REMOVED FROM ANIMAL OR NOT FOUND IN FIXATIVE.

MALE 120 (1704/80)

HEART

CONGESTION :
VESSELS OR SINUSOIDS ARE MARKEDLY DISTENDED WITH ERYTHROCYTES.

LUNG

PNEUMONIA :
THE ALVEOLAR WALLS ARE THICKENED AND ALVEOLI CONTAIN INFLAMMATORY CELLS AND FOAMY MACROPHAGES.PERIVASCULAR AND PERIBRONCHIAL LYMPHOCYTIC ACCUMULATIONS MAY BE PRESENT.

CONGESTION :

LUNG CONTINUED

VESSELS De SINUSOIDS ARE MARKEDLY DISTENDED WITH ERYTHROCYTES.

EMPHYSEMA :
THERE IS A EMPHYSEMATOUS CHANGE IN THE ALVEOLAR WALLS.

STOMACH

AUTOLYSIS PARTIAL :
NO OTHER CHANGES ARE SEEN. TISSUES ARE ALTERED.
BY POST-MORTEM MODIFICATIONS AND
DIAGNOSIS IS GIVEN WITH RESERVATION.

LIVER

CONGESTION :
VESSELS OR SINUSOIDS ARE MARKEDLY DISTENDED WITH ERYTHROCYTES.

PANCREAS

AUTOLYSIS PARTIAL :
NO OTHER CHANGES ARE SEEN. TISSUES ARE ALTERED.
BY POST-MORTEM MODIFICATIONS AND
DIAGNOSIS IS GIVEN WITH RESERVATION.

SPLEEN

HEMATOPOIESIS :
SEVERE
THE HEMATOPOIESIS IS EVIDENT.

KIDNEYS

DILATATION OF RENAL PELVIS :
UNILATERAL MODERATE
THE RENAL CAVITIES ARE MORE OR LESS ENLARGED.

PROGRESSIVE NEPHROPATHY :
BILATERAL MODERATE
AN AGE ASSOCIATED KIDNEY LESION CONSISTING OF CYSTIC TUBULES WITH COLLOID OR HYALINE CASTS CHRONIC INTERSTITIAL NEPHRITIS AND DILATATION OF BOWMAN'S CAPSULE WITH GLOMERULAR DEGENERATION .

BLADDER

AUTOLYSIS PARTIAL :
NO OTHER CHANGES ARE SEEN. TISSUES ARE ALTERED.
BY POST-MORTEM MODIFICATIONS AND
DIAGNOSIS IS GIVEN WITH RESERVATION.

ADRENALS

*** ADENOMA :
THIS IS BENIGN GLANDULAR EPITHELIAL TUMOR.

BAYER AG

MALE 121 (1700/80)

LUNG

*** ALVEOLOGENIC CARCINOMA :
MULTIFOCAL
A MALIGNANT TUMOR OF THE LUNG TISSUE WITH SYNONYMS IN MICE FOR ADENOMA, CARCINOMA, ALVEOLOGENIC PAPILLARY CARCINOMA, PAPILLARY CYSTADENOMA, ADENOCARCINOMA, BRONCHIOLAR CELL CARCINOMA, BRONCHIOLAR-ALVEOLAR TUMOR, TYPE A TUMOR, TYPE B TUMOR, INTERMEDIATE TYPE I TUMOR AND COMMON PULMONARY TUMOR OF THE MOUSE.

THYMUS

ABSENT :
ORGAN OR TISSUE NOT REMOVED FROM ANIMAL OR NOT FOUND IN FIXATIVE.

SPLEEN

HEMATOPOIESIS :
SEVERE
THE HEMATOPOIESIS IS EVIDENT.

KIDNEYS

TUBULOPATHY :
BILATERAL MINIMAL MULTIFOCAL
TUBULAR DEGENERATIVE CHANGES ARE PRESENT WHICH MAY BE ASSOCIATED WITH TUBULAR DILATATION.

THYROIDS

ABSENT :
ORGAN OR TISSUE NOT REMOVED FROM ANIMAL OR NOT FOUND IN FIXATIVE.

TESTES

ATROPHY SEMINIFEROUS :
BILATERAL MODERATE MULTIFOCAL
THERE IS ATROPHY OF SEMINIFEROUS TUBULES WITH DIMINISHED SPERMATOGENIC ACTIVITY.

CALCIFICATION :
BILATERAL MODERATE MULTIFOCAL
THERE ARE MINERAL DEPOSITS.

MALE 122 (174./60)

HEART

THROMBOSIS :
THE VASCULAR LUMEN CONTAINS AN ATTACHED ANTE MORTEM BLOOD CLOT.

LUNG

NORMAL :
HISTOLOGICAL ASPECT WITHIN NORMAL LIMITS.

STOMACH

AUTOLYSIS PARTIAL :
NO OTHER CHANGES ARE SEEN. TISSUES ARE ALTERED.
BY POST-MORTEM MODIFICATIONS AND
DIAGNOSIS IS GIVEN WITH RESERVATION.

LIVER

CYSTS :
MODERATE MULTIFOCAL
ONE OR MORE CYSTS FILLED WITH CLEAR LIQUID ARE SEEN.

AUTOLYSIS PARTIAL :
NO OTHER CHANGES ARE SEEN. TISSUES ARE ALTERED.
BY POST-MORTEM MODIFICATIONS AND
DIAGNOSIS IS GIVEN WITH RESERVATION.

PANCREAS

AUTOLYSIS :
THE TISSUES EXHIBIT AUTOLYSIS AND THEY ARE NOT
INTERPRETABLE.

SPLEEN

AUTOLYSIS :
THE TISSUES EXHIBIT AUTOLYSIS AND THEY ARE NOT
INTERPRETABLE.

KIDNEYS

FIBROSIS :
UNILATERAL MINIMAL FOCAL
THERE IS AN INCREASE IN INTERSTITIAL FIBROUS TISSUE.

TUBULOPATHY :
UNILATERAL MINIMAL MULTIFOCAL
TUBULAR DEGENERATIVE CHANGES ARE PRESENT
WHICH MAY BE ASSOCIATED WITH TUBULAR DILATATION.

AUTOLYSIS PARTIAL :
BILATERAL

BAYER AG

KIDNEYS CONTINUED

NO OTHER CHANGES ARE SEEN. TISSUES ARE ALTERED.
BY POST-MORTEM MODIFICATIONS AND
DIAGNOSIS IS GIVEN WITH RESERVATION.

BLADDER

AUTOLYSIS PARTIAL :
NO OTHER CHANGES ARE SEEN. TISSUES ARE ALTERED.
BY POST-MORTEM MODIFICATIONS AND
DIAGNOSIS IS GIVEN WITH RESERVATION.

ADRENALS

ABSENT :
ORGAN OR TISSUE NOT REMOVED FROM ANIMAL OR NOT FOUND IN
FIXATIVE.

MALE 124 (1738/80)

BRAIN

ABSENT :
ORGAN OR TISSUE NOT REMOVED FROM ANIMAL OR NOT FOUND IN
FIXATIVE.

LUNG

PNEUMONIA :
THE ALVEOLAR WALLS ARE THICKENED AND ALVEOLI CONTAIN
INFLAMMATORY CELLS AND FOAMY MACROPHAGES.PERIVASCULAR AND
PERIBRONCHIAL LYMPHOCYTIC ACCUMULATIONS MAY BE PRESENT.

STOMACH

AUTOLYSIS PARTIAL :
NO OTHER CHANGES ARE SEEN. TISSUES ARE ALTERED.
BY POST-MORTEM MODIFICATIONS AND
DIAGNOSIS IS GIVEN WITH RESERVATION.

LIVER

AUTOLYSIS PARTIAL :
NO OTHER CHANGES ARE SEEN. TISSUES ARE ALTERED.
BY POST-MORTEM MODIFICATIONS AND
DIAGNOSIS IS GIVEN WITH RESERVATION.

PANCREAS

AUTOLYSIS :
THE TISSUES EXHIBIT AUTOLYSIS AND THEY ARE NOT
INTERPRETABLE.

SPLEEN

AUTOLYSIS PARTIAL :
NO OTHER CHANGES ARE SEEN. TISSUES ARE ALTERED.
BY POST-MORTEM MODIFICATIONS AND
DIAGNOSIS IS GIVEN WITH RESERVATION.

KIDNEYS

FIBROSIS :
BILATERAL MINIMAL FOCAL
THERE IS AN INCREASE IN INTERSTITIAL FIBROUS TISSUE.

CYSTS :
UNILATERAL MINIMAL
ONE OR MORE CYSTS FILLED WITH CLEAR LIQUID ARE SEEN.

BLADDER

AUTOLYSIS PARTIAL :
NO OTHER CHANGES ARE SEEN. TISSUES ARE ALTERED.
BY POST-MORTEM MODIFICATIONS AND
DIAGNOSIS IS GIVEN WITH RESERVATION.

THYROIDS

ABSENT :
ORGAN OR TISSUE NOT REMOVED FROM ANIMAL OR NOT FOUND IN FIXATIVE.

MALE 125 (169a/80 B)

BRAIN

ABSENT :
ORGAN OR TISSUE NOT REMOVED FROM ANIMAL OR NOT FOUND IN FIXATIVE.

LUNG

EDEMA :
THE INTERSTITIAL TISSUES CONTAIN AN INCREASED AMOUNT OF FLUID.

EMPHYSEMA :
THERE IS A EMPHYSEMATOUS CHANGE IN THE ALVEOLAR WALLS.

STOMACH

AUTOLYSIS PARTIAL :
NO OTHER CHANGES ARE SEEN. TISSUES ARE ALTERED.
BY POST-MORTEM MODIFICATIONS AND
DIAGNOSIS IS GIVEN WITH RESERVATION.

BAYER AG

LIVER

*** ADENOMA HEPATIC BENIGN :
MULTIFOCAL
DISTINCT NODULES COMPRESS THE ADJACENT LIVER PARENCHYMA, ARE CHARACTERIZED BY WELL DIFFERENTIATED HEPATOCYTES AND DO NOT SHOW PORTAL TRIADS.

AUTOLYSIS PARTIAL :
NO OTHER CHANGES ARE SEEN. TISSUES ARE ALTERED. BY POST-MORTEM MODIFICATIONS AND DIAGNOSIS IS GIVEN WITH RESERVATION.

PANCREAS

ABSENT :
ORGAN OR TISSUE NOT REMOVED FROM ANIMAL OR NOT FOUND IN FIXATIVE.

SPLEEN

EDEMA :
THE INTERSTITIAL TISSUES CONTAIN AN INCREASED AMOUNT OF FLUID.

KIDNEYS

AUTOLYSIS PARTIAL :
NO OTHER CHANGES ARE SEEN. TISSUES ARE ALTERED. BY POST-MORTEM MODIFICATIONS AND DIAGNOSIS IS GIVEN WITH RESERVATION.

BLADDER

AUTOLYSIS PARTIAL :
NO OTHER CHANGES ARE SEEN. TISSUES ARE ALTERED. BY POST-MORTEM MODIFICATIONS AND DIAGNOSIS IS GIVEN WITH RESERVATION.

PITUITARY

ABSENT :
ORGAN OR TISSUE NOT REMOVED FROM ANIMAL OR NOT FOUND IN FIXATIVE.

THYROIDS

ABSENT :
ORGAN OR TISSUE NOT REMOVED FROM ANIMAL OR NOT FOUND IN FIXATIVE.

MALE 126 (167s/80)

LUNG

*** ALVEOLOGENIC CARCINOMA :
A MALIGNANT TUMOR OF THE LUNG TISSUE WITH SYNONYMS IN MICE FOR ADENOMA, CARCINOMA, ALVEOLOGENIC PAPILLARY CARCINOMA, PAPILLARY CYSTADENOMA, ADENOCARCINOMA, BRONCHIOLAR CEL. CARCINOMA, BRONCHIOLAR-ALVEOLAR TUMOR, TYPE A TUMOR, TYPE B TUMOR, INTERMEDIATE TYPE I TUMOR AND COMMON PULMONARY TUMOR OF THE MOUSE.

LIVER

INFLAMMATION GRANULOMATOUS :
MODERATE MULTIFOCAL
THERE IS A FOCAL GRANULOMATOUS PROCESS CHARACTERIZED BY MONONUCLEAR AND MULTINUCLEATED CELLULAR INFILTRATION.

HEMATOPOIESIS :
SEVERE MULTIFOCAL
THE HEMATOPOIESIS IS EVIDENT.

SPLEEN

HEMATOPOIESIS :
SEVERE
THE HEMATOPOIESIS IS EVIDENT.

KIDNEYS

PROGRESSIVE NEPHROPATHY :
BILATERAL MINIMAL
AN AGE ASSOCIATED KIDNEY LESION CONSISTING OF CYSTIC TUBULES WITH COLLOID OR HYALINE CASTS CHRONIC INTERSTITIAL NEPHRITIS AND DILATATION OF BOWMAN'S CAPSULE WITH GLOMERULAR DEGENERATION .

BLADDER

AUTOLYSIS PARTIAL :
NO OTHER CHANGES ARE SEEN. TISSUES ARE ALTERED. BY POST-MORTEM MODIFICATIONS AND DIAGNOSIS IS GIVEN WITH RESERVATION.

PITUITARY

ABSENT :
ORGAN OR TISSUE NOT REMOVED FROM ANIMAL OR NOT FOUND IN FIXATIVE.

THYROIDS

AUTOLYSIS PARTIAL :
NO OTHER CHANGES ARE SEEN. TISSUES ARE ALTERED. BY POST-MORTEM MODIFICATIONS AND DIAGNOSIS IS GIVEN WITH RESERVATION.

BAYER

MALE 129 (1694/80)

BRAIN

GLIOSIS :
MINIMAL FOCAL
THERE IS PROLIFERATION OF GLIAL CELLS.

HEART

PERICARDITIS :
MODERATE FOCAL
THE PERICARDIUM IS THE SITE OF ACUTE OR CHRONIC INFLAMMATION.

LUNG

*** ALVEOLOGENIC CARCINOMA :
A MALIGNANT TUMOR OF THE LUNG TISSUE WITH SYNONYMS IN MICE FOR ADENOMA, CARCINOMA, ALVEOLOGENIC PAPILLARY CARCINOMA, PAPILLARY CYSTADENOMA, ADENOCARCINOMA, BRONCHIOLAR CELL CARCINOMA, BRONCHIOLAR-ALVEOLAR TUMOR, TYPE A TUMOR, TYPE B TUMOR, INTERMEDIATE TYPE I TUMOR AND COMMON PULMONARY TUMOR OF THE MOUSE.

THICKENED ALVEOLAR WALLS :
THICKNESS OF ALVEOLAR WALLS IS INCREASED BY INFLAMMATORY CELLS AND/OR INTERSTITIAL EDEMA.

LIVER

CONGESTION :
VESSELS OR SINUSOIDS ARE MARKEDLY DISTENDED WITH ERYTHROCYTES.

PANCREAS

AUTOLYSIS PARTIAL :
NO OTHER CHANGES ARE SEEN. TISSUES ARE ALTERED. BY POST-MORTEM MODIFICATIONS AND DIAGNOSIS IS GIVEN WITH RESERVATION.

KIDNEYS

FIBROSIS :
UNILATERAL MODERATE MULTIFOCAL
THERE IS AN INCREASE IN INTERSTITIAL FIBROUS TISSUE.

TUBULOPATHY :
BILATERAL MINIMAL MULTIFOCAL
TUBULAR DEGENERATIVE CHANGES ARE PRESENT WHICH MAY BE ASSOCIATED WITH TUBULAR DILATATION.

BLADDER

AUTOLYSIS PARTIAL :
NO OTHER CHANGES ARE SEEN. TISSUES ARE ALTERED.
BY POST-MORTEM MODIFICATIONS AND
DIAGNOSIS IS GIVEN WITH RESERVATION.

THYROIDS

AUTOLYSIS PARTIAL :
NO OTHER CHANGES ARE SEEN. TISSUES ARE ALTERED.
BY POST-MORTEM MODIFICATIONS AND
DIAGNOSIS IS GIVEN WITH RESERVATION.

MALE 130 (1729/80)

BRAIN

ABSENT :
ORGAN OR TISSUE NOT REMOVED FROM ANIMAL OR NOT FOUND IN FIXATIVE.

LUNG

LEUKEMIC DEPOSITS :
ORGAN AND THE BLOOD ARE INVADED BY LEUKEMIC CELLS.

AUTOLYSIS PARTIAL :
NO OTHER CHANGES ARE SEEN. TISSUES ARE ALTERED.
BY POST-MORTEM MODIFICATIONS AND
DIAGNOSIS IS GIVEN WITH RESERVATION.

STOMACH

HEMORRHAGE :
FOCAL
THERE IS EXTRAVASATION OF BLOOD.

AUTOLYSIS PARTIAL :
NO OTHER CHANGES ARE SEEN. TISSUES ARE ALTERED.
BY POST-MORTEM MODIFICATIONS AND
DIAGNOSIS IS GIVEN WITH RESERVATION.

LIVER

LEUKEMIC DEPOSITS :
ORGAN AND THE BLOOD ARE INVADED BY LEUKEMIC CELLS.

AUTOLYSIS PARTIAL :
NO OTHER CHANGES ARE SEEN. TISSUES ARE ALTERED.
BY POST-MORTEM MODIFICATIONS AND
DIAGNOSIS IS GIVEN WITH RESERVATION.

BAYER AG

PANCREAS

AUTOLYSIS :
THE TISSUES EXHIBIT AUTOLYSIS AND THEY ARE NOT INTERPRETABLE.

SPLEEN

*** LYMPHOMA LYMPHOCYTIC :
THE NEOPLASM OF THE RETICULAR SYSTEM ORIGINATES FROM LYMPHOCYTES.

KIDNEYS

LEUKEMIC DEPOSITS :
ORGAN AND THE BLOOD ARE INVADED BY LEUKEMIC CELLS.

BLADDER

LEUKEMIC DEPOSITS :
ORGAN AND THE BLOOD ARE INVADED BY LEUKEMIC CELLS.

AUTOLYSIS PARTIAL :
NO OTHER CHANGES ARE SEEN. TISSUES ARE ALTERED. BY POST-MORTEM MODIFICATIONS AND DIAGNOSIS IS GIVEN WITH RESERVATION.

THYROIDS

ABSENT :
ORGAN OR TISSUE NOT REMOVED FROM ANIMAL OR NOT FOUND IN FIXATIVE.

SCIATIC NERVE

ABSENT :
ORGAN OR TISSUE NOT REMOVED FROM ANIMAL OR NOT FOUND IN FIXATIVE.

MESENTERY

LEUKEMIC DEPOSITS :
ORGAN AND THE BLOOD ARE INVADED BY LEUKEMIC CELLS.

MALE 131 (1730/80)

BRAIN

FAT VACUOLES :
MINIMAL FOCAL
THE CELLS ARE DISTENDED BY CLEAR CYTOPLASMIC VACUOLES WHICH FREQUENTLY DISPLACE THE NUCLEI.

LUNG

PNEUMONIA :
SEVERE
THE ALVEOLAR WALLS ARE THICKENED AND ALVEOLI CONTAIN INFLAMMATORY CELLS AND FOAMY MACROPHAGES.PERIVASCULAR AND PERIBRONCHIAL LYMPHOCYTIC ACCUMULATIONS MAY BE PRESENT.

*** ALVEOLOGENIC CARCINOMA :
A MALIGNANT TUMOR OF THE LUNG TISSUE WITH SYNONYMS IN MICE FOR ADENOMA, CARCINOMA, ALVEOLOGENIC PAPILLARY CARCINOMA, PAPILLARY CYSTADENOMA, ADENOCARCINOMA, BRONCHIOLAR CELL CARCINOMA, BRONCHIOLAR-ALVEOLAR TUMOR, TYPE A TUMOR, TYPE B TUMOR, INTERMEDIATE TYPE I TUMOR AND COMMON PULMONARY TUMOR OF THE MOUSE.

LEUKEMIC DEPOSITS :
ORGAN AND THE BLOOD ARE INVADED BY LEUKEMIC CELLS.

STOMACH

LEUKEMIC DEPOSITS :
ORGAN AND THE BLOOD ARE INVADED BY LEUKEMIC CELLS.

LIVER

FAT VACUOLES :
SEVERE
THE CELLS ARE DISTENDED BY CLEAR CYTOPLASMIC VACUOLES WHICH FREQUENTLY DISPLACE THE NUCLEI.

LEUKEMIC DEPOSITS :
ORGAN AND THE BLOOD ARE INVADED BY LEUKEMIC CELLS.

PANCREAS

LEUKEMIC DEPOSITS :
ORGAN AND THE BLOOD ARE INVADED BY LEUKEMIC CELLS.

SPLEEN

*** LYMPHOMA LYMPHOCYTIC :
THE NEOPLASM OF THE RETICULAR SYSTEM ORIGINATES FROM LYMPHOCYTES.

KIDNEYS

LEUKEMIC DEPOSITS :
ORGAN AND THE BLOOD ARE INVADED BY LEUKEMIC CELLS.

BLADDER

LEUKEMIC DEPOSITS :
ORGAN AND THE BLOOD ARE INVADED BY LEUKEMIC CELLS.

BAYER AG BAYER AG BAYER AG

Vertraulich
Eigentum der Firma Bayer AG
Benutzung, Verwertung oder Weitergabe nur mit Einwilligung der Bayer AG gestattet

PITUITARY

ABSENT :
ORGAN OR TISSUE NOT REMOVED FROM ANIMAL OR NOT FOUND IN FIXATIVE.

THYROIDS

ABSENT :
ORGAN OR TISSUE NOT REMOVED FROM ANIMAL OR NOT FOUND IN FIXATIVE.

ADRENALS

NORMAL :
HISTOLOGICAL ASPECT WITHIN NORMAL LIMITS.

MALE 132 (1733/80)

BRAIN

HYDROCEPHALUS :
MINIMAL
THE LATERAL VENTRICLES ARE ENLARGED AND THE SURROUNDING BRAIN PARENCHYMA APPEARS COMPRESSED.

LUNG

HEMORRHAGE :
THERE IS EXTRAVASATION OF BLOOD.

LIVER

FAT VACUOLES :
MINIMAL MULTIFOCAL
THE CELLS ARE DISTENDED BY CLEAR CYTOPLASMIC VACUOLES WHICH FREQUENTLY DISPLACE THE NUCLEI.

SPLEEN

HEMATOPOIESIS :
MINIMAL
THE HEMATOPOIESIS IS EVIDENT.

KIDNEYS

FIBROSIS :
BILATERAL MINIMAL
THERE IS AN INCREASE IN INTERSTITIAL FIBROUS TISSUE.

TUBULOPATHY :
BILATERAL MINIMAL
TUBULAR DEGENERATIVE CHANGES ARE PRESENT WHICH MAY BE ASSOCIATED WITH TUBULAR DILATATION.

INTERSTITIAL NEPHRITIS :
BILATERAL MINIMAL

KIDNEYS CONTINUED

INFLAMMATORY CELLS FIBROSIS AND SOME TUBULAR ALTERATIONS ARE ASSOCIATED.

PITUITARY

ABSENT :
ORGAN OR TISSUE NOT REMOVED FROM ANIMAL OR NOT FOUND IN FIXATIVE.

THYROIDS

ABSENT :
ORGAN OR TISSUE NOT REMOVED FROM ANIMAL OR NOT FOUND IN FIXATIVE.

TESTES

ATROPHY SEMINIFEROUS :
UNILATERAL MODERATE MULTIFOCAL
THERE IS ATROPHY OF SEMINIFEROUS TUBULES WITH DIMINISHED SPERMATOGENIC ACTIVITY.

MALE 133 (1679/80)

LIVER

INFARCT :
SEVERE
AN AREA OF ISCHEMIC NECROSIS DUE TO VASCULAR OCCLUSION IS PRESENT.

LEUKEMIC DEPOSITS :
ORGAN AND THE BLOOD ARE INVADED BY LEUKEMIC CELLS.

PANCREAS

LEUKEMIC DEPOSITS :
ORGAN AND THE BLOOD ARE INVADED BY LEUKEMIC CELLS.

SPLEEN

*** LYMPHOMA STEM CELLS :
THE NEOPLASM OF THE RETICULAR SYSTEM ORIGINATES FROM STEM CELLS.

KIDNEYS

DILATATION OF RENAL PELVIS :
UNILATERAL MODERATE
THE RENAL CAVITIES ARE MORE OR LESS ENLARGED.

PROGRESSIVE NEPHROPATHY :
BILATERAL MODERATE

BAYER AG BAYER AG BAYER AG

KIDNEYS CONTINUED

AN AGE ASSOCIATED KIDNEY LESION CONSISTING OF CYSTIC TUBULES WITH COLLOID OR HYALINE CASTS CHRONIC INTERSTITIAL NEPHRITIS AND DILATATION OF BOWMAN'S CAPSULE WITH GLOMERULAR DEGENERATION .

PITUITARY

ABSENT :
ORGAN OR TISSUE NOT REMOVED FROM ANIMAL OR NOT FOUND IN FIXATIVE.

ADRENALS

*** ADENOMA :
BILATERAL
THIS IS BENIGN GLANDULAR EPITHELIAL TUMOR.

SCIATIC NERVE

ABSENT :
ORGAN OR TISSUE NOT REMOVED FROM ANIMAL OR NOT FOUND IN FIXATIVE.

MESENTERY

LEUKEMIC DEPOSITS :
ORGAN AND THE BLOOD ARE INVADED BY LEUKEMIC CELLS.

FAT

LEUKEMIC DEPOSITS :
ORGAN AND THE BLOOD ARE INVADED BY LEUKEMIC CELLS.

MALE 134 (1703/80)

BRAIN

ABSENT :
ORGAN OR TISSUE NOT REMOVED FROM ANIMAL OR NOT FOUND IN FIXATIVE.

HEART

CONGESTION :
VESSELS OR SINUSOIDS ARE MARKEDLY DISTENDED WITH ERYTHROCYTES.

LUNG

EDEMA :
THE INTERSTITIAL TISSUES CONTAIN AN INCREASED AMOUNT OF FLUID.

PNEUMONIA :

LUNG CONTINUED

THE ALVEOLAR WALLS ARE THICKENED AND ALVEOLI CONTAIN INFLAMMATORY CELLS AND FOAMY MACROPHAGES.PERIVASCULAR AND PERIBRONCHIAL LYMPHOCYTIC ACCUMULATIONS MAY BE PRESENT.

CONGESTION :
VESSELS OR SINUSOIDS ARE MARKEDLY DISTENDED WITH ERYTHROCYTES.

STOMACH

AUTOLYSIS PARTIAL :
NO OTHER CHANGES ARE SEEN. TISSUES ARE ALTERED. BY POST-MORTEM MODIFICATIONS AND DIAGNOSIS IS GIVEN WITH RESERVATION.

LIVER

AUTOLYSIS PARTIAL :
NO OTHER CHANGES ARE SEEN. TISSUES ARE ALTERED. BY POST-MORTEM MODIFICATIONS AND DIAGNOSIS IS GIVEN WITH RESERVATION.

PANCREAS

CYSTIC DYSPLASIA :
ONE OR SEVERAL DUCTS ARE ENLARGED AND CYSTIC.

SPLEEN

AUTOLYSIS PARTIAL :
NO OTHER CHANGES ARE SEEN. TISSUES ARE ALTERED. BY POST-MORTEM MODIFICATIONS AND DIAGNOSIS IS GIVEN WITH RESERVATION.

ECTASIA VASCULAR :
THE LUMEN OF BLOOD VESSELS IS ABNORMALLY ENLARGED.

KIDNEYS

PROGRESSIVE NEPHROPATHY :
BILATERAL MODERATE
AN AGE ASSOCIATED KIDNEY LESION CONSISTING OF CYSTIC TUBULES WITH COLLOID OR HYALINE CASTS CHRONIC INTERSTITIAL NEPHRITIS AND DILATATION OF BOWMAN'S CAPSULE WITH GLOMERULAR DEGENERATION .

BLADDER

AUTOLYSIS PARTIAL :
NO OTHER CHANGES ARE SEEN. TISSUES ARE ALTERED. BY POST-MORTEM MODIFICATIONS AND DIAGNOSIS IS GIVEN WITH RESERVATION.

THYROIDS

AUTOLYSIS :
THE TISSUES EXHIBIT AUTOLYSIS AND THEY ARE NOT INTERPRETABLE.

BAYER AG

MALE 135 (1734/80)

HEART

CONGESTION :
VESSELS OR SINUSOIDS ARE MARKEDLY DISTENDED WITH ERYTHROCYTES.

LUNG

HEMORRHAGE :
THERE IS EXTRAVASATION OF BLOOD.

CONGESTION :
VESSELS OR SINUSOIDS ARE MARKEDLY DISTENDED WITH ERYTHROCYTES.

KIDNEYS

DILATATION OF RENAL PELVIS :
UNILATERAL MODERATE
THE RENAL CAVITIES ARE MORE OR LESS ENLARGED.

BLADDER

ECTASIA SIMPLE :
THE LUMEN OF THE ORGAN IS ABNORMALLY ENLARGED.

ADRENALS

HYPERPLASTIC NODULE :
UNILATERAL
A NODULE OF HYPERPLASTIC TISSUE IS PRESENT.

TESTES

SPERMATOCELE :
UNILATERAL MINIMAL FOCAL
FOCAL CYSTIC DILATATION CONTAINING SPERMATOZOA IS PRESENT.

MALE 136 (1677/80)

LIVER

VACUOLIZATION :
MINIMAL MULTIFOCAL
IN THESE CELLS THERE ARE CLEAR VACUOLES GREATER IN NUMBER AND SIZE THAN NORMALLY FOUND.

SPLEEN

HEMATOPOIESIS :
MODERATE
THE HEMATOPOIESIS IS EVIDENT.

KIDNEYS

CALCIFICATION :
UNILATERAL MODERATE MULTIFOCAL
THERE ARE MINERAL DEPOSITS.

PROGRESSIVE NEPHROPATHY :
BILATERAL MODERATE
AN AGE ASSOCIATED KIDNEY LESION CONSISTING OF CYSTIC TUBULES WITH COLLOID OR HYALINE CASTS CHRONIC INTERSTITIAL NEPHRITIS AND DILATATION OF BOWMAN'S CAPSULE WITH GLOMERULAR DEGENERATION .

BLADDER

HYPERPLASIA PAPILLOMATOUS :
THE THICKNESS OF THE MUCOSA IS INCREASED MAKING UNUSUALLY HIGH AND NUMEROUS FOLDS.

THYROIDS

ABSENT :
ORGAN OR TISSUE NOT REMOVED FROM ANIMAL OR NOT FOUND IN FIXATIVE.

FAT

*** LIPOMA :
THE BENIGN TUMOR IS COMPOSED OF NORMAL FAT CELLS WITH SOME VASCULAR FIBROUS STROMA.

MALE 137 (1678/80)

LUNG

*** ALVEOLOGENIC CARCINOMA :
MULTIFOCAL
A MALIGNANT TUMOR OF THE LUNG TISSUE WITH SYNONYMS IN MICE FOR ADENOMA, CARCINOMA, ALVEOLOGENIC PAPILLARY CARCINOMA, PAPILLARY CYSTADENOMA, ADENOCARCINOMA, BRONCHIOLAR CEL. CARCINOMA, BRONCHIOLAR-ALVEOLAR TUMOR, TYPE A TUMOR, TYPE B TUMOR, INTERMEDIATE TYPE I TUMOR AND COMMON PULMONARY TUMOR OF THE MOUSE.

LIVER

HEMORRHAGE :
SEVERE MULTIFOCAL

BAYER

LIVER CONTINUED

THERE IS EXTRAVASATION OF BLOOD.

MONONUCLEAR CELLS :
SEVERE MULTIFOCAL
FOCAL COLLECTIONS OF MONONUCLEAR CELLS ARE PRESENT.

SPLEEN

HEMATOPOIESIS :
MODERATE
THE HEMATOPOIESIS IS EVIDENT.

CONGESTION :
VESSELS OR SINUSOIDS ARE MARKEDLY DISTENDED WITH ERYTHROCYTES.

PITUITARY

ABSENT :
ORGAN OR TISSUE NOT REMOVED FROM ANIMAL OR NOT FOUND IN FIXATIVE.

THYROIDS

ABSENT :
ORGAN OR TISSUE NOT REMOVED FROM ANIMAL OR NOT FOUND IN FIXATIVE.

MALE 138 (1724/80)

BRAIN

FAT VACUOLES :
MINIMAL FOCAL
THE CELLS ARE DISTENDED BY CLEAR CYTOPLASMIC VACUOLES WHICH FREQUENTLY DISPLACE THE NUCLEI.

HEART

THROMBOSIS :
THE VASCULAR LUMEN CONTAINS AN ATTACHED ANTE MORTEM BLOOD CLOT.

CONGESTION :
VESSELS OR SINUSOIDS ARE MARKEDLY DISTENDED WITH ERYTHROCYTES.

LUNG

HEMORRHAGE :
THERE IS EXTRAVASATION OF BLOOD.

ADENOMATOSIS :
FOCAL

LUNG CONTINUED

THE PULMONARY ALVEOLI APPEAR GLANDULAR DUE TO METAPLASTIC TRANSFORMATION OF LINING CELLS INTO CUBOIDAL OR COLUMNAR CELLS

CONGESTION :
VESSELS OR SINUSOIDS ARE MARKEDLY DISTENDED WITH ERYTHROCYTES.

STOMACH

AUTOLYSIS PARTIAL :
NO OTHER CHANGES ARE SEEN. TISSUES ARE ALTERED. BY POST-MORTEM MODIFICATIONS AND DIAGNOSIS IS GIVEN WITH RESERVATION.

LIVER

AUTOLYSIS PARTIAL :
NO OTHER CHANGES ARE SEEN. TISSUES ARE ALTERED. BY POST-MORTEM MODIFICATIONS AND DIAGNOSIS IS GIVEN WITH RESERVATION.

SPLEEN

HEMATOPOIESIS :
SEVERE
THE HEMATOPOIESIS IS EVIDENT.

KIDNEYS

DILATATION OF RENAL PELVIS :
BILATERAL MINIMAL
THE RENAL CAVITIES ARE MORE OR LESS ENLARGED.

PROGRESSIVE NEPHROPATHY :
BILATERAL SEVERE
AN AGE ASSOCIATED KIDNEY LESION CONSISTING OF CYSTIC TUBULES WITH COLLOID OR HYALINE CASTS CHRONIC INTERSTITIAL NEPHRITIS AND DILATATION OF BOWMAN'S CAPSULE WITH GLOMERULAR DEGENERATION .

BLADDER

AUTOLYSIS PARTIAL :
NO OTHER CHANGES ARE SEEN. TISSUES ARE ALTERED. BY POST-MORTEM MODIFICATIONS AND DIAGNOSIS IS GIVEN WITH RESERVATION.

ADRENALS

*** ADENOMA :
UNILATERAL
THIS IS BENIGN GLANDULAR EPITHELIAL TUMOR.

SEMINAL VESICLES

HEMORRHAGE :
THERE IS EXTRAVASATION OF BLOOD.

COAGULUM :
AN ACIDOPHILIC STRUCTURE RESEMBLING COAGULATED PROTEIN IS

BAYER AG

SEMINAL VESICLES CONTINUED
PRESENT IN THE LUMEN.

MALE 139 (1697/80)

BRAIN

ABSENT :
ORGAN OR TISSUE NOT REMOVED FROM ANIMAL OR NOT FOUND IN FIXATIVE.

HEART

LEUKEMIC DEPOSITS :
ORGAN AND THE BLOOD ARE INVADED BY LEUKEMIC CELLS.

LUNG

LEUKEMIC DEPOSITS :
ORGAN AND THE BLOOD ARE INVADED BY LEUKEMIC CELLS.

STOMACH

AUTOLYSIS PARTIAL :
NO OTHER CHANGES ARE SEEN. TISSUES ARE ALTERED.
BY POST-MORTEM MODIFICATIONS AND
DIAGNOSIS IS GIVEN WITH RESERVATION.

LIVER

AUTOLYSIS PARTIAL :
NO OTHER CHANGES ARE SEEN. TISSUES ARE ALTERED.
BY POST-MORTEM MODIFICATIONS AND
DIAGNOSIS IS GIVEN WITH RESERVATION.

PANCREAS

AUTOLYSIS :
THE TISSUES EXHIBIT AUTOLYSIS AND THEY ARE NOT INTERPRETABLE.

THYMUS

*** LYMPHOMA LYMPHOCYTIC :
THE NEOPLASM OF THE RETICULAR SYSTEM ORIGINATES FROM LYMPHOCYTES.

SPLEEN

AUTOLYSIS PARTIAL :
NO OTHER CHANGES ARE SEEN. TISSUES ARE ALTERED.
BY POST-MORTEM MODIFICATIONS AND
DIAGNOSIS IS GIVEN WITH RESERVATION.

KIDNEYS

AUTOLYSIS PARTIAL :
NO OTHER CHANGES ARE SEEN. TISSUES ARE ALTERED.
BY POST-MORTEM MODIFICATIONS AND
DIAGNOSIS IS GIVEN WITH RESERVATION.

BLADDER

AUTOLYSIS PARTIAL :
NO OTHER CHANGES ARE SEEN. TISSUES ARE ALTERED.
BY POST-MORTEM MODIFICATIONS AND
DIAGNOSIS IS GIVEN WITH RESERVATION.

PITUITARY

ABSENT :
ORGAN OR TISSUE NOT REMOVED FROM ANIMAL OR NOT FOUND IN
FIXATIVE.

THYROIDS

AUTOLYSIS PARTIAL :
NO OTHER CHANGES ARE SEEN. TISSUES ARE ALTERED.
BY POST-MORTEM MODIFICATIONS AND
DIAGNOSIS IS GIVEN WITH RESERVATION.

SCIATIC NERVE

ABSENT :
ORGAN OR TISSUE NOT REMOVED FROM ANIMAL OR NOT FOUND IN
FIXATIVE.

MALE 140 (1739/80)

LUNG

ADENOMATOSIS :
MINIMAL FOCAL
THE PULMONARY ALVEOLI APPEAR GLANDULAR DUE TO METAPLASTIC
TRANSFORMATION OF LINING CELLS INTO CUBOIDAL OR COLUMNAR
CELLS

LIVER

AUTOLYSIS PARTIAL :
NO OTHER CHANGES ARE SEEN. TISSUES ARE ALTERED.
BY POST-MORTEM MODIFICATIONS AND
DIAGNOSIS IS GIVEN WITH RESERVATION.

NORMAL :
HISTOLOGICAL ASPECT WITHIN NORMAL LIMITS.

BAYER AG

NM1.39 MALE 140 CONTINUED

KIDNEYS

CALCIFICATION :
BILATERAL MINIMAL FOCAL
THERE ARE MINERAL DEPOSITS.

INTERSTITIAL NEPHRITIS :
BILATERAL MINIMAL MULTIFOCAL
INFLAMMATORY CELLS FIBROSIS AND SOME TUBULAR ALTERATIONS ARE ASSOCIATED.

PITUITARY

ABSENT :
ORGAN OR TISSUE NOT REMOVED FROM ANIMAL OR NOT FOUND IN FIXATIVE.

THYROIDS

*** ADENOMA :
UNILATERAL
THIS IS BENIGN GLANDULAR EPITHELIAL TUMOR.

MALE 143 (1693/80)

BRAIN

ABSENT :
ORGAN OR TISSUE NOT REMOVED FROM ANIMAL OR NOT FOUND IN FIXATIVE.

LUNG

EDEMA :
SEVERE
THE INTERSTITIAL TISSUES CONTAIN AN INCREASED AMOUNT OF FLUID.

AUTOLYSIS PARTIAL :
NO OTHER CHANGES ARE SEEN. TISSUES ARE ALTERED.
BY POST-MORTEM MODIFICATIONS AND
DIAGNOSIS IS GIVEN WITH RESERVATION.

ECTASIA VASCULAR :
SEVERE
THE LUMEN OF BLOOD VESSELS IS ABNORMALLY ENLARGED.

STOMACH

AUTOLYSIS PARTIAL :
NO OTHER CHANGES ARE SEEN. TISSUES ARE ALTERED.
BY POST-MORTEM MODIFICATIONS AND
DIAGNOSIS IS GIVEN WITH RESERVATION.

LIVER

AUTOLYSIS :
THE TISSUES EXHIBIT AUTOLYSIS AND THEY ARE NOT INTERPRETABLE.

PANCREAS

AUTOLYSIS :
THE TISSUES EXHIBIT AUTOLYSIS AND THEY ARE NOT INTERPRETABLE.

SPLEEN

AUTOLYSIS :
THE TISSUES EXHIBIT AUTOLYSIS AND THEY ARE NOT INTERPRETABLE.

KIDNEYS

AUTOLYSIS PARTIAL :
NO OTHER CHANGES ARE SEEN. TISSUES ARE ALTERED. BY POST-MORTEM MODIFICATIONS AND DIAGNOSIS IS GIVEN WITH RESERVATION.

BLADDER

AUTOLYSIS PARTIAL :
NO OTHER CHANGES ARE SEEN. TISSUES ARE ALTERED. BY POST-MORTEM MODIFICATIONS AND DIAGNOSIS IS GIVEN WITH RESERVATION.

PITUITARY

AUTOLYSIS PARTIAL :
NO OTHER CHANGES ARE SEEN. TISSUES ARE ALTERED. BY POST-MORTEM MODIFICATIONS AND DIAGNOSIS IS GIVEN WITH RESERVATION.

THYROIDS

ABSENT :
ORGAN OR TISSUE NOT REMOVED FROM ANIMAL OR NOT FOUND IN FIXATIVE.

ADRENALS

AUTOLYSIS PARTIAL :
NO OTHER CHANGES ARE SEEN. TISSUES ARE ALTERED. BY POST-MORTEM MODIFICATIONS AND DIAGNOSIS IS GIVEN WITH RESERVATION.

TESTES

AUTOLYSIS :
THE TISSUES EXHIBIT AUTOLYSIS AND THEY ARE NOT INTERPRETABLE.

BAYER AG BAYER AG BAYER AG

MALE 144 (1.99/80)

BRAIN

GLIOSIS :
FOCAL
THERE IS PROLIFERATION OF GLIAL CELLS.

HEART

CONGESTION :
VESSELS OR SINUSOIDS ARE MARKEDLY DISTENDED WITH ERYTHROCYTES.

LUNG

EDEMA :
THE INTERSTITIAL TISSUES CONTAIN AN INCREASED AMOUNT OF FLUID.

PNEUMONIA :
THE ALVEOLAR WALLS ARE THICKENED AND ALVEOLI CONTAIN INFLAMMATORY CELLS AND FOAMY MACROPHAGES.PERIVASCULAR AND PERIBRONCHIAL LYMPHOCYTIC ACCUMULATIONS MAY BE PRESENT.

PANCREAS

AUTOLYSIS PARTIAL :
NO OTHER CHANGES ARE SEEN. TISSUES ARE ALTERED.
BY POST-MORTEM MODIFICATIONS AND
DIAGNOSIS IS GIVEN WITH RESERVATION.

SPLEEN

AUTOLYSIS PARTIAL :
NO OTHER CHANGES ARE SEEN. TISSUES ARE ALTERED.
BY POST-MORTEM MODIFICATIONS AND
DIAGNOSIS IS GIVEN WITH RESERVATION.

KIDNEYS

INTERSTITIAL NEPHRITIS :
BILATERAL MODERATE MULTIFOCAL
INFLAMMATORY CELLS FIBROSIS AND SOME TUBULAR ALTERATIONS ARE ASSOCIATED.

AUTOLYSIS PARTIAL :
NO OTHER CHANGES ARE SEEN. TISSUES ARE ALTERED.
BY POST-MORTEM MODIFICATIONS AND
DIAGNOSIS IS GIVEN WITH RESERVATION.

BLADDER

AUTOLYSIS PARTIAL :
NO OTHER CHANGES ARE SEEN. TISSUES ARE ALTERED.

BLADDER CONTINUED
BY POST-MORTEM MODIFICATIONS AND
DIAGNOSIS IS GIVEN WITH RESERVATION.

THYROIDS

ABSENT :
ORGAN OR TISSUE NOT REMOVED FROM ANIMAL OR NOT FOUND IN
FIXATIVE.

TESTES

CALCIFICATION :
UNILATERAL MINIMAL FOCAL
THERE ARE MINERAL DEPOSITS.

SEMINAL VESICLES

COAGULUM :
AN ACIDOPHILIC STRUCTURE RESEMBLING COAGULATED PROTEIN IS
PRESENT IN THE LUMEN.

MALE 145 (1732/80)

BRAIN

ABSENT :
ORGAN OR TISSUE NOT REMOVED FROM ANIMAL OR NOT FOUND IN
FIXATIVE.

HEART

CONGESTION :
VESSELS OR SINUSOIDS ARE MARKEDLY DISTENDED WITH
ERYTHROCYTES.

LUNG

HEMORRHAGE :
MODERATE
THERE IS EXTRAVASATION OF BLOOD.

CONGESTION :
VESSELS OR SINUSOIDS ARE MARKEDLY DISTENDED WITH
ERYTHROCYTES.

EMPHYSEMA :
MODERATE
THERE IS A EMPHYSEMATOUS CHANGE IN THE ALVEOLAR WALLS.

STOMACH

AUTOLYSIS PARTIAL :
NO OTHER CHANGES ARE SEEN. TISSUES ARE ALTERED.
BY POST-MORTEM MODIFICATIONS AND

BAYER AG

STOMACH CONTINUED
DIAGNOSIS IS GIVEN WITH RESERVATION.

LIVER

AUTOLYSIS PARTIAL :
NO OTHER CHANGES ARE SEEN. TISSUES ARE ALTERED.
BY POST-MORTEM MODIFICATIONS AND
DIAGNOSIS IS GIVEN WITH RESERVATION.

PANCREAS

ABSENT :
ORGAN OR TISSUE NOT REMOVED FROM ANIMAL OR NOT FOUND IN
FIXATIVE.

FATTY CYST :
ACCUMULATION OF FAT CELLS IS PRESENT.

KIDNEYS

PROGRESSIVE NEPHROPATHY :
BILATERAL MINIMAL
AN AGE ASSOCIATED KIDNEY LESION CONSISTING OF CYSTIC TUBULES
WITH COLLOID OR HYALINE CASTS CHRONIC INTERSTITIAL NEPHRITIS
AND DILATATION OF BOWMAN'S CAPSULE WITH GLOMERULAR
DEGENERATION .

BLADDER

AUTOLYSIS PARTIAL :
NO OTHER CHANGES ARE SEEN. TISSUES ARE ALTERED.
BY POST-MORTEM MODIFICATIONS AND
DIAGNOSIS IS GIVEN WITH RESERVATION.

PITUITARY

ABSENT :
ORGAN OR TISSUE NOT REMOVED FROM ANIMAL OR NOT FOUND IN
FIXATIVE.

THYROIDS

ABSENT :
ORGAN OR TISSUE NOT REMOVED FROM ANIMAL OR NOT FOUND IN
FIXATIVE.

MALE 146 (169e/80)

LUNG

EDEMA :
THE INTERSTITIAL TISSUES CONTAIN AN INCREASED AMOUNT OF
FLUID.

CONGESTION :

LUNG CONTINUED

VESSELS OF SINUSOIDS ARE MARKEDLY DISTENDED WITH ERYTHROCYTES.

LIVER

NORMAL :
HISTOLOGICAL ASPECT WITHIN NORMAL LIMITS.

KIDNEYS

AUTOLYSIS PARTIAL :
NO OTHER CHANGES ARE SEEN. TISSUES ARE ALTERED. BY POST-MORTEM MODIFICATIONS AND DIAGNOSIS IS GIVEN WITH RESERVATION.

PITUITARY

ABSENT :
ORGAN OR TISSUE NOT REMOVED FROM ANIMAL OR NOT FOUND IN FIXATIVE.

THYROIDS

ABSENT :
ORGAN OR TISSUE NOT REMOVED FROM ANIMAL OR NOT FOUND IN FIXATIVE.

MALE 147 (1702/80)

LUNG

EDEMA :
THE INTERSTITIAL TISSUES CONTAIN AN INCREASED AMOUNT OF FLUID.

PNEUMONIA :
THE ALVEOLAR WALLS ARE THICKENED AND ALVEOLI CONTAIN INFLAMMATORY CELLS AND FOAMY MACROPHAGES. PERIVASCULAR AND PERIBRONCHIAL LYMPHOCYTIC ACCUMULATIONS MAY BE PRESENT.

*** ALVEOLOGENIC CARCINOMA :
MULTIFOCAL
A MALIGNANT TUMOR OF THE LUNG TISSUE WITH SYNONYMS IN MICE FOR ADENOMA, CARCINOMA, ALVEOLOGENIC PAPILLARY CARCINOMA, PAPILLARY CYSTADENOMA, ADENOCARCINOMA, BRONCHIOLAR CELL CARCINOMA, BRONCHIOLAR-ALVEOLAR TUMOR, TYPE A TUMOR, TYPE B TUMOR, INTERMEDIATE TYPE I TUMOR AND COMMON PULMONARY TUMOR OF THE MOUSE.

SALIVARY GLAND

NORMAL :

BAYER AG

NM1.45 MALE 147 CONTINUED

SALIVARY GLAND CONTINUED
HISTOLOGICAL ASPECT WITHIN NORMAL LIMITS.

STOMACH

NORMAL :
HISTOLOGICAL ASPECT WITHIN NORMAL LIMITS.

PANCREAS

AUTOLYSIS PARTIAL :
NO OTHER CHANGES ARE SEEN. TISSUES ARE ALTERED.
BY POST-MORTEM MODIFICATIONS AND
DIAGNOSIS IS GIVEN WITH RESERVATION.

KIDNEYS

PROGRESSIVE NEPHROPATHY :
BILATERAL MODERATE
AN AGE ASSOCIATED KIDNEY LESION CONSISTING OF CYSTIC TUBULES WITH COLLOID OR HYALINE CASTS CHRONIC INTERSTITIAL NEPHRITIS AND DILATATION OF BOWMAN'S CAPSULE WITH GLOMERULAR DEGENERATION .

BLADDER

NORMAL :
HISTOLOGICAL ASPECT WITHIN NORMAL LIMITS.

THYROIDS

ABSENT :
ORGAN OR TISSUE NOT REMOVED FROM ANIMAL OR NOT FOUND IN FIXATIVE.

FEMUR

ABSENT :
ORGAN OR TISSUE NOT REMOVED FROM ANIMAL OR NOT FOUND IN FIXATIVE.

MALE 150 (1736/80)

BRAIN

ABSENT :
ORGAN OR TISSUE NOT REMOVED FROM ANIMAL OR NOT FOUND IN FIXATIVE.

LUNG

EDEMA :
SEVERE
THE INTERSTITIAL TISSUES CONTAIN AN INCREASED AMOUNT OF FLUID.

AUTOLYSIS PARTIAL :

LUNG CONTINUED

NO OTHER CHANGES ARE SEEN. TISSUES ARE ALTERED.
BY POST-MORTEM MODIFICATIONS AND
DIAGNOSIS IS GIVEN WITH RESERVATION.

SALIVARY GLAND

CALCIFICATION :
MINIMAL MULTIFOCAL
THERE ARE MINERAL DEPOSITS.

STOMACH

AUTOLYSIS PARTIAL :
NO OTHER CHANGES ARE SEEN. TISSUES ARE ALTERED.
BY POST-MORTEM MODIFICATIONS AND
DIAGNOSIS IS GIVEN WITH RESERVATION.

LIVER

AUTOLYSIS :
THE TISSUES EXHIBIT AUTOLYSIS AND THEY ARE NOT
INTERPRETABLE.

PANCREAS

AUTOLYSIS :
THE TISSUES EXHIBIT AUTOLYSIS AND THEY ARE NOT
INTERPRETABLE.

SPLEEN

AUTOLYSIS :
THE TISSUES EXHIBIT AUTOLYSIS AND THEY ARE NOT
INTERPRETABLE.

KIDNEYS

TUBULOPATHY :
BILATERAL MODERATE
TUBULAR DEGENERATIVE CHANGES ARE PRESENT
WHICH MAY BE ASSOCIATED WITH TUBULAR DILATATION.

AUTOLYSIS PARTIAL :
NO OTHER CHANGES ARE SEEN. TISSUES ARE ALTERED.
BY POST-MORTEM MODIFICATIONS AND
DIAGNOSIS IS GIVEN WITH RESERVATION.

DILATATION OF GLOMERULAR LOOPS :
BILATERAL MODERATE
GLOMERULAR LOOPS APPEAR UNUSUALLY ENLARGED AND THIN.

BLADDER

AUTOLYSIS PARTIAL :
NO OTHER CHANGES ARE SEEN. TISSUES ARE ALTERED.
BY POST-MORTEM MODIFICATIONS AND
DIAGNOSIS IS GIVEN WITH RESERVATION.

PITUITARY

ABSENT :

BAYER AG BAYER AG BAYER AG BAYER AG

PITUITARY CONTINUED

ORGAN OR TISSUE NOT REMOVED FROM ANIMAL OR NOT FOUND IN FIXATIVE.

THYROIDS

ABSENT :
ORGAN OR TISSUE NOT REMOVED FROM ANIMAL OR NOT FOUND IN FIXATIVE.

ADRENALS

AUTOLYSIS PARTIAL :
NO OTHER CHANGES ARE SEEN. TISSUES ARE ALTERED.
BY POST-MORTEM MODIFICATIONS AND
DIAGNOSIS IS GIVEN WITH RESERVATION.

SKELETAL MUSCLE

CALCIFICATION :
MINIMAL MULTIFOCAL
THERE ARE MINERAL DEPOSITS.

TESTES

CALCIFICATION :
BILATERAL MINIMAL MULTIFOCAL
THERE ARE MINERAL DEPOSITS.

SM2. 1 CHRONIC TOXICITY STUDY IN MICE: SYSTEMATIC

HISTOPATHOLOGY

PRODUCT : KWG 0519 GROUP : 2
ROUTE : DIETARY
TIME : 105 WEEKS DOSE : 500 PPM
THIS GROUP COMPRISED : 13 MALES

THE FOLLOWING ORGANS WERE EXAMINED SYSTEMATICALLY :

HEART	LUNG	LIVER
PANCREAS	SPLEEN	KIDNEYS
BLADDER	STOMACH	TESTES
THYROIDS	ADRENALS	PITUITARY
BRAIN	SKELETAL MUSCLE	SCIATIC NERVE
FEMUR		

THESE ORGANS WERE EXAMINED IN 13 MALES

INDIVIDUAL RESULTS

IN THE ANIMALS SHOWN BELOW THE HISTOLOGICAL EXAMINATION OF THE ORGANS LISTED OR OF THE ANOMALIES FOUND AT AUTOPSY GAVE THE FOLLOWING RESULTS

MALE 202 (1522/80)

LUNG

ATELECTASIS :
MODERATE MULTIFOCAL
THERE IS COLLAPSE OF ALVEOLI.

STOMACH

MUCOID CYST :
MINIMAL
ONE OR MORE CYSTS CONTAINING MUCOID MATERIAL ARE OBSERVED.

LIVER

HYPERPLASTIC NODULE :
A NODULE OF HYPERPLASTIC TISSUE IS PRESENT.

SPLEEN

HEMATOPOIESIS :
MODERATE
THE HEMATOPOIESIS IS EVIDENT.

BONE MARROW

APLASIA MYELOID :
HEMATOPOIETIC TISSUE IS PARTIALLY OR TOTALLY DISAPPEARED AND IS SUBSTITUTED BY CONNECTIVE OR FATTY TISSUE OR EDEMA.

BAYER AG

SM2. 2 MALE 202 CONTINUED

KIDNEYS

TUBULOPATHY :
BILATERAL MINIMAL
TUBULAR DEGENERATIVE CHANGES ARE PRESENT WHICH MAY BE ASSOCIATED WITH TUBULAR DILATATION.

BLADDER

HYPERPLASIA PAPILLOMATOUS :
THE THICKNESS OF THE MUCOSA IS INCREASED MAKING UNUSUALLY HIGH AND NUMEROUS FOLDS.

TESTES

*** INTERSTITIAL CELL TUMOR :
BILATERAL
THIS BENIGN TUMOR IS COMPOSED OF LARGE EPITHELIAL CELLS WITH ABUNDANT ACIDOPHILIC CYTOPLASM.

MALE 205 (1523/80)

LUNG

THICKENED ALVEOLAR WALLS :
MULTIFOCAL
THICKNESS OF ALVEOLAR WALLS IS INCREASED BY INFLAMMATORY CELLS AND/OR INTERSTITIAL EDEMA.

STOMACH

MUCOID CYST :
MODERATE
ONE OR MORE CYSTS CONTAINING MUCOID MATERIAL ARE OBSERVED.

LIVER

FAT VACUOLES :
MINIMAL MULTIFOCAL
THE CELLS ARE DISTENDED BY CLEAR CYTOPLASMIC VACUOLES WHICH FREQUENTLY DISPLACE THE NUCLEI.

PANCREAS

ABSENT :
ORGAN OR TISSUE NOT REMOVED FROM ANIMAL OR NOT FOUND IN FIXATIVE.

SPLEEN

HEMATOPOIESIS :
MINIMAL
THE HEMATOPOIESIS IS EVIDENT.

KIDNEYS

INTERSTITIAL NEPHRITIS :
BILATERAL MINIMAL MULTIFOCAL
INFLAMMATORY CELLS FIBROSIS AND SOME TUBULAR ALTERATIONS ARE ASSOCIATED.

CYSTS :
BILATERAL MINIMAL MULTIFOCAL
ONE OR MORE CYSTS FILLED WITH CLEAR LIQUID ARE SEEN.

BLADDER

INFLAMMATION GRANULOMATOUS :
MULTIFOCAL
THERE IS A FOCAL GRANULOMATOUS PROCESS CHARACTERIZED BY MONONUCLEAR AND MULTINUCLEATED CELLULAR INFILTRATION.

THYROIDS

ABSENT :
ORGAN OR TISSUE NOT REMOVED FROM ANIMAL OR NOT FOUND IN FIXATIVE.

MALE 206 (1524/80)

BRAIN

FAT VACUOLES :
MINIMAL MULTIFOCAL
THE CELLS ARE DISTENDED BY CLEAR CYTOPLASMIC VACUOLES WHICH FREQUENTLY DISPLACE THE NUCLEI.

GLIOSIS :
FOCAL
THERE IS PROLIFERATION OF GLIAL CELLS.

HEART

LEUKEMIC DEPOSITS :
MINIMAL
ORGAN AND THE BLOOD ARE INVADED BY LEUKEMIC CELLS.

LUNG

LEUKEMIC DEPOSITS :
MINIMAL
ORGAN AND THE BLOOD ARE INVADED BY LEUKEMIC CELLS.

STOMACH

MUCOID CYST :
MULTIFOCAL

BAYER AG

STOMACH CONTINUED
ONE OR MORE CYSTS CONTAINING MUCOID MATERIAL ARE OBSERVED.

LIVER

NORMAL :
HISTOLOGICAL ASPECT WITHIN NORMAL LIMITS.

PANCREAS

LEUKEMIC DEPOSITS :
ORGAN AND THE BLOOD ARE INVADED BY LEUKEMIC CELLS.

SPLEEN

HYPERPLASIA LYMPHOID :
FOCAL
THE LYMPHOID FOLLICLES ARE INCREASED IN SIZE.

HEMATOPOIESIS :
SEVERE
THE HEMATOPOIESIS IS EVIDENT.

HYPERTROPHY :
SEVERE
THE SIZE OF THE ORGAN IS INCREASED WITHOUT STRUCTURAL ANOMALY.

KIDNEYS

LEUKEMIC DEPOSITS :
ORGAN AND THE BLOOD ARE INVADED BY LEUKEMIC CELLS.

THYROIDS

NORMAL :
HISTOLOGICAL ASPECT WITHIN NORMAL LIMITS.

ADRENALS

NORMAL :
HISTOLOGICAL ASPECT WITHIN NORMAL LIMITS.

SKELETAL MUSCLE

LEUKEMIC DEPOSITS :
ORGAN AND THE BLOOD ARE INVADED BY LEUKEMIC CELLS.

MESENTERY

LEUKEMIC DEPOSITS :
ORGAN AND THE BLOOD ARE INVADED BY LEUKEMIC CELLS.

TESTES

ATROPHY SEMINIFEROUS :
UNILATERAL
THERE IS ATROPHY OF SEMINIFEROUS TUBULES WITH DIMINISHED

TESTES CONTINUED

SPERMATOGENIC ACTIVITY.

AZOOSPERMIA :
UNILATERAL
NO SPERMATOGENESIS IS OBSERVED.THIS CONDITION MAY HAVE VARIOUS ORIGINS.

INTESTINE

NORMAL :
HISTOLOGICAL ASPECT WITHIN NORMAL LIMITS.

LYMPH NODE

*** LYMPHOMA LYMPHOCYTIC :
THE NEOPLASM OF THE RETICULAR SYSTEM ORIGINATES FROM LYMPHOCYTES.

MALE 215 (1525/60)

BRAIN

CALCIFICATION :
UNILATERAL MODERATE FOCAL
THERE ARE MINERAL DEPOSITS.

HEART

DEGENERATION MUSCULAR :
FOCAL
A NUMBER OF MORPHOLOGICALLY ALTERED MUSCULAR FIBERS SOMETIMES REPLACED BY INTERSTITIAL LIPOCYTES AND/OR FIBROSIS.

LUNG

PNEUMONIA :
MINIMAL
THE ALVEOLAR WALLS ARE THICKENED AND ALVEOLI CONTAIN INFLAMMATORY CELLS AND FOAMY MACROPHAGES.PERIVASCULAR AND PERIBRONCHIAL LYMPHOCYTIC ACCUMULATIONS MAY BE PRESENT.

LIVER

INFARCT :
SEVERE
AN AREA OF ISCHEMIC NECROSIS DUE TO VASCULAR OCCLUSION IS PRESENT.

FAT VACUOLES :
SEVERE
THE CELLS ARE DISTENDED BY CLEAR CYTOPLASMIC VACUOLES WHICH FREQUENTLY DISPLACE THE NUCLEI.

*** ADENOMA HEPATIC BENIGN :

BAYER AG

LIVER CONTINUED

DISTINCT VACUOLES COMPRESS THE ADJACENT LIVER PARENCHYMA, ARE CHARACTERIZED BY WELL DIFFERENTIATED HEPATOCYTES AND DO NOT SHOW PORTAL TRIADS.

SPLEEN

HEMATOPOIESIS :
SEVERE
THE HEMATOPOIESIS IS EVIDENT.

KIDNEYS

DILATATION OF RENAL PELVIS :
UNILATERAL
THE RENAL CAVITIES ARE MORE OR LESS ENLARGED.

SCIATIC NERVE

ABSENT :
ORGAN OR TISSUE NOT REMOVED FROM ANIMAL OR NOT FOUND IN FIXATIVE.

SEMINAL VESICLES

HEMORRAGIC CYST :
ONE OR SEVERAL CAVITIES FILLED WITH BLOOD.

MALE 217 (1525/80)

LUNG

PNEUMONIA :
THE ALVEOLAR WALLS ARE THICKENED AND ALVEOLI CONTAIN INFLAMMATORY CELLS AND FOAMY MACROPHAGES.PERIVASCULAR AND PERIBRONCHIAL LYMPHOCYTIC ACCUMULATIONS MAY BE PRESENT.

*** ALVEOLOGENIC CARCINOMA :
A MALIGNANT TUMOR OF THE LUNG TISSUE WITH SYNONYMS IN MICE FOR ADENOMA, CARCINOMA, ALVEOLOGENIC PAPILLARY CARCINOMA, PAPILLARY CYSTADENOMA, ADENOCARCINOMA, BRONCHIOLAR CELL CARCINOMA, BRONCHIOLAR-ALVEOLAR TUMOR, TYPE A TUMOR, TYPE B TUMOR, INTERMEDIATE TYPE I TUMOR AND COMMON PULMONARY TUMOR OF THE MOUSE.

LIVER

VACUOLIZATION :
MINIMAL MULTIFOCAL
IN THESE CELLS THERE ARE CLEAR VACUOLES GREATER IN NUMBER AND SIZE THAN NORMALLY FOUND.

KIDNEYS

TUBULOPATHY :
UNILATERAL MINIMAL MULTIFOCAL
TUBULAR DEGENERATIVE CHANGES ARE PRESENT WHICH MAY BE ASSOCIATED WITH TUBULAR DILATATION.

ADRENALS

PIGMENTATION :
UNILATERAL MINIMAL
NUMEROUS MACROPHAGES CONTAIN A GRANULAR BROWN CYTOPLASMIC PIGMENT.

TESTES

ATROPHY SEMINIFEROUS :
BILATERAL MODERATE MULTIFOCAL
THERE IS ATROPHY OF SEMINIFEROUS TUBULES WITH DIMINISHED SPERMATOGENIC ACTIVITY.

MALE 218 (1527/80)

LUNG

*** ALVEOLOGENIC CARCINOMA :
A MALIGNANT TUMOR OF THE LUNG TISSUE WITH SYNONYMS IN USE FOR ADENOMA, CARCINOMA, ALVEOLOGENIC PAPILLARY CARCINOMA, PAPILLARY CYSTADENOMA, ADENOCARCINOMA, BRONCHIOLAR CELL CARCINOMA, BRONCHIOLAR-ALVEOLAR TUMOR, TYPE A TUMOR, TYPE B TUMOR, INTERMEDIATE TYPE I TUMOR AND COMMON PULMONARY TUMOR OF THE MOUSE.

STOMACH

MUCOID CYST :
MINIMAL
ONE OR MORE CYSTS CONTAINING MUCOID MATERIAL ARE OBSERVED.

LIVER

FAT VACUOLES :
MODERATE
THE CELLS ARE DISTENDED BY CLEAR CYTOPLASMIC VACUOLES WHICH FREQUENTLY DISPLACE THE NUCLEI.

HYPERPLASTIC NODULE :
A NODULE OF HYPERPLASTIC TISSUE IS PRESENT.

SPLEEN

HEMATOPOIESIS :
MODERATE

BAYER AG

SPLEEN CONTINUED

THE HEMATOPOIESIS IS EVIDENT.

KIDNEYS

TUBULOPATHY :
BILATERAL MINIMAL
TUBULAR DEGENERATIVE CHANGES ARE PRESENT WHICH MAY BE ASSOCIATED WITH TUBULAR DILATATION.

BLADDER

INFLAMMATION GRANULOMATOUS :
MULTIFOCAL
THERE IS A FOCAL GRANULOMATOUS PROCESS CHARACTERIZED BY MONONUCLEAR AND MULTINUCLEATED CELLULAR INFILTRATION.

THYROIDS

ABSENT :
ORGAN OR TISSUE NOT REMOVED FROM ANIMAL OR NOT FOUND IN FIXATIVE.

TESTES

ABSENT :
ORGAN OR TISSUE NOT REMOVED FROM ANIMAL OR NOT FOUND IN FIXATIVE.

FEMUR

*** OSTEOMA :
THIS BENIGN WELL CIRCUMSCRIBED TUMOR IS COMPOSED OF WELL-DEVELOPED BONE.

MALE 21y (1525/80)

LUNG

PNEUMONIA :
THE ALVEOLAR WALLS ARE THICKENED AND ALVEOLI CONTAIN INFLAMMATORY CELLS AND FOAMY MACROPHAGES. PERIVASCULAR AND PERIBRONCHIAL LYMPHOCYTIC ACCUMULATIONS MAY BE PRESENT.

EMPHYSEMA :
MULTIFOCAL
THERE IS A EMPHYSEMATOUS CHANGE IN THE ALVEOLAR WALLS.

STOMACH

MUCOID CYST :
MINIMAL
ONE OR MORE CYSTS CONTAINING MUCOID MATERIAL ARE OBSERVED.

LIVER

HYPERPLASTIC NODULE :
A NODULE OF HYPERPLASTIC TISSUE IS PRESENT.

HYPERTROPHY :
THE SIZE OF THE ORGAN IS INCREASED WITHOUT STRUCTURAL ANOMALY.

KIDNEYS

CALCIFICATION :
BILATERAL MULTIFOCAL
THERE ARE MINERAL DEPOSITS.

TESTES

ATROPHY SEMINIFEROUS :
UNILATERAL MODERATE MULTIFOCAL
THERE IS ATROPHY OF SEMINIFEROUS TUBULES WITH DIMINISHED SPERMATOGENIC ACTIVITY.

MALE 226 (1529/80)

LUNG

THICKENED ALVEOLAR WALLS :
MULTIFOCAL
THICKNESS OF ALVEOLAR WALLS IS INCREASED BY INFLAMMATORY CELLS AND/OR INTERSTITIAL EDEMA.

LIVER

*** ADENOMA HEPATIC BENIGN :
DISTINCT NODULES COMPRESS THE ADJACENT LIVER PARENCHYMA, ARE CHARACTERIZED BY WELL DIFFERENTIATED HEPATOCYTES AND DO NOT SHOW PORTAL TRIADS.

SPLEEN

HEMATOPOIESIS :
MODERATE
THE HEMATOPOIESIS IS EVIDENT.

KIDNEYS

INTERSTITIAL NEPHRITIS :
BILATERAL MINIMAL MULTIFOCAL
INFLAMMATORY CELLS FIBROSIS AND SOME TUBULAR ALTERATIONS ARE ASSOCIATED.

PITUITARY

NORMAL :
HISTOLOGICAL ASPECT WITHIN NORMAL LIMITS.

BAYER AG

MALE 225 (1536/80)

STOMACH

MUCOID CYST :
MINIMAL
ONE OR MORE CYSTS CONTAINING MUCOID MATERIAL ARE OBSERVED.

SPLEEN

HEMATOPOIESIS :
MINIMAL
THE HEMATOPOIESIS IS EVIDENT.

KIDNEYS

TUBULOPATHY :
UNILATERAL MINIMAL MULTIFOCAL
TUBULAR DEGENERATIVE CHANGES ARE PRESENT
WHICH MAY BE ASSOCIATED WITH TUBULAR DILATATION.

INTERSTITIAL NEPHRITIS :
CONTRALATERAL MINIMAL MULTIFOCAL
INFLAMMATORY CELLS FIBROSIS AND SOME TUBULAR ALTERATIONS
ARE ASSOCIATED.

MALE 230 (1531/80)

LUNG

PNEUMONIA :
THE ALVEOLAR WALLS ARE THICKENED AND ALVEOLI CONTAIN
INFLAMMATORY CELLS AND FOAMY MACROPHAGES.PERIVASCULAR AND
PERIBRONCHIAL LYMPHOCYTIC ACCUMULATIONS MAY BE PRESENT.

PANCREAS

NORMAL :
HISTOLOGICAL ASPECT WITHIN NORMAL LIMITS.

SPLEEN

HEMATOPOIESIS :
MODERATE
THE HEMATOPOIESIS IS EVIDENT.

KIDNEYS

CYSTS :
UNILATERAL FOCAL
ONE OR MORE CYSTS FILLED WITH CLEAR LIQUID ARE SEEN.

PITUITARY

ABSENT :
ORGAN OR TISSUE NOT REMOVED FROM ANIMAL OR NOT FOUND IN FIXATIVE.

THYROIDS

ABSENT :
ORGAN OR TISSUE NOT REMOVED FROM ANIMAL OR NOT FOUND IN FIXATIVE.

ADRENALS

PIGMENTATION :
CONTRALATERAL MODERATE
NUMEROUS MACROPHAGES CONTAIN A GRANULAR BROWN CYTOPLASMIC PIGMENT.

*** ADENOMA :
UNILATERAL
THIS IS BENIGN GLANDULAR EPITHELIAL TUMOR.

MALE 233 (1532/60)

LUNG

PNEUMONIA :
SEVERE
THE ALVEOLAR WALLS ARE THICKENED AND ALVEOLI CONTAIN INFLAMMATORY CELLS AND FOAMY MACROPHAGES.PERIVASCULAR AND PERIBRONCHIAL LYMPHOCYTIC ACCUMULATIONS MAY BE PRESENT.

STOMACH

INFLAMMATION CHRONIC :
MODERATE MULTIFOCAL
THERE IS AN INFILTRATION BY MONONUCLEAR CELLS IN THE MUCOSA AND SUBMUCOSA.

PANCREAS

*** ISLET CELL ADENOMA :
THIS IS A BENIGN GLANDULAR TUMOR ARISING FROM THE ISLET CELLS.

KIDNEYS

INTERSTITIAL NEPHRITIS :
BILATERAL MODERATE MULTIFOCAL

BAYER AG

KIDNEYS CONTINUED

INFLAMMATORY CELLS FIBROSIS AND SOME TUBULAR ALTERATIONS ARE ASSOCIATED.

PITUITARY

ABSENT :
ORGAN OR TISSUE NOT REMOVED FROM ANIMAL OR NOT FOUND IN FIXATIVE.

MALE 239 (1533/80)

LUNG

PNEUMONIA :
MODERATE
THE ALVEOLAR WALLS ARE THICKENED AND ALVEOLI CONTAIN INFLAMMATORY CELLS AND FOAMY MACROPHAGES.PERIVASCULAR AND PERIBRONCHIAL LYMPHOCYTIC ACCUMULATIONS MAY BE PRESENT.

STOMACH

INFLAMMATION CHRONIC :
MINIMAL FOCAL
THERE IS AN INFILTRATION BY MONONUCLEAR CELLS IN THE MUCOSA AND SUBMUCOSA.

PANCREAS

NORMAL :
HISTOLOGICAL ASPECT WITHIN NORMAL LIMITS.

PITUITARY

ABSENT :
ORGAN OR TISSUE NOT REMOVED FROM ANIMAL OR NOT FOUND IN FIXATIVE.

ADRENALS

*** ADENOMA :
UNILATERAL
THIS IS BENIGN GLANDULAR EPITHELIAL TUMOR.

SCIATIC NERVE

ABSENT :
ORGAN OR TISSUE NOT REMOVED FROM ANIMAL OR NOT FOUND IN FIXATIVE.

TESTES

ATROPHY SEMINIFEROUS :
UNILATERAL MODERATE
THERE IS ATROPHY OF SEMINIFEROUS TUBULES WITH DIMINISHED

TESTES CONTINUED

SPERMATOGENIC ACTIVITY.

MALE 244 (1534/00)

LUNG

PNEUMONIA :
THE ALVEOLAR WALLS ARE THICKENED AND ALVEOLI CONTAIN INFLAMMATORY CELLS AND FOAMY MACROPHAGES. PERIVASCULAR AND PERIBRONCHIAL LYMPHOCYTIC ACCUMULATIONS MAY BE PRESENT.

*** ALVEOLOGENIC CARCINOMA :
A MALIGNANT TUMOR OF THE LUNG TISSUE WITH SYNONYMS IN MICE FOR ADENOMA, CARCINOMA, ALVEOLOGENIC PAPILLARY CARCINOMA, PAPILLARY CYSTADENOMA, ADENOCARCINOMA, BRONCHIOLAR CELL CARCINOMA, BRONCHIOLAR-ALVEOLAR TUMOR, TYPE A TUMOR, TYPE B TUMOR, INTERMEDIATE TYPE I TUMOR AND COMMON PULMONARY TUMOR OF THE MOUSE.

KIDNEYS

INTERSTITIAL NEPHRITIS :
BILATERAL MODERATE MULTIFOCAL
INFLAMMATORY CELLS FIBROSIS AND SOME TUBULAR ALTERATIONS ARE ASSOCIATED.

CYSTS :
UNILATERAL MULTIFOCAL
ONE OR MORE CYSTS FILLED WITH CLEAR LIQUID ARE SEEN.

SCIATIC NERVE

ABSENT :
ORGAN OR TISSUE NOT REMOVED FROM ANIMAL OR NOT FOUND IN FIXATIVE.

TESTES

ATROPHY SEMINIFEROUS :
BILATERAL MODERATE MULTIFOCAL
THERE IS ATROPHY OF SEMINIFEROUS TUBULES WITH DIMINISHED SPERMATOGENIC ACTIVITY.

CALCIFICATION :
BILATERAL MODERATE MULTIFOCAL
THERE ARE MINERAL DEPOSITS.

EPIDIDYMIS

ABSENT :
ORGAN OR TISSUE NOT REMOVED FROM ANIMAL OR NOT FOUND IN FIXATIVE.

BAYER AG

NM2. 1 CHRONIC TOXICITY STUDY IN MICE: NONSYSTEMATIC

HISTOPATHOLOGY

PRODUCT : CHG 0519 GROUP : 2
ROUTE : DIETARY
TIME : 105 WEEKS DOSE : 500 PPM
THIS GROUP COMPRISED : 36 MALES

THE FOLLOWING ORGANS WERE EXAMINED SYSTEMATICALLY :

HEART	LUNG	LIVER
PANCREAS	SPLEEN	KIDNEYS
BLADDER	STOMACH	TESTES
THYROIDS	ADRENALS	PITUITARY
BRAIN	SKELETAL MUSCLE	SCIATIC NERVE
FEMUR		

THESE ORGANS WERE EXAMINED IN 36 MALES

INDIVIDUAL RESULTS

IN THE ANIMALS SHOWN BELOW THE HISTOLOGICAL EXAMINATION OF THE ORGANS LISTED OR OF THE ANOMALIES FOUND AT AUTOPSY GAVE THE FOLLOWING RESULTS :

MALE 201 (1779/80)

LUNG

*** ALVEOLOGENIC CARCINOMA :
MULTIFOCAL
A MALIGNANT TUMOR OF THE LUNG TISSUE WITH SYNONYMS IN MICE FOR ADENOMA, CARCINOMA, ALVEOLOGENIC PAPILLARY CARCINOMA, PAPILLARY CYSTADENOMA, ADENOCARCINOMA, BRONCHIOLAR CELL CARCINOMA, BRONCHIOLAR-ALVEOLAR TUMOR, TYPE A TUMOR, TYPE B TUMOR, INTERMEDIATE TYPE I TUMOR AND COMMON PULMONARY TUMOR OF THE MOUSE.

LIVER

*** ADENOMA HEPATIC BENIGN :
DISTINCT NODULES COMPRESS THE ADJACENT LIVER PARENCHYMA, ARE CHARACTERIZED BY WELL DIFFERENTIATED HEPATOCYTES AND DO NOT SHOW PORTAL TRIADS.

SPLEEN

CONGESTION :
VESSELS OR SINUSOIDS ARE MARKEDLY DISTENDED WITH ERYTHROCYTES.

KIDNEYS

TUBULOPATHY :
BILATERAL MODERATE

KIDNEYS CONTINUED

TUBULAR DEGENERATIVE CHANGES ARE PRESENT WHICH MAY BE ASSOCIATED WITH TUBULAR DILATATION.

TESTES

*** INTERSTITIAL CELL TUMOR :
UNILATERAL
THIS BENIGN TUMOR IS COMPOSED OF LARGE EPITHELIAL CELLS WITH ABUNDANT ACIDOPHILIC CYTOPLASM.

FEMUR

UNREADABLE :
IT IS NOT POSSIBLE TO INTERPRET THE SECTION DUE TO AN ARTIFACT CAUSED BY SAMPLING OR HISTOLOGICAL TECHNIQUE.

MALE 203 (177a/80)

HEART

CONGESTION :
VESSELS OR SINUSOIDS ARE MARKEDLY DISTENDED WITH ERYTHROCYTES.

LUNG

*** ALVEOLOGENIC CARCINOMA :
MULTIFOCAL
A MALIGNANT TUMOR OF THE LUNG TISSUE WITH SYNONYMS IN MICE FOR ADENOMA, CARCINOMA, ALVEOLOGENIC PAPILLARY CARCINOMA, PAPILLARY CYSTADENOMA, ADENOCARCINOMA, BRONCHIOLAR CELL CARCINOMA, BRONCHIOLAR-ALVEOLAR TUMOR, TYPE A TUMOR, TYPE B TUMOR, INTERMEDIATE TYPE I TUMOR AND COMMON PULMONARY TUMOR OF THE MOUSE.

CONGESTION :
VESSELS OR SINUSOIDS ARE MARKEDLY DISTENDED WITH ERYTHROCYTES.

LIVER

AUTOLYSIS PARTIAL :
NO OTHER CHANGES ARE SEEN. TISSUES ARE ALTERED BY POST-MORTEM MODIFICATIONS AND DIAGNOSIS IS GIVEN WITH RESERVATION.

SPLEEN

HYPERPLASIA LYMPHOID :
THE LYMPHOID FOLLICLES ARE INCREASED IN SIZE.

BAYER AG

KIDNEYS

TUBULOPATHY :
BILATERAL MINIMAL MULTIFOCAL
TUBULAR DEGENERATIVE CHANGES ARE PRESENT WHICH MAY BE ASSOCIATED WITH TUBULAR DILATATION.

BLADDER

INFLAMMATION CHRONIC :
MODERATE MULTIFOCAL
THERE IS AN INFILTRATION BY MUNONUCLEAR CELLS IN THE MUCOSA AND SUBMUCOSA.

ADRENALS

PIGMENTATION :
BILATERAL MINIMAL
NUMEROUS MACROPHAGES CONTAIN A GRANULAR BROWN CYTOPLASMIC PIGMENT.

TESTES

CALCIFICATION :
UNILATERAL MINIMAL FOCAL
THERE ARE MINERAL DEPOSITS.

MALE 204 (176a/60)

LUNG

PNEUMONIA :
THE ALVEOLAR WALLS ARE THICKENED AND ALVEOLI CONTAIN INFLAMMATORY CELLS AND FOAMY MACROPHAGES.PERIVASCULAR AND PERIBRONCHIAL LYMPHOCYTIC ACCUMULATIONS MAY BE PRESENT.

LIVER

LEUKEMIC DEPOSITS :
ORGAN AND THE BLOOD ARE INVADED BY LEUKEMIC CELLS.

SPLEEN

*** LYMPHOMA LYMPHOCYTIC :
THE NEOPLASM OF THE RETICULAR SYSTEM ORIGINATES FROM LYMPHOCYTES.

KIDNEYS

TUBULOPATHY :
BILATERAL MINIMAL
TUBULAR DEGENERATIVE CHANGES ARE PRESENT WHICH MAY BE ASSOCIATED WITH TUBULAR DILATATION.

PITUITARY

ABSENT :
ORGAN OR TISSUE NOT REMOVED FROM ANIMAL OR NOT FOUND IN FIXATIVE.

ADRENALS

ABSENT :
ORGAN OR TISSUE NOT REMOVED FROM ANIMAL OR NOT FOUND IN FIXATIVE.

BONE

*** OSTEOMA :
THIS BENIGN WELL CIRCUMSCRIBED TUMOR IS COMPOSED OF WELL-DEVELOPED BONE.

MALE 207 (1753/80)

BRAIN

ABSENT :
ORGAN OR TISSUE NOT REMOVED FROM ANIMAL OR NOT FOUND IN FIXATIVE.

LUNG

EDEMA :
THE INTERSTITIAL TISSUES CONTAIN AN INCREASED AMOUNT OF FLUID.

EMPHYSEMA :
THERE IS A EMPHYSEMATOUS CHANGE IN THE ALVEOLAR WALLS.

AUTOLYSIS PARTIAL :
NO OTHER CHANGES ARE SEEN. TISSUES ARE ALTERED.
BY POST-MORTEM MODIFICATIONS AND
DIAGNOSIS IS GIVEN WITH RESERVATION.

STOMACH

AUTOLYSIS PARTIAL :
NO OTHER CHANGES ARE SEEN. TISSUES ARE ALTERED.
BY POST-MORTEM MODIFICATIONS AND
DIAGNOSIS IS GIVEN WITH RESERVATION.

PANCREAS

ABSENT :
ORGAN OR TISSUE NOT REMOVED FROM ANIMAL OR NOT FOUND IN FIXATIVE.

BAYER AG

SPLEEN

AUTOLYSIS :
THE TISSUES EXHIBIT AUTOLYSIS AND THEY ARE NOT INTERPRETABLE.

KIDNEYS

AUTOLYSIS PARTIAL :
NO OTHER CHANGES ARE SEEN. TISSUES ARE ALTERED.
BY POST-MORTEM MODIFICATIONS AND
DIAGNOSIS IS GIVEN WITH RESERVATION.

BLADDER

AUTOLYSIS :
THE TISSUES EXHIBIT AUTOLYSIS AND THEY ARE NOT INTERPRETABLE.

PITUITARY

ABSENT :
ORGAN OR TISSUE NOT REMOVED FROM ANIMAL OR NOT FOUND IN FIXATIVE.

THYROIDS

ABSENT :
ORGAN OR TISSUE NOT REMOVED FROM ANIMAL OR NOT FOUND IN FIXATIVE.

ADRENALS

AUTOLYSIS PARTIAL :
NO OTHER CHANGES ARE SEEN. TISSUES ARE ALTERED.
BY POST-MORTEM MODIFICATIONS AND
DIAGNOSIS IS GIVEN WITH RESERVATION.

SKELETAL MUSCLE

FATTY CYST :
ACCUMULATION OF FAT CELLS IS PRESENT.

TESTES

AUTOLYSIS PARTIAL :
NO OTHER CHANGES ARE SEEN. TISSUES ARE ALTERED.
BY POST-MORTEM MODIFICATIONS AND
DIAGNOSIS IS GIVEN WITH RESERVATION.

MALE 208 (1771/80)

BRAIN

FAT VACUOLES :
MODERATE MULTIFOCAL

LM2. 6 MALE 208 CONTINUED

BRAIN CONTINUED

THE CELLS ARE DISTENDED BY CLEAR CYTOPLASMIC VACUOLES WHICH FREQUENTLY DISPLACE THE NUCLEI.

HEART

CONGESTION :
VESSELS OR SINUSOIDS ARE MARKEDLY DISTENDED WITH ERYTHROCYTES.

LUNG

PNEUMONIA :
SEVERE
THE ALVEOLAR WALLS ARE THICKENED AND ALVEOLI CONTAIN INFLAMMATORY CELLS AND FOAMY MACROPHAGES. PERIVASCULAR AND PERIBRONCHIAL LYMPHOCYTIC ACCUMULATIONS MAY BE PRESENT.

CONGESTION :
SEVERE
VESSELS OR SINUSOIDS ARE MARKEDLY DISTENDED WITH ERYTHROCYTES.

STOMACH

AUTOLYSIS PARTIAL :
NO OTHER CHANGES ARE SEEN. TISSUES ARE ALTERED. BY POST-MORTEM MODIFICATIONS AND DIAGNOSIS IS GIVEN WITH RESERVATION.

LIVER

CALCIFICATION :
MODERATE MULTIFOCAL
THERE ARE MINERAL DEPOSITS.

*** ADENOMA HEPATIC BENIGN :
DISTINCT NODULES COMPRESS THE ADJACENT LIVER PARENCHYMA, ARE CHARACTERIZED BY WELL DIFFERENTIATED HEPATOCYTES AND DO NOT SHOW PORTAL TRIADS.

HEMORRHAGE :
MODERATE FOCAL
THERE IS EXTRAVASATION OF BLOOD.

AUTOLYSIS PARTIAL :
NO OTHER CHANGES ARE SEEN. TISSUES ARE ALTERED. BY POST-MORTEM MODIFICATIONS AND DIAGNOSIS IS GIVEN WITH RESERVATION.

PANCREAS

AUTOLYSIS :
THE TISSUES EXHIBIT AUTOLYSIS AND THEY ARE NOT INTERPRETABLE.

SPLEEN

HEMATOPOIESIS :
MODERATE
THE HEMATOPOIESIS IS EVIDENT.

AUTOLYSIS PARTIAL :

BAYER AG

SPLEEN CONTINUED
NO OTHER CHANGES ARE SEEN. TISSUES ARE ALTERED.
BY POST-MORTEM MODIFICATIONS AND
DIAGNOSIS IS GIVEN WITH RESERVATION.

KIDNEYS

CONGESTION :
BILATERAL
VESSELS OR SINUSOIDS ARE MARKEDLY DISTENDED WITH
ERYTHROCYTES.

INTERSTITIAL NEPHRITIS :
BILATERAL MINIMAL
INFLAMMATORY CELLS FIBROSIS AND SOME TUBULAR ALTERATIONS
ARE ASSOCIATED.

AUTOLYSIS PARTIAL :
BILATERAL
NO OTHER CHANGES ARE SEEN. TISSUES ARE ALTERED.
BY POST-MORTEM MODIFICATIONS AND
DIAGNOSIS IS GIVEN WITH RESERVATION.

THYROIDS

ABSENT :
ORGAN OR TISSUE NOT REMOVED FROM ANIMAL OR NOT FOUND IN
FIXATIVE.

ADRENALS

HEMORRAGIC CYST :
UNILATERAL FOCAL
ONE OR SEVERAL CAVITIES FILLED WITH BLOOD.

MALE 209 (1755/80)

HEART

CONGESTION :
VESSELS OR SINUSOIDS ARE MARKEDLY DISTENDED WITH
ERYTHROCYTES.

LUNG

PNEUMONIA :
THE ALVEOLAR WALLS ARE THICKENED AND ALVEOLI CONTAIN
INFLAMMATORY CELLS AND FOAMY MACROPHAGES.PERIVASCULAR AND
PERIBRONCHIAL LYMPHOCYTIC ACCUMULATIONS MAY BE PRESENT.

CONGESTION :
VESSELS OR SINUSOIDS ARE MARKEDLY DISTENDED WITH
ERYTHROCYTES.

STOMACH

AUTOLYSIS PARTIAL :
NO OTHER CHANGES ARE SEEN. TISSUES ARE ALTERED.
BY POST-MORTEM MODIFICATIONS AND
DIAGNOSIS IS GIVEN WITH RESERVATION.

LIVER

AUTOLYSIS PARTIAL :
NO OTHER CHANGES ARE SEEN. TISSUES ARE ALTERED.
BY POST-MORTEM MODIFICATIONS AND
DIAGNOSIS IS GIVEN WITH RESERVATION.

HEMORRAGIC CYST :
MODERATE MULTIFOCAL
ONE OR SEVERAL CAVITIES FILLED WITH BLOOD.

PANCREAS

AUTOLYSIS :
THE TISSUES EXHIBIT AUTOLYSIS AND THEY ARE NOT
INTERPRETABLE.

SPLEEN

AUTOLYSIS :
THE TISSUES EXHIBIT AUTOLYSIS AND THEY ARE NOT
INTERPRETABLE.

KIDNEYS

AUTOLYSIS PARTIAL :
NO OTHER CHANGES ARE SEEN. TISSUES ARE ALTERED.
BY POST-MORTEM MODIFICATIONS AND
DIAGNOSIS IS GIVEN WITH RESERVATION.

BLADDER

AUTOLYSIS PARTIAL :
NO OTHER CHANGES ARE SEEN. TISSUES ARE ALTERED.
BY POST-MORTEM MODIFICATIONS AND
DIAGNOSIS IS GIVEN WITH RESERVATION.

NORMAL :
HISTOLOGICAL ASPECT WITHIN NORMAL LIMITS.

THYROIDS

AUTOLYSIS PARTIAL :
NO OTHER CHANGES ARE SEEN. TISSUES ARE ALTERED.
BY POST-MORTEM MODIFICATIONS AND
DIAGNOSIS IS GIVEN WITH RESERVATION.

SCIATIC NERVE

ABSENT :
ORGAN OR TISSUE NOT REMOVED FROM ANIMAL OR NOT FOUND IN
FIXATIVE.

BAYER AG BAYER AG BAYER AG

MALE 210 (1762/80)

BRAIN

FAT VACUOLES :
MINIMAL FOCAL
THE CELLS ARE DISTENDED BY CLEAR CYTOPLASMIC VACUOLES WHICH FREQUENTLY DISPLACE THE NUCLEI.

LUNG

*** ALVEOLOGENIC CARCINOMA :
A MALIGNANT TUMOR OF THE LUNG TISSUE WITH SYNONYMS IN MICE FOR ADENOMA, CARCINOMA, ALVEOLOGENIC PAPILLARY CARCINOMA, PAPILLARY CYSTADENOMA, ADENOCARCINOMA, BRONCHIOLAR CELL CARCINOMA, BRONCHIOLAR-ALVEOLAR TUMOR, TYPE A TUMOR, TYPE B TUMOR, INTERMEDIATE TYPE I TUMOR AND COMMON PULMONARY TUMOR OF THE MOUSE.

AUTOLYSIS PARTIAL :
NO OTHER CHANGES ARE SEEN. TISSUES ARE ALTERED. BY POST-MORTEM MODIFICATIONS AND DIAGNOSIS IS GIVEN WITH RESERVATION.

LIVER

CONGESTION :
VESSELS OR SINUSOIDS ARE MARKEDLY DISTENDED WITH ERYTHROCYTES.

PANCREAS

AUTOLYSIS PARTIAL :
NO OTHER CHANGES ARE SEEN. TISSUES ARE ALTERED. BY POST-MORTEM MODIFICATIONS AND DIAGNOSIS IS GIVEN WITH RESERVATION.

SPLEEN

AUTOLYSIS PARTIAL :
NO OTHER CHANGES ARE SEEN. TISSUES ARE ALTERED. BY POST-MORTEM MODIFICATIONS AND DIAGNOSIS IS GIVEN WITH RESERVATION.

KIDNEYS

CONGESTION :
VESSELS OR SINUSOIDS ARE MARKEDLY DISTENDED WITH ERYTHROCYTES.

BLADDER

AUTOLYSIS PARTIAL :

NM2.10 MALE 210 CONTINUED

BLADDER CONTINUED

NO OTHER CHANGES ARE SEEN. TISSUES ARE ALTERED.
BY POST-MORTEM MODIFICATIONS AND
DIAGNOSIS IS GIVEN WITH RESERVATION.

THYROIDS

AUTOLYSIS PARTIAL :
NO OTHER CHANGES ARE SEEN. TISSUES ARE ALTERED.
BY POST-MORTEM MODIFICATIONS AND
DIAGNOSIS IS GIVEN WITH RESERVATION.

TESTES

CALCIFICATION :
BILATERAL MODERATE
THERE ARE MINERAL DEPOSITS.

MALE 211 (1766/80)

LUNG

PNEUMONIA :
SEVERE
THE ALVEOLAR WALLS ARE THICKENED AND ALVEOLI CONTAIN
INFLAMMATORY CELLS AND FOAMY MACROPHAGES.PERIVASCULAR AND
PERIBRONCHIAL LYMPHOCYTIC ACCUMULATIONS MAY BE PRESENT.

STOMACH

CALCIFICATION :
MINIMAL MULTIFOCAL
THERE ARE MINERAL DEPOSITS.

ECTASIA VASCULAR :
THE LUMEN OF BLOOD VESSELS IS ABNORMALLY ENLARGED.

LIVER

AUTOLYSIS PARTIAL :
NO OTHER CHANGES ARE SEEN. TISSUES ARE ALTERED.
BY POST-MORTEM MODIFICATIONS AND
DIAGNOSIS IS GIVEN WITH RESERVATION.

PANCREAS

AUTOLYSIS :
THE TISSUES EXHIBIT AUTOLYSIS AND THEY ARE NOT
INTERPRETABLE.

SPLEEN

AUTOLYSIS PARTIAL :
NO OTHER CHANGES ARE SEEN. TISSUES ARE ALTERED.
BY POST-MORTEM MODIFICATIONS AND

BAYER AG

SPLEEN CONTINUED
DIAGNOSIS IS GIVEN WITH RESERVATION.

KIDNEYS

PROGRESSIVE NEPHROPATHY :
BILATERAL MINIMAL
AN AGE ASSOCIATED KIDNEY LESION CONSISTING OF CYSTIC TUBULES WITH COLLOID OR HYALINE CASTS CHRONIC INTERSTITIAL NEPHRITIS AND DILATATION OF BOWMAN'S CAPSULE WITH GLOMERULAR DEGENERATION .

BLADDER

AUTOLYSIS PARTIAL :
NO OTHER CHANGES ARE SEEN. TISSUES ARE ALTERED.
BY POST-MORTEM MODIFICATIONS AND
DIAGNOSIS IS GIVEN WITH RESERVATION.

THYROIDS

ABSENT :
ORGAN OR TISSUE NOT REMOVED FROM ANIMAL OR NOT FOUND IN FIXATIVE.

ADRENALS

PIGMENTATION :
UNILATERAL MINIMAL
NUMEROUS MACROPHAGES CONTAIN A GRANULAR BROWN CYTOPLASMIC PIGMENT.

TESTES

CALCIFICATION :
BILATERAL MODERATE MULTIFOCAL
THERE ARE MINERAL DEPOSITS.

SPERMATOCELE :
UNILATERAL MULTIFOCAL
FOCAL CYSTIC DILATATION CONTAINING SPERMATOZOA IS PRESENT.

SEMINAL VESICLES

AUTOLYSIS PARTIAL :
NO OTHER CHANGES ARE SEEN. TISSUES ARE ALTERED.
BY POST-MORTEM MODIFICATIONS AND
DIAGNOSIS IS GIVEN WITH RESERVATION.

*** MESENCHYMAL TUMOR :
MALIGNANT TUMOR DERIVED FROM UNDIFFERENTIATED COMPONENTS OF CONNECTIVE TISSUE.

LYMPH NODE

ABSENT :
ORGAN OR TISSUE NOT REMOVED FROM ANIMAL OR NOT FOUND IN FIXATIVE.

MALE 212 (1778/80)

LUNG

PNEUMONIA :
THE ALVEOLAR WALLS ARE THICKENED AND ALVEOLI CONTAIN INFLAMMATORY CELLS AND FOAMY MACROPHAGES.PERIVASCULAR AND PERIBRONCHIAL LYMPHOCYTIC ACCUMULATIONS MAY BE PRESENT.

*** ALVEOLOGENIC CARCINOMA :
A MALIGNANT TUMOR OF THE LUNG TISSUE WITH SYNONYMS IN MICE FOR ADENOMA, CARCINOMA, ALVEOLOGENIC PAPILLARY CARCINOMA, PAPILLARY CYSTADENOMA, ADENOCARCINOMA, BRONCHIOLAR CELL CARCINOMA, BRONCHIOLAR-ALVEOLAR TUMOR, TYPE A TUMOR, TYPE B TUMOR, INTERMEDIATE TYPE I TUMOR AND COMMON PULMONARY TUMOR OF THE MOUSE.

STOMACH

NORMAL :
HISTOLOGICAL ASPECT WITHIN NORMAL LIMITS.

LIVER

HYPERPLASTIC NODULES :
WELL DEFINED ROUNDED FOCI OF HYPERPLASTIC AND HYPERTROPHIC CELLS ARE OBSERVED WITHIN THIS OTHERWISE NORMAL TISSUE.

KIDNEYS

HYDRONEPHROSIS :
UNILATERAL MODERATE
THE RENAL PELVIS IS DILATED AND THE ADJACENT PARENCHYMA IS REDUCED.

PROGRESSIVE NEPHROPATHY :
BILATERAL MINIMAL
AN AGE ASSOCIATED KIDNEY LESION CONSISTING OF CYSTIC TUBULES WITH COLLOID OR HYALINE CASTS CHRONIC INTERSTITIAL NEPHRITIS AND DILATATION OF BOWMAN'S CAPSULE WITH GLOMERULAR DEGENERATION .

PITUITARY

ABSENT :
ORGAN OR TISSUE NOT REMOVED FROM ANIMAL OR NOT FOUND IN FIXATIVE.

TESTES

ATROPHY SEMINIFEROUS :
BILATERAL
THERE IS ATROPHY OF SEMINIFEROUS TUBULES WITH DIMINISHED

BAYER AG

TESTES CONTINUED

SPERMATOGENIC ACTIVITY.

AZOOSPERMIA :
BILATERAL
NO SPERMATOGENESIS IS OBSERVED.THIS CONDITION MAY HAVE VARIOUS ORIGINS.

EPIDIDYMIS

ABSENT :
ORGAN OR TISSUE NOT REMOVED FROM ANIMAL OR NOT FOUND IN FIXATIVE.

LYMPH NODE

EDEMA :
THE INTERSTITIAL TISSUES CONTAIN AN INCREASED AMOUNT OF FLUID.

LYMPHATIC ECTASIA :
A DILATATION OF THE LYMPHATIC VESSELS IS NOTED.

MALE 213 (1765/80)

HEART

CONGESTION :
VESSELS OR SINUSOIDS ARE MARKEDLY DISTENDED WITH ERYTHROCYTES.

LUNG

EDEMA :
FOCAL
THE INTERSTITIAL TISSUES CONTAIN AN INCREASED AMOUNT OF FLUID.

CONGESTION :
FOCAL
VESSELS OR SINUSOIDS ARE MARKEDLY DISTENDED WITH ERYTHROCYTES.

STOMACH

AUTOLYSIS PARTIAL :
NO OTHER CHANGES ARE SEEN. TISSUES ARE ALTERED.
BY POST-MORTEM MODIFICATIONS AND
DIAGNOSIS IS GIVEN WITH RESERVATION.

ECTASIA VASCULAR :
THE LUMEN OF BLOOD VESSELS IS ABNORMALLY ENLARGED.

LIVER

HYPERPLASTIC NODULE :
A NODULE OF HYPERPLASTIC TISSUE IS PRESENT.

AUTOLYSIS PARTIAL :
NO OTHER CHANGES ARE SEEN. TISSUES ARE ALTERED.
BY POST-MORTEM MODIFICATIONS AND
DIAGNOSIS IS GIVEN WITH RESERVATION.

PANCREAS

AUTOLYSIS PARTIAL :
NO OTHER CHANGES ARE SEEN. TISSUES ARE ALTERED.
BY POST-MORTEM MODIFICATIONS AND
DIAGNOSIS IS GIVEN WITH RESERVATION.

SPLEEN

HEMATOPOIESIS :
MINIMAL
THE HEMATOPOIESIS IS EVIDENT.

KIDNEYS

AUTOLYSIS PARTIAL :
NO OTHER CHANGES ARE SEEN. TISSUES ARE ALTERED.
BY POST-MORTEM MODIFICATIONS AND
DIAGNOSIS IS GIVEN WITH RESERVATION.

BLADDER

AUTOLYSIS :
THE TISSUES EXHIBIT AUTOLYSIS AND THEY ARE NOT
INTERPRETABLE.

THYROIDS

AUTOLYSIS PARTIAL :
NO OTHER CHANGES ARE SEEN. TISSUES ARE ALTERED.
BY POST-MORTEM MODIFICATIONS AND
DIAGNOSIS IS GIVEN WITH RESERVATION.

MALE 214 (1777/80)

HEART

THROMBOSIS :
THE VASCULAR LUMEN CONTAINS AN ATTACHED ANTE MORTEM BLOOD
CLOT.

CONGESTION :
VESSELS OR SINUSOIDS ARE MARKEDLY DISTENDED WITH
ERYTHROCYTES.

BAYER AG

LUNG

ADENOMATOSIS :
FOCAL
THE PULMONARY ALVEOLI APPEAR GLANDULAR DUE TO METAPLASTIC TRANSFORMATION OF LINING CELLS INTO CUBOIDAL OR COLUMNAR CELLS

PNEUMONIA :
SEVERE
THE ALVEOLAR WALLS ARE THICKENED AND ALVEOLI CONTAIN INFLAMMATORY CELLS AND FOAMY MACROPHAGES.PERIVASCULAR AND PERIBRONCHIAL LYMPHOCYTIC ACCUMULATIONS MAY BE PRESENT.

CONGESTION :
SEVERE
VESSELS OR SINUSOIDS ARE MARKEDLY DISTENDED WITH ERYTHROCYTES.

STOMACH

AUTOLYSIS PARTIAL :
NO OTHER CHANGES ARE SEEN. TISSUES ARE ALTERED. BY POST-MORTEM MODIFICATIONS AND DIAGNOSIS IS GIVEN WITH RESERVATION.

LIVER

NORMAL :
HISTOLOGICAL ASPECT WITHIN NORMAL LIMITS.

PANCREAS

AUTOLYSIS PARTIAL :
NO OTHER CHANGES ARE SEEN. TISSUES ARE ALTERED. BY POST-MORTEM MODIFICATIONS AND DIAGNOSIS IS GIVEN WITH RESERVATION.

BLADDER

AUTOLYSIS PARTIAL :
NO OTHER CHANGES ARE SEEN. TISSUES ARE ALTERED. BY POST-MORTEM MODIFICATIONS AND DIAGNOSIS IS GIVEN WITH RESERVATION.

PITUITARY

ABSENT :
ORGAN OR TISSUE NOT REMOVED FROM ANIMAL OR NOT FOUND IN FIXATIVE.

THYROIDS

CYSTS :
UNILATERAL
ONE OR MORE CYSTS FILLED WITH CLEAR LIQUID ARE SEEN.

AUTOLYSIS PARTIAL :
NO OTHER CHANGES ARE SEEN. TISSUES ARE ALTERED. BY POST-MORTEM MODIFICATIONS AND DIAGNOSIS IS GIVEN WITH RESERVATION.

SKELETAL MUSCLE

FATTY CYST :
ACCUMULATION OF FAT CELLS IS PRESENT.

MALE 216 (1759/60)

BRAIN

ABSENT :
ORGAN OR TISSUE NOT REMOVED FROM ANIMAL OR NOT FOUND IN FIXATIVE.

LUNG

BRONCHOPNEUMONIA :
SEVERE
MULTIFOCAL INFLAMMATION OF THE BRONCHI AND SURROUNDING ALVEOLI ARE PRESENT.

CONGESTION :
SEVERE
VESSELS OR SINUSOIDS ARE MARKEDLY DISTENDED WITH ERYTHROCYTES.

SALIVARY GLAND

INFLAMMATION CHRONIC :
THE INTERSTITIAL TISSUES SHOW INFILTRATION BY MONONUCLEAR CELLS AND INCREASE IN FIBROUS STROMA.

STOMACH

AUTOLYSIS PARTIAL :
NO OTHER CHANGES ARE SEEN. TISSUES ARE ALTERED.
BY POST-MORTEM MODIFICATIONS AND
DIAGNOSIS IS GIVEN WITH RESERVATION.

LIVER

HEMORRAGIC CYST :
SEVERE MULTIFOCAL
ONE OR SEVERAL CAVITIES FILLED WITH BLOOD.

PANCREAS

ABSENT :
ORGAN OR TISSUE NOT REMOVED FROM ANIMAL OR NOT FOUND IN FIXATIVE.

SPLEEN

AUTOLYSIS :
THE TISSUES EXHIBIT AUTOLYSIS AND THEY ARE NOT INTERPRETABLE.

BAYER AG

KIDNEYS

CALCIFICATION :
UNILATERAL MINIMAL MULTIFOCAL
THERE ARE MINERAL DEPOSITS.

AUTOLYSIS PARTIAL :
BILATERAL
NO OTHER CHANGES ARE SEEN. TISSUES ARE ALTERED.
BY POST-MORTEM MODIFICATIONS AND
DIAGNOSIS IS GIVEN WITH RESERVATION.

BLADDER

AUTOLYSIS PARTIAL :
NO OTHER CHANGES ARE SEEN. TISSUES ARE ALTERED.
BY POST-MORTEM MODIFICATIONS AND
DIAGNOSIS IS GIVEN WITH RESERVATION.

NORMAL :
HISTOLOGICAL ASPECT WITHIN NORMAL LIMITS.

PITUITARY

ABSENT :
ORGAN OR TISSUE NOT REMOVED FROM ANIMAL OR NOT FOUND IN
FIXATIVE.

THYROIDS

AUTOLYSIS PARTIAL :
NO OTHER CHANGES ARE SEEN. TISSUES ARE ALTERED.
BY POST-MORTEM MODIFICATIONS AND
DIAGNOSIS IS GIVEN WITH RESERVATION.

ADRENALS

PIGMENTATION :
BILATERAL MINIMAL
NUMEROUS MACROPHAGES CONTAIN A GRANULAR BROWN CYTOPLASMIC
PIGMENT.

TESTES

CYSTS :
UNILATERAL
ONE OR MORE CYSTS FILLED WITH CLEAR LIQUID ARE SEEN.

SEMINAL VESICLES

COAGULUM :
AN ACIDOPHILIC STRUCTURE RESEMBLING COAGULATED PROTEIN IS
PRESENT IN THE LUMEN.

HEART

CONGESTION :
VESSELS OR SINUSOIDS ARE MARKEDLY DISTENDED WITH ERYTHROCYTES.

LUNG

ADENOMATOSIS :
THE PULMONARY ALVEOLI APPEAR GLANDULAR DUE TO METAPLASTIC TRANSFORMATION OF LINING CELLS INTO CUBOIDAL OR COLUMNAR CELLS

CONGESTION :
VESSELS OR SINUSOIDS ARE MARKEDLY DISTENDED WITH ERYTHROCYTES.

STOMACH

FIBROSIS :
MODERATE
THERE IS AN INCREASE IN INTERSTITIAL FIBROUS TISSUE.

INFLAMMATION CHRONIC :
MODERATE
THE INTERSTITIAL TISSUES SHOW INFILTRATION BY MONONUCLEAR CELLS AND INCREASE IN FIBROUS STROMA.

LIVER

FAT VACUOLES :
MODERATE
THE CELLS ARE DISTENDED BY CLEAR CYTOPLASMIC VACUOLES WHICH FREQUENTLY DISPLACE THE NUCLEI.

CONGESTION :
VESSELS OR SINUSOIDS ARE MARKEDLY DISTENDED WITH ERYTHROCYTES.

HYPERPLASTIC NODULE :
A NODULE OF HYPERPLASTIC TISSUE IS PRESENT.

SPLEEN

HEMATOPOIESIS :
SEVERE
THE HEMATOPOIESIS IS EVIDENT.

KIDNEYS

TUBULOPATHY :
BILATERAL MODERATE
TUBULAR DEGENERATIVE CHANGES ARE PRESENT WHICH MAY BE ASSOCIATED WITH TUBULAR DILATATION.

SCIATIC NERVE

ABSENT :
ORGAN OR TISSUE NOT REMOVED FROM ANIMAL OR NOT FOUND IN FIXATIVE.

BAYER

MALE 221 (175>/80)

BRAIN

ABSENT :
ORGAN OR TISSUE NOT REMOVED FROM ANIMAL OR NOT FOUND IN FIXATIVE.

HEART

FAT VACUOLES :
SEVERE
THE CELLS ARE DISTENDED BY CLEAR CYTOPLASMIC VACUOLES WHICH FREQUENTLY DISPLACE THE NUCLEI.

LUNG

EDEMA :
SEVERE
THE INTERSTITIAL TISSUES CONTAIN AN INCREASED AMOUNT OF FLUID.

PNEUMONIA :
SEVERE
THE ALVEOLAR WALLS ARE THICKENED AND ALVEOLI CONTAIN INFLAMMATORY CELLS AND FOAMY MACROPHAGES.PERIVASCULAR AND PERIBRONCHIAL LYMPHOCYTIC ACCUMULATIONS MAY BE PRESENT.

STOMACH

AUTOLYSIS :
THE TISSUES EXHIBIT AUTOLYSIS AND THEY ARE NOT INTERPRETABLE.

LIVER

AUTOLYSIS PARTIAL :
SEVERE
NO OTHER CHANGES ARE SEEN. TISSUES ARE ALTERED. BY POST-MORTEM MODIFICATIONS AND DIAGNOSIS IS GIVEN WITH RESERVATION.

HEMORRAGIC CYST :
SEVERE
ONE OR SEVERAL CAVITIES FILLED WITH BLOOD.

PANCREAS

AUTOLYSIS :
THE TISSUES EXHIBIT AUTOLYSIS AND THEY ARE NOT INTERPRETABLE.

SPLEEN

AUTOLYSIS :

SPLEEN CONTINUED

THE TISSUES EXHIBIT AUTOLYSIS AND THEY ARE NOT INTERPRETABLE.

KIDNEYS

CYSTS :
UNILATERAL
ONE OR MORE CYSTS FILLED WITH CLEAR LIQUID ARE SEEN.

AUTOLYSIS PARTIAL :
NO OTHER CHANGES ARE SEEN. TISSUES ARE ALTERED.
BY POST-MORTEM MODIFICATIONS AND
DIAGNOSIS IS GIVEN WITH RESERVATION.

BLADDER

ABSENT :
ORGAN OR TISSUE NOT REMOVED FROM ANIMAL OR NOT FOUND IN FIXATIVE.

PITUITARY

ABSENT :
ORGAN OR TISSUE NOT REMOVED FROM ANIMAL OR NOT FOUND IN FIXATIVE.

THYROIDS

ABSENT :
ORGAN OR TISSUE NOT REMOVED FROM ANIMAL OR NOT FOUND IN FIXATIVE.

ADRENALS

AUTOLYSIS PARTIAL :
NO OTHER CHANGES ARE SEEN. TISSUES ARE ALTERED.
BY POST-MORTEM MODIFICATIONS AND
DIAGNOSIS IS GIVEN WITH RESERVATION.

TESTES

AUTOLYSIS PARTIAL :
NO OTHER CHANGES ARE SEEN. TISSUES ARE ALTERED.
BY POST-MORTEM MODIFICATIONS AND
DIAGNOSIS IS GIVEN WITH RESERVATION.

MALE 222 (1748/60)

STOMACH

UNREADABLE :
IT IS NOT POSSIBLE TO INTERPRET THE SECTION DUE TO AN ARTIFACT CAUSED BY SAMPLING OR HISTOLOGICAL TECHNIQUE.

BAYER AG

LIVER

AMYLOID :
MODERATE
HOMOGENEOUS ACIDOPHILIC MATERIAL IS DEPOSITED.

PANCREAS

AMYLOID :
MINIMAL
HOMOGENEOUS ACIDOPHILIC MATERIAL IS DEPOSITED.

SPLEEN

AMYLOID :
SEVERE
HOMOGENEOUS ACIDOPHILIC MATERIAL IS DEPOSITED.

ADRENALS

AMYLOID :
MODERATE
HOMOGENEOUS ACIDOPHILIC MATERIAL IS DEPOSITED.

SEMINAL VESICLES

COAGULUM :
AN ACIDOPHILIC STRUCTURE RESEMBLING COAGULATED PROTEIN IS PRESENT IN THE LUMEN.

BODY WALL

ABSENT :
ORGAN OR TISSUE NOT REMOVED FROM ANIMAL OR NOT FOUND IN FIXATIVE.

MALE 223 (177a/80)

SPLEEN

HEMATOPOIESIS :
SEVERE
THE HEMATOPOIESIS IS EVIDENT.

KIDNEYS

INTERSTITIAL NEPHRITIS :
BILATERAL MINIMAL
INFLAMMATORY CELLS FIBROSIS AND SOME TUBULAR ALTERATIONS ARE ASSOCIATED.

SKIN

INFLAMMATION CHRONIC :
THE INTERSTITIAL TISSUES SHOW INFILTRATION BY MONONUCLEAR

SKIN CONTINUED

CELLS AND INCREASE IN FIBROUS STROMA.

MALE 224 (1776/80)

HEART

THROMBOSIS :
THE VASCULAR LUMEN CONTAINS AN ATTACHED ANTE-MORTEM BLOOD CLOT.

PERICARDITIS :
FOCAL
THE PERICARDIUM IS THE SITE OF ACUTE OR CHRONIC INFLAMMATION.

LUNG

PNEUMONIA :
SEVERE
THE ALVEOLAR WALLS ARE THICKENED AND ALVEOLI CONTAIN INFLAMMATORY CELLS AND FOAMY MACROPHAGES. PERIVASCULAR AND PERIBRONCHIAL LYMPHOCYTIC ACCUMULATIONS MAY BE PRESENT.

CONGESTION :
SEVERE
VESSELS OR SINUSOIDS ARE MARKEDLY DISTENDED WITH ERYTHROCYTES.

PANCREAS

CONGESTION :
VESSELS OR SINUSOIDS ARE MARKEDLY DISTENDED WITH ERYTHROCYTES.

BLADDER

INFLAMMATION CHRONIC :
MINIMAL
THERE IS AN INFILTRATION BY MUNONUCLEAR CELLS IN THE MUCOSA AND SUBMUCOSA.

THYROIDS

CYSTS :
UNILATERAL
ONE OR MORE CYSTS FILLED WITH CLEAR LIQUID ARE SEEN.

SCIATIC NERVE

ABSENT :
ORGAN OR TISSUE NOT REMOVED FROM ANIMAL OR NOT FOUND IN FIXATIVE.

BAYER BAYER BAYER BAYER

TESTES

CALCIFICATION :
UNILATERAL MODERATE MULTIFOCAL
THERE ARE MINERAL DEPOSITS.

MALE 225 (1747/60)

HEART

CONGESTION :
VESSELS OR SINUSOIDS ARE MARKEDLY DISTENDED WITH ERYTHROCYTES.

LUNG

PNEUMONIA :
THE ALVEOLAR WALLS ARE THICKENED AND ALVEOLI CONTAIN INFLAMMATORY CELLS AND FOAMY MACROPHAGES.PERIVASCULAR AND PERIBRONCHIAL LYMPHOCYTIC ACCUMULATIONS MAY BE PRESENT.

CONGESTION :
VESSELS OR SINUSOIDS ARE MARKEDLY DISTENDED WITH ERYTHROCYTES.

STOMACH

NORMAL :
HISTOLOGICAL ASPECT WITHIN NORMAL LIMITS.

LIVER

CONGESTION :
VESSELS OR SINUSOIDS ARE MARKEDLY DISTENDED WITH ERYTHROCYTES.

KIDNEYS

CYSTS :
UNILATERAL
ONE OR MORE CYSTS FILLED WITH CLEAR LIQUID ARE SEEN.

AUTOLYSIS PARTIAL :
NO OTHER CHANGES ARE SEEN. TISSUES ARE ALTERED.
BY POST-MORTEM MODIFICATIONS AND
DIAGNOSIS IS GIVEN WITH RESERVATION.

BLADDER

COAGULUM :
AN ACIDOPHILIC STRUCTURE RESEMBLING COAGULATED PROTEIN IS PRESENT IN THE LUMEN.

PITUITARY

ABSENT :
ORGAN OR TISSUE NOT REMOVED FROM ANIMAL OR NOT FOUND IN FIXATIVE.

PROSTATE

COAGULUM :
AN ACIDOPHILIC STRUCTURE RESEMBLING COAGULATED PROTEIN IS PRESENT IN THE LUMEN.

SEMINAL VESICLES

COAGULUM :
AN ACIDOPHILIC STRUCTURE RESEMBLING COAGULATED PROTEIN IS PRESENT IN THE LUMEN.

CYSTS :
ONE OR MORE CYSTS FILLED WITH CLEAR LIQUID ARE SEEN.

MALE 227 (1757/80)

STOMACH

NORMAL :
HISTOLOGICAL ASPECT WITHIN NORMAL LIMITS.

KIDNEYS

CONGESTION :
VESSELS OR SINUSOIDS ARE MARKEDLY DISTENDED WITH ERYTHROCYTES.

MALE 229 (1749/80)

LUNG

PNEUMONIA :
SEVERE
THE ALVEOLAR WALLS ARE THICKENED AND ALVEOLI CONTAIN INFLAMMATORY CELLS AND FOAMY MACROPHAGES.PERIVASCULAR AND PERIBRONCHIAL LYMPHOCYTIC ACCUMULATIONS MAY BE PRESENT.

CONGESTION :
SEVERE
VESSELS OR SINUSOIDS ARE MARKEDLY DISTENDED WITH ERYTHROCYTES.

BAYER AG

STOMACH

HEMORRHAGE :
FOCAL
THERE IS EXTRAVASATION OF BLOOD.

LIVER

AUTOLYSIS PARTIAL :
NO OTHER CHANGES ARE SEEN. TISSUES ARE ALTERED.
BY POST-MORTEM MODIFICATIONS AND
DIAGNOSIS IS GIVEN WITH RESERVATION.

PANCREAS

AUTOLYSIS PARTIAL :
NO OTHER CHANGES ARE SEEN. TISSUES ARE ALTERED.
BY POST-MORTEM MODIFICATIONS AND
DIAGNOSIS IS GIVEN WITH RESERVATION.

PITUITARY

ABSENT :
ORGAN OR TISSUE NOT REMOVED FROM ANIMAL OR NOT FOUND IN
FIXATIVE.

MALE 231 (1750/80)

BRAIN

ABSENT :
ORGAN OR TISSUE NOT REMOVED FROM ANIMAL OR NOT FOUND IN
FIXATIVE.

LUNG

EDEMA :
SEVERE
THE INTERSTITIAL TISSUES CONTAIN AN INCREASED AMOUNT OF
FLUID.

*** ALVEOLOGENIC CARCINOMA :
A MALIGNANT TUMOR OF THE LUNG TISSUE WITH
SYNONYMS IN MICE FOR ADENOMA, CARCINOMA,
ALVEOLOGENIC PAPILLARY CARCINOMA, PAPILLARY
CYSTADENOMA, ADENOCARCINOMA, BRONCHIOLAR
CELL CARCINOMA, BRONCHIOLAR-ALVEOLAR TUMOR,
TYPE A TUMOR, TYPE B TUMOR, INTERMEDIATE
TYPE I TUMOR AND COMMON PULMONARY TUMOR OF
THE MOUSE.

AUTOLYSIS PARTIAL :
NO OTHER CHANGES ARE SEEN. TISSUES ARE ALTERED.
BY POST-MORTEM MODIFICATIONS AND
DIAGNOSIS IS GIVEN WITH RESERVATION.

STOMACH

AUTOLYSIS PARTIAL :
NO OTHER CHANGES ARE SEEN. TISSUES ARE ALTERED.
BY POST-MORTEM MODIFICATIONS AND
DIAGNOSIS IS GIVEN WITH RESERVATION.

LIVER

LEUKEMIC DEPOSITS :
ORGAN AND THE BLOOD ARE INVADED BY LEUKEMIC
CELLS.

AUTOLYSIS PARTIAL :
NO OTHER CHANGES ARE SEEN. TISSUES ARE ALTERED.
BY POST-MORTEM MODIFICATIONS AND
DIAGNOSIS IS GIVEN WITH RESERVATION.

PANCREAS

AUTOLYSIS :
THE TISSUES EXHIBIT AUTOLYSIS AND THEY ARE NOT
INTERPRETABLE.

SPLEEN

*** LYMPHOMA LYMPHOCYTIC :
THE NEOPLASM OF THE RETICULAR SYSTEM ORIGINATES FROM
LYMPHOCYTES.

AUTOLYSIS PARTIAL :
NO OTHER CHANGES ARE SEEN. TISSUES ARE ALTERED.
BY POST-MORTEM MODIFICATIONS AND
DIAGNOSIS IS GIVEN WITH RESERVATION.

KIDNEYS

AUTOLYSIS PARTIAL :
NO OTHER CHANGES ARE SEEN. TISSUES ARE ALTERED.
BY POST-MORTEM MODIFICATIONS AND
DIAGNOSIS IS GIVEN WITH RESERVATION.

BLADDER

AUTOLYSIS PARTIAL :
NO OTHER CHANGES ARE SEEN. TISSUES ARE ALTERED.
BY POST-MORTEM MODIFICATIONS AND
DIAGNOSIS IS GIVEN WITH RESERVATION.

PITUITARY

AUTOLYSIS :
THE TISSUES EXHIBIT AUTOLYSIS AND THEY ARE NOT
INTERPRETABLE.

THYROIDS

AUTOLYSIS :
THE TISSUES EXHIBIT AUTOLYSIS AND THEY ARE NOT
INTERPRETABLE.

BAYER BAYER BAYER BAYER

ADRENALS

AUTOLYSIS :
THE TISSUES EXHIBIT AUTOLYSIS AND THEY ARE NOT INTERPRETABLE.

TESTES

AUTOLYSIS PARTIAL :
NO OTHER CHANGES ARE SEEN. TISSUES ARE ALTERED. BY POST-MORTEM MODIFICATIONS AND DIAGNOSIS IS GIVEN WITH RESERVATION.

MALE 232 (1783/80)

HEART

DILATED CHAMBER :
ONE OR MORE OF THE CHAMBERS OF THE HEART ARE DILATED.

LUNG

THROMBOSIS :
SEVERE
THE VASCULAR LUMEN CONTAINS AN ATTACHED ANTE MORTEM BLOOD CLOT.

CONGESTION :
SEVERE
VESSELS OR SINUSOIDS ARE MARKEDLY DISTENDED WITH ERYTHROCYTES.

ECTASIA VASCULAR :
SEVERE
THE LUMEN OF BLOOD VESSELS IS ABNORMALLY ENLARGED.

LIVER

INFARCT :
MULTIFOCAL
AN AREA OF ISCHEMIC NECROSIS DUE TO VASCULAR OCCLUSION IS PRESENT.

*** ADENOMA HEPATIC BENIGN :
DISTINCT NODULES COMPRESS THE ADJACENT LIVER PARENCHYMA, ARE CHARACTERIZED BY WELL DIFFERENTIATED HEPATOCYTES AND DO NOT SHOW PORTAL TRIADS.

PANCREAS

AUTOLYSIS PARTIAL :
NO OTHER CHANGES ARE SEEN. TISSUES ARE ALTERED. BY POST-MORTEM MODIFICATIONS AND DIAGNOSIS IS GIVEN WITH RESERVATION.

LM2.28 MALE 232 CONTINUED

SPLEEN

CONGESTION :
VESSELS OR SINUSOIDS ARE MARKEDLY DISTENDED WITH ERYTHROCYTES.

PITUITARY

ABSENT :
ORGAN OR TISSUE NOT REMOVED FROM ANIMAL OR NOT FOUND IN FIXATIVE.

THYROIDS

AUTOLYSIS PARTIAL :
NO OTHER CHANGES ARE SEEN. TISSUES ARE ALTERED BY POST-MORTEM MODIFICATIONS AND DIAGNOSIS IS GIVEN WITH RESERVATION.

SCIATIC NERVE

ABSENT :
ORGAN OR TISSUE NOT REMOVED FROM ANIMAL OR NOT FOUND IN FIXATIVE.

MALE 234 (176a/80)

HEART

CONGESTION :
VESSELS OR SINUSOIDS ARE MARKEDLY DISTENDED WITH ERYTHROCYTES.

LUNG

*** ALVEOLOGENIC CARCINOMA :
MULTIFOCAL
A MALIGNANT TUMOR OF THE LUNG TISSUE WITH SYNONYMS IN MICE FOR ADENOMA, CARCINOMA, ALVEOLOGENIC PAPILLARY CARCINOMA, PAPILLARY CYSTADENOMA, ADENOCARCINOMA, BRONCHIOLAR CELL CARCINOMA, BRONCHIOLAR-ALVEOLAR TUMOR, TYPE A TUMOR, TYPE B TUMOR, INTERMEDIATE TYPE I TUMOR AND COMMON PULMONARY TUMOR OF THE MOUSE.

CONGESTION :
SEVERE
VESSELS OR SINUSOIDS ARE MARKEDLY DISTENDED WITH ERYTHROCYTES.

KIDNEYS

TUBULOPATHY :
BILATERAL MINIMAL

BAYER AG

KIDNEYS CONTINUED

TUBULAR DEGENERATIVE CHANGES ARE PRESENT WHICH MAY BE ASSOCIATED WITH TUBULAR DILATATION.

BLADDER

AUTOLYSIS PARTIAL :
NO OTHER CHANGES ARE SEEN. TISSUES ARE ALTERED BY POST-MORTEM MODIFICATIONS AND DIAGNOSIS IS GIVEN WITH RESERVATION.

MALE 235 (1780/80)

BRAIN

FAT VACUOLES :
MODERATE MULTIFOCAL
THE CELLS ARE DISTENDED BY CLEAR CYTOPLASMIC VACUOLES WHICH FREQUENTLY DISPLACE THE NUCLEI.

HEART

THROMBOSIS :
THE VASCULAR LUMEN CONTAINS AN ATTACHED ANTE MORTEM BLOOD CLOT.

FIBROSIS :
THERE IS AN INCREASE IN INTERSTITIAL FIBROUS TISSUE.

INFLAMMATION CHRONIC :
THE INTERSTITIAL TISSUES SHOW INFILTRATION BY MONONUCLEAR CELLS AND INCREASE IN FIBROUS STROMA.

LUNG

PNEUMONIA :
THE ALVEOLAR WALLS ARE THICKENED AND ALVEOLI CONTAIN INFLAMMATORY CELLS AND FOAMY MACROPHAGES.PERIVASCULAR AND PERIBRONCHIAL LYMPHOCYTIC ACCUMULATIONS MAY BE PRESENT.

*** ALVEOLOGENIC CARCINOMA :
MULTIFOCAL
A MALIGNANT TUMOR OF THE LUNG TISSUE WITH SYNONYMS IN MICE FOR ADENOMA, CARCINOMA, ALVEOLOGENIC PAPILLARY CARCINOMA, PAPILLARY CYSTADENOMA, ADENOCARCINOMA, BRONCHIOLAR CELL CARCINOMA, BRONCHIOLAR-ALVEOLAR TUMOR, TYPE A TUMOR, TYPE B TUMOR, INTERMEDIATE TYPE I TUMOR AND COMMON PULMONARY TUMOR OF THE MOUSE.

LIVER

HYPERPLASTIC NODULE :
A NODULE OF HYPERPLASTIC TISSUE IS PRESENT.

HEMORRAGIC CYST :
SEVERE MULTIFOCAL

LIVER CONTINUED

ONE OR SEVERAL CAVITIES FILLED WITH BLOOD.

PANCREAS

AUTOLYSIS PARTIAL :
NO OTHER CHANGES ARE SEEN. TISSUES ARE ALTERED.
BY POST-MORTEM MODIFICATIONS AND
DIAGNOSIS IS GIVEN WITH RESERVATION.

SPLEEN

NORMAL :
HISTOLOGICAL ASPECT WITHIN NORMAL LIMITS.

KIDNEYS

INTERSTITIAL NEPHRITIS :
BILATERAL MINIMAL
INFLAMMATORY CELLS FIBROSIS AND SOME TUBULAR ALTERATIONS
ARE ASSOCIATED.

BLADDER

AUTOLYSIS PARTIAL :
NO OTHER CHANGES ARE SEEN. TISSUES ARE ALTERED.
BY POST-MORTEM MODIFICATIONS AND
DIAGNOSIS IS GIVEN WITH RESERVATION.

PITUITARY

ABSENT :
ORGAN OR TISSUE NOT REMOVED FROM ANIMAL OR NOT FOUND IN
FIXATIVE.

THYROIDS

AUTOLYSIS PARTIAL :
NO OTHER CHANGES ARE SEEN. TISSUES ARE ALTERED.
BY POST-MORTEM MODIFICATIONS AND
DIAGNOSIS IS GIVEN WITH RESERVATION.

TESTES

CALCIFICATION :
BILATERAL MINIMAL MULTIFOCAL
THERE ARE MINERAL DEPOSITS.

SEMINAL VESICLES

COAGULUM :
AN ACIDOPHILIC STRUCTURE RESEMBLING COAGULATED PROTEIN IS
PRESENT IN THE LUMEN.

FEMUR

*** OSTEOMA :
THIS BENIGN WELL CIRCUMSCRIBED TUMOR IS COMPOSED OF
WELL-DEVELOPED BONE.

BAYER AG

MALE 236 (1781/80)

LUNG

NECROSIS :
SEVERE
THE TISSUE HAS LOST ITS NORMAL STRUCTURE DUE TO CELL DEATH WHICH MAY BE OF VARIOUS ORIGIN.

BRONCHOPNEUMONIA :
SEVERE
MULTIFOCAL INFLAMMATION OF THE BRONCHI AND SURROUNDING ALVEOLI ARE PRESENT.

SPLEEN

HEMATOPOIESIS :
MINIMAL
THE HEMATOPOIESIS IS EVIDENT.

KIDNEYS

CYSTS :
BILATERAL MODERATE MULTIFOCAL
ONE OR MORE CYSTS FILLED WITH CLEAR LIQUID ARE SEEN.

PITUITARY

ABSENT :
ORGAN OR TISSUE NOT REMOVED FROM ANIMAL OR NOT FOUND IN FIXATIVE.

THYROIDS

ABSENT :
ORGAN OR TISSUE NOT REMOVED FROM ANIMAL OR NOT FOUND IN FIXATIVE.

MALE 237 (1760/80)

HEART

CONGESTION :
VESSELS OR SINUSOIDS ARE MARKEDLY DISTENDED WITH ERYTHROCYTES.

LUNG

PNEUMONIA :
THE ALVEOLAR WALLS ARE THICKENED AND ALVEOLI CONTAIN INFLAMMATORY CELLS AND FOAMY MACROPHAGES.PERIVASCULAR AND PERIBRONCHIAL LYMPHOCYTIC ACCUMULATIONS MAY BE PRESENT.

CONGESTION :
VESSELS OR SINUSOIDS ARE MARKEDLY DISTENDED WITH ERYTHROCYTES.

LIVER

CONGESTION :
VESSELS OR SINUSOIDS ARE MARKEDLY DISTENDED WITH ERYTHROCYTES.

KIDNEYS

TUBULOPATHY :
UNILATERAL MINIMAL
TUBULAR DEGENERATIVE CHANGES ARE PRESENT WHICH MAY BE ASSOCIATED WITH TUBULAR DILATATION.

PITUITARY

ABSENT :
ORGAN OR TISSUE NOT REMOVED FROM ANIMAL OR NOT FOUND IN FIXATIVE.

ADRENALS

*** ADENOMA :
UNILATERAL
THIS IS BENIGN GLANDULAR EPITHELIAL TUMOR.

BAYER AG

MALE 238 (1770/80)

LUNG

HEMORRHAGE :
FOCAL
THERE IS EXTRAVASATION OF BLOOD.

LIVER

HYPERPLASTIC NODULE :
FOCAL
A NODULE OF HYPERPLASTIC TISSUE IS PRESENT.

SPLEEN

HEMATOPOIESIS :
SEVERE
THE HEMATOPOIESIS IS EVIDENT.

KIDNEYS

CYSTS :
BILATERAL MINIMAL MULTIFOCAL
ONE OR MORE CYSTS FILLED WITH CLEAR LIQUID ARE SEEN.

PITUITARY

ABSENT :
ORGAN OR TISSUE NOT REMOVED FROM ANIMAL OR NOT FOUND IN FIXATIVE.

THYROIDS

ABSENT :
ORGAN OR TISSUE NOT REMOVED FROM ANIMAL OR NOT FOUND IN FIXATIVE.

SCIATIC NERVE

ABSENT :
ORGAN OR TISSUE NOT REMOVED FROM ANIMAL OR NOT FOUND IN FIXATIVE.

SEMINAL VESICLES

COAGULUM :
AN ACIDOPHILIC STRUCTURE RESEMBLING COAGULATED PROTEIN IS PRESENT IN THE LUMEN.

FEMUR

ABSENT :
ORGAN OR TISSUE NOT REMOVED FROM ANIMAL OR NOT FOUND IN FIXATIVE.

MALE 240 (1769/80)

BRAIN

ABSENT :
ORGAN OR TISSUE NOT REMOVED FROM ANIMAL OR NOT FOUND IN FIXATIVE.

HEART

AUTOLYSIS PARTIAL :
NO OTHER CHANGES ARE SEEN. TISSUES ARE ALTERED.
BY POST-MORTEM MODIFICATIONS AND
DIAGNOSIS IS GIVEN WITH RESERVATION.

LUNG

AUTOLYSIS :
THE TISSUES EXHIBIT AUTOLYSIS AND THEY ARE NOT

LUNG CONTINUED

INTERPRETABLE.

STOMACH

AUTOLYSIS :
THE TISSUES EXHIBIT AUTOLYSIS AND THEY ARE NOT INTERPRETABLE.

LIVER

AUTOLYSIS :
THE TISSUES EXHIBIT AUTOLYSIS AND THEY ARE NOT INTERPRETABLE.

PANCREAS

ABSENT :
ORGAN OR TISSUE NOT REMOVED FROM ANIMAL OR NOT FOUND IN FIXATIVE.

SPLEEN

AUTOLYSIS :
THE TISSUES EXHIBIT AUTOLYSIS AND THEY ARE NOT INTERPRETABLE.

KIDNEYS

AUTOLYSIS :
THE TISSUES EXHIBIT AUTOLYSIS AND THEY ARE NOT INTERPRETABLE.

BLADDER

AUTOLYSIS :
THE TISSUES EXHIBIT AUTOLYSIS AND THEY ARE NOT INTERPRETABLE.

PITUITARY

AUTOLYSIS :
THE TISSUES EXHIBIT AUTOLYSIS AND THEY ARE NOT INTERPRETABLE.

THYROIDS

AUTOLYSIS :
THE TISSUES EXHIBIT AUTOLYSIS AND THEY ARE NOT INTERPRETABLE.

ADRENALS

AUTOLYSIS :
THE TISSUES EXHIBIT AUTOLYSIS AND THEY ARE NOT INTERPRETABLE.

SKELETAL MUSCLE

ABSENT :
ORGAN OR TISSUE NOT REMOVED FROM ANIMAL OR NOT FOUND IN FIXATIVE.

BAYER AG

SCIATIC NERVE

ABSENT :
ORGAN OR TISSUE NOT REMOVED FROM ANIMAL OR NOT FOUND IN FIXATIVE.

TESTES

AUTOLYSIS :
THE TISSUES EXHIBIT AUTOLYSIS AND THEY ARE NOT INTERPRETABLE.

FEMUR

ABSENT :
ORGAN OR TISSUE NOT REMOVED FROM ANIMAL OR NOT FOUND IN FIXATIVE.

MALE 241 (1751/80)

HEART

PERICARDITIS :
SEVERE
THE PERICARDIUM IS THE SITE OF ACUTE OR CHRONIC INFLAMMATION.

LUNG

PNEUMONIA :
SEVERE
THE ALVEOLAR WALLS ARE THICKENED AND ALVEOLI CONTAIN INFLAMMATORY CELLS AND FOAMY MACROPHAGES.PERIVASCULAR AND PERIBRONCHIAL LYMPHOCYTIC ACCUMULATIONS MAY BE PRESENT.

CONGESTION :
SEVERE
VESSELS OR SINUSOIDS ARE MARKEDLY DISTENDED WITH ERYTHROCYTES.

LIVER

MONONUCLEAR CELLS :
MODERATE MULTIFOCAL
FOCAL COLLECTIONS OF MONONUCLEAR CELLS ARE PRESENT.

PANCREAS

ABSENT :
ORGAN OR TISSUE NOT REMOVED FROM ANIMAL OR NOT FOUND IN FIXATIVE.

SPLEEN

AUTOLYSIS :

SPLEEN CONTINUED

THE TISSUES EXHIBIT AUTOLYSIS AND THEY ARE NOT INTERPRETABLE.

KIDNEYS

TUBULOPATHY :
UNILATERAL MINIMAL
TUBULAR DEGENERATIVE CHANGES ARE PRESENT WHICH MAY BE ASSOCIATED WITH TUBULAR DILATATION.

AUTOLYSIS PARTIAL :
NO OTHER CHANGES ARE SEEN. TISSUES ARE ALTERED. BY POST-MORTEM MODIFICATIONS AND DIAGNOSIS IS GIVEN WITH RESERVATION.

THYROIDS

ABSENT :
ORGAN OR TISSUE NOT REMOVED FROM ANIMAL OR NOT FOUND IN FIXATIVE.

ADRENALS

PIGMENTATION :
BILATERAL MODERATE
NUMEROUS MACROPHAGES CONTAIN A GRANULAR BROWN CYTOPLASMIC PIGMENT.

TESTES

AUTOLYSIS PARTIAL :
NO OTHER CHANGES ARE SEEN. TISSUES ARE ALTERED. BY POST-MORTEM MODIFICATIONS AND DIAGNOSIS IS GIVEN WITH RESERVATION.

INTESTINE

AUTOLYSIS :
THE TISSUES EXHIBIT AUTOLYSIS AND THEY ARE NOT INTERPRETABLE.

MALE 242 (1782/80)

HEART

THROMBOSIS :
THE VASCULAR LUMEN CONTAINS AN ATTACHED ANTE MORTEM BLOOD CLOT.

LIVER

NORMAL :
HISTOLOGICAL ASPECT WITHIN NORMAL LIMITS.

BAYER AG

SPLEEN

NORMAL :
HISTOLOGICAL ASPECT WITHIN NORMAL LIMITS.

KIDNEYS

HYDRONEPHROSIS :
BILATERAL MODERATE
THE RENAL PELVIS IS DILATED AND THE ADJACENT PARENCHYMA IS REDUCED.

PROGRESSIVE NEPHROPATHY :
BILATERAL MODERATE
AN AGE ASSOCIATED KIDNEY LESION CONSISTING OF CYSTIC TUBULES WITH COLLOID OR HYALINE CASTS CHRONIC INTERSTITIAL NEPHRITIS AND DILATATION OF BOWMAN'S CAPSULE WITH GLOMERULAR DEGENERATION .

PITUITARY

ABSENT :
ORGAN OR TISSUE NOT REMOVED FROM ANIMAL OR NOT FOUND IN FIXATIVE.

ADRENALS

ABSENT :
UNILATERAL
ORGAN OR TISSUE NOT REMOVED FROM ANIMAL OR NOT FOUND IN FIXATIVE.

MALE 243 (1775/80)

BRAIN

ABSENT :
ORGAN OR TISSUE NOT REMOVED FROM ANIMAL OR NOT FOUND IN FIXATIVE.

HEART

LEUKOCYTOSIS :
SEVERE
THERE IS AN INCREASE IN LEUKOCYTES.

CONGESTION :
SEVERE
VESSELS OR SINUSOIDS ARE MARKEDLY DISTENDED WITH ERYTHROCYTES.

LUNG

EDEMA :
THE INTERSTITIAL TISSUES CONTAIN AN INCREASED AMOUNT OF

LUNG CONTINUED

FLUID.

ADENOMATOSIS :
FOCAL
THE PULMONARY ALVEOLI APPEAR GLANDULAR DUE TO METAPLASTIC TRANSFORMATION OF LINING CELLS INTO CUBOIDAL OR COLUMNAR CELLS

PNEUMONIA :
THE ALVEOLAR WALLS ARE THICKENED AND ALVEOLI CONTAIN INFLAMMATORY CELLS AND FOAMY MACROPHAGES.PERIVASCULAR AND PERIBRONCHIAL LYMPHOCYTIC ACCUMULATIONS MAY BE PRESENT.

LEUKOCYTOSIS :
THERE IS AN INCREASE IN LEUKOCYTES.

STOMACH

AUTOLYSIS :
THE TISSUES EXHIBIT AUTOLYSIS AND THEY ARE NOT INTERPRETABLE.

LIVER

LEUKEMIC DEPOSITS :
ORGAN AND THE BLOOD ARE INVADED BY LEUKEMIC CELLS.

AUTOLYSIS PARTIAL :
NO OTHER CHANGES ARE SEEN. TISSUES ARE ALTERED. BY POST-MORTEM MODIFICATIONS AND DIAGNOSIS IS GIVEN WITH RESERVATION.

PANCREAS

AUTOLYSIS :
THE TISSUES EXHIBIT AUTOLYSIS AND THEY ARE NOT INTERPRETABLE.

SPLEEN

*** LYMPHOMA LYMPHOCYTIC :
THE NEOPLASM OF THE RETICULAR SYSTEM ORIGINATES FROM LYMPHOCYTES.

AUTOLYSIS PARTIAL :
NO OTHER CHANGES ARE SEEN. TISSUES ARE ALTERED. BY POST-MORTEM MODIFICATIONS AND DIAGNOSIS IS GIVEN WITH RESERVATION.

KIDNEYS

CYSTS :
BILATERAL MODERATE MULTIFOCAL
ONE OR MORE CYSTS FILLED WITH CLEAR LIQUID ARE SEEN.

LEUKEMIC DEPOSITS :
MINIMAL
ORGAN AND THE BLOOD ARE INVADED BY LEUKEMIC CELLS.

AUTOLYSIS PARTIAL :

BAYER AG

KIDNEYS CONTINUED

NO OTHER CHANGES ARE SEEN. TISSUES ARE ALTERED. BY POST-MORTEM MODIFICATIONS AND DIAGNOSIS IS GIVEN WITH RESERVATION.

BLADDER

AUTOLYSIS :
THE TISSUES EXHIBIT AUTOLYSIS AND THEY ARE NOT INTERPRETABLE.

PITUITARY

ABSENT :
ORGAN OR TISSUE NOT REMOVED FROM ANIMAL OR NOT FOUND IN FIXATIVE.

THYROIDS

ABSENT :
ORGAN OR TISSUE NOT REMOVED FROM ANIMAL OR NOT FOUND IN FIXATIVE.

TESTES

CALCIFICATION :
UNILATERAL MODERATE MULTIFOCAL
THERE ARE MINERAL DEPOSITS.

MALE 246 (1768/80)

BRAIN

FAT VACUOLES :
MODERATE FOCAL
THE CELLS ARE DISTENDED BY CLEAR CYTOPLASMIC VACUOLES WHICH FREQUENTLY DISPLACE THE NUCLEI.

HEART

CONGESTION :
VESSELS OR SINUSOIDS ARE MARKEDLY DISTENDED WITH ERYTHROCYTES.

LUNG

HEMORRHAGE :
THERE IS EXTRAVASATION OF BLOOD.

PNEUMONIA :
THE ALVEOLAR WALLS ARE THICKENED AND ALVEOLI CONTAIN INFLAMMATORY CELLS AND FOAMY MACROPHAGES. PERIVASCULAR AND PERIBRONCHIAL LYMPHOCYTIC ACCUMULATIONS MAY BE PRESENT.

CONGESTION :

LUNG CONTINUED

VESSELS OR SINUSOIDS ARE MARKEDLY DISTENDED WITH ERYTHROCYTES.

STOMACH

ABSENT :
ORGAN OR TISSUE NOT REMOVED FROM ANIMAL OR NOT FOUND IN FIXATIVE.

LIVER

CONGESTION :
VESSELS OR SINUSOIDS ARE MARKEDLY DISTENDED WITH ERYTHROCYTES.

LEUKEMIC DEPOSITS :
ORGAN AND THE BLOOD ARE INVADED BY LEUKEMIC CELLS.

SPLEEN

*** LYMPHOMA LYMPHOCYTIC :
THE NEOPLASM OF THE RETICULAR SYSTEM ORIGINATES FROM LYMPHOCYTES.

KIDNEYS

INTERSTITIAL NEPHRITIS
UNILATERAL MULTIFOCAL
INFLAMMATORY CELLS FIBROSIS AND SOME TUBULAR ALTERATIONS ARE ASSOCIATED.

THYROIDS

ABSENT :
ORGAN OR TISSUE NOT REMOVED FROM ANIMAL OR NOT FOUND IN FIXATIVE.

SCIATIC NERVE

ABSENT :
ORGAN OR TISSUE NOT REMOVED FROM ANIMAL OR NOT FOUND IN FIXATIVE.

MALE 247 (1761/80)

BRAIN

ABSENT :
ORGAN OR TISSUE NOT REMOVED FROM ANIMAL OR NOT FOUND IN FIXATIVE.

BAYER AG

LUNG

AUTOLYSIS :
THE TISSUES EXHIBIT AUTOLYSIS AND THEY ARE NOT INTERPRETABLE.

STOMACH

AUTOLYSIS :
THE TISSUES EXHIBIT AUTOLYSIS AND THEY ARE NOT INTERPRETABLE.

LIVER

AUTOLYSIS PARTIAL :
NO OTHER CHANGES ARE SEEN. TISSUES ARE ALTERED.
BY POST-MORTEM MODIFICATIONS AND
DIAGNOSIS IS GIVEN WITH RESERVATION.

HEMORRAGIC CYST :
SEVERE MULTIFOCAL
ONE OR SEVERAL CAVITIES FILLED WITH BLOOD.

PANCREAS

AUTOLYSIS :
THE TISSUES EXHIBIT AUTOLYSIS AND THEY ARE NOT INTERPRETABLE.

SPLEEN

AUTOLYSIS :
THE TISSUES EXHIBIT AUTOLYSIS AND THEY ARE NOT INTERPRETABLE.

KIDNEYS

AUTOLYSIS :
BILATERAL MODERATE
THE TISSUES EXHIBIT AUTOLYSIS AND THEY ARE NOT INTERPRETABLE.

CYSTS :
BILATERAL MODERATE
ONE OR MORE CYSTS FILLED WITH CLEAR LIQUID ARE SEEN.

BLADDER

AUTOLYSIS :
THE TISSUES EXHIBIT AUTOLYSIS AND THEY ARE NOT INTERPRETABLE.

PITUITARY

AUTOLYSIS :
THE TISSUES EXHIBIT AUTOLYSIS AND THEY ARE NOT INTERPRETABLE.

THYROIDS

ABSENT :
ORGAN OR TISSUE NOT REMOVED FROM ANIMAL OR NOT FOUND IN

THYROIDS CONTINUED
FIXATIVE.

ADRENALS

AUTOLYSIS :
THE TISSUES EXHIBIT AUTOLYSIS AND THEY ARE NOT INTERPRETABLE.

TESTES

AUTOLYSIS :
THE TISSUES EXHIBIT AUTOLYSIS AND THEY ARE NOT INTERPRETABLE.

MALE 248 (1756/80)

BRAIN

VACUOLIZATION :
MODERATE FOCAL
IN THESE CELLS THERE ARE CLEAR VACUOLES GREATER IN NUMBER AND SIZE THAN NORMALLY FOUND.

HEART

CONGESTION :
VESSELS OR SINUSOIDS ARE MARKEDLY DISTENDED WITH ERYTHROCYTES.

LUNG

THROMBOSIS :
MULTIFOCAL
THE VASCULAR LUMEN CONTAINS AN ATTACHED ANTE MORTEM BLOOD CLOT.

PNEUMONIA :
MULTIFOCAL
THE ALVEOLAR WALLS ARE THICKENED AND ALVEOLI CONTAIN INFLAMMATORY CELLS AND FOAMY MACROPHAGES.PERIVASCULAR AND PERIBRONCHIAL LYMPHOCYTIC ACCUMULATIONS MAY BE PRESENT.

CONGESTION :
VESSELS OR SINUSOIDS ARE MARKEDLY DISTENDED WITH ERYTHROCYTES.

LIVER

HYPERPLASTIC NODULES :
MULTIFOCAL
WELL DEFINED ROUNDED FOCI OF HYPERPLASTIC AND HYPERTROPHIC CELLS ARE OBSERVED WITHIN THIS OTHERWISE NORMAL TISSUE.

BAYER AG

PANCREAS

AUTOLYSIS PARTIAL :
NO OTHER CHANGES ARE SEEN. TISSUES ARE ALTERED.
BY POST-MORTEM MODIFICATIONS AND
DIAGNOSIS IS GIVEN WITH RESERVATION.

SPLEEN

CONGESTION :
VESSELS OR SINUSOIDS ARE MARKEDLY DISTENDED WITH
ERYTHROCYTES.

KIDNEYS

PYELONEPHRITIS :
BILATERAL MODERATE
INFLAMMATION OF RENAL PARENCHYMA WITH OR WITHOUT
NECROSIS EXTENDED TO RENAL PELVIS.

THYROIDS

ABSENT :
ORGAN OR TISSUE NOT REMOVED FROM ANIMAL OR NOT FOUND IN
FIXATIVE.

MALE 249 (175a/60)

HEART

LEUKEMIC DEPOSITS :
ORGAN AND THE BLOOD ARE INVADED BY LEUKEMIC
CELLS.

LUNG

LEUKEMIC DEPOSITS :
ORGAN AND THE BLOOD ARE INVADED BY LEUKEMIC
CELLS.

STOMACH

LEUKEMIC DEPOSITS :
ORGAN AND THE BLOOD ARE INVADED BY LEUKEMIC
CELLS.

LIVER

CONGESTION :
VESSELS OR SINUSOIDS ARE MARKEDLY DISTENDED WITH
ERYTHROCYTES.

THYMUS

*** LYMPHOMA LYMPHOCYTIC :

THYMUS CONTINUED

THE NEOPLASM OF THE RETICULAR SYSTEM ORIGINATES FROM LYMPHOCYTES.

MALE 250 (1758/80)

LUNG

FIBROSIS :
MODERATE MULTIFOCAL
THERE IS AN INCREASE IN INTERSTITIAL FIBROUS TISSUE.

PNEUMONIA :
THE ALVEOLAR WALLS ARE THICKENED AND ALVEOLI CONTAIN INFLAMMATORY CELLS AND FOAMY MACROPHAGES.PERIVASCULAR AND PERIBRONCHIAL LYMPHOCYTIC ACCUMULATIONS MAY BE PRESENT.

LIVER

MONONUCLEAR CELLS :
MINIMAL MULTIFOCAL
FOCAL COLLECTIONS OF MONONUCLEAR CELLS ARE PRESENT.

PIGMENTATION :
MODERATE
NUMEROUS MACROPHAGES CONTAIN A GRANULAR BROWN CYTOPLASMIC PIGMENT.

SPLEEN

HEMATOPOIESIS :
MINIMAL
THE HEMATOPOIESIS IS EVIDENT.

KIDNEYS

CALCIFICATION :
UNILATERAL MINIMAL FOCAL
THERE ARE MINERAL DEPOSITS.

DILATATION OF GLOMERULAR LOOPS :
BILATERAL MINIMAL MULTIFOCAL
GLOMERULAR LOOPS APPEAR UNUSUALLY ENLARGED AND THIN.

PITUITARY

ABSENT :
ORGAN OR TISSUE NOT REMOVED FROM ANIMAL OR NOT FOUND IN FIXATIVE.

THYROIDS

ABSENT :
ORGAN OR TISSUE NOT REMOVED FROM ANIMAL OR NOT FOUND IN FIXATIVE.

BAYER AG

SM3. 1 CHRONIC TOXICITY STUDY IN MICE: SYSTEMATIC HISTOPATHOLOGY

PRODUCT : KNG 0519 GROUP : 3
ROUTE : DIETARY
TIME : 105 WEEKS DOSE : 2000 PPM
THIS GROUP COMPRISED : 17 MALES

THE FOLLOWING ORGANS WERE EXAMINED SYSTEMATICALLY :

HEART	LUNG	LIVER
PANCREAS	SPLEEN	KIDNEYS
BLADDER	STOMACH	TESTES
THYROIDS	ADRENALS	PITUITARY
BRAIN	SKELETAL MUSCLE	SCIATIC NERVE
FEMUR		

THESE ORGANS WERE EXAMINED IN 17 MALES .

INDIVIDUAL RESULTS

IN THE ANIMALS SHOWN BELOW THE HISTOLOGICAL EXAMINATION OF THE ORGANS LISTED OR OF THE ANOMALIES FOUND AT AUTOPSY GAVE THE FOLLOWING RESULTS :

MALE 306 (1552/80)

LUNG

*** ALVEOLOGENIC CARCINOMA :
A MALIGNANT TUMOR OF THE LUNG TISSUE WITH SYNONYMS IN MICE FOR ADENOMA, CARCINOMA, ALVEOLOGENIC PAPILLARY CARCINOMA, PAPILLARY CYSTADENOMA, ADENOCARCINOMA, BRONCHIOLAR CELL CARCINOMA, BRONCHIOLAR-ALVEOLAR TUMOR, TYPE A TUMOR, TYPE B TUMOR, INTERMEDIATE TYPE I TUMOR AND COMMON PULMONARY TUMOR OF THE MOUSE.

LIVER

HYPERPLASIA :
MULTIFOCAL
THERE IS AN EXAGGERATED INCREASE/DEVELOPMENT OF THE NORMAL TISSUE/GLAND IN THE ORGAN.

*** ADENOMA HEPATIC BENIGN :
DISTINCT NODULES COMPRESS THE ADJACENT LIVER PARENCHYMA, ARE CHARACTERIZED BY WELL DIFFERENTIATED HEPATOCYTES AND DO NOT SHOW PORTAL TRIADS.

VACUOLIZATION :
SEVERE MULTIFOCAL
IN THESE CELLS THERE ARE CLEAR VACUOLES GREATER IN NUMBER AND SIZE THAN NORMALLY FOUND.

SPLEEN

HEMATOPOIESIS :
SEVERE
THE HEMATOPOIESIS IS EVIDENT.

KIDNEYS

INTERSTITIAL NEPHRITIS :
BILATERAL MINIMAL MULTIFOCAL
INFLAMMATORY CELLS FIBROSIS AND SOME TUBULAR ALTERATIONS ARE ASSOCIATED.

CYSTS :
BILATERAL. MODERATE MULTIFOCAL
ONE OR MORE CYSTS FILLED WITH CLEAR LIQUID ARE SEEN.

THYROIDS

ABSENT :
ORGAN OR TISSUE NOT REMOVED FROM ANIMAL OR NOT FOUND IN FIXATIVE.

MALE 308 (1553/80)

LUNG

*** ALVEOLOGENIC CARCINOMA :
MULTIFOCAL
A MALIGNANT TUMOR OF THE LUNG TISSUE WITH SYNONYMS IN MICE FOR ADENOMA, CARCINOMA, ALVEOLOGENIC PAPILLARY CARCINOMA, PAPILLARY CYSTADENOMA, ADENOCARCINOMA, BRONCHIOLAR CELL CARCINOMA, BRONCHIOLAR-ALVEOLAR TUMOR, TYPE A TUMOR, TYPE B TUMOR, INTERMEDIATE TYPE I TUMOR AND COMMON PULMONARY TUMOR OF THE MOUSE.

LIVER

HYPERPLASIA :
MULTIFOCAL
THERE IS AN EXAGGERATED INCREASE/DEVELOPMENT OF THE NORMAL TISSUE/GLAND IN THE ORGAN.

MONONUCLEAR CELLS :
FOCAL COLLECTIONS OF MONONUCLEAR CELLS ARE PRESENT.

HYPERPLASTIC NODULES :
MULTIFOCAL
WELL DEFINED ROUNDED FOCI OF HYPERPLASTIC AND HYPERTROPHIC CELLS ARE OBSERVED WITHIN THIS OTHERWISE NORMAL TISSUE.

BAYER AG BAYER AG BAYER AG

KIDNEYS

CYSTS :
BILATERAL MINIMAL MULTIFOCAL
ONE OR MORE CYSTS FILLED WITH CLEAR LIQUID ARE SEEN.

THYROIDS _

CYSTS :
UNILATERAL
ONE OR MORE CYSTS FILLED WITH CLEAR LIQUID ARE SEEN.

ADRENALS

*** PHEOCHROMOCYTOMA :
UNILATERAL
THIS TUMOR IS COMPOSED OF POLYHEDRAL CELLS WHICH ARISE FROM THE CHROMAFFIN CELLS OF THE ADRENAL MEDULLA AND FORM LOBULES SEPARATED BY VASCULAR CONNECTIVE TISSUE SEPTA.

TESTES

CALCIFICATION :
UNILATERAL MINIMAL FOCAL
THERE ARE MINERAL DEPOSITS.

MALE 310 (1554/60)

LUNG

*** ALVEOLOGENIC CARCINOMA :
A MALIGNANT TUMOR OF THE LUNG TISSUE WITH SYNONYMS IN MICE FOR ADENOMA, CARCINOMA, ALVEOLOGENIC PAPILLARY CARCINOMA, PAPILLARY CYSTADENOMA, ADENOCARCINOMA, BRONCHIOLAR CELL CARCINOMA, BRONCHIOLAR-ALVEOLAR TUMOR, TYPE A TUMOR, TYPE C TUMOR, INTERMEDIATE TYPE I TUMOR AND COMMON PULMONARY TUMOR OF THE MOUSE.

LIVER

HYPERPLASIA :
MULTIFOCAL
THERE IS AN EXAGGERATED INCREASE/DEVELOPMENT OF THE NORMAL TISSUE/GLAND IN THE ORGAN.

CALCIFICATION :
SEVERE MULTIFOCAL
THERE ARE MINERAL DEPOSITS.

MONONUCLEAR CELLS :
MULTIFOCAL
FOCAL COLLECTIONS OF MONONUCLEAR CELLS ARE PRESENT.

HYPERPLASTIC NODULES :
MULTIFOCAL

SM3. 4 MALE 310 CONTINUED

LIVER CONTINUED

WELL DEFINED ROUNDED FOCI OF HYPERPLASTIC AND HYPERTROPHIC CELLS ARE OBSERVED WITHIN THIS OTHERWISE NORMAL TISSUE.

PANCREAS

NORMAL :
HISTOLOGICAL ASPECT WITHIN NORMAL LIMITS.

SPLEEN

HEMATOPOIESIS :
SEVERE
THE HEMATOPOIESIS IS EVIDENT.

KIDNEYS

INTERSTITIAL NEPHRITIS :
UNILATERAL MINIMAL MULTIFOCAL
INFLAMMATORY CELLS FIBROSIS AND SOME TUBULAR ALTERATIONS ARE ASSOCIATED.

CYSTS :
BILATERAL MINIMAL MULTIFOCAL
ONE OR MORE CYSTS FILLED WITH CLEAR LIQUID ARE SEEN.

BLADDER

HYPERPLASIA PAPILLOMATOUS :
THE THICKNESS OF THE MUCOSA IS INCREASED MAKING UNUSUALLY HIGH AND NUMEROUS FOLDS.

PITUITARY

ABSENT :
ORGAN OR TISSUE NOT REMOVED FROM ANIMAL OR NOT FOUND IN FIXATIVE.

THYROIDS

ABSENT :
ORGAN OR TISSUE NOT REMOVED FROM ANIMAL OR NOT FOUND IN FIXATIVE.

MALE 312 (1555/80)

LUNG

ATELECTASIS :
MULTIFOCAL
THERE IS COLLAPSE OF ALVEOLI.

SPLEEN

HEMATOPOIESIS :
MODERATE

BAYER AG

SPLEEN CONTINUED
THE HEMATOPOIESIS IS EVIDENT.

KIDNEYS

INTERSTITIAL NEPHRITIS :
BILATERAL MODERATE MULTIFOCAL
INFLAMMATORY CELLS FIBROSIS AND SOME TUBULAR ALTERATIONS ARE ASSOCIATED.

CYSTS :
UNILATERAL MODERATE MULTIFOCAL
ONE OR MORE CYSTS FILLED WITH CLEAR LIQUID ARE SEEN.

BLADDER

HYPERPLASIA PAPILLOMATOUS :
THE THICKNESS OF THE MUCOSA IS INCREASED MAKING UNUSUALLY HIGH AND NUMEROUS FOLDS.

PITUITARY

ABSENT :
ORGAN OR TISSUE NOT REMOVED FROM ANIMAL OR NOT FOUND IN FIXATIVE.

TESTES

CALCIFICATION :
UNILATERAL SEVERE MULTIFOCAL
THERE ARE MINERAL DEPOSITS.

SPERMATOCELE :
UNILATERAL
FOCAL CYSTIC DILATATION CONTAINING SPERMATOZOA IS PRESENT.

MALE 315 (1556/80)

STOMACH

MUCOID CYST :
MODERATE MULTIFOCAL
ONE OR MORE CYSTS CONTAINING MUCOID MATERIAL ARE OBSERVED.

LIVER

*** ADENOMA HEPATIC BENIGN :
DISTINCT NODULES COMPRESS THE ADJACENT LIVER PARENCHYMA. ARE CHARACTERIZED BY WELL DIFFERENTIATED HEPATOCYTES AND DO NOT SHOW PORTAL TRIADS.

HYPERPLASTIC NODULES :
MULTIFOCAL
WELL DEFINED ROUNDED FOCI OF HYPERPLASTIC AND HYPERTROPHIC CELLS ARE OBSERVED WITHIN THIS OTHERWISE NORMAL TISSUE.

KIDNEYS

HYDRONEPHROSIS :
UNILATERAL
THE RENAL PELVIS IS DILATED AND THE ADJACENT PARENCHYMA IS REDUCED.

INTERSTITIAL NEPHRITIS :
BILATERAL MINIMAL MULTIFOCAL
INFLAMMATORY CELLS FIBROSIS AND SOME TUBULAR ALTERATIONS ARE ASSOCIATED.

CYSTS :
BILATERAL SEVERE MULTIFOCAL
ONE OR MORE CYSTS FILLED WITH CLEAR LIQUID ARE SEEN.

THYROIDS

CYSTS :
UNILATERAL
ONE OR MORE CYSTS FILLED WITH CLEAR LIQUID ARE SEEN.

ADRENALS

*** ADENOMA :
UNILATERAL
THIS IS BENIGN GLANDULAR EPITHELIAL TUMOR.

MALE 322 (1557/80)

LUNG

CONGESTION :
VESSELS OR SINUSOIDS ARE MARKEDLY DISTENDED WITH ERYTHROCYTES.

PANCREAS

FIBROSIS :
MINIMAL MULTIFOCAL
THERE IS AN INCREASE IN INTERSTITIAL FIBROUS TISSUE.

SPLEEN

HEMATOPOIESIS :
MODERATE
THE HEMATOPOIESIS IS EVIDENT.

KIDNEYS

INTERSTITIAL NEPHRITIS :
BILATERAL MINIMAL MULTIFOCAL
INFLAMMATORY CELLS FIBROSIS AND SOME TUBULAR ALTERATIONS ARE ASSOCIATED.

BAYER AG

BLADDER

*** CARCINOSARCOMA :
IRREGULAR NESTS OF EPITHELIAL CELLS ARE CLOSELY INTERMIXED WITH MALIGNANT SPINDLE CELLS.

PITUITARY

ABSENT :
ORGAN OR TISSUE NOT REMOVED FROM ANIMAL OR NOT FOUND IN FIXATIVE.

SEMINAL VESICLES

ATROPHY EPITHELIAL :
THE EPITHELIAL TISSUE IS ATROPHIC AND SCANTY WITH INCREASED FIBROUS STROMA.

ECTASIA SIMPLE :
THE LUMEN OF THE ORGAN IS ABNORMALLY ENLARGED.

COAGULUM :
AN ACIDOPHILIC STRUCTURE RESEMBLING COAGULATED PROTEIN IS PRESENT IN THE LUMEN.

MALE 327 (1556/80)

LUNG

PNEUMONIA :
MODERATE
THE ALVEOLAR WALLS ARE THICKENED AND ALVEOLI CONTAIN INFLAMMATORY CELLS AND FOAMY MACROPHAGES.PERIVASCULAR AND PERIBRONCHIAL LYMPHOCYTIC ACCUMULATIONS MAY BE PRESENT.

SPLEEN

*** LYMPHOMA LYMPHOCYTIC :
THE NEOPLASM OF THE RETICULAR SYSTEM ORIGINATES FROM LYMPHOCYTES.

KIDNEYS

LEUKEMIC DEPOSITS :
ORGAN AND THE BLOOD ARE INVADED BY LEUKEMIC CELLS.

SCIATIC NERVE

ABSENT :
ORGAN OR TISSUE NOT REMOVED FROM ANIMAL OR NOT FOUND IN FIXATIVE.

TESTES

CALCIFICATION :
UNILATERAL MODERATE MULTIFOCAL
THERE ARE MINERAL DEPOSITS.

SPERMATOCELE :
UNILATERAL
FOCAL CYSTIC DILATATION CONTAINING SPERMATOZOA IS PRESENT.

MALE 331 (1559/80)

LIVER

HYPERPLASTIC NODULE :
A NODULE OF HYPERPLASTIC TISSUE IS PRESENT.

SPLEEN

HEMATOPOIESIS :
MODERATE
THE HEMATOPOIESIS IS EVIDENT.

PITUITARY

ABSENT :
ORGAN OR TISSUE NOT REMOVED FROM ANIMAL OR NOT FOUND IN FIXATIVE.

ADRENALS

HYPERPLASIA OF THE GLOMERULAR LAYER :
UNILATERAL MINIMAL FOCAL
THE GLOMERULAR LAYER IS THICKER THAN NORMAL.

TESTES

SPERMATOCELE :
UNILATERAL
FOCAL CYSTIC DILATATION CONTAINING SPERMATOZOA IS PRESENT.

FEMUR

ABSENT :
ORGAN OR TISSUE NOT REMOVED FROM ANIMAL OR NOT FOUND IN FIXATIVE.

MALE 332 (1560/80)

BAYER AG BAYER AG BAYER AG

LUNG

*** ALVEOLOGENIC CARCINOMA :
A MALIGNANT TUMOR OF THE LUNG TISSUE WITH SYNONYMS IN MICE FOR ADENOMA, CARCINOMA, ALVEOLOGENIC PAPILLARY CARCINOMA, PAPILLARY CYSTADENOMA, ADENOCARCINOMA, BRONCHIOLAR CELL CARCINOMA, BRONCHIOLAR-ALVEOLAR TUMOR, TYPE A TUMOR, TYPE B TUMOR, INTERMEDIATE TYPE I TUMOR AND COMMON PULMONARY TUMOR OF THE MOUSE.

LIVER

CYSTS :
ONE OR MORE CYSTS FILLED WITH CLEAR LIQUID ARE SEEN.

PITUITARY

ABSENT :
ORGAN OR TISSUE NOT REMOVED FROM ANIMAL OR NOT FOUND IN FIXATIVE.

ADRENALS

ABSENT :
ORGAN OR TISSUE NOT REMOVED FROM ANIMAL OR NOT FOUND IN FIXATIVE.

MALE 334 (1561/60)

LUNG

MUCOID CYST :
FOCAL
ONE OR MORE CYSTS CONTAINING MUCOID MATERIAL ARE OBSERVED.

PIGMENTATION :
UNILATERAL
NUMEROUS MACROPHAGES CONTAIN A GRANULAR BROWN CYTOPLASMIC PIGMENT.

LIVER

HYPERTROPHY :
THE SIZE OF THE ORGAN IS INCREASED WITHOUT STRUCTURAL ANOMALY.

PANCREAS

NORMAL :
HISTOLOGICAL ASPECT WITHIN NORMAL LIMITS.

THYROIDS

CYSTS :
ONE OR MORE CYSTS FILLED WITH CLEAR LIQUID ARE SEEN.

ADRENALS

*** ADENOMA :
UNILATERAL
THIS IS BENIGN GLANDULAR EPITHELIAL TUMOR.

TESTES

CALCIFICATION :
UNILATERAL MINIMAL MULTIFOCAL
THERE ARE MINERAL DEPOSITS.

MALE 335 (1562/80)

HEART

VENTRICULAR DILATATION :
ORGAN CHAMBERS ARE ENLARGED.

LUNG

*** ALVEOLOGENIC CARCINOMA :
A MALIGNANT TUMOR OF THE LUNG TISSUE WITH SYNONYMS IN MICE FOR ADENOMA, CARCINOMA, ALVEOLOGENIC PAPILLARY CARCINOMA, PAPILLARY CYSTADENOMA, ADENOCARCINOMA, BRONCHIOLAR CELL CARCINOMA, BRONCHIOLAR-ALVEOLAR TUMOR, TYPE A TUMOR, TYPE B TUMOR, INTERMEDIATE TYPE I TUMOR AND COMMON PULMONARY TUMOR OF THE MOUSE.

LIVER

HEPATOCYTIC HYPERPIGMENTATION :
HEPATOCYTES ARE LADEN WITH GRANULES OF HEMOSIDERIN OR BILE OR OTHER PIGMENT.

PANCREAS

NORMAL :
HISTOLOGICAL ASPECT WITHIN NORMAL LIMITS.

SPLEEN

HEMATOPOIESIS :
MINIMAL
THE HEMATOPOIESIS IS EVIDENT.

BAYER AG

KIDNEYS

INTERSTITIAL NEPHRITIS :
UNILATERAL MINIMAL MULTIFOCAL
INFLAMMATORY CELLS FIBROSIS AND SOME TUBULAR ALTERATIONS ARE ASSOCIATED.

BLADDER

HYPERPLASIA EPITHELIAL :
MULTIFOCAL
THERE IS AN INCREASE IN THE NUMBER OF THE EPITHELIAL CELLS.

COAGULUM :
AN ACIDOPHILIC STRUCTURE RESEMBLING COAGULATED PROTEIN IS PRESENT IN THE LUMEN.

MALE 336 (1563/80)

LUNG

*** ALVEOLOGENIC CARCINOMA :
A MALIGNANT TUMOR OF THE LUNG TISSUE WITH SYNONYMS IN MICE FOR ADENOMA, CARCINOMA, ALVEOLOGENIC PAPILLARY CARCINOMA, PAPILLARY CYSTADENOMA, ADENOCARCINOMA, BRONCHIOLAR CELL CARCINOMA, BRONCHIOLAR-ALVEOLAR TUMOR, TYPE A TUMOR, TYPE B TUMOR, INTERMEDIATE TYPE I TUMOR AND COMMON PULMONARY TUMOR OF THE MOUSE.

LIVER

HYPERPLASIA FOCAL :
FOCAL
WELL DEFINED ROUND FOCUS OF HYPERPLASTIC CELLS IS OBSERVED WITHIN THIS OTHERWISE NORMAL TISSUE.

PANCREAS

INFLAMMATION CHRONIC :
MINIMAL
THE INTERSTITIAL TISSUES SHOW INFILTRATION BY MONONUCLEAR CELLS AND INCREASE IN FIBROUS STROMA.

KIDNEYS

CALCIFICATION :
UNILATERAL MINIMAL MULTIFOCAL
THERE ARE MINERAL DEPOSITS.

HYDRONEPHROSIS :
UNILATERAL
THE RENAL PELVIS IS DILATED AND THE ADJACENT PARENCHYMA IS REDUCED.

PITUITARY

ABSENT :
ORGAN OR TISSUE NOT REMOVED FROM ANIMAL OR NOT FOUND IN FIXATIVE.

ADRENALS

CALCIFICATION :
UNILATERAL MODERATE FOCAL
THERE ARE MINERAL DEPOSITS.

PIGMENTATION :
BILATERAL MODERATE
NUMEROUS MACROPHAGES CONTAIN A GRANULAR BROWN CYTOPLASMIC PIGMENT.

*** ADENOMA :
UNILATERAL
THIS IS BENIGN GLANDULAR EPITHELIAL TUMOR.

MALE 338 (1564/80)

LIVER

HYPERPLASTIC NODULES :
WELL DEFINED ROUNDED FOCI OF HYPERPLASTIC AND HYPERTROPHIC CELLS ARE OBSERVED WITHIN THIS OTHERWISE NORMAL TISSUE.

PANCREAS

NORMAL :
HISTOLOGICAL ASPECT WITHIN NORMAL LIMITS.

KIDNEYS

INTERSTITIAL NEPHRITIS :
UNILATERAL MINIMAL MULTIFOCAL
INFLAMMATORY CELLS FIBROSIS AND SOME TUBULAR ALTERATIONS ARE ASSOCIATED.

THYROIDS

CYSTS :
BILATERAL MINIMAL
ONE OR MORE CYSTS FILLED WITH CLEAR LIQUID ARE SEEN.

TESTES

ATROPHY SEMINIFEROUS :
UNILATERAL MODERATE MULTIFOCAL
THERE IS ATROPHY OF SEMINIFEROUS TUBULES WITH DIMINISHED SPERMATOGENIC ACTIVITY.

SPERMATOCELE :
UNILATERAL MODERATE FOCAL

BAYER AG

SM3.13 MALE 338 CONTINUED

TESTES CONTINUED
FOCAL CYSTIC DILATATION CONTAINING SPERMATOZOA IS PRESENT.

MALE 342 (1565/00)

LIVER

*** ADENOMA HEPATIC BENIGN :
DISTINCT NODULES COMPRESS THE ADJACENT LIVER PARENCHYMA, ARE CHARACTERIZED BY WELL DIFFERENTIATED HEPATOCYTES AND DO NOT SHOW PORTAL TRIADS.

LEUKEMIC DEPOSITS :
ORGAN AND THE BLOOD ARE INVADED BY LEUKEMIC CELLS.

HEPATOCYTIC HYPERPIGMENTATION :
HEPATOCYTES ARE LADEN WITH GRANULES OF HEMOSIDERIN OR BILE OR OTHER PIGMENT.

SPLEEN

*** LYMPHOMA LYMPHOCYTIC :
THE NEOPLASM OF THE RETICULAR SYSTEM ORIGINATES FROM LYMPHOCYTES.

KIDNEYS

LEUKEMIC DEPOSITS :
ORGAN AND THE BLOOD ARE INVADED BY LEUKEMIC CELLS.

BLADDER

LEUKEMIC DEPOSITS :
ORGAN AND THE BLOOD ARE INVADED BY LEUKEMIC CELLS.

THYROIDS

ABSENT :
ORGAN OR TISSUE NOT REMOVED FROM ANIMAL OR NOT FOUND IN FIXATIVE.

ADRENALS

LEUKEMIC DEPOSITS :
ORGAN AND THE BLOOD ARE INVADED BY LEUKEMIC CELLS.

MALE 343 (1566/80)

LUNG

PNEUMONIA :
MINIMAL
THE ALVEOLAR WALLS ARE THICKENED AND ALVEOLI CONTAIN INFLAMMATORY CELLS AND FOAMY MACROPHAGES.PERIVASCULAR AND PERIBRONCHIAL LYMPHOCYTIC ACCUMULATIONS MAY BE PRESENT.

LIVER

*** ADENOMA HEPATIC BENIGN :
DISTINCT NODULES COMPRESS THE ADJACENT LIVER PARENCHYMA, ARE CHARACTERIZED BY WELL DIFFERENTIATED HEPATOCYTES AND DO NOT SHOW PORTAL TRIADS.

MONONUCLEAR CELLS :
SEVERE
FOCAL COLLECTIONS OF MONONUCLEAR CELLS ARE PRESENT.

HEPATOCYTIC HYPERPIGMENTATION :
HEPATOCYTES ARE LADEN WITH GRANULES OF HEMOSIDERIN OR BILE OR OTHER PIGMENT.

SPLEEN

PIGMENTATION :
NUMEROUS MACROPHAGES CONTAIN A GRANULAR BROWN CYTOPLASMIC PIGMENT.

KIDNEYS

INTERSTITIAL NEPHRITIS :
BILATERAL MINIMAL MULTIFOCAL
INFLAMMATORY CELLS FIBROSIS AND SOME TUBULAR ALTERATIONS ARE ASSOCIATED.

PITUITARY

ABSENT :
ORGAN OR TISSUE NOT REMOVED FROM ANIMAL OR NOT FOUND IN FIXATIVE.

ADRENALS

PIGMENTATION :
UNILATERAL MODERATE
NUMEROUS MACROPHAGES CONTAIN A GRANULAR BROWN CYTOPLASMIC PIGMENT.

TESTES

ATROPHY SEMINIFEROUS :
UNILATERAL MODERATE MULTIFOCAL

BAYER AG

SM3.15 MALE 343 CONTINUED

TESTES CONTINUED
THERE IS ATROPHY OF SEMINIFEROUS TUBULES WITH DIMINISHED SPERMATOGENIC ACTIVITY.

CALCIFICATION :
BILATERAL MINIMAL MULTIFOCAL
THERE ARE MINERAL DEPOSITS.

MALE 345 (1507/00)

HEART

INFLAMMATION CHRONIC :
MULTIFOCAL
THE INTERSTITIAL TISSUES SHOW INFILTRATION BY MONONUCLEAR CELLS AND INCREASE IN FIBROUS STROMA.

LIVER

*** ADENOMA HEPATIC BENIGN :
DISTINCT NODULES COMPRESS THE ADJACENT LIVER PARENCHYMA. ARE CHARACTERIZED BY WELL DIFFERENTIATED HEPATOCYTES AND DO NOT SHOW PORTAL TRIADS.

HEMORRHAGE :
THERE IS EXTRAVASATION OF BLOOD.

KIDNEYS

INTERSTITIAL NEPHRITIS :
BILATERAL MODERATE MULTIFOCAL
INFLAMMATORY CELLS FIBROSIS AND SOME TUBULAR ALTERATIONS ARE ASSOCIATED.

CYSTS :
UNILATERAL MINIMAL FOCAL
ONE OR MORE CYSTS FILLED WITH CLEAR LIQUID ARE SEEN.

THYROIDS

CYSTS :
BILATERAL
ONE OR MORE CYSTS FILLED WITH CLEAR LIQUID ARE SEEN.

TESTES

CALCIFICATION :
BILATERAL MINIMAL MULTIFOCAL
THERE ARE MINERAL DEPOSITS.

MALE 340 (1566/00)

SPLEEN

HEMATOPOIESIS :
MINIMAL
THE HEMATOPOIESIS IS EVIDENT.

KIDNEYS

TUBULOPATHY :
BILATERAL MINIMAL MULTIFOCAL
TUBULAR DEGENERATIVE CHANGES ARE PRESENT
WHICH MAY BE ASSOCIATED WITH TUBULAR DILATATION.

INTERSTITIAL NEPHRITIS :
BILATERAL MINIMAL MULTIFOCAL
INFLAMMATORY CELLS FIBROSIS AND SOME TUBULAR ALTERATIONS
ARE ASSOCIATED.

THYROIDS

ABSENT :
ORGAN OR TISSUE NOT REMOVED FROM ANIMAL OR NOT FOUND IN
FIXATIVE.

TESTES

ATROPHY SEMINIFEROUS :
UNILATERAL MODERATE MULTIFOCAL
THERE IS ATROPHY OF SEMINIFEROUS TUBULES WITH DIMINISHED
SPERMATOGENIC ACTIVITY.

CALCIFICATION :
CONTRALATERAL MODERATE MULTIFOCAL
THERE ARE MINERAL DEPOSITS.

SPERMATOCELE :
UNILATERAL MINIMAL MULTIFOCAL
FOCAL CYSTIC DILATATION CONTAINING SPERMATOZOA IS PRESENT.

BAYER AG BAYER AG BAYER AG

NM3. 1 CHRONIC TOXICITY STUDY IN MICE: NONSYSTEMATIC HISTOPATHOLOGY

PRODUCT : KWG 0519 GROUP : 3
ROUTE : DIETARY
TIME : 105 WEEKS DOSE : 2000 PPM
THIS GROUP COMPRISED : 33 MALES

THE FOLLOWING ORGANS WERE EXAMINED SYSTEMATICALLY :

HEART	LUNG	LIVER
PANCREAS	SPLEEN	KIDNEYS
BLADDER	STOMACH	TESTES
THYROIDS	ADRENALS	PITUITARY
BRAIN	SKELETAL MUSCLE	SCIATIC NERVE
FEMUR		

THESE ORGANS WERE EXAMINED IN 33 MALES

INDIVIDUAL RESULTS

IN THE ANIMALS SHOWN BELOW THE HISTOLOGICAL EXAMINATION OF THE ORGANS LISTED OR OF THE ANOMALIES FOUND AT AUTOPSY GAVE THE FOLLOWING RESULTS :

MALE 301 (1649/80)

HEART

LEUKEMIC DEPOSITS :
ORGAN AND THE BLOOD ARE INVADED BY LEUKEMIC CELLS.

LUNG

*** ALVEOLOGENIC CARCINOMA :
A MALIGNANT TUMOR OF THE LUNG TISSUE WITH SYNONYMS IN MICE FOR ADENOMA, CARCINOMA, ALVEOLOGENIC PAPILLARY CARCINOMA, PAPILLARY CYSTADENOMA, ADENOCARCINOMA, BRONCHIOLAR CELL CARCINOMA, BRONCHIOLAR-ALVEOLAR TUMOR, TYPE A TUMOR, TYPE B TUMOR, INTERMEDIATE TYPE I TUMOR AND COMMON PULMONARY TUMOR OF THE MOUSE.

STOMACH

UNREADABLE :
IT IS NOT POSSIBLE TO INTERPRET THE SECTION DUE TO AN ARTIFACT CAUSED BY SAMPLING OR HISTOLOGICAL TECHNIQUE.

LIVER

LEUKEMIC DEPOSITS :
ORGAN AND THE BLOOD ARE INVADED BY LEUKEMIC CELLS.

PANCREAS

LEUKEMIC DEPOSITS :
ORGAN AND THE BLOOD ARE INVADED BY LEUKEMIC CELLS.

SPLEEN

*** LYMPHOMA LYMPHOCYTIC :
THE NEOPLASM OF THE RETICULAR SYSTEM ORIGINATES FROM LYMPHOCYTES.

KIDNEYS

LEUKEMIC DEPOSITS :
ORGAN AND THE BLOOD ARE INVADED BY LEUKEMIC CELLS.

PITUITARY

ABSENT :
ORGAN OR TISSUE NOT REMOVED FROM ANIMAL OR NOT FOUND IN FIXATIVE.

THYROIDS

ABSENT :
ORGAN OR TISSUE NOT REMOVED FROM ANIMAL OR NOT FOUND IN FIXATIVE.

ADRENALS

LEUKEMIC DEPOSITS :
BILATERAL
ORGAN AND THE BLOOD ARE INVADED BY LEUKEMIC CELLS.

TESTES

ATROPHY SEMINIFEROUS :
BILATERAL MODERATE
THERE IS ATROPHY OF SEMINIFEROUS TUBULES WITH DIMINISHED SPERMATOGENIC ACTIVITY.

CALCIFICATION :
UNILATERAL MODERATE MULTIFOCAL
THERE ARE MINERAL DEPOSITS.

SPERMATOCELE :
UNILATERAL MODERATE
FOCAL CYSTIC DILATATION CONTAINING SPERMATOZOA IS PRESENT.

LYMPH NODE

*** LYMPHOMA LYMPHOCYTIC :
THE NEOPLASM OF THE RETICULAR SYSTEM ORIGINATES FROM LYMPHOCYTES.

BAYER AG

MALE 302 (1839/80)

HEART

CONGESTION :
VESSELS OR SINUSOIDS ARE MARKEDLY DISTENDED WITH ERYTHROCYTES.

LUNG

*** FIBROMA :
WITHIN THIS ENCAPSULATED SPINDLE CELL TUMOR THERE IS COLLAGEN FORMATION.

STOMACH

HEMORRHAGE :
MINIMAL MULTIFOCAL
THERE IS EXTRAVASATION OF BLOOD.

LIVER

CALCIFICATION :
MODERATE MULTIFOCAL
THERE ARE MINERAL DEPOSITS.

*** ADENOMA HEPATIC BENIGN :
DISTINCT NODULES COMPRESS THE ADJACENT LIVER PARENCHYMA, ARE CHARACTERIZED BY WELL DIFFERENTIATED HEPATOCYTES AND DO NOT SHOW PORTAL TRIADS.

CONGESTION :
SEVERE
VESSELS OR SINUSOIDS ARE MARKEDLY DISTENDED WITH ERYTHROCYTES.

HYALINOSIS :
DEPOSITS OF HYALINIC MATERIAL IS OBSERVED IN THE TISSUE.

HEPATOCYTIC HYPERPIGMENTATION :
HEPATOCYTES ARE LADEN WITH GRANULES OF HEMOSIDERIN OR BILE OR OTHER PIGMENT.

PANCREAS

INFLAMMATION CHRONIC :
MINIMAL MULTIFOCAL
THE INTERSTITIAL TISSUES SHOW INFILTRATION BY MONONUCLEAR CELLS AND INCREASE IN FIBROUS STROMA.

SPLEEN

HEMATOPOIESIS :
SEVERE
THE HEMATOPOIESIS IS EVIDENT.

KIDNEYS

INTERSTITIAL NEPHRITIS :
BILATERAL MINIMAL MULTIFOCAL
INFLAMMATORY CELLS FIBROSIS AND SOME TUBULAR ALTERATIONS ARE ASSOCIATED.

CYSTS :
BILATERAL MINIMAL MULTIFOCAL
ONE OR MORE CYSTS FILLED WITH CLEAR LIQUID ARE SEEN.

PITUITARY

ABSENT :
ORGAN OR TISSUE NOT REMOVED FROM ANIMAL OR NOT FOUND IN FIXATIVE.

THYROIDS

CYSTS :
BILATERAL
ONE OR MORE CYSTS FILLED WITH CLEAR LIQUID ARE SEEN.

ADRENALS

ABSENT :
ORGAN OR TISSUE NOT REMOVED FROM ANIMAL OR NOT FOUND IN FIXATIVE.

SKELETAL MUSCLE

ABSENT :
ORGAN OR TISSUE NOT REMOVED FROM ANIMAL OR NOT FOUND IN FIXATIVE.

SCIATIC NERVE

ABSENT :
ORGAN OR TISSUE NOT REMOVED FROM ANIMAL OR NOT FOUND IN FIXATIVE.

SEMINAL VESICLES

ATROPHY EPITHELIAL :
THE EPITHELIAL TISSUE IS ATROPHIC AND SCANTY WITH INCREASED FIBROUS STROMA.

COAGULUM :
AN ACIDOPHILIC STRUCTURE RESEMBLING COAGULATED PROTEIN IS PRESENT IN THE LUMEN.

FEMUR

ABSENT :
ORGAN OR TISSUE NOT REMOVED FROM ANIMAL OR NOT FOUND IN FIXATIVE.

BAYER AG

MALE 303 (1623/80)

HEART

CONGESTION :
MODERATE FOCAL
VESSELS OR SINUSOIDS ARE MARKEDLY DISTENDED WITH ERYTHROCYTES.

LUNG

EDEMA :
THE INTERSTITIAL TISSUES CONTAIN AN INCREASED AMOUNT OF FLUID.

CONGESTION :
SEVERE
VESSELS OR SINUSOIDS ARE MARKEDLY DISTENDED WITH ERYTHROCYTES.

LIVER

CONGESTION :
VESSELS OR SINUSOIDS ARE MARKEDLY DISTENDED WITH ERYTHROCYTES.

SPLEEN

HEMATOPOIESIS :
SEVERE
THE HEMATOPOIESIS IS EVIDENT.

KIDNEYS

TUBULOPATHY :
BILATERAL MODERATE MULTIFOCAL
TUBULAR DEGENERATIVE CHANGES ARE PRESENT WHICH MAY BE ASSOCIATED WITH TUBULAR DILATATION.

INTERSTITIAL NEPHRITIS :
BILATERAL MINIMAL MULTIFOCAL
INFLAMMATORY CELLS FIBROSIS AND SOME TUBULAR ALTERATIONS ARE ASSOCIATED.

BLADDER

UNREADABLE :
IT IS NOT POSSIBLE TO INTERPRET THE SECTION DUE TO AN ARTIFACT CAUSED BY SAMPLING OR HISTOLOGICAL TECHNIQUE.

SKIN

INFLAMMATION CHRONIC :
MODERATE
THE INTERSTITIAL TISSUES SHOW INFILTRATION BY MONONUCLEAR

SKIN CONTINUED

CELLS AND INCREASE IN FIBROUS STROMA.

TESTES

SPERMATOCELE :
UNILATERAL MODERATE
FOCAL CYSTIC DILATATION CONTAINING SPERMATOZOA IS PRESENT.

MALE 304 (1838/80)

HEART

FIBROSIS :
MODERATE MULTIFOCAL
THERE IS AN INCREASE IN INTERSTITIAL FIBROUS TISSUE.

MONONUCLEAR CELLS :
MODERATE MULTIFOCAL
FOCAL COLLECTIONS OF MONONUCLEAR CELLS ARE PRESENT.

KIDNEYS

INTERSTITIAL NEPHRITIS :
UNILATERAL MINIMAL MULTIFOCAL
INFLAMMATORY CELLS FIBROSIS AND SOME TUBULAR ALTERATIONS ARE ASSOCIATED.

PITUITARY

ABSENT :
ORGAN OR TISSUE NOT REMOVED FROM ANIMAL OR NOT FOUND IN FIXATIVE.

THYROIDS

ABSENT :

ORGAN OR TISSUE NOT REMOVED FROM ANIMAL OR NOT FOUND IN FIXATIVE.

SKELETAL MUSCLE

ABSENT :
ORGAN OR TISSUE NOT REMOVED FROM ANIMAL OR NOT FOUND IN FIXATIVE.

SCIATIC NERVE

ABSENT :
ORGAN OR TISSUE NOT REMOVED FROM ANIMAL OR NOT FOUND IN FIXATIVE.

BAYER AG

FEMUR

ABSENT :
ORGAN OR TISSUE NOT REMOVED FROM ANIMAL OR NOT FOUND IN FIXATIVE.

MALE 305 (1822/80)

BRAIN

AUTOLYSIS PARTIAL :
NO OTHER CHANGES ARE SEEN. TISSUES ARE ALTERED.
BY POST-MORTEM MODIFICATIONS AND
DIAGNOSIS IS GIVEN WITH RESERVATION.

HEART

AUTOLYSIS PARTIAL :
NO OTHER CHANGES ARE SEEN. TISSUES ARE ALTERED.
BY POST-MORTEM MODIFICATIONS AND
DIAGNOSIS IS GIVEN WITH RESERVATION.

LUNG

ABSENT :
ORGAN OR TISSUE NOT REMOVED FROM ANIMAL OR NOT FOUND IN FIXATIVE.

STOMACH

AUTOLYSIS :
THE TISSUES EXHIBIT AUTOLYSIS AND THEY ARE NOT INTERPRETABLE.

LIVER

AUTOLYSIS :
THE TISSUES EXHIBIT AUTOLYSIS AND THEY ARE NOT INTERPRETABLE.

AUTOLYSIS :
THE TISSUES EXHIBIT AUTOLYSIS AND THEY ARE NOT INTERPRETABLE.

PANCREAS

AUTOLYSIS :
THE TISSUES EXHIBIT AUTOLYSIS AND THEY ARE NOT INTERPRETABLE.

SPLEEN

AUTOLYSIS :
THE TISSUES EXHIBIT AUTOLYSIS AND THEY ARE NOT INTERPRETABLE.

KIDNEYS

AUTOLYSIS :
THE TISSUES EXHIBIT AUTOLYSIS AND THEY ARE NOT INTERPRETABLE.

BLADDER

AUTOLYSIS PARTIAL :
NO OTHER CHANGES ARE SEEN. TISSUES ARE ALTERED. BY POST-MORTEM MODIFICATIONS AND DIAGNOSIS IS GIVEN WITH RESERVATION.

PITUITARY

ABSENT :
ORGAN OR TISSUE NOT REMOVED FROM ANIMAL OR NOT FOUND IN FIXATIVE.

THYROIDS

ABSENT :
ORGAN OR TISSUE NOT REMOVED FROM ANIMAL OR NOT FOUND IN FIXATIVE.

ADRENALS

AUTOLYSIS PARTIAL :
NO OTHER CHANGES ARE SEEN. TISSUES ARE ALTERED. BY POST-MORTEM MODIFICATIONS AND DIAGNOSIS IS GIVEN WITH RESERVATION.

BAYER AG

MALE 307 (1841/80)

HEART

FIBROSIS :
MINIMAL
THERE IS AN INCREASE IN INTERSTITIAL FIBROUS TISSUE.

MONONUCLEAR CELLS :
MINIMAL
FOCAL COLLECTIONS OF MONONUCLEAR CELLS ARE PRESENT.

LIVER

AMYLOID :
HOMOGENEOUS ACIDOPHILIC MATERIAL IS DEPOSITED.

HYPERPLASIA FOCAL :
WELL DEFINED ROUND FOCUS OF HYPERPLASTIC CELLS IS OBSERVED WITHIN THIS OTHERWISE NORMAL TISSUE.

PANCREAS

AMYLOID :
HOMOGENEOUS ACIDOPHILIC MATERIAL IS DEPOSITED.

SPLEEN

HYPERPLASIA LYMPHOID :
THE LYMPHOID FOLLICLES ARE INCREASED IN SIZE.

AMYLOID :
HOMOGENEOUS ACIDOPHILIC MATERIAL IS DEPOSITED.

KIDNEYS

AMYLOID :
HOMOGENEOUS ACIDOPHILIC MATERIAL IS DEPOSITED.

INTERSTITIAL NEPHRITIS :
BILATERAL MODERATE MULTIFOCAL
INFLAMMATORY CELLS FIBROSIS AND SOME TUBULAR ALTERATIONS ARE ASSOCIATED.

PITUITARY

ABSENT :
ORGAN OR TISSUE NOT REMOVED FROM ANIMAL OR NOT FOUND IN FIXATIVE.

THYROIDS

ABSENT :
ORGAN OR TISSUE NOT REMOVED FROM ANIMAL OR NOT FOUND IN FIXATIVE.

ADRENALS

AMYLOID :
HOMOGENEOUS ACIDOPHILIC MATERIAL IS DEPOSITED.

SKELETAL MUSCLE

ABSENT :
ORGAN OR TISSUE NOT REMOVED FROM ANIMAL OR NOT FOUND IN FIXATIVE.

SCIATIC NERVE

ABSENT :
ORGAN OR TISSUE NOT REMOVED FROM ANIMAL OR NOT FOUND IN FIXATIVE.

FEMUR

ABSENT :
ORGAN OR TISSUE NOT REMOVED FROM ANIMAL OR NOT FOUND IN FIXATIVE.

MALE 309 (1836/80)

HEART

THROMBOSIS :
THE VASCULAR LUMEN CONTAINS AN ATTACHED ANTE MORTEM BLOOD CLOT.

LUNG

PNEUMONIA :
SEVERE
THE ALVEOLAR WALLS ARE THICKENED AND ALVEOLI CONTAIN INFLAMMATORY CELLS AND FOAMY MACROPHAGES.PERIVASCULAR AND PERIBRONCHIAL LYMPHOCYTIC ACCUMULATIONS MAY BE PRESENT.

CONGESTION :
SEVERE
VESSELS OR SINUSOIDS ARE MARKEDLY DISTENDED WITH ERYTHROCYTES.

LIVER

CONGESTION :
VESSELS OR SINUSOIDS ARE MARKEDLY DISTENDED WITH ERYTHROCYTES.

LEUKEMIC DEPOSITS :
MINIMAL
ORGAN AND THE BLOOD ARE INVADED BY LEUKEMIC CELLS.

PANCREAS

AUTOLYSIS :
THE TISSUES EXHIBIT AUTOLYSIS AND THEY ARE NOT INTERPRETABLE.

SPLEEN

*** LYMPHOMA GRANULOCYTIC :
THE NEOPLASM OF THE RETICULAR SYSTEM ORIGINATES FROM GRANULOCYTES.

KIDNEYS

LEUKEMIC DEPOSITS :
SEVERE
ORGAN AND THE BLOOD ARE INVADED BY LEUKEMIC CELLS.

BLADDER

NECROSIS :
THE TISSUE HAS LOST ITS NORMAL STRUCTURE DUE TO CELL DEATH

BAYER AG BAYER AG BAYER AG

BLADDER CONTINUED

WHICH MAY BE OF VARIOUS ORIGIN.

LEUKEMIC DEPOSITS :
ORGAN AND THE BLOOD ARE INVADED BY LEUKEMIC CELLS.

THYROIDS

ABSENT :
ORGAN OR TISSUE NOT REMOVED FROM ANIMAL OR NOT FOUND IN FIXATIVE.

MALE 311 (1820/80)

BRAIN

AUTOLYSIS PARTIAL :
NO OTHER CHANGES ARE SEEN. TISSUES ARE ALTERED. BY POST-MORTEM MODIFICATIONS AND DIAGNOSIS IS GIVEN WITH RESERVATION.

HEART

CONGESTION :
VESSELS OR SINUSOIDS ARE MARKEDLY DISTENDED WITH ERYTHROCYTES.

LUNG

CONGESTION :
VESSELS OR SINUSOIDS ARE MARKEDLY DISTENDED WITH ERYTHROCYTES.

STOMACH

AUTOLYSIS PARTIAL :
NO OTHER CHANGES ARE SEEN. TISSUES ARE ALTERED. BY POST-MORTEM MODIFICATIONS AND DIAGNOSIS IS GIVEN WITH RESERVATION.

KIDNEYS

CONGESTION :
BILATERAL MODERATE
VESSELS OR SINUSOIDS ARE MARKEDLY DISTENDED WITH ERYTHROCYTES.

AUTOLYSIS PARTIAL :
NO OTHER CHANGES ARE SEEN. TISSUES ARE ALTERED. BY POST-MORTEM MODIFICATIONS AND DIAGNOSIS IS GIVEN WITH RESERVATION.

BLADDER

AUTOLYSIS PARTIAL :
NO OTHER CHANGES ARE SEEN. TISSUES ARE ALTERED.
BY POST-MORTEM MODIFICATIONS AND
DIAGNOSIS IS GIVEN WITH RESERVATION.

PITUITARY

ABSENT :
ORGAN OR TISSUE NOT REMOVED FROM ANIMAL OR NOT FOUND IN
FIXATIVE.

SCIATIC NERVE

ABSENT :
ORGAN OR TISSUE NOT REMOVED FROM ANIMAL OR NOT FOUND IN
FIXATIVE.

BAYER AG

MALE 313 (1848/80)

LUNG

*** ALVEOLOGENIC CARCINOMA :
MULTIFOCAL
A MALIGNANT TUMOR OF THE LUNG TISSUE WITH
SYNONYMS IN MICE FOR ADENOMA, CARCINOMA,
ALVEOLOGENIC PAPILLARY CARCINOMA, PAPILLARY
CYSTADENOMA, ADENOCARCINOMA, BRONCHIOLAR
CELL CARCINOMA, BRONCHIOLAR-ALVEOLAR TUMOR,
TYPE A TUMOR, TYPE B TUMOR, INTERMEDIATE
TYPE I TUMOR AND COMMON PULMONARY TUMOR OF
THE MOUSE.

LIVER

HYPERPLASTIC NODULES :
WELL DEFINED ROUNDED FOCI OF HYPERPLASTIC AND HYPERTROPHIC
CELLS ARE OBSERVED WITHIN THIS OTHERWISE NORMAL TISSUE.

SPLEEN

NORMAL :
HISTOLOGICAL ASPECT WITHIN NORMAL LIMITS.

KIDNEYS

CYSTS :
BILATERAL MODERATE MULTIFOCAL
ONE OR MORE CYSTS FILLED WITH CLEAR LIQUID ARE SEEN.

PITUITARY

UNREADABLE :
IT IS NOT POSSIBLE TO INTERPRET THE SECTION DUE TO AN

PITUITARY CONTINUED
ARTIFACT CAUSED BY SAMPLING OR HISTOLOGICAL TECHNIQUE.

TESTES

ATROPHY SEMINIFEROUS :
BILATERAL MODERATE
THERE IS ATROPHY OF SEMINIFEROUS TUBULES WITH DIMINISHED SPERMATOGENIC ACTIVITY.

SPERMATOCELE :
UNILATERAL MINIMAL FOCAL
FOCAL CYSTIC DILATATION CONTAINING SPERMATOZOA IS PRESENT.

MALE 314 (1834/80)

HEART

AUTOLYSIS PARTIAL :
NO OTHER CHANGES ARE SEEN. TISSUES ARE ALTERED. BY POST-MORTEM MODIFICATIONS AND DIAGNOSIS IS GIVEN WITH RESERVATION.

LUNG

AUTOLYSIS PARTIAL :
NO OTHER CHANGES ARE SEEN. TISSUES ARE ALTERED. BY POST-MORTEM MODIFICATIONS AND DIAGNOSIS IS GIVEN WITH RESERVATION.

STOMACH

AUTOLYSIS :
THE TISSUES EXHIBIT AUTOLYSIS AND THEY ARE NOT INTERPRETABLE.

LIVER

AUTOLYSIS :
THE TISSUES EXHIBIT AUTOLYSIS AND THEY ARE NOT INTERPRETABLE.

PANCREAS

AUTOLYSIS :
THE TISSUES EXHIBIT AUTOLYSIS AND THEY ARE NOT INTERPRETABLE.

SPLEEN

AUTOLYSIS :
THE TISSUES EXHIBIT AUTOLYSIS AND THEY ARE NOT INTERPRETABLE.

KIDNEYS

AUTOLYSIS PARTIAL :
NO OTHER CHANGES ARE SEEN. TISSUES ARE ALTERED.
BY POST-MORTEM MODIFICATIONS AND
DIAGNOSIS IS GIVEN WITH RESERVATION.

BLADDER

AUTOLYSIS :
THE TISSUES EXHIBIT AUTOLYSIS AND THEY ARE NOT
INTERPRETABLE.

PITUITARY

ABSENT :
ORGAN OR TISSUE NOT REMOVED FROM ANIMAL OR NOT FOUND IN
FIXATIVE.

THYROIDS

ABSENT :
ORGAN OR TISSUE NOT REMOVED FROM ANIMAL OR NOT FOUND IN
FIXATIVE.

ADRENALS

AUTOLYSIS :
THE TISSUES EXHIBIT AUTOLYSIS AND THEY ARE NOT
INTERPRETABLE.

SKELETAL MUSCLE

AUTOLYSIS PARTIAL :
NO OTHER CHANGES ARE SEEN. TISSUES ARE ALTERED.
BY POST-MORTEM MODIFICATIONS AND
DIAGNOSIS IS GIVEN WITH RESERVATION.

SCIATIC NERVE

AUTOLYSIS PARTIAL :
NO OTHER CHANGES ARE SEEN. TISSUES ARE ALTERED.
BY POST-MORTEM MODIFICATIONS AND
DIAGNOSIS IS GIVEN WITH RESERVATION.

TESTES

SPERMATOCELE :
UNILATERAL MINIMAL FOCAL
FOCAL CYSTIC DILATATION CONTAINING SPERMATOZOA IS PRESENT.

AUTOLYSIS PARTIAL :
NO OTHER CHANGES ARE SEEN. TISSUES ARE ALTERED.
BY POST-MORTEM MODIFICATIONS AND
DIAGNOSIS IS GIVEN WITH RESERVATION.

FEMUR

AUTOLYSIS PARTIAL :
NO OTHER CHANGES ARE SEEN. TISSUES ARE ALTERED.
BY POST-MORTEM MODIFICATIONS AND
DIAGNOSIS IS GIVEN WITH RESERVATION.

BAYER AG BAYER AG BAYER AG

UNKNOWN TISSUE OR ANY GT

UNREADABLE :
IT IS NOT POSSIBLE TO INTERPRET THE SECTION DUE TO AN ARTIFACT CAUSED BY SAMPLING OR HISTOLOGICAL TECHNIQUE.

MALE 316 (1849/80)

LUNG

EDEMA :
MODERATE
THE INTERSTITIAL TISSUES CONTAIN AN INCREASED AMOUNT OF FLUID.

PNEUMONIA :
MODERATE
THE ALVEOLAR WALLS ARE THICKENED AND ALVEOLI CONTAIN INFLAMMATORY CELLS AND FOAMY MACROPHAGES.PERIVASCULAR AND PERIBRONCHIAL LYMPHOCYTIC ACCUMULATIONS MAY BE PRESENT.

LIVER

NECROSIS :
MINIMAL MULTIFOCAL
THE TISSUE HAS LOST ITS NORMAL STRUCTURE DUE TO CELL DEATH WHICH MAY BE OF VARIOUS ORIGIN.

HEMORRHAGE :
MODERATE MULTIFOCAL
THERE IS EXTRAVASATION OF BLOOD.

HEPATOCYTIC HYPERPIGMENTATION :
HEPATOCYTES ARE LADEN WITH GRANULES OF HEMOSIDERIN OR BILE OR OTHER PIGMENT.

HYPERPLASTIC NODULES :
WELL DEFINED ROUNDED FOCI OF HYPERPLASTIC AND HYPERTROPHIC CELLS ARE OBSERVED WITHIN THIS OTHERWISE NORMAL TISSUE.

PANCREAS

CONGESTION :
SEVERE
VESSELS OR SINUSOIDS ARE MARKEDLY DISTENDED WITH ERYTHROCYTES.

SPLEEN

PIGMENTATION :
NUMEROUS MACROPHAGES CONTAIN A GRANULAR BROWN CYTOPLASMIC PIGMENT.

KIDNEYS

INTERSTITIAL NEPHRITIS :
BILATERAL MODERATE MULTIFOCAL
INFLAMMATORY CELLS FIBROSIS AND SOME TUBULAR ALTERATIONS ARE ASSOCIATED.

PROGRESSIVE NEPHROPATHY :
SEVERE
AN AGE ASSOCIATED KIDNEY LESION CONSISTING OF CYSTIC TUBULES WITH COLLOID OR HYALINE CASTS CHRONIC INTERSTITIAL NEPHRITIS AND DILATATION OF BOWMAN'S CAPSULE WITH GLOMERULAR DEGENERATION .

BLADDER

INFLAMMATION CHRONIC :
SEVERE MULTIFOCAL
THERE IS AN INFILTRATION BY MONONUCLEAR CELLS IN THE MUCOSA AND SUBMUCOSA.

PITUITARY

ABSENT :
ORGAN OR TISSUE NOT REMOVED FROM ANIMAL OR NOT FOUND IN FIXATIVE.

THYROIDS

CYSTS :
BILATERAL FOCAL
ONE OR MORE CYSTS FILLED WITH CLEAR LIQUID ARE SEEN.

BAYER AG

MALE 317 (1618/80)

LIVER

AMYLOID :
MODERATE MULTIFOCAL
HOMOGENEOUS ACIDOPHILIC MATERIAL IS DEPOSITED.

SPLEEN

HYPERPLASIA LYMPHOID :
THE LYMPHOID FOLLICLES ARE INCREASED IN SIZE.

BONE MARROW

HYPERPLASIA :
THERE IS AN EXAGGERATED INCREASE/DEVELOPMENT OF THE NORMAL TISSUE/GLAND IN THE ORGAN.

KIDNEYS

INTERSTITIAL NEPHRITIS :
BILATERAL MINIMAL MULTIFOCAL

KIDNEYS CONTINUED

INFLAMMATORY CELLS FIBROSIS AND SOME TUBULAR ALTERATIONS ARE ASSOCIATED.

SKELETAL MUSCLE

EDEMA :
MODERATE
THE INTERSTITIAL TISSUES CONTAIN AN INCREASED AMOUNT OF FLUID.

MONONUCLEAR CELLS :
MINIMAL
FOCAL COLLECTIONS OF MONONUCLEAR CELLS ARE PRESENT.

SKIN

NECROSIS :
SEVERE
THE TISSUE HAS LOST ITS NORMAL STRUCTURE DUE TO CELL DEATH WHICH MAY BE OF VARIOUS ORIGIN.

MONONUCLEAR CELLS :
SEVERE
FOCAL COLLECTIONS OF MONONUCLEAR CELLS ARE PRESENT.

MALE 318 (1846/80)

BRAIN

AUTOLYSIS PARTIAL :
NO OTHER CHANGES ARE SEEN. TISSUES ARE ALTERED. BY POST-MORTEM MODIFICATIONS AND DIAGNOSIS IS GIVEN WITH RESERVATION.

HEART

CONGESTION :
VESSELS OR SINUSOIDS ARE MARKEDLY DISTENDED WITH ERYTHROCYTES.

LUNG

CONGESTION :
MODERATE
VESSELS OR SINUSOIDS ARE MARKEDLY DISTENDED WITH ERYTHROCYTES.

STOMACH

AUTOLYSIS :
THE TISSUES EXHIBIT AUTOLYSIS AND THEY ARE NOT INTERPRETABLE.

LIVER

CONGESTION :
SEVERE
VESSELS OR SINUSOIDS ARE MARKEDLY DISTENDED WITH ERYTHROCYTES.

PANCREAS

AUTOLYSIS :
THE TISSUES EXHIBIT AUTOLYSIS AND THEY ARE NOT INTERPRETABLE.

SPLEEN

ATROPHY :
THE ORGAN IS REDUCED IN SIZE.

AUTOLYSIS PARTIAL :
NO OTHER CHANGES ARE SEEN. TISSUES ARE ALTERED. BY POST-MORTEM MODIFICATIONS AND DIAGNOSIS IS GIVEN WITH RESERVATION.

KIDNEYS

CONGESTION :
BILATERAL MODERATE
VESSELS OR SINUSOIDS ARE MARKEDLY DISTENDED WITH ERYTHROCYTES.

BLADDER

AUTOLYSIS :
THE TISSUES EXHIBIT AUTOLYSIS AND THEY ARE NOT INTERPRETABLE.

PITUITARY

ABSENT :
ORGAN OR TISSUE NOT REMOVED FROM ANIMAL OR NOT FOUND IN FIXATIVE.

ADRENALS

UNREADABLE :
IT IS NOT POSSIBLE TO INTERPRET THE SECTION DUE TO AN ARTIFACT CAUSED BY SAMPLING OR HISTOLOGICAL TECHNIQUE.

BAYER AG BAYER AG BAYER AG

MALE 319 (1843/80)

HEART

MONONUCLEAR CELLS :
MINIMAL FOCAL
FOCAL COLLECTIONS OF MONONUCLEAR CELLS ARE PRESENT.

CONGESTION :

HEART CONTINUED
VESSELS OR SINUSOIDS ARE MARKEDLY DISTENDED WITH ERYTHROCYTES.

LUNG

EDEMA :
THE INTERSTITIAL TISSUES CONTAIN AN INCREASED AMOUNT OF FLUID.

CONGESTION :
SEVERE
VESSELS OR SINUSOIDS ARE MARKEDLY DISTENDED WITH ERYTHROCYTES.

LIVER

*** ADENOMA HEPATIC BENIGN :
DISTINCT NODULES COMPRESS THE ADJACENT LIVER PARENCHYMA, ARE CHARACTERIZED BY WELL DIFFERENTIATED HEPATOCYTES AND DO NOT SHOW PORTAL TRIADS.

AMYLOID :
MODERATE MULTIFOCAL
HOMOGENEOUS ACIDOPHILIC MATERIAL IS DEPOSITED.

PANCREAS

AUTOLYSIS PARTIAL :
NO OTHER CHANGES ARE SEEN. TISSUES ARE ALTERED BY POST-MORTEM MODIFICATIONS AND DIAGNOSIS IS GIVEN WITH RESERVATION.

KIDNEYS

CONGESTION :
BILATERAL MODERATE
VESSELS OR SINUSOIDS ARE MARKEDLY DISTENDED WITH ERYTHROCYTES.

TUBULOPATHY :
BILATERAL MODERATE
TUBULAR DEGENERATIVE CHANGES ARE PRESENT WHICH MAY BE ASSOCIATED WITH TUBULAR DILATATION.

DILATATION OF RENAL PELVIS :
UNILATERAL
THE RENAL CAVITIES ARE MORE OR LESS ENLARGED.

BLADDER

UNREADABLE :
IT IS NOT POSSIBLE TO INTERPRET THE SECTION DUE TO AN ARTIFACT CAUSED BY SAMPLING OR HISTOLOGICAL TECHNIQUE.

AUTOLYSIS PARTIAL :
NO OTHER CHANGES ARE SEEN. TISSUES ARE ALTERED BY POST-MORTEM MODIFICATIONS AND DIAGNOSIS IS GIVEN WITH RESERVATION.

PITUITARY

ABSENT :
ORGAN OR TISSUE NOT REMOVED FROM ANIMAL OR NOT FOUND IN FIXATIVE.

MALE 320 (1833/60)

HEART

CONGESTION :
VESSELS OR SINUSOIDS ARE MARKEDLY DISTENDED WITH ERYTHROCYTES.

LUNG

*** ALVEOLOGENIC CARCINOMA :
MULTIFOCAL
A MALIGNANT TUMOR OF THE LUNG TISSUE WITH SYNONYMS IN MICE FOR ADENOMA, CARCINOMA, ALVEOLOGENIC PAPILLARY CARCINOMA, PAPILLARY CYSTADENOMA, ADENOCARCINOMA, BRONCHIOLAR CELL CARCINOMA, BRONCHIOLAR-ALVEOLAR TUMOR, TYPE A TUMOR, TYPE B TUMOR, INTERMEDIATE TYPE I TUMOR AND COMMON PULMONARY TUMOR OF THE MOUSE.

STOMACH

NORMAL :
HISTOLOGICAL ASPECT WITHIN NORMAL LIMITS.

LIVER

CALCIFICATION :
MULTIFOCAL
THERE ARE MINERAL DEPOSITS.

*** ADENOMA HEPATIC BENIGN :
DISTINCT NODULES COMPRESS THE ADJACENT LIVER PARENCHYMA, ARE CHARACTERIZED BY WELL DIFFERENTIATED HEPATOCYTES AND DO NOT SHOW PORTAL TRIADS.

HEMORRHAGE :
SEVERE MULTIFOCAL
THERE IS EXTRAVASATION OF BLOOD.

AMYLOID :
MULTIFOCAL
HOMOGENEOUS ACIDOPHILIC MATERIAL IS DEPOSITED.

HEPATOCYTIC HYPERPIGMENTATION :
HEPATOCYTES ARE LADEN WITH GRANULES OF HEMOSIDERIN OR BILE OR OTHER PIGMENT.

BAYER AG

BLADDER

*** CARCINOSARCOMA :
IRREGULAR NESTS OF EPITHELIAL CELLS ARE CLOSELY INTERMIXED WITH MALIGNANT SPINDLE CELLS.

SKELETAL MUSCLE

ABSENT :
ORGAN OR TISSUE NOT REMOVED FROM ANIMAL OR NOT FOUND IN FIXATIVE.

SCIATIC NERVE

ABSENT :
ORGAN OR TISSUE NOT REMOVED FROM ANIMAL OR NOT FOUND IN FIXATIVE.

TESTES

CALCIFICATION :
UNILATERAL MODERATE MULTIFOCAL
THERE ARE MINERAL DEPOSITS.

INTESTINE

HEMORRHAGE :
MINIMAL MULTIFOCAL
THERE IS EXTRAVASATION OF BLOOD.

MALE 321 (1621/80)

BRAIN

ABSENT :
ORGAN OR TISSUE NOT REMOVED FROM ANIMAL OR NOT FOUND IN FIXATIVE.

LUNG

LEUKEMIC DEPOSITS :
ORGAN AND THE BLOOD ARE INVADED BY LEUKEMIC CELLS.

AUTOLYSIS PARTIAL :
NO OTHER CHANGES ARE SEEN. TISSUES ARE ALTERED. BY POST-MORTEM MODIFICATIONS AND DIAGNOSIS IS GIVEN WITH RESERVATION.

STOMACH

AUTOLYSIS :
THE TISSUES EXHIBIT AUTOLYSIS AND THEY ARE NOT INTERPRETABLE.

LIVER

LEUKEMIC DEPOSITS :
ORGAN AND THE BLOOD ARE INVADED BY LEUKEMIC CELLS.

AUTOLYSIS PARTIAL :
NO OTHER CHANGES ARE SEEN. TISSUES ARE ALTERED. BY POST-MORTEM MODIFICATIONS AND DIAGNOSIS IS GIVEN WITH RESERVATION.

PANCREAS

AUTOLYSIS :
THE TISSUES EXHIBIT AUTOLYSIS AND THEY ARE NOT INTERPRETABLE.

AUTOLYSIS :
THE TISSUES EXHIBIT AUTOLYSIS AND THEY ARE NOT INTERPRETABLE.

THYMUS

*** LYMPHOMA LYMPHOCYTIC :
THE NEOPLASM OF THE RETICULAR SYSTEM ORIGINATES FROM LYMPHOCYTES.

AUTOLYSIS PARTIAL :
NO OTHER CHANGES ARE SEEN. TISSUES ARE ALTERED. BY POST-MORTEM MODIFICATIONS AND DIAGNOSIS IS GIVEN WITH RESERVATION.

SPLEEN

*** LYMPHOMA LYMPHOCYTIC :
THE NEOPLASM OF THE RETICULAR SYSTEM ORIGINATES FROM LYMPHOCYTES.

AUTOLYSIS PARTIAL :
NO OTHER CHANGES ARE SEEN. TISSUES ARE ALTERED. BY POST-MORTEM MODIFICATIONS AND DIAGNOSIS IS GIVEN WITH RESERVATION.

KIDNEYS

LEUKEMIC DEPOSITS :
BILATERAL
ORGAN AND THE BLOOD ARE INVADED BY LEUKEMIC CELLS.

AUTOLYSIS PARTIAL :
NO OTHER CHANGES ARE SEEN. TISSUES ARE ALTERED. BY POST-MORTEM MODIFICATIONS AND DIAGNOSIS IS GIVEN WITH RESERVATION.

BLADDER

AUTOLYSIS :
THE TISSUES EXHIBIT AUTOLYSIS AND THEY ARE NOT INTERPRETABLE.

BAYER AG

PITUITARY

AUTOLYSIS :
THE TISSUES EXHIBIT AUTOLYSIS AND THEY ARE NOT INTERPRETABLE.

THYROIDS

AUTOLYSIS :
THE TISSUES EXHIBIT AUTOLYSIS AND THEY ARE NOT INTERPRETABLE.

ADRENALS

LEUKEMIC DEPOSITS :
ORGAN AND THE BLOOD ARE INVADED BY LEUKEMIC CELLS.

AUTOLYSIS PARTIAL :
NO OTHER CHANGES ARE SEEN. TISSUES ARE ALTERED. BY POST-MORTEM MODIFICATIONS AND DIAGNOSIS IS GIVEN WITH RESERVATION.

MESENTERY

LEUKEMIC DEPOSITS :
ORGAN AND THE BLOOD ARE INVADED BY LEUKEMIC CELLS.

MALE 323 (1837/80)

LUNG

*** ALVEOLOGENIC CARCINOMA :
MULTIFOCAL
A MALIGNANT TUMOR OF THE LUNG TISSUE WITH SYNONYMS IN MICE FOR ADENOMA, CARCINOMA, ALVEOLOGENIC PAPILLARY CARCINOMA, PAPILLARY CYSTADENOMA, ADENOCARCINOMA, BRONCHIOLAR CELL CARCINOMA, BRONCHIOLAR-ALVEOLAR TUMOR, TYPE A TUMOR, TYPE B TUMOR, INTERMEDIATE TYPE I TUMOR AND COMMON PULMONARY TUMOR OF THE MOUSE.

LIVER

CALCIFICATION :
SEVERE MULTIFOCAL
THERE ARE MINERAL DEPOSITS.

*** ADENOCARCINOMA :
MALIGNANT EPITHELIAL TUMOR SHOWING VARIOUS WELL DIFFERENTIATED MORPHOLOGICAL ASPECTS.

AMYLOID :
SEVERE MULTIFOCAL

LM3.24 MALE 323 CONTINUED

LIVER CONTINUED

HOMOGENEOUS ACIDOPHILIC MATERIAL IS DEPOSITED.

HEPATOCYTIC HYPERPIGMENTATION :
HEPATOCYTES ARE LADEN WITH GRANULES OF HEMOSIDERIN OR BILE OR OTHER PIGMENT.

HYPERPLASTIC NODULES :
WELL DEFINED ROUNDED FOCI OF HYPERPLASTIC AND HYPERTROPHIC CELLS ARE OBSERVED WITHIN THIS OTHERWISE NORMAL TISSUE.

SPLEEN

HEMATOPOIESIS :
MODERATE
THE HEMATOPOIESIS IS EVIDENT.

KIDNEYS

TUBULOPATHY :
UNILATERAL MINIMAL MULTIFOCAL
TUBULAR DEGENERATIVE CHANGES ARE PRESENT WHICH MAY BE ASSOCIATED WITH TUBULAR DILATATION.

MALE 324 (1831/80)

LUNG

LEUKEMIC DEPOSITS :
ORGAN AND THE BLOOD ARE INVADED BY LEUKEMIC CELLS.

STOMACH

CYSTS :
MINIMAL
ONE OR MORE CYSTS FILLED WITH CLEAR LIQUID ARE SEEN.

LIVER

CALCIFICATION :
MULTIFOCAL
THERE ARE MINERAL DEPOSITS.

HYPERPLASTIC NODULE :
A NODULE OF HYPERPLASTIC TISSUE IS PRESENT.

THYMUS

*** LYMPHOMA LYMPHOCYTIC :
THE NEOPLASM OF THE RETICULAR SYSTEM ORIGINATES FROM LYMPHOCYTES.

BAYER AG BAYER AG BAYER AG BAYER AG

BLADDER

HYPERTROPHY :
THE SIZE OF THE ORGAN IS INCREASED WITHOUT STRUCTURAL ANOMALY.

COAGULUM :
AN ACIDOPHILIC STRUCTURE RESEMBLING COAGULATED PROTEIN IS PRESENT IN THE LUMEN.

PITUITARY

ABSENT :
ORGAN OR TISSUE NOT REMOVED FROM ANIMAL OR NOT FOUND IN FIXATIVE.

ADRENALS

HEMORRAGIC CYST :
ONE OR SEVERAL CAVITIES FILLED WITH BLOOD.

MALE 325 (1628/80)

BRAIN

ABSENT :
ORGAN OR TISSUE NOT REMOVED FROM ANIMAL OR NOT FOUND IN FIXATIVE.

HEART

CONGESTION :
SEVERE
VESSELS OR SINUSOIDS ARE MARKEDLY DISTENDED WITH ERYTHROCYTES.

LUNG

EDEMA :
SEVERE
THE INTERSTITIAL TISSUES CONTAIN AN INCREASED AMOUNT OF FLUID.

AUTOLYSIS PARTIAL :
NO OTHER CHANGES ARE SEEN. TISSUES ARE ALTERED.
BY POST-MORTEM MODIFICATIONS AND
DIAGNOSIS IS GIVEN WITH RESERVATION.

STOMACH

AUTOLYSIS :
THE TISSUES EXHIBIT AUTOLYSIS AND THEY ARE NOT INTERPRETABLE.

LIVER

AUTOLYSIS PARTIAL :
NO OTHER CHANGES ARE SEEN. TISSUES ARE ALTERED.
BY POST-MORTEM MODIFICATIONS AND
DIAGNOSIS IS GIVEN WITH RESERVATION.

PANCREAS

AUTOLYSIS PARTIAL :
NO OTHER CHANGES ARE SEEN. TISSUES ARE ALTERED.
BY POST-MORTEM MODIFICATIONS AND
DIAGNOSIS IS GIVEN WITH RESERVATION.

SPLEEN

AUTOLYSIS PARTIAL :
NO OTHER CHANGES ARE SEEN. TISSUES ARE ALTERED.
BY POST-MORTEM MODIFICATIONS AND
DIAGNOSIS IS GIVEN WITH RESERVATION.

KIDNEYS

CALCIFICATION :
BILATERAL MINIMAL MULTIFOCAL
THERE ARE MINERAL DEPOSITS.

INTERSTITIAL NEPHRITIS :
BILATERAL MINIMAL MULTIFOCAL
INFLAMMATORY CELLS FIBROSIS AND SOME TUBULAR ALTERATIONS
ARE ASSOCIATED.

BLADDER

AUTOLYSIS :
THE TISSUES EXHIBIT AUTOLYSIS AND THEY ARE NOT
INTERPRETABLE.

PITUITARY

ABSENT :
ORGAN OR TISSUE NOT REMOVED FROM ANIMAL OR NOT FOUND IN
FIXATIVE.

THYROIDS

AUTOLYSIS PARTIAL :
NO OTHER CHANGES ARE SEEN. TISSUES ARE ALTERED.
BY POST-MORTEM MODIFICATIONS AND
DIAGNOSIS IS GIVEN WITH RESERVATION.

ADRENALS

AUTOLYSIS PARTIAL :
NO OTHER CHANGES ARE SEEN. TISSUES ARE ALTERED.
BY POST-MORTEM MODIFICATIONS AND
DIAGNOSIS IS GIVEN WITH RESERVATION.

TESTES

AUTOLYSIS PARTIAL :
NO OTHER CHANGES ARE SEEN. TISSUES ARE ALTERED.

BAYER AG

NM3-27 MALE 325 CONTINUED

TESTES CONTINUED
BY POST-MORTEM MODIFICATIONS AND
DIAGNOSIS IS GIVEN WITH RESERVATION.

MALE 326 (1625/60)

BRAIN

ABSENT :
ORGAN OR TISSUE NOT REMOVED FROM ANIMAL OR NOT FOUND IN FIXATIVE.

LUNG

*** ALVEOLOGENIC CARCINOMA :
A MALIGNANT TUMOR OF THE LUNG TISSUE WITH SYNONYMS IN MICE FOR ADENOMA, CARCINOMA, ALVEOLOGENIC PAPILLARY CARCINOMA, PAPILLARY CYSTADENOMA, ADENOCARCINOMA, BRONCHIOLAR CELL CARCINOMA, BRONCHIOLAR-ALVEOLAR TUMOR, TYPE A TUMOR, TYPE B TUMOR, INTERMEDIATE TYPE I TUMOR AND COMMON PULMONARY TUMOR OF THE MOUSE.

AUTOLYSIS PARTIAL :
NO OTHER CHANGES ARE SEEN. TISSUES ARE ALTERED.
BY POST-MORTEM MODIFICATIONS AND
DIAGNOSIS IS GIVEN WITH RESERVATION.

STOMACH

AUTOLYSIS :
THE TISSUES EXHIBIT AUTOLYSIS AND THEY ARE NOT INTERPRETABLE.

LIVER

AUTOLYSIS PARTIAL :
NO OTHER CHANGES ARE SEEN. TISSUES ARE ALTERED.
BY POST-MORTEM MODIFICATIONS AND
DIAGNOSIS IS GIVEN WITH RESERVATION.

HEPATOCYTIC HYPERPIGMENTATION :
HEPATOCYTES ARE LADEN WITH GRANULES OF HEMOSIDERIN OR BILE OR OTHER PIGMENT.

PANCREAS

AUTOLYSIS :
THE TISSUES EXHIBIT AUTOLYSIS AND THEY ARE NOT INTERPRETABLE.

SPLEEN

HYPERTROPHY :

NM3.28 MALE 326 CONTINUED

SPLEEN CONTINUED

THE SIZE OF THE ORGAN IS INCREASED WITHOUT STRUCTURAL ANOMALY.

AUTOLYSIS PARTIAL :
NO OTHER CHANGES ARE SEEN. TISSUES ARE ALTERED.
BY POST-MORTEM MODIFICATIONS AND
DIAGNOSIS IS GIVEN WITH RESERVATION.

KIDNEYS

AMYLOID :
HOMOGENEOUS ACIDOPHILIC MATERIAL IS DEPOSITED.

AUTOLYSIS PARTIAL :
NO OTHER CHANGES ARE SEEN. TISSUES ARE ALTERED.
BY POST-MORTEM MODIFICATIONS AND
DIAGNOSIS IS GIVEN WITH RESERVATION.

BLADDER

MONONUCLEAR CELLS :
MINIMAL FOCAL
FOCAL COLLECTIONS OF MONONUCLEAR CELLS ARE PRESENT.

COAGULUM :
AN ACIDOPHILIC STRUCTURE RESEMBLING COAGULATED PROTEIN IS PRESENT IN THE LUMEN.

AUTOLYSIS PARTIAL :
NO OTHER CHANGES ARE SEEN. TISSUES ARE ALTERED.
BY POST-MORTEM MODIFICATIONS AND
DIAGNOSIS IS GIVEN WITH RESERVATION.

PITUITARY

ABSENT :
ORGAN OR TISSUE NOT REMOVED FROM ANIMAL OR NOT FOUND IN FIXATIVE.

THYROIDS

AUTOLYSIS PARTIAL :
NO OTHER CHANGES ARE SEEN. TISSUES ARE ALTERED.
BY POST-MORTEM MODIFICATIONS AND
DIAGNOSIS IS GIVEN WITH RESERVATION.

TESTES

AUTOLYSIS PARTIAL :
NO OTHER CHANGES ARE SEEN. TISSUES ARE ALTERED.
BY POST-MORTEM MODIFICATIONS AND
DIAGNOSIS IS GIVEN WITH RESERVATION.

BAYER AG

MALE 326 (1835/80)

NM3.29 MALE 328 CONTINUED

HEART

FIBROSIS :
MINIMAL FOCAL
THERE IS AN INCREASE IN INTERSTITIAL FIBROUS TISSUE.

MONONUCLEAR CELLS :
MINIMAL FOCAL
FOCAL COLLECTIONS OF MONONUCLEAR CELLS ARE PRESENT.

CONGESTION :
VESSELS OR SINUSOIDS ARE MARKEDLY DISTENDED WITH ERYTHROCYTES.

LUNG

CONGESTION :
VESSELS OR SINUSOIDS ARE MARKEDLY DISTENDED WITH ERYTHROCYTES.

PANCREAS

INFLAMMATION CHRONIC :
MINIMAL MULTIFOCAL
THE INTERSTITIAL TISSUES SHOW INFILTRATION BY MONONUCLEAR CELLS AND INCREASE IN FIBROUS STROMA.

KIDNEYS

INTERSTITIAL NEPHRITIS :
CONTRALATERAL MINIMAL MULTIFOCAL
INFLAMMATORY CELLS FIBROSIS AND SOME TUBULAR ALTERATIONS ARE ASSOCIATED.

CYSTS :
UNILATERAL
ONE OR MORE CYSTS FILLED WITH CLEAR LIQUID ARE SEEN.

BLADDER

AUTOLYSIS PARTIAL :
NO OTHER CHANGES ARE SEEN. TISSUES ARE ALTERED.
BY POST-MORTEM MODIFICATIONS AND
DIAGNOSIS IS GIVEN WITH RESERVATION.

TESTES

SPERMATOCELE :
UNILATERAL MINIMAL
FOCAL CYSTIC DILATATION CONTAINING SPERMATOZOA IS PRESENT.

MALE 329 (1829/80)

BRAIN

ABSENT :
ORGAN OR TISSUE NOT REMOVED FROM ANIMAL OR NOT FOUND IN FIXATIVE.

HEART

AUTOLYSIS PARTIAL :
NO OTHER CHANGES ARE SEEN. TISSUES ARE ALTERED. BY POST-MORTEM MODIFICATIONS AND DIAGNOSIS IS GIVEN WITH RESERVATION.

LUNG

PNEUMONIA :
MODERATE
THE ALVEOLAR WALLS ARE THICKENED AND ALVEOLI CONTAIN INFLAMMATORY CELLS AND FOAMY MACROPHAGES. PERIVASCULAR AND PERIBRONCHIAL LYMPHOCYTIC ACCUMULATIONS MAY BE PRESENT.

*** ALVEOLOGENIC CARCINOMA :
A MALIGNANT TUMOR OF THE LUNG TISSUE WITH SYNONYMS IN MICE FOR ADENOMA, CARCINOMA, ALVEOLOGENIC PAPILLARY CARCINOMA, PAPILLARY CYSTADENOMA, ADENOCARCINOMA, BRONCHIOLAR CELL CARCINOMA, BRONCHIOLAR-ALVEOLAR TUMOR, TYPE A TUMOR, TYPE B TUMOR, INTERMEDIATE TYPE I TUMOR AND COMMON PULMONARY TUMOR OF THE MOUSE.

AUTOLYSIS PARTIAL :
NO OTHER CHANGES ARE SEEN. TISSUES ARE ALTERED. BY POST-MORTEM MODIFICATIONS AND DIAGNOSIS IS GIVEN WITH RESERVATION.

STOMACH

AUTOLYSIS :
THE TISSUES EXHIBIT AUTOLYSIS AND THEY ARE NOT INTERPRETABLE.

LIVER

AUTOLYSIS PARTIAL :
NO OTHER CHANGES ARE SEEN. TISSUES ARE ALTERED. BY POST-MORTEM MODIFICATIONS AND DIAGNOSIS IS GIVEN WITH RESERVATION.

PANCREAS

AUTOLYSIS :
THE TISSUES EXHIBIT AUTOLYSIS AND THEY ARE NOT INTERPRETABLE.

SPLEEN

AUTOLYSIS :
THE TISSUES EXHIBIT AUTOLYSIS AND THEY ARE NOT INTERPRETABLE.

BAYER AG

KIDNEYS

INTERSTITIAL NEPHRITIS :
BILATERAL MODERATE MULTIFOCAL
INFLAMMATORY CELLS FIBROSIS AND SOME TUBULAR ALTERATIONS ARE ASSOCIATED.

AUTOLYSIS PARTIAL :
NO OTHER CHANGES ARE SEEN. TISSUES ARE ALTERED. BY POST-MORTEM MODIFICATIONS AND DIAGNOSIS IS GIVEN WITH RESERVATION.

BLADDER

AUTOLYSIS :
THE TISSUES EXHIBIT AUTOLYSIS AND THEY ARE NOT INTERPRETABLE.

PITUITARY

AUTOLYSIS :
THE TISSUES EXHIBIT AUTOLYSIS AND THEY ARE NOT INTERPRETABLE.

THYROIDS

ABSENT :
ORGAN OR TISSUE NOT REMOVED FROM ANIMAL OR NOT FOUND IN FIXATIVE.

ADRENALS

AUTOLYSIS :
THE TISSUES EXHIBIT AUTOLYSIS AND THEY ARE NOT INTERPRETABLE.

SKELETAL MUSCLE

MONONUCLEAR CELLS :
MINIMAL MULTIFOCAL
FOCAL COLLECTIONS OF MONONUCLEAR CELLS ARE PRESENT.

AUTOLYSIS PARTIAL :
NO OTHER CHANGES ARE SEEN. TISSUES ARE ALTERED. BY POST-MORTEM MODIFICATIONS AND DIAGNOSIS IS GIVEN WITH RESERVATION.

TESTES

AUTOLYSIS PARTIAL :
NO OTHER CHANGES ARE SEEN. TISSUES ARE ALTERED. BY POST-MORTEM MODIFICATIONS AND DIAGNOSIS IS GIVEN WITH RESERVATION.

FEMUR

AUTOLYSIS PARTIAL :
NO OTHER CHANGES ARE SEEN. TISSUES ARE ALTERED. BY POST-MORTEM MODIFICATIONS AND DIAGNOSIS IS GIVEN WITH RESERVATION.

UNKNOWN TISSUE OR ANY OT

*** UNCLASSIFIED RCS :
THIS TUMOR ARISES FROM RETICULUM CELLS.

AUTOLYSIS PARTIAL :
NO OTHER CHANGES ARE SEEN. TISSUES ARE ALTERED.
BY POST-MORTEM MODIFICATIONS AND
DIAGNOSIS IS GIVEN WITH RESERVATION.

MALE 330 (1817/80.)

STOMACH

NORMAL :
HISTOLOGICAL ASPECT WITHIN NORMAL LIMITS.

LIVER

AMYLOID :
SEVERE MULTIFOCAL
HOMOGENEOUS ACIDOPHILIC MATERIAL IS DEPOSITED.

PITUITARY

UNREADABLE :
IT IS NOT POSSIBLE TO INTERPRET THE SECTION DUE TO AN
ARTIFACT CAUSED BY SAMPLING OR HISTOLOGICAL TECHNIQUE.

SEMINAL VESICLES

ATROPHY EPITHELIAL :
THE EPITHELIAL TISSUE IS ATROPHIC AND SCANTY WITH INCREASED
FIBROUS STROMA.

ECTASIA SIMPLE :
THE LUMEN OF THE ORGAN IS ABNORMALLY ENLARGED.

COAGULUM :
AN ACIDOPHILIC STRUCTURE RESEMBLING COAGULATED PROTEIN IS
PRESENT IN THE LUMEN.

INTESTINE

AUTOLYSIS :
THE TISSUES EXHIBIT AUTOLYSIS AND THEY ARE NOT
INTERPRETABLE.

MALE 333 (1645/80)

BAYER AG

LUNG

CONGESTION :
SEVERE
VESSELS OR SINUSOIDS ARE MARKEDLY DISTENDED WITH ERYTHROCYTES.

ATELECTASIS :
SEVERE FOCAL
THERE IS COLLAPSE OF ALVEOLI.

STOMACH

MUCOID CYST :
MINIMAL
ONE OR MORE CYSTS CONTAINING MUCOID MATERIAL ARE OBSERVED.

LIVER

NORMAL :
HISTOLOGICAL ASPECT WITHIN NORMAL LIMITS.

KIDNEYS

FIBROSIS :
BILATERAL MINIMAL FOCAL
THERE IS AN INCREASE IN INTERSTITIAL FIBROUS TISSUE.

PITUITARY

ABSENT :
ORGAN OR TISSUE NOT REMOVED FROM ANIMAL OR NOT FOUND IN FIXATIVE.

MALE 337 (184A/80)

LUNG

*** ALVEOLOGENIC CARCINOMA :
A MALIGNANT TUMOR OF THE LUNG TISSUE WITH SYNONYMS IN MICE FOR ADENOMA, CARCINOMA, ALVEOLOGENIC PAPILLARY CARCINOMA, PAPILLARY CYSTADENOMA, ADENOCARCINOMA, BRONCHIOLAR CELL CARCINOMA, BRONCHIOLAR-ALVEOLAR TUMOR, TYPE A TUMOR, TYPE B TUMOR, INTERMEDIATE TYPE I TUMOR AND COMMON PULMONARY TUMOR OF THE MOUSE.

STOMACH

MONONUCLEAR CELLS :
MINIMAL
FOCAL COLLECTIONS OF MONONUCLEAR CELLS ARE PRESENT.

KIDNEYS

INTERSTITIAL NEPHRITIS :
BILATERAL MINIMAL MULTIFOCAL
INFLAMMATORY CELLS FIBROSIS AND SOME TUBULAR ALTERATIONS ARE ASSOCIATED.

BLADDER

MONONUCLEAR CELLS :
MINIMAL
FOCAL COLLECTIONS OF MONONUCLEAR CELLS ARE PRESENT.

PITUITARY

ABSENT :
ORGAN OR TISSUE NOT REMOVED FROM ANIMAL OR NOT FOUND IN FIXATIVE.

THYROIDS

AUTOLYSIS PARTIAL :
NO OTHER CHANGES ARE SEEN. TISSUES ARE ALTERED.
BY POST-MORTEM MODIFICATIONS AND
DIAGNOSIS IS GIVEN WITH RESERVATION.

SKELETAL MUSCLE

ABSENT :
ORGAN OR TISSUE NOT REMOVED FROM ANIMAL OR NOT FOUND IN FIXATIVE.

SCIATIC NERVE

ABSENT :
ORGAN OR TISSUE NOT REMOVED FROM ANIMAL OR NOT FOUND IN FIXATIVE.

TESTES

CALCIFICATION :
UNILATERAL MINIMAL
THERE ARE MINERAL DEPOSITS.

SPERMATOCELE :
UNILATERAL MINIMAL
FOCAL CYSTIC DILATATION CONTAINING SPERMATOZOA IS PRESENT.

FEMUR

ABSENT :
ORGAN OR TISSUE NOT REMOVED FROM ANIMAL OR NOT FOUND IN FIXATIVE.

MALE 339 (1647/60)

BAYER AG

LUNG

*** ALVEOLOGENIC CARCINOMA :
A MALIGNANT TUMOR OF THE LUNG TISSUE WITH SYNONYMS IN MICE FOR ADENOMA, CARCINOMA, ALVEOLOGENIC PAPILLARY CARCINOMA, PAPILLARY CYSTADENOMA, ADENOCARCINOMA, BRONCHIOLAR CELL CARCINOMA, BRONCHIOLAR-ALVEOLAR TUMOR, TYPE A TUMOR, TYPE B TUMOR, INTERMEDIATE TYPE I TUMOR AND COMMON PULMONARY TUMOR OF THE MOUSE.

STOMACH

MONONUCLEAR CELLS :
MINIMAL FOCAL
FOCAL COLLECTIONS OF MONONUCLEAR CELLS ARE PRESENT.

KIDNEYS

CALCIFICATION :
UNILATERAL MODERATE MULTIFOCAL
THERE ARE MINERAL DEPOSITS.

BLADDER

AUTOLYSIS :
THE TISSUES EXHIBIT AUTOLYSIS AND THEY ARE NOT INTERPRETABLE.

PITUITARY

ABSENT :
ORGAN OR TISSUE NOT REMOVED FROM ANIMAL OR NOT FOUND IN FIXATIVE.

THYROIDS

CYSTS :
UNILATERAL MINIMAL
ONE OR MORE CYSTS FILLED WITH CLEAR LIQUID ARE SEEN.

MALE 340 (1819/80)

BRAIN

HEMORRHAGE :
MINIMAL FOCAL
THERE IS EXTRAVASATION OF BLOOD.

LUNG

CONGESTION :
VESSELS OR SINUSOIDS ARE MARKEDLY DISTENDED WITH ERYTHROCYTES.

SPLEEN

*** LYMPHOMA STEM CELLS :
THE NEOPLASM OF THE RETICULAR SYSTEM ORIGINATES FROM STEM CELLS.

HYPOPLASIA LYMPHOID :
SEVERE
THE NUMBER OF LYMPHOID FOLLICLES IS DECREASED.

KIDNEYS

INTERSTITIAL NEPHRITIS :
UNILATERAL MINIMAL MULTIFOCAL
INFLAMMATORY CELLS FIBROSIS AND SOME TUBULAR ALTERATIONS ARE ASSOCIATED.

CYSTS :
UNILATERAL MINIMAL MULTIFOCAL
ONE OR MORE CYSTS FILLED WITH CLEAR LIQUID ARE SEEN.

MALE 341 (1827/80)

HEART

THROMBOSIS :
THE VASCULAR LUMEN CONTAINS AN ATTACHED ANTE MORTEM BLOOD CLOT.

LUNG

CONGESTION :
MODERATE
VESSELS OR SINUSOIDS ARE MARKEDLY DISTENDED WITH ERYTHROCYTES.

STOMACH

AUTOLYSIS PARTIAL :
NO OTHER CHANGES ARE SEEN. TISSUES ARE ALTERED. BY POST-MORTEM MODIFICATIONS AND DIAGNOSIS IS GIVEN WITH RESERVATION.

PANCREAS

AUTOLYSIS PARTIAL :
NO OTHER CHANGES ARE SEEN. TISSUES ARE ALTERED. BY POST-MORTEM MODIFICATIONS AND DIAGNOSIS IS GIVEN WITH RESERVATION.

SPLEEN

HEMATOPOIESIS :
SEVERE
THE HEMATOPOIESIS IS EVIDENT.

BAYER AG

BLADDER

AUTOLYSIS PARTIAL :
NO OTHER CHANGES ARE SEEN. TISSUES ARE ALTERED.
BY POST-MORTEM MODIFICATIONS AND
DIAGNOSIS IS GIVEN WITH RESERVATION.

PITUITARY

ABSENT :
ORGAN OR TISSUE NOT REMOVED FROM ANIMAL OR NOT FOUND IN
FIXATIVE.

THYROIDS

AUTOLYSIS PARTIAL :
NO OTHER CHANGES ARE SEEN. TISSUES ARE ALTERED.
BY POST-MORTEM MODIFICATIONS AND
DIAGNOSIS IS GIVEN WITH RESERVATION.

ADRENALS

NORMAL :
HISTOLOGICAL ASPECT WITHIN NORMAL LIMITS.

SKIN

*** SQUAMOUS CELL CARCINOMA KERATINIZING :
IT IS A MALIGNANT EPITHELIAL TUMOR DEMONSTRATING KERATIN
PRODUCTION.

MALE 344 (1824/80)

LUNG

LEUKEMIC DEPOSITS :
ORGAN AND THE BLOOD ARE INVADED BY LEUKEMIC
CELLS.

STOMACH

AUTOLYSIS PARTIAL :
NO OTHER CHANGES ARE SEEN. TISSUES ARE ALTERED.
BY POST-MORTEM MODIFICATIONS AND
DIAGNOSIS IS GIVEN WITH RESERVATION.

LIVER

LEUKEMIC DEPOSITS :
ORGAN AND THE BLOOD ARE INVADED BY LEUKEMIC
CELLS.

PANCREAS

LEUKEMIC DEPOSITS :

PANCREAS CONTINUED

ORGAN AND THE BLOOD ARE INVADED BY LEUKEMIC CELLS.

SPLEEN

*** LYMPHOMA STEM CELLS :
THE NEOPLASM OF THE RETICULAR SYSTEM ORIGINATES FROM STEM CELLS.

AUTOLYSIS PARTIAL :
NO OTHER CHANGES ARE SEEN. TISSUES ARE ALTERED. BY POST-MORTEM MODIFICATIONS AND DIAGNOSIS IS GIVEN WITH RESERVATION.

KIDNEYS

AUTOLYSIS :
THE TISSUES EXHIBIT AUTOLYSIS AND THEY ARE NOT INTERPRETABLE.

BLADDER

AUTOLYSIS :
THE TISSUES EXHIBIT AUTOLYSIS AND THEY ARE NOT INTERPRETABLE.

PITUITARY

ABSENT :
ORGAN OR TISSUE NOT REMOVED FROM ANIMAL OR NOT FOUND IN FIXATIVE.

THYROIDS

AUTOLYSIS :
THE TISSUES EXHIBIT AUTOLYSIS AND THEY ARE NOT INTERPRETABLE.

MESENTERY

LEUKEMIC DEPOSITS :
ORGAN AND THE BLOOD ARE INVADED BY LEUKEMIC CELLS.

LYMPH NODE

*** LYMPHOMA STEM CELLS :
THE NEOPLASM OF THE RETICULAR SYSTEM ORIGINATES FROM STEM CELLS.

BAYER AG BAYER AG BAYER AG

MALE 346 (163n/80)

HEART

THROMBOSIS :
THE VASCULAR LUMEN CONTAINS AN ATTACHED ANTE MORTEM BLOOD CLOT.

AUTOLYSIS PARTIAL :
NO OTHER CHANGES ARE SEEN. TISSUES ARE ALTERED. BY POST-MORTEM MODIFICATIONS AND DIAGNOSIS IS GIVEN WITH RESERVATION.

LUNG

LEUKEMIC DEPOSITS :
ORGAN AND THE BLOOD ARE INVADED BY LEUKEMIC CELLS.

AUTOLYSIS PARTIAL :
NO OTHER CHANGES ARE SEEN. TISSUES ARE ALTERED. BY POST-MORTEM MODIFICATIONS AND DIAGNOSIS IS GIVEN WITH RESERVATION.

STOMACH

AUTOLYSIS :
THE TISSUES EXHIBIT AUTOLYSIS AND THEY ARE NOT INTERPRETABLE.

LIVER

HYPERPLASTIC NODULE :
A NODULE OF HYPERPLASTIC TISSUE IS PRESENT.

LEUKEMIC DEPOSITS :
ORGAN AND THE BLOOD ARE INVADED BY LEUKEMIC CELLS.

AUTOLYSIS PARTIAL :
NO OTHER CHANGES ARE SEEN. TISSUES ARE ALTERED. BY POST-MORTEM MODIFICATIONS AND DIAGNOSIS IS GIVEN WITH RESERVATION.

PANCREAS

AUTOLYSIS :
THE TISSUES EXHIBIT AUTOLYSIS AND THEY ARE NOT INTERPRETABLE.

SPLEEN

*** LYMPHOMA LYMPHOCYTIC :
THE NEOPLASM OF THE RETICULAR SYSTEM ORIGINATES FROM LYMPHOCYTES.

AUTOLYSIS PARTIAL :
NO OTHER CHANGES ARE SEEN. TISSUES ARE ALTERED. BY POST-MORTEM MODIFICATIONS AND DIAGNOSIS IS GIVEN WITH RESERVATION.

KIDNEYS

LEUKEMIC DEPOSITS :

KIDNEYS CONTINUED

ORGAN AND THE BLOOD ARE INVADED BY LEUKEMIC CELLS.

AUTOLYSIS PARTIAL :
NO OTHER CHANGES ARE SEEN. TISSUES ARE ALTERED. BY POST-MORTEM MODIFICATIONS AND DIAGNOSIS IS GIVEN WITH RESERVATION.

BLADDER

AUTOLYSIS :
THE TISSUES EXHIBIT AUTOLYSIS AND THEY ARE NOT INTERPRETABLE.

PITUITARY

ABSENT :
ORGAN OR TISSUE NOT REMOVED FROM ANIMAL OR NOT FOUND IN FIXATIVE.

THYROIDS

AUTOLYSIS :
THE TISSUES EXHIBIT AUTOLYSIS AND THEY ARE NOT INTERPRETABLE.

ADRENALS

AUTOLYSIS PARTIAL :
NO OTHER CHANGES ARE SEEN. TISSUES ARE ALTERED. BY POST-MORTEM MODIFICATIONS AND DIAGNOSIS IS GIVEN WITH RESERVATION.

SKELETAL MUSCLE

LEUKEMIC DEPOSITS :
ORGAN AND THE BLOOD ARE INVADED BY LEUKEMIC CELLS.

TESTES

AUTOLYSIS PARTIAL :
NO OTHER CHANGES ARE SEEN. TISSUES ARE ALTERED. BY POST-MORTEM MODIFICATIONS AND DIAGNOSIS IS GIVEN WITH RESERVATION.

MALE 347 (1844/80)

BRAIN

CONGESTION :
MINIMAL
VESSELS OR SINUSOIDS ARE MARKEDLY DISTENDED WITH ERYTHROCYTES.

BAYER AG

LUNG

CONGESTION :
MODERATE
VESSELS OR SINUSOIDS ARE MARKEDLY DISTENDED WITH ERYTHROCYTES.

LIVER

INFLAMMATION PORTAL :
SEVERE
INFILTRATION OF PORTAL SPACE BY INFLAMMATORY CELLS.

SPLEEN

HEMATOPOIESIS :
SEVERE
THE HEMATOPOIESIS IS EVIDENT.

KIDNEYS

INTERSTITIAL NEPHRITIS :
BILATERAL MINIMAL MULTIFOCAL
INFLAMMATORY CELLS FIBROSIS AND SOME TUBULAR ALTERATIONS ARE ASSOCIATED.

BLADDER

ECTASIA SIMPLE :
THE LUMEN OF THE ORGAN IS ABNORMALLY ENLARGED.

AUTOLYSIS PARTIAL :
NO OTHER CHANGES ARE SEEN. TISSUES ARE ALTERED. BY POST-MORTEM MODIFICATIONS AND DIAGNOSIS IS GIVEN WITH RESERVATION.

PITUITARY

ABSENT :
ORGAN OR TISSUE NOT REMOVED FROM ANIMAL OR NOT FOUND IN FIXATIVE.

SKELETAL MUSCLE

MONONUCLEAR CELLS :
UNILATERAL MODERATE
FOCAL COLLECTIONS OF MONONUCLEAR CELLS ARE PRESENT.

MALE 349 (1826/60)

HEART

CONGESTION :
VESSELS OR SINUSOIDS ARE MARKEDLY DISTENDED WITH ERYTHROCYTES.

LUNG

CONGESTION :
SEVERE
VESSELS OR SINUSOIDS ARE MARKEDLY DISTENDED WITH ERYTHROCYTES.

STOMACH

AUTOLYSIS PARTIAL :
NO OTHER CHANGES ARE SEEN. TISSUES ARE ALTERED. BY POST-MORTEM MODIFICATIONS AND DIAGNOSIS IS GIVEN WITH RESERVATION.

NORMAL :
HISTOLOGICAL ASPECT WITHIN NORMAL LIMITS.

LIVER

HEPATOCYTIC HYPERPIGMENTATION :
HEPATOCYTES ARE LADEN WITH GRANULES OF HEMOSIDERIN OR BILE OR OTHER PIGMENT.

PANCREAS

AUTOLYSIS PARTIAL :
NO OTHER CHANGES ARE SEEN. TISSUES ARE ALTERED. BY POST-MORTEM MODIFICATIONS AND DIAGNOSIS IS GIVEN WITH RESERVATION.

SPLEEN

PIGMENTATION :
NUMEROUS MACROPHAGES CONTAIN A GRANULAR BROWN CYTOPLASMIC PIGMENT.

KIDNEYS

TUBULOPATHY :
BILATERAL MINIMAL MULTIFOCAL
TUBULAR DEGENERATIVE CHANGES ARE PRESENT WHICH MAY BE ASSOCIATED WITH TUBULAR DILATATION.

BLADDER

AUTOLYSIS PARTIAL :
NO OTHER CHANGES ARE SEEN. TISSUES ARE ALTERED. BY POST-MORTEM MODIFICATIONS AND DIAGNOSIS IS GIVEN WITH RESERVATION.

PITUITARY

ABSENT :
ORGAN OR TISSUE NOT REMOVED FROM ANIMAL OR NOT FOUND IN FIXATIVE.

THYROIDS

CYSTS :
UNILATERAL MINIMAL
ONE OR MORE CYSTS FILLED WITH CLEAR LIQUID ARE SEEN.

BAYER AG BAYER AG BAYER AG

ADRENALS

ABSENT :
ORGAN OR TISSUE NOT REMOVED FROM ANIMAL OR NOT FOUND IN FIXATIVE.

BONE

*** OSTEOMA :
THIS BENIGN WELL CIRCUMSCRIBED TUMOR IS COMPOSED OF WELL-DEVELOPED BONE.

INTESTINE

AUTOLYSIS PARTIAL :
NO OTHER CHANGES ARE SEEN. TISSUES ARE ALTERED.
BY POST-MORTEM MODIFICATIONS AND
DIAGNOSIS IS GIVEN WITH RESERVATION.

NORMAL :
HISTOLOGICAL ASPECT WITHIN NORMAL LIMITS.

MALE 350 (1839/80)

LUNG

ADENOMATOSIS :
MINIMAL FOCAL
THE PULMONARY ALVEOLI APPEAR GLANDULAR DUE TO METAPLASTIC TRANSFORMATION OF LINING CELLS INTO CUBOIDAL OR COLUMNAR CELLS

CONGESTION :
SEVERE
VESSELS OR SINUSOIDS ARE MARKEDLY DISTENDED WITH ERYTHROCYTES.

LIVER

LEUKEMIC DEPOSITS :
ORGAN AND THE BLOOD ARE INVADED BY LEUKEMIC CELLS.

SPLEEN

*** LYMPHOMA LYMPHOCYTIC :
THE NEOPLASM OF THE RETICULAR SYSTEM ORIGINATES FROM LYMPHOCYTES.

KIDNEYS

LEUKEMIC DEPOSITS :
ORGAN AND THE BLOOD ARE INVADED BY LEUKEMIC CELLS.

BLADDER

NECROSIS :
THE TISSUE HAS LOST ITS NORMAL STRUCTURE DUE TO CELL DEATH WHICH MAY BE OF VARIOUS ORIGIN.

HEMORRHAGE :
THERE IS EXTRAVASATION OF BLOOD.

THYROIDS

CYSTS :
BILATERAL MINIMAL MULTIFOCAL
ONE OR MORE CYSTS FILLED WITH CLEAR LIQUID ARE SEEN.

BAYER AG BAYER AG BAYER AG BAYER AG

SEC. 1 CHRONIC TOXICITY STUDY IN MICE: SYSTEMATIC HISTOPATHOLOGY

PRODUCT : KWG 0519 GROUP : CONTROL
ROUTE : DIETARY
TIME : 105 WEEKS DOSE : 0 PPM
THIS GROUP COMPRISED : 16 FEMALES

THE FOLLOWING ORGANS WERE EXAMINED SYSTEMATICALLY :

HEART	LUNG	LIVER
PANCREAS	SPLEEN	KIDNEYS
BLADDER	STOMACH	OVARIES
THYROIDS	ADRENALS	PITUITARY
BRAIN	SKELETAL MUSCLE	SCIATIC NERVE
FEMUR		

THESE ORGANS WERE EXAMINED IN 16 FEMALES

INDIVIDUAL RESULTS

IN THE ANIMALS SHOWN BELOW THE HISTOLOGICAL EXAMINATION OF THE ORGANS LISTED OR OF THE ANOMALIES FOUND AT AUTOPSY GAVE THE FOLLOWING RESULTS :

FEMALE 51 (1479/80)

LUNG

PNEUMONIA :
THE ALVEOLAR WALLS ARE THICKENED AND ALVEOLI CONTAIN INFLAMMATORY CELLS AND FOAMY MACROPHAGES.PERIVASCULAR AND PERIBRONCHIAL LYMPHOCYTIC ACCUMULATIONS MAY BE PRESENT.

STOMACH

HYPERPLASIA PAPILLOMATOUS :
THE THICKNESS OF THE MUCOSA IS INCREASED MAKING UNUSUALLY HIGH AND NUMEROUS FOLDS.

LIVER

MONONUCLEAR CELLS :
MINIMAL FOCAL
FOCAL COLLECTIONS OF MONONUCLEAR CELLS ARE PRESENT.

HEPATOCYTIC HYPERPIGMENTATION :
MINIMAL FOCAL
HEPATOCYTES ARE LADEN WITH GRANULES OF HEMOSIDERIN OR BILE OR OTHER PIGMENT.

SPLEEN

HEMATOPOIESIS :
MODERATE
THE HEMATOPOIESIS IS EVIDENT.

KIDNEYS

PYELITIS :
UNILATERAL
INFLAMMATORY CELL INFILTRATION IN THE RENAL PELVIS IS PRESENT.

CYSTS :
BILATERAL
ONE OR MORE CYSTS FILLED WITH CLEAR LIQUID ARE SEEN.

BLADDER

INFLAMMATION CHRONIC :
THERE IS AN INFILTRATION BY MONONUCLEAR CELLS IN THE MUCOSA AND SUBMUCOSA.

PITUITARY

ABSENT :
ORGAN OR TISSUE NOT REMOVED FROM ANIMAL OR NOT FOUND IN FIXATIVE.

THYROIDS

ABSENT :
ORGAN OR TISSUE NOT REMOVED FROM ANIMAL OR NOT FOUND IN FIXATIVE.

OVARIES

PIGMENTATION :
NUMEROUS MACROPHAGES CONTAIN A GRANULAR BROWN CYTOPLASMIC PIGMENT.

ATROPHY :
THE ORGAN IS REDUCED IN SIZE.

CYSTS :
ONE OR MORE CYSTS FILLED WITH CLEAR LIQUID ARE SEEN.

UTERUS

HYPERPLASIA POLYPOID:
A PEDUNCULATED GROWTH IN THE LUMEN IS PRESENT

HEMORRHAGE :
THERE IS EXTRAVASATION OF BLOOD.

CYSTIC ENDOMETRIAL HYPERPLASIA :
SEVERE
THE ENDOMETRIAL GLANDS ARE INCREASED IN NUMBER AND SOME ARE DILATED OR CYSTIC.

FEMALE 52 (1480/80)

BAYER AG

LIVER

MONONUCLEAR CELLS :
MINIMAL FOCAL
FOCAL COLLECTIONS OF MONONUCLEAR CELLS ARE PRESENT.

HYPERPLASTIC NODULE :
A NODULE OF HYPERPLASTIC TISSUE IS PRESENT.

SPLEEN

HEMATOPOIESIS :
SEVERE
THE HEMATOPOIESIS IS EVIDENT.

KIDNEYS

INTERSTITIAL NEPHRITIS :
SEVERE
INFLAMMATORY CELLS FIBROSIS AND SOME TUBULAR ALTERATIONS ARE ASSOCIATED.

BLADDER

INFLAMMATION CHRONIC :
THERE IS AN INFILTRATION BY MONONUCLEAR CELLS IN THE MUCOSA AND SUBMUCOSA.

THYROIDS

ABSENT :
ORGAN OR TISSUE NOT REMOVED FROM ANIMAL OR NOT FOUND IN FIXATIVE.

ADRENALS

PIGMENTATION :
UNILATERAL MINIMAL
NUMEROUS MACROPHAGES CONTAIN A GRANULAR BROWN CYTOPLASMIC PIGMENT.

OVARIES

CYSTS :
UNILATERAL
ONE OR MORE CYSTS FILLED WITH CLEAR LIQUID ARE SEEN.

UTERUS

HYPERPLASIA POLYPOID:
UNILATERAL
A PEDUNCULATED GROWTH IN THE LUMEN IS PRESENT

FEMALE 55 (1481/60)

LUNG

*** ALVEOLOGENIC CARCINOMA :
A MALIGNANT TUMOR OF THE LUNG TISSUE WITH SYNONYMS IN MICE FOR ADENOMA, CARCINOMA, ALVEOLOGENIC PAPILLARY CARCINOMA, PAPILLARY CYSTADENOMA, ADENOCARCINOMA, BRONCHIOLAR CELL CARCINOMA, BRONCHIOLAR-ALVEOLAR TUMOR, TYPE A TUMOR, TYPE B TUMOR, INTERMEDIATE TYPE I TUMOR AND COMMON PULMONARY TUMOR OF THE MOUSE.

LIVER

VACUOLIZATION :
IN THESE CELLS THERE ARE CLEAR VACUOLES GREATER IN NUMBER AND SIZE THAN NORMALLY FOUND.

PANCREAS

ABSENT :
ORGAN OR TISSUE NOT REMOVED FROM ANIMAL OR NOT FOUND IN FIXATIVE.

SPLEEN

HEMATOPOIESIS :
MODERATE
THE HEMATOPOIESIS IS EVIDENT.

BLADDER

HYPERPLASIA PAPILLOMATOUS :
THE THICKNESS OF THE MUCOSA IS INCREASED MAKING UNUSUALLY HIGH AND NUMEROUS FOLDS.

ADRENALS

PIGMENTATION :
NUMEROUS MACROPHAGES CONTAIN A GRANULAR BROWN CYTOPLASMIC PIGMENT.

OVARIES

** LUTEOMA :
UNILATERAL
IT IS A BENIGN TUMOR COMPOSED OF CELLS RESEMBLING THOSE OF THE CORPUS LUTEUM.

UTERUS

ENDOMETRIOSIS :
CONTRALATERAL
ENDOMETRIAL GLANDS ARE SEEN AT VARIOUS SITES OUTSIDE THE NORMAL ENDOMETRIUM.

HYPERPLASIA SECRETORY :
UNILATERAL
THE DEVELOPED GLANDS AND/OR DUCTS CONTAIN A SECRETION

BAYER AG

FEMALE 57 (1482/60)

LUNG

*** ALVEOLOGENIC CARCINOMA :
A MALIGNANT TUMOR OF THE LUNG TISSUE WITH SYNONYMS IN MICE FOR ADENOMA, CARCINOMA, ALVEOLOGENIC PAPILLARY CARCINOMA, PAPILLARY CYSTADENOMA, ADENOCARCINOMA, BRONCHIOLAR CELL CARCINOMA, BRONCHIOLAR-ALVEOLAR TUMOR, TYPE A TUMOR, TYPE B TUMOR, INTERMEDIATE TYPE I TUMOR AND COMMON PULMONARY TUMOR OF THE MOUSE.

LIVER

HYPERTROPHY :
THE SIZE OF THE ORGAN IS INCREASED WITHOUT STRUCTURAL ANOMALY.

SPLEEN

HEMATOPOIESIS :
SEVERE
THE HEMATOPOIESIS IS EVIDENT.

HEMORRAGIC CYST :
ONE OR SEVERAL CAVITIES FILLED WITH BLOOD.

KIDNEYS

INTERSTITIAL NEPHRITIS :
BILATERAL MULTIFOCAL
INFLAMMATORY CELLS FIBROSIS AND SOME TUBULAR ALTERATIONS ARE ASSOCIATED.

CYSTS :
BILATERAL
ONE OR MORE CYSTS FILLED WITH CLEAR LIQUID ARE SEEN.

BLADDER

INFLAMMATION CHRONIC :
THERE IS AN INFILTRATION BY MONONUCLEAR CELLS IN THE MUCOSA AND SUBMUCOSA.

HYPERPLASIA PAPILLOMATOUS :
THE THICKNESS OF THE MUCOSA IS INCREASED MAKING UNUSUALLY HIGH AND NUMEROUS FOLDS.

THYROIDS

ABSENT :
ORGAN OR TISSUE NOT REMOVED FROM ANIMAL OR NOT FOUND IN FIXATIVE.

ADRENALS

PIGMENTATION :
SEVERE
NUMEROUS MACROPHAGES CONTAIN A GRANULAR BROWN CYTOPLASMIC PIGMENT.

MAMMARY GLAND

*** ADENOCARCINOMA :
THE MAMMARY TUMOR IS COMPOSED OF SMALL ACINI OR TUBULES LINED BY SINGLE LAYER OF CUBOIDAL CELLS WHICH MAY BE INFILTRATING/METASTASING.

OVARIES

ATROPHY :
BILATERAL
THE ORGAN IS REDUCED IN SIZE.

CYSTS :
UNILATERAL
ONE OR MORE CYSTS FILLED WITH CLEAR LIQUID ARE SEEN.

FEMALE 66 (1483/80)

BRAIN

HEMORRHAGE :
THERE IS EXTRAVASATION OF BLOOD.

LUNG

*** ALVEOLOGENIC CARCINOMA :
A MALIGNANT TUMOR OF THE LUNG TISSUE WITH SYNONYMS IN MICE FOR ADENOMA, CARCINOMA, ALVEOLOGENIC PAPILLARY CARCINOMA, PAPILLARY CYSTADENOMA, ADENOCARCINOMA, BRONCHIOLAR CELL CARCINOMA, BRONCHIOLAR-ALVEOLAR TUMOR, TYPE A TUMOR, TYPE B TUMOR, INTERMEDIATE TYPE I TUMOR AND COMMON PULMONARY TUMOR OF THE MOUSE.

LIVER

FAT VACUOLES :
THE CELLS ARE DISTENDED BY CLEAR CYTOPLASMIC VACUOLES WHICH FREQUENTLY DISPLACE THE NUCLEI.

CYSTS :
ONE OR MORE CYSTS FILLED WITH CLEAR LIQUID ARE SEEN.

PANCREAS

ATROPHY EPITHELIAL :

BAYER AG

PANCREAS CONTINUED

THE EPITHELIAL TISSUE IS ATROPHIC AND SCANTY WITH INCREASED FIBROUS STROMA.

PERIARTERITIS :
NON SPECIFIC INFLAMMATION (ACUTE SUBACUTE OR CHRONIC) OF THE TUNICA ADVENTITIA (PERIVASCULAR GRANULOMA).

SPLEEN

HEMATOPOIESIS :
SEVERE
THE HEMATOPOIESIS IS EVIDENT.

PITUITARY

CYSTS :
ONE OR MORE CYSTS FILLED WITH CLEAR LIQUID ARE SEEN.

THYROIDS

ABSENT :
ORGAN OR TISSUE NOT REMOVED FROM ANIMAL OR NOT FOUND IN FIXATIVE.

ADRENALS

ABSENT :
ORGAN OR TISSUE NOT REMOVED FROM ANIMAL OR NOT FOUND IN FIXATIVE.

MESENTERY

INFLAMMATION CHRONIC :
THE INTERSTITIAL TISSUES SHOW INFILTRATION BY MONONUCLEAR CELLS AND INCREASE IN FIBROUS STROMA.

OVARIES

ATROPHY :
THE ORGAN IS REDUCED IN SIZE.

UTERUS

CYSTIC ENDOMETRIAL HYPERPLASIA :
THE ENDOMETRIAL GLANDS ARE INCREASED IN NUMBER AND SOME ARE DILATED OR CYSTIC.

FEMALE 74 (1484/80)

LUNG

ATELECTASIS :
THERE IS COLLAPSE OF ALVEOLI.

LIVER

FAT VACUOLES :
THE CELLS ARE DISTENDED BY CLEAR CYTOPLASMIC VACUOLES WHICH FREQUENTLY DISPLACE THE NUCLEI.

MONONUCLEAR CELLS :
MINIMAL MULTIFOCAL
FOCAL COLLECTIONS OF MONONUCLEAR CELLS ARE PRESENT.

SPLEEN

HEMATOPOIESIS :
MINIMAL
THE HEMATOPOIESIS IS EVIDENT.

KIDNEYS

INTERSTITIAL NEPHRITIS :
BILATERAL MINIMAL MULTIFOCAL
INFLAMMATORY CELLS FIBROSIS AND SOME TUBULAR ALTERATIONS ARE ASSOCIATED.

DILATATION OF RENAL PELVIS :
BILATERAL
THE RENAL CAVITIES ARE MORE OR LESS ENLARGED.

THYROIDS

ABSENT :
ORGAN OR TISSUE NOT REMOVED FROM ANIMAL OR NOT FOUND IN FIXATIVE.

ADRENALS

PIGMENTATION :
SEVERE
NUMEROUS MACROPHAGES CONTAIN A GRANULAR BROWN CYTOPLASMIC PIGMENT.

OVARIES

ATROPHY :
BILATERAL
THE ORGAN IS REDUCED IN SIZE.

UTERUS

ENDOMETRIOSIS :
ENDOMETRIAL GLANDS ARE SEEN AT VARIOUS SITES OUTSIDE THE NORMAL ENDOMETRIUM.

BAYER AG BAYER AG BAYER AG

FEMALE 76 (1486/60)

BRAIN

VENTRICULAR DILATATION :
ORGAN CHAMBERS ARE ENLARGED.

LUNG

PNEUMONIA :
THE ALVEOLAR WALLS ARE THICKENED AND ALVEOLI CONTAIN INFLAMMATORY CELLS AND FOAMY MACROPHAGES.PERIVASCULAR AND PERIBRONCHIAL LYMPHOCYTIC ACCUMULATIONS MAY BE PRESENT.

STOMACH

HYPERKERATOSIS :
THE STRATIFIED SQUAMOUS EPITHELIUM EXHIBITS THICKENING AND EXCESS CORNIFICATION.

INFLAMMATION CHRONIC :
THERE IS AN INFILTRATION BY MONONUCLEAR CELLS IN THE MUCOSA AND SUBMUCOSA.

MUCOID CYST :
ONE OR MORE CYSTS CONTAINING MUCOID MATERIAL ARE OBSERVED.

LIVER

VACUOLIZATION :
IN THESE CELLS THERE ARE CLEAR VACUOLES GREATER IN NUMBER AND SIZE THAN NORMALLY FOUND.

HEPATOCYTIC HYPERPIGMENTATION :
MINIMAL
HEPATOCYTES ARE LADEN WITH GRANULES OF HEMOSIDERIN OR BILE OR OTHER PIGMENT.

KIDNEYS

INTERSTITIAL NEPHRITIS :
BILATERAL MINIMAL MULTIFOCAL
INFLAMMATORY CELLS FIBROSIS AND SOME TUBULAR ALTERATIONS ARE ASSOCIATED.

PITUITARY

HEMORRHAGE :
THERE IS EXTRAVASATION OF BLOOD.

THYROIDS

ABSENT :
ORGAN OR TISSUE NOT REMOVED FROM ANIMAL OR NOT FOUND IN FIXATIVE.

ADRENALS

PIGMENTATION :
SEVERE
NUMEROUS MACROPHAGES CONTAIN A GRANULAR BROWN CYTOPLASMIC PIGMENT.

MESENTERY

INFLAMMATION CHRONIC :
THE INTERSTITIAL TISSUES SHOW INFILTRATION BY MONONUCLEAR CELLS AND INCREASE IN FIBROUS STROMA.

OVARIES

ATROPHY :
THE ORGAN IS REDUCED IN SIZE.

UTERUS

HYPERPLASIA SECRETORY :
THE DEVELOPED GLANDS AND/OR DUCTS CONTAIN A SECRETION

FEMALE 78 (1464/80)

LUNG

PIGMENTATION :
MINIMAL FOCAL
NUMEROUS MACROPHAGES CONTAIN A GRANULAR BROWN CYTOPLASMIC PIGMENT.

PNEUMONIA :
THE ALVEOLAR WALLS ARE THICKENED AND ALVEOLI CONTAIN INFLAMMATORY CELLS AND FOAMY MACROPHAGES.PERIVASCULAR AND PERIBRONCHIAL LYMPHOCYTIC ACCUMULATIONS MAY BE PRESENT.

LIVER

MONONUCLEAR CELLS :
MINIMAL FOCAL
FOCAL COLLECTIONS OF MONONUCLEAR CELLS ARE PRESENT.

VACUOLIZATION :
IN THESE CELLS THERE ARE CLEAR VACUOLES GREATER IN NUMBER AND SIZE THAN NORMALLY FOUND.

PANCREAS

NORMAL :
HISTOLOGICAL ASPECT WITHIN NORMAL LIMITS.

SPLEEN

HEMATOPOIESIS :
SEVERE
THE HEMATOPOIESIS IS EVIDENT.

BLADDER

*** PAPILLOMA :

BAYER AG

BLADDER CONTINUED
A BENIGN GROWTH INTO THE LUMEN IS COMPOSED OF A VASCULAR FIBROUS CORE COVERED BY TRANSITIONAL EPITHELIUM.

ADRENALS

PIGMENTATION :
MODERATE
NUMEROUS MACROPHAGES CONTAIN A GRANULAR BROWN CYTOPLASMIC PIGMENT.

SKELETAL MUSCLE

ABSENT :
ORGAN OR TISSUE NOT REMOVED FROM ANIMAL OR NOT FOUND IN FIXATIVE.

SCIATIC NERVE

ABSENT :
ORGAN OR TISSUE NOT REMOVED FROM ANIMAL OR NOT FOUND IN FIXATIVE.

MAMMARY GLAND

*** ADENOCARCINOMA :
THE MAMMARY TUMOR IS COMPOSED OF SMALL ACINI OR TUBULES LINED BY SINGLE LAYER OF CUBOIDAL CELLS WHICH MAY BE INFILTRATING/METASTASING.

OVARIES

ATROPHY :
THE ORGAN IS REDUCED IN SIZE.

FEMUR

ABSENT :
ORGAN OR TISSUE NOT REMOVED FROM ANIMAL OR NOT FOUND IN FIXATIVE.

FEMALE 81 (1487/80)

LUNG

*** ALVEOLOGENIC CARCINOMA :
MULTIFOCAL
A MALIGNANT TUMOR OF THE LUNG TISSUE WITH SYNONYMS IN MICE FOR ADENOMA, CARCINOMA, ALVEOLOGENIC PAPILLARY CARCINOMA, PAPILLARY CYSTADENOMA, ADENOCARCINOMA, BRONCHIOLAR CELL CARCINOMA, BRONCHIOLAR-ALVEOLAR TUMOR, TYPE A TUMOR, TYPE B TUMOR, INTERMEDIATE TYPE I TUMOR AND COMMON PULMONARY TUMOR OF THE MOUSE.

LIVER

FAT VACUOLES :
MINIMAL
THE CELLS ARE DISTENDED BY CLEAR CYTOPLASMIC VACUOLES WHICH FREQUENTLY DISPLACE THE NUCLEI.

KIDNEYS

HYDRONEPHROSIS :
UNILATERAL
THE RENAL PELVIS IS DILATED AND THE ADJACENT PARENCHYMA IS REDUCED.

INTERSTITIAL NEPHRITIS :
BILATERAL MINIMAL MULTIFOCAL
INFLAMMATORY CELLS FIBROSIS AND SOME TUBULAR ALTERATIONS ARE ASSOCIATED.

BLADDER

HYPERPLASIA PAPILLOMATOUS :
THE THICKNESS OF THE MUCOSA IS INCREASED MAKING UNUSUALLY HIGH AND NUMEROUS FOLDS.

ADRENALS

PIGMENTATION :
SEVERE
NUMEROUS MACROPHAGES CONTAIN A GRANULAR BROWN CYTOPLASMIC PIGMENT.

SCIATIC NERVE

ABSENT :
ORGAN OR TISSUE NOT REMOVED FROM ANIMAL OR NOT FOUND IN FIXATIVE.

OVARIES

ATROPHY :
THE ORGAN IS REDUCED IN SIZE.

CYSTS :
UNILATERAL
ONE OR MORE CYSTS FILLED WITH CLEAR LIQUID ARE SEEN.

UTERUS

ENDOMETRIOSIS :
ENDOMETRIAL GLANDS ARE SEEN AT VARIOUS SITES OUTSIDE THE NORMAL ENDOMETRIUM.

HEMORRAGIC CYST :
UNILATERAL
ONE OR SEVERAL CAVITIES FILLED WITH BLOOD.

BAYER AG BAYER AG BAYER AG

FEMALE 82 (1488/60)

LUNG

ATELECTASIS :
THERE IS COLLAPSE OF ALVEOLI.

PANCREAS

PERIARTERITIS :
NON SPECIFIC INFLAMMATION (ACUTE SUBACUTE OR CHRONIC) OF THE TUNICA ADVENTITIA (PERIVASCULAR GRANULOMA).

KIDNEYS

INTERSTITIAL NEPHRITIS :
BILATERAL SEVERE MULTIFOCAL
INFLAMMATORY CELLS FIBROSIS AND SOME TUBULAR ALTERATIONS ARE ASSOCIATED.

BLADDER

INFLAMMATION CHRONIC :
THERE IS AN INFILTRATION BY MONONUCLEAR CELLS IN THE MUCOSA AND SUBMUCOSA.

THYROIDS

ABSENT :
ORGAN OR TISSUE NOT REMOVED FROM ANIMAL OR NOT FOUND IN FIXATIVE.

ADRENALS

PIGMENTATION :
SEVERE
NUMEROUS MACROPHAGES CONTAIN A GRANULAR BROWN CYTOPLASMIC PIGMENT.

MESENTERY

INFLAMMATION CHRONIC :
THE INTERSTITIAL TISSUES SHOW INFILTRATION BY MONONUCLEAR CELLS AND INCREASE IN FIBROUS STROMA.

OVARIES

ATROPHY :
THE ORGAN IS REDUCED IN SIZE.

FEMALE 83 (1489/80)

LUNG

PNEUMONIA :
THE ALVEOLAR WALLS ARE THICKENED AND ALVEOLI CONTAIN INFLAMMATORY CELLS AND FOAMY MACROPHAGES.PERIVASCULAR AND PERIBRONCHIAL LYMPHOCYTIC ACCUMULATIONS MAY BE PRESENT.

LIVER

FAT VACUOLES :
MINIMAL
THE CELLS ARE DISTENDED BY CLEAR CYTOPLASMIC VACUOLES WHICH FREQUENTLY DISPLACE THE NUCLEI.

SPLEEN

HEMATOPOIESIS :
MODERATE
THE HEMATOPOIESIS IS EVIDENT.

KIDNEYS

INTERSTITIAL NEPHRITIS :
BILATERAL MINIMAL FOCAL
INFLAMMATORY CELLS FIBROSIS AND SOME TUBULAR ALTERATIONS ARE ASSOCIATED

CYSTS :
BILATERAL MINIMAL FOCAL
ONE OR MORE CYSTS FILLED WITH CLEAR LIQUID ARE SEEN.

BLADDER

INFLAMMATION CHRONIC :
THERE IS AN INFILTRATION BY MONONUCLEAR CELLS IN THE MUCOSA AND SUBMUCOSA.

ADRENALS

FAT VACUOLES :
UNILATERAL
THE CELLS ARE DISTENDED BY CLEAR CYTOPLASMIC VACUOLES WHICH FREQUENTLY DISPLACE THE NUCLEI.

PIGMENTATION :
BILATERAL SEVERE
NUMEROUS MACROPHAGES CONTAIN A GRANULAR BROWN CYTOPLASMIC PIGMENT.

SCIATIC NERVE

ABSENT :
ORGAN OR TISSUE NOT REMOVED FROM ANIMAL OR NOT FOUND IN

BAYER AG

SCIATIC NERVE CONTINUED
FIXATIVE.

MESENTERY

INFLAMMATION CHRONIC :
THE INTERSTITIAL TISSUES SHOW INFILTRATION BY MONONUCLEAR CELLS AND INCREASE IN FIBROUS STROMA.

OVARIES

INFLAMMATION ACUTE :
CONTRALATERAL SEVERE
A LESION MADE OF CONGESTION EDEMA FIBRINOUS EXUDATE WITH INFILTRATION OF LEUKOCYTES.

ATROPHY :
UNILATERAL
THE ORGAN IS REDUCED IN SIZE.

HEMORRAGIC CYST :
CONTRALATERAL SEVERE
ONE OR SEVERAL CAVITIES FILLED WITH BLOOD.

UTERUS

HYPERPLASIA SECRETORY :
THE DEVELOPED GLANDS AND/OR DUCTS CONTAIN A SECRETION

FEMALE 84 (1490/80)

LUNG

NORMAL :
HISTOLOGICAL ASPECT WITHIN NORMAL LIMITS.

LIVER

FAT VACUOLES :
MINIMAL
THE CELLS ARE DISTENDED BY CLEAR CYTOPLASMIC VACUOLES WHICH FREQUENTLY DISPLACE THE NUCLEI.

HEPATOCYTIC HYPERPIGMENTATION :
MINIMAL
HEPATOCYTES ARE LADEN WITH GRANULES OF HEMOSIDERIN OR BILE OR OTHER PIGMENT.

SPLEEN

HYPERPLASIA LYMPHOID :
THE LYMPHOID FOLLICLES ARE INCREASED IN SIZE.

KIDNEYS

NORMAL :
HISTOLOGICAL ASPECT WITHIN NORMAL LIMITS.

THYROIDS

ABSENT :
ORGAN OR TISSUE NOT REMOVED FROM ANIMAL OR NOT FOUND IN FIXATIVE.

ADRENALS

PIGMENTATION :
MINIMAL
NUMEROUS MACROPHAGES CONTAIN A GRANULAR BROWN CYTOPLASMIC PIGMENT.

OVARIES

HEMORRAGIC CYST :
SEVERE
ONE OR SEVERAL CAVITIES FILLED WITH BLOOD.

UTERUS

NORMAL :
HISTOLOGICAL ASPECT WITHIN NORMAL LIMITS.

FEMALE 89 (1491/80

LUNG

EDEMA :
THE INTERSTITIAL TISSUES CONTAIN AN INCREASED AMOUNT OF FLUID.

HEMORRHAGE :

THERE IS EXTRAVASATION OF BLOOD.

*** ALVEOLOGENIC CARCINOMA :
MULTIFOCAL
A MALIGNANT TUMOR OF THE LUNG TISSUE WITH SYNONYMS IN MICE FOR ADENOMA, CARCINOMA, ALVEOLOGENIC PAPILLARY CARCINOMA, PAPILLARY CYSTADENOMA, ADENOCARCINOMA, BRONCHIOLAR CELL CARCINOMA, BRONCHIOLAR-ALVEOLAR TUMOR, TYPE A TUMOR, TYPE B TUMOR, INTERMEDIATE TYPE I TUMOR AND COMMON PULMONARY TUMOR OF THE MOUSE.

LEUKEMIC DEPOSITS :
ORGAN AND THE BLOOD ARE INVADED BY LEUKEMIC CELLS.

BAYER AG

STOMACH

INFLAMMATION CHRONIC :
SEVERE
THERE IS AN INFILTRATION BY MONONUCLEAR CELLS IN THE MUCOSA AND SUBMUCOSA.

LIVER

VACUOLIZATION :
MINIMAL
IN THESE CELLS THERE ARE CLEAR VACUOLES GREATER IN NUMBER AND SIZE THAN NORMALLY FOUND.

THYMUS

*** LYMPHOMA LYMPHOCYTIC :
THE NEOPLASM OF THE RETICULAR SYSTEM ORIGINATES FROM LYMPHOCYTES.

SPLEEN

NORMAL :
HISTOLOGICAL ASPECT WITHIN NORMAL LIMITS.

THYROIDS

ABSENT :
ORGAN OR TISSUE NOT REMOVED FROM ANIMAL OR NOT FOUND IN FIXATIVE.

OVARIES

CYSTS :
UNILATERAL
ONE OR MORE CYSTS FILLED WITH CLEAR LIQUID ARE SEEN.

HYPERTROPHIC CORPORA LUTEA :
BILATERAL
ALL CORPORA LUTEA ARE IMPORTANT IN SIZE. THEY CONTAIN LARGE LUTEAL CELLS WITH ACIDOPHILIC CYTOPLASM.

FEMALE 92 (1492/80)

LUNG

*** ALVEOLOGENIC CARCINOMA :
MULTIFOCAL
A MALIGNANT TUMOR OF THE LUNG TISSUE WITH SYNONYMS IN MICE FOR ADENOMA, CARCINOMA, ALVEOLOGENIC PAPILLARY CARCINOMA, PAPILLARY CYSTADENOMA, ADENOCARCINOMA, BRONCHIOLAR CELL CARCINOMA, BRONCHIOLAR-ALVEOLAR TUMOR, TYPE A TUMOR, TYPE B TUMOR, INTERMEDIATE TYPE I TUMOR AND COMMON PULMONARY TUMOR OF

LUNG CONTINUED

THE MOUSE.

LIVER

VACUOLIZATION :
IN THESE CELLS THERE ARE CLEAR VACUOLES GREATER IN NUMBER AND SIZE THAN NORMALLY FOUND.

SPLEEN

HEMATOPOIESIS :
MODERATE
THE HEMATOPOIESIS IS EVIDENT.

KIDNEYS

INTERSTITIAL NEPHRITIS :
BILATERAL MINIMAL FOCAL
INFLAMMATORY CELLS FIBROSIS AND SOME TUBULAR ALTERATIONS ARE ASSOCIATED.

BLADDER

INFLAMMATION CHRONIC :
THERE IS AN INFILTRATION BY MONONUCLEAR CELLS IN THE MUCOSA AND SUBMUCOSA.

HYPERPLASIA PAPILLOMATOUS :
THE THICKNESS OF THE MUCOSA IS INCREASED MAKING UNUSUALLY HIGH AND NUMEROUS FOLDS.

PITUITARY

ABSENT :
ORGAN OR TISSUE NOT REMOVED FROM ANIMAL OR NOT FOUND IN FIXATIVE.

THYROIDS

CYSTS :
ONE OR MORE CYSTS FILLED WITH CLEAR LIQUID ARE SEEN.

OVARIES

CYSTS :
CONTRALATERAL SEVERE
ONE OR MORE CYSTS FILLED WITH CLEAR LIQUID ARE SEEN.

*** CYSTADENOMA :
UNILATERAL
CYSTIC AND ADENOMATOUS CHANGE WITH CYSTIC HYPERPLASIA.

UTERUS

CYSTIC ENDOMETRIAL HYPERPLASIA :
THE ENDOMETRIAL GLANDS ARE INCREASED IN NUMBER AND SOME ARE DILATED OR CYSTIC.

BAYER AG

FEMALE 96 (1493/80)

LUNG

PNEUMONIA :
SEVERE
THE ALVEOLAR WALLS ARE THICKENED AND ALVEOLI CONTAIN INFLAMMATORY CELLS AND FOAMY MACROPHAGES.PERIVASCULAR AND PERIBRONCHIAL LYMPHOCYTIC ACCUMULATIONS MAY BE PRESENT.

STOMACH

MUCOID CYST :
MINIMAL
ONE OR MORE CYSTS CONTAINING MUCOID MATERIAL ARE OBSERVED.

LIVER

MONONUCLEAR CELLS :
MINIMAL MULTIFOCAL
FOCAL COLLECTIONS OF MONONUCLEAR CELLS ARE PRESENT.

VACUOLIZATION :
IN THESE CELLS THERE ARE CLEAR VACUOLES GREATER IN NUMBER AND SIZE THAN NORMALLY FOUND.

HEPATOCYTIC HYPERPIGMENTATION :
MINIMAL
HEPATOCYTES ARE LADEN WITH GRANULES OF HEMOSIDERIN OR BILE OR OTHER PIGMENT.

PANCREAS

FIBROSIS :
THERE IS AN INCREASE IN INTERSTITIAL FIBROUS TISSUE.

SPLEEN

HEMATOPOIESIS :
MINIMAL
THE HEMATOPOIESIS IS EVIDENT.

BLADDER

HYPERPLASIA PAPILLOMATOUS :
THE THICKNESS OF THE MUCOSA IS INCREASED MAKING UNUSUALLY HIGH AND NUMEROUS FOLDS.

THYROIDS

ABSENT :
ORGAN OR TISSUE NOT REMOVED FROM ANIMAL OR NOT FOUND IN FIXATIVE.

ADRENALS

PIGMENTATION :
SEVERE
NUMEROUS MACROPHAGES CONTAIN A GRANULAR BROWN CYTOPLASMIC PIGMENT.

OVARIES

INFLAMMATION ACUTE :
UNILATERAL
A LESION MADE OF CONGESTION EDEMA FIBRINOUS EXUDATE WITH INFILTRATION OF LEUKOCYTES.

CYSTS :
UNILATERAL
ONE OR MORE CYSTS FILLED WITH CLEAR LIQUID ARE SEEN.

CYSTS :
CONTRALATERAL
ONE OR MORE CYSTS FILLED WITH CLEAR LIQUID ARE SEEN.

UTERUS

ENDOMETRIOSIS :
SEVERE
ENDOMETRIAL GLANDS ARE SEEN AT VARIOUS SITES OUTSIDE THE NORMAL ENDOMETRIUM.

FEMALE 100 (1494/80

BRAIN

FAT VACUOLES :
MINIMAL
THE CELLS ARE DISTENDED BY CLEAR CYTOPLASMIC VACUOLES WHICH FREQUENTLY DISPLACE THE NUCLEI.

STOMACH

MUCOID CYST :
MINIMAL
ONE OR MORE CYSTS CONTAINING MUCOID MATERIAL ARE OBSERVED.

LIVER

FAT VACUOLES :
MINIMAL
THE CELLS ARE DISTENDED BY CLEAR CYTOPLASMIC VACUOLES WHICH FREQUENTLY DISPLACE THE NUCLEI.

MONONUCLEAR CELLS :
MINIMAL
FOCAL COLLECTIONS OF MONONUCLEAR CELLS ARE PRESENT.

BAYER AG

SPLEEN

HEMATOPOIESIS :
SEVERE
THE HEMATOPOIESIS IS EVIDENT.

KIDNEYS

TUBULOPATHY :
MINIMAL
TUBULAR DEGENERATIVE CHANGES ARE PRESENT
WHICH MAY BE ASSOCIATED WITH TUBULAR DILATATION.

INTERSTITIAL NEPHRITIS :
MINIMAL
INFLAMMATORY CELLS FIBROSIS AND SOME TUBULAR ALTERATIONS
ARE ASSOCIATED.

BLADDER

HYPERPLASIA PAPILLOMATOUS :
THE THICKNESS OF THE MUCOSA IS INCREASED MAKING UNUSUALLY
HIGH AND NUMEROUS FOLDS.

PITUITARY

ABSENT :
ORGAN OR TISSUE NOT REMOVED FROM ANIMAL OR NOT FOUND IN
FIXATIVE.

ADRENALS

PIGMENTATION :
UNILATERAL SEVERE
NUMEROUS MACROPHAGES CONTAIN A GRANULAR BROWN CYTOPLASMIC
PIGMENT.

OVARIES

INFLAMMATION CHRONIC :
UNILATERAL
THE INTERSTITIAL TISSUES SHOW INFILTRATION BY MONONUCLEAR
CELLS AND INCREASE IN FIBROUS STROMA.

CYSTS :
BILATERAL
ONE OR MORE CYSTS FILLED WITH CLEAR LIQUID ARE SEEN.

HISTOPATHOLOGY

PRODUCT : KWG 0519 GROUP : CONTROL
ROUTE : DIETARY
TIME : 105 WEEKS DOSE : 0 PPM
THIS GROUP COMPRISED : 33 FEMALES

THE FOLLOWING ORGANS WERE EXAMINED SYSTEMATICALLY :

HEART	LUNG	LIVER
PANCREAS	SPLEEN	KIDNEYS
BLADDER	STOMACH	OVARIES
THYROIDS	ADRENALS	PITUITARY
BRAIN	SKELETAL MUSCLE	SCIATIC NERVE
FEMUR		

THESE ORGANS WERE EXAMINED IN 33 FEMALES

INDIVIDUAL RESULTS

IN THE ANIMALS SHOWN BELOW THE HISTOLOGICAL EXAMINATION OF THE ORGANS LISTED OR OF THE ANOMALIES FOUND AT AUTOPSY GAVE THE FOLLOWING RESULTS :

FEMALE 53 (1648/80)

BRAIN

FAT VACUOLES :
FOCAL
THE CELLS ARE DISTENDED BY CLEAR CYTOPLASMIC VACUOLES WHICH FREQUENTLY DISPLACE THE NUCLEI.

HEART

CONGESTION :
VESSELS OR SINUSOIDS ARE MARKEDLY DISTENDED WITH ERYTHROCYTES.

LUNG

EDEMA :
SEVERE
THE INTERSTITIAL TISSUES CONTAIN AN INCREASED AMOUNT OF FLUID.

CONGESTION :
SEVERE
VESSELS OR SINUSOIDS ARE MARKEDLY DISTENDED WITH ERYTHROCYTES.

LEUKEMIC DEPOSITS :
ORGAN AND THE BLOOD ARE INVADED BY LEUKEMIC CELLS.

BAYER AG

LIVER

LEUKEMIC DEPOSITS :
ORGAN AND THE BLOOD ARE INVADED BY LEUKEMIC CELLS.

PANCREAS

LEUKEMIC DEPOSITS :
ORGAN AND THE BLOOD ARE INVADED BY LEUKEMIC CELLS.

SPLEEN

*** LYMPHOMA LYMPHOCYTIC :
THE NEOPLASM OF THE RETICULAR SYSTEM ORIGINATES FROM LYMPHOCYTES.

KIDNEYS

LEUKEMIC DEPOSITS :
ORGAN AND THE BLOOD ARE INVADED BY LEUKEMIC CELLS.

BLADDER

LEUKEMIC DEPOSITS :
ORGAN AND THE BLOOD ARE INVADED BY LEUKEMIC CELLS.

MESENTERY

LEUKEMIC DEPOSITS :
ORGAN AND THE BLOOD ARE INVADED BY LEUKEMIC CELLS.

OVARIES

LEUKEMIC DEPOSITS :
ORGAN AND THE BLOOD ARE INVADED BY LEUKEMIC CELLS.

UTERUS

LEUKEMIC DEPOSITS :
ORGAN AND THE BLOOD ARE INVADED BY LEUKEMIC CELLS.

LYMPH NODE

*** LYMPHOMA LYMPHOCYTIC :
THE NEOPLASM OF THE RETICULAR SYSTEM ORIGINATES FROM LYMPHOCYTES.

FEMALE 54 (165:/60)

HEART

CONGESTION :
VESSELS OR SINUSOIDS ARE MARKEDLY DISTENDED WITH ERYTHROCYTES.

LUNG

HEMORRHAGE :
SEVERE
THERE IS EXTRAVASATION OF BLOOD.

CONGESTION :
SEVERE
VESSELS OR SINUSOIDS ARE MARKEDLY DISTENDED WITH ERYTHROCYTES.

STOMACH

NORMAL :
HISTOLOGICAL ASPECT WITHIN NORMAL LIMITS.

LIVER

CONGESTION :
VESSELS OR SINUSOIDS ARE MARKEDLY DISTENDED WITH ERYTHROCYTES.

SPLEEN

HEMATOPOIESIS :
SEVERE
THE HEMATOPOIESIS IS EVIDENT.

KIDNEYS

CALCIFICATION :
BILATERAL MINIMAL MULTIFOCAL
THERE ARE MINERAL DEPOSITS.

INTERSTITIAL NEPHRITIS :
BILATERAL MINIMAL MULTIFOCAL
INFLAMMATORY CELLS FIBROSIS AND SOME TUBULAR ALTERATIONS ARE ASSOCIATED.

THYROIDS

CYSTS :
UNILATERAL
ONE OR MORE CYSTS FILLED WITH CLEAR LIQUID ARE SEEN.

ADRENALS

PIGMENTATION :
UNILATERAL MINIMAL
NUMEROUS MACROPHAGES CONTAIN A GRANULAR BROWN CYTOPLASMIC PIGMENT.

OVARIES

HYPERTROPHIC CORPORA LUTEA :
BILATERAL

BAYER AG

OVARIES CONTINUED

ALL CORPORA LUTEA ARE IMPORTANT IN SIZE. THEY CONTAIN LARGE LUTEAL CELLS WITH ACIDOPHILIC CYTOPLASM.

UTERUS

NORMAL :
HISTOLOGICAL ASPECT WITHIN NORMAL LIMITS.

FEMALE 56 (165a/80)

BRAIN

AUTOLYSIS :
THE TISSUES EXHIBIT AUTOLYSIS AND THEY ARE NOT INTERPRETABLE.

HEART

CONGESTION :
VESSELS OR SINUSOIDS ARE MARKEDLY DISTENDED WITH ERYTHROCYTES.

LUNG

CONGESTION :
VESSELS OR SINUSOIDS ARE MARKEDLY DISTENDED WITH ERYTHROCYTES.

STOMACH

AUTOLYSIS :
THE TISSUES EXHIBIT AUTOLYSIS AND THEY ARE NOT INTERPRETABLE.

LIVER

LEUKEMIC DEPOSITS :
ORGAN AND THE BLOOD ARE INVADED BY LEUKEMIC CELLS.

AUTOLYSIS PARTIAL :
NO OTHER CHANGES ARE SEEN. TISSUES ARE ALTERED. BY POST-MORTEM MODIFICATIONS AND DIAGNOSIS IS GIVEN WITH RESERVATION.

PANCREAS

AUTOLYSIS :
THE TISSUES EXHIBIT AUTOLYSIS AND THEY ARE NOT INTERPRETABLE.

SPLEEN

*** LYMPHOMA LYMPHOCYTIC :

SPLEEN CONTINUED

THE NEOPLASM OF THE RETICULAR SYSTEM ORIGINATES FROM LYMPHOCYTES.

KIDNEYS

AUTOLYSIS :
THE TISSUES EXHIBIT AUTOLYSIS AND THEY ARE NOT INTERPRETABLE.

BLADDER

AUTOLYSIS :
THE TISSUES EXHIBIT AUTOLYSIS AND THEY ARE NOT INTERPRETABLE.

PITUITARY

AUTOLYSIS :
THE TISSUES EXHIBIT AUTOLYSIS AND THEY ARE NOT INTERPRETABLE.

THYROIDS

AUTOLYSIS :
THE TISSUES EXHIBIT AUTOLYSIS AND THEY ARE NOT INTERPRETABLE.

ADRENALS

AUTOLYSIS :
THE TISSUES EXHIBIT AUTOLYSIS AND THEY ARE NOT INTERPRETABLE.

SKELETAL MUSCLE

AUTOLYSIS :
THE TISSUES EXHIBIT AUTOLYSIS AND THEY ARE NOT INTERPRETABLE.

SCIATIC NERVE

AUTOLYSIS :
THE TISSUES EXHIBIT AUTOLYSIS AND THEY ARE NOT INTERPRETABLE.

OVARIES

AUTOLYSIS :
THE TISSUES EXHIBIT AUTOLYSIS AND THEY ARE NOT INTERPRETABLE.

LYMPH-NODE

*** LYMPHOMA LYMPHOCYTIC :
THE NEOPLASM OF THE RETICULAR SYSTEM ORIGINATES FROM LYMPHOCYTES.

AUTOLYSIS PARTIAL :
NO OTHER CHANGES ARE SEEN. TISSUES ARE ALTERED. BY POST-MORTEM MODIFICATIONS AND DIAGNOSIS IS GIVEN WITH RESERVATION.

BAYER AG

FEMALE 56 (1058/80)

HEART

CONGESTION :
VESSELS OR SINUSOIDS ARE MARKEDLY DISTENDED WITH ERYTHROCYTES.

LEUKEMIC DEPOSITS :
ORGAN AND THE BLOOD ARE INVADED BY LEUKEMIC CELLS.

LUNG

NORMAL :
HISTOLOGICAL ASPECT WITHIN NORMAL LIMITS.

STOMACH

AUTOLYSIS :
THE TISSUES EXHIBIT AUTOLYSIS AND THEY ARE NOT INTERPRETABLE.

LIVER

HYPERPLASTIC NODULE :
A NODULE OF HYPERPLASTIC TISSUE IS PRESENT.

AUTOLYSIS PARTIAL :
NO OTHER CHANGES ARE SEEN. TISSUES ARE ALTERED. BY POST-MORTEM MODIFICATIONS AND DIAGNOSIS IS GIVEN WITH RESERVATION.

PANCREAS

AUTOLYSIS PARTIAL :
NO OTHER CHANGES ARE SEEN. TISSUES ARE ALTERED. BY POST-MORTEM MODIFICATIONS AND DIAGNOSIS IS GIVEN WITH RESERVATION.

THYMUS

*** LYMPHOMA LYMPHOCYTIC :
THE NEOPLASM OF THE RETICULAR SYSTEM ORIGINATES FROM LYMPHOCYTES.

SPLEEN

AUTOLYSIS PARTIAL :
NO OTHER CHANGES ARE SEEN. TISSUES ARE ALTERED. BY POST-MORTEM MODIFICATIONS AND DIAGNOSIS IS GIVEN WITH RESERVATION.

KIDNEYS

INTERSTITIAL NEPHRITIS :
BILATERAL MINIMAL
INFLAMMATORY CELLS FIBROSIS AND SOME TUBULAR ALTERATIONS ARE ASSOCIATED.

AUTOLYSIS PARTIAL :
BILATERAL MINIMAL
NO OTHER CHANGES ARE SEEN. TISSUES ARE ALTERED. BY POST-MORTEM MODIFICATIONS AND DIAGNOSIS IS GIVEN WITH RESERVATION.

BLADDER

AUTOLYSIS :
THE TISSUES EXHIBIT AUTOLYSIS AND THEY ARE NOT INTERPRETABLE.

MESENTERY

LEUKEMIC DEPOSITS :
ORGAN AND THE BLOOD ARE INVADED BY LEUKEMIC CELLS.

OVARIES

CYSTS :
UNILATERAL
ONE OR MORE CYSTS FILLED WITH CLEAR LIQUID ARE SEEN.

UTERUS

HYPERPLASIA SECRETORY :
THE DEVELOPED GLANDS AND/OR DUCTS CONTAIN A SECRETION

LEUKEMIC DEPOSITS :
ORGAN AND THE BLOOD ARE INVADED BY LEUKEMIC CELLS.

FEMALE 59 (1657/80)

BRAIN

FAT VACUOLES :
FOCAL
THE CELLS ARE DISTENDED BY CLEAR CYTOPLASMIC VACUOLES WHICH FREQUENTLY DISPLACE THE NUCLEI.

LUNG

EDEMA :
SEVERE
THE INTERSTITIAL TISSUES CONTAIN AN INCREASED AMOUNT OF

BAYER AG

LUNG CONTINUED

FLUID.

HEMORRHAGE :
THERE IS EXTRAVASATION OF BLOOD.

CONGESTION :
SEVERE
VESSELS OR SINUSOIDS ARE MARKEDLY DISTENDED WITH ERYTHROCYTES.

LIVER

HEMATOPOIESIS :
SEVERE
THE HEMATOPOIESIS IS EVIDENT.

CONGESTION :
VESSELS OR SINUSOIDS ARE MARKEDLY DISTENDED WITH ERYTHROCYTES.

AUTOLYSIS PARTIAL :
NO OTHER CHANGES ARE SEEN. TISSUES ARE ALTERED. BY POST-MORTEM MODIFICATIONS AND DIAGNOSIS IS GIVEN WITH RESERVATION.

PANCREAS

AUTOLYSIS PARTIAL :
NO OTHER CHANGES ARE SEEN. TISSUES ARE ALTERED. BY POST-MORTEM MODIFICATIONS AND DIAGNOSIS IS GIVEN WITH RESERVATION.

SPLEEN

AUTOLYSIS :
THE TISSUES EXHIBIT AUTOLYSIS AND THEY ARE NOT INTERPRETABLE.

KIDNEYS

CONGESTION :
VESSELS OR SINUSOIDS ARE MARKEDLY DISTENDED WITH ERYTHROCYTES.

OVARIES

*** METASTASIS :
UNILATERAL
A SECONDARY MALIGNANT TUMOR DEVELOPED AWAY FROM THE INITIAL GROWTH.

CYSTS :
UNILATERAL
ONE OR MORE CYSTS FILLED WITH CLEAR LIQUID ARE SEEN.

UTERUS

ENDOMETRIOSIS :
ENDOMETRIAL GLANDS ARE SEEN AT VARIOUS SITES OUTSIDE THE NORMAL ENDOMETRIUM.

CERVIX

*** LEIOMYOSARCOMA :
MALIGNANT TUMOR DERIVED FROM SMOOTH MUSCLE FIBERS.

FEMALE 60 (1670/80)

HEART

CONGESTION :
VESSELS OR SINUSOIDS ARE MARKEDLY DISTENDED WITH ERYTHROCYTES.

LUNG

EDEMA :
SEVERE
THE INTERSTITIAL TISSUES CONTAIN AN INCREASED AMOUNT OF FLUID.

CONGESTION :
SEVERE
VESSELS OR SINUSOIDS ARE MARKEDLY DISTENDED WITH ERYTHROCYTES.

LIVER

INFARCT :
MULTIFOCAL
AN AREA OF ISCHEMIC NECROSIS DUE TO VASCULAR OCCLUSION IS PRESENT.

*** ADENOCARCINOMA :
MALIGNANT EPITHELIAL TUMOR SHOWING VARIOUS WELL DIFFERENTIATED MORPHOLOGICAL ASPECTS.

CONGESTION :
VESSELS OR SINUSOIDS ARE MARKEDLY DISTENDED WITH ERYTHROCYTES.

HEMORRAGIC CYST :
ONE OR SEVERAL CAVITIES FILLED WITH BLOOD.

PANCREAS

HEMORRAGIC CYST :
ONE OR SEVERAL CAVITIES FILLED WITH BLOOD.

SPLEEN

HEMATOPOIESIS :
SEVERE
THE HEMATOPOIESIS IS EVIDENT.

BAYER AG

BLADDER

UNREADABLE :
IT IS NOT POSSIBLE TO INTERPRET THE SECTION DUE TO AN ARTIFACT CAUSED BY SAMPLING OR HISTOLOGICAL TECHNIQUE.

OVARIES

ATROPHY :
UNILATERAL
THE ORGAN IS REDUCED IN SIZE.

HEMORRAGIC CYST :
UNILATERAL
ONE OR SEVERAL CAVITIES FILLED WITH BLOOD.

UTERUS

UNREADABLE :
IT IS NOT POSSIBLE TO INTERPRET THE SECTION DUE TO AN ARTIFACT CAUSED BY SAMPLING OR HISTOLOGICAL TECHNIQUE.

FEMALE 61 (1649/80)

LUNG

PNEUMONIA :
THE ALVEOLAR WALLS ARE THICKENED AND ALVEOLI CONTAIN INFLAMMATORY CELLS AND FOAMY MACROPHAGES.PERIVASCULAR AND PERIBRONCHIAL LYMPHOCYTIC ACCUMULATIONS MAY BE PRESENT.

LIVER

ABSENT :
ORGAN OR TISSUE NOT REMOVED FROM ANIMAL OR NOT FOUND IN FIXATIVE.

KIDNEYS

INTERSTITIAL NEPHRITIS :
UNILATERAL MINIMAL FOCAL
INFLAMMATORY CELLS FIBROSIS AND SOME TUBULAR ALTERATIONS ARE ASSOCIATED.

ADRENALS

PIGMENTATION :
SEVERE
NUMEROUS MACROPHAGES CONTAIN A GRANULAR BROWN CYTOPLASMIC PIGMENT.

OVARIES

ATROPHY :
THE ORGAN IS REDUCED IN SIZE.

UTERUS

HYPERPLASIA POLYPOID:
A PEDUNCULATED GROWTH IN THE LUMEN IS PRESENT

FEMALE 62 (1655/80)

HEART

LEUKEMIC DEPOSITS :
ORGAN AND THE BLOOD ARE INVADED BY LEUKEMIC CELLS.

LUNG

CONGESTION :
VESSELS OR SINUSOIDS ARE MARKEDLY DISTENDED WITH ERYTHROCYTES.

LEUKEMIC DEPOSITS :
ORGAN AND THE BLOOD ARE INVADED BY LEUKEMIC CELLS.

LIVER

MONONUCLEAR CELLS :
MINIMAL MULTIFOCAL
FOCAL COLLECTIONS OF MONONUCLEAR CELLS ARE PRESENT.

CONGESTION :
VESSELS OR SINUSOIDS ARE MARKEDLY DISTENDED WITH ERYTHROCYTES.

HEPATOCYTIC HYPERPIGMENTATION :
MINIMAL MULTIFOCAL
HEPATOCYTES ARE LADEN WITH GRANULES OF HEMOSIDERIN OR BILE OR OTHER PIGMENT.

PANCREAS

LEUKEMIC DEPOSITS :
ORGAN AND THE BLOOD ARE INVADED BY LEUKEMIC CELLS.

SPLEEN

HYPERTROPHY :
THE SIZE OF THE ORGAN IS INCREASED WITHOUT STRUCTURAL ANOMALY.

KIDNEYS

HYDRONEPHROSIS :
THE RENAL PELVIS IS DILATED AND THE ADJACENT PARENCHYMA IS REDUCED.

INTERSTITIAL NEPHRITIS :
BILATERAL MINIMAL MULTIFOCAL

BAYER AG

KIDNEYS CONTINUED

INFLAMMATORY CELLS FIBROSIS AND SOME TUBULAR ALTERATIONS ARE ASSOCIATED.

BLADDER

LEUKEMIC DEPOSITS :
ORGAN AND THE BLOOD ARE INVADED BY LEUKEMIC CELLS.

PITUITARY

ABSENT :
ORGAN OR TISSUE NOT REMOVED FROM ANIMAL OR NOT FOUND IN FIXATIVE.

SKELETAL MUSCLE

ABSENT :
ORGAN OR TISSUE NOT REMOVED FROM ANIMAL OR NOT FOUND IN FIXATIVE.

SCIATIC NERVE

ABSENT :
ORGAN OR TISSUE NOT REMOVED FROM ANIMAL OR NOT FOUND IN FIXATIVE.

OVARIES

LEUKEMIC DEPOSITS :
ORGAN AND THE BLOOD ARE INVADED BY LEUKEMIC CELLS.

UTERUS

LEUKEMIC DEPOSITS :
ORGAN AND THE BLOOD ARE INVADED BY LEUKEMIC CELLS.

LYMPH NODE

*** LYMPHOMA LYMPHOCYTIC :
THE NEOPLASM OF THE RETICULAR SYSTEM ORIGINATES FROM LYMPHOCYTES.

LYMPHOCELE :
THE LYMPH NODE IS VERY DISTENDED BY A LIQUID.

FEMALE 63 (1674/80)

BRAIN

GLIOSIS :
FOCAL

BRAIN CONTINUED
THERE IS PROLIFERATION OF GLIAL CELLS.

SPLEEN

HEMATOPOIESIS :
SEVERE
THE HEMATOPOIESIS IS EVIDENT.

KIDNEYS

PROGRESSIVE NEPHROPATHY :
SEVERE
AN AGE ASSOCIATED KIDNEY LESION CONSISTING OF CYSTIC TUBULES WITH COLLOID OR HYALINE CASTS CHRONIC INTERSTITIAL NEPHRITIS AND DILATATION OF BOWMAN'S CAPSULE WITH GLOMERULAR DEGENERATION .

THYROIDS

ABSENT :
ORGAN OR TISSUE NOT REMOVED FROM ANIMAL OR NOT FOUND IN FIXATIVE.

ADRENALS

HYPERPLASIA OF THE GLOMERULAR LAYER :
BILATERAL
THE GLOMERULAR LAYER IS THICKER THAN NORMAL.

SCIATIC NERVE

ABSENT :
ORGAN OR TISSUE NOT REMOVED FROM ANIMAL OR NOT FOUND IN FIXATIVE.

OVARIES

ATROPHY :
THE ORGAN IS REDUCED IN SIZE.

CYSTS :
UNILATERAL
ONE OR MORE CYSTS FILLED WITH CLEAR LIQUID ARE SEEN.

UTERUS

HEMORRHAGE :
SEVERE
THERE IS EXTRAVASATION OF BLOOD.

*** ADENOCARCINOMA :
UNILATERAL
THE MALIGNANT TUMOR IS COMPOSED OF A DIVERSIFIED GROUP OF EPITHELIAL CELLS WITH GLANDULAR PATTERNS WICH MAY BE SOMETIMES CYSTIC.

HYPERPLASIA SECRETORY :

THE DEVELOPED GLANDS AND/OR DUCTS CONTAIN A SECRETION

BAYER AG BAYER BAYER

FEMALE 64 (1669/80)

HEART

CONGESTION :
VESSELS OR SINUSOIDS ARE MARKEDLY DISTENDED WITH ERYTHROCYTES.

LUNG

EDEMA :
THE INTERSTITIAL TISSUES CONTAIN AN INCREASED AMOUNT OF FLUID.

*** ALVEOLOGENIC CARCINOMA :
A MALIGNANT TUMOR OF THE LUNG TISSUE WITH SYNONYMS IN MICE FOR ADENOMA, CARCINOMA, ALVEOLOGENIC PAPILLARY CARCINOMA, PAPILLARY CYSTADENOMA, ADENOCARCINOMA, BRONCHIOLAR CELL CARCINOMA, BRONCHIOLAR-ALVEOLAR TUMOR, TYPE A TUMOR, TYPE B TUMOR, INTERMEDIATE TYPE I TUMOR AND COMMON PULMONARY TUMOR OF THE MOUSE.

CONGESTION :
VESSELS OR SINUSOIDS ARE MARKEDLY DISTENDED WITH ERYTHROCYTES.

STOMACH

LEUKEMIC DEPOSITS :
ORGAN AND THE BLOOD ARE INVADED BY LEUKEMIC CELLS.

LIVER

LEUKEMIC DEPOSITS :
ORGAN AND THE BLOOD ARE INVADED BY LEUKEMIC CELLS.

SPLEEN

*** LYMPHOMA LYMPHOCYTIC :
THE NEOPLASM OF THE RETICULAR SYSTEM ORIGINATES FROM LYMPHOCYTES.

KIDNEYS

LEUKEMIC DEPOSITS :
ORGAN AND THE BLOOD ARE INVADED BY LEUKEMIC CELLS.

PROGRESSIVE NEPHROPATHY :
AN AGE ASSOCIATED KIDNEY LESION CONSISTING OF CYSTIC TUBULES WITH COLLOID OR HYALINE CASTS CHRONIC INTERSTITIAL NEPHRITIS

KIDNEYS CONTINUED

AND DILATATION OF BOWMAN'S CAPSULE WITH GLOMERULAR DEGENERATION .

BLADDER

LEUKEMIC DEPOSITS :
ORGAN AND THE BLOOD ARE INVADED BY LEUKEMIC CELLS.

THYROIDS

LEUKEMIC DEPOSITS :
ORGAN AND THE BLOOD ARE INVADED BY LEUKEMIC CELLS.

SKELETAL MUSCLE

LEUKEMIC DEPOSITS :
ORGAN AND THE BLOOD ARE INVADED BY LEUKEMIC CELLS.

MESENTERY

LEUKEMIC DEPOSITS :
ORGAN AND THE BLOOD ARE INVADED BY LEUKEMIC CELLS.

OVARIES

ATROPHY :
THE ORGAN IS REDUCED IN SIZE.

UTERUS

HYPERPLASIA SECRETORY :
THE DEVELOPED GLANDS AND/OR DUCTS CONTAIN A SECRETION

LYMPH NODE

*** LYMPHOMA LYMPHOCYTIC :
THE NEOPLASM OF THE RETICULAR SYSTEM ORIGINATES FROM LYMPHOCYTES.

FEMALE 67 (1645/80)

STOMACH

AUTOLYSIS :
THE TISSUES EXHIBIT AUTOLYSIS AND THEY ARE NOT INTERPRETABLE.

BAYER AG

LIVER

LEUKEMIC DEPOSITS :
ORGAN AND THE BLOOD ARE INVADED BY LEUKEMIC CELLS.

AUTOLYSIS PARTIAL :
NO OTHER CHANGES ARE SEEN. TISSUES ARE ALTERED. BY POST-MORTEM MODIFICATIONS AND DIAGNOSIS IS GIVEN WITH RESERVATION.

PANCREAS

AUTOLYSIS :
THE TISSUES EXHIBIT AUTOLYSIS AND THEY ARE NOT INTERPRETABLE.

SPLEEN

*** LYMPHOMA LYMPHOCYTIC :
THE NEOPLASM OF THE RETICULAR SYSTEM ORIGINATES FROM LYMPHOCYTES.

KIDNEYS

TUBULOPATHY :
TUBULAR DEGENERATIVE CHANGES ARE PRESENT WHICH MAY BE ASSOCIATED WITH TUBULAR DILATATION.

INTERSTITIAL NEPHRITIS :
MULTIFOCAL
INFLAMMATORY CELLS FIBROSIS AND SOME TUBULAR ALTERATIONS ARE ASSOCIATED.

BLADDER

AUTOLYSIS :
THE TISSUES EXHIBIT AUTOLYSIS AND THEY ARE NOT INTERPRETABLE.

ADRENALS

PIGMENTATION :
UNILATERAL MINIMAL
NUMEROUS MACROPHAGES CONTAIN A GRANULAR BROWN CYTOPLASMIC PIGMENT.

OVARIES

HYPERTROPHIC CORPORA LUTEA :
ALL CORPORA LUTEA ARE IMPORTANT IN SIZE. THEY CONTAIN LARGE LUTEAL CELLS WITH ACIDOPHILIC CYTOPLASM.

FEMALE 68 (1052/80)

HEART

LEUKEMIC DEPOSITS :
ORGAN AND THE BLOOD ARE INVADED BY LEUKEMIC CELLS.

LUNG

LEUKEMIC DEPOSITS :
ORGAN AND THE BLOOD ARE INVADED BY LEUKEMIC CELLS.

LIVER

NORMAL :
HISTOLOGICAL ASPECT WITHIN NORMAL LIMITS.

THYMUS

*** LYMPHOMA LYMPHOCYTIC :
THE NEOPLASM OF THE RETICULAR SYSTEM ORIGINATES FROM LYMPHOCYTES.

SPLEEN

NORMAL :
HISTOLOGICAL ASPECT WITHIN NORMAL LIMITS.

KIDNEYS

NORMAL :
HISTOLOGICAL ASPECT WITHIN NORMAL LIMITS.

PITUITARY

CYSTS :

ONE OR MORE CYSTS FILLED WITH CLEAR LIQUID ARE SEEN.

ADRENALS

PIGMENTATION :
UNILATERAL SEVERE
NUMEROUS MACROPHAGES CONTAIN A GRANULAR BROWN CYTOPLASMIC PIGMENT.

OVARIES

ATROPHY :
CONTRALATERAL
THE ORGAN IS REDUCED IN SIZE.

CYSTS :
CONTRALATERAL
ONE OR MORE CYSTS FILLED WITH CLEAR LIQUID ARE SEEN.

HYPERTROPHIC CORPORA LUTEA :
UNILATERAL
ALL CORPORA LUTEA ARE IMPORTANT IN SIZE. THEY CONTAIN LARGE LUTEAL CELLS WITH ACIDOPHILIC CYTOPLASM.

BAYER AG

UTERUS

ENDOMETRIOSIS :
ENDOMETRIAL GLANDS ARE SEEN AT VARIOUS SITES OUTSIDE THE NORMAL ENDOMETRIUM.

FEMALE 69 (1659/80)

HEART

CONGESTION :
SEVERE
VESSELS OR SINUSOIDS ARE MARKEDLY DISTENDED WITH ERYTHROCYTES.

LUNG

THROMBOSIS :
SEVERE
THE VASCULAR LUMEN CONTAINS AN ATTACHED ANTE MORTEM BLOOD CLOT.

PNEUMONIA :
SEVERE
THE ALVEOLAR WALLS ARE THICKENED AND ALVEOLI CONTAIN INFLAMMATORY CELLS AND FOAMY MACROPHAGES.PERIVASCULAR AND PERIBRONCHIAL LYMPHOCYTIC ACCUMULATIONS MAY BE PRESENT.

CONGESTION :
SEVERE
VESSELS OR SINUSOIDS ARE MARKEDLY DISTENDED WITH ERYTHROCYTES.

LIVER

CONGESTION :
VESSELS OR SINUSOIDS ARE MARKEDLY DISTENDED WITH ERYTHROCYTES.

PANCREAS

AUTOLYSIS :
THE TISSUES EXHIBIT AUTOLYSIS AND THEY ARE NOT INTERPRETABLE.

SPLEEN

HEMATOPOIESIS :
SEVERE
THE HEMATOPOIESIS IS EVIDENT.

KIDNEYS

INTERSTITIAL NEPHRITIS :
BILATERAL MODERATE MULTIFOCAL

NFC.19 FEMALE 69 CONTINUED

KIDNEYS CONTINUED

INFLAMMATORY CELLS FIBROSIS AND SOME TUBULAR ALTERATIONS ARE ASSOCIATED.

MESENTERY

*** METASTASIS :
A SECONDARY MALIGNANT TUMOR DEVELOPED AWAY FROM THE INITIAL GROWTH.

OVARIES

ATROPHY :
THE ORGAN IS REDUCED IN SIZE.

UTERUS

AUTOLYSIS PARTIAL :
NO OTHER CHANGES ARE SEEN. TISSUES ARE ALTERED.
BY POST-MORTEM MODIFICATIONS AND
DIAGNOSIS IS GIVEN WITH RESERVATION.

BODY WALL

AUTOLYSIS PARTIAL :
NO OTHER CHANGES ARE SEEN. TISSUES ARE ALTERED.
BY POST-MORTEM MODIFICATIONS AND
DIAGNOSIS IS GIVEN WITH RESERVATION.

*** MESENCHYMAL TUMOR :
MALIGNANT TUMOR DERIVED FROM UNDIFFERENTIATED COMPONENTS OF CONNECTIVE TISSUE.

FEMALE 70 (1642/60)

LUNG

HEMORRHAGE :
SEVERE
THERE IS EXTRAVASATION OF BLOOD.

CONGESTION :
SEVERE
VESSELS OR SINUSOIDS ARE MARKEDLY DISTENDED WITH ERYTHROCYTES.

STOMACH

UNREADABLE :
IT IS NOT POSSIBLE TO INTERPRET THE SECTION DUE TO AN ARTIFACT CAUSED BY SAMPLING OR HISTOLOGICAL TECHNIQUE.

LIVER

CONGESTION :
SEVERE

BAYER AG

LIVER CONTINUED

VESSELS OR SINUSOIDS ARE MARKEDLY DISTENDED WITH ERYTHROCYTES.

BLADDER

AUTOLYSIS :
THE TISSUES EXHIBIT AUTOLYSIS AND THEY ARE NOT INTERPRETABLE.

PITUITARY

ABSENT :
ORGAN OR TISSUE NOT REMOVED FROM ANIMAL OR NOT FOUND IN FIXATIVE.

THYROIDS

ABSENT :
ORGAN OR TISSUE NOT REMOVED FROM ANIMAL OR NOT FOUND IN FIXATIVE.

OVARIES

CYSTS :
BILATERAL
ONE OR MORE CYSTS FILLED WITH CLEAR LIQUID ARE SEEN.

HYPERTROPHIC CORPORA LUTEA :
BILATERAL
ALL CORPORA LUTEA ARE IMPORTANT IN SIZE. THEY CONTAIN LARGE LUTEAL CELLS WITH ACIDOPHILIC CYTOPLASM.

FEMALE 71 (1668/80)

HEART

THROMBOSIS :
THE VASCULAR LUMEN CONTAINS AN ATTACHED ANTE MORTEM BLOOD CLOT.

LUNG

PNEUMONIA :
THE ALVEOLAR WALLS ARE THICKENED AND ALVEOLI CONTAIN INFLAMMATORY CELLS AND FOAMY MACROPHAGES.PERIVASCULAR AND PERIBRONCHIAL LYMPHOCYTIC ACCUMULATIONS MAY BE PRESENT.

LIVER

MONONUCLEAR CELLS :
MINIMAL MULTIFOCAL
FOCAL COLLECTIONS OF MONONUCLEAR CELLS ARE PRESENT.

SPLEEN

*** LYMPHOMA LYMPHOCYTIC :
THE NEOPLASM OF THE RETICULAR SYSTEM ORIGINATES FROM LYMPHOCYTES.

KIDNEYS

INTERSTITIAL NEPHRITIS :
UNILATERAL MINIMAL FOCAL
INFLAMMATORY CELLS FIBROSIS AND SOME TUBULAR ALTERATIONS ARE ASSOCIATED.

BLADDER

LEUKEMIC DEPOSITS :
ORGAN AND THE BLOOD ARE INVADED BY LEUKEMIC CELLS.

ADRENALS

LEUKEMIC DEPOSITS :
UNILATERAL
ORGAN AND THE BLOOD ARE INVADED BY LEUKEMIC CELLS.

MESENTERY

LEUKEMIC DEPOSITS :
ORGAN AND THE BLOOD ARE INVADED BY LEUKEMIC CELLS.

OVARIES

ATROPHY :
UNILATERAL
THE ORGAN IS REDUCED IN SIZE.

ATROPHY :
CONTRALATERAL
THE ORGAN IS REDUCED IN SIZE.

CYSTS :
UNILATERAL
ONE OR MORE CYSTS FILLED WITH CLEAR LIQUID ARE SEEN.

FEMALE 72 (1671/80)

BRAIN

GLIOSIS :
THERE IS PROLIFERATION OF GLIAL CELLS.

BAYER AG

HEART

CONGESTION :
VESSELS OR SINUSOIDS ARE MARKEDLY DISTENDED WITH ERYTHROCYTES.

LUNG

PNEUMONIA :
SEVERE
THE ALVEOLAR WALLS ARE THICKENED AND ALVEOLI CONTAIN INFLAMMATORY CELLS AND FOAMY MACROPHAGES.PERIVASCULAR AND PERIBRONCHIAL LYMPHOCYTIC ACCUMULATIONS MAY BE PRESENT.

STOMACH

HYPERKERATOSIS :
THE STRATIFIED SQUAMOUS EPITHELIUM EXHIBITS THICKENING AND EXCESS CORNIFICATION.

LIVER

LEUKEMIC DEPOSITS :
ORGAN AND THE BLOOD ARE INVADED BY LEUKEMIC CELLS.

PANCREAS

HEMORRAGIC CYST :
ONE OR SEVERAL CAVITIES FILLED WITH BLOOD.

SPLEEN

*** LYMPHOMA GRANULOCYTIC :
THE NEOPLASM OF THE RETICULAR SYSTEM ORIGINATES FROM GRANULOCYTES.

HEMORRAGIC CYST :
ONE OR SEVERAL CAVITIES FILLED WITH BLOOD.

KIDNEYS

PROGRESSIVE NEPHROPATHY :
MINIMAL
AN AGE ASSOCIATED KIDNEY LESION CONSISTING OF CYSTIC TUBULES WITH COLLOID OR HYALINE CASTS CHRONIC INTERSTITIAL NEPHRITIS AND DILATATION OF BOWMAN'S CAPSULE WITH GLOMERULAR DEGENERATION .

MESENTERY

LEUKEMIC DEPOSITS :
ORGAN AND THE BLOOD ARE INVADED BY LEUKEMIC CELLS.

OVARIES

PUS :
A MORE OR LESS IMPORTANT QUANTITY OF PUS IS OBSERVED IN THIS TISSUE OR ORGAN.

NFC.23 FEMALE 72 CONTINUED

UTERUS

ENDOMETRIOSIS :
SEVERE
ENDOMETRIAL GLANDS ARE SEEN AT VARIOUS SITES OUTSIDE THE NORMAL ENDOMETRIUM.

ENDOMETRITIS :
SEVERE
ACUTE OR SUBACUTE INFLAMMATION IS SEEN IN ENDOMETRIUM.

PUS :
SEVERE
A MORE OR LESS IMPORTANT QUANTITY OF PUS IS OBSERVED IN THIS TISSUE OR ORGAN.

FEMALE 73 (1668/80)

LUNG

PNEUMONIA :
THE ALVEOLAR WALLS ARE THICKENED AND ALVEOLI CONTAIN INFLAMMATORY CELLS AND FOAMY MACROPHAGES, PERIVASCULAR AND PERIBRONCHIAL LYMPHOCYTIC ACCUMULATIONS MAY BE PRESENT.

STOMACH

MUCOID CYST :
ONE OR MORE CYSTS CONTAINING MUCOID MATERIAL ARE OBSERVED.

LIVER

NORMAL :
HISTOLOGICAL ASPECT WITHIN NORMAL LIMITS.

SPLEEN

HEMATOPOIESIS :
SEVERE
THE HEMATOPOIESIS IS EVIDENT.

KIDNEYS

INTERSTITIAL NEPHRITIS :
BILATERAL MINIMAL
INFLAMMATORY CELLS FIBROSIS AND SOME TUBULAR ALTERATIONS ARE ASSOCIATED.

BLADDER

INFLAMMATION CHRONIC :
THERE IS AN INFILTRATION BY MONONUCLEAR CELLS IN THE MUCOSA AND SUBMUCOSA.

BAYER AG

PITUITARY

ABSENT :
ORGAN OR TISSUE NOT REMOVED FROM ANIMAL OR NOT FOUND IN FIXATIVE.

ADRENALS

PIGMENTATION :
SEVERE
NUMEROUS MACROPHAGES CONTAIN A GRANULAR BROWN CYTOPLASMIC PIGMENT.

OVARIES

CYSTS :
ONE OR MORE CYSTS FILLED WITH CLEAR LIQUID ARE SEEN.

UTERUS

*** MESENCHYMAL TUMOR :
MALIGNANT TUMOR DERIVED FROM UNDIFFERENTIATED COMPONENTS OF CONNECTIVE TISSUE.

FEMALE 75 (1043/80)

BRAIN

AUTOLYSIS :
THE TISSUES EXHIBIT AUTOLYSIS AND THEY ARE NOT INTERPRETABLE.

HEART

CONGESTION :
SEVERE
VESSELS OR SINUSOIDS ARE MARKEDLY DISTENDED WITH ERYTHROCYTES.

LUNG

AUTOLYSIS :
THE TISSUES EXHIBIT AUTOLYSIS AND THEY ARE NOT INTERPRETABLE.

STOMACH

AUTOLYSIS :
THE TISSUES EXHIBIT AUTOLYSIS AND THEY ARE NOT INTERPRETABLE.

LIVER

AUTOLYSIS :
THE TISSUES EXHIBIT AUTOLYSIS AND THEY ARE NOT

LIVER CONTINUED

INTERPRETABLE.

PANCREAS

AUTOLYSIS :
THE TISSUES EXHIBIT AUTOLYSIS AND THEY ARE NOT INTERPRETABLE.

SPLEEN

AUTOLYSIS :
THE TISSUES EXHIBIT AUTOLYSIS AND THEY ARE NOT INTERPRETABLE.

KIDNEYS

AUTOLYSIS :
THE TISSUES EXHIBIT AUTOLYSIS AND THEY ARE NOT INTERPRETABLE.

BLADDER

AUTOLYSIS :
THE TISSUES EXHIBIT AUTOLYSIS AND THEY ARE NOT INTERPRETABLE.

PITUITARY

AUTOLYSIS :
THE TISSUES EXHIBIT AUTOLYSIS AND THEY ARE NOT INTERPRETABLE.

THYROIDS

AUTOLYSIS :
THE TISSUES EXHIBIT AUTOLYSIS AND THEY ARE NOT INTERPRETABLE.

ADRENALS

AUTOLYSIS :
THE TISSUES EXHIBIT AUTOLYSIS AND THEY ARE NOT INTERPRETABLE.

SKELETAL MUSCLE

AUTOLYSIS :
THE TISSUES EXHIBIT AUTOLYSIS AND THEY ARE NOT INTERPRETABLE.

SCIATIC NERVE

AUTOLYSIS :
THE TISSUES EXHIBIT AUTOLYSIS AND THEY ARE NOT INTERPRETABLE.

OVARIES

AUTOLYSIS :
THE TISSUES EXHIBIT AUTOLYSIS AND THEY ARE NOT INTERPRETABLE.

BAYER AG BAYER AG BAYER AG

FEMALE 77 (1644/80)

BRAIN

FAT VACUOLES :
FOCAL
THE CELLS ARE DISTENDED BY CLEAR CYTOPLASMIC VACUOLES WHICH FREQUENTLY DISPLACE THE NUCLEI.

HEART

LEUKEMIC DEPOSITS :
ORGAN AND THE BLOOD ARE INVADED BY LEUKEMIC CELLS.

LUNG

LEUKEMIC DEPOSITS :
ORGAN AND THE BLOOD ARE INVADED BY LEUKEMIC CELLS.

STOMACH

AUTOLYSIS :
THE TISSUES EXHIBIT AUTOLYSIS AND THEY ARE NOT INTERPRETABLE.

LIVER

AUTOLYSIS :
THE TISSUES EXHIBIT AUTOLYSIS AND THEY ARE NOT INTERPRETABLE.

PANCREAS

AUTOLYSIS :
THE TISSUES EXHIBIT AUTOLYSIS AND THEY ARE NOT INTERPRETABLE.

THYMUS

*** LYMPHOMA LYMPHOCYTIC :
THE NEOPLASM OF THE RETICULAR SYSTEM ORIGINATES FROM LYMPHOCYTES.

SPLEEN

*** LYMPHOMA LYMPHOCYTIC :
THE NEOPLASM OF THE RETICULAR SYSTEM ORIGINATES FROM LYMPHOCYTES.

KIDNEYS

LEUKEMIC DEPOSITS :
ORGAN AND THE BLOOD ARE INVADED BY LEUKEMIC

KIDNEYS CONTINUED

CELLS.

BLADDER

AUTOLYSIS :
THE TISSUES EXHIBIT AUTOLYSIS AND THEY ARE NOT INTERPRETABLE.

THYROIDS

AUTOLYSIS :
THE TISSUES EXHIBIT AUTOLYSIS AND THEY ARE NOT INTERPRETABLE.

OVARIES

CYSTS :
ONE OR MORE CYSTS FILLED WITH CLEAR LIQUID ARE SEEN.

LEUKEMIC DEPOSITS :
ORGAN AND THE BLOOD ARE INVADED BY LEUKEMIC CELLS.

FEMALE 79 (1667/80)

HEART

CONGESTION :
VESSELS OR SINUSOIDS ARE MARKEDLY DISTENDED WITH ERYTHROCYTES.

LUNG

CONGESTION :
VESSELS OR SINUSOIDS ARE MARKEDLY DISTENDED WITH ERYTHROCYTES.

LEUKEMIC DEPOSITS :
ORGAN AND THE BLOOD ARE INVADED BY LEUKEMIC CELLS.

LIVER

LEUKEMIC DEPOSITS :
ORGAN AND THE BLOOD ARE INVADED BY LEUKEMIC CELLS.

PANCREAS

LEUKEMIC DEPOSITS :
ORGAN AND THE BLOOD ARE INVADED BY LEUKEMIC CELLS.

BAYER AG

SPLEEN

*** LYMPHOMA GRANULOCYTIC :
THE NEOPLASM OF THE RETICULAR SYSTEM ORIGINATES FROM GRANULOCYTES.

KIDNEYS

LEUKEMIC DEPOSITS :
ORGAN AND THE BLOOD ARE INVADED BY LEUKEMIC CELLS.

BLADDER

LEUKEMIC DEPOSITS :
ORGAN AND THE BLOOD ARE INVADED BY LEUKEMIC CELLS.

PITUITARY

ABSENT :
ORGAN OR TISSUE NOT REMOVED FROM ANIMAL OR NOT FOUND IN FIXATIVE.

MESENTERY

*** METASTASIS :
A SECONDARY MALIGNANT TUMOR DEVELOPED AWAY FROM THE INITIAL GROWTH.

OVARIES

AUTOLYSIS :
THE TISSUES EXHIBIT AUTOLYSIS AND THEY ARE NOT INTERPRETABLE.

UTERUS

*** HISTIOCYTIC SARCOMA :
THIS TUMOR IS PRINCIPALLY COMPOSED OF HISTIOCYTE-LIKE CELLS. MULTINUCLEATED OR FIBROBLAST-LIKE CELLS CAN BE OBSERVED. MITOSES ARE FAIRLY FREQUENT.

FEMALE 80 (1672/80)

LUNG

PNEUMONIA :
SEVERE
THE ALVEOLAR WALLS ARE THICKENED AND ALVEOLI CONTAIN INFLAMMATORY CELLS AND FOAMY MACROPHAGES. PERIVASCULAR AND PERIBRONCHIAL LYMPHOCYTIC ACCUMULATIONS MAY BE PRESENT.

STOMACH

UNREADABLE :
IT IS NOT POSSIBLE TO INTERPRET THE SECTION DUE TO AN ARTIFACT CAUSED BY SAMPLING OR HISTOLOGICAL TECHNIQUE.

LIVER

LEUKEMIC DEPOSITS :
ORGAN AND THE BLOOD ARE INVADED BY LEUKEMIC CELLS.

SPLEEN

*** LYMPHOMA LYMPHOLYTIC :
THE NEOPLASM OF THE RETICULAR SYSTEM ORIGINATES FROM LYMPHOCYTES.

KIDNEYS

INTERSTITIAL NEPHRITIS :
MODERATE
INFLAMMATORY CELLS FIBROSIS AND SOME TUBULAR ALTERATIONS ARE ASSOCIATED.

BLADDER

UNREADABLE :
IT IS NOT POSSIBLE TO INTERPRET THE SECTION DUE TO AN ARTIFACT CAUSED BY SAMPLING OR HISTOLOGICAL TECHNIQUE.

PITUITARY

ABSENT :
ORGAN OR TISSUE NOT REMOVED FROM ANIMAL OR NOT FOUND IN FIXATIVE.

ADRENALS

HYPERPLASIA OF THE GLOMERULAR LAYER :
THE GLOMERULAR LAYER IS THICKER THAN NORMAL.

OVARIES

ATROPHY :
BILATERAL
THE ORGAN IS REDUCED IN SIZE.

CYSTS :
UNILATERAL
ONE OR MORE CYSTS FILLED WITH CLEAR LIQUID ARE SEEN.

UTERUS

HEMORRHAGE :
SEVERE
THERE IS EXTRAVASATION OF BLOOD.

CYSTIC ENDOMETRIAL HYPERPLASIA :
SEVERE
THE ENDOMETRIAL GLANDS ARE INCREASED IN NUMBER AND SOME ARE DILATED OR CYSTIC.

BAYER AG

LYMPH NODE

*** LYMPHOMA LYMPHOCYTIC :
THE NEOPLASM OF THE RETICULAR SYSTEM ORIGINATES FROM LYMPHOCYTES.

FEMALE 85 (1065/80)

BRAIN

FAT VACUOLES :
FOCAL
THE CELLS ARE DISTENDED BY CLEAR CYTOPLASMIC VACUOLES WHICH FREQUENTLY DISPLACE THE NUCLEI.

HEART

CONGESTION :
VESSELS OR SINUSOIDS ARE MARKEDLY DISTENDED WITH ERYTHROCYTES.

LUNG

HEMORRHAGE :
FOCAL
THERE IS EXTRAVASATION OF BLOOD.

CONGESTION :
VESSELS OR SINUSOIDS ARE MARKEDLY DISTENDED WITH ERYTHROCYTES.

LIVER

CONGESTION :
VESSELS OR SINUSOIDS ARE MARKEDLY DISTENDED WITH ERYTHROCYTES.

SPLEEN

HEMATOPOIESIS :
SEVERE
THE HEMATOPOIESIS IS EVIDENT.

KIDNEYS

PROGRESSIVE NEPHROPATHY :
MINIMAL
AN AGE ASSOCIATED KIDNEY LESION CONSISTING OF CYSTIC TUBULES WITH COLLOID OR HYALINE CASTS CHRONIC INTERSTITIAL NEPHRITIS AND DILATATION OF BOWMAN'S CAPSULE WITH GLOMERULAR DEGENERATION .

MESENTERY

INFLAMMATION CHRONIC :

MESENTERY CONTINUED
THE INTERSTITIAL TISSUES SHOW INFILTRATION BY MONONUCLEAR CELLS AND INCREASE IN FIBROUS STROMA.

OVARIES

ATROPHY :
THE ORGAN IS REDUCED IN SIZE.

UTERUS

HYPERPLASIA POLYPOID:
UNILATERAL
A PEDUNCULATED GROWTH IN THE LUMEN IS PRESENT

FEMALE 86 (1666/80)

LUNG

HEMORRHAGE :
MULTIFOCAL
THERE IS EXTRAVASATION OF BLOOD.

CONGESTION :
SEVERE
VESSELS OR SINUSOIDS ARE MARKEDLY DISTENDED WITH ERYTHROCYTES.

STOMACH

INFLAMMATION CHRONIC :
THERE IS AN INFILTRATION BY MONONUCLEAR CELLS IN THE MUCOSA AND SUBMUCOSA.

MUCOID CYST :
MINIMAL
ONE OR MORE CYSTS CONTAINING MUCOID MATERIAL ARE OBSERVED.

KIDNEYS

TUBULOPATHY :
BILATERAL SEVERE
TUBULAR DEGENERATIVE CHANGES ARE PRESENT WHICH MAY BE ASSOCIATED WITH TUBULAR DILATATION.

OVARIES

HYPERTROPHIC CORPORA LUTEA :
ALL CORPORA LUTEA ARE IMPORTANT IN SIZE. THEY CONTAIN LARGE LUTEAL CELLS WITH ACIDOPHILIC CYTOPLASM.

UTERUS

HYPERPLASIA SECRETORY :
THE DEVELOPED GLANDS AND/OR DUCTS CONTAIN A

BAYER AG

UTERUS CONTINUED
SECRETION

FEMALE 87 (1656/80)

HEART

CONGESTION :
VESSELS OR SINUSOIDS ARE MARKEDLY DISTENDED WITH ERYTHROCYTES.

LUNG

PNEUMONIA :
THE ALVEOLAR WALLS ARE THICKENED AND ALVEOLI CONTAIN INFLAMMATORY CELLS AND FOAMY MACROPHAGES.PERIVASCULAR AND PERIBRONCHIAL LYMPHOCYTIC ACCUMULATIONS MAY BE PRESENT.

CONGESTION :
VESSELS OR SINUSOIDS ARE MARKEDLY DISTENDED WITH ERYTHROCYTES.

STOMACH

NORMAL :
HISTOLOGICAL ASPECT WITHIN NORMAL LIMITS.

DUODENUM

AUTOLYSIS :
THE TISSUES EXHIBIT AUTOLYSIS AND THEY ARE NOT INTERPRETABLE.

LIVER

LEUKEMIC DEPOSITS :
ORGAN AND THE BLOOD ARE INVADED BY LEUKEMIC CELLS.

AUTOLYSIS PARTIAL :
NO OTHER CHANGES ARE SEEN. TISSUES ARE ALTERED. BY POST-MORTEM MODIFICATIONS AND DIAGNOSIS IS GIVEN WITH RESERVATION.

SPLEEN

*** LYMPHOMA STEM CELLS :
THE NEOPLASM OF THE RETICULAR SYSTEM ORIGINATES FROM STEM CELLS.

AUTOLYSIS PARTIAL :
NO OTHER CHANGES ARE SEEN. TISSUES ARE ALTERED. BY POST-MORTEM MODIFICATIONS AND DIAGNOSIS IS GIVEN WITH RESERVATION.

KIDNEYS

INTERSTITIAL NEPHRITIS :
MINIMAL
INFLAMMATORY CELLS FIBROSIS AND SOME TUBULAR ALTERATIONS ARE ASSOCIATED.

AUTOLYSIS PARTIAL :
NO OTHER CHANGES ARE SEEN. TISSUES ARE ALTERED. BY POST-MORTEM MODIFICATIONS AND DIAGNOSIS IS GIVEN WITH RESERVATION.

DILATATION OF GLOMERULAR LOOPS :
GLOMERULAR LOOPS APPEAR UNUSUALLY ENLARGED AND THIN.

BLADDER

LEUKEMIC DEPOSITS :
ORGAN AND THE BLOOD ARE INVADED BY LEUKEMIC CELLS.

PITUITARY

ABSENT :
ORGAN OR TISSUE NOT REMOVED FROM ANIMAL OR NOT FOUND IN FIXATIVE.

ADRENALS

PIGMENTATION :
SEVERE
NUMEROUS MACROPHAGES CONTAIN A GRANULAR BROWN CYTOPLASMIC PIGMENT.

SKELETAL MUSCLE

LEUKEMIC DEPOSITS :
ORGAN AND THE BLOOD ARE INVADED BY LEUKEMIC CELLS.

MESENTERY

LEUKEMIC DEPOSITS :
ORGAN AND THE BLOOD ARE INVADED BY LEUKEMIC CELLS.

OVARIES

LEUKEMIC DEPOSITS :
ORGAN AND THE BLOOD ARE INVADED BY LEUKEMIC CELLS.

UTERUS

LEUKEMIC DEPOSITS :
ORGAN AND THE BLOOD ARE INVADED BY LEUKEMIC CELLS.

BAYER AG BAYER AG BAYER AG

FEMALE 86 (1647/60)

BRAIN

CONGESTION :
VESSELS OR SINUSOIDS ARE MARKEDLY DISTENDED WITH ERYTHROCYTES.

HEART

CONGESTION :
VESSELS OR SINUSOIDS ARE MARKEDLY DISTENDED WITH ERYTHROCYTES.

LUNG

CONGESTION :
VESSELS OR SINUSOIDS ARE MARKEDLY DISTENDED WITH ERYTHROCYTES.

STOMACH

AUTOLYSIS :
THE TISSUES EXHIBIT AUTOLYSIS AND THEY ARE NOT INTERPRETABLE.

LIVER

CALCIFICATION :
MULTIFOCAL
THERE ARE MINERAL DEPOSITS.

CONGESTION :
VESSELS OR SINUSOIDS ARE MARKEDLY DISTENDED WITH ERYTHROCYTES.

PANCREAS

AUTOLYSIS :
THE TISSUES EXHIBIT AUTOLYSIS AND THEY ARE NOT INTERPRETABLE.

SPLEEN

PIGMENTATION :
MODERATE
NUMEROUS MACROPHAGES CONTAIN A GRANULAR BROWN CYTOPLASMIC PIGMENT.

KIDNEYS

CALCIFICATION :
MINIMAL
THERE ARE MINERAL DEPOSITS.

CONGESTION :
MINIMAL

KIDNEYS CONTINUED

VESSELS OR SINUSOIDS ARE MARKEDLY DISTENDED WITH ERYTHROCYTES.

INTERSTITIAL NEPHRITIS :
MINIMAL
INFLAMMATORY CELLS FIBROSIS AND SOME TUBULAR ALTERATIONS ARE ASSOCIATED.

BLADDER

AUTOLYSIS :
THE TISSUES EXHIBIT AUTOLYSIS AND THEY ARE NOT INTERPRETABLE.

OVARIES

ATROPHY :
BILATERAL
THE ORGAN IS REDUCED IN SIZE.

CYSTS :
BILATERAL
ONE OR MORE CYSTS FILLED WITH CLEAR LIQUID ARE SEEN.

UTERUS

HEMORRHAGE :
THERE IS EXTRAVASATION OF BLOOD.

*** LEIOMYOSARCOMA :
MALIGNANT TUMOR DERIVED FROM SMOOTH MUSCLE FIBERS.

FEMALE 90 (1646/80)

BRAIN

AUTOLYSIS :
THE TISSUES EXHIBIT AUTOLYSIS AND THEY ARE NOT INTERPRETABLE.

LUNG

AUTOLYSIS :
THE TISSUES EXHIBIT AUTOLYSIS AND THEY ARE NOT INTERPRETABLE.

STOMACH

AUTOLYSIS :
THE TISSUES EXHIBIT AUTOLYSIS AND THEY ARE NOT INTERPRETABLE.

BAYER AG

LIVER

AUTOLYSIS :
THE TISSUES EXHIBIT AUTOLYSIS AND THEY ARE NOT INTERPRETABLE.

PANCREAS

AUTOLYSIS :
THE TISSUES EXHIBIT AUTOLYSIS AND THEY ARE NOT INTERPRETABLE.

SPLEEN

AUTOLYSIS :
THE TISSUES EXHIBIT AUTOLYSIS AND THEY ARE NOT INTERPRETABLE.

KIDNEYS

AUTOLYSIS :
THE TISSUES EXHIBIT AUTOLYSIS AND THEY ARE NOT INTERPRETABLE.

BLADDER

AUTOLYSIS :
THE TISSUES EXHIBIT AUTOLYSIS AND THEY ARE NOT INTERPRETABLE.

PITUITARY

AUTOLYSIS :
THE TISSUES EXHIBIT AUTOLYSIS AND THEY ARE NOT INTERPRETABLE.

THYROIDS

AUTOLYSIS :
THE TISSUES EXHIBIT AUTOLYSIS AND THEY ARE NOT INTERPRETABLE.

ADRENALS

AUTOLYSIS :
THE TISSUES EXHIBIT AUTOLYSIS AND THEY ARE NOT INTERPRETABLE.

SKELETAL MUSCLE

AUTOLYSIS :
THE TISSUES EXHIBIT AUTOLYSIS AND THEY ARE NOT INTERPRETABLE.

SCIATIC NERVE

AUTOLYSIS :
THE TISSUES EXHIBIT AUTOLYSIS AND THEY ARE NOT INTERPRETABLE.

OVARIES

AUTOLYSIS :
THE TISSUES EXHIBIT AUTOLYSIS AND THEY ARE NOT INTERPRETABLE.

FEMUR

AUTOLYSIS :
THE TISSUES EXHIBIT AUTOLYSIS AND THEY ARE NOT INTERPRETABLE.

FEMALE 91 (1660/80)

LUNG

HYPERPLASIA LYMPHOID :
THE LYMPHOID FOLLICLES ARE INCREASED IN SIZE.

*** ALVEOLOGENIC CARCINOMA :
A MALIGNANT TUMOR OF THE LUNG TISSUE WITH SYNONYMS IN MICE FOR ADENOMA, CARCINOMA, ALVEOLOGENIC PAPILLARY CARCINOMA, PAPILLARY CYSTADENOMA, ADENOCARCINOMA, BRONCHIOLAR CELL CARCINOMA, BRONCHIOLAR-ALVEOLAR TUMOR, TYPE A TUMOR, TYPE B TUMOR, INTERMEDIATE TYPE I TUMOR AND COMMON PULMONARY TUMOR OF THE MOUSE.

LIVER

CONGESTION :
VESSELS OR SINUSOIDS ARE MARKEDLY DISTENDED WITH ERYTHROCYTES.

PANCREAS

INFLAMMATION CHRONIC :
FOCAL
THE INTERSTITIAL TISSUES SHOW INFILTRATION BY MONONUCLEAR CELLS AND INCREASE IN FIBROUS STROMA.

SPLEEN

CONGESTION :
VESSELS OR SINUSOIDS ARE MARKEDLY DISTENDED WITH ERYTHROCYTES.

KIDNEYS

INTERSTITIAL NEPHRITIS :
MODERATE MULTIFOCAL
INFLAMMATORY CELLS FIBROSIS AND SOME TUBULAR ALTERATIONS ARE ASSOCIATED.

BAYER AG

BLADDER

LEUKEMIC DEPOSITS :
ORGAN AND THE BLOOD ARE INVADED BY LEUKEMIC CELLS.

PITUITARY

ABSENT :
ORGAN OR TISSUE NOT REMOVED FROM ANIMAL OR NOT FOUND IN FIXATIVE.

MESENTERY

LEUKEMIC DEPOSITS :
ORGAN AND THE BLOOD ARE INVADED BY LEUKEMIC CELLS.

OVARIES

ABSENT :
ORGAN OR TISSUE NOT REMOVED FROM ANIMAL OR NOT FOUND IN FIXATIVE.

UTERUS

CYSTIC ENDOMETRIAL HYPERPLASIA :
BILATERAL
THE ENDOMETRIAL GLANDS ARE INCREASED IN NUMBER AND SOME ARE DILATED OR CYSTIC.

ENDOMETRITIS :
UNILATERAL
ACUTE OR SUBACUTE INFLAMMATION IS SEEN IN ENDOMETRIUM.

LYMPH NODE

*** LYMPHOMA LYMPHOCYTIC :
THE NEOPLASM OF THE RETICULAR SYSTEM ORIGINATES FROM LYMPHOCYTES.

FEMALE 93 (1673/80)

LUNG

*** ALVEOLOGENIC CARCINOMA :
MULTIFOCAL
A MALIGNANT TUMOR OF THE LUNG TISSUE WITH SYNONYMS IN MICE FOR ADENOMA, CARCINOMA, ALVEOLOGENIC PAPILLARY CARCINOMA, PAPILLARY CYSTADENOMA, ADENOCARCINOMA, BRONCHIOLAR CELL CARCINOMA, BRONCHIOLAR-ALVEOLAR TUMOR, TYPE A TUMOR, TYPE B TUMOR, INTERMEDIATE TYPE I TUMOR AND COMMON PULMONARY TUMOR OF THE MOUSE.

LIVER

MONONUCLEAR CELLS :
MODERATE MULTIFOCAL
FOCAL COLLECTIONS OF MONONUCLEAR CELLS ARE PRESENT.

AUTOLYSIS PARTIAL :
NO OTHER CHANGES ARE SEEN. TISSUES ARE ALTERED.
BY POST-MORTEM MODIFICATIONS AND
DIAGNOSIS IS GIVEN WITH RESERVATION.

PANCREAS

AUTOLYSIS PARTIAL :
NO OTHER CHANGES ARE SEEN. TISSUES ARE ALTERED.
BY POST-MORTEM MODIFICATIONS AND
DIAGNOSIS IS GIVEN WITH RESERVATION.

SPLEEN

AMYLOID :
HOMOGENEOUS ACIDOPHILIC MATERIAL IS DEPOSITED.

KIDNEYS

PROGRESSIVE NEPHROPATHY :
SEVERE
AN AGE ASSOCIATED KIDNEY LESION CONSISTING OF CYSTIC TUBULES WITH COLLOID OR HYALINE CASTS CHRONIC INTERSTITIAL NEPHRITIS AND DILATATION OF BOWMAN'S CAPSULE WITH GLOMERULAR DEGENERATION .

BLADDER

UNREADABLE :
IT IS NOT POSSIBLE TO INTERPRET THE SECTION DUE TO AN ARTIFACT CAUSED BY SAMPLING OR HISTOLOGICAL TECHNIQUE.

THYROIDS

CYSTS :
UNILATERAL
ONE OR MORE CYSTS FILLED WITH CLEAR LIQUID ARE SEEN.

ADRENALS

AMYLOID :
HOMOGENEOUS ACIDOPHILIC MATERIAL IS DEPOSITED.

OVARIES

HEMORRHAGE :
UNILATERAL
THERE IS EXTRAVASATION OF BLOOD.

ATROPHY :
CONTRALATERAL
THE ORGAN IS REDUCED IN SIZE.

ARTERITIS :
UNILATERAL
THERE IS A INFLAMMATORY REACTION SURROUNDING ONE OR

BAYER AG BAYER AG BAYER AG

OVARIES CONTINUED
SEVERAL ARTERIES.

FEMALE 94 (1661/80)

LUNG

*** ALVEOLOGENIC CARCINOMA :
A MALIGNANT TUMOR OF THE LUNG TISSUE WITH SYNONYMS IN MICE FOR ADENOMA, CARCINOMA, ALVEOLOGENIC PAPILLARY CARCINOMA, PAPILLARY CYSTADENOMA, ADENOCARCINOMA, BRONCHIOLAR CELL CARCINOMA, BRONCHIOLAR-ALVEOLAR TUMOR, TYPE A TUMOR, TYPE B TUMOR, INTERMEDIATE TYPE I TUMOR AND COMMON PULMONARY TUMOR OF THE MOUSE.

LIVER

LEUKEMIC DEPOSITS :
ORGAN AND THE BLOOD ARE INVADED BY LEUKEMIC CELLS.

SPLEEN

*** LYMPHOMA GRANULOCYTIC :
THE NEUPLASM OF THE RETICULAR SYSTEM ORIGINATES FROM GRANULOCYTES.

KIDNEYS

LEUKEMIC DEPOSITS :
ORGAN AND THE BLOOD ARE INVADED BY LEUKEMIC CELLS.

PITUITARY

ABSENT :
ORGAN OR TISSUE NOT REMOVED FROM ANIMAL OR NOT FOUND IN FIXATIVE.

ADRENALS

LEUKEMIC DEPOSITS :
UNILATERAL
ORGAN AND THE BLOOD ARE INVADED BY LEUKEMIC CELLS.

SKELETAL MUSCLE

LEUKEMIC DEPOSITS :
ORGAN AND THE BLOOD ARE INVADED BY LEUKEMIC CELLS.

OVARIES

LEUKEMIC DEPOSITS :
ORGAN AND THE BLOOD ARE INVADED BY LEUKEMIC CELLS.

UTERUS

LEUKEMIC DEPOSITS :
ORGAN AND THE BLOOD ARE INVADED BY LEUKEMIC CELLS.

*** LEIOMYOSARCOMA :
MALIGNANT TUMOR DERIVED FROM SMOOTH MUSCLE FIBERS.

LYMPH NODE

LYMPHATIC ECTASIA :
A DILATATION OF THE LYMPHATIC VESSELS IS NOTED.

LEUKEMIC DEPOSITS :
ORGAN AND THE BLOOD ARE INVADED BY LEUKEMIC CELLS.

FEMALE 95 (1663/80)

LUNG

NORMAL :
HISTOLOGICAL ASPECT WITHIN NORMAL LIMITS.

STOMACH

NORMAL :
HISTOLOGICAL ASPECT WITHIN NORMAL LIMITS.

LIVER

CONGESTION :
VESSELS OR SINUSOIDS ARE MARKEDLY DISTENDED WITH ERYTHROCYTES.

PANCREAS

AUTOLYSIS PARTIAL :
NO OTHER CHANGES ARE SEEN. TISSUES ARE ALTERED.
BY POST-MORTEM MODIFICATIONS AND
DIAGNOSIS IS GIVEN WITH RESERVATION.

SPLEEN

*** LYMPHOMA STEM CELLS :
THE NEOPLASM OF THE RETICULAR SYSTEM ORIGINATES FROM STEM CELLS.

BAYER AG

KIDNEYS

PROGRESSIVE NEPHROPATHY :
AN AGE ASSOCIATED KIDNEY LESION CONSISTING OF CYSTIC TUBULES WITH COLLOID OR HYALINE CASTS CHRONIC INTERSTITIAL NEPHRITIS AND DILATATION OF BOWMAN'S CAPSULE WITH GLOMERULAR DEGENERATION .

BLADDER

LEUKEMIC DEPOSITS :
ORGAN AND THE BLOOD ARE INVADED BY LEUKEMIC CELLS.

THYROIDS

AUTOLYSIS PARTIAL :
NO OTHER CHANGES ARE SEEN. TISSUES ARE ALTERED. BY POST-MORTEM MODIFICATIONS AND DIAGNOSIS IS GIVEN WITH RESERVATION.

ADRENALS

PIGMENTATION :
SEVERE
NUMEROUS MACROPHAGES CONTAIN A GRANULAR BROWN CYTOPLASMIC PIGMENT.

HYPERPLASTIC NODULE :
UNILATERAL
A NODULE OF HYPERPLASTIC TISSUE IS PRESENT.

MESENTERY

LEUKEMIC DEPOSITS :
ORGAN AND THE BLOOD ARE INVADED BY LEUKEMIC CELLS.

OVARIES

ARTERITIS :
THERE IS A INFLAMMATORY REACTION SURROUNDING ONE OR SEVERAL ARTERIES.

UTERUS

ENDOMETRIOSIS :
CONTRALATERAL
ENDOMETRIAL GLANDS ARE SEEN AT VARIOUS SITES OUTSIDE THE NORMAL ENDOMETRIUM.

LEUKEMIC DEPOSITS :
ORGAN AND THE BLOOD ARE INVADED BY LEUKEMIC CELLS.

ENDOMETRITIS :
UNILATERAL
ACUTE OR SUBACUTE INFLAMMATION IS SEEN IN ENDOMETRIUM.

*** LEIOMYOSARCOMA :
MALIGNANT TUMOR DERIVED FROM SMOOTH MUSCLE FIBERS.

FEMALE 97 (1662/80)

HEART

CONGESTION :
VESSELS OR SINUSOIDS ARE MARKEDLY DISTENDED WITH ERYTHROCYTES.

LUNG

EDEMA :
THE INTERSTITIAL TISSUES CONTAIN AN INCREASED AMOUNT OF FLUID.

CONGESTION :
VESSELS OR SINUSOIDS ARE MARKEDLY DISTENDED WITH ERYTHROCYTES.

LIVER

LEUKEMIC DEPOSITS :
ORGAN AND THE BLOOD ARE INVADED BY LEUKEMIC CELLS.

PANCREAS

AUTOLYSIS :
THE TISSUES EXHIBIT AUTOLYSIS AND THEY ARE NOT INTERPRETABLE.

SPLEEN

*** LYMPHOMA STEM CELLS :
THE NEOPLASM OF THE RETICULAR SYSTEM ORIGINATES FROM STEM CELLS.

AUTOLYSIS PARTIAL :
NO OTHER CHANGES ARE SEEN. TISSUES ARE ALTERED. BY POST-MORTEM MODIFICATIONS AND DIAGNOSIS IS GIVEN WITH RESERVATION.

PITUITARY

ABSENT :
ORGAN OR TISSUE NOT REMOVED FROM ANIMAL OR NOT FOUND IN FIXATIVE.

ADRENALS

LEUKEMIC DEPOSITS :
ORGAN AND THE BLOOD ARE INVADED BY LEUKEMIC CELLS.

BAYER AG

SKELETAL MUSCLE

LEUKEMIC DEPOSITS :
ORGAN AND THE BLOOD ARE INVADED BY LEUKEMIC CELLS.

MESENTERY

LEUKEMIC DEPOSITS :
ORGAN AND THE BLOOD ARE INVADED BY LEUKEMIC CELLS.

OVARIES

LEUKEMIC DEPOSITS :
ORGAN AND THE BLOOD ARE INVADED BY LEUKEMIC CELLS.

UTERUS

LEUKEMIC DEPOSITS :
ORGAN AND THE BLOOD ARE INVADED BY LEUKEMIC CELLS.

LYMPH NODE

*** LYMPHOMA STEM CELLS :
THE NEOPLASM OF THE RETICULAR SYSTEM ORIGINATES FROM STEM CELLS.

FEMALE 98 (1653/80)

BRAIN

ABSENT :
ORGAN OR TISSUE NOT REMOVED FROM ANIMAL OR NOT FOUND IN FIXATIVE.

HEART

THROMBOSIS :
THE VASCULAR LUMEN CONTAINS AN ATTACHED ANTE MORTEM BLOOD CLOT.

LUNG

EDEMA :
SEVERE
THE INTERSTITIAL TISSUES CONTAIN AN INCREASED AMOUNT OF FLUID.

STOMACH

AUTOLYSIS :
THE TISSUES EXHIBIT AUTOLYSIS AND THEY ARE NOT

STOMACH CONTINUED

INTERPRETABLE.

LIVER

AUTOLYSIS :
THE TISSUES EXHIBIT AUTOLYSIS AND THEY ARE NOT INTERPRETABLE.

PANCREAS

AUTOLYSIS :
THE TISSUES EXHIBIT AUTOLYSIS AND THEY ARE NOT INTERPRETABLE.

SPLEEN

AUTOLYSIS :
THE TISSUES EXHIBIT AUTOLYSIS AND THEY ARE NOT INTERPRETABLE.

KIDNEYS

AUTOLYSIS :
THE TISSUES EXHIBIT AUTOLYSIS AND THEY ARE NOT INTERPRETABLE.

BLADDER

AUTOLYSIS :
THE TISSUES EXHIBIT AUTOLYSIS AND THEY ARE NOT INTERPRETABLE.

FEMALE 99 (1650/80)

LUNG

PNEUMONIA :
THE ALVEOLAR WALLS ARE THICKENED AND ALVEOLI CONTAIN INFLAMMATORY CELLS AND FOAMY MACROPHAGES.PERIVASCULAR AND PERIBRONCHIAL LYMPHOCYTIC ACCUMULATIONS MAY BE PRESENT.

LIVER

MONONUCLEAR CELLS :
MINIMAL MULTIFOCAL
FOCAL COLLECTIONS OF MONONUCLEAR CELLS ARE PRESENT.

SPLEEN

HEMATOPOIESIS :
MINIMAL
THE HEMATOPOIESIS IS EVIDENT.

BAYER AG

KIDNEYS

TUBULOPATHY :
BILATERAL
TUBULAR DEGENERATIVE CHANGES ARE PRESENT WHICH MAY BE ASSOCIATED WITH TUBULAR DILATATION.

INTERSTITIAL NEPHRITIS :
BILATERAL MINIMAL MULTIFOCAL
INFLAMMATORY CELLS FIBROSIS AND SOME TUBULAR ALTERATIONS ARE ASSOCIATED.

DILATATION OF GLOMERULAR LOOPS :
BILATERAL MINIMAL MULTIFOCAL
GLOMERULAR LOOPS APPEAR UNUSUALLY ENLARGED AND THIN.

BLADDER

HYPERPLASIA PAPILLOMATOUS :
THE THICKNESS OF THE MUCOSA IS INCREASED MAKING UNUSUALLY HIGH AND NUMEROUS FOLDS.

PITUITARY

ABSENT :
ORGAN OR TISSUE NOT REMOVED FROM ANIMAL OR NOT FOUND IN FIXATIVE.

ADRENALS

PIGMENTATION :
SEVERE
NUMEROUS MACROPHAGES CONTAIN A GRANULAR BROWN CYTOPLASMIC PIGMENT.

HYPERPLASIA OF THE GLOMERULAR LAYER :
UNILATERAL FOCAL
THE GLOMERULAR LAYER IS THICKER THAN NORMAL.

OVARIES

ATROPHY :
CONTRALATERAL
THE ORGAN IS REDUCED IN SIZE.

CYSTS :
UNILATERAL
ONE OR MORE CYSTS FILLED WITH CLEAR LIQUID ARE SEEN.

UTERUS

UNREADABLE :
IT IS NOT POSSIBLE TO INTERPRET THE SECTION DUE TO AN ARTIFACT CAUSED BY SAMPLING OR HISTOLOGICAL TECHNIQUE.

FEMUR

*** OSTEOGENIC SARCOMA :
A MALIGNANT MESENCHYMAL TUMOR WITH ISLANDS OF OSTEOID AND BONE FORMATION IS FOUND.

NFC.47 FEMALE 99 CONTINUED 372

SKULL

*** METASTASIS :
A SECONDARY MALIGNANT TUMOR DEVELOPED AWAY FROM THE INITIAL GROWTH.

BAYER AG BAYER AG BAYER AG BAYER AG

Vertraulich
Eigentum der Firma Bayer AG
Benutzung, Verwertung oder Weitergabe nur mit Einwilligung der Bayer AG gestattet

SF1. 1 CHRONIC TOXICITY STUDY IN MICE: SYSTEMATIC HISTOPATHOLOGY

PRODUCT : KWG 0519 GROUP : 1
ROUTE : DIETARY
TIME : 105 WEEKS DOSE : 125 PPM
THIS GROUP COMPRISED : 16 FEMALES

THE FOLLOWING ORGANS WERE EXAMINED SYSTEMATICALLY :

HEART	LUNG	LIVER
PANCREAS	SPLEEN	KIDNEYS
BLADDER	STOMACH	OVARIES
THYROIDS	ADRENALS	PITUITARY
BRAIN	SKELETAL MUSCLE	SCIATIC NERVE
FEMUR		

THESE ORGANS WERE EXAMINED IN 16 FEMALES

INDIVIDUAL RESULTS

IN THE ANIMALS SHOWN BELOW THE HISTOLOGICAL EXAMINATION OF THE ORGANS LISTED OR OF THE ANOMALIES FOUND AT AUTOPSY GAVE THE FOLLOWING RESULTS :

FEMALE 158 (1506/80)

BRAIN

GLIOSIS :
FOCAL
THERE IS PROLIFERATION OF GLIAL CELLS.

LUNG

*** ALVEOLOGENIC CARCINOMA :
A MALIGNANT TUMOR OF THE LUNG TISSUE WITH SYNONYMS IN MICE FOR ADENOMA, CARCINOMA, ALVEOLOGENIC PAPILLARY CARCINOMA, PAPILLARY CYSTADENOMA, ADENOCARCINOMA, BRONCHIOLAR CELL CARCINOMA, BRONCHIOLAR-ALVEOLAR TUMOR, TYPE A TUMOR, TYPE B TUMOR, INTERMEDIATE TYPE I TUMOR AND COMMON PULMONARY TUMOR OF THE MOUSE.

SPLEEN

HEMATOPOIESIS :
MODERATE
THE HEMATOPOIESIS IS EVIDENT.

OVARIES

ATROPHY :
BILATERAL
THE ORGAN IS REDUCED IN SIZE.

CYSTS :
UNILATERAL

OVARIES CONTINUED
ONE OR MORE CYSTS FILLED WITH CLEAR LIQUID ARE SEEN.

UTERUS

ENDOMETRIOSIS :
ENDOMETRIAL GLANDS ARE SEEN AT VARIOUS SITES OUTSIDE THE NORMAL ENDOMETRIUM.

FEMALE 161 (1507/80)

LUNG

ADENOMATOSIS :
THE PULMONARY ALVEOLI APPEAR GLANDULAR DUE TO METAPLASTIC TRANSFORMATION OF LINING CELLS INTO CUBOIDAL OR COLUMNAR CELLS

PNEUMONIA :
THE ALVEOLAR WALLS ARE THICKENED AND ALVEOLI CONTAIN INFLAMMATORY CELLS AND FOAMY MACROPHAGES.PERIVASCULAR AND PERIBRONCHIAL LYMPHOCYTIC ACCUMULATIONS MAY BE PRESENT.

LIVER

MONONUCLEAR CELLS :
MINIMAL FOCAL
FOCAL COLLECTIONS OF MONONUCLEAR CELLS ARE PRESENT.

SPLEEN

HEMATOPOIESIS :
MINIMAL
THE HEMATOPOIESIS IS EVIDENT.

KIDNEYS

INTERSTITIAL NEPHRITIS :
MINIMAL
INFLAMMATORY CELLS FIBROSIS AND SOME TUBULAR ALTERATIONS ARE ASSOCIATED.

BLADDER

INFLAMMATION CHRONIC :
THERE IS AN INFILTRATION BY MONONUCLEAR CELLS IN THE MUCOSA AND SUBMUCOSA.

OVARIES

ATROPHY :
BILATERAL
THE ORGAN IS REDUCED IN SIZE.

CYSTS :
BILATERAL

BAYER AG

OVARIES CONTINUED
ONE OR MORE CYSTS FILLED WITH CLEAR LIQUID ARE SEEN.

UTERUS

ENDOMETRIOSIS :
ENDOMETRIAL GLANDS ARE SEEN AT VARIOUS SITES OUTSIDE THE NORMAL ENDOMETRIUM.

FEMALE 163 (1508/80)

LUNG

*** ALVEOLOGENIC CARCINOMA :
MULTIFOCAL
A MALIGNANT TUMOR OF THE LUNG TISSUE WITH SYNONYMS IN MICE FOR ADENOMA, CARCINOMA, ALVEOLOGENIC PAPILLARY CARCINOMA, PAPILLARY CYSTADENOMA, ADENOCARCINOMA, BRONCHIOLAR CELL CARCINOMA, BRONCHIOLAR-ALVEOLAR TUMOR, TYPE A TUMOR, TYPE B TUMOR, INTERMEDIATE TYPE I TUMOR AND COMMON PULMONARY TUMOR OF THE MOUSE.

SPLEEN

HEMATOPOIESIS :
MODERATE
THE HEMATOPOIESIS IS EVIDENT.

KIDNEYS

INTERSTITIAL NEPHRITIS :
UNILATERAL MINIMAL
INFLAMMATORY CELLS FIBROSIS AND SOME TUBULAR ALTERATIONS ARE ASSOCIATED.

PITUITARY

ABSENT :
ORGAN OR TISSUE NOT REMOVED FROM ANIMAL OR NOT FOUND IN FIXATIVE.

ADRENALS

HYPERPLASIA OF THE GLOMERULAR LAYER :
UNILATERAL
THE GLOMERULAR LAYER IS THICKER THAN NORMAL.

OVARIES

ATROPHY :
BILATERAL
THE ORGAN IS REDUCED IN SIZE.

CYSTS :
UNILATERAL

OVARIES CONTINUED
ONE OR MORE CYSTS FILLED WITH CLEAR LIQUID ARE SEEN.

UTERUS

UNREADABLE :
IT IS NOT POSSIBLE TO INTERPRET THE SECTION DUE TO AN ARTIFACT CAUSED BY SAMPLING OR HISTOLOGICAL TECHNIQUE.

FEMALE 164 (1509/80)

BRAIN

GLIOSIS :
FOCAL
THERE IS PROLIFERATION OF GLIAL CELLS.

LUNG

ATELECTASIS :
SEVERE
THERE IS COLLAPSE OF ALVEOLI.

EMPHYSEMA :
MINIMAL
THERE IS A EMPHYSEMATOUS CHANGE IN THE ALVEOLAR WALLS.

SPLEEN

HEMATOPOIESIS :
SEVERE
THE HEMATOPOIESIS IS EVIDENT.

BLADDER

HYPERPLASIA PAPILLOMATOUS :
THE THICKNESS OF THE MUCOSA IS INCREASED MAKING UNUSUALLY HIGH AND NUMEROUS FOLDS.

THYROIDS

ABSENT :
ORGAN OR TISSUE NOT REMOVED FROM ANIMAL OR NOT FOUND IN FIXATIVE.

OVARIES

ATROPHY :
BILATERAL
THE ORGAN IS REDUCED IN SIZE.

CYSTS :
UNILATERAL
ONE OR MORE CYSTS FILLED WITH CLEAR LIQUID ARE SEEN.

BAYER AG

UTERUS

ENDOMETRIOSIS :
ENDOMETRIAL GLANDS ARE SEEN AT VARIOUS SITES OUTSIDE THE NORMAL ENDOMETRIUM.

FEMALE 166 (151D/80)

BRAIN

GLIOSIS :
FOCAL
THERE IS PROLIFERATION OF GLIAL CELLS.

LUNG

PNEUMONIA :
THE ALVEOLAR WALLS ARE THICKENED AND ALVEOLI CONTAIN INFLAMMATORY CELLS AND FOAMY MACROPHAGES.PERIVASCULAR AND PERIBRONCHIAL LYMPHOCYTIC ACCUMULATIONS MAY BE PRESENT.

LIVER

MONONUCLEAR CELLS :
MINIMAL MULTIFOCAL
FOCAL COLLECTIONS OF MONONUCLEAR CELLS ARE PRESENT.

VACUOLIZATION :
MINIMAL
IN THESE CELLS THERE ARE CLEAR VACUOLES GREATER IN NUMBER AND SIZE THAN NORMALLY FOUND.

PANCREAS

FATTY CYST :
ACCUMULATION OF FAT CELLS IS PRESENT.

KIDNEYS

TUBULOPATHY :
MINIMAL
TUBULAR DEGENERATIVE CHANGES ARE PRESENT
WHICH MAY BE ASSOCIATED WITH TUBULAR DILATATION.

INTERSTITIAL NEPHRITIS :
MINIMAL
INFLAMMATORY CELLS FIBROSIS AND SOME TUBULAR ALTERATIONS ARE ASSOCIATED.

BLADDER

HYPERPLASIA PAPILLOMATOUS :
THE THICKNESS OF THE MUCOSA IS INCREASED MAKING UNUSUALLY HIGH AND NUMEROUS FOLDS.

ADRENALS

PIGMENTATION :
SEVERE
NUMEROUS MACROPHAGES CONTAIN A GRANULAR BROWN CYTOPLASMIC PIGMENT.

OVARIES

CYSTS :
BILATERAL
ONE OR MORE CYSTS FILLED WITH CLEAR LIQUID ARE SEEN.

UTERUS

HYPERPLASIA POLYPOID:
UNILATERAL
A PEDUNCULATED GROWTH IN THE LUMEN IS PRESENT

HYPERPLASIA SECRETORY :
CONTRALATERAL
THE DEVELOPED GLANDS AND/OR DUCTS CONTAIN A SECRETION

FEMALE 170 (1511/80)

LUNG

PNEUMONIA :
MODERATE
THE ALVEOLAR WALLS ARE THICKENED AND ALVEOLI CONTAIN INFLAMMATORY CELLS AND FOAMY MACROPHAGES.PERIVASCULAR AND PERIBRONCHIAL LYMPHOCYTIC ACCUMULATIONS MAY BE PRESENT.

SPLEEN

HEMATOPOIESIS :
MINIMAL
THE HEMATOPOIESIS IS EVIDENT.

ADRENALS

PIGMENTATION :
MINIMAL
NUMEROUS MACROPHAGES CONTAIN A GRANULAR BROWN CYTOPLASMIC PIGMENT.

OVARIES

HYPERTROPHIC CORPORA LUTEA :
ALL CORPORA LUTEA ARE IMPORTANT IN SIZE. THEY CONTAIN LARGE LUTEAL CELLS WITH ACIDOPHILIC CYTOPLASM.

BAYER AG

UTERUS

CYSTIC ENDOMETRIAL HYPERPLASIA :
CONTRALATERAL
THE ENDOMETRIAL GLANDS ARE INCREASED IN NUMBER AND SOME ARE DILATED OR CYSTIC.

ENDOMETRIOSIS :
CONTRALATERAL
ENDOMETRIAL GLANDS ARE SEEN AT VARIOUS SITES OUTSIDE THE NORMAL ENDOMETRIUM.

HYPERPLASIA PAPILLOMATOUS :
UNILATERAL
THE THICKNESS OF THE MUCOSA IS INCREASED MAKING UNUSUALLY HIGH AND NUMEROUS FOLDS.

FEMALE 171 (1512/80)

LUNG

*** ALVEOLOGENIC CARCINOMA :
MULTIFOCAL
A MALIGNANT TUMOR OF THE LUNG TISSUE WITH SYNONYMS IN MICE FOR ADENOMA, CARCINOMA, ALVEOLOGENIC PAPILLARY CARCINOMA, PAPILLARY CYSTADENOMA, ADENOCARCINOMA, BRONCHIOLAR CELL CARCINOMA, BRONCHIOLAR-ALVEOLAR TUMOR, TYPE A TUMOR, TYPE B TUMOR, INTERMEDIATE TYPE I TUMOR AND COMMON PULMONARY TUMOR OF THE MOUSE.

LIVER

LEUKEMIC DEPOSITS :
ORGAN AND THE BLOOD ARE INVADED BY LEUKEMIC CELLS.

SPLEEN

*** LYMPHOMA LYMPHOCYTIC :
THE NEOPLASM OF THE RETICULAR SYSTEM ORIGINATES FROM LYMPHOCYTES.

KIDNEYS

INTERSTITIAL NEPHRITIS :
MULTIFOCAL
INFLAMMATORY CELLS FIBROSIS AND SOME TUBULAR ALTERATIONS ARE ASSOCIATED.

BLADDER

INFLAMMATION CHRONIC :
MINIMAL

BLADDER CONTINUED
THERE IS AN INFILTRATION BY MONONUCLEAR CELLS IN THE MUCOSA AND SUBMUCOSA.

THYROIDS

ABSENT :
ORGAN OR TISSUE NOT REMOVED FROM ANIMAL OR NOT FOUND IN FIXATIVE.

ADRENALS

PIGMENTATION :
MODERATE
NUMEROUS MACROPHAGES CONTAIN A GRANULAR BROWN CYTOPLASMIC PIGMENT.

BONE

*** OSTEOMA :
THIS BENIGN WELL CIRCUMSCRIBED TUMOR IS COMPOSED OF WELL-DEVELOPED BONE.

OVARIES

HYPERTROPHIC CORPORA LUTEA :
ALL CORPORA LUTEA ARE IMPORTANTLY IN SIZE. THEY CONTAIN LARGE LUTEAL CELLS WITH ACIDOPHILIC CYTOPLASM.

UTERUS

HYPERPLASIA SECRETORY
UNILATERAL
THE DEVELOPED GLANDS AND/OR DUCTS CONTAIN A SECRETION

FEMALE 177 (1513/80)

LUNG

*** ALVEOLOGENIC CARCINOMA :
MULTIFOCAL
A MALIGNANT TUMOR OF THE LUNG TISSUE WITH SYNONYMS IN MICE FOR ADENOMA, CARCINOMA, ALVEOLOGENIC PAPILLARY CARCINOMA, PAPILLARY CYSTADENOMA, ADENOCARCINOMA, BRONCHIOLAR CELL CARCINOMA, BRONCHIOLAR-ALVEOLAR TUMOR, TYPE A TUMOR, TYPE B TUMOR, INTERMEDIATE TYPE I TUMOR AND COMMON PULMONARY TUMOR OF THE MOUSE.

SPLEEN

HEMATOPOIESIS :
MINIMAL

BAYER AG

SPLEEN CONTINUED
THE HEMATOPOIESIS IS EVIDENT.

KIDNEYS

INTERSTITIAL NEPHRITIS :
MINIMAL MULTIFOCAL
INFLAMMATORY CELLS FIBROSIS AND SOME TUBULAR ALTERATIONS ARE ASSOCIATED.

THYROIDS

ABSENT :
ORGAN OR TISSUE NOT REMOVED FROM ANIMAL OR NOT FOUND IN FIXATIVE.

ADRENALS

PIGMENTATION :
SEVERE
NUMEROUS MACROPHAGES CONTAIN A GRANULAR BROWN CYTOPLASMIC PIGMENT.

OVARIES

CYSTS :
ONE OR MORE CYSTS FILLED WITH CLEAR LIQUID ARE SEEN.

UTERUS

HEMORRHAGE :
UNILATERAL
THERE IS EXTRAVASATION OF BLOOD.

AMYLOID :
UNILATERAL
HOMOGENEOUS ACIDOPHILIC MATERIAL IS DEPOSITED.

HYPERPLASIA SECRETORY :
BILATERAL
THE DEVELOPED GLANDS AND/OR DUCTS CONTAIN A SECRETION

FEMALE 178 (1514/80)

LUNG

ATELECTASIS :
FOCAL
THERE IS COLLAPSE OF ALVEOLI.

SPLEEN

HEMATOPOIESIS :
MODERATE

SPLEEN CONTINUED
THE HEMATOPOIESIS IS EVIDENT.

KIDNEYS

INTERSTITIAL NEPHRITIS :
MINIMAL FOCAL
INFLAMMATORY CELLS FIBROSIS AND SOME TUBULAR ALTERATIONS ARE ASSOCIATED.

OVARIES

ATROPHY :
THE ORGAN IS REDUCED IN SIZE.

UTERUS

HYPERPLASIA SECRETORY :
BILATERAL
THE DEVELOPED GLANDS AND/OR DUCTS CONTAIN A SECRETION

FEMALE 179 (1515/80)

LUNG

ATELECTASIS :
THERE IS COLLAPSE OF ALVEOLI.

LIVER

MONONUCLEAR CELLS :
MINIMAL MULTIFOCAL
FOCAL COLLECTIONS OF MONONUCLEAR CELLS ARE PRESENT.

SPLEEN

HEMATOPOIESIS :
MODERATE
THE HEMATOPOIESIS IS EVIDENT.

KIDNEYS

PYELONEPHRITIS :
MINIMAL
INFLAMMATION OF RENAL PARENCHYMA WITH OR WITHOUT NECROSIS EXTENDED TO RENAL PELVIS.

BLADDER

INFLAMMATION CHRONIC :
MINIMAL
THERE IS AN INFILTRATION BY MONONUCLEAR CELLS IN THE MUCOSA AND SUBMUCOSA.

HYPERPLASIA PAPILLOMATOUS :

BAYER AG

FEMALE 179 CONTINUED 383

BLADDER CONTINUED
THE THICKNESS OF THE MUCOSA IS INCREASED MAKING UNUSUALLY HIGH AND NUMEROUS FOLDS.

THYROIDS

ABSENT :
ORGAN OR TISSUE NOT REMOVED FROM ANIMAL OR NOT FOUND IN FIXATIVE.

ADRENALS

*** ADENOMA :
UNILATERAL
THIS IS BENIGN GLANDULAR EPITHELIAL TUMOR.

OVARIES

*** LUTEOMA :
UNILATERAL
IT IS A BENIGN TUMOR COMPOSED OF CELLS RESEMBLING THOSE OF THE CORPUS LUTEUM.

CYSTS :
BILATERAL
ONE OR MORE CYSTS FILLED WITH CLEAR LIQUID ARE SEEN.

UTERUS

ENDOMETRIOSIS :
ENDOMETRIAL GLANDS ARE SEEN AT VARIOUS SITES OUTSIDE THE NORMAL ENDOMETRIUM.

FEMALE 181 (1517/80)

LUNG

OSSEOUS METAPLASIA :
MULTIFOCAL
A FOCAL AREA OF ECTOPIC OSTEOID OR BONE IS PRESENT.

STOMACH

INFLAMMATION CHRONIC :
SEVERE MULTIFOCAL
THERE IS AN INFILTRATION BY MONONUCLEAR CELLS IN THE MUCOSA AND SUBMUCOSA.

MUCOID CYST :
SEVERE MULTIFOCAL
ONE OR MORE CYSTS CONTAINING MUCOID MATERIAL ARE OBSERVED.

PANCREAS

ATROPHY :
SEVERE

PANCREAS CONTINUED

THE ORGAN IS REDUCED IN SIZE.

CYSTS :
ONE OR MORE CYSTS FILLED WITH CLEAR LIQUID ARE SEEN.

KIDNEYS

PYELONEPHRITIS :
BILATERAL MODERATE MULTIFOCAL
INFLAMMATION OF RENAL PARENCHYMA WITH OR WITHOUT NECROSIS EXTENDED TO RENAL PELVIS.

THYROIDS

ABSENT :
ORGAN OR TISSUE NOT REMOVED FROM ANIMAL OR NOT FOUND IN FIXATIVE.

ADRENALS

PIGMENTATION :
SEVERE
NUMEROUS MACROPHAGES CONTAIN A GRANULAR BROWN CYTOPLASMIC PIGMENT.

OVARIES

CYSTS :
BILATERAL
ONE OR MORE CYSTS FILLED WITH CLEAR LIQUID ARE SEEN.

UTERUS

HYPERPLASIA SECRETORY :
THE DEVELOPED GLANDS AND/OR DUCTS CONTAIN A SECRETION

BAYER AG

FEMALE 186 (1516/80)

LUNG

PNEUMONIA :
THE ALVEOLAR WALLS ARE THICKENED AND ALVEOLI CONTAIN INFLAMMATORY CELLS AND FOAMY MACROPHAGES.PERIVASCULAR AND PERIBRONCHIAL LYMPHOCYTIC ACCUMULATIONS MAY BE PRESENT.

LEUKEMIC DEPOSITS :
ORGAN AND THE BLOOD ARE INVADED BY LEUKEMIC CELLS.

STOMACH

MUCOID CYST :
ONE OR MORE CYSTS CONTAINING MUCOID MATERIAL ARE OBSERVED.

LIVER

MONONUCLEAR CELLS :
MINIMAL MULTIFOCAL
FOCAL COLLECTIONS OF MONONUCLEAR CELLS ARE PRESENT.

PANCREAS

LEUKEMIC DEPOSITS :
ORGAN AND THE BLOOD ARE INVADED BY LEUKEMIC CELLS.

SPLEEN

HYPERPLASIA LYMPHOID :
THE LYMPHOID FOLLICLES ARE INCREASED IN SIZE.

KIDNEYS

LEUKEMIC DEPOSITS :
ORGAN AND THE BLOOD ARE INVADED BY LEUKEMIC CELLS.

BLADDER

LEUKEMIC DEPOSITS :
ORGAN AND THE BLOOD ARE INVADED BY LEUKEMIC CELLS.

THYROIDS

CYSTS :
ONE OR MORE CYSTS FILLED WITH CLEAR LIQUID ARE SEEN.

ADRENALS

CYSTS :
CONTRALATERAL
ONE OR MORE CYSTS FILLED WITH CLEAR LIQUID ARE SEEN.

NORMAL :
UNILATERAL
HISTOLOGICAL ASPECT WITHIN NORMAL LIMITS.

MESENTERY

LEUKEMIC DEPOSITS :
ORGAN AND THE BLOOD ARE INVADED BY LEUKEMIC CELLS.

OVARIES

HYPERTROPHIC CORPORA LUTEA :
ALL CORPORA LUTEA ARE IMPORTANT IN SIZE. THEY CONTAIN LARGE LUTEAL CELLS WITH ACIDOPHILIC CYTOPLASM.

UTERUS

CYSTIC ENDOMETRIAL HYPERPLASIA :
BILATERAL
THE ENDOMETRIAL GLANDS ARE INCREASED IN NUMBER AND SOME ARE DILATED OR CYSTIC.

LYMPH NODE

*** LYMPHOMA LYMPHOCYTIC :
THE NEOPLASM OF THE RETICULAR SYSTEM ORIGINATES FROM LYMPHOCYTES.

FEMALE 194 (1518/80)

LUNG

PNEUMONIA :
SEVERE
THE ALVEOLAR WALLS ARE THICKENED AND ALVEOLI CONTAIN INFLAMMATORY CELLS AND FOAMY MACROPHAGES. PERIVASCULAR AND PERIBRONCHIAL LYMPHOCYTIC ACCUMULATIONS MAY BE PRESENT.

KIDNEYS

INTERSTITIAL NEPHRITIS :
BILATERAL MINIMAL MULTIFOCAL
INFLAMMATORY CELLS FIBROSIS AND SOME TUBULAR ALTERATIONS ARE ASSOCIATED.

BLADDER

HYPERPLASIA PAPILLOMATOUS :
THE THICKNESS OF THE MUCOSA IS INCREASED MAKING UNUSUALLY HIGH AND NUMEROUS FOLDS.

ADRENALS

PIGMENTATION :
UNILATERAL MODERATE
NUMEROUS MACROPHAGES CONTAIN A GRANULAR BROWN CYTOPLASMIC PIGMENT.

ABSENT :
CONTRALATERAL
ORGAN OR TISSUE NOT REMOVED FROM ANIMAL OR NOT FOUND IN FIXATIVE.

OVARIES

ATROPHY :
BILATERAL
THE ORGAN IS REDUCED IN SIZE.

CYSTS :
BILATERAL
ONE OR MORE CYSTS FILLED WITH CLEAR LIQUID ARE SEEN.

UTERUS

HYPERPLASIA SECRETORY :
UNILATERAL

BAYER AG

UTERUS CONTINUED
THE DEVELOPED GLANDS AND/OR DUCTS CONTAIN A SECRETION

HEMORRAGIC CYST :
CONTRALATERAL
ONE OR SEVERAL CAVITIES FILLED WITH BLOOD.

FEMALE 196 (1519/80)

HEART

NORMAL :
HISTOLOGICAL ASPECT WITHIN NORMAL LIMITS.

LUNG

*** ALVEOLOGENIC CARCINOMA :
A MALIGNANT TUMOR OF THE LUNG TISSUE WITH SYNONYMS IN MICE FOR ADENOMA, CARCINOMA, ALVEOLOGENIC PAPILLARY CARCINOMA, PAPILLARY CYSTADENOMA, ADENOCARCINOMA, BRONCHIOLAR CELL CARCINOMA, BRONCHIOLAR-ALVEOLAR TUMOR, TYPE A TUMOR, TYPE B TUMOR, INTERMEDIATE TYPE I TUMOR AND COMMON PULMONARY TUMOR OF THE MOUSE.

STOMACH

HYPERKERATOSIS :
THE STRATIFIED SQUAMOUS EPITHELIUM EXHIBITS THICKENING AND EXCESS CORNIFICATION.

LIVER

HYPERTROPHY :
THE SIZE OF THE ORGAN IS INCREASED WITHOUT STRUCTURAL ANOMALY.

SPLEEN

HEMATOPOIESIS :
MODERATE
THE HEMATOPOIESIS IS EVIDENT.

KIDNEYS

INTERSTITIAL NEPHRITIS :
BILATERAL MODERATE MULTIFOCAL
INFLAMMATORY CELLS FIBROSIS AND SOME TUBULAR ALTERATIONS ARE ASSOCIATED.

PITUITARY

ABSENT :

PITUITARY CONTINUED

ORGAN OR TISSUE NOT REMOVED FROM ANIMAL OR NOT FOUND IN FIXATIVE.

SKELETAL MUSCLE

*** METASTASIS :
A SECONDARY MALIGNANT TUMOR DEVELOPED AWAY FROM THE INITIAL GROWTH.

OVARIES

CYSTS :
BILATERAL
ONE OR MORE CYSTS FILLED WITH CLEAR LIQUID ARE SEEN.

UTERUS

CYSTIC ENDOMETRIAL HYPERPLASIA :
UNILATERAL
THE ENDOMETRIAL GLANDS ARE INCREASED IN NUMBER AND SOME ARE DILATED OR CYSTIC.

ENDOMETRIOSIS :
UNILATERAL
ENDOMETRIAL GLANDS ARE SEEN AT VARIOUS SITES OUTSIDE THE NORMAL ENDOMETRIUM.

SUBCUTANEOUS TISSUE

NECROSIS :
MULTIFOCAL
THE TISSUE HAS LOST ITS NORMAL STRUCTURE DUE TO CELL DEATH WHICH MAY BE OF VARIOUS ORIGIN.

*** FIBROSARCOMA :
IN THIS MALIGNANT MESENCHIMAL TUMOR THE NEOPLASTIC CELLS SHOW MITOSES AND SLIGHT PLEOMORPHISM. FORMATION OF COLLAGEN IS NOTED.

FEMALE 197 (152/80)

LUNG

PNEUMONIA :
MODERATE
THE ALVEOLAR WALLS ARE THICKENED AND ALVEOLI CONTAIN INFLAMMATORY CELLS AND FOAMY MACROPHAGES. PERIVASCULAR AND PERIBRONCHIAL LYMPHOCYTIC ACCUMULATIONS MAY BE PRESENT.

ATELECTASIS :
SEVERE
THERE IS COLLAPSE OF ALVEOLI.

BAYER AG

LIVER

CONGESTION :
VESSELS OR SINUSOIDS ARE MARKEDLY DISTENDED WITH ERYTHROCYTES.

VACUOLIZATION :
IN THESE CELLS THERE ARE CLEAR VACUOLES GREATER IN NUMBER AND SIZE THAN NORMALLY FOUND.

PANCREAS

MONONUCLEAR CELLS :
FOCAL
FOCAL COLLECTIONS OF MONONUCLEAR CELLS ARE PRESENT.

SPLEEN

HEMATOPOIESIS :
MINIMAL
THE HEMATOPOIESIS IS EVIDENT.

KIDNEYS

PYELONEPHRITIS :
BILATERAL MINIMAL
INFLAMMATION OF RENAL PARENCHYMA WITH OR WITHOUT NECROSIS EXTENDED TO RENAL PELVIS.

OVARIES

*** LUTEOMA :
UNILATERAL MULTIFOCAL
IT IS A BENIGN TUMOR COMPOSED OF CELLS RESEMBLING THOSE OF THE CORPUS LUTEUM.

UTERUS

ENDOMETRIOSIS :
BILATERAL
ENDOMETRIAL GLANDS ARE SEEN AT VARIOUS SITES OUTSIDE THE NORMAL ENDOMETRIUM.

HYPERPLASIA SECRETORY :
BILATERAL
THE DEVELOPED GLANDS AND/OR DUCTS CONTAIN A SECRETION

FEMALE 198 (1521/60)

LUNG

*** ALVEOLOGENIC CARCINOMA :
A MALIGNANT TUMOR OF THE LUNG TISSUE WITH SYNONYMS IN MICE FOR ADENOMA, CARCINOMA,

LUNG CONTINUED

ALVEOLOGENIC PAPILLARY CARCINOMA, PAPILLARY CYSTADENOMA, ADENOCARCINOMA, BRONCHIOLAR CELL CARCINOMA, BRONCHIOLAR-ALVEOLAR TUMOR, TYPE A TUMOR, TYPE B TUMOR, INTERMEDIATE TYPE I TUMOR AND COMMON PULMONARY TUMOR OF THE MOUSE.

STOMACH

LEUKEMIC DEPOSITS :
ORGAN AND THE BLOOD ARE INVADED BY LEUKEMIC CELLS.

LIVER

LEUKEMIC DEPOSITS :
ORGAN AND THE BLOOD ARE INVADED BY LEUKEMIC CELLS.

SPLEEN

*** LYMPHOMA LYMPHOCYTIC :
THE NEOPLASM OF THE RETICULAR SYSTEM ORIGINATES FROM LYMPHOCYTES.

BLADDER

LEUKEMIC DEPOSITS :
ORGAN AND THE BLOOD ARE INVADED BY LEUKEMIC CELLS.

THYROIDS

CYSTS :
UNILATERAL
ONE OR MORE CYSTS FILLED WITH CLEAR LIQUID ARE SEEN.

ADRENALS

PIGMENTATION :
MINIMAL
NUMEROUS MACROPHAGES CONTAIN A GRANULAR BROWN CYTOPLASMIC PIGMENT.

MESENTERY

LEUKEMIC DEPOSITS :
ORGAN AND THE BLOOD ARE INVADED BY LEUKEMIC CELLS.

UTERUS

CYSTIC ENDOMETRIAL HYPERPLASIA :
UNILATERAL SEVERE
THE ENDOMETRIAL GLANDS ARE INCREASED IN NUMBER AND SOME ARE DILATED OR CYSTIC.

ENDOMETRITIS :
UNILATERAL SEVERE
ACUTE OR SUBACUTE INFLAMMATION IS SEEN IN ENDOMETRIUM.

BAYER AG

NF1. 1 CHRONIC TOXICITY STUDY IN MICE: NONSYSTEMATIC

HISTOPATHOLOGY

PRODUCT : KWG 0519

GROUP : 1
ROUTE : DIETARY
DOSE : 125 PPM

TIME : 105 WEEKS
THIS GROUP COMPRISED : 33 FEMALES

THE FOLLOWING ORGANS WERE EXAMINED SYSTEMATICALLY :

HEART	LUNG	LIVER
PANCREAS	SPLEEN	KIDNEYS
BLADDER	STOMACH	OVARIES
THYROIDS	ADRENALS	PITUITARY
BRAIN	SKELETAL MUSCLE	SCIATIC NERVE
FEMUR		

THESE ORGANS WERE EXAMINED IN 33 FEMALES

INDIVIDUAL RESULTS

IN THE ANIMALS SHOWN BELOW THE HISTOLOGICAL EXAMINATION OF THE ORGANS LISTED OR OF THE ANOMALIES FOUND AT AUTOPSY GAVE THE FOLLOWING RESULTS :

FEMALE 151 (1721/80)

LUNG

*** ALVEOLOGENIC CARCINOMA :
A MALIGNANT TUMOR OF THE LUNG TISSUE WITH SYNONYMS IN MICE FOR ADENOMA, CARCINOMA, ALVEOLOGENIC PAPILLARY CARCINOMA, PAPILLARY CYSTADENOMA, ADENOCARCINOMA, BRONCHIOLAR CELL CARCINOMA, BRONCHIOLAR-ALVEOLAR TUMOR, TYPE A TUMOR, TYPE B TUMOR, INTERMEDIATE TYPE I TUMOR AND COMMON PULMONARY TUMOR OF THE MOUSE.

LIVER

HEMORRHAGE :
THERE IS EXTRAVASATION OF BLOOD.

CONGESTION :
VESSELS OR SINUSOIDS ARE MARKEDLY DISTENDED WITH ERYTHROCYTES.

AUTOLYSIS PARTIAL :
NO OTHER CHANGES ARE SEEN. TISSUES ARE ALTERED BY POST-MORTEM MODIFICATIONS AND DIAGNOSIS IS GIVEN WITH RESERVATION.

SPLEEN

CONGESTION :

SPLEEN CONTINUED
VESSELS OR SINUSOIDS ARE MARKEDLY DISTENDED WITH ERYTHROCYTES.

BLADDER

AUTOLYSIS PARTIAL :
NO OTHER CHANGES ARE SEEN. TISSUES ARE ALTERED. BY POST-MORTEM MODIFICATIONS AND DIAGNOSIS IS GIVEN WITH RESERVATION.

ADRENALS

PIGMENTATION :
MODERATE
NUMEROUS MACROPHAGES CONTAIN A GRANULAR BROWN CYTOPLASMIC PIGMENT.

OVARIES

HYPERTROPHIC CORPORA LUTEA :
ALL CORPORA LUTEA ARE IMPORTANT IN SIZE. THEY CONTAIN LARGE LUTEAL CELLS WITH ACIDOPHILIC CYTOPLASM.

UTERUS

CYSTIC ENDOMETRIAL HYPERPLASIA
THE ENDOMETRIAL GLANDS ARE INCREASED IN NUMBER AND SOME ARE DILATED OR CYSTIC.

FEMALE 152 (1708/80)

HEART

CONGESTION :
VESSELS OR SINUSOIDS ARE MARKEDLY DISTENDED WITH ERYTHROCYTES.

LUNG

PNEUMONIA :
SEVERE
THE ALVEOLAR WALLS ARE THICKENED AND ALVEOLI CONTAIN INFLAMMATORY CELLS AND FOAMY MACROPHAGES. PERIVASCULAR AND PERIBRONCHIAL LYMPHOCYTIC ACCUMULATIONS MAY BE PRESENT.

LEUKEMIC DEPOSITS :
ORGAN AND THE BLOOD ARE INVADED BY LEUKEMIC CELLS.

STOMACH

LEUKEMIC DEPOSITS :
ORGAN AND THE BLOOD ARE INVADED BY LEUKEMIC CELLS.

BAYER AG

PANCREAS

LEUKEMIC DEPOSITS :
ORGAN AND THE BLOOD ARE INVADED BY LEUKEMIC CELLS.

AUTOLYSIS PARTIAL :
NO OTHER CHANGES ARE SEEN. TISSUES ARE ALTERED. BY POST-MORTEM MODIFICATIONS AND DIAGNOSIS IS GIVEN WITH RESERVATION.

SPLEEN

HYPERPLASIA LYMPHOID :
THE LYMPHOID FOLLICLES ARE INCREASED IN SIZE.

BLADDER

LEUKEMIC DEPOSITS :
ORGAN AND THE BLOOD ARE INVADED BY LEUKEMIC CELLS.

THYROIDS

AUTOLYSIS PARTIAL :
NO OTHER CHANGES ARE SEEN. TISSUES ARE ALTERED. BY POST-MORTEM MODIFICATIONS AND DIAGNOSIS IS GIVEN WITH RESERVATION.

ADRENALS

LEUKEMIC DEPOSITS :
UNILATERAL
ORGAN AND THE BLOOD ARE INVADED BY LEUKEMIC CELLS.

SKELETAL MUSCLE

ABSENT :
ORGAN OR TISSUE NOT REMOVED FROM ANIMAL OR NOT FOUND IN FIXATIVE.

SCIATIC NERVE

ABSENT :
ORGAN OR TISSUE NOT REMOVED FROM ANIMAL OR NOT FOUND IN FIXATIVE.

MESENTERY

LEUKEMIC DEPOSITS :
ORGAN AND THE BLOOD ARE INVADED BY LEUKEMIC CELLS.

OVARIES

LEUKEMIC DEPOSITS :
ORGAN AND THE BLOOD ARE INVADED BY LEUKEMIC CELLS.

FAT

LEUKEMIC DEPOSITS :
ORGAN AND THE BLOOD ARE INVADED BY LEUKEMIC CELLS.

FEMUR

ABSENT :
ORGAN OR TISSUE NOT REMOVED FROM ANIMAL OR NOT FOUND IN FIXATIVE.

LYMPH NODE

*** LYMPHOMA LYMPHOCYTIC :
THE NEOPLASM OF THE RETICULAR SYSTEM ORIGINATES FROM LYMPHOCYTES.

FEMALE 153 (1684/80)

BRAIN

CONGESTION :
VESSELS OR SINUSOIDS ARE MARKEDLY DISTENDED WITH ERYTHROCYTES.

HEART

CONGESTION :
VESSELS OR SINUSOIDS ARE MARKEDLY DISTENDED WITH ERYTHROCYTES.

LUNG

CONGESTION :
VESSELS OR SINUSOIDS ARE MARKEDLY DISTENDED WITH ERYTHROCYTES.

STOMACH

HEMORRHAGE :
MULTIFOCAL
THERE IS EXTRAVASATION OF BLOOD.

LIVER

AUTOLYSIS PARTIAL :
NO OTHER CHANGES ARE SEEN. TISSUES ARE ALTERED. BY POST-MORTEM MODIFICATIONS AND DIAGNOSIS IS GIVEN WITH RESERVATION.

PANCREAS

AUTOLYSIS PARTIAL :
NO OTHER CHANGES ARE SEEN. TISSUES ARE ALTERED.

BAYER AG

PANCREAS CONTINUED
BY POST-MORTEM MODIFICATIONS AND
DIAGNOSIS IS GIVEN WITH RESERVATION.

KIDNEYS

CYSTS :
UNILATERAL FOCAL
ONE OR MORE CYSTS FILLED WITH CLEAR LIQUID ARE SEEN.

THYROIDS

ABSENT :
ORGAN OR TISSUE NOT REMOVED FROM ANIMAL OR NOT FOUND IN
FIXATIVE.

OVARIES

HYPERTROPHIC CORPORA LUTEA :
ALL CORPORA LUTEA ARE IMPORTANT IN SIZE. THEY CONTAIN LARGE
LUTEAL CELLS WITH ACIDOPHILIC CYTOPLASM.

INTESTINE

AUTOLYSIS :
THE TISSUES EXHIBIT AUTOLYSIS AND THEY ARE NOT
INTERPRETABLE.

FEMALE 154 (1691/80)

SPLEEN

HEMATOPOIESIS :
MODERATE
THE HEMATOPOIESIS IS EVIDENT.

KIDNEYS

PROGRESSIVE NEPHROPATHY :
BILATERAL MODERATE
AN AGE ASSOCIATED KIDNEY LESION CONSISTING OF CYSTIC TUBULES
WITH COLLOID OR HYALINE CASTS CHRONIC INTERSTITIAL NEPHRITIS
AND DILATATION OF BOWMAN'S CAPSULE WITH GLOMERULAR
DEGENERATION .

BLADDER

INFLAMMATION CHRONIC :
MINIMAL
THERE IS AN INFILTRATION BY MONONUCLEAR CELLS IN THE MUCOSA
AND SUBMUCOSA.

SCIATIC NERVE

ABSENT :

SCIATIC NERVE CONTINUED
ORGAN OR TISSUE NOT REMOVED FROM ANIMAL OR NOT FOUND IN FIXATIVE.

OVARIES

ATROPHY :
UNILATERAL
THE ORGAN IS REDUCED IN SIZE.

CYSTS :
UNILATERAL
ONE OR MORE CYSTS FILLED WITH CLEAR LIQUID ARE SEEN.

CYSTS :
CONTRALATERAL
ONE OR MORE CYSTS FILLED WITH CLEAR LIQUID ARE SEEN.

HYPERTROPHIC CORPORA LUTEA :
CONTRALATERAL
ALL CORPORA LUTEA ARE IMPORTANT IN SIZE. THEY CONTAIN LARGE LUTEAL CELLS WITH ACIDOPHILIC CYTOPLASM.

UTERUS

HYPERPLASIA SECRETORY :
THE DEVELOPED GLANDS AND/OR DUCTS CONTAIN A SECRETION

FEMALE 155 (1683/80

STOMACH

HEMORRHAGE :
THERE IS EXTRAVASATION OF BLOOD.

LIVER

CONGESTION :
VESSELS OR SINUSOIDS ARE MARKEDLY DISTENDED WITH ERYTHROCYTES.

KIDNEYS

CONGESTION :
VESSELS OR SINUSOIDS ARE MARKEDLY DISTENDED WITH ERYTHROCYTES.

BLADDER

INFLAMMATION CHRONIC :
THERE IS AN INFILTRATION BY MUNONUCLEAR CELLS IN THE MUCOSA AND SUBMUCOSA.

BAYER AG

NF1. 7 FEMALE 155 CONTINUED

ADRENALS

*** ADENOMA :
BILATERAL
THIS IS BENIGN GLANDULAR EPITHELIAL TUMOR.

OVARIES

HYPERTROPHIC CORPORA LUTEA :
BILATERAL
ALL CORPORA LUTEA ARE IMPORTANT IN SIZE. THEY CONTAIN LARGE LUTEAL CELLS WITH ACIDOPHILIC CYTOPLASM.

UTERUS

NORMAL :
HISTOLOGICAL ASPECT WITHIN NORMAL LIMITS.

FEMALE 156 (1687/60)

HEART

CONGESTION :
VESSELS OR SINUSOIDS ARE MARKEDLY DISTENDED WITH ERYTHROCYTES.

LUNG

EDEMA :
THE INTERSTITIAL TISSUES CONTAIN AN INCREASED AMOUNT OF FLUID.

LIVER

AUTOLYSIS PARTIAL :
NO OTHER CHANGES ARE SEEN. TISSUES ARE ALTERED. BY POST-MORTEM MODIFICATIONS AND DIAGNOSIS IS GIVEN WITH RESERVATION.

PANCREAS

AUTOLYSIS PARTIAL :
NO OTHER CHANGES ARE SEEN. TISSUES ARE ALTERED. BY POST-MORTEM MODIFICATIONS AND DIAGNOSIS IS GIVEN WITH RESERVATION.

SPLEEN

HYPERPLASIA LYMPHOID :
THE LYMPHOID FOLLICLES ARE INCREASED IN SIZE.

KIDNEYS

INTERSTITIAL NEPHRITIS :
BILATERAL MINIMAL MULTIFOCAL

KIDNEYS CONTINUED

INFLAMMATORY CELLS FIBROSIS AND SOME TUBULAR ALTERATIONS ARE ASSOCIATED.

AUTOLYSIS PARTIAL :
BILATERAL MINIMAL MULTIFOCAL
NO OTHER CHANGES ARE SEEN. TISSUES ARE ALTERED. BY POST-MORTEM MODIFICATIONS AND DIAGNOSIS IS GIVEN WITH RESERVATION.

BLADDER

AUTOLYSIS PARTIAL :
NO OTHER CHANGES ARE SEEN. TISSUES ARE ALTERED. BY POST-MORTEM MODIFICATIONS AND DIAGNOSIS IS GIVEN WITH RESERVATION.

PITUITARY

ABSENT :
ORGAN OR TISSUE NOT REMOVED FROM ANIMAL OR NOT FOUND IN FIXATIVE.

THYROIDS

ABSENT :
ORGAN OR TISSUE NOT REMOVED FROM ANIMAL OR NOT FOUND IN FIXATIVE.

OVARIES

HYPERTROPHIC CORPORA LUTEA :
ALL CORPORA LUTEA ARE IMPORTANT IN SIZE. THEY CONTAIN LARGE LUTEAL CELLS WITH ACIDOPHILIC CYTOPLASM.

FEMALE 157 (1746/80)

LUNG

ALVEOLOGENIC CARCINOMA :
A MALIGNANT TUMOR OF THE LUNG TISSUE WITH SYNONYMS IN MICE FOR ADENOMA, CARCINOMA, ALVEOLOGENIC PAPILLARY CARCINOMA, PAPILLARY CYSTADENOMA, ADENOCARCINOMA, BRONCHIOLAR CELL CARCINOMA, BRONCHIOLAR-ALVEOLAR TUMOR, TYPE A TUMOR, TYPE B TUMOR, INTERMEDIATE TYPE I TUMOR AND COMMON PULMONARY TUMOR OF THE MOUSE.

LIVER

MONONUCLEAR CELLS :
MINIMAL MULTIFOCAL
FOCAL COLLECTIONS OF MONONUCLEAR CELLS ARE PRESENT.

VACUOLIZATION :
MINIMAL

BAYER AG

LIVER CONTINUED
IN THESE CELLS THERE ARE CLEAR VACUOLES GREATER IN NUMBER AND SIZE THAN NORMALLY FOUND.

FEMALE 159 (1090/00)

BRAIN

ABSENT :
ORGAN OR TISSUE NOT REMOVED FROM ANIMAL OR NOT FOUND IN FIXATIVE.

HEART

LEUKEMIC DEPOSITS :
ORGAN AND THE BLOOD ARE INVADED BY LEUKEMIC CELLS.

LUNG

LEUKEMIC DEPOSITS :
ORGAN AND THE BLOOD ARE INVADED BY LEUKEMIC CELLS.

AUTOLYSIS PARTIAL :
NO OTHER CHANGES ARE SEEN. TISSUES ARE ALTERED. BY POST-MORTEM MODIFICATIONS AND DIAGNOSIS IS GIVEN WITH RESERVATION.

STOMACH

AUTOLYSIS PARTIAL :
NO OTHER CHANGES ARE SEEN. TISSUES ARE ALTERED. BY POST-MORTEM MODIFICATIONS AND DIAGNOSIS IS GIVEN WITH RESERVATION.

LIVER

AUTOLYSIS :
THE TISSUES EXHIBIT AUTOLYSIS AND THEY ARE NOT INTERPRETABLE.

PANCREAS

AUTOLYSIS :
THE TISSUES EXHIBIT AUTOLYSIS AND THEY ARE NOT INTERPRETABLE.

THYMUS

*** LYMPHOMA LYMPHOCYTIC :
THE NEOPLASM OF THE RETICULAR SYSTEM ORIGINATES FROM LYMPHOCYTES.

SPLEEN

AUTOLYSIS :
THE TISSUES EXHIBIT AUTOLYSIS AND THEY ARE NOT INTERPRETABLE.

KIDNEYS

LEUKEMIC DEPOSITS :
ORGAN AND THE BLOOD ARE INVADED BY LEUKEMIC CELLS.

AUTOLYSIS PARTIAL :
NO OTHER CHANGES ARE SEEN. TISSUES ARE ALTERED. BY POST-MORTEM MODIFICATIONS AND DIAGNOSIS IS GIVEN WITH RESERVATION.

BLADDER

AUTOLYSIS PARTIAL :
NO OTHER CHANGES ARE SEEN. TISSUES ARE ALTERED. BY POST-MORTEM MODIFICATIONS AND DIAGNOSIS IS GIVEN WITH RESERVATION.

PITUITARY

ABSENT :
ORGAN OR TISSUE NOT REMOVED FROM ANIMAL OR NOT FOUND IN FIXATIVE.

THYROIDS

AUTOLYSIS PARTIAL :
NO OTHER CHANGES ARE SEEN. TISSUES ARE ALTERED. BY POST-MORTEM MODIFICATIONS AND DIAGNOSIS IS GIVEN WITH RESERVATION.

SKELETAL MUSCLE

LEUKEMIC DEPOSITS :
ORGAN AND THE BLOOD ARE INVADED BY LEUKEMIC CELLS.

MESENTERY

LEUKEMIC DEPOSITS :
ORGAN AND THE BLOOD ARE INVADED BY LEUKEMIC CELLS.

BAYER AG BAYER AG BAYER AG

FEMALE 160 (1710/80)

HEART

CONGESTION :
VESSELS OR SINUSOIDS ARE MARKEDLY DISTENDED WITH

HEART CONTINUED

ERYTHROCYTES.

LUNG

EDEMA :
THE INTERSTITIAL TISSUES CONTAIN AN INCREASED AMOUNT OF FLUID.

CONGESTION :
VESSELS OR SINUSOIDS ARE MARKEDLY DISTENDED WITH ERYTHROCYTES.

LEUKEMIC DEPOSITS :
ORGAN AND THE BLOOD ARE INVADED BY LEUKEMIC CELLS.

STOMACH

LEUKEMIC DEPOSITS :
ORGAN AND THE BLOOD ARE INVADED BY LEUKEMIC CELLS.

LIVER

CONGESTION :
VESSELS OR SINUSOIDS ARE MARKEDLY DISTENDED WITH ERYTHROCYTES.

LEUKEMIC DEPOSITS :
ORGAN AND THE BLOOD ARE INVADED BY LEUKEMIC CELLS.

AUTOLYSIS PARTIAL :
NO OTHER CHANGES ARE SEEN. TISSUES ARE ALTERED. BY POST-MORTEM MODIFICATIONS AND DIAGNOSIS IS GIVEN WITH RESERVATION.

PANCREAS

CONGESTION :
VESSELS OR SINUSOIDS ARE MARKEDLY DISTENDED WITH ERYTHROCYTES.

LEUKEMIC DEPOSITS :
ORGAN AND THE BLOOD ARE INVADED BY LEUKEMIC CELLS.

AUTOLYSIS PARTIAL :
NO OTHER CHANGES ARE SEEN. TISSUES ARE ALTERED. BY POST-MORTEM MODIFICATIONS AND DIAGNOSIS IS GIVEN WITH RESERVATION.

THYMUS

*** LYMPHOMA LYMPHOCYTIC :
THE NEOPLASM OF THE RETICULAR SYSTEM ORIGINATES FROM LYMPHOCYTES.

SPLEEN

HYPERPLASIA LYMPHOID :

LF1.12 FEMALE 160 CONTINUED

SPLEEN CONTINUED
THE LYMPHOID FOLLICLES ARE INCREASED IN SIZE.

KIDNEYS

CONGESTION :
VESSELS OR SINUSOIDS ARE MARKEDLY DISTENDED WITH ERYTHROCYTES.

LEUKEMIC DEPOSITS :
ORGAN AND THE BLOOD ARE INVADED BY LEUKEMIC CELLS.

AUTOLYSIS PARTIAL :
NO OTHER CHANGES ARE SEEN. TISSUES ARE ALTERED. BY POST-MORTEM MODIFICATIONS AND DIAGNOSIS IS GIVEN WITH RESERVATION.

BLADDER

LEUKEMIC DEPOSITS :
ORGAN AND THE BLOOD ARE INVADED BY LEUKEMIC CELLS.

SKELETAL MUSCLE

LEUKEMIC DEPOSITS :
ORGAN AND THE BLOOD ARE INVADED BY LEUKEMIC CELLS.

MESENTERY

LEUKEMIC DEPOSITS :
ORGAN AND THE BLOOD ARE INVADED BY LEUKEMIC CELLS.

OVARIES

LEUKEMIC DEPOSITS :
ORGAN AND THE BLOOD ARE INVADED BY LEUKEMIC CELLS.

FEMALE 162 (1720/80)

LUNG

LEUKEMIC DEPOSITS :
ORGAN AND THE BLOOD ARE INVADED BY LEUKEMIC CELLS.

LIVER

LEUKEMIC DEPOSITS :
ORGAN AND THE BLOOD ARE INVADED BY LEUKEMIC CELLS.

BAYER AG

PANCREAS

LEUKEMIC DEPOSITS :
ORGAN AND THE BLOOD ARE INVADED BY LEUKEMIC CELLS.

SPLEEN

*** LYMPHOMA LYMPHOCYTIC :
THE NEOPLASM OF THE RETICULAR SYSTEM ORIGINATES FROM LYMPHOCYTES.

KIDNEYS

LEUKEMIC DEPOSITS :
ORGAN AND THE BLOOD ARE INVADED BY LEUKEMIC CELLS.

BLADDER

LEUKEMIC DEPOSITS :
ORGAN AND THE BLOOD ARE INVADED BY LEUKEMIC CELLS.

THYROIDS

CYSTS :
UNILATERAL
ONE OR MORE CYSTS FILLED WITH CLEAR LIQUID ARE SEEN.

ADRENALS

LEUKEMIC DEPOSITS :
ORGAN AND THE BLOOD ARE INVADED BY LEUKEMIC CELLS.

OVARIES

ATROPHY :
BILATERAL
THE ORGAN IS REDUCED IN SIZE.

CYSTS :
UNILATERAL
ONE OR MORE CYSTS FILLED WITH CLEAR LIQUID ARE SEEN.

UTERUS

CYSTIC ENDOMETRIAL HYPERPLASIA :
THE ENDOMETRIAL GLANDS ARE INCREASED IN NUMBER AND SOME ARE DILATED OR CYSTIC.

FEMALE 165 (168a/80)

NF1•14 FEMALE 165 CONTINUED

LUNG

CONGESTION :
VESSELS OR SINUSOIDS ARE MARKEDLY DISTENDED WITH ERYTHROCYTES.

LIVER

AUTOLYSIS PARTIAL :
NO OTHER CHANGES ARE SEEN. TISSUES ARE ALTERED BY POST-MORTEM MODIFICATIONS AND DIAGNOSIS IS GIVEN WITH RESERVATION.

PANCREAS

AUTOLYSIS PARTIAL :
NO OTHER CHANGES ARE SEEN. TISSUES ARE ALTERED BY POST-MORTEM MODIFICATIONS AND DIAGNOSIS IS GIVEN WITH RESERVATION.

SPLEEN

*** LYMPHOMA LYMPHOCYTIC :
THE NEOPLASM OF THE RETICULAR SYSTEM ORIGINATES FROM LYMPHOCYTES.

AUTOLYSIS PARTIAL :
NO OTHER CHANGES ARE SEEN. TISSUES ARE ALTERED BY POST-MORTEM MODIFICATIONS AND DIAGNOSIS IS GIVEN WITH RESERVATION.

KIDNEYS

CONGESTION :
VESSELS OR SINUSOIDS ARE MARKEDLY DISTENDED WITH ERYTHROCYTES.

LEUKEMIC DEPOSITS :
ORGAN AND THE BLOOD ARE INVADED BY LEUKEMIC CELLS.

BLADDER

AUTOLYSIS PARTIAL :
NO OTHER CHANGES ARE SEEN. TISSUES ARE ALTERED BY POST-MORTEM MODIFICATIONS AND DIAGNOSIS IS GIVEN WITH RESERVATION.

PITUITARY

ABSENT :
ORGAN OR TISSUE NOT REMOVED FROM ANIMAL OR NOT FOUND IN FIXATIVE.

UTERUS

NORMAL :
HISTOLOGICAL ASPECT WITHIN NORMAL LIMITS.

BAYER AG

FEMALE 166 (1715/60)

BRAIN

ABSENT :
ORGAN OR TISSUE NOT REMOVED FROM ANIMAL OR NOT FOUND IN FIXATIVE.

LUNG

EDEMA :
THE INTERSTITIAL TISSUES CONTAIN AN INCREASED AMOUNT OF FLUID.

CONGESTION :
VESSELS OR SINUSOIDS ARE MARKEDLY DISTENDED WITH ERYTHROCYTES.

LEUKEMIC DEPOSITS :
ORGAN AND THE BLOOD ARE INVADED BY LEUKEMIC CELLS.

LIVER

LEUKEMIC DEPOSITS :
ORGAN AND THE BLOOD ARE INVADED BY LEUKEMIC CELLS.

AUTOLYSIS PARTIAL :
NO OTHER CHANGES ARE SEEN. TISSUES ARE ALTERED. BY POST-MORTEM MODIFICATIONS AND DIAGNOSIS IS GIVEN WITH RESERVATION.

PANCREAS

LEUKEMIC DEPOSITS :
ORGAN AND THE BLOOD ARE INVADED BY LEUKEMIC CELLS.

AUTOLYSIS PARTIAL :
NO OTHER CHANGES ARE SEEN. TISSUES ARE ALTERED. BY POST-MORTEM MODIFICATIONS AND DIAGNOSIS IS GIVEN WITH RESERVATION.

SPLEEN

*** LYMPHOMA LYMPHOCYTIC :
THE NEOPLASM OF THE RETICULAR SYSTEM ORIGINATES FROM LYMPHOCYTES.

AUTOLYSIS PARTIAL :
NO OTHER CHANGES ARE SEEN. TISSUES ARE ALTERED. BY POST-MORTEM MODIFICATIONS AND DIAGNOSIS IS GIVEN WITH RESERVATION.

KIDNEYS

LEUKEMIC DEPOSITS :
ORGAN AND THE BLOOD ARE INVADED BY LEUKEMIC CELLS.

AUTOLYSIS PARTIAL :
NO OTHER CHANGES ARE SEEN. TISSUES ARE ALTERED. BY POST-MORTEM MODIFICATIONS AND DIAGNOSIS IS GIVEN WITH RESERVATION.

PITUITARY

ABSENT :
ORGAN OR TISSUE NOT REMOVED FROM ANIMAL OR NOT FOUND IN FIXATIVE.

THYROIDS

AUTOLYSIS PARTIAL :
NO OTHER CHANGES ARE SEEN. TISSUES ARE ALTERED. BY POST-MORTEM MODIFICATIONS AND DIAGNOSIS IS GIVEN WITH RESERVATION.

ADRENALS

LEUKEMIC DEPOSITS :
ORGAN AND THE BLOOD ARE INVADED BY LEUKEMIC CELLS.

MESENTERY

LEUKEMIC DEPOSITS :
ORGAN AND THE BLOOD ARE INVADED BY LEUKEMIC CELLS.

OVARIES

ABSENT :
ORGAN OR TISSUE NOT REMOVED FROM ANIMAL OR NOT FOUND IN FIXATIVE.

LYMPH NODE

*** LYMPHOMA LYMPHOCYTIC :
THE NEOPLASM OF THE RETICULAR SYSTEM ORIGINATES FROM LYMPHOCYTES.

FEMALE 167 (1742/80)

LUNG

*** ALVEOLOGENIC CARCINOMA :
MULTIFOCAL
A MALIGNANT TUMOR OF THE LUNG TISSUE WITH

BAYER AG

LUNG CONTINUED

SYNONYMS IN MICE FOR ADENOMA, CARCINOMA, ALVEOLOGENIC PAPILLARY CARCINOMA, PAPILLARY CYSTADENOMA, ADENOCARCINOMA, BRONCHIOLAR CELL CARCINOMA, BRONCHIOLAR-ALVEOLAR TUMOR, TYPE A TUMOR, TYPE B TUMOR, INTERMEDIATE TYPE I TUMOR AND COMMON PULMONARY TUMOR OF THE MOUSE.

KIDNEYS

TUBULOPATHY :
BILATERAL MODERATE
TUBULAR DEGENERATIVE CHANGES ARE PRESENT WHICH MAY BE ASSOCIATED WITH TUBULAR DILATATION.

DILATATION OF GLOMERULAR LOOPS :
BILATERAL MODERATE
GLOMERULAR LOOPS APPEAR UNUSUALLY ENLARGED AND THIN.

BLADDER

UNREADABLE :
IT IS NOT POSSIBLE TO INTERPRET THE SECTION DUE TO AN ARTIFACT CAUSED BY SAMPLING OR HISTOLOGICAL TECHNIQUE.

ADRENALS

PIGMENTATION :
MODERATE
NUMEROUS MACROPHAGES CONTAIN A GRANULAR BROWN CYTOPLASMIC PIGMENT.

HYPERPLASIA OF THE GLOMERULAR LAYER :
BILATERAL MULTIFOCAL
THE GLOMERULAR LAYER IS THICKER THAN NORMAL.

OVARIES

INFLAMMATION ACUTE :
UNILATERAL
A LESION MADE OF CONGESTION EDEMA FIBRINOUS EXUDATE WITH INFILTRATION OF LEUKOCYTES.

CYSTS :
BILATERAL
ONE OR MORE CYSTS FILLED WITH CLEAR LIQUID ARE SEEN.

PUS :
UNILATERAL
A MORE OR LESS IMPORTANT QUANTITY OF PUS IS OBSERVED IN THIS TISSUE OR ORGAN.

UTERUS

CYSTIC ENDOMETRIAL HYPERPLASIA :
THE ENDOMETRIAL GLANDS ARE INCREASED IN NUMBER AND SOME ARE DILATED OR CYSTIC.

FEMUR

UNREADABLE :

FEMUR CONTINUED

IT IS NOT POSSIBLE TO INTERPRET THE SECTION DUE TO AN ARTIFACT CAUSED BY SAMPLING OR HISTOLOGICAL TECHNIQUE.

FEMALE 169 (1682/80)

HEART

AUTOLYSIS PARTIAL :
NO OTHER CHANGES ARE SEEN. TISSUES ARE ALTERED.
BY POST-MORTEM MODIFICATIONS AND
DIAGNOSIS IS GIVEN WITH RESERVATION.

LUNG

AUTOLYSIS PARTIAL :
NO OTHER CHANGES ARE SEEN. TISSUES ARE ALTERED.
BY POST-MORTEM MODIFICATIONS AND
DIAGNOSIS IS GIVEN WITH RESERVATION.

STOMACH

NORMAL :
HISTOLOGICAL ASPECT WITHIN NORMAL LIMITS.

PANCREAS

AUTOLYSIS PARTIAL :
NO OTHER CHANGES ARE SEEN. TISSUES ARE ALTERED.
BY POST-MORTEM MODIFICATIONS AND
DIAGNOSIS IS GIVEN WITH RESERVATION.

KIDNEYS

AUTOLYSIS PARTIAL :
NO OTHER CHANGES ARE SEEN. TISSUES ARE ALTERED.
BY POST-MORTEM MODIFICATIONS AND
DIAGNOSIS IS GIVEN WITH RESERVATION.

BLADDER

EDEMA :
THE INTERSTITIAL TISSUES CONTAIN AN INCREASED AMOUNT OF FLUID.

PITUITARY

UNREADABLE :
IT IS NOT POSSIBLE TO INTERPRET THE SECTION DUE TO AN ARTIFACT CAUSED BY SAMPLING OR HISTOLOGICAL TECHNIQUE.

ADRENALS

AUTOLYSIS PARTIAL :
NO OTHER CHANGES ARE SEEN. TISSUES ARE ALTERED.

BAYER AG

ADRENALS CONTINUED
BY POST-MORTEM MODIFICATIONS AND
DIAGNOSIS IS GIVEN WITH RESERVATION.

OVARIES

HYPERTROPHIC CORPORA LUTEA :
ALL CORPORA LUTEA ARE IMPORTANT IN SIZE. THEY CONTAIN LARGE LUTEAL CELLS WITH ACIDOPHILIC CYTOPLASM.

FEMALE 172 (1718/80)

HEART

CALCIFICATION :
MODERATE
THERE ARE MINERAL DEPOSITS.

LUNG

THICKENED ALVEOLAR WALLS :
THICKNESS OF ALVEOLAR WALLS IS INCREASED BY INFLAMMATORY CELLS AND/OR INTERSTITIAL EDEMA.

STOMACH

NORMAL :
HISTOLOGICAL ASPECT WITHIN NORMAL LIMITS.

DUODENUM

NORMAL :
HISTOLOGICAL ASPECT WITHIN NORMAL LIMITS.

SPLEEN

CONGESTION :
VESSELS OR SINUSOIDS ARE MARKEDLY DISTENDED WITH ERYTHROCYTES.

BLADDER

HYPERPLASIA PAPILLOMATOUS :
THE THICKNESS OF THE MUCOSA IS INCREASED MAKING UNUSUALLY HIGH AND NUMEROUS FOLDS.

ADRENALS

PIGMENTATION :
MODERATE
NUMEROUS MACROPHAGES CONTAIN A GRANULAR BROWN CYTOPLASMIC PIGMENT.

OVARIES

ATROPHY :
THE ORGAN IS REDUCED IN SIZE.

UTERUS

*** LEIOMYOSARCOMA :
UNILATERAL
MALIGNANT TUMOR DERIVED FROM SMOOTH MUSCLE FIBERS.

FEMALE 173 (1712/80)

HEART

CONGESTION :
VESSELS OR SINUSOIDS ARE MARKEDLY DISTENDED WITH ERYTHROCYTES.

LUNG

*** ALVEOLOGENIC CARCINOMA :
A MALIGNANT TUMOR OF THE LUNG TISSUE WITH SYNONYMS IN MICE FOR ADENOMA, CARCINOMA, ALVEOLOGENIC PAPILLARY CARCINOMA, PAPILLARY CYSTADENOMA, ADENOCARCINOMA, BRONCHIOLAR CELL CARCINOMA, BRONCHIOLAR-ALVEOLAR TUMOR, TYPE A TUMOR, TYPE B TUMOR, INTERMEDIATE TYPE I TUMOR AND COMMON PULMONARY TUMOR OF THE MOUSE.

CONGESTION :
VESSELS OR SINUSOIDS ARE MARKEDLY DISTENDED WITH ERYTHROCYTES.

LIVER

HYPERTROPHY :
THE SIZE OF THE ORGAN IS INCREASED WITHOUT STRUCTURAL ANOMALY.

LEUKEMIC DEPOSITS :
ORGAN AND THE BLOOD ARE INVADED BY LEUKEMIC CELLS.

SPLEEN

*** LYMPHOMA LYMPHOCYTIC :
THE NEOPLASM OF THE RETICULAR SYSTEM ORIGINATES FROM LYMPHOCYTES.

KIDNEYS

LEUKEMIC DEPOSITS :
ORGAN AND THE BLOOD ARE INVADED BY LEUKEMIC

BAYER AG

KIDNEYS CONTINUED
CELLS.

THYROIDS

ABSENT :
ORGAN OR TISSUE NOT REMOVED FROM ANIMAL OR NOT FOUND IN FIXATIVE.

ADRENALS

HYPERPLASIA OF THE GLOMERULAR LAYER :
THE GLOMERULAR LAYER IS THICKER THAN NORMAL.

OVARIES

CYSTS :
UNILATERAL
ONE OR MORE CYSTS FILLED WITH CLEAR LIQUID ARE SEEN.

HYPERTROPHIC CORPORA LUTEA :
CONTRALATERAL
ALL CORPORA LUTEA ARE IMPORTANT IN SIZE. THEY CONTAIN LARGE LUTEAL CELLS WITH ACIDOPHILIC CYTOPLASM.

UTERUS

CYSTIC ENDOMETRIAL HYPERPLASIA :
THE ENDOMETRIAL GLANDS ARE INCREASED IN NUMBER AND SOME ARE DILATED OR CYSTIC.

FEMALE 174 (1688/80)

BRAIN

ABSENT :
ORGAN OR TISSUE NOT REMOVED FROM ANIMAL OR NOT FOUND IN FIXATIVE.

HEART

AUTOLYSIS PARTIAL :
NO OTHER CHANGES ARE SEEN. TISSUES ARE ALTERED.
BY POST-MORTEM MODIFICATIONS AND
DIAGNOSIS IS GIVEN WITH RESERVATION.

PERICARDITIS :
THE PERICARDIUM IS THE SITE OF ACUTE OR CHRONIC INFLAMMATION.

LUNG

AUTOLYSIS PARTIAL :
NO OTHER CHANGES ARE SEEN. TISSUES ARE ALTERED.
BY POST-MORTEM MODIFICATIONS AND

LUNG CONTINUED

DIAGNOSIS IS GIVEN WITH RESERVATION.

STOMACH

AUTOLYSIS :
THE TISSUES EXHIBIT AUTOLYSIS AND THEY ARE NOT INTERPRETABLE.

LIVER

AUTOLYSIS :
THE TISSUES EXHIBIT AUTOLYSIS AND THEY ARE NOT INTERPRETABLE.

PANCREAS

AUTOLYSIS :
THE TISSUES EXHIBIT AUTOLYSIS AND THEY ARE NOT INTERPRETABLE.

SPLEEN

AUTOLYSIS :
THE TISSUES EXHIBIT AUTOLYSIS AND THEY ARE NOT INTERPRETABLE.

KIDNEYS

AUTOLYSIS :
THE TISSUES EXHIBIT AUTOLYSIS AND THEY ARE NOT INTERPRETABLE.

BLADDER

AUTOLYSIS :
THE TISSUES EXHIBIT AUTOLYSIS AND THEY ARE NOT INTERPRETABLE.

ADRENALS

AUTOLYSIS :
THE TISSUES EXHIBIT AUTOLYSIS AND THEY ARE NOT INTERPRETABLE.

FEMALE 175 (1713/80)

LUNG

*** ALVEOLOGENIC CARCINOMA :
A MALIGNANT TUMOR OF THE LUNG TISSUE WITH SYNONYMS IN MICL FOR ADENOMA, CARCINOMA, ALVEOLOGENIC PAPILLARY CARCINOMA, PAPILLARY CYSTADENOMA, ADENOCARCINOMA, BRONCHIOLAR CELL CARCINOMA, BRONCHIOLAR-ALVEOLAR TUMOR,

BAYER AG

LUNG CONTINUED

TYPE A TUMOR, TYPE B TUMOR, INTERMEDIATE TYPE I TUMOR AND COMMON PULMONARY TUMOR OF THE MOUSE.

STOMACH

MUCOID CYST :
ONE OR MORE CYSTS CONTAINING MUCOID MATERIAL ARE OBSERVED.

LIVER

AMYLOID :
MULTIFOCAL
HOMOGENEOUS ACIDOPHILIC MATERIAL IS DEPOSITED.

SPLEEN

*** LYMPHOMA LYMPHOCYTIC :
THE NEOPLASM OF THE RETICULAR SYSTEM ORIGINATES FROM LYMPHOCYTES.

KIDNEYS

PROGRESSIVE NEPHROPATHY :
BILATERAL MINIMAL
AN AGE ASSOCIATED KIDNEY LESION CONSISTING OF CYSTIC TUBULES WITH COLLOID OR HYALINE CASTS CHRONIC INTERSTITIAL NEPHRITIS AND DILATATION OF BOWMAN'S CAPSULE WITH GLOMERULAR DEGENERATION .

THYROIDS

ABSENT :
ORGAN OR TISSUE NOT REMOVED FROM ANIMAL OR NOT FOUND IN FIXATIVE.

ADRENALS

PIGMENTATION :
BILATERAL SEVERE
NUMEROUS MACROPHAGES CONTAIN A GRANULAR BROWN CYTOPLASMIC PIGMENT.

SCIATIC NERVE

ABSENT :
ORGAN OR TISSUE NOT REMOVED FROM ANIMAL OR NOT FOUND IN FIXATIVE.

OVARIES

ATROPHY :
THE ORGAN IS REDUCED IN SIZE.

UTERUS

THROMBOSIS :
SEVERE
THE VASCULAR LUMEN CONTAINS AN ATTACHED ANTE MORTEM BLOOD CLOT.

HEMORRHAGE :
SEVERE

UTERUS CONTINUED
THERE IS EXTRAVASATION OF BLOOD.

FEMALE 176 (1080/80)

BRAIN

AUTOLYSIS :
THE TISSUES EXHIBIT AUTOLYSIS AND THEY ARE NOT INTERPRETABLE.

HEART

AUTOLYSIS :
THE TISSUES EXHIBIT AUTOLYSIS AND THEY ARE NOT INTERPRETABLE.

LUNG

AUTOLYSIS :
THE TISSUES EXHIBIT AUTOLYSIS AND THEY ARE NOT INTERPRETABLE.

STOMACH

AUTOLYSIS :
THE TISSUES EXHIBIT AUTOLYSIS AND THEY ARE NOT INTERPRETABLE.

LIVER

AUTOLYSIS :
THE TISSUES EXHIBIT AUTOLYSIS AND THEY ARE NOT INTERPRETABLE.

PANCREAS

AUTOLYSIS :
THE TISSUES EXHIBIT AUTOLYSIS AND THEY ARE NOT INTERPRETABLE.

SPLEEN

AUTOLYSIS :
THE TISSUES EXHIBIT AUTOLYSIS AND THEY ARE NOT INTERPRETABLE.

KIDNEYS

AUTOLYSIS :
THE TISSUES EXHIBIT AUTOLYSIS AND THEY ARE NOT INTERPRETABLE.

BAYER AG

Vertraulich
Eigentum der Firma Bayer AG
Benutzung, Verwertung oder Weitergabe nur mit Einwilligung der Bayer AG gestattet

BLADDER

AUTOLYSIS :
THE TISSUES EXHIBIT AUTOLYSIS AND THEY ARE NOT INTERPRETABLE.

PITUITARY

AUTOLYSIS :
THE TISSUES EXHIBIT AUTOLYSIS AND THEY ARE NOT INTERPRETABLE.

THYROIDS

AUTOLYSIS :
THE TISSUES EXHIBIT AUTOLYSIS AND THEY ARE NOT INTERPRETABLE.

ADRENALS

AUTOLYSIS :
THE TISSUES EXHIBIT AUTOLYSIS AND THEY ARE NOT INTERPRETABLE.

OVARIES

AUTOLYSIS :
THE TISSUES EXHIBIT AUTOLYSIS AND THEY ARE NOT INTERPRETABLE.

FEMALE 180 (1719/80)

LUNG

*** ALVEOLOGENIC CARCINOMA :
A MALIGNANT TUMOR OF THE LUNG TISSUE WITH SYNONYMS IN MICE FOR ADENOMA, CARCINOMA, ALVEOLOGENIC PAPILLARY CARCINOMA, PAPILLARY CYSTADENOMA, ADENOCARCINOMA, BRONCHIOLAR CELL CARCINOMA, BRONCHIOLAR-ALVEOLAR TUMOR, TYPE A TUMOR, TYPE B TUMOR, INTERMEDIATE TYPE I TUMOR AND COMMON PULMONARY TUMOR OF THE MOUSE.

LIVER

HYPERPLASTIC NODULE :
A NODULE OF HYPERPLASTIC TISSUE IS PRESENT.

SPLEEN

HYPERPLASIA LYMPHOID :
THE LYMPHOID FOLLICLES ARE INCREASED IN SIZE.

ADRENALS

PIGMENTATION :
MINIMAL
NUMEROUS MACROPHAGES CONTAIN A GRANULAR BROWN CYTOPLASMIC PIGMENT.

MAMMARY GLAND

HYPERPLASIA SECRETORY :
THE DEVELOPED GLANDS AND/OR DUCTS CONTAIN A SECRETION

OVARIES

ATROPHY :
BILATERAL
THE ORGAN IS REDUCED IN SIZE.

CYSTS :
UNILATERAL
ONE OR MORE CYSTS FILLED WITH CLEAR LIQUID ARE SEEN.

FEMALE 181 (1745/80)

HEART

THROMBOSIS :
THE VASCULAR LUMEN CONTAINS AN ATTACHED ANTE MORTEM BLOOD CLOT.

LIVER

VACUOLIZATION :
MINIMAL
IN THESE CELLS THERE ARE CLEAR VACUOLES GREATER IN NUMBER AND SIZE THAN NORMALLY FOUND.

SPLEEN

HEMATOPOIESIS :
MODERATE
THE HEMATOPOIESIS IS EVIDENT.

KIDNEYS

HYDRONEPHROSIS :
CONTRALATERAL
THE RENAL PELVIS IS DILATED AND THE ADJACENT PARENCHYMA IS REDUCED.

HEMORRHAGE :
UNILATERAL
THERE IS EXTRAVASATION OF BLOOD.

PROGRESSIVE NEPHROPATHY :
BILATERAL MINIMAL

BAYER AG

KIDNEYS CONTINUED

AN AGE ASSOCIATED KIDNEY LESION CONSISTING OF CYSTIC TUBULES WITH COLLOID OR HYALINE CASTS CHRONIC INTERSTITIAL NEPHRITIS AND DILATATION OF BOWMAN'S CAPSULE WITH GLOMERULAR DEGENERATION .

OVARIES

ATROPHY :
BILATERAL
THE ORGAN IS REDUCED IN SIZE.

CYSTS :
UNILATERAL
ONE OR MORE CYSTS FILLED WITH CLEAR LIQUID ARE SEEN.

UTERUS

HEMORRHAGE :
SEVERE
THERE IS EXTRAVASATION OF BLOOD.

CYSTIC ENDOMETRIAL HYPERPLASIA :
SEVERE
THE ENDOMETRIAL GLANDS ARE INCREASED IN NUMBER AND SOME ARE DILATED OR CYSTIC.

ENDOMETRIOSIS :
SEVERE
ENDOMETRIAL GLANDS ARE SEEN AT VARIOUS SITES OUTSIDE THE NORMAL ENDOMETRIUM.

FEMALE 182 (1685/80)

BRAIN

ABSENT :
ORGAN OR TISSUE NOT REMOVED FROM ANIMAL OR NOT FOUND IN FIXATIVE.

LUNG

LEUKEMIC DEPOSITS :
ORGAN AND THE BLOOD ARE INVADED BY LEUKEMIC CELLS.

STOMACH

AUTOLYSIS :
THE TISSUES EXHIBIT AUTOLYSIS AND THEY ARE NOT INTERPRETABLE.

LIVER

AUTOLYSIS PARTIAL :

LIVER CONTINUED

NO OTHER CHANGES ARE SEEN. TISSUES ARE ALTERED.
BY POST-MORTEM MODIFICATIONS AND
DIAGNOSIS IS GIVEN WITH RESERVATION.

PANCREAS

AUTOLYSIS :
THE TISSUES EXHIBIT AUTOLYSIS AND THEY ARE NOT
INTERPRETABLE.

SPLEEN

*** LYMPHOMA LYMPHOCYTIC :
THE NEOPLASM OF THE RETICULAR SYSTEM ORIGINATES FROM
LYMPHOCYTES.

AUTOLYSIS PARTIAL :
NO OTHER CHANGES ARE SEEN. TISSUES ARE ALTERED.
BY POST-MORTEM MODIFICATIONS AND
DIAGNOSIS IS GIVEN WITH RESERVATION.

KIDNEYS

LEUKEMIC DEPOSITS :
ORGAN AND THE BLOOD ARE INVADED BY LEUKEMIC
CELLS.

AUTOLYSIS PARTIAL :
NO OTHER CHANGES ARE SEEN. TISSUES ARE ALTERED.
BY POST-MORTEM MODIFICATIONS AND
DIAGNOSIS IS GIVEN WITH RESERVATION.

BLADDER

LEUKEMIC DEPOSITS :
ORGAN AND THE BLOOD ARE INVADED BY LEUKEMIC
CELLS.

AUTOLYSIS PARTIAL :
NO OTHER CHANGES ARE SEEN. TISSUES ARE ALTERED.
BY POST-MORTEM MODIFICATIONS AND
DIAGNOSIS IS GIVEN WITH RESERVATION.

THYROIDS

ABSENT :
ORGAN OR TISSUE NOT REMOVED FROM ANIMAL OR NOT FOUND IN
FIXATIVE.

OVARIES

LEUKEMIC DEPOSITS :
ORGAN AND THE BLOOD ARE INVADED BY LEUKEMIC
CELLS.

BAYER AG

FEMALE 183 (1709/80)

BRAIN

LEUKEMIC DEPOSITS :
ORGAN AND THE BLOOD ARE INVADED BY LEUKEMIC CELLS.

HEART

LEUKEMIC DEPOSITS :
ORGAN AND THE BLOOD ARE INVADED BY LEUKEMIC CELLS.

LUNG

LEUKEMIC DEPOSITS :
ORGAN AND THE BLOOD ARE INVADED BY LEUKEMIC CELLS.

STOMACH

LEUKEMIC DEPOSITS :
ORGAN AND THE BLOOD ARE INVADED BY LEUKEMIC CELLS.

LIVER

LEUKEMIC DEPOSITS :
ORGAN AND THE BLOOD ARE INVADED BY LEUKEMIC CELLS.

PANCREAS

LEUKEMIC DEPOSITS :
ORGAN AND THE BLOOD ARE INVADED BY LEUKEMIC CELLS.

SPLEEN

HYPERPLASIA LYMPHOID :
THE LYMPHOID FOLLICLES ARE INCREASED IN SIZE.

KIDNEYS

LEUKEMIC DEPOSITS :
ORGAN AND THE BLOOD ARE INVADED BY LEUKEMIC CELLS.

BLADDER

LEUKEMIC DEPOSITS :
ORGAN AND THE BLOOD ARE INVADED BY LEUKEMIC CELLS.

ADRENALS

LEUKEMIC DEPOSITS :
ORGAN AND THE BLOOD ARE INVADED BY LEUKEMIC CELLS.

SCIATIC NERVE

ABSENT :
ORGAN OR TISSUE NOT REMOVED FROM ANIMAL OR NOT FOUND IN FIXATIVE.

MESENTERY

LEUKEMIC DEPOSITS :
ORGAN AND THE BLOOD ARE INVADED BY LEUKEMIC CELLS.

OVARIES

LEUKEMIC DEPOSITS :
ORGAN AND THE BLOOD ARE INVADED BY LEUKEMIC CELLS.

UTERUS

LEUKEMIC DEPOSITS :
ORGAN AND THE BLOOD ARE INVADED BY LEUKEMIC CELLS.

LYMPH NODE

*** LYMPHOMA LYMPHOCYTIC :
THE NEOPLASM OF THE RETICULAR SYSTEM ORIGINATES FROM LYMPHOCYTES.

FEMALE 184 (1743/80)

LUNG

CONGESTION :
VESSELS OR SINUSOIDS ARE MARKEDLY DISTENDED WITH ERYTHROCYTES.

STOMACH

MUCOID CYST :
MULTIFOCAL
ONE OR MORE CYSTS CONTAINING MUCOID MATERIAL ARE OBSERVED.

LIVER

CONGESTION :
VESSELS OR SINUSOIDS ARE MARKEDLY DISTENDED WITH ERYTHROCYTES.

BAYER AG

SPLEEN

HEMATOPOIESIS :
SEVERE
THE HEMATOPOIESIS IS EVIDENT.

ADRENALS

PIGMENTATION :
SEVERE
NUMEROUS MACROPHAGES CONTAIN A GRANULAR BROWN CYTOPLASMIC PIGMENT.

OVARIES

ATROPHY :
BILATERAL
THE ORGAN IS REDUCED IN SIZE.

CYSTS :
BILATERAL
ONE OR MORE CYSTS FILLED WITH CLEAR LIQUID ARE SEEN.

UTERUS

CYSTIC ENDOMETRIAL HYPERPLASIA :
SEVERE
THE ENDOMETRIAL GLANDS ARE INCREASED IN NUMBER AND SOME ARE DILATED OR CYSTIC.

FEMALE 185 (1722/80)

LUNG

NECROSIS :
THE TISSUE HAS LOST ITS NORMAL STRUCTURE DUE TO CELL DEATH WHICH MAY BE OF VARIOUS ORIGIN.

HEMORRHAGE :
THERE IS EXTRAVASATION OF BLOOD.

*** ALVEOLOGENIC CARCINOMA :
MULTIFOCAL
A MALIGNANT TUMOR OF THE LUNG TISSUE WITH SYNONYMS IN MICE FOR ADENOMA, CARCINOMA, ALVEOLOGENIC PAPILLARY CARCINOMA, PAPILLARY CYSTADENOMA, ADENOCARCINOMA, BRONCHIOLAR CELL CARCINOMA, BRONCHIOLAR-ALVEOLAR TUMOR, TYPE A TUMOR, TYPE B TUMOR, INTERMEDIATE TYPE I TUMOR AND COMMON PULMONARY TUMOR OF THE MOUSE.

PANCREAS

INFLAMMATION CHRONIC :

PANCREAS CONTINUED

THE INTERSTITIAL TISSUES SHOW INFILTRATION BY MONONUCLEAR CELLS AND INCREASE IN FIBROUS STROMA.

ATROPHY :
THE ORGAN IS REDUCED IN SIZE.

KIDNEYS

TUBULOPATHY :
UNILATERAL
TUBULAR DEGENERATIVE CHANGES ARE PRESENT WHICH MAY BE ASSOCIATED WITH TUBULAR DILATATION.

DILATATION OF GLOMERULAR LOOPS :
UNILATERAL
GLOMERULAR LOOPS APPEAR UNUSUALLY ENLARGED AND THIN.

ADRENALS

PIGMENTATION :
MINIMAL
NUMEROUS MACROPHAGES CONTAIN A GRANULAR BROWN CYTOPLASMIC PIGMENT.

MESENTERY

PERITONITIS :
THE SEROSA IS COVERED BY EXUDATE SHOWING ORGANIZATION AND INFLAMMATION.

OVARIES

INFLAMMATION ACUTE :
UNILATERAL
A LESION MADE OF CONGESTION EDEMA FIBRINOUS EXUDATE WITH INFILTRATION OF LEUKOCYTES.

PUS :
UNILATERAL
A MORE OR LESS IMPORTANT QUANTITY OF PUS IS OBSERVED IN THIS TISSUE OR ORGAN.

UTERUS

CYSTIC ENDOMETRIAL HYPERPLASIA :
THE ENDOMETRIAL GLANDS ARE INCREASED IN NUMBER AND SOME ARE DILATED OR CYSTIC.

BAYER AG

FEMALE 187 (1689/80)

HEART

CONGESTION :
VESSELS OR SINUSOIDS ARE MARKEDLY DISTENDED WITH

HEART CONTINUED

ERYTHROCYTES.

LUNG

CONGESTION :
VESSELS OR SINUSOIDS ARE MARKEDLY DISTENDED WITH ERYTHROCYTES.

KIDNEYS

TUBULOPATHY :
UNILATERAL MINIMAL
TUBULAR DEGENERATIVE CHANGES ARE PRESENT WHICH MAY BE ASSOCIATED WITH TUBULAR DILATATION.

OVARIES

CYSTS :
UNILATERAL
ONE OR MORE CYSTS FILLED WITH CLEAR LIQUID ARE SEEN.

HYPERTROPHIC CORPORA LUTEA :
BILATERAL
ALL CORPORA LUTEA ARE IMPORTANT IN SIZE. THEY CONTAIN LARGE LUTEAL CELLS WITH ACIDOPHILIC CYTOPLASM.

ABDOMINAL CAVITY

STEATONECROSIS :
FAT TISSUE IS NECROTIC AND SURROUNDED BY INFLAMMATORY AND GIANT CELL REACTION.

FEMALE 189 (1714/80)

HEART

CONGESTION :
VESSELS OR SINUSOIDS ARE MARKEDLY DISTENDED WITH ERYTHROCYTES.

LUNG

CONGESTION :
VESSELS OR SINUSOIDS ARE MARKEDLY DISTENDED WITH ERYTHROCYTES.

THICKENED ALVEOLAR WALLS :
THICKNESS OF ALVEOLAR WALLS IS INCREASED BY INFLAMMATORY CELLS AND/OR INTERSTITIAL EDEMA.

STOMACH

HEMORRHAGE :
THERE IS EXTRAVASATION OF BLOOD.

LIVER

CONGESTION :
VESSELS OR SINUSOIDS ARE MARKEDLY DISTENDED WITH ERYTHROCYTES.

PANCREAS

AUTOLYSIS :
THE TISSUES EXHIBIT AUTOLYSIS AND THEY ARE NOT INTERPRETABLE.

SPLEEN

HYPERPLASIA LYMPHOID :
THE LYMPHOID FOLLICLES ARE INCREASED IN SIZE.

KIDNEYS

HEMORRHAGE :
SEVERE
THERE IS EXTRAVASATION OF BLOOD.

LEUKEMIC DEPOSITS :
BILATERAL
ORGAN AND THE BLOOD ARE INVADED BY LEUKEMIC CELLS.

BLADDER

LEUKEMIC DEPOSITS :
ORGAN AND THE BLOOD ARE INVADED BY LEUKEMIC CELLS.

THYROIDS

ABSENT :
ORGAN OR TISSUE NOT REMOVED FROM ANIMAL OR NOT FOUND IN FIXATIVE.

ADRENALS

HYPERPLASIA OF THE GLOMERULAR LAYER :
THE GLOMERULAR LAYER IS THICKER THAN NORMAL.

MESENTERY

LEUKEMIC DEPOSITS :
ORGAN AND THE BLOOD ARE INVADED BY LEUKEMIC CELLS.

OVARIES

CYSTS :
BILATERAL
ONE OR MORE CYSTS FILLED WITH CLEAR LIQUID ARE SEEN.

LEUKEMIC DEPOSITS :
ORGAN AND THE BLOOD ARE INVADED BY LEUKEMIC CELLS.

BAYER AG

UTERUS

LEUKEMIC DEPOSITS :
ORGAN AND THE BLOOD ARE INVADED BY LEUKEMIC CELLS.

LYMPH NODE

*** LYMPHOMA LYMPHOCYTIC :
THE NEOPLASM OF THE RETICULAR SYSTEM ORIGINATES FROM LYMPHOCYTES.

FEMALE 190 (1723/80)

LUNG

*** ALVEOLOGENIC CARCINOMA :
A MALIGNANT TUMOR OF THE LUNG TISSUE WITH SYNONYMS IN MICE FOR ADENOMA, CARCINOMA, ALVEOLOGENIC PAPILLARY CARCINOMA, PAPILLARY CYSTADENOMA, ADENOCARCINOMA, BRONCHIOLAR CELL CARCINOMA, BRONCHIOLAR-ALVEOLAR TUMOR, TYPE A TUMOR, TYPE B TUMOR, INTERMEDIATE TYPE I TUMOR AND COMMON PULMONARY TUMOR OF THE MOUSE.

ADRENALS

PIGMENTATION :
MINIMAL
NUMEROUS MACROPHAGES CONTAIN A GRANULAR BROWN CYTOPLASMIC PIGMENT.

OVARIES

ATROPHY :
THE ORGAN IS REDUCED IN SIZE.

CYSTS :
ONE OR MORE CYSTS FILLED WITH CLEAR LIQUID ARE SEEN.

UTERUS

CYSTIC ENDOMETRIAL HYPERPLASIA :
THE ENDOMETRIAL GLANDS ARE INCREASED IN NUMBER AND SOME ARE DILATED OR CYSTIC.

FEMALE 191 (1716/80)

HEART

LEUKOCYTOSIS :
THERE IS AN INCREASE IN LEUKOCYTES.

LUNG

THROMBOSIS :
THE VASCULAR LUMEN CONTAINS AN ATTACHED ANTE MORTEM BLOOD CLOT.

ATELECTASIS :
THERE IS COLLAPSE OF ALVEOLI.

STOMACH

LEUKEMIC DEPOSITS :
ORGAN AND THE BLOOD ARE INVADED BY LEUKEMIC CELLS.

LIVER

LEUKEMIC DEPOSITS :
ORGAN AND THE BLOOD ARE INVADED BY LEUKEMIC CELLS.

SPLEEN

*** LYMPHOMA LYMPHOCYTIC :
THE NEOPLASM OF THE RETICULAR SYSTEM ORIGINATES FROM LYMPHOCYTES.

KIDNEYS

LEUKEMIC DEPOSITS :
ORGAN AND THE BLOOD ARE INVADED BY LEUKEMIC CELLS.

PITUITARY

ABSENT :
ORGAN OR TISSUE NOT REMOVED FROM ANIMAL OR NOT FOUND IN FIXATIVE.

THYROIDS

ABSENT :
ORGAN OR TISSUE NOT REMOVED FROM ANIMAL OR NOT FOUND IN FIXATIVE.

OVARIES

CYSTS :
BILATERAL
ONE OR MORE CYSTS FILLED WITH CLEAR LIQUID ARE SEEN.

LEUKEMIC DEPOSITS :
BILATERAL
ORGAN AND THE BLOOD ARE INVADED BY LEUKEMIC CELLS.

BAYER AG

FEMALE 192 (1744/80)

LUNG

THICKENED ALVEOLAR WALLS :
MULTIFOCAL
THICKNESS OF ALVEOLAR WALLS IS INCREASED BY INFLAMMATORY CELLS AND/OR INTERSTITIAL EDEMA.

STOMACH

MUCOID CYST :
MINIMAL
ONE OR MORE CYSTS CONTAINING MUCOID MATERIAL ARE OBSERVED.

LIVER

MONONUCLEAR CELLS :
MINIMAL MULTIFOCAL
FOCAL COLLECTIONS OF MONONUCLEAR CELLS ARE PRESENT.

PANCREAS

ATROPHY :
THE ORGAN IS REDUCED IN SIZE.

SPLEEN

HEMATOPOIESIS :
SEVERE
THE HEMATOPOIESIS IS EVIDENT.

KIDNEYS

PYELITIS :
BILATERAL SEVERE
INFLAMMATORY CELL INFILTRATION IN THE RENAL PELVIS IS PRESENT.

TUBULOPATHY :
BILATERAL SEVERE
TUBULAR DEGENERATIVE CHANGES ARE PRESENT
WHICH MAY BE ASSOCIATED WITH TUBULAR DILATATION.

AUTOLYSIS PARTIAL :
BILATERAL SEVERE
NO OTHER CHANGES ARE SEEN. TISSUES ARE ALTERED.
BY POST-MORTEM MODIFICATIONS AND
DIAGNOSIS IS GIVEN WITH RESERVATION.

BLADDER

AUTOLYSIS PARTIAL :
NO OTHER CHANGES ARE SEEN. TISSUES ARE ALTERED.
BY POST-MORTEM MODIFICATIONS AND

BLADDER CONTINUED
DIAGNOSIS IS GIVEN WITH RESERVATION.

THYROIDS

ABSENT :
ORGAN OR TISSUE NOT REMOVED FROM ANIMAL OR NOT FOUND IN FIXATIVE.

ADRENALS

PIGMENTATION :
UNILATERAL MINIMAL
NUMEROUS MACROPHAGES CONTAIN A GRANULAR BROWN CYTOPLASMIC PIGMENT.

OVARIES

ATROPHY :
BILATERAL
THE ORGAN IS REDUCED IN SIZE.

UTERUS

CYSTIC ENDOMETRIAL HYPERPLASIA :
SEVERE
THE ENDOMETRIAL GLANDS ARE INCREASED IN NUMBER AND SOME ARE DILATED OR CYSTIC.

ENDOMETRITIS :
SEVERE
ACUTE OR SUBACUTE INFLAMMATION IS SEEN IN ENDOMETRIUM.

CERVIX

*** KERATOACANTHOMA :
THERE IS A BENIGN TUMOR OF THE SQUAMOUS EPITHELIUM.
CONSIDERABLE PRODUCTION OF KERATIN IS SEEN.

FEMALE 193 (1711/80)

HEART

CONGESTION :
SEVERE
VESSELS OR SINUSOIDS ARE MARKEDLY DISTENDED WITH ERYTHROCYTES.

LUNG

EDEMA :
SEVERE
THE INTERSTITIAL TISSUES CONTAIN AN INCREASED AMOUNT OF FLUID.

CONGESTION :
SEVERE

BAYER AG

LUNG CONTINUED

VESSELS OR SINUSOIDS ARE MARKEDLY DISTENDED WITH ERYTHROCYTES.

EMPHYSEMA :
SEVERE
THERE IS A EMPHYSEMATOUS CHANGE IN THE ALVEOLAR WALLS.

STOMACH

AUTOLYSIS PARTIAL :
NO OTHER CHANGES ARE SEEN. TISSUES ARE ALTERED.
BY POST-MORTEM MODIFICATIONS AND
DIAGNOSIS IS GIVEN WITH RESERVATION.

LIVER

CONGESTION :
VESSELS OR SINUSOIDS ARE MARKEDLY DISTENDED WITH ERYTHROCYTES.

AUTOLYSIS PARTIAL :
NO OTHER CHANGES ARE SEEN. TISSUES ARE ALTERED.
BY POST-MORTEM MODIFICATIONS AND
DIAGNOSIS IS GIVEN WITH RESERVATION.

PANCREAS

LEUKEMIC DEPOSITS :
ORGAN AND THE BLOOD ARE INVADED BY LEUKEMIC CELLS.

SPLEEN

*** LYMPHOMA LYMPHOCYTIC :
THE NEOPLASM OF THE RETICULAR SYSTEM ORIGINATES FROM LYMPHOCYTES.

AUTOLYSIS PARTIAL :
NO OTHER CHANGES ARE SEEN. TISSUES ARE ALTERED.
BY POST-MORTEM MODIFICATIONS AND
DIAGNOSIS IS GIVEN WITH RESERVATION.

KIDNEYS

LEUKEMIC DEPOSITS :
ORGAN AND THE BLOOD ARE INVADED BY LEUKEMIC CELLS.

BLADDER

LEUKEMIC DEPOSITS :
ORGAN AND THE BLOOD ARE INVADED BY LEUKEMIC CELLS.

PITUITARY

ABSENT :
ORGAN OR TISSUE NOT REMOVED FROM ANIMAL OR NOT FOUND IN FIXATIVE.

THYROIDS

AUTOLYSIS PARTIAL :
NO OTHER CHANGES ARE SEEN. TISSUES ARE ALTERED.
BY POST-MORTEM MODIFICATIONS AND
DIAGNOSIS IS GIVEN WITH RESERVATION.

ADRENALS

LEUKEMIC DEPOSITS :
ORGAN AND THE BLOOD ARE INVADED BY LEUKEMIC
CELLS.

SKELETAL MUSCLE

LEUKEMIC DEPOSITS :
ORGAN AND THE BLOOD ARE INVADED BY LEUKEMIC
CELLS.

MESENTERY

STEATONECROSIS :
FAT TISSUE IS NECROTIC AND SURROUNDED BY INFLAMMATORY AND
GIANT CELL REACTION.

LEUKEMIC DEPOSITS :
ORGAN AND THE BLOOD ARE INVADED BY LEUKEMIC
CELLS.

OVARIES

LEUKEMIC DEPOSITS :
ORGAN AND THE BLOOD ARE INVADED BY LEUKEMIC
CELLS.

AUTOLYSIS PARTIAL :
NO OTHER CHANGES ARE SEEN. TISSUES ARE ALTERED.
BY POST-MORTEM MODIFICATIONS AND
DIAGNOSIS IS GIVEN WITH RESERVATION.

UTERUS

LEUKEMIC DEPOSITS :
ORGAN AND THE BLOOD ARE INVADED BY LEUKEMIC
CELLS.

FEMALE 195 (1717/80)

STOMACH

NORMAL :
HISTOLOGICAL ASPECT WITHIN NORMAL LIMITS.

BAYER AG

PANCREAS

ATROPHY :
THE ORGAN IS REDUCED IN SIZE.

KIDNEYS

DILATATION OF GLOMERULAR LOOPS :
BILATERAL MINIMAL
GLOMERULAR LOOPS APPEAR UNUSUALLY ENLARGED AND THIN.

PITUITARY

ABSENT :
ORGAN OR TISSUE NOT REMOVED FROM ANIMAL OR NOT FOUND IN FIXATIVE.

ADRENALS

PIGMENTATION :
MODERATE
NUMEROUS MACROPHAGES CONTAIN A GRANULAR BROWN CYTOPLASMIC PIGMENT.

SKELETAL MUSCLE

ABSENT :
ORGAN OR TISSUE NOT REMOVED FROM ANIMAL OR NOT FOUND IN FIXATIVE.

SCIATIC NERVE

ABSENT :
ORGAN OR TISSUE NOT REMOVED FROM ANIMAL OR NOT FOUND IN FIXATIVE.

OVARIES

CYSTS :
UNILATERAL
ONE OR MORE CYSTS FILLED WITH CLEAR LIQUID ARE SEEN.

UTERUS

CYSTIC ENDOMETRIAL HYPERPLASIA :
SEVERE
THE ENDOMETRIAL GLANDS ARE INCREASED IN NUMBER AND SOME ARE DILATED OR CYSTIC.

FEMUR

ABSENT :
ORGAN OR TISSUE NOT REMOVED FROM ANIMAL OR NOT FOUND IN FIXATIVE.

FEMALE 200 (1681/80)

BRAIN

ABSENT :
ORGAN OR TISSUE NOT REMOVED FROM ANIMAL OR NOT FOUND IN FIXATIVE.

LUNG

LEUKEMIC DEPOSITS :
ORGAN AND THE BLOOD ARE INVADED BY LEUKEMIC CELLS.

AUTOLYSIS PARTIAL :
NO OTHER CHANGES ARE SEEN. TISSUES ARE ALTERED. BY POST-MORTEM MODIFICATIONS AND DIAGNOSIS IS GIVEN WITH RESERVATION.

STOMACH

AUTOLYSIS :
THE TISSUES EXHIBIT AUTOLYSIS AND THEY ARE NOT INTERPRETABLE.

LIVER

AUTOLYSIS :
THE TISSUES EXHIBIT AUTOLYSIS AND THEY ARE NOT INTERPRETABLE.

PANCREAS

AUTOLYSIS :
THE TISSUES EXHIBIT AUTOLYSIS AND THEY ARE NOT INTERPRETABLE.

THYMUS

*** LYMPHOMA LYMPHOCYTIC :
THE NEOPLASM OF THE RETICULAR SYSTEM ORIGINATES FROM LYMPHOCYTES.

SPLEEN

AUTOLYSIS :
THE TISSUES EXHIBIT AUTOLYSIS AND THEY ARE NOT INTERPRETABLE.

KIDNEYS

AUTOLYSIS :
THE TISSUES EXHIBIT AUTOLYSIS AND THEY ARE NOT INTERPRETABLE.

BLADDER

AUTOLYSIS :
THE TISSUES EXHIBIT AUTOLYSIS AND THEY ARE NOT INTERPRETABLE.

THYROIDS

LEUKEMIC DEPOSITS :

BAYER AG

THYROIDS CONTINUED

ORGAN AND THE BLOOD ARE INVADED BY LEUKEMIC CELLS.

ADRENALS

AUTOLYSIS PARTIAL :
NO OTHER CHANGES ARE SEEN. TISSUES ARE ALTERED. BY POST-MORTEM MODIFICATIONS AND DIAGNOSIS IS GIVEN WITH RESERVATION.

OVARIES

AUTOLYSIS :
THE TISSUES EXHIBIT AUTOLYSIS AND THEY ARE NOT INTERPRETABLE.

SF2. 1 CHRONIC TOXICITY STUDY IN MICE: SYSTEMATIC HISTOPATHOLOGY

PRODUCT : KWG 0519 GROUP : 2
ROUTE : DIETARY
TIME : 105 WEEKS DOSE : 500 PPM
THIS GROUP COMPRISED : 17 FEMALES

THE FOLLOWING ORGANS WERE EXAMINED SYSTEMATICALLY :

HEART	LUNG	LIVER
PANCREAS	SPLEEN	KIDNEYS
BLADDER	STOMACH	OVARIES
THYROIDS	ADRENALS	PITUITARY
BRAIN	SKELETAL MUSCLE	SCIATIC NERVE
FEMUR		

THESE ORGANS WERE EXAMINED IN 17 FEMALES

INDIVIDUAL RESULTS

IN THE ANIMALS SHOWN BELOW THE HISTOLOGICAL EXAMINATION OF THE ORGANS LISTED OR OF THE ANOMALIES FOUND AT AUTOPSY GAVE THE FOLLOWING RESULTS :

FEMALE 253 (1535/80)

BRAIN

GLIOSIS :
FOCAL
THERE IS PROLIFERATION OF GLIAL CELLS.

LUNG

ATELECTASIS :
MODERATE
THERE IS COLLAPSE OF ALVEOLI.

THICKENED ALVEOLAR WALLS :
MODERATE
THICKNESS OF ALVEOLAR WALLS IS INCREASED BY INFLAMMATORY CELLS AND/OR INTERSTITIAL EDEMA.

SPLEEN

HEMATOPOIESIS :
MODERATE
THE HEMATOPOIESIS IS EVIDENT.

KIDNEYS

INTERSTITIAL NEPHRITIS :
BILATERAL FOCAL
INFLAMMATORY CELLS FIBROSIS AND SOME TUBULAR ALTERATIONS ARE ASSOCIATED.

BAYER AG

ADRENALS

PIGMENTATION :
BILATERAL MINIMAL
NUMEROUS MACROPHAGES CONTAIN A GRANULAR BROWN CYTOPLASMIC PIGMENT.

OVARIES

ATROPHY :
BILATERAL
THE ORGAN IS REDUCED IN SIZE.

CYSTS :
UNILATERAL
ONE OR MORE CYSTS FILLED WITH CLEAR LIQUID ARE SEEN.

UTERUS

THROMBOSIS :
UNILATERAL SEVERE
THE VASCULAR LUMEN CONTAINS AN ATTACHED ANTE MORTEM BLOOD CLOT.

HEMORRHAGE :
UNILATERAL SEVERE
THERE IS EXTRAVASATION OF BLOOD.

CYSTIC ENDOMETRIAL HYPERPLASIA :
UNILATERAL SEVERE
THE ENDOMETRIAL GLANDS ARE INCREASED IN NUMBER AND SOME ARE DILATED OR CYSTIC.

HYPERPLASIA SECRETORY :
CONTRALATERAL SEVERE
THE DEVELOPED GLANDS AND/OR DUCTS CONTAIN A SECRETION

FEMALE 258 (1536/80)

LUNG

PNEUMONIA :
MINIMAL
THE ALVEOLAR WALLS ARE THICKENED AND ALVEOLI CONTAIN INFLAMMATORY CELLS AND FOAMY MACROPHAGES.PERIVASCULAR AND PERIBRONCHIAL LYMPHOCYTIC ACCUMULATIONS MAY BE PRESENT.

STOMACH

MUCOID CYST :
MINIMAL
ONE OR MORE CYSTS CONTAINING MUCOID MATERIAL ARE OBSERVED.

LIVER

VACUOLIZATION :
MINIMAL
IN THESE CELLS THERE ARE CLEAR VACUOLES GREATER IN NUMBER AND SIZE THAN NORMALLY FOUND.

SPLEEN

HEMATOPOIESIS :
MINIMAL
THE HEMATOPOIESIS IS EVIDENT.

KIDNEYS

CYSTS :
UNILATERAL
ONE OR MORE CYSTS FILLED WITH CLEAR LIQUID ARE SEEN.

PROGRESSIVE NEPHROPATHY :
UNILATERAL MINIMAL
AN AGE ASSOCIATED KIDNEY LESION CONSISTING OF CYSTIC TUBULES WITH COLLOID OR HYALINE CASTS CHRONIC INTERSTITIAL NEPHRITIS AND DILATATION OF BOWMAN'S CAPSULE WITH GLOMERULAR DEGENERATION .

THYROIDS

CYSTS :
UNILATERAL
ONE OR MORE CYSTS FILLED WITH CLEAR LIQUID ARE SEEN.

ADRENALS

PIGMENTATION :
MINIMAL
NUMEROUS MACROPHAGES CONTAIN A GRANULAR BROWN CYTOPLASMIC PIGMENT.

OVARIES

*** LUTEOMA :
UNILATERAL
IT IS A BENIGN TUMOR COMPOSED OF CELLS RESEMBLING THOSE OF THE CORPUS LUTEUM.

HYPERTROPHIC CORPORA LUTEA :
CONTRALATERAL
ALL CORPORA LUTEA ARE IMPORTANT IN SIZE. THEY CONTAIN LARGE LUTEAL CELLS WITH ACIDOPHILIC CYTOPLASM.

BAYER AG

FEMALE 263 (1537/80)

LUNG

ATELECTASIS :
MODERATE MULTIFOCAL
THERE IS COLLAPSE OF ALVEOLI.

STOMACH

MUCOID CYST :
MINIMAL
ONE OR MORE CYSTS CONTAINING MUCOID MATERIAL ARE OBSERVED.

LIVER

MONONUCLEAR CELLS :
MINIMAL FOCAL
FOCAL COLLECTIONS OF MONONUCLEAR CELLS ARE PRESENT.

SPLEEN

HEMATOPOIESIS :
MINIMAL
THE HEMATOPOIESIS IS EVIDENT.

THYROIDS

ABSENT :
ORGAN OR TISSUE NOT REMOVED FROM ANIMAL OR NOT FOUND IN FIXATIVE.

ADRENALS

PIGMENTATION :
MODERATE
NUMEROUS MACROPHAGES CONTAIN A GRANULAR BROWN CYTOPLASMIC PIGMENT.

OVARIES

NORMAL :
HISTOLOGICAL ASPECT WITHIN NORMAL LIMITS.

UTERUS

ENDOMETRIOSIS :
UNILATERAL SEVERE
ENDOMETRIAL GLANDS ARE SEEN AT VARIOUS SITES OUTSIDE THE NORMAL ENDOMETRIUM.

HEMORRAGIC CYST :
UNILATERAL
ONE OR SEVERAL CAVITIES FILLED WITH BLOOD.

FEMUR

UNREADABLE :
IT IS NOT POSSIBLE TO INTERPRET THE SECTION DUE TO AN ARTIFACT CAUSED BY SAMPLING OR HISTOLOGICAL TECHNIQUE.

FEMALE 266 (1538/80)

LUNG

LEUKEMIC DEPOSITS :
ORGAN AND THE BLOOD ARE INVADED BY LEUKEMIC CELLS.

LIVER

*** ADENOMA HEPATIC BENIGN :
DISTINCT NODULES COMPRESS THE ADJACENT LIVER PARENCHYMA, ARE CHARACTERIZED BY WELL DIFFERENTIATED HEPATOCYTES AND DO NOT SHOW PORTAL TRIADS.

LEUKEMIC DEPOSITS :
ORGAN AND THE BLOOD ARE INVADED BY LEUKEMIC CELLS.

PANCREAS

LEUKEMIC DEPOSITS :
ORGAN AND THE BLOOD ARE INVADED BY LEUKEMIC CELLS.

SPLEEN

*** LYMPHOMA LYMPHOCYTIC :
THE NEOPLASM OF THE RETICULAR SYSTEM ORIGINATES FROM LYMPHOCYTES.

KIDNEYS

LEUKEMIC DEPOSITS :
ORGAN AND THE BLOOD ARE INVADED BY LEUKEMIC CELLS.

THYROIDS

ABSENT :
ORGAN OR TISSUE NOT REMOVED FROM ANIMAL OR NOT FOUND IN FIXATIVE.

ADRENALS

PIGMENTATION :
MINIMAL
NUMEROUS MACROPHAGES CONTAIN A GRANULAR BROWN CYTOPLASMIC PIGMENT.

OVARIES

ATROPHY :
UNILATERAL
THE ORGAN IS REDUCED IN SIZE.

CYSTS :
UNILATERAL

BAYER AG

FEMALE 266 CONTINUED 439

OVARIES CONTINUED

ONE OR MORE CYSTS FILLED WITH CLEAR LIQUID ARE SEEN.

UTERUS

HYPERPLASIA SECRETORY :
UNILATERAL
THE DEVELOPED GLANDS AND/OR DUCTS CONTAIN A SECRETION

LYMPH NODE

ABSENT :
ORGAN OR TISSUE NOT REMOVED FROM ANIMAL OR NOT FOUND IN FIXATIVE.

FEMALE 267 (1539/80)

LUNG

PNEUMONIA :
MULTIFOCAL
THE ALVEOLAR WALLS ARE THICKENED AND ALVEOLI CONTAIN INFLAMMATORY CELLS AND FOAMY MACROPHAGES.PERIVASCULAR AND PERIBRONCHIAL LYMPHOCYTIC ACCUMULATIONS MAY BE PRESENT.

LIVER

PIGMENTATION :
MODERATE
NUMEROUS MACROPHAGES CONTAIN A GRANULAR BROWN CYTOPLASMIC PIGMENT.

*** ANGIOSARCOMA :
MALIGNANT MESENCHYMAL TUMOR OF VASCULAR ORIGIN OR SHOWING VASCULAR DIFFERENTIATION.

PANCREAS

INFLAMMATION CHRONIC :
FOCAL
THE INTERSTITIAL TISSUES SHOW INFILTRATION BY MONONUCLEAR CELLS AND INCREASE IN FIBROUS STROMA.

SPLEEN

HEMATOPOIESIS :
SEVERE
THE HEMATOPOIESIS IS EVIDENT.

KIDNEYS

INTERSTITIAL NEPHRITIS :
BILATERAL FOCAL
INFLAMMATORY CELLS FIBROSIS AND SOME TUBULAR ALTERATIONS

KIDNEYS CONTINUED
ARE ASSOCIATED.

BLADDER

INFLAMMATION CHRONIC :
THERE IS AN INFILTRATION BY MONONUCLEAR CELLS IN THE MUCOSA AND SUBMUCOSA.

THYROIDS

ABSENT :
ORGAN OR TISSUE NOT REMOVED FROM ANIMAL OR NOT FOUND IN FIXATIVE.

ADRENALS

PIGMENTATION :
MODERATE
NUMEROUS MACROPHAGES CONTAIN A GRANULAR BROWN CYTOPLASMIC PIGMENT.

OVARIES

ATROPHY :
BILATERAL
THE ORGAN IS REDUCED IN SIZE.

CYSTS :
UNILATERAL
ONE OR MORE CYSTS FILLED WITH CLEAR LIQUID ARE SEEN.

UTERUS

HYPERPLASIA SECRETORY :
BILATERAL
THE DEVELOPED GLANDS AND/OR DUCTS CONTAIN A SECRETION

FEMALE 268 (1546/80)

BRAIN

GLIOSIS :
MINIMAL MULTIFOCAL
THERE IS PROLIFERATION OF GLIAL CELLS.

LUNG

PNEUMONIA :
MULTIFOCAL
THE ALVEOLAR WALLS ARE THICKENED AND ALVEOLI CONTAIN INFLAMMATORY CELLS AND FOAMY MACROPHAGES.PERIVASCULAR AND PERIBRONCHIAL LYMPHOCYTIC ACCUMULATIONS MAY BE PRESENT.

BAYER AG

LIVER

VACUOLIZATION :
MODERATE
IN THESE CELLS THERE ARE CLEAR VACUOLES GREATER IN NUMBER AND SIZE THAN NORMALLY FOUND.

SPLEEN

HEMATOPOIESIS :
MODERATE
THE HEMATOPOIESIS IS EVIDENT.

KIDNEYS

CYSTS :
UNILATERAL FOCAL
ONE OR MORE CYSTS FILLED WITH CLEAR LIQUID ARE SEEN.

PITUITARY

ABSENT :
ORGAN OR TISSUE NOT REMOVED FROM ANIMAL OR NOT FOUND IN FIXATIVE.

SCIATIC NERVE

ABSENT :
ORGAN OR TISSUE NOT REMOVED FROM ANIMAL OR NOT FOUND IN FIXATIVE.

MESENTERY

INFLAMMATION CHRONIC :
THE INTERSTITIAL TISSUES SHOW INFILTRATION BY MONONUCLEAR CELLS AND INCREASE IN FIBROUS STROMA.

OVARIES

CYSTS :
UNILATERAL
ONE OR MORE CYSTS FILLED WITH CLEAR LIQUID ARE SEEN.

HYPERTROPHIC CORPORA LUTEA :
BILATERAL
ALL CORPORA LUTEA ARE IMPORTANT IN SIZE. THEY CONTAIN LARGE LUTEAL CELLS WITH ACIDOPHILIC CYTOPLASM.

FEMALE 270 (1541/80)

LUNG

PNEUMONIA :
FOCAL
THE ALVEOLAR WALLS ARE THICKENED AND ALVEOLI CONTAIN

LUNG CONTINUED

INFLAMMATORY CELLS AND FOAMY MACROPHAGES.PERIVASCULAR AND PERIBRONCHIAL LYMPHOCYTIC ACCUMULATIONS MAY BE PRESENT.

*** ALVEOLOGENIC CARCINOMA :
A MALIGNANT TUMOR OF THE LUNG TISSUE WITH SYNONYMS IN MICE FOR ADENOMA, CARCINOMA, ALVEOLOGENIC PAPILLARY CARCINOMA, PAPILLARY CYSTADENOMA, ADENOCARCINOMA, BRONCHIOLAR CELL CARCINOMA, BRONCHIOLAR-ALVEOLAR TUMOR, TYPE A TUMOR, TYPE B TUMOR, INTERMEDIATE TYPE I TUMOR AND COMMON PULMONARY TUMOR OF THE MOUSE.

LIVER

VACUOLIZATION :
MINIMAL
IN THESE CELLS THERE ARE CLEAR VACUOLES GREATER IN NUMBER AND SIZE THAN NORMALLY FOUND.

SPLEEN

HEMATOPOIESIS :
MODERATE
THE HEMATOPOIESIS IS EVIDENT.

KIDNEYS

INTERSTITIAL NEPHRITIS :
BILATERAL MINIMAL MULTIFOCAL
INFLAMMATORY CELLS FIBROSIS AND SOME TUBULAR ALTERATIONS ARE ASSOCIATED.

OVARIES

ATROPHY :
BILATERAL
THE ORGAN IS REDUCED IN SIZE.

HEMORRAGIC CYST :
UNILATERAL
ONE OR SEVERAL CAVITIES FILLED WITH BLOOD.

UTERUS

ENDOMETRIOSIS :
UNILATERAL
ENDOMETRIAL GLANDS ARE SEEN AT VARIOUS SITES OUTSIDE THE NORMAL ENDOMETRIUM.

BAYER AG BAYER AG BAYER AG

FEMALE 271 (1542/80)

LUNG

PNEUMONIA :
THE ALVEOLAR WALLS ARE THICKENED AND ALVEOLI CONTAIN INFLAMMATORY CELLS AND FOAMY MACROPHAGES.PERIVASCULAR AND PERIBRONCHIAL LYMPHOCYTIC ACCUMULATIONS MAY BE PRESENT.

LIVER

*** ADENOMA HEPATIC BENIGN :
DISTINCT NODULES COMPRESS THE ADJACENT LIVER PARENCHYMA, ARE CHARACTERIZED BY WELL DIFFERENTIATED HEPATOCYTES AND DO NOT SHOW PORTAL TRIADS.

VACUOLIZATION :
IN THESE CELLS THERE ARE CLEAR VACUOLES GREATER IN NUMBER AND SIZE THAN NORMALLY FOUND.

SPLEEN

HEMATOPOIESIS :
MODERATE
THE HEMATOPOIESIS IS EVIDENT.

OVARIES

CYSTS :
UNILATERAL
ONE OR MORE CYSTS FILLED WITH CLEAR LIQUID ARE SEEN.

UTERUS

ABSENT :
ORGAN OR TISSUE NOT REMOVED FROM ANIMAL OR NOT FOUND IN FIXATIVE.

FEMUR

HYPOPLASIA :
MARROW CELLS ARE REDUCED IN NUMBER AND SINUSES ARE SLIGHTLY CONGESTED.

FEMALE 272 (1543/80)

BRAIN

MENINGITIS :
MINIMAL FOCAL
CHRONIC INFLAMMATION OF THE MENINGES.

LUNG

PNEUMONIA :
THE ALVEOLAR WALLS ARE THICKENED AND ALVEOLI CONTAIN INFLAMMATORY CELLS AND FOAMY MACROPHAGES.PERIVASCULAR AND

LUNG CONTINUED

PERIBRONCHIAL LYMPHOCYTIC ACCUMULATIONS MAY BE PRESENT.

STOMACH

MUCOID CYST :
MINIMAL
ONE OR MORE CYSTS CONTAINING MUCOID MATERIAL ARE OBSERVED.

SPLEEN

HEMATOPOIESIS :
MODERATE
THE HEMATOPOIESIS IS EVIDENT.

KIDNEYS

TUBULOPATHY :
UNILATERAL
TUBULAR DEGENERATIVE CHANGES ARE PRESENT WHICH MAY BE ASSOCIATED WITH TUBULAR DILATATION.

INTERSTITIAL NEPHRITIS :
BILATERAL MINIMAL
INFLAMMATORY CELLS FIBROSIS AND SOME TUBULAR ALTERATIONS ARE ASSOCIATED.

MESENTERY

INFLAMMATION CHRONIC :
THE INTERSTITIAL TISSUES SHOW INFILTRATION BY MONONUCLEAR CELLS AND INCREASE IN FIBROUS STROMA.

OVARIES

ATROPHY :
UNILATERAL
THE ORGAN IS REDUCED IN SIZE.

CYSTS :
UNILATERAL
ONE OR MORE CYSTS FILLED WITH CLEAR LIQUID ARE SEEN.

UTERUS

CYSTIC ENDOMETRIAL HYPERPLASIA :
CONTRALATERAL SEVERE
THE ENDOMETRIAL GLANDS ARE INCREASED IN NUMBER AND SOME ARE DILATED OR CYSTIC.

*** LEIOMYOSARCOMA :
UNILATERAL
MALIGNANT TUMOR DERIVED FROM SMOOTH MUSCLE FIBERS.

BAYER AG BAYER AG BAYER AG

FEMALE 273 (1544/80)

LUNG

HEMORRHAGE :
THERE IS EXTRAVASATION OF BLOOD.

PNEUMONIA :
THE ALVEOLAR WALLS ARE THICKENED AND ALVEOLI CONTAIN INFLAMMATORY CELLS AND FOAMY MACROPHAGES.PERIVASCULAR AND PERIBRONCHIAL LYMPHOCYTIC ACCUMULATIONS MAY BE PRESENT.

SPLEEN

HEMATOPOIESIS :
MODERATE
THE HEMATOPOIESIS IS EVIDENT.

BLADDER

HYPERPLASIA PAPILLOMATOUS :
THE THICKNESS OF THE MUCOSA IS INCREASED MAKING UNUSUALLY HIGH AND NUMEROUS FOLDS.

ADRENALS

PIGMENTATION :
UNILATERAL SEVERE
NUMEROUS MACROPHAGES CONTAIN A GRANULAR BROWN CYTOPLASMIC PIGMENT.

OVARIES

ATROPHY :
BILATERAL
THE ORGAN IS REDUCED IN SIZE.

CYSTS :
UNILATERAL
ONE OR MORE CYSTS FILLED WITH CLEAR LIQUID ARE SEEN.

UTERUS

ENDOMETRIOSIS :
MODERATE
ENDOMETRIAL GLANDS ARE SEEN AT VARIOUS SITES OUTSIDE THE NORMAL ENDOMETRIUM.

FEMALE 276 (1545/80)

LUNG

PNEUMONIA :
THE ALVEOLAR WALLS ARE THICKENED AND ALVEOLI CONTAIN INFLAMMATORY CELLS AND FOAMY MACROPHAGES.PERIVASCULAR AND PERIBRONCHIAL LYMPHOCYTIC ACCUMULATIONS MAY BE PRESENT.

SPLEEN

HEMATOPOIESIS :
MINIMAL
THE HEMATOPOIESIS IS EVIDENT.

KIDNEYS

INTERSTITIAL NEPHRITIS :
BILATERAL MINIMAL MULTIFOCAL
INFLAMMATORY CELLS FIBROSIS AND SOME TUBULAR ALTERATIONS ARE ASSOCIATED.

THYROIDS

ABSENT :
ORGAN OR TISSUE NOT REMOVED FROM ANIMAL OR NOT FOUND IN FIXATIVE.

OVARIES

ATROPHY :
BILATERAL
THE ORGAN IS REDUCED IN SIZE.

UTERUS

ENDOMETRIOSIS :
BILATERAL
ENDOMETRIAL GLANDS ARE SEEN AT VARIOUS SITES OUTSIDE THE NORMAL ENDOMETRIUM.

FEMALE 279 (1546/80 B)

BRAIN

FAT VACUOLES :
FOCAL
THE CELLS ARE DISTENDED BY CLEAR CYTOPLASMIC VACUOLES WHICH FREQUENTLY DISPLACE THE NUCLEI.

LUNG

*** ALVEOLOGENIC CARCINOMA :
A MALIGNANT TUMOR OF THE LUNG TISSUE WITH SYNONYMS IN MICE FOR ADENOMA, CARCINOMA, ALVEOLOGENIC PAPILLARY CARCINOMA, PAPILLARY CYSTADENOMA, ADENOCARCINOMA, BRONCHIOLAR CELL CARCINOMA, BRONCHIOLAR-ALVEOLAR TUMOR, TYPE A TUMOR, TYPE B TUMOR, INTERMEDIATE TYPE I TUMOR AND COMMON PULMONARY TUMOR OF THE MOUSE.

BAYER AG

STOMACH

MUCOID CYST :
MODERATE
ONE OR MORE CYSTS CONTAINING MUCOID MATERIAL ARE OBSERVED.

PANCREAS

PERIARTERITIS :
NON SPECIFIC INFLAMMATION (ACUTE SUBACUTE OR CHRONIC) OF THE TUNICA ADVENTITIA (PERIVASCULAR GRANULOMA).

SPLEEN

HEMATOPOIESIS :
MODERATE
THE HEMATOPOIESIS IS EVIDENT.

BLADDER

INFLAMMATION CHRONIC :
MODERATE
THERE IS AN INFILTRATION BY MONONUCLEAR CELLS IN THE MUCOSA AND SUBMUCOSA.

THYROIDS

ABSENT :
ORGAN OR TISSUE NOT REMOVED FROM ANIMAL OR NOT FOUND IN FIXATIVE.

OVARIES

HEMORRAGIC CYST :
UNILATERAL
ONE OR SEVERAL CAVITIES FILLED WITH BLOOD.

UTERUS

ENDOMETRIOSIS :
UNILATERAL
ENDOMETRIAL GLANDS ARE SEEN AT VARIOUS SITES OUTSIDE THE NORMAL ENDOMETRIUM.

HYPERPLASIA SECRETORY :
UNILATERAL
THE DEVELOPED GLANDS AND/OR DUCTS CONTAIN A SECRETION

FEMALE 281 (1547/80)

LUNG

THICKENED ALVEOLAR WALLS :
FOCAL

LUNG CONTINUED

THICKNESS OF ALVEOLAR WALLS IS INCREASED BY INFLAMMATORY CELLS AND/OR INTERSTITIAL EDEMA.

SPLEEN

HEMATOPOIESIS :
MINIMAL
THE HEMATOPOIESIS IS EVIDENT.

KIDNEYS

INTERSTITIAL NEPHRITIS :
UNILATERAL FOCAL
INFLAMMATORY CELLS FIBROSIS AND SOME TUBULAR ALTERATIONS ARE ASSOCIATED.

PITUITARY

ABSENT :
ORGAN OR TISSUE NOT REMOVED FROM ANIMAL OR NOT FOUND IN FIXATIVE.

ADRENALS

PIGMENTATION :
MINIMAL
NUMEROUS MACROPHAGES CONTAIN A GRANULAR BROWN CYTOPLASMIC PIGMENT.

OVARIES

HYPERTROPHIC CORPORA LUTEA :
BILATERAL
ALL CORPORA LUTEA ARE IMPORTANT IN SIZE. THEY CONTAIN LARGE LUTEAL CELLS WITH ACIDOPHILIC CYTOPLASM.

UTERUS

CYSTIC ENDOMETRIAL HYPERPLASIA :
BILATERAL SEVERE
THE ENDOMETRIAL GLANDS ARE INCREASED IN NUMBER AND SOME ARE DILATED OR CYSTIC.

ENDOMETRIOSIS :
BILATERAL SEVERE
ENDOMETRIAL GLANDS ARE SEEN AT VARIOUS SITES OUTSIDE THE NORMAL ENDOMETRIUM.

FEMALE 291 (1548/60)

LUNG

ATELECTASIS :
MULTIFOCAL

BAYER AG

LUNG CONTINUED

THERE IS COLLAPSE OF ALVEOLI.

SPLEEN

*** LYMPHOMA LYMPHOLYTIC :
THE NEOPLASM OF THE RETICULAR SYSTEM ORIGINATES FROM LYMPHOCYTES.

KIDNEYS

CYSTS :
UNILATERAL MINIMAL FOCAL
ONE OR MORE CYSTS FILLED WITH CLEAR LIQUID ARE SEEN.

BLADDER

LEUKEMIC DEPOSITS :
ORGAN AND THE BLOOD ARE INVADED BY LEUKEMIC CELLS.

THYROIDS

ABSENT :
ORGAN OR TISSUE NOT REMOVED FROM ANIMAL OR NOT FOUND IN FIXATIVE.

ADRENALS

PIGMENTATION :
UNILATERAL MINIMAL
NUMEROUS MACROPHAGES CONTAIN A GRANULAR BROWN CYTOPLASMIC PIGMENT.

HYPERPLASIA OF THE GLOMERULAR LAYER :
UNILATERAL MODERATE
THE GLOMERULAR LAYER IS THICKER THAN NORMAL.

OVARIES

CYSTS :
UNILATERAL
ONE OR MORE CYSTS FILLED WITH CLEAR LIQUID ARE SEEN.

LYMPH NODE

HYPERTROPHY :
THE SIZE OF THE ORGAN IS INCREASED WITHOUT STRUCTURAL ANOMALY.

FEMALE 295 (1549/60)

LUNG

PNEUMONIA :

LUNG CONTINUED

THE ALVEOLAR WALLS ARE THICKENED AND ALVEOLI CONTAIN INFLAMMATORY CELLS AND FOAMY MACROPHAGES.PERIVASCULAR AND PERIBRONCHIAL LYMPHOCYTIC ACCUMULATIONS MAY BE PRESENT.

LIVER

VACUOLIZATION :
MINIMAL
IN THESE CELLS THERE ARE CLEAR VACUOLES GREATER IN NUMBER AND SIZE THAN NORMALLY FOUND.

SPLEEN

HEMATOPOIESIS :
MODERATE
THE HEMATOPOIESIS IS EVIDENT.

THYROIDS

ABSENT :
ORGAN OR TISSUE NOT REMOVED FROM ANIMAL OR NOT FOUND IN FIXATIVE.

SCIATIC NERVE

ABSENT :
ORGAN OR TISSUE NOT REMOVED FROM ANIMAL OR NOT FOUND IN FIXATIVE.

OVARIES

CYSTS :
UNILATERAL
ONE OR MORE CYSTS FILLED WITH CLEAR LIQUID ARE SEEN.

UTERUS

CYSTIC ENDOMETRIAL HYPERPLASIA :
UNILATERAL
THE ENDOMETRIAL GLANDS ARE INCREASED IN NUMBER AND SOME ARE DILATED OR CYSTIC.

FEMALE 296 (1550/80)

LUNG

PNEUMONIA :
THE ALVEOLAR WALLS ARE THICKENED AND ALVEOLI CONTAIN INFLAMMATORY CELLS AND FOAMY MACROPHAGES.PERIVASCULAR AND PERIBRONCHIAL LYMPHOCYTIC ACCUMULATIONS MAY BE PRESENT.

*** ALVEOLOGENIC CARCINOMA :
A MALIGNANT TUMOR OF THE LUNG TISSUE WITH SYNONYMS IN MICE FOR ADENOMA, CARCINOMA,

BAYER AG

LUNG CONTINUED

ALVEOLOGENIC PAPILLARY CARCINOMA, PAPILLARY CYSTADENOMA, ADENOCARCINOMA, BRONCHIOLAR CELL CARCINOMA, BRONCHIOLAR-ALVEOLAR TUMOR, TYPE A TUMOR, TYPE B TUMOR, INTERMEDIATE TYPE I TUMOR AND COMMON PULMONARY TUMOR OF THE MOUSE.

SPLEEN

HEMATOPOIESIS :
MODERATE
THE HEMATOPOIESIS IS EVIDENT.

KIDNEYS

CYSTS :
UNILATERAL MINIMAL
ONE OR MORE CYSTS FILLED WITH CLEAR LIQUID ARE SEEN.

THYROIDS

ABSENT :
ORGAN OR TISSUE NOT REMOVED FROM ANIMAL OR NOT FOUND IN FIXATIVE.

ADRENALS

FAT VACUOLES :
UNILATERAL
THE CELLS ARE DISTENDED BY CLEAR CYTOPLASMIC VACUOLES WHICH FREQUENTLY DISPLACE THE NUCLEI.

PIGMENTATION :
BILATERAL SEVERE
NUMEROUS MACROPHAGES CONTAIN A GRANULAR BROWN CYTOPLASMIC PIGMENT.

OVARIES

*** LUTEOMA :
UNILATERAL
IT IS A BENIGN TUMOR COMPOSED OF CELLS RESEMBLING THOSE OF THE CORPUS LUTEUM.

CYSTS :
CONTRALATERAL
ONE OR MORE CYSTS FILLED WITH CLEAR LIQUID ARE SEEN.

UTERUS

CYSTIC ENDOMETRIAL HYPERPLASIA :
BILATERAL SEVERE
THE ENDOMETRIAL GLANDS ARE INCREASED IN NUMBER AND SOME ARE DILATED OR CYSTIC.

FEMALE 299 (1551/80)

LUNG

PNEUMONIA :
MINIMAL
THE ALVEOLAR WALLS ARE THICKENED AND ALVEOLI CONTAIN INFLAMMATORY CELLS AND FOAMY MACROPHAGES.PERIVASCULAR AND PERIBRONCHIAL LYMPHOCYTIC ACCUMULATIONS MAY BE PRESENT.

SPLEEN

HEMATOPOIESIS :
MODERATE
THE HEMATOPOIESIS IS EVIDENT.

THYROIDS

ABSENT :
ORGAN OR TISSUE NOT REMOVED FROM ANIMAL OR NOT FOUND IN FIXATIVE.

ADRENALS

PIGMENTATION :
MODERATE
NUMEROUS MACROPHAGES CONTAIN A GRANULAR BROWN CYTOPLASMIC PIGMENT.

OVARIES

ATROPHY :
BILATERAL
THE ORGAN IS REDUCED IN SIZE.

CYST :
UNILATERAL
ONE OR MORE CYSTS FILLED WITH CLEAR LIQUID ARE SEEN.

UTERUS

HEMORRHAGE :
BILATERAL SEVERE
THERE IS EXTRAVASATION OF BLOOD.

CYSTIC ENDOMETRIAL HYPERPLASIA :
BILATERAL SEVERE
THE ENDOMETRIAL GLANDS ARE INCREASED IN NUMBER AND SOME ARE DILATED OR CYSTIC.

BAYER AG

NF2. 1 CHRONIC TOXICITY STUDY IN MICE: NONSYSTEMATIC

HISTOPATHOLOGY

PRODUCT : KWG 0519 GROUP : 2
ROUTE : DIETARY
TIME : 105 WEEKS DOSE : 500 PPM
THIS GROUP COMPRISED : 33 FEMALES

THE FOLLOWING ORGANS WERE EXAMINED SYSTEMATICALLY :

HEART	LUNG	LIVER
PANCREAS	SPLEEN	KIDNEYS
BLADDER	STOMACH	OVARIES
THYROIDS	ADRENALS	PITUITARY
BRAIN	SKELETAL MUSCLE	SCIATIC NERVE
FEMUR		

THESE ORGANS WERE EXAMINED IN 33 FEMALES

INDIVIDUAL RESULTS

IN THE ANIMALS SHOWN BELOW THE HISTOLOGICAL EXAMINATION OF THE ORGANS LISTED OR OF THE ANOMALIES FOUND AT AUTOPSY GAVE THE FOLLOWING RESULTS :

FEMALE 251 (1794/80)

LUNG

HEMORRHAGE :
MULTIFOCAL
THERE IS EXTRAVASATION OF BLOOD.

STOMACH

NORMAL :
HISTOLOGICAL ASPECT WITHIN NORMAL LIMITS.

LIVER

LEUKEMIC DEPOSITS :
ORGAN AND THE BLOOD ARE INVADED BY LEUKEMIC CELLS.

SPLEEN

*** LYMPHOMA LYMPHOCYTIC :
THE NEOPLASM OF THE RETICULAR SYSTEM ORIGINATES FROM LYMPHOCYTES.

CONGESTION :
VESSELS OR SINUSOIDS ARE MARKEDLY DISTENDED WITH ERYTHROCYTES.

KIDNEYS

LEUKEMIC DEPOSITS :
ORGAN AND THE BLOOD ARE INVADED BY LEUKEMIC CELLS.

BLADDER

AUTOLYSIS PARTIAL :
NO OTHER CHANGES ARE SEEN. TISSUES ARE ALTERED. BY POST-MORTEM MODIFICATIONS AND DIAGNOSIS IS GIVEN WITH RESERVATION.

ADRENALS

CALCIFICATION :
UNILATERAL
THERE ARE MINERAL DEPOSITS.

PIGMENTATION :
BILATERAL MODERATE
NUMEROUS MACROPHAGES CONTAIN A GRANULAR BROWN CYTOPLASMIC PIGMENT.

LYMPH NODE

CONGESTION :
VESSELS OR SINUSOIDS ARE MARKEDLY DISTENDED WITH ERYTHROCYTES.

HYPERTROPHY :
THE SIZE OF THE ORGAN IS INCREASED WITHOUT STRUCTURAL ANOMALY.

AUTOLYSIS PARTIAL :
NO OTHER CHANGES ARE SEEN. TISSUES ARE ALTERED. BY POST-MORTEM MODIFICATIONS AND DIAGNOSIS IS GIVEN WITH RESERVATION.

FEMALE 252 (1803/80)

BRAIN

FAT VACUOLES :
FOCAL
THE CELLS ARE DISTENDED BY CLEAR CYTOPLASMIC VACUOLES WHICH FREQUENTLY DISPLACE THE NUCLEI.

LUNG

*** ALVEOLOGENIC CARCINOMA :
A MALIGNANT TUMOR OF THE LUNG TISSUE WITH SYNONYMS IN MICE FOR ADENOMA, CARCINOMA, ALVEOLOGENIC PAPILLARY CARCINOMA, PAPILLARY CYSTADENOMA, ADENOCARCINOMA, BRONCHIOLAR

BAYER AG

LUNG CONTINUED

CELL CARCINOMA, BRONCHIOLAR-ALVEOLAR TUMOR, TYPE A TUMOR, TYPE B TUMOR, INTERMEDIATE TYPE I TUMOR AND COMMON PULMONARY TUMOR OF THE MOUSE.

LEUKOCYTOSIS :
SEVERE
THERE IS AN INCREASE IN LEUKOCYTES.

LEUKEMIC DEPOSITS :
ORGAN AND THE BLOOD ARE INVADED BY LEUKEMIC CELLS.

LIVER

LEUKEMIC DEPOSITS :
ORGAN AND THE BLOOD ARE INVADED BY LEUKEMIC CELLS.

AUTOLYSIS PARTIAL :
NO OTHER CHANGES ARE SEEN. TISSUES ARE ALTERED. BY POST-MORTEM MODIFICATIONS AND DIAGNOSIS IS GIVEN WITH RESERVATION.

SPLEEN

*** LYMPHOMA LYMPHOCYTIC :
THE NEOPLASM OF THE RETICULAR SYSTEM ORIGINATES FROM LYMPHOCYTES.

KIDNEYS

INTERSTITIAL NEPHRITIS :
UNILATERAL MINIMAL FOCAL
INFLAMMATORY CELLS FIBROSIS AND SOME TUBULAR ALTERATIONS ARE ASSOCIATED.

CYSTS :
UNILATERAL MINIMAL FOCAL
ONE OR MORE CYSTS FILLED WITH CLEAR LIQUID ARE SEEN.

BLADDER

AUTOLYSIS PARTIAL :
NO OTHER CHANGES ARE SEEN. TISSUES ARE ALTERED. BY POST-MORTEM MODIFICATIONS AND DIAGNOSIS IS GIVEN WITH RESERVATION.

PITUITARY

ABSENT :
ORGAN OR TISSUE NOT REMOVED FROM ANIMAL OR NOT FOUND IN FIXATIVE.

OVARIES

ATROPHY :
BILATERAL
THE ORGAN IS REDUCED IN SIZE.

UTERUS

HYPERPLASIA POLYPOID:
UNILATERAL
A PEDUNCULATED GROWTH IN THE LUMEN IS PRESENT

LEUKEMIC DEPOSITS :
ORGAN AND THE BLOOD ARE INVADED BY LEUKEMIC CELLS.

LYMPH NODE

*** LYMPHOMA LYMPHOCYTIC :
THE NEOPLASM OF THE RETICULAR SYSTEM ORIGINATES FROM LYMPHOCYTES.

FEMALE 254 (1808/80)

LUNG

*** ALVEOLOGENIC CARCINOMA :
MULTIFOCAL
A MALIGNANT TUMOR OF THE LUNG TISSUE WITH SYNONYMS IN MICE FOR ADENOMA, CARCINOMA, ALVEOLOGENIC PAPILLARY CARCINOMA, PAPILLARY CYSTADENOMA, ADENOCARCINOMA, BRONCHIOLAR CELL CARCINOMA, BRONCHIOLAR-ALVEOLAR TUMOR, TYPE A TUMOR, TYPE B TUMOR, INTERMEDIATE TYPE I TUMOR AND COMMON PULMONARY TUMOR OF THE MOUSE.

LEUKEMIC DEPOSITS :
ORGAN AND THE BLOOD ARE INVADED BY LEUKEMIC CELLS.

LIVER

AUTOLYSIS PARTIAL :
NO OTHER CHANGES ARE SEEN. TISSUES ARE ALTERED BY POST-MORTEM MODIFICATIONS AND DIAGNOSIS IS GIVEN WITH RESERVATION.

PANCREAS

AUTOLYSIS PARTIAL :
NO OTHER CHANGES ARE SEEN. TISSUES ARE ALTERED BY POST-MORTEM MODIFICATIONS AND DIAGNOSIS IS GIVEN WITH RESERVATION.

SPLEEN

HEMATOPOIESIS :
SEVERE
THE HEMATOPOIESIS IS EVIDENT.

BAYER AG

KIDNEYS

PYELONEPHRITIS :
BILATERAL MODERATE MULTIFOCAL
INFLAMMATION OF RENAL PARENCHYMA WITH OR WITHOUT NECROSIS EXTENDED TO RENAL PELVIS.

BLADDER

AUTOLYSIS PARTIAL :
NO OTHER CHANGES ARE SEEN. TISSUES ARE ALTERED. BY POST-MORTEM MODIFICATIONS AND DIAGNOSIS IS GIVEN WITH RESERVATION.

THYROIDS

AUTOLYSIS PARTIAL :
NO OTHER CHANGES ARE SEEN. TISSUES ARE ALTERED. BY POST-MORTEM MODIFICATIONS AND DIAGNOSIS IS GIVEN WITH RESERVATION.

OVARIES

ATROPHY :
BILATERAL
THE ORGAN IS REDUCED IN SIZE.

FEMUR

NORMAL :
HISTOLOGICAL ASPECT WITHIN NORMAL LIMITS.

LYMPH NODE

*** LYMPHOMA LYMPHOCYTIC :
THE NEOPLASM OF THE RETICULAR SYSTEM ORIGINATES FROM LYMPHOCYTES.

FEMALE 255 (1799/80)

HEART

CONGESTION :
VESSELS OR SINUSOIDS ARE MARKEDLY DISTENDED WITH ERYTHROCYTES.

LUNG

LEUKEMIC DEPOSITS :
ORGAN AND THE BLOOD ARE INVADED BY LEUKEMIC CELLS.

STOMACH

LEUKEMIC DEPOSITS :

STOMACH CONTINUED

ORGAN AND THE BLOOD ARE INVADED BY LEUKEMIC CELLS.

LIVER

LEUKEMIC DEPOSITS :
ORGAN AND THE BLOOD ARE INVADED BY LEUKEMIC CELLS.

PANCREAS

LEUKEMIC DEPOSITS :
ORGAN AND THE BLOOD ARE INVADED BY LEUKEMIC CELLS.

SPLEEN

*** LYMPHOMA LYMPHOCYTIC :
THE NEOPLASM OF THE RETICULAR SYSTEM ORIGINATES FROM LYMPHOCYTES.

KIDNEYS

LEUKEMIC DEPOSITS :
ORGAN AND THE BLOOD ARE INVADED BY LEUKEMIC CELLS.

BLADDER

LEUKEMIC DEPOSITS :
ORGAN AND THE BLOOD ARE INVADED BY LEUKEMIC CELLS.

THYROIDS

ABSENT :
ORGAN OR TISSUE NOT REMOVED FROM ANIMAL OR NOT FOUND IN FIXATIVE.

ADRENALS

PIGMENTATION :
UNILATERAL MINIMAL
NUMEROUS MACROPHAGES CONTAIN A GRANULAR BROWN CYTOPLASMIC PIGMENT.

SKELETAL MUSCLE

LEUKEMIC DEPOSITS :
ORGAN AND THE BLOOD ARE INVADED BY LEUKEMIC CELLS.

MESENTERY

LEUKEMIC DEPOSITS :
ORGAN AND THE BLOOD ARE INVADED BY LEUKEMIC CELLS.

OVARIES

LEUKEMIC DEPOSITS :

BAYER AG

OVARIES CONTINUED
ORGAN AND THE BLOOD ARE INVADED BY LEUKEMIC CELLS.

LYMPH NODE

*** LYMPHOMA LYMPHOCYTIC :
THE NEOPLASM OF THE RETICULAR SYSTEM ORIGINATES FROM LYMPHOCYTES.

FEMALE 256 (1789/80)

HEART

CONGESTION :
VESSELS OR SINUSOIDS ARE MARKEDLY DISTENDED WITH ERYTHROCYTES.

PERICARDITIS :
FOCAL
THE PERICARDIUM IS THE SITE OF ACUTE OR CHRONIC INFLAMMATION.

LUNG

EDEMA :
THE INTERSTITIAL TISSUES CONTAIN AN INCREASED AMOUNT OF FLUID.

HEMORRHAGE :
THERE IS EXTRAVASATION OF BLOOD.

CONGESTION :
VESSELS OR SINUSOIDS ARE MARKEDLY DISTENDED WITH ERYTHROCYTES.

STOMACH

AUTOLYSIS PARTIAL :
NO OTHER CHANGES ARE SEEN. TISSUES ARE ALTERED. BY POST-MORTEM MODIFICATIONS AND DIAGNOSIS IS GIVEN WITH RESERVATION.

LIVER

CONGESTION :
VESSELS OR SINUSOIDS ARE MARKEDLY DISTENDED WITH ERYTHROCYTES.

VACUOLIZATION :
MINIMAL
IN THESE CELLS THERE ARE CLEAR VACUOLES GREATER IN NUMBER AND SIZE THAN NORMALLY FOUND.

AUTOLYSIS PARTIAL :

LIVER CONTINUED

NO OTHER CHANGES ARE SEEN. TISSUES ARE ALTERED.
BY POST-MORTEM MODIFICATIONS AND
DIAGNOSIS IS GIVEN WITH RESERVATION.

PANCREAS

AUTOLYSIS PARTIAL :
NO OTHER CHANGES ARE SEEN. TISSUES ARE ALTERED.
BY POST-MORTEM MODIFICATIONS AND
DIAGNOSIS IS GIVEN WITH RESERVATION.

THYMUS

*** LYMPHOMA LYMPHOCYTIC :
THE NEOPLASM OF THE RETICULAR SYSTEM ORIGINATES FROM
LYMPHOCYTES.

SPLEEN

HEMATOPOIESIS :
MODERATE
THE HEMATOPOIESIS IS EVIDENT.

KIDNEYS

CONGESTION :
VESSELS OR SINUSOIDS ARE MARKEDLY DISTENDED WITH
ERYTHROCYTES.

AUTOLYSIS PARTIAL :
NO OTHER CHANGES ARE SEEN. TISSUES ARE ALTERED.
BY POST-MORTEM MODIFICATIONS AND
DIAGNOSIS IS GIVEN WITH RESERVATION.

BLADDER

AUTOLYSIS PARTIAL :
NO OTHER CHANGES ARE SEEN. TISSUES ARE ALTERED.
BY POST-MORTEM MODIFICATIONS AND
DIAGNOSIS IS GIVEN WITH RESERVATION.

THYROIDS

ABSENT :
ORGAN OR TISSUE NOT REMOVED FROM ANIMAL OR NOT FOUND IN
FIXATIVE.

UTERUS

HYPERPLASIA SECRETORY :
BILATERAL MODERATE
THE DEVELOPED GLANDS AND/OR DUCTS CONTAIN A
SECRETION

BAYER AG

FEMALE 257 (1805/80)

STOMACH

AUTOLYSIS PARTIAL :
NO OTHER CHANGES ARE SEEN. TISSUES ARE ALTERED.
BY POST-MORTEM MODIFICATIONS AND
DIAGNOSIS IS GIVEN WITH RESERVATION.

LIVER

LEUKEMIC DEPOSITS :
ORGAN AND THE BLOOD ARE INVADED BY LEUKEMIC
CELLS.

PANCREAS

AUTOLYSIS PARTIAL :
NO OTHER CHANGES ARE SEEN. TISSUES ARE ALTERED.
BY POST-MORTEM MODIFICATIONS AND
DIAGNOSIS IS GIVEN WITH RESERVATION.

SPLEEN

HEMATOPOIESIS :
SEVERE
THE HEMATOPOIESIS IS EVIDENT.

*** LYMPHOMA LYMPHOCYTIC :
THE NEOPLASM OF THE RETICULAR SYSTEM ORIGINATES FROM
LYMPHOCYTES.

KIDNEYS

TUBULOPATHY :
BILATERAL MODERATE
TUBULAR DEGENERATIVE CHANGES ARE PRESENT
WHICH MAY BE ASSOCIATED WITH TUBULAR DILATATION.

LEUKEMIC DEPOSITS :
ORGAN AND THE BLOOD ARE INVADED BY LEUKEMIC
CELLS.

BLADDER

LEUKEMIC DEPOSITS :
ORGAN AND THE BLOOD ARE INVADED BY LEUKEMIC
CELLS.

PITUITARY

ABSENT :
ORGAN OR TISSUE NOT REMOVED FROM ANIMAL OR NOT FOUND IN
FIXATIVE.

THYROIDS

ABSENT :
ORGAN OR TISSUE NOT REMOVED FROM ANIMAL OR NOT FOUND IN
FIXATIVE.

SKELETAL MUSCLE

LEUKEMIC DEPOSITS :

M.F2.10 FEMALE 257 CONTINUED

SKELETAL MUSCLE CONTINUED
ORGAN AND THE BLOOD ARE INVADED BY LEUKEMIC CELLS.

OVARIES

ATROPHY :
BILATERAL
THE ORGAN IS REDUCED IN SIZE.

CYSTS :
BILATERAL
ONE OR MORE CYSTS FILLED WITH CLEAR LIQUID ARE SEEN.

FEMUR

*** OSTEOGENIC SARCOMA :
MULTIFOCAL
A MALIGNANT MESENCHYMAL TUMOR WITH ISLANDS OF OSTEOID AND BONE FORMATION IS FOUND.

LYMPH NODE

*** LYMPHOMA LYMPHOCYTIC :
THE NEOPLASM OF THE RETICULAR SYSTEM ORIGINATES FROM LYMPHOCYTES.

FEMALE 259 (1797/80)

BRAIN

ABSENT :
ORGAN OR TISSUE NOT REMOVED FROM ANIMAL OR NOT FOUND IN FIXATIVE.

LUNG

LEUKOCYTOSIS :
THERE IS AN INCREASE IN LEUKOCYTES.

AUTOLYSIS PARTIAL :
NO OTHER CHANGES ARE SEEN. TISSUES ARE ALTERED.
BY POST-MORTEM MODIFICATIONS AND
DIAGNOSIS IS GIVEN WITH RESERVATION.

STOMACH

AUTOLYSIS :
THE TISSUES EXHIBIT AUTOLYSIS AND THEY ARE NOT INTERPRETABLE.

LIVER

LEUKEMIC DEPOSITS :
ORGAN AND THE BLOOD ARE INVADED BY LEUKEMIC

BAYER AG

LIVER CONTINUED

CELLS.

AUTOLYSIS PARTIAL :
NO OTHER CHANGES ARE SEEN. TISSUES ARE ALTERED.
BY POST-MORTEM MODIFICATIONS AND
DIAGNOSIS IS GIVEN WITH RESERVATION.

PANCREAS

AUTOLYSIS :
THE TISSUES EXHIBIT AUTOLYSIS AND THEY ARE NOT
INTERPRETABLE.

SPLEEN

*** LYMPHOMA LYMPHOCYTIC :
THE NEOPLASM OF THE RETICULAR SYSTEM ORIGINATES FROM
LYMPHOCYTES.

AUTOLYSIS PARTIAL :
NO OTHER CHANGES ARE SEEN. TISSUES ARE ALTERED.
BY POST-MORTEM MODIFICATIONS AND
DIAGNOSIS IS GIVEN WITH RESERVATION.

KIDNEYS

LEUKEMIC DEPOSITS :
ORGAN AND THE BLOOD ARE INVADED BY LEUKEMIC
CELLS.

AUTOLYSIS PARTIAL :
NO OTHER CHANGES ARE SEEN. TISSUES ARE ALTERED.
BY POST-MORTEM MODIFICATIONS AND
DIAGNOSIS IS GIVEN WITH RESERVATION.

BLADDER

AUTOLYSIS :
THE TISSUES EXHIBIT AUTOLYSIS AND THEY ARE NOT
INTERPRETABLE.

PITUITARY

ABSENT :
ORGAN OR TISSUE NOT REMOVED FROM ANIMAL OR NOT FOUND IN
FIXATIVE.

THYROIDS

ABSENT :
ORGAN OR TISSUE NOT REMOVED FROM ANIMAL OR NOT FOUND IN
FIXATIVE.

ADRENALS

AUTOLYSIS PARTIAL :
NO OTHER CHANGES ARE SEEN. TISSUES ARE ALTERED.
BY POST-MORTEM MODIFICATIONS AND
DIAGNOSIS IS GIVEN WITH RESERVATION.

SKELETAL MUSCLE

AUTOLYSIS PARTIAL :
NO OTHER CHANGES ARE SEEN. TISSUES ARE ALTERED.
BY POST-MORTEM MODIFICATIONS AND
DIAGNOSIS IS GIVEN WITH RESERVATION.

MESENTERY

LEUKEMIC DEPOSITS :
ORGAN AND THE BLOOD ARE INVADED BY LEUKEMIC
CELLS.

OVARIES

AUTOLYSIS :
THE TISSUES EXHIBIT AUTOLYSIS AND THEY ARE NOT
INTERPRETABLE.

BAYER AG

FEMALE 260 (1814/80)

HEART

CONGESTION :
VESSELS OR SINUSOIDS ARE MARKEDLY DISTENDED WITH
ERYTHROCYTES.

DILATED CHAMBER :
ONE OR MORE OF THE CHAMBERS OF THE HEART ARE DILATED.

BAYER AG

LUNG

*** ALVEOLOGENIC CARCINOMA :
A MALIGNANT TUMOR OF THE LUNG TISSUE WITH
SYNONYMS IN MICE FOR ADENOMA, CARCINOMA,
ALVEOLOGENIC PAPILLARY CARCINOMA, PAPILLARY
CYSTADENOMA, ADENOCARCINOMA, BRONCHIOLAR
CELL CARCINOMA, BRONCHIOLAR-ALVEOLAR TUMOR,
TYPE A TUMOR, TYPE B TUMOR, INTERMEDIATE
TYPE I TUMOR AND COMMON PULMONARY TUMOR OF
THE MOUSE.

BAYER AG

LIVER

*** ADENOMA HEPATIC BENIGN :
MULTIFOCAL
DISTINCT NODULES COMPRESS THE ADJACENT LIVER PARENCHYMA,
ARE CHARACTERIZED BY WELL DIFFERENTIATED HEPATOCYTES AND DO
NOT SHOW PORTAL TRIADS.

CONGESTION :
VESSELS OR SINUSOIDS ARE MARKEDLY DISTENDED WITH
ERYTHROCYTES.

PANCREAS

LEUKEMIC DEPOSITS :
ORGAN AND THE BLOOD ARE INVADED BY LEUKEMIC CELLS.

SPLEEN

*** LYMPHOMA STEM CELLS :
THE NEOPLASM OF THE RETICULAR SYSTEM ORIGINATES FROM STEM CELLS.

KIDNEYS

TUBULOPATHY :
BILATERAL MINIMAL
TUBULAR DEGENERATIVE CHANGES ARE PRESENT WHICH MAY BE ASSOCIATED WITH TUBULAR DILATATION.

MESENTERY

LEUKEMIC DEPOSITS :
ORGAN AND THE BLOOD ARE INVADED BY LEUKEMIC CELLS.

OVARIES

ATROPHY :
BILATERAL
THE ORGAN IS REDUCED IN SIZE.

CYSTS :
BILATERAL
ONE OR MORE CYSTS FILLED WITH CLEAR LIQUID ARE SEEN.

LEUKEMIC DEPOSITS :
ORGAN AND THE BLOOD ARE INVADED BY LEUKEMIC CELLS.

UTERUS

SQUAMOUS METAPLASIA :
CONTRALATERAL
THE COLUMNAR EPITHELIAL CELLS HAVE BEEN REPLACED BY SQUAMOUS EPITHELIAL CELLS.

ENDOMETRIOSIS :
BILATERAL
ENDOMETRIAL GLANDS ARE SEEN AT VARIOUS SITES OUTSIDE THE NORMAL ENDOMETRIUM.

LEUKEMIC DEPOSITS :
BILATERAL
ORGAN AND THE BLOOD ARE INVADED BY LEUKEMIC CELLS.

FEMALE 261 (1606/60)

LUNG

PNEUMONIA :
THE ALVEOLAR WALLS ARE THICKENED AND ALVEOLI CONTAIN INFLAMMATORY CELLS AND FOAMY MACROPHAGES.PERIVASCULAR AND PERIBRONCHIAL LYMPHOCYTIC ACCUMULATIONS MAY BE PRESENT.

STOMACH

LEUKEMIC DEPOSITS :
ORGAN AND THE BLOOD ARE INVADED BY LEUKEMIC CELLS.

LIVER

NECROSIS :
THE TISSUE HAS LOST ITS NORMAL STRUCTURE DUE TO CELL DEATH WHICH MAY BE OF VARIOUS ORIGIN.

HYPERPLASTIC NODULE :
A NODULE OF HYPERPLASTIC TISSUE IS PRESENT.

LEUKEMIC DEPOSITS :
ORGAN AND THE BLOOD ARE INVADED BY LEUKEMIC CELLS.

PANCREAS

AUTOLYSIS PARTIAL :
NO OTHER CHANGES ARE SEEN. TISSUES ARE ALTERED.
BY POST-MORTEM MODIFICATIONS AND
DIAGNOSIS IS GIVEN WITH RESERVATION.

SPLEEN

HEMATOPOIESIS :
SEVERE
THE HEMATOPOIESIS IS EVIDENT.

BLADDER

ABSENT :
ORGAN OR TISSUE NOT REMOVED FROM ANIMAL OR NOT FOUND IN FIXATIVE.

ADRENALS

PIGMENTATION :
BILATERAL MODERATE
NUMEROUS MACROPHAGES CONTAIN A GRANULAR BROWN CYTOPLASMIC PIGMENT.

BAYER AG

SKELETAL MUSCLE

ABSENT :
ORGAN OR TISSUE NOT REMOVED FROM ANIMAL OR NOT FOUND IN FIXATIVE.

SCIATIC NERVE

ABSENT :
ORGAN OR TISSUE NOT REMOVED FROM ANIMAL OR NOT FOUND IN FIXATIVE.

OVARIES

ATROPHY :
BILATERAL
THE ORGAN IS REDUCED IN SIZE.

CYSTS :
UNILATERAL
ONE OR MORE CYSTS FILLED WITH CLEAR LIQUID ARE SEEN.

UTERUS

HYPERPLASIA POLYPOID:
BILATERAL
A PEDUNCULATED GROWTH IN THE LUMEN IS PRESENT

FEMUR

ABSENT :
ORGAN OR TISSUE NOT REMOVED FROM ANIMAL OR NOT FOUND IN FIXATIVE.

LYMPH NODE

*** LYMPHOMA LYMPHOCYTIC :
THE NEOPLASM OF THE RETICULAR SYSTEM ORIGINATES FROM LYMPHOCYTES.

FEMALE 262 (1791/80)

BRAIN

FAT VACUOLES :
MODERATE FOCAL
THE CELLS ARE DISTENDED BY CLEAR CYTOPLASMIC VACUOLES WHICH FREQUENTLY DISPLACE THE NUCLEI.

HEART

CONGESTION :
VESSELS OR SINUSOIDS ARE MARKEDLY DISTENDED WITH ERYTHROCYTES.

LUNG

NECROSIS :
THE TISSUE HAS LOST ITS NORMAL STRUCTURE DUE TO CELL DEATH WHICH MAY BE OF VARIOUS ORIGIN.

*** ALVEOLOGENIC CARCINOMA :
A MALIGNANT TUMOR OF THE LUNG TISSUE WITH SYNONYMS IN MICE FOR ADENOMA, CARCINOMA, ALVEOLOGENIC PAPILLARY CARCINOMA, PAPILLARY CYSTADENOMA, ADENOCARCINOMA, BRONCHIOLAR CELL CARCINOMA, BRONCHIOLAR-ALVEOLAR TUMOR, TYPE A TUMOR, TYPE B TUMOR, INTERMEDIATE TYPE I TUMOR AND COMMON PULMONARY TUMOR OF THE MOUSE.

STOMACH

HEMORRHAGE :
THERE IS EXTRAVASATION OF BLOOD.

LEUKEMIC DEPOSITS :
ORGAN AND THE BLOOD ARE INVADED BY LEUKEMIC CELLS.

AUTOLYSIS PARTIAL :
NO OTHER CHANGES ARE SEEN. TISSUES ARE ALTERED BY POST-MORTEM MODIFICATIONS AND DIAGNOSIS IS GIVEN WITH RESERVATION.

LIVER

INFARCT :
MULTIFOCAL
AN AREA OF ISCHEMIC NECROSIS DUE TO VASCULAR OCCLUSION IS PRESENT.

LEUKEMIC DEPOSITS :
ORGAN AND THE BLOOD ARE INVADED BY LEUKEMIC CELLS.

PANCREAS

INFLAMMATION CHRONIC :
MODERATE MULTIFOCAL
THE INTERSTITIAL TISSUES SHOW INFILTRATION BY MONONUCLEAR CELLS AND INCREASE IN FIBROUS STROMA.

ATROPHY :
MODERATE MULTIFOCAL
THE ORGAN IS REDUCED IN SIZE.

SPLEEN

*** LYMPHOMA STEM CELLS :
THE NEOPLASM OF THE RETICULAR SYSTEM ORIGINATES FROM STEM CELLS.

CONGESTION :
VESSELS OR SINUSOIDS ARE MARKEDLY DISTENDED WITH ERYTHROCYTES.

BAYER AG

KIDNEYS

LEUKEMIC DEPOSITS :
ORGAN AND THE BLOOD ARE INVADED BY LEUKEMIC CELLS.

BLADDER

LEUKEMIC DEPOSITS :
ORGAN AND THE BLOOD ARE INVADED BY LEUKEMIC CELLS.

PITUITARY

ABSENT :
ORGAN OR TISSUE NOT REMOVED FROM ANIMAL OR NOT FOUND IN FIXATIVE.

THYROIDS

ABSENT :
ORGAN OR TISSUE NOT REMOVED FROM ANIMAL OR NOT FOUND IN FIXATIVE.

MESENTERY

LEUKEMIC DEPOSITS :
ORGAN AND THE BLOOD ARE INVADED BY LEUKEMIC CELLS.

OVARIES

CYSTS :
UNILATERAL
ONE OR MORE CYSTS FILLED WITH CLEAR LIQUID ARE SEEN.

UTERUS

UNREADABLE :
IT IS NOT POSSIBLE TO INTERPRET THE SECTION DUE TO AN ARTIFACT CAUSED BY SAMPLING OR HISTOLOGICAL TECHNIQUE.

FEMALE 264 (1807/60)

BRAIN

ABSENT :
ORGAN OR TISSUE NOT REMOVED FROM ANIMAL OR NOT FOUND IN FIXATIVE.

LUNG

EDEMA :
THE INTERSTITIAL TISSUES CONTAIN AN INCREASED AMOUNT OF FLUID.

AUTOLYSIS PARTIAL :

LUNG CONTINUED

NO OTHER CHANGES ARE SEEN. TISSUES ARE ALTERED.
BY POST-MORTEM MODIFICATIONS AND
DIAGNOSIS IS GIVEN WITH RESERVATION.

STOMACH

AUTOLYSIS PARTIAL :
NO OTHER CHANGES ARE SEEN. TISSUES ARE ALTERED.
BY POST-MORTEM MODIFICATIONS AND
DIAGNOSIS IS GIVEN WITH RESERVATION.

LIVER

AUTOLYSIS PARTIAL :
NO OTHER CHANGES ARE SEEN. TISSUES ARE ALTERED.
BY POST-MORTEM MODIFICATIONS AND
DIAGNOSIS IS GIVEN WITH RESERVATION.

PANCREAS

AUTOLYSIS :
THE TISSUES EXHIBIT AUTOLYSIS AND THEY ARE NOT
INTERPRETABLE.

SPLEEN

AUTOLYSIS :
THE TISSUES EXHIBIT AUTOLYSIS AND THEY ARE NOT
INTERPRETABLE.

KIDNEYS

AUTOLYSIS PARTIAL :
NO OTHER CHANGES ARE SEEN. TISSUES ARE ALTERED.
BY POST-MORTEM MODIFICATIONS AND
DIAGNOSIS IS GIVEN WITH RESERVATION.

BLADDER

AUTOLYSIS PARTIAL :
NO OTHER CHANGES ARE SEEN. TISSUES ARE ALTERED.
BY POST-MORTEM MODIFICATIONS AND
DIAGNOSIS IS GIVEN WITH RESERVATION.

PITUITARY

ABSENT :
ORGAN OR TISSUE NOT REMOVED FROM ANIMAL OR NOT FOUND IN
FIXATIVE.

THYROIDS

AUTOLYSIS PARTIAL :
NO OTHER CHANGES ARE SEEN. TISSUES ARE ALTERED.
BY POST-MORTEM MODIFICATIONS AND
DIAGNOSIS IS GIVEN WITH RESERVATION.

ADRENALS

PIGMENTATION :
BILATERAL MODERATE

BAYER AG BAYER AG BAYER AG

ADRENALS CONTINUED
NUMEROUS MACROPHAGES CONTAIN A GRANULAR BROWN CYTOPLASMIC PIGMENT.

OVARIES

AUTOLYSIS :
THE TISSUES EXHIBIT AUTOLYSIS AND THEY ARE NOT INTERPRETABLE.

DIAPHRAGM

*** LEIOMYOSARCOMA :
MALIGNANT TUMOR DERIVED FROM SMOOTH MUSCLE FIBERS.

FEMALE 265 (1804/80)

HEART

CONGESTION :
VESSELS OR SINUSOIDS ARE MARKEDLY DISTENDED WITH ERYTHROCYTES.

LUNG

HEMORRHAGE :
SEVERE
THERE IS EXTRAVASATION OF BLOOD.

PNEUMONIA :
SEVERE
THE ALVEOLAR WALLS ARE THICKENED AND ALVEOLI CONTAIN INFLAMMATORY CELLS AND FOAMY MACROPHAGES.PERIVASCULAR AND PERIBRONCHIAL LYMPHOCYTIC ACCUMULATIONS MAY BE PRESENT.

LIVER

INFARCT :
AN AREA OF ISCHEMIC NECROSIS DUE TO VASCULAR OCCLUSION IS PRESENT.

*** ADENOCARCINOMA :
MALIGNANT EPITHELIAL TUMOR SHOWING VARIOUS WELL DIFFERENTIATED MORPHOLOGICAL ASPECTS.

PANCREAS

EDEMA :
THE INTERSTITIAL TISSUES CONTAIN AN INCREASED AMOUNT OF FLUID.

INFLAMMATION CHRONIC :
THE INTERSTITIAL TISSUES SHOW INFILTRATION BY MONONUCLEAR CELLS AND INCREASE IN FIBROUS STROMA.

AUTOLYSIS PARTIAL :

PANCREAS CONTINUED
NO OTHER CHANGES ARE SEEN. TISSUES ARE ALTERED.
BY POST-MORTEM MODIFICATIONS AND
DIAGNOSIS IS GIVEN WITH RESERVATION.

SPLEEN

*** LYMPHOMA LYMPHOCYTIC :
THE NEOPLASM OF THE RETICULAR SYSTEM ORIGINATES FROM
LYMPHOCYTES.

KIDNEYS

HYDRONEPHROSIS :
UNILATERAL SEVERE
THE RENAL PELVIS IS DILATED AND THE ADJACENT PARENCHYMA IS
REDUCED.

LEUKEMIC DEPOSITS :
BILATERAL
ORGAN AND THE BLOOD ARE INVADED BY LEUKEMIC
CELLS.

THYROIDS

AUTOLYSIS PARTIAL :
NO OTHER CHANGES ARE SEEN. TISSUES ARE ALTERED.
BY POST-MORTEM MODIFICATIONS AND
DIAGNOSIS IS GIVEN WITH RESERVATION.

MESENTERY

LEUKEMIC DEPOSITS :
ORGAN AND THE BLOOD ARE INVADED BY LEUKEMIC
CELLS.

OVARIES

LEUKEMIC DEPOSITS :
ORGAN AND THE BLOOD ARE INVADED BY LEUKEMIC
CELLS.

FEMUR

HEMATOPOIESIS :
MODERATE
THE HEMATOPOIESIS IS EVIDENT.

FEMALE 269 (1600/00)

BRAIN

FAT VACUOLES :
FOCAL
THE CELLS ARE DISTENDED BY CLEAR CYTOPLASMIC

BAYER AG

BRAIN CONTINUED
VACUOLES WHICH FREQUENTLY DISPLACE THE NUCLEI.

LUNG

CONGESTION :
VESSELS OR SINUSOIDS ARE MARKEDLY DISTENDED WITH ERYTHROCYTES.

THICKENED ALVEOLAR WALLS :
MULTIFOCAL
THICKNESS OF ALVEOLAR WALLS IS INCREASED BY INFLAMMATORY CELLS AND/OR INTERSTITIAL EDEMA.

DUODENUM

AUTOLYSIS PARTIAL :
NO OTHER CHANGES ARE SEEN. TISSUES ARE ALTERED. BY POST-MORTEM MODIFICATIONS AND DIAGNOSIS IS GIVEN WITH RESERVATION.

LIVER

CONGESTION :
VESSELS OR SINUSOIDS ARE MARKEDLY DISTENDED WITH ERYTHROCYTES.

KIDNEYS

CYSTS :
BILATERAL MINIMAL MULTIFOCAL
ONE OR MORE CYSTS FILLED WITH CLEAR LIQUID ARE SEEN.

BLADDER

AUTOLYSIS PARTIAL :
NO OTHER CHANGES ARE SEEN. TISSUES ARE ALTERED. BY POST-MORTEM MODIFICATIONS AND DIAGNOSIS IS GIVEN WITH RESERVATION.

PITUITARY

ABSENT :
ORGAN OR TISSUE NOT REMOVED FROM ANIMAL OR NOT FOUND IN FIXATIVE.

THYROIDS

ABSENT :
ORGAN OR TISSUE NOT REMOVED FROM ANIMAL OR NOT FOUND IN FIXATIVE.

ADRENALS

HYPERPLASIA OF THE GLOMERULAR LAYER :
UNILATERAL FOCAL
THE GLOMERULAR LAYER IS THICKER THAN NORMAL.

BONE

*** OSTEOMA :
THIS BENIGN WELL CIRCUMSCRIBED TUMOR IS COMPOSED OF

BONE CONTINUED

WELL-DEVELOPED BONE.

OVARIES

THROMBOSIS :
UNILATERAL
THE VASCULAR LUMEN CONTAINS AN ATTACHED ANTE MORTEM BLOOD CLOT.

HEMORRAGIC CYST :
UNILATERAL
ONE OR SEVERAL CAVITIES FILLED WITH BLOOD.

UTERUS

HYPERPLASIA SECRETORY :
UNILATERAL
THE DEVELOPED GLANDS AND/OR DUCTS CONTAIN A SECRETION

FEMUR

NORMAL :
HISTOLOGICAL ASPECT WITHIN NORMAL LIMITS.

FEMALE 274 (1785/80)

BRAIN

ABSENT :
ORGAN OR TISSUE NOT REMOVED FROM ANIMAL OR NOT FOUND IN FIXATIVE.

LUNG

EDEMA :
THE INTERSTITIAL TISSUES CONTAIN AN INCREASED AMOUNT OF FLUID.

LEUKEMIC DEPOSITS :
ORGAN AND THE BLOOD ARE INVADED BY LEUKEMIC CELLS.

STOMACH

AUTOLYSIS :
THE TISSUES EXHIBIT AUTOLYSIS AND THEY ARE NOT INTERPRETABLE.

LIVER

AUTOLYSIS :
THE TISSUES EXHIBIT AUTOLYSIS AND THEY ARE NOT INTERPRETABLE.

BAYER AG

PANCREAS

AUTOLYSIS :
THE TISSUES EXHIBIT AUTOLYSIS AND THEY ARE NOT INTERPRETABLE.

SPLEEN

*** LYMPHOMA LYMPHOCYTIC :
THE NEOPLASM OF THE RETICULAR SYSTEM ORIGINATES FROM LYMPHOCYTES.

AUTOLYSIS PARTIAL :
NO OTHER CHANGES ARE SEEN. TISSUES ARE ALTERED. BY POST-MORTEM MODIFICATIONS AND DIAGNOSIS IS GIVEN WITH RESERVATION.

KIDNEYS

AUTOLYSIS PARTIAL :
NO OTHER CHANGES ARE SEEN. TISSUES ARE ALTERED. BY POST-MORTEM MODIFICATIONS AND DIAGNOSIS IS GIVEN WITH RESERVATION.

BLADDER

AUTOLYSIS :
THE TISSUES EXHIBIT AUTOLYSIS AND THEY ARE NOT INTERPRETABLE.

PITUITARY

ABSENT :
ORGAN OR TISSUE NOT REMOVED FROM ANIMAL OR NOT FOUND IN FIXATIVE.

THYROIDS

AUTOLYSIS PARTIAL :
NO OTHER CHANGES ARE SEEN. TISSUES ARE ALTERED. BY POST-MORTEM MODIFICATIONS AND DIAGNOSIS IS GIVEN WITH RESERVATION.

ADRENALS

ABSENT :
ORGAN OR TISSUE NOT REMOVED FROM ANIMAL OR NOT FOUND IN FIXATIVE.

OVARIES

AUTOLYSIS PARTIAL :
NO OTHER CHANGES ARE SEEN. TISSUES ARE ALTERED. BY POST-MORTEM MODIFICATIONS AND DIAGNOSIS IS GIVEN WITH RESERVATION.

FEMALE 275 (1609/80)

LUNG

PNEUMONIA :
THE ALVEOLAR WALLS ARE THICKENED AND ALVEOLI CONTAIN INFLAMMATORY CELLS AND FOAMY MACROPHAGES, PERIVASCULAR AND PERIBRONCHIAL LYMPHOCYTIC ACCUMULATIONS MAY BE PRESENT.

*** ALVEOLOGENIC CARCINOMA :
A MALIGNANT TUMOR OF THE LUNG TISSUE WITH SYNONYMS IN MICE FOR ADENOMA, CARCINOMA, ALVEOLOGENIC PAPILLARY CARCINOMA, PAPILLARY CYSTADENOMA, ADENOCARCINOMA, BRONCHIOLAR CELL CARCINOMA, BRONCHIOLAR-ALVEOLAR TUMOR, TYPE A TUMOR, TYPE B TUMOR, INTERMEDIATE TYPE I TUMOR AND COMMON PULMONARY TUMOR OF THE MOUSE.

CONGESTION :
VESSELS OR SINUSOIDS ARE MARKEDLY DISTENDED WITH ERYTHROCYTES.

STOMACH

HEMORRHAGE :
FOCAL
THERE IS EXTRAVASATION OF BLOOD.

LIVER

INFARCT :
SEVERE MULTIFOCAL
AN AREA OF ISCHEMIC NECROSIS DUE TO VASCULAR OCCLUSION IS PRESENT.

PANCREAS

ABSENT :
ORGAN OR TISSUE NOT REMOVED FROM ANIMAL OR NOT FOUND IN FIXATIVE.

SPLEEN

HEMATOPOIESIS :
SEVERE
THE HEMATOPOIESIS IS EVIDENT.

ADRENALS

PIGMENTATION :
UNILATERAL MINIMAL
NUMEROUS MACROPHAGES CONTAIN A GRANULAR BROWN CYTOPLASMIC PIGMENT.

BAYER AG

OVARIES

ATROPHY :
BILATERAL
THE ORGAN IS REDUCED IN SIZE.

CYSTS :
UNILATERAL
ONE OR MORE CYSTS FILLED WITH CLEAR LIQUID ARE SEEN.

UTERUS

HYPERPLASIA SECRETORY :
BILATERAL MODERATE
THE DEVELOPED GLANDS AND/OR DUCTS CONTAIN A SECRETION

FEMALE 277 (1816/80)

HEART

CONGESTION :
VESSELS OR SINUSOIDS ARE MARKEDLY DISTENDED WITH ERYTHROCYTES.

LUNG

*** ALVEOLOGENIC CARCINOMA :
A MALIGNANT TUMOR OF THE LUNG TISSUE WITH SYNONYMS IN MICE FOR ADENOMA, CARCINOMA, ALVEOLOGENIC PAPILLARY CARCINOMA, PAPILLARY CYSTADENOMA, ADENOCARCINOMA, BRONCHIOLAR CELL CARCINOMA, BRONCHIOLAR-ALVEOLAR TUMOR, TYPE A TUMOR, TYPE B TUMOR, INTERMEDIATE TYPE I TUMOR AND COMMON PULMONARY TUMOR OF THE MOUSE.

LIVER

LEUKEMIC DEPOSITS :
ORGAN AND THE BLOOD ARE INVADED BY LEUKEMIC CELLS.

PANCREAS

LEUKEMIC DEPOSITS :
ORGAN AND THE BLOOD ARE INVADED BY LEUKEMIC CELLS.

SPLEEN

*** LYMPHOMA LYMPHOCYTIC :
THE NEOPLASM OF THE RETICULAR SYSTEM ORIGINATES FROM LYMPHOCYTES.

PITUITARY

ABSENT :
ORGAN OR TISSUE NOT REMOVED FROM ANIMAL OR NOT FOUND IN FIXATIVE.

BONE

NORMAL :
HISTOLOGICAL ASPECT WITHIN NORMAL LIMITS.

OVARIES

ATROPHY :
BILATERAL
THE ORGAN IS REDUCED IN SIZE.

FEMUR

*** OSTEOMA :
THIS BENIGN WELL CIRCUMSCRIBED TUMOR IS COMPOSED OF WELL-DEVELOPED BONE.

LYMPH NODE

*** LYMPHOMA LYMPHOCYTIC :
THE NEOPLASM OF THE RETICULAR SYSTEM ORIGINATES FROM LYMPHOCYTES.

FEMALE 278 (1795/80)

BRAIN

ABSENT :
ORGAN OR TISSUE NOT REMOVED FROM ANIMAL OR NOT FOUND IN FIXATIVE.

HEART

CONGESTION :
VESSELS OR SINUSOIDS ARE MARKEDLY DISTENDED WITH ERYTHROCYTES.

LUNG

HEMORRHAGE :
MULTIFOCAL
THERE IS EXTRAVASATION OF BLOOD.

CONGESTION :
VESSELS OR SINUSOIDS ARE MARKEDLY DISTENDED WITH ERYTHROCYTES.

BAYER AG

STOMACH

NORMAL :
HISTOLOGICAL ASPECT WITHIN NORMAL LIMITS.

LIVER

HYPERTROPHY :
MULTIFOCAL
THE SIZE OF THE ORGAN IS INCREASED WITHOUT STRUCTURAL ANOMALY.

LEUKEMIC DEPOSITS :
ORGAN AND THE BLOOD ARE INVADED BY LEUKEMIC CELLS.

AUTOLYSIS PARTIAL :
NO OTHER CHANGES ARE SEEN. TISSUES ARE ALTERED. BY POST-MORTEM MODIFICATIONS AND DIAGNOSIS IS GIVEN WITH RESERVATION.

PANCREAS

AUTOLYSIS PARTIAL :
NO OTHER CHANGES ARE SEEN. TISSUES ARE ALTERED. BY POST-MORTEM MODIFICATIONS AND DIAGNOSIS IS GIVEN WITH RESERVATION.

SPLEEN

*** LYMPHOMA LYMPHOCYTIC :
THE NEOPLASM OF THE RETICULAR SYSTEM ORIGINATES FROM LYMPHOCYTES.

KIDNEYS

CYSTS :
UNILATERAL
ONE OR MORE CYSTS FILLED WITH CLEAR LIQUID ARE SEEN.

LEUKEMIC DEPOSITS :
BILATERAL
ORGAN AND THE BLOOD ARE INVADED BY LEUKEMIC CELLS.

BLADDER

LEUKEMIC DEPOSITS :
ORGAN AND THE BLOOD ARE INVADED BY LEUKEMIC CELLS.

PITUITARY

ABSENT :

ORGAN OR TISSUE NOT REMOVED FROM ANIMAL OR NOT FOUND IN FIXATIVE.

SKELETAL MUSCLE

ABSENT :
ORGAN OR TISSUE NOT REMOVED FROM ANIMAL OR NOT FOUND IN

SKELETAL MUSCLE CONTINUED
FIXATIVE.

SCIATIC NERVE

ABSENT :
ORGAN OR TISSUE NOT REMOVED FROM ANIMAL OR NOT FOUND IN FIXATIVE.

MESENTERY

LEUKEMIC DEPOSITS :
ORGAN AND THE BLOOD ARE INVADED BY LEUKEMIC CELLS.

UTERUS

LEUKEMIC DEPOSITS :
BILATERAL
ORGAN AND THE BLOOD ARE INVADED BY LEUKEMIC CELLS.

*** MESENCHYMAL TUMOR :
UNILATERAL
MALIGNANT TUMOR DERIVED FROM UNDIFFERENTIATED COMPONENTS OF CONNECTIVE TISSUE.

LYMPH NODE

CRYSTALS :
SHARPLY DEFINED CRYSTALS ARE PRESENT.

*** LYMPHOMA LYMPHOCYTIC :
THE NEOPLASM OF THE RETICULAR SYSTEM ORIGINATES FROM LYMPHOCYTES.

FEMALE 280 (1792/80)

LUNG

ATELECTASIS :
MULTIFOCAL
THERE IS COLLAPSE OF ALVEOLI.

LIVER

CONGESTION :
VESSELS OR SINUSOIDS ARE MARKEDLY DISTENDED WITH ERYTHROCYTES.

SPLEEN

HEMATOPOIESIS :
SEVERE
THE HEMATOPOIESIS IS EVIDENT.

HYPERTROPHY :

BAYER AG

SPLEEN CONTINUED

THE SIZE OF THE ORGAN IS INCREASED WITHOUT STRUCTURAL ANOMALY.

KIDNEYS

INTERSTITIAL NEPHRITIS :
BILATERAL MINIMAL MULTIFOCAL
INFLAMMATORY CELLS FIBROSIS AND SOME TUBULAR ALTERATIONS ARE ASSOCIATED.

ADRENALS

PIGMENTATION :
UNILATERAL MODERATE
NUMEROUS MACROPHAGES CONTAIN A GRANULAR BROWN CYTOPLASMIC PIGMENT.

OVARIES

ATROPHY :
BILATERAL
THE ORGAN IS REDUCED IN SIZE.

CYSTS :
BILATERAL
ONE OR MORE CYSTS FILLED WITH CLEAR LIQUID ARE SEEN.

UTERUS

HYPERPLASIA POLYPOID:
UNILATERAL
A PEDUNCULATED GROWTH IN THE LUMEN IS PRESENT

FEMALE 282 (1790/80)

BRAIN

FAT VACUOLES :
MINIMAL MULTIFOCAL
THE CELLS ARE DISTENDED BY CLEAR CYTOPLASMIC VACUOLES WHICH FREQUENTLY DISPLACE THE NUCLEI.

HEART

LEUKOCYTOSIS :
THERE IS AN INCREASE IN LEUKOCYTES.

CONGESTION :
VESSELS OR SINUSOIDS ARE MARKEDLY DISTENDED WITH ERYTHROCYTES.

LUNG

EDEMA :
SEVERE

LUNG CONTINUED

THE INTERSTITIAL TISSUES CONTAIN AN INCREASED AMOUNT OF FLUID.

PNEUMONIA :
SEVERE
THE ALVEOLAR WALLS ARE THICKENED AND ALVEOLI CONTAIN INFLAMMATORY CELLS AND FOAMY MACROPHAGES.PERIVASCULAR AND PERIBRONCHIAL LYMPHOCYTIC ACCUMULATIONS MAY BE PRESENT.

LEUKOCYTOSIS :
SEVERE
THERE IS AN INCREASE IN LEUKOCYTES.

CONGESTION :
SEVERE
VESSELS OR SINUSOIDS ARE MARKEDLY DISTENDED WITH ERYTHROCYTES.

LIVER

MONONUCLEAR CELLS :
MINIMAL MULTIFOCAL
FOCAL COLLECTIONS OF MONONUCLEAR CELLS ARE PRESENT.

CONGESTION :
VESSELS OR SINUSOIDS ARE MARKEDLY DISTENDED WITH ERYTHROCYTES.

SPLEEN

*** LYMPHOMA GRANULOCYTIC :
THE NEOPLASM OF THE RETICULAR SYSTEM ORIGINATES FROM GRANULOCYTES.

KIDNEYS

LEUKEMIC DEPOSITS :
ORGAN AND THE BLOOD ARE INVADED BY LEUKEMIC CELLS.

PITUITARY

HEMORRHAGE :
THERE IS EXTRAVASATION OF BLOOD.

ADRENALS

HYPERPLASIA OF THE GLOMERULAR LAYER :
UNILATERAL MULTIFOCAL
THE GLOMERULAR LAYER IS THICKER THAN NORMAL.

SKIN

NECROSIS :
THE TISSUE HAS LOST ITS NORMAL STRUCTURE DUE TO CELL DEATH WHICH MAY BE OF VARIOUS ORIGIN.

PUS :
A MORE OR LESS IMPORTANT QUANTITY OF PUS IS OBSERVED IN THIS TISSUE OR ORGAN.

BAYER AG

OVARIES

ATROPHY :
BILATERAL
THE ORGAN IS REDUCED IN SIZE.

FEMALE 283 (1788/80)

BRAIN

CONGESTION :
VESSELS OR SINUSOIDS ARE MARKEDLY DISTENDED WITH ERYTHROCYTES.

HEART

CONGESTION :
VESSELS OR SINUSOIDS ARE MARKEDLY DISTENDED WITH ERYTHROCYTES.

LUNG

CONGESTION :
VESSELS OR SINUSOIDS ARE MARKEDLY DISTENDED WITH ERYTHROCYTES.

LIVER

CONGESTION :
VESSELS OR SINUSOIDS ARE MARKEDLY DISTENDED WITH ERYTHROCYTES.

SPLEEN

NORMAL :
HISTOLOGICAL ASPECT WITHIN NORMAL LIMITS.

KIDNEYS

CONGESTION :
VESSELS OR SINUSOIDS ARE MARKEDLY DISTENDED WITH ERYTHROCYTES.

BLADDER

AUTOLYSIS PARTIAL :
NO OTHER CHANGES ARE SEEN. TISSUES ARE ALTERED.
BY POST-MORTEM MODIFICATIONS AND
DIAGNOSIS IS GIVEN WITH RESERVATION.

PITUITARY

ABSENT :
ORGAN OR TISSUE NOT REMOVED FROM ANIMAL OR NOT FOUND IN FIXATIVE.

OVARIES

ATROPHY :
BILATERAL
THE ORGAN IS REDUCED IN SIZE.

UTERUS

CYSTIC ENDOMETRIAL HYPERPLASIA :
BILATERAL MINIMAL
THE ENDOMETRIAL GLANDS ARE INCREASED IN NUMBER AND SOME ARE DILATED OR CYSTIC.

FEMALE 284 (1815/60)

BRAIN

HEMORRHAGE :
FOCAL
THERE IS EXTRAVASATION OF BLOOD

HEART

CONGESTION :
VESSELS OR SINUSOIDS ARE MARKEDLY DISTENDED WITH ERYTHROCYTES.

DILATED CHAMBER :
ONE OR MORE OF THE CHAMBERS OF THE HEART ARE DILATED.

LUNG

*** ALVEOLOGENIC CARCINOMA :
MULTIFOCAL
A MALIGNANT TUMOR OF THE LUNG TISSUE WITH SYNONYMS IN MICE FOR ADENOMA, CARCINOMA, ALVEOLOGENIC PAPILLARY CARCINOMA, PAPILLARY CYSTADENOMA, ADENOCARCINOMA, BRONCHIOLAR CELL CARCINOMA, BRONCHIOLAR-ALVEOLAR TUMOR, TYPE A TUMOR, TYPE B TUMOR, INTERMEDIATE TYPE I TUMOR AND COMMON PULMONARY TUMOR OF THE MOUSE.

LIVER

VACUOLIZATION :
MINIMAL MULTIFOCAL
IN THESE CELLS THERE ARE CLEAR VACUOLES GREATER IN NUMBER AND SIZE THAN NORMALLY FOUND.

SPLEEN

HEMATOPOIESIS :
SEVERE
THE HEMATOPOIESIS IS EVIDENT.

BAYER AG BAYER AG BAYER AG

KIDNEYS

PROGRESSIVE NEPHROPATHY :
BILATERAL SEVERE
AN AGE ASSOCIATED KIDNEY LESION CONSISTING OF CYSTIC TUBULES WITH COLLOID OR HYALINE CASTS CHRONIC INTERSTITIAL NEPHRITIS AND DILATATION OF BOWMAN'S CAPSULE WITH GLOMERULAR DEGENERATION .

MESENTERY

HEMORRHAGE :
THERE IS EXTRAVASATION OF BLOOD.

OVARIES

ATROPHY :
BILATERAL
THE ORGAN IS REDUCED IN SIZE.

CYSTS :
BILATERAL
ONE OR MORE CYSTS FILLED WITH CLEAR LIQUID ARE SEEN.

FEMALE 285 (1784/80)

BRAIN

FAT VACUOLES :
MODERATE MULTIFOCAL
THE CELLS ARE DISTENDED BY CLEAR CYTOPLASMIC VACUOLES WHICH FREQUENTLY DISPLACE THE NUCLEI.

LUNG

CONGESTION :
VESSELS OR SINUSOIDS ARE MARKEDLY DISTENDED WITH ERYTHROCYTES.

THICKENED ALVEOLAR WALLS :
THICKNESS OF ALVEOLAR WALLS IS INCREASED BY INFLAMMATORY CELLS AND/OR INTERSTITIAL EDEMA.

LIVER

MONONUCLEAR CELLS :
MINIMAL MULTIFOCAL
FOCAL COLLECTIONS OF MONONUCLEAR CELLS ARE PRESENT.

CONGESTION :
VESSELS OR SINUSOIDS ARE MARKEDLY DISTENDED WITH ERYTHROCYTES.

KIDNEYS

INTERSTITIAL NEPHRITIS :
UNILATERAL MINIMAL MULTIFOCAL
INFLAMMATORY CELLS FIBROSIS AND SOME TUBULAR ALTERATIONS ARE ASSOCIATED.

ADRENALS

PIGMENTATION :
UNILATERAL MINIMAL
NUMEROUS MACROPHAGES CONTAIN A GRANULAR BROWN CYTOPLASMIC PIGMENT.

SCIATIC NERVE

ABSENT :
ORGAN OR TISSUE NOT REMOVED FROM ANIMAL OR NOT FOUND IN FIXATIVE.

OVARIES

ABSENT :
ORGAN OR TISSUE NOT REMOVED FROM ANIMAL OR NOT FOUND IN FIXATIVE.

FEMALE 286 (1810/80)

LUNG

PNEUMONIA :
MODERATE
THE ALVEOLAR WALLS ARE THICKENED AND ALVEOLI CONTAIN INFLAMMATORY CELLS AND FOAMY MACROPHAGES.PERIVASCULAR AND PERIBRONCHIAL LYMPHOCYTIC ACCUMULATIONS MAY BE PRESENT.

LIVER

CONGESTION :
VESSELS OR SINUSOIDS ARE MARKEDLY DISTENDED WITH ERYTHROCYTES.

SPLEEN

HEMATOPOIESIS :
MODERATE
THE HEMATOPOIESIS IS EVIDENT.

KIDNEYS

FIBROSIS :
UNILATERAL MINIMAL FOCAL
THERE IS AN INCREASE IN INTERSTITIAL FIBROUS TISSUE.

BAYER AG

BLADDER

AUTOLYSIS PARTIAL :
NO OTHER CHANGES ARE SEEN. TISSUES ARE ALTERED.
BY POST-MORTEM MODIFICATIONS AND
DIAGNOSIS IS GIVEN WITH RESERVATION.

PITUITARY

*** ADENOMA :
THIS IS BENIGN GLANDULAR EPITHELIAL TUMOR.

ADRENALS

PIGMENTATION :
UNILATERAL SEVERE
NUMEROUS MACROPHAGES CONTAIN A GRANULAR BROWN CYTOPLASMIC PIGMENT.

ABSENT :
CONTRALATERAL
ORGAN OR TISSUE NOT REMOVED FROM ANIMAL OR NOT FOUND IN FIXATIVE.

OVARIES

CYSTS :
BILATERAL
ONE OR MORE CYSTS FILLED WITH CLEAR LIQUID ARE SEEN.

FEMALE 287 (1787/80)

HEART

CONGESTION :
VESSELS OR SINUSOIDS ARE MARKEDLY DISTENDED WITH ERYTHROCYTES.

LUNG

EDEMA :
THE INTERSTITIAL TISSUES CONTAIN AN INCREASED AMOUNT OF FLUID.

*** ALVEOLOGENIC CARCINOMA :
MULTIFOCAL
A MALIGNANT TUMOR OF THE LUNG TISSUE WITH SYNONYMS IN MICE FOR ADENOMA, CARCINOMA, ALVEOLOGENIC PAPILLARY CARCINOMA, PAPILLARY CYSTADENOMA, ADENOCARCINOMA, BRONCHIOLAR CELL CARCINOMA, BRONCHIOLAR-ALVEOLAR TUMOR, TYPE A TUMOR, TYPE B TUMOR, INTERMEDIATE TYPE I TUMOR AND COMMON PULMONARY TUMOR OF THE MOUSE.

AUTOLYSIS PARTIAL :

LUNG CONTINUED

NO OTHER CHANGES ARE SEEN. TISSUES ARE ALTERED.
BY POST-MORTEM MODIFICATIONS AND
DIAGNOSIS IS GIVEN WITH RESERVATION.

STOMACH

AUTOLYSIS :
THE TISSUES EXHIBIT AUTOLYSIS AND THEY ARE NOT
INTERPRETABLE.

LIVER

LEUKEMIC DEPOSITS :
ORGAN AND THE BLOOD ARE INVADED BY LEUKEMIC
CELLS.

AUTOLYSIS PARTIAL :
NO OTHER CHANGES ARE SEEN. TISSUES ARE ALTERED.
BY POST-MORTEM MODIFICATIONS AND
DIAGNOSIS IS GIVEN WITH RESERVATION.

PANCREAS

ABSENT :
ORGAN OR TISSUE NOT REMOVED FROM ANIMAL OR NOT FOUND IN
FIXATIVE.

SPLEEN

*** LYMPHOMA LYMPHOCYTIC :
THE NEOPLASM OF THE RETICULAR SYSTEM ORIGINATES FROM
LYMPHOCYTES.

KIDNEYS

LEUKEMIC DEPOSITS :
ORGAN AND THE BLOOD ARE INVADED BY LEUKEMIC
CELLS.

AUTOLYSIS PARTIAL :
NO OTHER CHANGES ARE SEEN. TISSUES ARE ALTERED.
BY POST-MORTEM MODIFICATIONS AND
DIAGNOSIS IS GIVEN WITH RESERVATION.

BLADDER

AUTOLYSIS :
THE TISSUES EXHIBIT AUTOLYSIS AND THEY ARE NOT
INTERPRETABLE.

ADRENALS

HEMATOPOIESIS :
UNILATERAL MINIMAL
THE HEMATOPOIESIS IS EVIDENT.

OVARIES

CYSTS :
UNILATERAL
ONE OR MORE CYSTS FILLED WITH CLEAR LIQUID ARE SEEN.

LEUKEMIC DEPOSITS :
CONTRALATERAL

BAYER AG

OVARIES CONTINUED
ORGAN AND THE BLOOD ARE INVADED BY LEUKEMIC CELLS.

UTERUS

LEUKEMIC DEPOSITS :
ORGAN AND THE BLOOD ARE INVADED BY LEUKEMIC CELLS.

AUTOLYSIS PARTIAL :
NO OTHER CHANGES ARE SEEN. TISSUES ARE ALTERED. BY POST-MORTEM MODIFICATIONS AND DIAGNOSIS IS GIVEN WITH RESERVATION.

LYMPH NODE

*** LYMPHOMA LYMPHOCYTIC :
THE NEOPLASM OF THE RETICULAR SYSTEM ORIGINATES FROM LYMPHOCYTES.

AUTOLYSIS PARTIAL :
NO OTHER CHANGES ARE SEEN. TISSUES ARE ALTERED. BY POST-MORTEM MODIFICATIONS AND DIAGNOSIS IS GIVEN WITH RESERVATION.

FEMALE 288 (1612/80)

BRAIN

FAT VACUOLES :
FOCAL
THE CELLS ARE DISTENDED BY CLEAR CYTOPLASMIC VACUOLES WHICH FREQUENTLY DISPLACE THE NUCLEI.

LUNG

*** ALVEOLOGENIC CARCINOMA :
MULTIFOCAL
A MALIGNANT TUMOR OF THE LUNG TISSUE WITH SYNONYMS IN MICE FOR ADENOMA, CARCINOMA, ALVEOLOGENIC PAPILLARY CARCINOMA, PAPILLARY CYSTADENOMA, ADENOCARCINOMA, BRONCHIOLAR CELL CARCINOMA, BRONCHIOLAR-ALVEOLAR TUMOR, TYPE A TUMOR, TYPE B TUMOR, INTERMEDIATE TYPE I TUMOR AND COMMON PULMONARY TUMOR OF THE MOUSE.

STOMACH

AUTOLYSIS PARTIAL :
NO OTHER CHANGES ARE SEEN. TISSUES ARE ALTERED. BY POST-MORTEM MODIFICATIONS AND DIAGNOSIS IS GIVEN WITH RESERVATION.

LIVER

LEUKEMIC DEPOSITS :
ORGAN AND THE BLOOD ARE INVADED BY LEUKEMIC CELLS.

PANCREAS

AUTOLYSIS :
THE TISSUES EXHIBIT AUTOLYSIS AND THEY ARE NOT INTERPRETABLE.

SPLEEN

HEMORRHAGE :
FOCAL
THERE IS EXTRAVASATION OF BLOOD.

*** LYMPHOMA LYMPHOCYTIC :
THE NEOPLASM OF THE RETICULAR SYSTEM ORIGINATES FROM LYMPHOCYTES.

AUTOLYSIS PARTIAL :
NO OTHER CHANGES ARE SEEN. TISSUES ARE ALTERED. BY POST-MORTEM MODIFICATIONS AND DIAGNOSIS IS GIVEN WITH RESERVATION.

KIDNEYS

LEUKEMIC DEPOSITS :
ORGAN AND THE BLOOD ARE INVADED BY LEUKEMIC CELLS.

BLADDER

AUTOLYSIS PARTIAL :
NO OTHER CHANGES ARE SEEN. TISSUES ARE ALTERED. BY POST-MORTEM MODIFICATIONS AND DIAGNOSIS IS GIVEN WITH RESERVATION.

ADRENALS

LEUKEMIC DEPOSITS :
ORGAN AND THE BLOOD ARE INVADED BY LEUKEMIC CELLS.

SCIATIC NERVE

ABSENT :
ORGAN OR TISSUE NOT REMOVED FROM ANIMAL OR NOT FOUND IN FIXATIVE.

MESENTERY

LEUKEMIC DEPOSITS :
ORGAN AND THE BLOOD ARE INVADED BY LEUKEMIC CELLS.

OVARIES

ATROPHY :
BILATERAL

BAYER AG

OVARIES CONTINUED
THE ORGAN IS REDUCED IN SIZE.

HEMORRAGIC CYST :
UNILATERAL
ONE OR SEVERAL CAVITIES FILLED WITH BLOOD.

UTERUS

LEUKEMIC DEPOSITS :
ORGAN AND THE BLOOD ARE INVADED BY LEUKEMIC CELLS.

LYMPH NODE

*** LYMPHOMA LYMPHOCYTIC :
THE NEOPLASM OF THE RETICULAR SYSTEM ORIGINATES FROM LYMPHOCYTES.

FEMALE 289 (1811/80)

HEART

INFLAMMATION CHRONIC :
FOCAL
THE INTERSTITIAL TISSUES SHOW INFILTRATION BY MONONUCLEAR CELLS AND INCREASE IN FIBROUS STROMA.

PERICARDITIS :
THE PERICARDIUM IS THE SITE OF ACUTE OR CHRONIC INFLAMMATION.

LUNG

LEUKEMIC DEPOSITS :
ORGAN AND THE BLOOD ARE INVADED BY LEUKEMIC CELLS.

STOMACH

LEUKEMIC DEPOSITS :
ORGAN AND THE BLOOD ARE INVADED BY LEUKEMIC CELLS.

LIVER

*** ADENOMA HEPATIC BENIGN :
DISTINCT NODULES COMPRESS THE ADJACENT LIVER PARENCHYMA, ARE CHARACTERIZED BY WELL DIFFERENTIATED HEPATOCYTES AND DO NOT SHOW PORTAL TRIADS.

PANCREAS

LEUKEMIC DEPOSITS :
ORGAN AND THE BLOOD ARE INVADED BY LEUKEMIC

PANCREAS CONTINUED

CELLS.

SPLEEN

*** LYMPHOMA LYMPHOCYTIC :
THE NEOPLASM OF THE RETICULAR SYSTEM ORIGINATES FROM LYMPHOCYTES.

AUTOLYSIS PARTIAL :
NO OTHER CHANGES ARE SEEN. TISSUES ARE ALTERED. BY POST-MORTEM MODIFICATIONS AND DIAGNOSIS IS GIVEN WITH RESERVATION.

BLADDER

AUTOLYSIS PARTIAL :
NO OTHER CHANGES ARE SEEN. TISSUES ARE ALTERED. BY POST-MORTEM MODIFICATIONS AND DIAGNOSIS IS GIVEN WITH RESERVATION.

PITUITARY

ABSENT :
ORGAN OR TISSUE NOT REMOVED FROM ANIMAL OR NOT FOUND IN FIXATIVE.

ADRENALS

PIGMENTATION :
UNILATERAL MODERATE
NUMEROUS MACROPHAGES CONTAIN A GRANULAR BROWN CYTOPLASMIC PIGMENT.

SCIATIC NERVE

ABSENT :
ORGAN OR TISSUE NOT REMOVED FROM ANIMAL OR NOT FOUND IN FIXATIVE.

MESENTERY

LEUKEMIC DEPOSITS :
ORGAN AND THE BLOOD ARE INVADED BY LEUKEMIC CELLS.

OVARIES

ATROPHY :
BILATERAL
THE ORGAN IS REDUCED IN SIZE.

CYSTS :
UNILATERAL
ONE OR MORE CYSTS FILLED WITH CLEAR LIQUID ARE SEEN.

LYMPH NODE

*** LYMPHOMA LYMPHOCYTIC :
THE NEOPLASM OF THE RETICULAR SYSTEM ORIGINATES FROM LYMPHOCYTES.

BAYER AG

FEMALE 290 (1804/80)

LUNG

PNEUMONIA :
THE ALVEOLAR WALLS ARE THICKENED AND ALVEOLI CONTAIN INFLAMMATORY CELLS AND FOAMY MACROPHAGES.PERIVASCULAR AND PERIBRONCHIAL LYMPHOCYTIC ACCUMULATIONS MAY BE PRESENT.

*** ALVEOLOGENIC CARCINOMA :
A MALIGNANT TUMOR OF THE LUNG TISSUE WITH SYNONYMS IN MICE FOR ADENOMA, CARCINOMA, ALVEOLOGENIC PAPILLARY CARCINOMA, PAPILLARY CYSTADENOMA, ADENOCARCINOMA, BRONCHIOLAR CELL CARCINOMA, BRONCHIOLAR-ALVEOLAR TUMOR, TYPE A TUMOR, TYPE B TUMOR, INTERMEDIATE TYPE I TUMOR AND COMMON PULMONARY TUMOR OF THE MOUSE.

STOMACH

MUCOID CYST :
MINIMAL
ONE OR MORE CYSTS CONTAINING MUCOID MATERIAL ARE OBSERVED.

LIVER

LEUKEMIC DEPOSITS :
ORGAN AND THE BLOOD ARE INVADED BY LEUKEMIC CELLS.

PANCREAS

VACUOLIZATION :
MINIMAL
IN THESE CELLS THERE ARE CLEAR VACUOLES GREATER IN NUMBER AND SIZE THAN NORMALLY FOUND.

AUTOLYSIS PARTIAL :
NO OTHER CHANGES ARE SEEN. TISSUES ARE ALTERED. BY POST-MORTEM MODIFICATIONS AND DIAGNOSIS IS GIVEN WITH RESERVATION.

THYMUS

NECROSIS :
THE TISSUE HAS LOST ITS NORMAL STRUCTURE DUE TO CELL DEATH WHICH MAY BE OF VARIOUS ORIGIN.

*** THYMOMA :
TUMOR DEVELOPED IN THE THYMUS AND DERIVED FROM THE EPITHELIAL CELLS.

N.F2.42 FEMALE 290 CONTINUED

SPLEEN

HYPERPLASIA LYMPHOID :
THE LYMPHOID FOLLICLES ARE INCREASED IN SIZE.

HEMATOPOIESIS :
SEVERE
THE HEMATOPOIESIS IS EVIDENT.

KIDNEYS

INTERSTITIAL NEPHRITIS :
UNILATERAL MINIMAL MULTIFOCAL
INFLAMMATORY CELLS FIBROSIS AND SOME TUBULAR ALTERATIONS ARE ASSOCIATED.

ADRENALS

PIGMENTATION :
BILATERAL MINIMAL
NUMEROUS MACROPHAGES CONTAIN A GRANULAR BROWN CYTOPLASMIC PIGMENT.

BONE

*** OSTEOMA :
THIS BENIGN WELL CIRCUMSCRIBED TUMOR IS COMPOSED OF WELL-DEVELOPED BONE.

OVARIES

ATROPHY :
BILATERAL
THE ORGAN IS REDUCED IN SIZE.

CYSTS :
UNILATERAL
ONE OR MORE CYSTS FILLED WITH CLEAR LIQUID ARE SEEN.

FEMALE 292 (1801/80)

HEART

CONGESTION :
VESSELS OR SINUSOIDS ARE MARKEDLY DISTENDED WITH ERYTHROCYTES.

LIVER

MONONUCLEAR CELLS :
MINIMAL MULTIFOCAL
FOCAL COLLECTIONS OF MONONUCLEAR CELLS ARE PRESENT.

BAYER AG

SPLEEN

HEMATOPOIESIS :
SEVERE
THE HEMATOPOIESIS IS EVIDENT.

KIDNEYS

INTERSTITIAL NEPHRITIS :
BILATERAL MINIMAL
INFLAMMATORY CELLS FIBROSIS AND SOME TUBULAR ALTERATIONS ARE ASSOCIATED.

BLADDER

UNREADABLE :
IT IS NOT POSSIBLE TO INTERPRET THE SECTION DUE TO AN ARTIFACT CAUSED BY SAMPLING OR HISTOLOGICAL TECHNIQUE.

SKIN

FIBROSIS :
THERE IS AN INCREASE IN INTERSTITIAL FIBROUS TISSUE.

INFLAMMATION CHRONIC :
THE INTERSTITIAL TISSUES SHOW INFILTRATION BY MONONUCLEAR CELLS AND INCREASE IN FIBROUS STROMA.

OVARIES

*** LUTEOMA :
UNILATERAL
IT IS A BENIGN TUMOR COMPOSED OF CELLS RESEMBLING THOSE OF THE CORPUS LUTEUM.

ATROPHY :
CONTRALATERAL
THE ORGAN IS REDUCED IN SIZE.

CYSTS :
CONTRALATERAL
ONE OR MORE CYSTS FILLED WITH CLEAR LIQUID ARE SEEN.

FEMUR

INFLAMMATION CHRONIC :
THE INTERSTITIAL TISSUES SHOW INFILTRATION BY MONONUCLEAR CELLS AND INCREASE IN FIBROUS STROMA.

FEMALE 293 (1784/80)

HEART

CONGESTION :
VESSELS OR SINUSOIDS ARE MARKEDLY DISTENDED WITH

HEART CONTINUED

ERYTHROCYTES.

LUNG

HEMORRHAGE :
THERE IS EXTRAVASATION OF BLOOD.

CONGESTION :
VESSELS OR SINUSOIDS ARE MARKEDLY DISTENDED WITH ERYTHROCYTES.

STOMACH

AUTOLYSIS PARTIAL :
NO OTHER CHANGES ARE SEEN. TISSUES ARE ALTERED. BY POST-MORTEM MODIFICATIONS AND DIAGNOSIS IS GIVEN WITH RESERVATION.

LIVER

CONGESTION :
VESSELS OR SINUSOIDS ARE MARKEDLY DISTENDED WITH ERYTHROCYTES.

PANCREAS

AUTOLYSIS PARTIAL :
NO OTHER CHANGES ARE SEEN. TISSUES ARE ALTERED. BY POST-MORTEM MODIFICATIONS AND DIAGNOSIS IS GIVEN WITH RESERVATION.

THYMUS

*** LYMPHOMA LYMPHOCYTIC :
THE NEOPLASM OF THE RETICULAR SYSTEM ORIGINATES FROM LYMPHOCYTES.

SPLEEN

HEMATOPOIESIS :
MINIMAL
THE HEMATOPOIESIS IS EVIDENT.

KIDNEYS

AUTOLYSIS PARTIAL :
NO OTHER CHANGES ARE SEEN. TISSUES ARE ALTERED. BY POST-MORTEM MODIFICATIONS AND DIAGNOSIS IS GIVEN WITH RESERVATION.

BLADDER

AUTOLYSIS PARTIAL :
NO OTHER CHANGES ARE SEEN. TISSUES ARE ALTERED. BY POST-MORTEM MODIFICATIONS AND DIAGNOSIS IS GIVEN WITH RESERVATION.

THYROIDS

ABSENT :
ORGAN OR TISSUE NOT REMOVED FROM ANIMAL OR NOT FOUND IN

BAYER AG

NF2.45 FEMALE 293 CONTINUED

THYROIDS CONTINUED
FIXATIVE.

FEMALE 294 (1796/60)

BRAIN

ABSENT :
ORGAN OR TISSUE NOT REMOVED FROM ANIMAL OR NOT FOUND IN FIXATIVE.

LUNG

EDEMA :
THE INTERSTITIAL TISSUES CONTAIN AN INCREASED AMOUNT OF FLUID.

LEUKOCYTOSIS :
THERE IS AN INCREASE IN LEUKOCYTES.

STOMACH

AUTOLYSIS PARTIAL :
NO OTHER CHANGES ARE SEEN. TISSUES ARE ALTERED.
BY POST-MORTEM MODIFICATIONS AND
DIAGNOSIS IS GIVEN WITH RESERVATION.

LIVER

LEUKEMIC DEPOSITS :
ORGAN AND THE BLOOD ARE INVADED BY LEUKEMIC CELLS.

AUTOLYSIS PARTIAL :
NO OTHER CHANGES ARE SEEN. TISSUES ARE ALTERED.
BY POST-MORTEM MODIFICATIONS AND
DIAGNOSIS IS GIVEN WITH RESERVATION.

PANCREAS

AUTOLYSIS :
THE TISSUES EXHIBIT AUTOLYSIS AND THEY ARE NOT INTERPRETABLE.

SPLEEN

*** LYMPHOMA LYMPHOCYTIC :
THE NEOPLASM OF THE RETICULAR SYSTEM ORIGINATES FROM LYMPHOCYTES.

AUTOLYSIS PARTIAL :
NO OTHER CHANGES ARE SEEN. TISSUES ARE ALTERED.
BY POST-MORTEM MODIFICATIONS AND
DIAGNOSIS IS GIVEN WITH RESERVATION.

KIDNEYS

LEUKEMIC DEPOSITS :
ORGAN AND THE BLOOD ARE INVADED BY LEUKEMIC CELLS.

AUTOLYSIS PARTIAL :
NO OTHER CHANGES ARE SEEN. TISSUES ARE ALTERED. BY POST-MORTEM MODIFICATIONS AND DIAGNOSIS IS GIVEN WITH RESERVATION.

BLADDER

AUTOLYSIS PARTIAL :
NO OTHER CHANGES ARE SEEN. TISSUES ARE ALTERED. BY POST-MORTEM MODIFICATIONS AND DIAGNOSIS IS GIVEN WITH RESERVATION.

THYROIDS

ABSENT :
ORGAN OR TISSUE NOT REMOVED FROM ANIMAL OR NOT FOUND IN FIXATIVE.

MESENTERY

LEUKEMIC DEPOSITS :
ORGAN AND THE BLOOD ARE INVADED BY LEUKEMIC CELLS.

OVARIES

AUTOLYSIS PARTIAL :
NO OTHER CHANGES ARE SEEN. TISSUES ARE ALTERED. BY POST-MORTEM MODIFICATIONS AND DIAGNOSIS IS GIVEN WITH RESERVATION.

FEMALE 297 (1793/80)

BRAIN

AUTOLYSIS :
THE TISSUES EXHIBIT AUTOLYSIS AND THEY ARE NOT INTERPRETABLE.

HEART

CONGESTION :
VESSELS OR SINUSOIDS ARE MARKEDLY DISTENDED WITH ERYTHROCYTES.

LUNG

AUTOLYSIS :
THE TISSUES EXHIBIT AUTOLYSIS AND THEY ARE NOT

LUNG CONTINUED

INTERPRETABLE.

STOMACH

AUTOLYSIS :
THE TISSUES EXHIBIT AUTOLYSIS AND THEY ARE NOT INTERPRETABLE.

LIVER

AUTOLYSIS :
THE TISSUES EXHIBIT AUTOLYSIS AND THEY ARE NOT INTERPRETABLE.

PANCREAS

AUTOLYSIS :
THE TISSUES EXHIBIT AUTOLYSIS AND THEY ARE NOT INTERPRETABLE.

SPLEEN

AUTOLYSIS :
THE TISSUES EXHIBIT AUTOLYSIS AND THEY ARE NOT INTERPRETABLE.

KIDNEYS

AUTOLYSIS PARTIAL :
NO OTHER CHANGES ARE SEEN. TISSUES ARE ALTERED.
BY POST-MORTEM MODIFICATIONS AND
DIAGNOSIS IS GIVEN WITH RESERVATION.

BLADDER

AUTOLYSIS :
THE TISSUES EXHIBIT AUTOLYSIS AND THEY ARE NOT INTERPRETABLE.

PITUITARY

AUTOLYSIS :
THE TISSUES EXHIBIT AUTOLYSIS AND THEY ARE NOT INTERPRETABLE.

THYROIDS

ABSENT :
ORGAN OR TISSUE NOT REMOVED FROM ANIMAL OR NOT FOUND IN FIXATIVE.

ADRENALS

AUTOLYSIS :
THE TISSUES EXHIBIT AUTOLYSIS AND THEY ARE NOT INTERPRETABLE.

OVARIES

AUTOLYSIS :
THE TISSUES EXHIBIT AUTOLYSIS AND THEY ARE NOT

OVARIES CONTINUED
INTERPRETABLE.

FEMALE 298 (1796/60)

LUNG

PNEUMONIA :
THE ALVEOLAR WALLS ARE THICKENED AND ALVEOLI CONTAIN INFLAMMATORY CELLS AND FOAMY MACROPHAGES.PERIVASCULAR AND PERIBRONCHIAL LYMPHOCYTIC ACCUMULATIONS MAY BE PRESENT.

*** ALVEOLOGENIC CARCINOMA :
A MALIGNANT TUMOR OF THE LUNG TISSUE WITH SYNONYMS IN MICE FOR ADENOMA, CARCINOMA, ALVEOLOGENIC PAPILLARY CARCINOMA, PAPILLARY CYSTADENOMA, ADENOCARCINOMA, BRONCHIOLAR CELL CARCINOMA, BRONCHIOLAR-ALVEOLAR TUMOR, TYPE A TUMOR, TYPE B TUMOR, INTERMEDIATE TYPE I TUMOR AND COMMON PULMONARY TUMOR OF THE MOUSE.

LIVER

LEUKEMIC DEPOSITS :
ORGAN AND THE BLOOD ARE INVADED BY LEUKEMIC CELLS.

PANCREAS

LEUKEMIC DEPOSITS :
ORGAN AND THE BLOOD ARE INVADED BY LEUKEMIC CELLS.

SPLEEN

NORMAL :
HISTOLOGICAL ASPECT WITHIN NORMAL LIMITS.

KIDNEYS

TUBULOPATHY :
BILATERAL SEVERE
TUBULAR DEGENERATIVE CHANGES ARE PRESENT WHICH MAY BE ASSOCIATED WITH TUBULAR DILATATION.

PITUITARY

ABSENT :
ORGAN OR TISSUE NOT REMOVED FROM ANIMAL OR NOT FOUND IN FIXATIVE.

THYROIDS

ABSENT :

BAYER AG

THYROIDS CONTINUED

ORGAN OR TISSUE NOT REMOVED FROM ANIMAL OR NOT FOUND IN FIXATIVE.

SKELETAL MUSCLE

LEUKEMIC DEPOSITS :
ORGAN AND THE BLOOD ARE INVADED BY LEUKEMIC CELLS.

MESENTERY

LEUKEMIC DEPOSITS :
ORGAN AND THE BLOOD ARE INVADED BY LEUKEMIC CELLS.

OVARIES

CYSTS :
UNILATERAL
ONE OR MORE CYSTS FILLED WITH CLEAR LIQUID ARE SEEN.

DIAPHRAGM

LEUKEMIC DEPOSITS :
ORGAN AND THE BLOOD ARE INVADED BY LEUKEMIC CELLS.

LYMPH NODE

*** LYMPHOMA LYMPHOCYTIC :
THE NEOPLASM OF THE RETICULAR SYSTEM ORIGINATES FROM LYMPHOCYTES.

FEMALE 300 (1813/80)

BRAIN

GLIOSIS :
MINIMAL MULTIFOCAL
THERE IS PROLIFERATION OF GLIAL CELLS.

HEART

CONGESTION :
VESSELS OR SINUSOIDS ARE MARKEDLY DISTENDED WITH ERYTHROCYTES.

LUNG

*** ALVEOLOGENIC CARCINOMA :
MULTIFOCAL
A MALIGNANT TUMOR OF THE LUNG TISSUE WITH SYNONYMS IN MICE FOR ADENOMA, CARCINOMA, ALVEOLOGENIC PAPILLARY CARCINOMA, PAPILLARY

LUNG CONTINUED

CYSTADENOMA, ADENOCARCINOMA, BRONCHIOLAR CELL CARCINOMA, BRONCHIOLAR-ALVEOLAR TUMOR, TYPE A TUMOR, TYPE B TUMOR, INTERMEDIATE TYPE I TUMOR AND COMMON PULMONARY TUMOR OF THE MOUSE.

LIVER

CONGESTION :
VESSELS OR SINUSOIDS ARE MARKEDLY DISTENDED WITH ERYTHROCYTES.

KIDNEYS

CONGESTION :
VESSELS OR SINUSOIDS ARE MARKEDLY DISTENDED WITH ERYTHROCYTES.

BLADDER

AUTOLYSIS PARTIAL :
NO OTHER CHANGES ARE SEEN. TISSUES ARE ALTERED. BY POST-MORTEM MODIFICATIONS AND DIAGNOSIS IS GIVEN WITH RESERVATION.

PITUITARY

ABSENT :
ORGAN OR TISSUE NOT REMOVED FROM ANIMAL OR NOT FOUND IN FIXATIVE.

ADRENALS

PIGMENTATION :
BILATERAL MODERATE
NUMEROUS MACROPHAGES CONTAIN A GRANULAR BROWN CYTOPLASMIC PIGMENT.

OVARIES

HEMORRHAGE :
BILATERAL
THERE IS EXTRAVASATION OF BLOOD.

ATROPHY :
BILATERAL
THE ORGAN IS REDUCED IN SIZE.

BAYER AG BAYER AG BAYER AG

SF3. 1 CHRONIC TOXICITY STUDY IN MICE: SYSTEMATIC

HISTOPATHOLOGY

PRODUCT : CHG 05.9 GROUP : 3
ROUTE : DIETARY
TIME : 105 WEEKS DOSE : 2000 PPM
THIS GROUP COMPRISED : 19 FEMALES

THE FOLLOWING ORGANS WERE EXAMINED SYSTEMATICALLY :

HEART	LUNG	LIVER
PANCREAS	SPLEEN	KIDNEYS
BLADDER	STOMACH	OVARIES
THYROIDS	ADRENALS	PITUITARY
BRAIN	SKELETAL MUSCLE	SCIATIC NERVE
FEMUR		

THESE ORGANS WERE EXAMINED IN 19 FEMALES

INDIVIDUAL RESULTS

IN THE ANIMALS SHOWN BELOW THE HISTOLOGICAL EXAMINATION OF THE ORGANS LISTED OR OF THE ANOMALIES FOUND AT AUTOPSY GAVE THE FOLLOWING RESULTS :

FEMALE 351 (1569/80)

LUNG

PNEUMONIA :
THE ALVEOLAR WALLS ARE THICKENED AND ALVEOLI CONTAIN INFLAMMATORY CELLS AND FOAMY MACROPHAGES.PERIVASCULAR AND PERIBRONCHIAL LYMPHOCYTIC ACCUMULATIONS MAY BE PRESENT.

LIVER

FAT VACUOLES :
THE CELLS ARE DISTENDED BY CLEAR CYTOPLASMIC VACUOLES WHICH FREQUENTLY DISPLACE THE NUCLEI.

MONONUCLEAR CELLS :
FOCAL COLLECTIONS OF MONONUCLEAR CELLS ARE PRESENT.

HEPATOCYTIC HYPERPIGMENTATION :
HEPATOCYTES ARE LADEN WITH GRANULES OF HEMOSIDERIN OR BILE OR OTHER PIGMENT.

HYPERPLASTIC NODULES :
WELL DEFINED ROUNDED FOCI OF HYPERPLASTIC AND HYPERTROPHIC CELLS ARE OBSERVED WITHIN THIS OTHERWISE NORMAL TISSUE.

PANCREAS

INFLAMMATION CHRONIC :
THE INTERSTITIAL TISSUES SHOW INFILTRATION BY MONONUCLEAR CELLS AND INCREASE IN FIBROUS STROMA.

SPLEEN

HEMATOPOIESIS :
MODERATE
THE HEMATOPOIESIS IS EVIDENT.

ADRENALS

PIGMENTATION :
MINIMAL
NUMEROUS MACROPHAGES CONTAIN A GRANULAR BROWN CYTOPLASMIC PIGMENT.

OVARIES

ATROPHY :
BILATERAL
THE ORGAN IS REDUCED IN SIZE.

CYSTS :
CONTRALATERAL
ONE OR MORE CYSTS FILLED WITH CLEAR LIQUID ARE SEEN.

UTERUS

HYPERPLASIA SECRETORY :
THE DEVELOPED GLANDS AND/OR DUCTS CONTAIN A SECRETION

FEMALE 354 (1570/80)

LUNG

ATELECTASIS :
THERE IS COLLAPSE OF ALVEOLI.

THICKENED ALVEOLAR WALLS :
THICKNESS OF ALVEOLAR WALLS IS INCREASED BY INFLAMMATORY CELLS AND/OR INTERSTITIAL EDEMA.

SPLEEN

HEMATOPOIESIS :
MODERATE
THE HEMATOPOIESIS IS EVIDENT.

BLADDER

INFLAMMATION CHRONIC :
THERE IS AN INFILTRATION BY MONONUCLEAR CELLS IN THE MUCOSA AND SUBMUCOSA.

THYROIDS

ABSENT :

BAYER AG BAYER AG BAYER AG

SF3. 3 FEMALE 354 CONTINUED

THYROIDS CONTINUED

ORGAN OR TISSUE NOT REMOVED FROM ANIMAL OR NOT FOUND IN FIXATIVE.

OVARIES

ATROPHY :
BILATERAL
THE ORGAN IS REDUCED IN SIZE.

CYSTS :
UNILATERAL
ONE OR MORE CYSTS FILLED WITH CLEAR LIQUID ARE SEEN.

UTERUS

CYSTIC ENDOMETRIAL HYPERPLASIA :
THE ENDOMETRIAL GLANDS ARE INCREASED IN NUMBER AND SOME ARE DILATED OR CYSTIC.

FEMALE 357 (1571/80)

LUNG

PNEUMONIA :
THE ALVEOLAR WALLS ARE THICKENED AND ALVEOLI CONTAIN INFLAMMATORY CELLS AND FOAMY MACROPHAGES.PERIVASCULAR AND PERIBRONCHIAL LYMPHOCYTIC ACCUMULATIONS MAY BE PRESENT.

SPLEEN

HEMATOPOIESIS :
MINIMAL
THE HEMATOPOIESIS IS EVIDENT.

CONGESTION :
VESSELS OR SINUSOIDS ARE MARKEDLY DISTENDED WITH ERYTHROCYTES.

KIDNEYS

INTERSTITIAL NEPHRITIS :
BILATERAL
INFLAMMATORY CELLS FIBROSIS AND SOME TUBULAR ALTERATIONS ARE ASSOCIATED.

BLADDER

INFLAMMATION CHRONIC :
THERE IS AN INFILTRATION BY MONONUCLEAR CELLS IN THE MUCOSA AND SUBMUCOSA.

PITUITARY

ABSENT :

SF3. 4 FEMALE 357 CONTINUED

PITUITARY CONTINUED

ORGAN OR TISSUE NOT REMOVED FROM ANIMAL OR NOT FOUND IN FIXATIVE.

OVARIES

HEMORRAGIC CYST :
UNILATERAL
ONE OR SEVERAL CAVITIES FILLED WITH BLOOD.

UTERUS

CYSTIC ENDOMETRIAL HYPERPLASIA :
UNILATERAL
THE ENDOMETRIAL GLANDS ARE INCREASED IN NUMBER AND SOME ARE DILATED OR CYSTIC.

*** MESENCHYMAL TUMOR :
CONTRALATERAL
MALIGNANT TUMOR DERIVED FROM UNDIFFERENTIATED COMPONENTS OF CONNECTIVE TISSUE.

FEMALE 359 (1572/80)

LUNG

PNEUMONIA :
THE ALVEOLAR WALLS ARE THICKENED AND ALVEOLI CONTAIN INFLAMMATORY CELLS AND FOAMY MACROPHAGES. PERIVASCULAR AND PERIBRONCHIAL LYMPHOCYTIC ACCUMULATIONS MAY BE PRESENT.

STOMACH

MUCOID CYST :
ONE OR MORE CYSTS CONTAINING MUCOID MATERIAL ARE OBSERVED.

LIVER

FAT VACUOLES :
MINIMAL
THE CELLS ARE DISTENDED BY CLEAR CYTOPLASMIC VACUOLES WHICH FREQUENTLY DISPLACE THE NUCLEI.

PANCREAS

INFLAMMATION CHRONIC :
THE INTERSTITIAL TISSUES SHOW INFILTRATION BY MONONUCLEAR CELLS AND INCREASE IN FIBROUS STROMA.

SPLEEN

HEMATOPOIESIS :
SEVERE
THE HEMATOPOIESIS IS EVIDENT.

BAYER AG

KIDNEYS

TUBULOPATHY :
UNILATERAL
TUBULAR DEGENERATIVE CHANGES ARE PRESENT WHICH MAY BE ASSOCIATED WITH TUBULAR DILATATION.

ADRENALS

PIGMENTATION :
MINIMAL
NUMEROUS MACROPHAGES CONTAIN A GRANULAR BROWN CYTOPLASMIC PIGMENT.

OVARIES

ATROPHY :
BILATERAL
THE ORGAN IS REDUCED IN SIZE.

HEMORRAGIC CYST :
UNILATERAL
ONE OR SEVERAL CAVITIES FILLED WITH BLOOD.

UTERUS

HYPERPLASIA SECRETORY :
BILATERAL
THE DEVELOPED GLANDS AND/OR DUCTS CONTAIN A SECRETION

FEMALE 360 (1573/80)

LUNG

THICKENED ALVEOLAR WALLS :
THICKNESS OF ALVEOLAR WALLS IS INCREASED BY INFLAMMATORY CELLS AND/OR INTERSTITIAL EDEMA.

STOMACH

ABSENT :
ORGAN OR TISSUE NOT REMOVED FROM ANIMAL OR NOT FOUND IN FIXATIVE.

LIVER

MONONUCLEAR CELLS :
MINIMAL
FOCAL COLLECTIONS OF MONONUCLEAR CELLS ARE PRESENT.

SPLEEN

HEMATOPOIESIS :
SEVERE

SPLEEN CONTINUED
THE HEMATOPOIESIS IS EVIDENT.

KIDNEYS

INTERSTITIAL NEPHRITIS :
MINIMAL
INFLAMMATORY CELLS FIBROSIS AND SOME TUBULAR ALTERATIONS ARE ASSOCIATED.

BLADDER

INFLAMMATION CHRONIC :
MULTIFOCAL
THERE IS AN INFILTRATION BY MONONUCLEAR CELLS IN THE MUCOSA AND SUBMUCOSA.

THYROIDS

CYSTS :
MINIMAL
ONE OR MORE CYSTS FILLED WITH CLEAR LIQUID ARE SEEN.

OVARIES

CYSTS :
UNILATERAL
ONE OR MORE CYSTS FILLED WITH CLEAR LIQUID ARE SEEN.

UTERUS

CYSTIC ENDOMETRIAL HYPERPLASIA :
CONTRALATERAL
THE ENDOMETRIAL GLANDS ARE INCREASED IN NUMBER AND SOME ARE DILATED OR CYSTIC.

*** LEIOMYOSARCOMA
UNILATERAL
MALIGNANT TUMOR DERIVED FROM SMOOTH MUSCLE FIBERS.

FEMUR

HEMATOPOIESIS :
THE HEMATOPOIESIS IS EVIDENT.

FEMALE 367 (1574/80)

LUNG

PNEUMONIA :
THE ALVEOLAR WALLS ARE THICKENED AND ALVEOLI CONTAIN INFLAMMATORY CELLS AND FOAMY MACROPHAGES.PERIVASCULAR AND PERIBRONCHIAL LYMPHOCYTIC ACCUMULATIONS MAY BE PRESENT.

BAYER AG

LIVER

*** ADENOMA HEPATIC BENIGN :
DISTINCT NODULES COMPRESS THE ADJACENT LIVER PARENCHYMA, ARE CHARACTERIZED BY WELL DIFFERENTIATED HEPATOCYTES AND DO NOT SHOW PORTAL TRIADS.

SPLEEN

HEMATOPOIESIS :
SEVERE
THE HEMATOPOIESIS IS EVIDENT.

KIDNEYS

INTERSTITIAL NEPHRITIS :
MINIMAL
INFLAMMATORY CELLS FIBROSIS AND SOME TUBULAR ALTERATIONS ARE ASSOCIATED.

BLADDER

INFLAMMATION GRANULOMATOUS :
THERE IS A FOCAL GRANULOMATOUS PROCESS CHARACTERIZED BY MONONUCLEAR AND MULTINUCLEATED CELLULAR INFILTRATION.

ADRENALS

FAT VACUOLES :
UNILATERAL
THE CELLS ARE DISTENDED BY CLEAR CYTOPLASMIC VACUOLES WHICH FREQUENTLY DISPLACE THE NUCLEI.

PIGMENTATION :
BILATERAL
NUMEROUS MACROPHAGES CONTAIN A GRANULAR BROWN CYTOPLASMIC PIGMENT.

SCIATIC NERVE

ABSENT :
ORGAN OR TISSUE NOT REMOVED FROM ANIMAL OR NOT FOUND IN FIXATIVE.

OVARIES

ATROPHY :
BILATERAL
THE ORGAN IS REDUCED IN SIZE.

HEMORRAGIC CYST :
UNILATERAL
ONE OR SEVERAL CAVITIES FILLED WITH BLOOD.

UTERUS

CYSTIC ENDOMETRIAL HYPERPLASIA :
MINIMAL
THE ENDOMETRIAL GLANDS ARE INCREASED IN NUMBER AND SOME ARE DILATED OR CYSTIC.

FEMALE 368 (1575/80)

LUNG

PNEUMONIA :
THE ALVEOLAR WALLS ARE THICKENED AND ALVEOLI CONTAIN INFLAMMATORY CELLS AND FOAMY MACROPHAGES.PERIVASCULAR AND PERIBRONCHIAL LYMPHOCYTIC ACCUMULATIONS MAY BE PRESENT.

SPLEEN

HEMATOPOIESIS :
MINIMAL
THE HEMATOPOIESIS IS EVIDENT.

OVARIES

ATROPHY :
BILATERAL
THE ORGAN IS REDUCED IN SIZE.

CYSTIC FOLLICLE :
UNILATERAL
ONE OR SEVERAL CYSTIC FOLLICLES ARE OBSERVED.

UTERUS

HYPERPLASIA SECRETORY :
BILATERAL
THE DEVELOPED GLANDS AND/OR DUCTS CONTAIN A SECRETION

FEMALE 375 (1576/80)

LUNG

PNEUMONIA :
THE ALVEOLAR WALLS ARE THICKENED AND ALVEOLI CONTAIN INFLAMMATORY CELLS AND FOAMY MACROPHAGES.PERIVASCULAR AND PERIBRONCHIAL LYMPHOCYTIC ACCUMULATIONS MAY BE PRESENT.

LIVER

INFARCT :
AN AREA OF ISCHEMIC NECROSIS DUE TO VASCULAR OCCLUSION IS PRESENT.

THROMBOSIS :

BAYER AG

LIVER CONTINUED

THE VASCULAR LUMEN CONTAINS AN ATTACHED ANTE MORTEM BLOOD CLOT.

*** ADENOMA HEPATIC BENIGN :
DISTINCT NODULES COMPRESS THE ADJACENT LIVER PARENCHYMA, ARE CHARACTERIZED BY WELL DIFFERENTIATED HEPATOCYTES AND DO NOT SHOW PORTAL TRIADS.

CONGESTION :
VESSELS OR SINUSOIDS ARE MARKEDLY DISTENDED WITH ERYTHROCYTES.

SPLEEN

HEMATOPOIESIS :
SEVERE
THE HEMATOPOIESIS IS EVIDENT.

KIDNEYS

INTERSTITIAL NEPHRITIS :
MINIMAL MULTIFOCAL
INFLAMMATORY CELLS FIBROSIS AND SOME TUBULAR ALTERATIONS ARE ASSOCIATED.

BLADDER

ABSENT :
ORGAN OR TISSUE NOT REMOVED FROM ANIMAL OR NOT FOUND IN FIXATIVE.

PITUITARY

ABSENT :
ORGAN OR TISSUE NOT REMOVED FROM ANIMAL OR NOT FOUND IN FIXATIVE.

ADRENALS

PIGMENTATION :
NUMEROUS MACROPHAGES CONTAIN A GRANULAR BROWN CYTOPLASMIC PIGMENT.

OVARIES

ATROPHY :
BILATERAL
THE ORGAN IS REDUCED IN SIZE.

FEMALE 377 (1577/80)

LUNG

PNEUMONIA :

LUNG CONTINUED

THE ALVEOLAR WALLS ARE THICKENED AND ALVEOLI CONTAIN INFLAMMATORY CELLS AND FOAMY MACROPHAGES.PERIVASCULAR AND PERIBRONCHIAL LYMPHOCYTIC ACCUMULATIONS MAY BE PRESENT.

LIVER

*** ADENOMA HEPATIC BENIGN :
DISTINCT NODULES COMPRESS THE ADJACENT LIVER PARENCHYMA, ARE CHARACTERIZED BY WELL DIFFERENTIATED HEPATOCYTES AND DO NOT SHOW PORTAL TRIADS.

KIDNEYS

INTERSTITIAL NEPHRITIS :
MINIMAL MULTIFOCAL
INFLAMMATORY CELLS FIBROSIS AND SOME TUBULAR ALTERATIONS ARE ASSOCIATED.

ADRENALS

PIGMENTATION :
BILATERAL SEVERE
NUMEROUS MACROPHAGES CONTAIN A GRANULAR BROWN CYTOPLASMIC PIGMENT.

OVARIES

ATROPHY :
BILATERAL
THE ORGAN IS REDUCED IN SIZE.

CYSTS :
BILATERAL
ONE OR MORE CYSTS FILLED WITH CLEAR LIQUID ARE SEEN.

UTERUS

ENDOMETRIOSIS :
BILATERAL
ENDOMETRIAL GLANDS ARE SEEN AT VARIOUS SITES OUTSIDE THE NORMAL ENDOMETRIUM.

FEMALE 378 (1578/80)

LUNG

PNEUMONIA :
THE ALVEOLAR WALLS ARE THICKENED AND ALVEOLI CONTAIN INFLAMMATORY CELLS AND FOAMY MACROPHAGES.PERIVASCULAR AND PERIBRONCHIAL LYMPHOCYTIC ACCUMULATIONS MAY BE PRESENT.

*** ALVEOLOGENIC CARCINOMA :
A MALIGNANT TUMOR OF THE LUNG TISSUE WITH SYNONYMS IN MICE FOR ADENOMA, CARCINOMA,

BAYER AG

LUNG CONTINUED

ALVEOLOGENIC PAPILLARY CARCINOMA, PAPILLARY CYSTADENOMA, ADENOCARCINOMA, BRONCHIOLAR CELL CARCINOMA, BRONCHIOLAR-ALVEOLAR TUMOR, TYPE A TUMOR, TYPE B TUMOR, INTERMEDIATE TYPE I TUMOR AND COMMON PULMONARY TUMOR OF THE MOUSE.

OVARIES

CYSTS :
BILATERAL
ONE OR MORE CYSTS FILLED WITH CLEAR LIQUID ARE SEEN.

UTERUS

HYPERPLASIA SECRETORY :
BILATERAL
THE DEVELOPED GLANDS AND/OR DUCTS CONTAIN A SECRETION

FEMALE 379 (1579/80)

LUNG

ATELECTASIS :
THERE IS COLLAPSE OF ALVEOLI.

STOMACH

INFLAMMATION CHRONIC :
THERE IS AN INFILTRATION BY MONONUCLEAR CELLS IN THE MUCOSA AND SUBMUCOSA.

LIVER

HEPATOCYTIC HYPERPIGMENTATION :
MINIMAL
HEPATOCYTES ARE LADEN WITH GRANULES OF HEMOSIDERIN OR BILE OR OTHER PIGMENT.

SPLEEN

HEMATOPOIESIS :
MINIMAL
THE HEMATOPOIESIS IS EVIDENT.

ADRENALS

PIGMENTATION :
BILATERAL SEVERE
NUMEROUS MACROPHAGES CONTAIN A GRANULAR BROWN CYTOPLASMIC PIGMENT.

FEMALE 379 CONTINUED 514

OVARIES

CYSTS :
UNILATERAL
ONE OR MORE CYSTS FILLED WITH CLEAR LIQUID ARE SEEN.

UTERUS

HYPERPLASIA SECRETORY :
BILATERAL
THE DEVELOPED GLANDS AND/OR DUCTS CONTAIN A SECRETION

FEMUR

ABSENT :
ORGAN OR TISSUE NOT REMOVED FROM ANIMAL OR NOT FOUND IN FIXATIVE.

FEMALE 383 (1580/80)

LUNG

PNEUMONIA :
THE ALVEOLAR WALLS ARE THICKENED AND ALVEOLI CONTAIN INFLAMMATORY CELLS AND FOAMY MACROPHAGES.PERIVASCULAR AND PERIBRONCHIAL LYMPHOCYTIC ACCUMULATIONS MAY BE PRESENT.

*** ALVEOLOGENIC CARCINOMA :
MULTIFOCAL
A MALIGNANT TUMOR OF THE LUNG TISSUE WITH SYNONYMS IN MICE FOR ADENOMA, CARCINOMA, ALVEOLOGENIC PAPILLARY CARCINOMA, PAPILLARY CYSTADENOMA, ADENOCARCINOMA, BRONCHIOLAR CELL CARCINOMA, BRONCHIOLAR-ALVEOLAR TUMOR, TYPE A TUMOR, TYPE B TUMOR, INTERMEDIATE TYPE I TUMOR AND COMMON PULMONARY TUMOR OF THE MOUSE.

KIDNEYS

INTERSTITIAL NEPHRITIS :
MINIMAL MULTIFOCAL
INFLAMMATORY CELLS FIBROSIS AND SOME TUBULAR ALTERATIONS ARE ASSOCIATED.

OVARIES

ATROPHY :
BILATERAL
THE ORGAN IS REDUCED IN SIZE.

UTERUS

CYSTIC ENDOMETRIAL HYPERPLASIA :
BILATERAL

BAYER AG

UTERUS CONTINUED

THE ENDOMETRIAL GLANDS ARE INCREASED IN NUMBER AND SOME ARE DILATED OR CYSTIC.

FEMALE 384 (1581/80)

LUNG

*** ALVEOLOGENIC CARCINOMA :
A MALIGNANT TUMOR OF THE LUNG TISSUE WITH SYNONYMS IN MICE FOR ADENOMA, CARCINOMA, ALVEOLOGENIC PAPILLARY CARCINOMA, PAPILLARY CYSTADENOMA, ADENOCARCINOMA, BRONCHIOLAR CELL CARCINOMA, BRONCHIOLAR-ALVEOLAR TUMOR, TYPE A TUMOR, TYPE B TUMOR, INTERMEDIATE TYPE I TUMOR AND COMMON PULMONARY TUMOR OF THE MOUSE.

KIDNEYS

INTERSTITIAL NEPHRITIS :
MINIMAL MULTIFOCAL
INFLAMMATORY CELLS FIBROSIS AND SOME TUBULAR ALTERATIONS ARE ASSOCIATED.

BLADDER

PERIARTERITIS :
NON SPECIFIC INFLAMMATION (ACUTE SUBACUTE OR CHRONIC) OF THE TUNICA ADVENTITIA (PERIVASCULAR GRANULOMA).

PITUITARY

ABSENT :
ORGAN OR TISSUE NOT REMOVED FROM ANIMAL OR NOT FOUND IN FIXATIVE.

OVARIES

CYSTS :
UNILATERAL
ONE OR MORE CYSTS FILLED WITH CLEAR LIQUID ARE SEEN.

UTERUS

ENDOMETRIOSIS :
BILATERAL
ENDOMETRIAL GLANDS ARE SEEN AT VARIOUS SITES OUTSIDE THE NORMAL ENDOMETRIUM.

FEMALE 386 (1562/80)

BRAIN

CALCIFICATION :
THERE ARE MINERAL DEPOSITS.

LUNG

PNEUMONIA :
THE ALVEOLAR WALLS ARE THICKENED AND ALVEOLI CONTAIN INFLAMMATORY CELLS AND FOAMY MACROPHAGES. PERIVASCULAR AND PERIBRONCHIAL LYMPHOCYTIC ACCUMULATIONS MAY BE PRESENT.

LIVER

MONONUCLEAR CELLS :
MINIMAL
FOCAL COLLECTIONS OF MONONUCLEAR CELLS ARE PRESENT.

SPLEEN

HYPERTROPHY :
THE SIZE OF THE ORGAN IS INCREASED WITHOUT STRUCTURAL ANOMALY.

KIDNEYS

INTERSTITIAL NEPHRITIS :
MINIMAL MULTIFOCAL
INFLAMMATORY CELLS FIBROSIS AND SOME TUBULAR ALTERATIONS ARE ASSOCIATED.

BLADDER

INFLAMMATION CHRONIC :
THERE IS AN INFILTRATION BY MONONUCLEAR CELLS IN THE MUCOSA AND SUBMUCOSA.

SCIATIC NERVE

ABSENT :
ORGAN OR TISSUE NOT REMOVED FROM ANIMAL OR NOT FOUND IN FIXATIVE.

MESENTERY

PERITONITIS :
THE SEROSA IS COVERED BY EXUDATE SHOWING ORGANIZATION AND INFLAMMATION.

OVARIES

CYSTS :
BILATERAL

BAYER AG

OVARIES CONTINUED
ONE OR MORE CYSTS FILLED WITH CLEAR LIQUID ARE SEEN.

UTERUS

*** ADENOMA :
UNILATERAL
THIS IS BENIGN GLANDULAR EPITHELIAL TUMOR.

FEMALE 389 (1583/80)

LUNG

ATELECTASIS :
THERE IS COLLAPSE OF ALVEOLI.

LIVER

HYPERPLASTIC NODULE :
A NODULE OF HYPERPLASTIC TISSUE IS PRESENT.

PITUITARY

HEMORRAGIC CYST :
ONE OR SEVERAL CAVITIES FILLED WITH BLOOD.

THYROIDS

ABSENT :
ORGAN OR TISSUE NOT REMOVED FROM ANIMAL OR NOT FOUND IN FIXATIVE.

OVARIES

ATROPHY :
BILATERAL
THE ORGAN IS REDUCED IN SIZE.

UTERUS

HYPERPLASIA SECRETORY :
THE DEVELOPED GLANDS AND/OR DUCTS CONTAIN A SECRETION

FEMALE 391 (158A/80)

LUNG

*** ALVEOLOGENIC CARCINOMA :
MULTIFOCAL
A MALIGNANT TUMOR OF THE LUNG TISSUE WITH SYNONYMS IN MICE FOR ADENOMA, CARCINOMA, ALVEOLOGENIC PAPILLARY CARCINOMA, PAPILLARY CYSTADENOMA, ADENOCARCINOMA, BRONCHIOLAR CELL CARCINOMA, BRONCHIOLAR-ALVEOLAR TUMOR, TYPE A TUMOR, TYPE B TUMOR, INTERMEDIATE TYPE I TUMOR AND COMMON PULMONARY TUMOR OF THE MOUSE.

STOMACH

MUCOID CYST :
MINIMAL
ONE OR MORE CYSTS CONTAINING MUCOID MATERIAL ARE OBSERVED.

LIVER

MONONUCLEAR CELLS :
MINIMAL
FOCAL COLLECTIONS OF MONONUCLEAR CELLS ARE PRESENT.

HYPERPLASTIC NODULE :
A NODULE OF HYPERPLASTIC TISSUE IS PRESENT.

HEPATOCYTIC HYPERPIGMENTATION :
HEPATOCYTES ARE LADEN WITH GRANULES OF HEMOSIDERIN OR BILE OR OTHER PIGMENT.

PANCREAS

NORMAL :
HISTOLOGICAL ASPECT WITHIN NORMAL LIMITS.

THYROIDS

CYSTS :
MINIMAL
ONE OR MORE CYSTS FILLED WITH CLEAR LIQUID ARE SEEN.

SCIATIC NERVE

ABSENT :
ORGAN OR TISSUE NOT REMOVED FROM ANIMAL OR NOT FOUND IN FIXATIVE.

OVARIES

ATROPHY :
BILATERAL
THE ORGAN IS REDUCED IN SIZE.

UTERUS

ENDOMETRIOSIS :
BILATERAL
ENDOMETRIAL GLANDS ARE SEEN AT VARIOUS SITES OUTSIDE THE NORMAL ENDOMETRIUM.

BAYER AG

FEMALE 398 (158c/80)

LUNG

PNEUMONIA :
THE ALVEOLAR WALLS ARE THICKENED AND ALVEOLI CONTAIN INFLAMMATORY CELLS AND FOAMY MACROPHAGES.PERIVASCULAR AND PERIBRONCHIAL LYMPHOCYTIC ACCUMULATIONS MAY BE PRESENT.

SPLEEN

HEMATOPOIESIS :
MINIMAL
THE HEMATOPOIESIS IS EVIDENT.

BLADDER

HYPERPLASIA PAPILLOMATOUS :
THE THICKNESS OF THE MUCOSA IS INCREASED MAKING UNUSUALLY HIGH AND NUMEROUS FOLDS.

THYROIDS

CYSTS :
MINIMAL
ONE OR MORE CYSTS FILLED WITH CLEAR LIQUID ARE SEEN.

ADRENALS

*** PHEOCHROMOCYTOMA :
UNILATERAL
THIS TUMOR IS COMPOSED OF POLYHEDRAL CELLS WHICH ARISE FROM THE CHROMAFFIN CELLS OF THE ADRENAL MEDULLA AND FORM LOBULES SEPARATED BY VASCULAR CONNECTIVE TISSUE SEPTA.

OVARIES

ATROPHY :
BILATERAL
THE ORGAN IS REDUCED IN SIZE.

HEMORRAGIC CYST :
UNILATERAL
ONE OR SEVERAL CAVITIES FILLED WITH BLOOD.

UTERUS

CYSTIC ENDOMETRIAL HYPERPLASIA :
BILATERAL
THE ENDOMETRIAL GLANDS ARE INCREASED IN NUMBER AND SOME ARE DILATED OR CYSTIC.

FEMALE 399 (1602/80)

LUNG

*** ALVEOLOGENIC CARCINOMA :
A MALIGNANT TUMOR OF THE LUNG TISSUE WITH SYNONYMS IN MICE FOR ADENOMA, CARCINOMA, ALVEOLOGENIC PAPILLARY CARCINOMA, PAPILLARY CYSTADENOMA, ADENOCARCINOMA, BRONCHIOLAR CELL CARCINOMA, BRONCHIOLAR-ALVEOLAR TUMOR, TYPE A TUMOR, TYPE B TUMOR, INTERMEDIATE TYPE I TUMOR AND COMMON PULMONARY TUMOR OF THE MOUSE.

LIVER

FAT VACUOLES :
MINIMAL
THE CELLS ARE DISTENDED BY CLEAR CYTOPLASMIC VACUOLES WHICH FREQUENTLY DISPLACE THE NUCLEI.

HEPATOCYTIC HYPERPIGMENTATION :
MINIMAL
HEPATOCYTES ARE LADEN WITH GRANULES OF HEMOSIDERIN OR BILE OR OTHER PIGMENT.

SCIATIC NERVE

ABSENT :
ORGAN OR TISSUE NOT REMOVED FROM ANIMAL OR NOT FOUND IN FIXATIVE.

OVARIES

*** ARRHENOBLASTOMA :
BILATERAL
THIS TUMOR IS MAINLY COMPOSED OF IMMATURE GONADAL ELEMENTS OF THE MALE TYPE SUCH AS TUBULAR STRUCTURES SUGGESTING POORLY DEVELOPED SEMINIFEROUS TUBULES.

UTERUS

CYSTIC ENDOMETRIAL HYPERPLASIA :
BILATERAL
THE ENDOMETRIAL GLANDS ARE INCREASED IN NUMBER AND SOME ARE DILATED OR CYSTIC.

FEMALE 400 (1,03/80)

BAYER AG

SF3.19 FEMALE 400 CONTINUED

LUNG

PNEUMONIA :
THE ALVEOLAR WALLS ARE THICKENED AND ALVEOLI CONTAIN INFLAMMATORY CELLS AND FOAMY MACROPHAGES.PERIVASCULAR AND PERIBRONCHIAL LYMPHOCYTIC ACCUMULATIONS MAY BE PRESENT.

LIVER

FAT VACUOLES :
MODERATE
THE CELLS ARE DISTENDED BY CLEAR CYTOPLASMIC VACUOLES WHICH FREQUENTLY DISPLACE THE NUCLEI.

CYSTS :
ONE OR MORE CYSTS FILLED WITH CLEAR LIQUID ARE SEEN.

HEPATOCYTIC HYPERPIGMENTATION :
MINIMAL
HEPATOCYTES ARE LADEN WITH GRANULES OF HEMOSIDERIN OR BILE OR OTHER PIGMENT.

HYPERPLASTIC NODULES :
WELL DEFINED ROUNDED FOCI OF HYPERPLASTIC AND HYPERTROPHIC CELLS ARE OBSERVED WITHIN THIS OTHERWISE NORMAL TISSUE.

PANCREAS

ATROPHY :
THE ORGAN IS REDUCED IN SIZE.

PERIARTERITIS :
NON SPECIFIC INFLAMMATION (ACUTE SUBACUTE OR CHRONIC) OF THE TUNICA ADVENTITIA (PERIVASCULAR GRANULOMA).

SPLEEN

HEMATOPOIESIS :
MODERATE
THE HEMATOPOIESIS IS EVIDENT.

KIDNEYS

INTERSTITIAL NEPHRITIS :
BILATERAL MINIMAL
INFLAMMATORY CELLS FIBROSIS AND SOME TUBULAR ALTERATIONS ARE ASSOCIATED.

THYROIDS

ABSENT :
ORGAN OR TISSUE NOT REMOVED FROM ANIMAL OR NOT FOUND IN FIXATIVE..

ADRENALS

PIGMENTATION :
UNILATERAL
NUMEROUS MACROPHAGES CONTAIN A GRANULAR BROWN CYTOPLASMIC PIGMENT.

HYPERTROPHY :
UNILATERAL

ADRENALS CONTINUED

THE SIZE OF THE ORGAN IS INCREASED WITHOUT STRUCTURAL ANOMALY.

SCIATIC NERVE

ABSENT :
ORGAN OR TISSUE NOT REMOVED FROM ANIMAL OR NOT FOUND IN FIXATIVE.

OVARIES

ATROPHY :
BILATERAL
THE ORGAN IS REDUCED IN SIZE.

CYSTS :
UNILATERAL
ONE OR MORE CYSTS FILLED WITH CLEAR LIQUID ARE SEEN.

UTERUS

ENDOMETRIOSIS :
ENDOMETRIAL GLANDS ARE SEEN AT VARIOUS SITES OUTSIDE THE NORMAL ENDOMETRIUM.

ENDOMETRITIS :
ACUTE OR SUBACUTE INFLAMMATION IS SEEN IN ENDOMETRIUM.

BAYER AG BAYER AG BAYER AG BAYER AG

NF3. 1 CHRONIC TOXICITY STUDY IN MICE: NONSYSTEMATIC HISTOPATHOLOGY

PRODUCT : KWG 0519

GROUP : 3
ROUTE : DIETARY
DOSE : 2000 PPM

TIME : 105 WEEKS
THIS GROUP COMPRISED : 30 FEMALES

THE FOLLOWING ORGANS WERE EXAMINED SYSTEMATICALLY :

HEART	LUNG	LIVER
PANCREAS	SPLEEN	KIDNEYS
BLADDER	STOMACH	OVARIES
THYROIDS	ADRENALS	PITUITARY
BRAIN	SKELETAL MUSCLE	SCIATIC NERVE
FEMUR		

THESE ORGANS WERE EXAMINED IN 30 FEMALES

INDIVIDUAL RESULTS

IN THE ANIMALS SHOWN BELOW THE HISTOLOGICAL EXAMINATION OF THE ORGANS LISTED OR OF THE ANOMALIES FOUND AT AUTOPSY GAVE THE FOLLOWING RESULTS :

FEMALE 352 (1850/80)

LUNG

LEUKEMIC DEPOSITS :
ORGAN AND THE BLOOD ARE INVADED BY LEUKEMIC CELLS.

LIVER

CONGESTION :
VESSELS OR SINUSOIDS ARE MARKEDLY DISTENDED WITH ERYTHROCYTES.

THYMUS

*** LYMPHOMA LYMPHOCYTIC :
THE NEOPLASM OF THE RETICULAR SYSTEM ORIGINATES FROM LYMPHOCYTES.

SPLEEN

HYPERPLASIA LYMPHOID :
THE LYMPHOID FOLLICLES ARE INCREASED IN SIZE.

PITUITARY

ABSENT :
ORGAN OR TISSUE NOT REMOVED FROM ANIMAL OR NOT FOUND IN FIXATIVE.

THYROIDS

ABSENT :
ORGAN OR TISSUE NOT REMOVED FROM ANIMAL OR NOT FOUND IN FIXATIVE.

FEMALE 353 (1659/80)

LUNG

CONGESTION :
SEVERE
VESSELS OR SINUSOIDS ARE MARKEDLY DISTENDED WITH ERYTHROCYTES.

LIVER

LEUKEMIC DEPOSITS :
ORGAN AND THE BLOOD ARE INVADED BY LEUKEMIC CELLS.

PANCREAS

AUTOLYSIS :
THE TISSUES EXHIBIT AUTOLYSIS AND THEY ARE NOT INTERPRETABLE.

SPLEEN

*** LYMPHOMA STEM CELLS :
THE NEOPLASM OF THE RETICULAR SYSTEM ORIGINATES FROM STEM CELLS.

THYROIDS

ABSENT :
ORGAN OR TISSUE NOT REMOVED FROM ANIMAL OR NOT FOUND IN FIXATIVE.

SCIATIC NERVE

ABSENT :
ORGAN OR TISSUE NOT REMOVED FROM ANIMAL OR NOT FOUND IN FIXATIVE.

BONE

*** OSTEOMA :
THIS BENIGN WELL CIRCUMSCRIBED TUMOR IS COMPOSED OF WELL-DEVELOPED BONE.

MESENTERY

LEUKEMIC DEPOSITS :
ORGAN AND THE BLOOD ARE INVADED BY LEUKEMIC

BAYER AG

MESENTERY CONTINUED

CELLS.

OVARIES

LEUKEMIC DEPOSITS :
ORGAN AND THE BLOOD ARE INVADED BY LEUKEMIC CELLS.

UTERUS

LEUKEMIC DEPOSITS :
ORGAN AND THE BLOOD ARE INVADED BY LEUKEMIC CELLS.

FEMALE 356 (1590/80)

LUNG

PERITONITIS :
THE SEROSA IS COVERED BY EXUDATE SHOWING ORGANIZATION AND INFLAMMATION.

LIVER

MONONUCLEAR CELLS :
MINIMAL
FOCAL COLLECTIONS OF MONONUCLEAR CELLS ARE PRESENT.

PERIARTERITIS :
NON SPECIFIC INFLAMMATION (ACUTE SUBACUTE OR CHRONIC) OF THE TUNICA ADVENTITIA (PERIVASCULAR GRANULOMA).

SPLEEN

HYPERPLASIA LYMPHOID :
THE LYMPHOID FOLLICLES ARE INCREASED IN SIZE.

CONGESTION :
VESSELS OR SINUSOIDS ARE MARKEDLY DISTENDED WITH ERYTHROCYTES.

KIDNEYS

CYSTS :
FOCAL
ONE OR MORE CYSTS FILLED WITH CLEAR LIQUID ARE SEEN.

BLADDER

INFLAMMATION CHRONIC :
THERE IS AN INFILTRATION BY MONONUCLEAR CELLS IN THE MUCOSA AND SUBMUCOSA.

NF3. 4 FEMALE 356 CONTINUED

PITUITARY

ABSENT :
ORGAN OR TISSUE NOT REMOVED FROM ANIMAL OR NOT FOUND IN FIXATIVE.

THYROIDS

ABSENT :
ORGAN OR TISSUE NOT REMOVED FROM ANIMAL OR NOT FOUND IN FIXATIVE.

ADRENALS

HEMORRAGIC CYST :
UNILATERAL
ONE OR SEVERAL CAVITIES FILLED WITH BLOOD.

SKIN

NORMAL :
HISTOLOGICAL ASPECT WITHIN NORMAL LIMITS.

OVARIES

ATROPHY :
BILATERAL
THE ORGAN IS REDUCED IN SIZE.

UTERUS

ENDOMETRITIS :
UNILATERAL
ACUTE OR SUBACUTE INFLAMMATION IS SEEN IN ENDOMETRIUM.

FEMALE 358 (1594/80)

LUNG

PNEUMONIA :
THE ALVEOLAR WALLS ARE THICKENED AND ALVEOLI CONTAIN INFLAMMATORY CELLS AND FOAMY MACROPHAGES.PERIVASCULAR AND PERIBRONCHIAL LYMPHOCYTIC ACCUMULATIONS MAY BE PRESENT.

LIVER

HYPERPLASTIC NODULE :
A NODULE OF HYPERPLASTIC TISSUE IS PRESENT.

PANCREAS

AUTOLYSIS PARTIAL :
NO OTHER CHANGES ARE SEEN. TISSUES ARE ALTERED.
BY POST-MORTEM MODIFICATIONS AND
DIAGNOSIS IS GIVEN WITH RESERVATION.

BAYER AG

KIDNEYS

TUBULOPATHY :
TUBULAR DEGENERATIVE CHANGES ARE PRESENT WHICH MAY BE ASSOCIATED WITH TUBULAR DILATATION.

BLADDER

INFLAMMATION CHRONIC :
THERE IS AN INFILTRATION BY MONONUCLEAR CELLS IN THE MUCOSA AND SUBMUCOSA.

PITUITARY

ABSENT :
ORGAN OR TISSUE NOT REMOVED FROM ANIMAL OR NOT FOUND IN FIXATIVE.

THYROIDS

ABSENT :
ORGAN OR TISSUE NOT REMOVED FROM ANIMAL OR NOT FOUND IN FIXATIVE.

ADRENALS

PIGMENTATION :
BILATERAL MINIMAL
NUMEROUS MACROPHAGES CONTAIN A GRANULAR BROWN CYTOPLASMIC PIGMENT.

*** ADENOMA :
UNILATERAL
THIS IS BENIGN GLANDULAR EPITHELIAL TUMOR.

SCIATIC NERVE

ABSENT :
ORGAN OR TISSUE NOT REMOVED FROM ANIMAL OR NOT FOUND IN FIXATIVE.

OVARIES

HEMORRAGIC CYST :
UNILATERAL
ONE OR SEVERAL CAVITIES FILLED WITH BLOOD.

UTERUS

HYPERPLASIA SECRETORY :
THE DEVELOPED GLANDS AND/OR DUCTS CONTAIN A SECRETION

FEMALE 361 (1856/60)

HEART

THROMBOSIS :
THE VASCULAR LUMEN CONTAINS AN ATTACHED ANTE MORTEM BLOOD CLOT.

TRACHEA

LEUKEMIC DEPOSITS :
ORGAN AND THE BLOOD ARE INVADED BY LEUKEMIC CELLS.

LUNG

LEUKEMIC DEPOSITS :
ORGAN AND THE BLOOD ARE INVADED BY LEUKEMIC CELLS.

LIVER

LEUKEMIC DEPOSITS :
ORGAN AND THE BLOOD ARE INVADED BY LEUKEMIC CELLS.

SPLEEN

*** LYMPHOMA LYMPHOCYTIC :
THE NEOPLASM OF THE RETICULAR SYSTEM ORIGINATES FROM LYMPHOCYTES.

KIDNEYS

LEUKEMIC DEPOSITS :
ORGAN AND THE BLOOD ARE INVADED BY LEUKEMIC CELLS.

BLADDER

LEUKEMIC DEPOSITS :
ORGAN AND THE BLOOD ARE INVADED BY LEUKEMIC CELLS.

THYROIDS

ABSENT :
ORGAN OR TISSUE NOT REMOVED FROM ANIMAL OR NOT FOUND IN FIXATIVE.

ADRENALS

ABSENT :
ORGAN OR TISSUE NOT REMOVED FROM ANIMAL OR NOT FOUND IN FIXATIVE.

OVARIES

LEUKEMIC DEPOSITS :
ORGAN AND THE BLOOD ARE INVADED BY LEUKEMIC CELLS.

BAYER AG

Vertraulich
Eigentum der Firma Bayer AG
Benutzung, Verwertung oder Weitergabe nur mit Einwilligung der Bayer AG gestattet

UTERUS

LEUKEMIC DEPOSITS :
ORGAN AND THE BLOOD ARE INVADED BY LEUKEMIC CELLS.

LYMPH NODE

*** LYMPHOMA LYMPHOCYTIC :
THE NEOPLASM OF THE RETICULAR SYSTEM ORIGINATES FROM LYMPHOCYTES.

FEMALE 362 (1600/80)

HEART

CONGESTION :
VESSELS OR SINUSOIDS ARE MARKEDLY DISTENDED WITH ERYTHROCYTES.

LUNG

CONGESTION :
VESSELS OR SINUSOIDS ARE MARKEDLY DISTENDED WITH ERYTHROCYTES.

ATELECTASIS :
FOCAL
THERE IS COLLAPSE OF ALVEOLI.

STOMACH

PAPILLOMATOUS ACANTHOSIS :
THERE IS A THICKENING AND FOLDING OF THE SQUAMOUS EPITHELIUM.

MUCOID CYST :
ONE OR MORE CYSTS CONTAINING MUCOID MATERIAL ARE OBSERVED.

LIVER

LEUKEMIC DEPOSITS :
ORGAN AND THE BLOOD ARE INVADED BY LEUKEMIC CELLS.

PANCREAS

LEUKEMIC DEPOSITS :
ORGAN AND THE BLOOD ARE INVADED BY LEUKEMIC CELLS.

SPLEEN

*** LYMPHOMA LYMPHOCYTIC :
THE NEOPLASM OF THE RETICULAR SYSTEM ORIGINATES FROM

NF3. 8 FEMALE 362 CONTINUED

SPLEEN CONTINUED

LYMPHOCYTES.

KIDNEYS

LEUKEMIC DEPOSITS :
ORGAN AND THE BLOOD ARE INVADED BY LEUKEMIC CELLS.

AUTOLYSIS PARTIAL :
NO OTHER CHANGES ARE SEEN. TISSUES ARE ALTERED. BY POST-MORTEM MODIFICATIONS AND DIAGNOSIS IS GIVEN WITH RESERVATION.

BLADDER

LEUKEMIC DEPOSITS :
ORGAN AND THE BLOOD ARE INVADED BY LEUKEMIC CELLS.

MESENTERY

LEUKEMIC DEPOSITS :
ORGAN AND THE BLOOD ARE INVADED BY LEUKEMIC CELLS.

OVARIES

LEUKEMIC DEPOSITS :
ORGAN AND THE BLOOD ARE INVADED BY LEUKEMIC CELLS.

SKULL

*** OSTEOMA :
THIS BENIGN WELL CIRCUMSCRIBED TUMOR IS COMPOSED OF WELL-DEVELOPED BONE.

FEMALE 363 (1860/80)

HEART

LEUKEMIC DEPOSITS :
ORGAN AND THE BLOOD ARE INVADED BY LEUKEMIC CELLS.

LUNG

LEUKEMIC DEPOSITS :
ORGAN AND THE BLOOD ARE INVADED BY LEUKEMIC CELLS.

LIVER

LEUKEMIC DEPOSITS :

BAYER AG

LIVER CONTINUED

ORGAN AND THE BLOOD ARE INVADED BY LEUKEMIC CELLS.

PANCREAS

LEUKEMIC DEPOSITS :
ORGAN AND THE BLOOD ARE INVADED BY LEUKEMIC CELLS.

THYMUS

*** LYMPHOMA LYMPHOCYTIC :
THE NEOPLASM OF THE RETICULAR SYSTEM ORIGINATES FROM LYMPHOCYTES.

SPLEEN

*** LYMPHOMA LYMPHOCYTIC :
THE NEOPLASM OF THE RETICULAR SYSTEM ORIGINATES FROM LYMPHOCYTES.

KIDNEYS

LEUKEMIC DEPOSITS :
ORGAN AND THE BLOOD ARE INVADED BY LEUKEMIC CELLS.

BLADDER

LEUKEMIC DEPOSITS :
ORGAN AND THE BLOOD ARE INVADED BY LEUKEMIC CELLS.

THYROIDS

AUTOLYSIS PARTIAL :
NO OTHER CHANGES ARE SEEN. TISSUES ARE ALTERED.
BY POST-MORTEM MODIFICATIONS AND
DIAGNOSIS IS GIVEN WITH RESERVATION.

SCIATIC NERVE

LEUKEMIC DEPOSITS :
ORGAN AND THE BLOOD ARE INVADED BY LEUKEMIC CELLS.

OVARIES

LEUKEMIC DEPOSITS :
ORGAN AND THE BLOOD ARE INVADED BY LEUKEMIC CELLS.

UTERUS

LEUKEMIC DEPOSITS :
ORGAN AND THE BLOOD ARE INVADED BY LEUKEMIC CELLS.

FEMALE 364 (1055/80)

LUNG

EDEMA :
SEVERE
THE INTERSTITIAL TISSUES CONTAIN AN INCREASED AMOUNT OF FLUID.

CONGESTION :
SEVERE
VESSELS OR SINUSOIDS ARE MARKEDLY DISTENDED WITH ERYTHROCYTES.

STOMACH

UNREADABLE :
IT IS NOT POSSIBLE TO INTERPRET THE SECTION DUE TO AN ARTIFACT CAUSED BY SAMPLING OR HISTOLOGICAL TECHNIQUE.

LIVER

CONGESTION :
VESSELS OR SINUSOIDS ARE MARKEDLY DISTENDED WITH ERYTHROCYTES.

PANCREAS

AUTOLYSIS :
THE TISSUES EXHIBIT AUTOLYSIS AND THEY ARE NOT INTERPRETABLE.

SPLEEN

AUTOLYSIS :
THE TISSUES EXHIBIT AUTOLYSIS AND THEY ARE NOT INTERPRETABLE.

KIDNEYS

CONGESTION :
SEVERE
VESSELS OR SINUSOIDS ARE MARKEDLY DISTENDED WITH ERYTHROCYTES.

THYROIDS

ABSENT :
ORGAN OR TISSUE NOT REMOVED FROM ANIMAL OR NOT FOUND IN FIXATIVE.

SKELETAL MUSCLE

ABSENT :
ORGAN OR TISSUE NOT REMOVED FROM ANIMAL OR NOT FOUND IN

BAYER AG

NF3.11 FEMALE 364 CONTINUED 533

SKELETAL MUSCLE CONTINUED
FIXATIVE.

SCIATIC NERVE

ABSENT :
ORGAN OR TISSUE NOT REMOVED FROM ANIMAL OR NOT FOUND IN FIXATIVE.

OVARIES

ATROPHY :
THE ORGAN IS REDUCED IN SIZE.

UTERUS

NORMAL :
HISTOLOGICAL ASPECT WITHIN NORMAL LIMITS.

FEMUR

ABSENT :
ORGAN OR TISSUE NOT REMOVED FROM ANIMAL OR NOT FOUND IN FIXATIVE.

FEMALE 365 (1599/80)

LUNG

CONGESTION :
VESSELS OR SINUSOIDS ARE MARKEDLY DISTENDED WITH ERYTHROCYTES.

LIVER

*** ADENOMA HEPATIC BENIGN :
UNILATERAL MULTIFOCAL
DISTINCT NODULES COMPRESS THE ADJACENT LIVER PARENCHYMA, ARE CHARACTERIZED BY WELL DIFFERENTIATED HEPATOCYTES AND DO NOT SHOW PORTAL TRIADS.

MONONUCLEAR CELLS :
MODERATE MULTIFOCAL
FOCAL COLLECTIONS OF MONONUCLEAR CELLS ARE PRESENT.

PANCREAS

INFLAMMATION CHRONIC :
THE INTERSTITIAL TISSUES SHOW INFILTRATION BY MONONUCLEAR CELLS AND INCREASE IN FIBROUS STROMA.

SPLEEN

HEMATOPOIESIS :
SEVERE

NF3.12 FEMALE 365 CONTINUED

SPLEEN CONTINUED
THE HEMATOPOIESIS IS EVIDENT.

KIDNEYS

INTERSTITIAL NEPHRITIS :
BILATERAL MODERATE MULTIFOCAL
INFLAMMATORY CELLS FIBROSIS AND SOME TUBULAR ALTERATIONS ARE ASSOCIATED.

BLADDER

HYPERPLASIA PAPILLOMATOUS :
THE THICKNESS OF THE MUCOSA IS INCREASED MAKING UNUSUALLY HIGH AND NUMEROUS FOLDS.

ADRENALS

PIGMENTATION :
SEVERE
NUMEROUS MACROPHAGES CONTAIN A GRANULAR BROWN CYTOPLASMIC PIGMENT.

OVARIES

INFLAMMATION ACUTE :
SEVERE
A LESION MADE OF CONGESTION EDEMA FIBRINOUS EXUDATE WITH INFILTRATION OF LEUKOCYTES.

HEMORRHAGE :
SEVERE
THERE IS EXTRAVASATION OF BLOOD.

UTERUS

ENDOMETRITIS :
SEVERE
ACUTE OR SUBACUTE INFLAMMATION IS SEEN IN ENDOMETRIUM.

FEMALE 366 (1597/80)

BRAIN

EDEMA :
FOCAL
THE INTERSTITIAL TISSUES CONTAIN AN INCREASED AMOUNT OF FLUID.

HEART

LEUKEMIC DEPOSITS :
ORGAN AND THE BLOOD ARE INVADED BY LEUKEMIC CELLS.

BAYER AG

LUNG

LEUKEMIC DEPOSITS :
ORGAN AND THE BLOOD ARE INVADED BY LEUKEMIC CELLS.

STOMACH

LEUKEMIC DEPOSITS :
ORGAN AND THE BLOOD ARE INVADED BY LEUKEMIC CELLS.

LIVER

LEUKEMIC DEPOSITS :
ORGAN AND THE BLOOD ARE INVADED BY LEUKEMIC CELLS.

PANCREAS

LEUKEMIC DEPOSITS :
ORGAN AND THE BLOOD ARE INVADED BY LEUKEMIC CELLS.

SPLEEN

*** LYMPHOMA LYMPHOCYTIC :
THE NEOPLASM OF THE RETICULAR SYSTEM ORIGINATES FROM LYMPHOCYTES.

KIDNEYS

LEUKEMIC DEPOSITS :
ORGAN AND THE BLOOD ARE INVADED BY LEUKEMIC CELLS.

BLADDER

LEUKEMIC DEPOSITS :
ORGAN AND THE BLOOD ARE INVADED BY LEUKEMIC CELLS.

ADRENALS

LEUKEMIC DEPOSITS :
ORGAN AND THE BLOOD ARE INVADED BY LEUKEMIC CELLS.

OVARIES

LEUKEMIC DEPOSITS :
ORGAN AND THE BLOOD ARE INVADED BY LEUKEMIC CELLS.

LYMPH NODE

*** LYMPHOMA LYMPHOCYTIC :
THE NEOPLASM OF THE RETICULAR SYSTEM ORIGINATES FROM LYMPHOCYTES.

FEMALE 369 (1658/80)

LUNG

LEUKEMIC DEPOSITS :
ORGAN AND THE BLOOD ARE INVADED BY LEUKEMIC CELLS.

STOMACH

LEUKEMIC DEPOSITS :
ORGAN AND THE BLOOD ARE INVADED BY LEUKEMIC CELLS.

LIVER

LEUKEMIC DEPOSITS :
ORGAN AND THE BLOOD ARE INVADED BY LEUKEMIC CELLS.

PANCREAS

AUTOLYSIS :
THE TISSUES EXHIBIT AUTOLYSIS AND THEY ARE NOT INTERPRETABLE.

THYMUS

*** LYMPHOMA LYMPHOCYTIC :
THE NEOPLASM OF THE RETICULAR SYSTEM ORIGINATES FROM LYMPHOCYTES.

SPLEEN

*** LYMPHOMA LYMPHOCYTIC :
THE NEOPLASM OF THE RETICULAR SYSTEM ORIGINATES FROM LYMPHOCYTES.

KIDNEYS

LEUKEMIC DEPOSITS :
ORGAN AND THE BLOOD ARE INVADED BY LEUKEMIC CELLS.

BLADDER

LEUKEMIC DEPOSITS :
ORGAN AND THE BLOOD ARE INVADED BY LEUKEMIC CELLS.

OVARIES

CYSTS :
ONE OR MORE CYSTS FILLED WITH CLEAR LIQUID ARE SEEN.

BAYER AG

UTERUS

LEUKEMIC DEPOSITS :
ORGAN AND THE BLOOD ARE INVADED BY LEUKEMIC CELLS.

FEMALE 370 (1861/00)

LUNG

LEUKEMIC DEPOSITS :
ORGAN AND THE BLOOD ARE INVADED BY LEUKEMIC CELLS.

STOMACH

NORMAL :
HISTOLOGICAL ASPECT WITHIN NORMAL LIMITS.

LIVER

LEUKEMIC DEPOSITS :
ORGAN AND THE BLOOD ARE INVADED BY LEUKEMIC CELLS.

PANCREAS

ATROPHY :
THE ORGAN IS REDUCED IN SIZE.

SPLEEN

*** LYMPHOMA LYMPHOCYTIC :
THE NEOPLASM OF THE RETICULAR SYSTEM ORIGINATES FROM LYMPHOCYTES.

KIDNEYS

TUBULOPATHY :
TUBULAR DEGENERATIVE CHANGES ARE PRESENT WHICH MAY BE ASSOCIATED WITH TUBULAR DILATATION.

BLADDER

LEUKEMIC DEPOSITS :
ORGAN AND THE BLOOD ARE INVADED BY LEUKEMIC CELLS.

OVARIES

*** LUTEOMA :
UNILATERAL
IT IS A BENIGN TUMOR COMPOSED OF CELLS RESEMBLING THOSE OF THE CORPUS LUTEUM.

UTERUS

CYSTIC ENDOMETRIAL HYPERPLASIA :
THE ENDOMETRIAL GLANDS ARE INCREASED IN NUMBER AND SOME ARE DILATED OR CYSTIC.

FEMALE 371 (1853/60)

HEART

LEUKEMIC DEPOSITS :
ORGAN AND THE BLOOD ARE INVADED BY LEUKEMIC CELLS.

LUNG

LEUKEMIC DEPOSITS :
ORGAN AND THE BLOOD ARE INVADED BY LEUKEMIC CELLS.

LIVER

CONGESTION :
VESSELS OR SINUSOIDS ARE MARKEDLY DISTENDED WITH ERYTHROCYTES.

PANCREAS

INFLAMMATION CHRONIC :
THE INTERSTITIAL TISSUES SHOW INFILTRATION BY MONONUCLEAR CELLS AND INCREASE IN FIBROUS STROMA.

THYMUS

*** LYMPHOMA LYMPHOCYTIC :
THE NEOPLASM OF THE RETICULAR SYSTEM ORIGINATES FROM LYMPHOCYTES.

SPLEEN

AUTOLYSIS PARTIAL :
NO OTHER CHANGES ARE SEEN. TISSUES ARE ALTERED.
BY POST-MORTEM MODIFICATIONS AND
DIAGNOSIS IS GIVEN WITH RESERVATION.

KIDNEYS

TUBULOPATHY :
TUBULAR DEGENERATIVE CHANGES ARE PRESENT
WHICH MAY BE ASSOCIATED WITH TUBULAR DILATATION.

PYELONEPHRITIS :
INFLAMMATION OF RENAL PARENCHYMA WITH OR WITHOUT
NECROSIS EXTENDED TO RENAL PELVIS.

BAYER AG

THYROIDS

ABSENT :
ORGAN OR TISSUE NOT REMOVED FROM ANIMAL OR NOT FOUND IN FIXATIVE.

OVARIES

*** LUTEOMA :
BILATERAL
IT IS A BENIGN TUMOR COMPOSED OF CELLS RESEMBLING THOSE OF THE CORPUS LUTEUM.

UTERUS

NORMAL :
HISTOLOGICAL ASPECT WITHIN NORMAL LIMITS.

FEMALE 372 (1863/80)

HEART

CONGESTION :
VESSELS OR SINUSOIDS ARE MARKEDLY DISTENDED WITH ERYTHROCYTES.

LUNG

EDEMA :
THE INTERSTITIAL TISSUES CONTAIN AN INCREASED AMOUNT OF FLUID.

CONGESTION :
VESSELS OR SINUSOIDS ARE MARKEDLY DISTENDED WITH ERYTHROCYTES.

STOMACH

AUTOLYSIS :
THE TISSUES EXHIBIT AUTOLYSIS AND THEY ARE NOT INTERPRETABLE.

LIVER

CONGESTION :
VESSELS OR SINUSOIDS ARE MARKEDLY DISTENDED WITH ERYTHROCYTES.

KIDNEYS

CALCIFICATION :
UNILATERAL
THERE ARE MINERAL DEPOSITS.

HYDRONEPHROSIS :
CONTRALATERAL

NF3.18 FEMALE 372 CONTINUED

KIDNEYS CONTINUED

THE RENAL PELVIS IS DILATED AND THE ADJACENT PARENCHYMA IS REDUCED.

BLADDER

AUTOLYSIS :
THE TISSUES EXHIBIT AUTOLYSIS AND THEY ARE NOT INTERPRETABLE.

ADRENALS

PIGMENTATION :
NUMEROUS MACROPHAGES CONTAIN A GRANULAR BROWN CYTOPLASMIC PIGMENT.

OVARIES

ATROPHY :
THE ORGAN IS REDUCED IN SIZE.

UTERUS

ENDOMETRIOSIS :
UNILATERAL
ENDOMETRIAL GLANDS ARE SEEN AT VARIOUS SITES OUTSIDE THE NORMAL ENDOMETRIUM.

FEMALE 373 (1598/80

BRAIN

FAT VACUOLES :
MINIMAL
THE CELLS ARE DISTENDED BY CLEAR CYTOPLASMIC VACUOLES WHICH FREQUENTLY DISPLACE THE NUCLEI.

LUNG

*** METASTASIS :
A SECONDARY MALIGNANT TUMOR DEVELOPED AWAY FROM THE INITIAL GROWTH.

LIVER

MONONUCLEAR CELLS :
MINIMAL MULTIFOCAL
FOCAL COLLECTIONS OF MONONUCLEAR CELLS ARE PRESENT.

SPLEEN

HEMATOPOIESIS :
MODERATE
THE HEMATOPOIESIS IS EVIDENT.

BAYER AG

THYROIDS

ABSENT :
ORGAN OR TISSUE NOT REMOVED FROM ANIMAL OR NOT FOUND IN FIXATIVE.

ADRENALS

PIGMENTATION :
MINIMAL
NUMEROUS MACROPHAGES CONTAIN A GRANULAR BROWN CYTOPLASMIC PIGMENT.

SKELETAL MUSCLE

*** METASTASIS :
A SECONDARY MALIGNANT TUMOR DEVELOPED AWAY FROM THE INITIAL GROWTH.

OVARIES

ATROPHY :
BILATERAL
THE ORGAN IS REDUCED IN SIZE.

UTERUS

HYPERPLASIA POLYPOID:
BILATERAL
A PEDUNCULATED GROWTH IN THE LUMEN IS PRESENT

CYSTIC ENDOMETRIAL HYPERPLASIA :
BILATERAL
THE ENDOMETRIAL GLANDS ARE INCREASED IN NUMBER AND SOME ARE DILATED OR CYSTIC.

FEMUR

*** OSTEOGENIC SARCOMA :
A MALIGNANT MESENCHYMAL TUMOR WITH ISLANDS OF OSTEOID AND BONE FORMATION IS FOUND.

FEMALE 374 (1587/80)

BRAIN

ABSENT :
ORGAN OR TISSUE NOT REMOVED FROM ANIMAL OR NOT FOUND IN FIXATIVE.

HEART

THROMBUS :
THE VASCULAR LUMEN CONTAINS AN ATTACHED ANTE MORTEM BLOOD CLOT.

LUNG

PNEUMONIA :
THE ALVEOLAR WALLS ARE THICKENED AND ALVEOLI CONTAIN INFLAMMATORY CELLS AND FOAMY MACROPHAGES.PERIVASCULAR AND PERIBRONCHIAL LYMPHOCYTIC ACCUMULATIONS MAY BE PRESENT.

LIVER

LEUKEMIC DEPOSITS :
ORGAN AND THE BLOOD ARE INVADED BY LEUKEMIC CELLS.

PANCREAS

LEUKEMIC DEPOSITS :
ORGAN AND THE BLOOD ARE INVADED BY LEUKEMIC CELLS.

SPLEEN

*** LYMPHOMA LYMPHOCYTIC :
THE NEOPLASM OF THE RETICULAR SYSTEM ORIGINATES FROM LYMPHOCYTES.

KIDNEYS

INTERSTITIAL NEPHRITIS :
MINIMAL
INFLAMMATORY CELLS FIBROSIS AND SOME TUBULAR ALTERATIONS ARE ASSOCIATED.

THYROIDS

UNREADABLE :
IT IS NOT POSSIBLE TO INTERPRET THE SECTION DUE TO AN ARTIFACT CAUSED BY SAMPLING OR HISTOLOGICAL TECHNIQUE.

SCIATIC NERVE

ABSENT :
ORGAN OR TISSUE NOT REMOVED FROM ANIMAL OR NOT FOUND IN FIXATIVE.

OVARIES

ATROPHY :
BILATERAL
THE ORGAN IS REDUCED IN SIZE.

UTERUS

LEUKEMIC DEPOSITS :
ORGAN AND THE BLOOD ARE INVADED BY LEUKEMIC CELLS.

RIGHT HIND EXTREMITY

*** METASTASIS :
A SECONDARY MALIGNANT TUMOR DEVELOPED AWAY FROM THE INITIAL GROWTH.

BAYER AG BAYER AG BAYER AG BAYER AG

FEMUR

*** OSTEOGENIC SARCOMA :
A MALIGNANT MESENCHYMAL TUMOR WITH ISLANDS OF OSTEOID AND BONE FORMATION IS FOUND.

BODY CAVITY

*** METASTASIS :
A SECONDARY MALIGNANT TUMOR DEVELOPED AWAY FROM THE INITIAL GROWTH.

FEMALE 376 (1857/80)

LUNG

EDEMA :
THE INTERSTITIAL TISSUES CONTAIN AN INCREASED AMOUNT OF FLUID.

LIVER

*** ADENOMA HEPATIC BENIGN :
DISTINCT NODULES COMPRESS THE ADJACENT LIVER PARENCHYMA, ARE CHARACTERIZED BY WELL DIFFERENTIATED HEPATOCYTES AND DO NOT SHOW PORTAL TRIADS.

HYPERPLASTIC NODULE :
A NODULE OF HYPERPLASTIC TISSUE IS PRESENT.

CYSTS :
ONE OR MORE CYSTS FILLED WITH CLEAR LIQUID ARE SEEN.

KIDNEYS

PYELONEPHRITIS :
INFLAMMATION OF RENAL PARENCHYMA WITH OR WITHOUT NECROSIS EXTENDED TO RENAL PELVIS.

ADRENALS

HYPERPLASTIC NODULE :
A NODULE OF HYPERPLASTIC TISSUE IS PRESENT.

OVARIES

HYPERPLASIA POLYPOID:
UNILATERAL
A PEDUNCULATED GROWTH IN THE LUMEN IS PRESENT

HYPERTROPHIC CORPORA LUTEA :
ALL CORPORA LUTEA ARE IMPORTANT IN SIZE. THEY CONTAIN LARGE LUTEAL CELLS WITH ACIDOPHILIC CYTOPLASM.

FEMALE 380 (1601/60)

LUNG

NORMAL :
HISTOLOGICAL ASPECT WITHIN NORMAL LIMITS.

LIVER

LEUKEMIC DEPOSITS :
ORGAN AND THE BLOOD ARE INVADED BY LEUKEMIC CELLS.

PANCREAS

LEUKEMIC DEPOSITS :
ORGAN AND THE BLOOD ARE INVADED BY LEUKEMIC CELLS.

SPLEEN

*** LYMPHOMA LYMPHOCYTIC :
THE NEOPLASM OF THE RETICULAR SYSTEM ORIGINATES FROM LYMPHOCYTES.

KIDNEYS

LEUKEMIC DEPOSITS :
UNILATERAL
ORGAN AND THE BLOOD ARE INVADED BY LEUKEMIC CELLS.

BLADDER

LEUKEMIC DEPOSITS :
ORGAN AND THE BLOOD ARE INVADED BY LEUKEMIC CELLS.

THYROIDS

ABSENT :
ORGAN OR TISSUE NOT REMOVED FROM ANIMAL OR NOT FOUND IN FIXATIVE.

OVARIES

LEUKEMIC DEPOSITS :
ORGAN AND THE BLOOD ARE INVADED BY LEUKEMIC CELLS.

LYMPH NODE

*** LYMPHOMA LYMPHOCYTIC :
THE NEOPLASM OF THE RETICULAR SYSTEM ORIGINATES FROM LYMPHOCYTES.

BAYER AG

FEMALE 381 (1596/80)

BRAIN

FAT VACUOLES :
FOCAL
THE CELLS ARE DISTENDED BY CLEAR CYTOPLASMIC VACUOLES WHICH FREQUENTLY DISPLACE THE NUCLEI.

HEART

LEUKEMIC DEPOSITS :
ORGAN AND THE BLOOD ARE INVADED BY LEUKEMIC CELLS.

TRACHEA

INFLAMMATION CHRONIC :
THERE IS AN INFILTRATION BY MONONUCLEAR CELLS IN THE MUCOSA AND SUBMUCOSA.

LUNG

PNEUMONIA :
THE ALVEOLAR WALLS ARE THICKENED AND ALVEOLI CONTAIN INFLAMMATORY CELLS AND FOAMY MACROPHAGES.PERIVASCULAR AND PERIBRONCHIAL LYMPHOCYTIC ACCUMULATIONS MAY BE PRESENT.

CONGESTION :
VESSELS OR SINUSOIDS ARE MARKEDLY DISTENDED WITH ERYTHROCYTES.

LIVER

*** ADENOMA HEPATIC BENIGN :
DISTINCT NODULES COMPRESS THE ADJACENT LIVER PARENCHYMA, ARE CHARACTERIZED BY WELL DIFFERENTIATED HEPATOCYTES AND DO NOT SHOW PORTAL TRIADS.

HYPERPLASTIC NODULES :
MULTIFOCAL
WELL DEFINED ROUNDED FOCI OF HYPERPLASTIC AND HYPERTROPHIC CELLS ARE OBSERVED WITHIN THIS OTHERWISE NORMAL TISSUE.

PANCREAS

AUTOLYSIS :
THE TISSUES EXHIBIT AUTOLYSIS AND THEY ARE NOT INTERPRETABLE.

SPLEEN

*** LYMPHOMA LYMPHOCYTIC :
THE NEOPLASM OF THE RETICULAR SYSTEM ORIGINATES FROM LYMPHOCYTES.

KIDNEYS

CONGESTION :
BILATERAL
VESSELS OR SINUSOIDS ARE MARKEDLY DISTENDED WITH ERYTHROCYTES.

INTERSTITIAL NEPHRITIS :
BILATERAL MINIMAL MULTIFOCAL
INFLAMMATORY CELLS FIBROSIS AND SOME TUBULAR ALTERATIONS ARE ASSOCIATED.

BLADDER

LEUKEMIC DEPOSITS :
ORGAN AND THE BLOOD ARE INVADED BY LEUKEMIC CELLS.

THYROIDS

ABSENT :
ORGAN OR TISSUE NOT REMOVED FROM ANIMAL OR NOT FOUND IN FIXATIVE.

ADRENALS

CONGESTION :
VESSELS OR SINUSOIDS ARE MARKEDLY DISTENDED WITH ERYTHROCYTES.

HYPERPLASTIC NODULE :
A NODULE OF HYPERPLASTIC TISSUE IS PRESENT.

SKELETAL MUSCLE

LEUKEMIC DEPOSITS :
ORGAN AND THE BLOOD ARE INVADED BY LEUKEMIC CELLS.

MESENTERY

LEUKEMIC DEPOSITS :
ORGAN AND THE BLOOD ARE INVADED BY LEUKEMIC CELLS.

OVARIES

HYPERPLASIA PAPILLOMATOUS :
UNILATERAL
THE THICKNESS OF THE MUCOSA IS INCREASED MAKING UNUSUALLY HIGH AND NUMEROUS FOLDS.

UTERUS

NORMAL :
HISTOLOGICAL ASPECT WITHIN NORMAL LIMITS.

FEMUR

HEMATOPOIESIS :
MODERATE
THE HEMATOPOIESIS IS EVIDENT.

BAYER AG

LYMPH NODE

ABSENT :
ORGAN OR TISSUE NOT REMOVED FROM ANIMAL OR NOT FOUND IN FIXATIVE.

FEMALE 382 (1586/80)

HEART

LEUKEMIC DEPOSITS :
ORGAN AND THE BLOOD ARE INVADED BY LEUKEMIC CELLS.

LUNG

LEUKEMIC DEPOSITS :
ORGAN AND THE BLOOD ARE INVADED BY LEUKEMIC CELLS.

LIVER

LEUKEMIC DEPOSITS :
ORGAN AND THE BLOOD ARE INVADED BY LEUKEMIC CELLS.

THYMUS

*** LYMPHOMA LYMPHOCYTIC :
THE NEOPLASM OF THE RETICULAR SYSTEM ORIGINATES FROM LYMPHOCYTES.

SPLEEN

*** LYMPHOMA LYMPHOCYTIC :
THE NEOPLASM OF THE RETICULAR SYSTEM ORIGINATES FROM LYMPHOCYTES.

KIDNEYS

LEUKEMIC DEPOSITS :
ORGAN AND THE BLOOD ARE INVADED BY LEUKEMIC CELLS.

ADRENALS

*** ADENOMA :
UNILATERAL
THIS IS BENIGN GLANDULAR EPITHELIAL TUMOR.

OVARIES

ATROPHY :
BILATERAL
THE ORGAN IS REDUCED IN SIZE.

HEMORRAGIC CYST :
UNILATERAL

NF3.26 FEMALE 382 CONTINUED

OVARIES CONTINUED
ONE OR SEVERAL CAVITIES FILLED WITH BLOOD.

UTERUS

HYPERPLASIA SECRETORY :
BILATERAL
THE DEVELOPED GLANDS AND/OR DUCTS CONTAIN A SECRETION

FEMALE 385 (1588/80)

HEART

CONGESTION :
SEVERE
VESSELS OR SINUSOIDS ARE MARKEDLY DISTENDED WITH ERYTHROCYTES.

LUNG

LEUKEMIC DEPOSITS :
ORGAN AND THE BLOOD ARE INVADED BY LEUKEMIC CELLS.

STOMACH

LEUKEMIC DEPOSITS :
ORGAN AND THE BLOOD ARE INVADED BY LEUKEMIC CELLS.

LIVER

LEUKEMIC DEPOSITS :
ORGAN AND THE BLOOD ARE INVADED BY LEUKEMIC CELLS.

PANCREAS

AUTOLYSIS :
THE TISSUES EXHIBIT AUTOLYSIS AND THEY ARE NOT INTERPRETABLE.

SPLEEN

*** LYMPHOMA LYMPHOCYTIC :
THE NEOPLASM OF THE RETICULAR SYSTEM ORIGINATES FROM LYMPHOCYTES.

KIDNEYS

LEUKEMIC DEPOSITS :
ORGAN AND THE BLOOD ARE INVADED BY LEUKEMIC CELLS.

BAYER AG

BLADDER

LEUKEMIC DEPOSITS :
ORGAN AND THE BLOOD ARE INVADED BY LEUKEMIC CELLS.

PITUITARY

ABSENT :
ORGAN OR TISSUE NOT REMOVED FROM ANIMAL OR NOT FOUND IN FIXATIVE.

THYROIDS

LEUKEMIC DEPOSITS :
ORGAN AND THE BLOOD ARE INVADED BY LEUKEMIC CELLS.

ADRENALS

PIGMENTATION :
BILATERAL MINIMAL
NUMEROUS MACROPHAGES CONTAIN A GRANULAR BROWN CYTOPLASMIC PIGMENT.

OVARIES

LEUKEMIC DEPOSITS :
ORGAN AND THE BLOOD ARE INVADED BY LEUKEMIC CELLS.

UTERUS

LEUKEMIC DEPOSITS :
ORGAN AND THE BLOOD ARE INVADED BY LEUKEMIC CELLS.

FEMALE 386 (0260/81)

LUNG

CONGESTION :
SEVERE
VESSELS OR SINUSOIDS ARE MARKEDLY DISTENDED WITH ERYTHROCYTES.

LIVER

MONONUCLEAR CELLS :
SEVERE MULTIFOCAL
FOCAL COLLECTIONS OF MONONUCLEAR CELLS ARE PRESENT.

CONGESTION :
SEVERE
VESSELS OR SINUSOIDS ARE MARKEDLY DISTENDED WITH

NF3.28 FEMALE 386 CONTINUED

LIVER CONTINUED

ERYTHROCYTES.

KIDNEYS

PYELONEPHRITIS :
BILATERAL MODERATE MULTIFOCAL
INFLAMMATION OF RENAL PARENCHYMA WITH OR WITHOUT NECROSIS EXTENDED TO RENAL PELVIS.

PITUITARY

ABSENT :
ORGAN OR TISSUE NOT REMOVED FROM ANIMAL OR NOT FOUND IN FIXATIVE.

THYROIDS

ABSENT :
ORGAN OR TISSUE NOT REMOVED FROM ANIMAL OR NOT FOUND IN FIXATIVE.

SKELETAL MUSCLE

ABSENT :
ORGAN OR TISSUE NOT REMOVED FROM ANIMAL OR NOT FOUND IN FIXATIVE.

SCIATIC NERVE

ABSENT :
ORGAN OR TISSUE NOT REMOVED FROM ANIMAL OR NOT FOUND IN FIXATIVE.

OVARIES

ABSENT :
ORGAN OR TISSUE NOT REMOVED FROM ANIMAL OR NOT FOUND IN FIXATIVE.

UTERUS

CYSTIC ENDOMETRIAL HYPERPLASIA :
THE ENDOMETRIAL GLANDS ARE INCREASED IN NUMBER AND SOME ARE DILATED OR CYSTIC.

FEMUR

ABSENT :
ORGAN OR TISSUE NOT REMOVED FROM ANIMAL OR NOT FOUND IN FIXATIVE.

FEMALE 387 (1592/00)

BRAIN

GLIOSIS :
THERE IS PROLIFERATION OF GLIAL CELLS.

HEART

PERICARDITIS :
THE PERICARDIUM IS THE SITE OF ACUTE OR CHRONIC INFLAMMATION.

STOMACH

HYPERKERATOSIS :
THE STRATIFIED SQUAMOUS EPITHELIUM EXHIBITS THICKENING AND EXCESS CORNIFICATION.

ULCERATION :
CIRCUMSCRIBED LOSS OF SUBSTANCE FROM THE EPITHELIAL SURFACE ACCOMPANIED BY INFLAMMATION OF THE ADJACENT TISSUE IS PRESEN

MUCOID CYST :
MINIMAL
ONE OR MORE CYSTS CONTAINING MUCOID MATERIAL ARE OBSERVED.

LIVER

FAT VACUOLES :
THE CELLS ARE DISTENDED BY CLEAR CYTOPLASMIC VACUOLES WHICH FREQUENTLY DISPLACE THE NUCLEI.

SPLEEN

HEMATOPOIESIS :
MODERATE
THE HEMATOPOIESIS IS EVIDENT.

KIDNEYS

INTERSTITIAL NEPHRITIS :
BILATERAL MULTIFOCAL
INFLAMMATORY CELLS FIBROSIS AND SOME TUBULAR ALTERATIONS ARE ASSOCIATED.

ADRENALS

PIGMENTATION :
MODERATE
NUMEROUS MACROPHAGES CONTAIN A GRANULAR BROWN CYTOPLASMIC PIGMENT.

MESENTERY

INFLAMMATION CHRONIC :
THE INTERSTITIAL TISSUES SHOW INFILTRATION BY MONONUCLEAR CELLS AND INCREASE IN FIBROUS STROMA.

OVARIES

ABSENT :
ORGAN OR TISSUE NOT REMOVED FROM ANIMAL OR NOT FOUND IN FIXATIVE.

UTERUS

CYSTIC ENDOMETRIAL HYPERPLASIA :
THE ENDOMETRIAL GLANDS ARE INCREASED IN NUMBER AND SOME ARE DILATED OR CYSTIC.

FEMALE 390 (1862/80)

STOMACH

NORMAL :
HISTOLOGICAL ASPECT WITHIN NORMAL LIMITS.

LIVER

LEUKEMIC DEPOSITS :
ORGAN AND THE BLOOD ARE INVADED BY LEUKEMIC CELLS.

PANCREAS

AUTOLYSIS :
THE TISSUES EXHIBIT AUTOLYSIS AND THEY ARE NOT INTERPRETABLE.

SPLEEN

INFARCT :
AN AREA OF ISCHEMIC NECROSIS DUE TO VASCULAR OCCLUSION IS PRESENT.

*** LYMPHOMA LYMPHOCYTIC :
THE NEOPLASM OF THE RETICULAR SYSTEM ORIGINATES FROM LYMPHOCYTES.

KIDNEYS

LEUKEMIC DEPOSITS :
ORGAN AND THE BLOOD ARE INVADED BY LEUKEMIC CELLS.

PITUITARY

ABSENT :
ORGAN OR TISSUE NOT REMOVED FROM ANIMAL OR NOT FOUND IN FIXATIVE.

OVARIES

ATROPHY :
THE ORGAN IS REDUCED IN SIZE.

CYSTS :
ONE OR MORE CYSTS FILLED WITH CLEAR LIQUID ARE SEEN.

BAYER AG

UTERUS

*** LEI-MYOSARCOMA :
MALIGNANT TUMOR DERIVED FROM SMOOTH MUSCLE FIBERS.

FEMALE 392 (1854/00)

STOMACH

ULCERATION :
CIRCUMSCRIBED LOSS OF SUBSTANCE FROM THE EPITHELIAL SURFACE
ACCOMPANIED BY INFLAMMATION OF THE ADJACENT TISSUE IS PRESEN

LIVER

AUTOLYSIS PARTIAL :
NO OTHER CHANGES ARE SEEN. TISSUES ARE ALTERED.
BY POST-MORTEM MODIFICATIONS AND
DIAGNOSIS IS GIVEN WITH RESERVATION.

PANCREAS

AUTOLYSIS PARTIAL :
NO OTHER CHANGES ARE SEEN. TISSUES ARE ALTERED.
BY POST-MORTEM MODIFICATIONS AND
DIAGNOSIS IS GIVEN WITH RESERVATION.

SPLEEN

AUTOLYSIS PARTIAL :
NO OTHER CHANGES ARE SEEN. TISSUES ARE ALTERED.
BY POST-MORTEM MODIFICATIONS AND
DIAGNOSIS IS GIVEN WITH RESERVATION.

KIDNEYS

CONGESTION :
VESSELS OR SINUSOIDS ARE MARKEDLY DISTENDED WITH
ERYTHROCYTES.

ADRENALS

ABSENT :
ORGAN OR TISSUE NOT REMOVED FROM ANIMAL OR NOT FOUND IN
FIXATIVE.

OVARIES

ATROPHY :
THE ORGAN IS REDUCED IN SIZE.

UTERUS

NORMAL :
HISTOLOGICAL ASPECT WITHIN NORMAL LIMITS.

NF3.32 FEMALE 392 CONTINUED

INTESTINE

AUTOLYSIS :
THE TISSUES EXHIBIT AUTOLYSIS AND THEY ARE NOT INTERPRETABLE.

FEMALE 393 (1852/80)

HEART

CONGESTION :
VESSELS OR SINUSOIDS ARE MARKEDLY DISTENDED WITH ERYTHROCYTES.

LUNG

CONGESTION :
VESSELS OR SINUSOIDS ARE MARKEDLY DISTENDED WITH ERYTHROCYTES.

STOMACH

HYPERKERATOSIS :
THE STRATIFIED SQUAMOUS EPITHELIUM EXHIBITS THICKENING AND EXCESS CORNIFICATION.

PANCREAS

AUTOLYSIS PARTIAL :
NO OTHER CHANGES ARE SEEN. TISSUES ARE ALTERED. BY POST-MORTEM MODIFICATIONS AND DIAGNOSIS IS GIVEN WITH RESERVATION.

PITUITARY

ABSENT :
ORGAN OR TISSUE NOT REMOVED FROM ANIMAL OR NOT FOUND IN FIXATIVE.

ADRENALS

HYPERPLASIA OF THE GLOMERULAR LAYER :
THE GLOMERULAR LAYER IS THICKER THAN NORMAL.

OVARIES

HYPERTROPHIC CORPORA LUTEA :
ALL CORPORA LUTEA ARE IMPORTANT IN SIZE. THEY CONTAIN LARGE LUTEAL CELLS WITH ACIDOPHILIC CYTOPLASM.

UTERUS

NORMAL :
HISTOLOGICAL ASPECT WITHIN NORMAL LIMITS.

BAYER AG

INTESTINE

AUTOLYSIS :
THE TISSUES EXHIBIT AUTOLYSIS AND THEY ARE NOT INTERPRETABLE.

FEMALE 394 (1595/80)

HEART

CONGESTION :
VESSELS OR SINUSOIDS ARE MARKEDLY DISTENDED WITH ERYTHROCYTES.

LUNG

*** ALVEOLOGENIC CARCINOMA :
MULTIFOCAL
A MALIGNANT TUMOR OF THE LUNG TISSUE WITH SYNONYMS IN MICE FOR ADENOMA, CARCINOMA, ALVEOLOGENIC PAPILLARY CARCINOMA, PAPILLARY CYSTADENOMA, ADENOCARCINOMA, BRONCHIOLAR CELL CARCINOMA, BRONCHIOLAR-ALVEOLAR TUMOR, TYPE A TUMOR, TYPE B TUMOR, INTERMEDIATE TYPE I TUMOR AND COMMON PULMONARY TUMOR OF THE MOUSE.

CONGESTION :
VESSELS OR SINUSOIDS ARE MARKEDLY DISTENDED WITH ERYTHROCYTES.

LIVER

LEUKEMIC DEPOSITS :
ORGAN AND THE BLOOD ARE INVADED BY LEUKEMIC CELLS.

PANCREAS

ABSENT :
ORGAN OR TISSUE NOT REMOVED FROM ANIMAL OR NOT FOUND IN FIXATIVE.

SPLEEN

*** LYMPHOMA LYMPHOCYTIC :
THE NEOPLASM OF THE RETICULAR SYSTEM ORIGINATES FROM LYMPHOCYTES.

KIDNEYS

LEUKEMIC DEPOSITS :
ORGAN AND THE BLOOD ARE INVADED BY LEUKEMIC CELLS.

BLADDER

PERIARTERITIS :
NON SPECIFIC INFLAMMATION (ACUTE SUBACUTE OR CHRONIC) OF THE TUNICA ADVENTITIA (PERIVASCULAR GRANULOMA).

PITUITARY

ABSENT :
ORGAN OR TISSUE NOT REMOVED FROM ANIMAL OR NOT FOUND IN FIXATIVE.

OVARIES

ATROPHY :
THE ORGAN IS REDUCED IN SIZE.

UTERUS

ECTASIA SIMPLE :
UNILATERAL
THE LUMEN OF THE ORGAN IS ABNORMALLY ENLARGED.

ENDOMETRITIS :
CONTRALATERAL
ACUTE OR SUBACUTE INFLAMMATION IS SEEN IN ENDOMETRIUM.

FEMALE 395 (1589/80)

HEART

HYPERTROPHY :
THE SIZE OF THE ORGAN IS INCREASED WITHOUT STRUCTURAL ANOMALY.

LUNG

NORMAL :
HISTOLOGICAL ASPECT WITHIN NORMAL LIMITS.

LIVER

AUTOLYSIS :
THE TISSUES EXHIBIT AUTOLYSIS AND THEY ARE NOT INTERPRETABLE.

HYPERTROPHY :
THE SIZE OF THE ORGAN IS INCREASED WITHOUT STRUCTURAL ANOMALY.

PANCREAS

AUTOLYSIS :
THE TISSUES EXHIBIT AUTOLYSIS AND THEY ARE NOT INTERPRETABLE.

BAYER AG

SPLEEN

ABSENT :
ORGAN OR TISSUE NOT REMOVED FROM ANIMAL OR NOT FOUND IN FIXATIVE.

KIDNEYS

AUTOLYSIS PARTIAL :
NO OTHER CHANGES ARE SEEN. TISSUES ARE ALTERED BY POST-MORTEM MODIFICATIONS AND DIAGNOSIS IS GIVEN WITH RESERVATION.

BLADDER

AUTOLYSIS :
THE TISSUES EXHIBIT AUTOLYSIS AND THEY ARE NOT INTERPRETABLE.

PITUITARY

AUTOLYSIS :
THE TISSUES EXHIBIT AUTOLYSIS AND THEY ARE NOT INTERPRETABLE.

OVARIES

ATROPHY :
BILATERAL
THE ORGAN IS REDUCED IN SIZE.

UTERUS

NORMAL :
HISTOLOGICAL ASPECT WITHIN NORMAL LIMITS.

CERVIX

*** LEIOMYOSARCOMA :
MALIGNANT TUMOR DERIVED FROM SMOOTH MUSCLE FIBERS.

FEMALE 396 (1593/80)

HEART

INFLAMMATION CHRONIC :
MINIMAL FOCAL
THE INTERSTITIAL TISSUES SHOW INFILTRATION BY MONONUCLEAR CELLS AND INCREASE IN FIBROUS STROMA.

TRACHEA

LEUKEMIC DEPOSITS :
ORGAN AND THE BLOOD ARE INVADED BY LEUKEMIC CELLS.

NF3.36 FEMALE 396 CONTINUED

LUNG

LEUKEMIC DEPOSITS :
ORGAN AND THE BLOOD ARE INVADED BY LEUKEMIC CELLS.

STOMACH

LEUKEMIC DEPOSITS :
ORGAN AND THE BLOOD ARE INVADED BY LEUKEMIC CELLS.

LIVER

LEUKEMIC DEPOSITS :
ORGAN AND THE BLOOD ARE INVADED BY LEUKEMIC CELLS.

PANCREAS

LEUKEMIC DEPOSITS :
ORGAN AND THE BLOOD ARE INVADED BY LEUKEMIC CELLS.

SPLEEN

*** LYMPHOMA LYMPHOCYTIC :
THE NEOPLASM OF THE RETICULAR SYSTEM ORIGINATES FROM LYMPHOCYTES.

KIDNEYS

LEUKEMIC DEPOSITS :
ORGAN AND THE BLOOD ARE INVADED BY LEUKEMIC CELLS.

BLADDER

LEUKEMIC DEPOSITS :
ORGAN AND THE BLOOD ARE INVADED BY LEUKEMIC CELLS.

THYROID

LEUKEMIC DEPOSITS :
ORGAN AND THE BLOOD ARE INVADED BY LEUKEMIC CELLS.

ADRENALS

LEUKEMIC DEPOSITS :
ORGAN AND THE BLOOD ARE INVADED BY LEUKEMIC CELLS.

SKELETAL MUSCLE

LEUKEMIC DEPOSITS :
ORGAN AND THE BLOOD ARE INVADED BY LEUKEMIC CELLS.

BAYER AG

OVARIES

ABSENT :
ORGAN OR TISSUE NOT REMOVED FROM ANIMAL OR NOT FOUND IN FIXATIVE.

FEMUR

LEUKEMIC DEPOSITS :
ORGAN AND THE BLOOD ARE INVADED BY LEUKEMIC CELLS.

FEMALE 397 (1651/80)

LUNG

LEUKEMIC DEPOSITS :
ORGAN AND THE BLOOD ARE INVADED BY LEUKEMIC CELLS.

STOMACH

ULCERATION :
CIRCUMSCRIBED LOSS OF SUBSTANCE FROM THE EPITHELIAL SURFACE ACCOMPANIED BY INFLAMMATION OF THE ADJACENT TISSUE IS PRESEN

LIVER

LEUKEMIC DEPOSITS :
ORGAN AND THE BLOOD ARE INVADED BY LEUKEMIC CELLS.

SPLEEN

*** LYMPHOMA LYMPHOCYTIC :
THE NEOPLASM OF THE RETICULAR SYSTEM ORIGINATES FROM LYMPHOCYTES.

KIDNEYS

FIBROSIS :
BILATERAL
THERE IS AN INCREASE IN INTERSTITIAL FIBROUS TISSUE.

TUBULOPATHY :
BILATERAL
TUBULAR DEGENERATIVE CHANGES ARE PRESENT WHICH MAY BE ASSOCIATED WITH TUBULAR DILATATION.

BLADDER

INFLAMMATION CHRONIC :
THERE IS AN INFILTRATION BY MONONUCLEAR CELLS IN THE MUCOSA AND SUBMUCOSA.

PITUITARY

ABSENT :
ORGAN OR TISSUE NOT REMOVED FROM ANIMAL OR NOT FOUND IN FIXATIVE.

ADRENALS

PIGMENTATION :
MINIMAL
NUMEROUS MACROPHAGES CONTAIN A GRANULAR BROWN CYTOPLASMIC PIGMENT.

SKELETAL MUSCLE

ABSENT :
ORGAN OR TISSUE NOT REMOVED FROM ANIMAL OR NOT FOUND IN FIXATIVE.

SCIATIC NERVE

ABSENT :
ORGAN OR TISSUE NOT REMOVED FROM ANIMAL OR NOT FOUND IN FIXATIVE.

OVARIES

ATROPHY :
BILATERAL
THE ORGAN IS REDUCED IN SIZE.

UTERUS

NORMAL :
HISTOLOGICAL ASPECT WITHIN NORMAL LIMITS.

CERVICAL LYMPH NODE

HYPERTROPHY :
THE SIZE OF THE ORGAN IS INCREASED WITHOUT STRUCTURAL ANOMALY.

BAYER AG BAYER AG BAYER AG BAYER AG

APPENDIX III

LIST OF ANIMALS BEARING TUMOURS

BAYER AG BAYER AG BAYER AG BAYER AG

SMCT 1 CHRONIC TOXICITY STUDY IN MICE: SYSTEMATIC

HISTOPATHOLOGY: LIST OF TUMOR BEARERS

PRODUCT : SMG 0519

TIME : 105 WEEKS
THIS GROUP COMPRISED : 11 MALES

GROUP : CONTROL
ROUTE : DIETARY
DOSE : 0 PPM

MALE 16 (1470/80)

LUNG

*** ALVEOLOGENIC CARCINOMA :
A MALIGNANT TUMOR OF THE LUNG TISSUE WITH SYNONYMS IN MICE FOR ADENOMA, CARCINOMA, ALVEOLOGENIC PAPILLARY CARCINOMA, PAPILLARY CYSTADENOMA, ADENOCARCINOMA, BRONCHIOLAR CELL CARCINOMA, BRONCHIOLAR-ALVEOLAR TUMOR, TYPE A TUMOR, TYPE B TUMOR, INTERMEDIATE TYPE I TUMOR AND COMMON PULMONARY TUMOR OF THE MOUSE.

LIVER

*** ADENOMA HEPATIC BENIGN :
DISTINCT NODULES COMPRESS THE ADJACENT LIVER PARENCHYMA, ARE CHARACTERIZED BY WELL DIFFERENTIATED HEPATOCYTES AND DO NOT SHOW PORTAL TRIADS.

MALE 22 (1472/80)

ADRENALS

*** ADENOMA :
UNILATERAL
THIS IS BENIGN GLANDULAR EPITHELIAL TUMOR.

MALE 24 (1473/80)

LUNG

*** ALVEOLOGENIC CARCINOMA :
MULTIFOCAL
A MALIGNANT TUMOR OF THE LUNG TISSUE WITH SYNONYMS IN MICE FOR ADENOMA, CARCINOMA, ALVEOLOGENIC PAPILLARY CARCINOMA, PAPILLARY CYSTADENOMA, ADENOCARCINOMA, BRONCHIOLAR CELL CARCINOMA, BRONCHIOLAR-ALVEOLAR TUMOR, TYPE A TUMOR, TYPE B TUMOR, INTERMEDIATE TYPE I TUMOR AND COMMON PULMONARY TUMOR OF THE MOUSE.

MALE 31 (1475/80)

LUNG

*** ALVEOLOGENIC CARCINOMA :
A MALIGNANT TUMOR OF THE LUNG TISSUE WITH SYNONYMS IN MICE FOR ADENOMA, CARCINOMA, ALVEOLOGENIC PAPILLARY CARCINOMA, PAPILLARY CYSTADENOMA, ADENOCARCINOMA, BRONCHIOLAR CELL CARCINOMA, BRONCHIOLAR-ALVEOLAR TUMOR, TYPE A TUMOR, TYPE B TUMOR, INTERMEDIATE TYPE I TUMOR AND COMMON PULMONARY TUMOR OF THE MOUSE.

ADRENALS

*** ADENOMA :
UNILATERAL
THIS IS BENIGN GLANDULAR EPITHELIAL TUMOR.

FAT

*** LIPOMA :
THE BENIGN TUMOR IS COMPOSED OF NORMAL FAT CELLS WITH SOME VASCULAR FIBROUS STROMA.

MALE 33 (1476/80)

LIVER

*** ADENOMA HEPATIC BENIGN :
DISTINCT NODULES COMPRESS THE ADJACENT LIVER PARENCHYMA, ARE CHARACTERIZED BY WELL DIFFERENTIATED HEPATOCYTES AND DO NOT SHOW PORTAL TRIADS.

BAYER AG

MALE 35 (1477/80)

LUNG

*** ALVEOLOGENIC CARCINOMA :
A MALIGNANT TUMOR OF THE LUNG TISSUE WITH SYNONYMS IN MICE FOR ADENOMA, CARCINOMA, ALVEOLOGENIC PAPILLARY CARCINOMA, PAPILLARY CYSTADENOMA, ADENOCARCINOMA, BRONCHIOLAR CELL CARCINOMA, BRONCHIOLAR-ALVEOLAR TUMOR, TYPE A TUMOR, TYPE B TUMOR, INTERMEDIATE TYPE I TUMOR AND COMMON PULMONARY TUMOR OF THE MOUSE.

MALE 40 (1478/80)

LUNG

*** ALVEOLOGENIC CARCINOMA :
A MALIGNANT TUMOR OF THE LUNG TISSUE WITH SYNONYMS IN MICE FOR ADENOMA, CARCINOMA, ALVEOLOGENIC PAPILLARY CARCINOMA, PAPILLARY CYSTADENOMA, ADENOCARCINOMA, BRONCHIOLAR CELL CARCINOMA, BRONCHIOLAR-ALVEOLAR TUMOR, TYPE A TUMOR, TYPE B TUMOR, INTERMEDIATE TYPE I TUMOR AND COMMON PULMONARY TUMOR OF THE MOUSE.

ADRENALS

*** ADENOMA :
UNILATERAL
THIS IS BENIGN GLANDULAR EPITHELIAL TUMOR.

NMCT 1 CHRONIC TOXICITY STUDY IN MICE: NONSYSTEMATIC

HISTOPATHOLOGY: LIST OF TUMOR BEARERS

PRODUCT : XWG 0519 CD

GROUP : CONTROL
ROUTE : DIETARY
DOSE : 0 PPM

TIME : 105 WEEKS
THIS GROUP COMPRISED : 39 MALES

MALE 2 (1644/80)

LUNG

*** ALVEOLOGENIC CARCINOMA :
A MALIGNANT TUMOR OF THE LUNG TISSUE WITH SYNONYMS IN MICE FOR ADENOMA, CARCINOMA, ALVEOLOGENIC PAPILLARY CARCINOMA, PAPILLARY CYSTADENOMA, ADENOCARCINOMA, BRONCHIOLAR CELL CARCINOMA, BRONCHIOLAR-ALVEOLAR TUMOR, TYPE A TUMOR, TYPE B TUMOR, INTERMEDIATE TYPE I TUMOR AND COMMON PULMONARY TUMOR OF THE MOUSE.

MALE 3 (1641/80)

LUNG

*** ALVEOLOGENIC CARCINOMA :
A MALIGNANT TUMOR OF THE LUNG TISSUE WITH SYNONYMS IN MICE FOR ADENOMA, CARCINOMA, ALVEOLOGENIC PAPILLARY CARCINOMA, PAPILLARY CYSTADENOMA, ADENOCARCINOMA, BRONCHIOLAR CELL CARCINOMA, BRONCHIOLAR-ALVEOLAR TUMOR, TYPE A TUMOR, TYPE B TUMOR, INTERMEDIATE TYPE I TUMOR AND COMMON PULMONARY TUMOR OF THE MOUSE.

MALE 6 (1620/80)

BAYER AG BAYER AG BAYER AG

SPLEEN

*** LYMPHOMA LYMPHOCYTIC :
THE NEOPLASM OF THE RETICULAR SYSTEM ORIGINATES FROM LYMPHOCYTES.

MALE 7 (1611/80)

THYMUS

*** LYMPHOMA LYMPHOCYTIC :
THE NEOPLASM OF THE RETICULAR SYSTEM ORIGINATES FROM LYMPHOCYTES.

MALE 8 (1617/80)

LUNG

*** ALVEOLOGENIC CARCINOMA :
A MALIGNANT TUMOR OF THE LUNG TISSUE WITH SYNONYMS IN MICE FOR ADENOMA, CARCINOMA, ALVEOLOGENIC PAPILLARY CARCINOMA, PAPILLARY CYSTADENOMA, ADENOCARCINOMA, BRONCHIOLAR CELL CARCINOMA, BRONCHIOLAR-ALVEOLAR TUMOR, TYPE A TUMOR, TYPE B TUMOR, INTERMEDIATE TYPE I TUMOR AND COMMON PULMONARY TUMOR OF THE MOUSE.

MESENTERY

*** FIBROMYXOMA :
MALIGNANT TUMOR MADE OF SPINDLE-SHAPED CELLS SCATTERED IN A MUCOID-LIKE STROMA; MAY OR MAY NOT BE PARTIALLY CALCIFIED.

MALE 11 (1619/80)

THYMUS

*** LYMPHOMA LYMPHOCYTIC :
THE NEOPLASM OF THE RETICULAR SYSTEM ORIGINATES FROM LYMPHOCYTES.

BONE

*** OSTEOMA :
THIS BENIGN WELL CIRCUMSCRIBED TUMOR IS COMPOSED OF WELL-DEVELOPED BONE.

MALE 12 (1004/80)

SPLEEN

*** LYMPHOMA STEM CELLS :
THE NEOPLASM OF THE RETICULAR SYSTEM ORIGINATES FROM STEM CELLS.

MALE 14 (1625/80)

SPLEEN

*** LYMPHOMA LYMPHOLYTIC :
THE NEOPLASM OF THE RETICULAR SYSTEM ORIGINATES FROM LYMPHOCYTES.

MALE 15 (1612/80)

TESTES

*** INTERSTITIAL CELL TUMOR :
UNILATERAL
THIS BENIGN TUMOR IS COMPOSED OF LARGE EPITHELIAL CELLS WITH ABUNDANT ACIDOPHILIC CYTOPLASM.

MALE 16 (1610/80)

BAYER AG

NMCT 4 MALE 18 CONTINUED

LYMPH NODE

*** LYMPHOMA STEM CELLS :
THE NEOPLASM OF THE RETICULAR SYSTEM ORIGINATES FROM STEM CELLS.

MALE 20 (1638/80)

LUNG

*** ALVEOLOGENIC CARCINOMA :
MULTIFOCAL
A MALIGNANT TUMOR OF THE LUNG TISSUE WITH SYNONYMS IN MICE FOR ADENOMA, CARCINOMA, ALVEOLOGENIC PAPILLARY CARCINOMA, PAPILLARY CYSTADENOMA, ADENOCARCINOMA, BRONCHIOLAR CELL CARCINOMA, BRONCHIOLAR-ALVEOLAR TUMOR, TYPE A TUMOR, TYPE B TUMOR, INTERMEDIATE TYPE I TUMOR AND COMMON PULMONARY TUMOR OF THE MOUSE.

MALE 21 (1608/80)

SPLEEN

*** LYMPHOMA STEM CELLS :
THE NEOPLASM OF THE RETICULAR SYSTEM ORIGINATES FROM STEM CELLS.

LYMPH NODE

*** LYMPHOMA STEM CELLS :
THE NEOPLASM OF THE RETICULAR SYSTEM ORIGINATES FROM STEM CELLS.

MALE 23 (1614/80)

LUNG

*** ALVEOLOGENIC CARCINOMA :
A MALIGNANT TUMOR OF THE LUNG TISSUE WITH

NMCT 5 MALE 23 CONTINUED

LUNG CONTINUED

SYNONYMS IN MICE FOR ADENOMA, CARCINOMA, ALVEOLOGENIC PAPILLARY CARCINOMA, PAPILLARY CYSTADENOMA, ADENOCARCINOMA, BRONCHIOLAR CELL CARCINOMA, BRONCHIOLAR-ALVEOLAR TUMOR, TYPE A TUMOR, TYPE B TUMOR, INTERMEDIATE TYPE I TUMOR AND COMMON PULMONARY TUMOR OF THE MOUSE.

SPLEEN

*** LYMPHOMA LYMPHOCYTIC :
THE NEOPLASM OF THE RETICULAR SYSTEM ORIGINATES FROM LYMPHOCYTES.

MALE 25 (1634/80)

LUNG

*** ALVEOLOGENIC CARCINOMA :
A MALIGNANT TUMOR OF THE LUNG TISSUE WITH SYNONYMS IN MICE FOR ADENOMA, CARCINOMA, ALVEOLOGENIC PAPILLARY CARCINOMA, PAPILLARY CYSTADENOMA, ADENOCARCINOMA, BRONCHIOLAR CELL CARCINOMA, BRONCHIOLAR-ALVEOLAR TUMOR, TYPE A TUMOR, TYPE B TUMOR, INTERMEDIATE TYPE I TUMOR AND COMMON PULMONARY TUMOR OF THE MOUSE.

LIVER

*** ADENOMA HEPATIC BENIGN :
DISTINCT NODULES COMPRESS THE ADJACENT LIVER PARENCHYMA, ARE CHARACTERIZED BY WELL DIFFERENTIATED HEPATOCYTES AND DO NOT SHOW PORTAL TRIADS.

*** METASTASIS : (alveologenic carcinoma)
A SECONDARY MALIGNANT TUMOR DEVELOPED AWAY FROM THE INITIAL GROWTH.

MALE 27 (0261/81)

LUNG

*** ALVEOLOGENIC CARCINOMA :
A MALIGNANT TUMOR OF THE LUNG TISSUE WITH SYNONYMS IN MICE FOR ADENOMA, CARCINOMA, ALVEOLOGENIC PAPILLARY CARCINOMA, PAPILLARY

BAYER AG

MALE 27 CONTINUED 570

LUNG CONTINUED

CYSTADENOMA, ADENOCARCINOMA, BRONCHIOLAR CELL CARCINOMA, BRONCHIOLAR-ALVEOLAR TUMOR, TYPE A TUMOR, TYPE B TUMOR, INTERMEDIATE TYPE I TUMOR AND COMMON PULMONARY TUMOR OF THE MOUSE.

LIVER

*** ADENOMA HEPATIC BENIGN :
DISTINCT NODULES COMPRESS THE ADJACENT LIVER PARENCHYMA, ARE CHARACTERIZED BY WELL DIFFERENTIATED HEPATOCYTES AND DO NOT SHOW PORTAL TRIADS.

MALE 29 (1623/80)

SPLEEN

*** LYMPHOMA LYMPHOCYTIC :
THE NEOPLASM OF THE RETICULAR SYSTEM ORIGINATES FROM LYMPHOCYTES.

LYMPH NODE

*** LYMPHOMA LYMPHOCYTIC :
THE NEOPLASM OF THE RETICULAR SYSTEM ORIGINATES FROM LYMPHOCYTES.

MALE 30 (1635/80)

LUNG

*** ALVEOLOGENIC CARCINOMA :
A MALIGNANT TUMOR OF THE LUNG TISSUE WITH SYNONYMS IN MICE FOR ADENOMA, CARCINOMA, ALVEOLOGENIC PAPILLARY CARCINOMA, PAPILLARY CYSTADENOMA, ADENOCARCINOMA, BRONCHIOLAR CELL CARCINOMA, BRONCHIOLAR-ALVEOLAR TUMOR, TYPE A TUMOR, TYPE B TUMOR, INTERMEDIATE TYPE I TUMOR AND COMMON PULMONARY TUMOR OF THE MOUSE.

SPLEEN

*** LYMPHOMA LYMPHOCYTIC :
THE NEOPLASM OF THE RETICULAR SYSTEM ORIGINATES FROM LYMPHOCYTES.

LYMPH NODE

*** LYMPHOMA LYMPHOCYTIC :
THE NEOPLASM OF THE RETICULAR SYSTEM ORIGINATES FROM LYMPHOCYTES.

MALE 32 (1633/80)

LUNG

*** ALVEOLOGENIC CARCINOMA :
A MALIGNANT TUMOR OF THE LUNG TISSUE WITH SYNONYMS IN MICE FOR ADENOMA, CARCINOMA, ALVEOLOGENIC PAPILLARY CARCINOMA, PAPILLARY CYSTADENOMA, ADENOCARCINOMA, BRONCHIOLAR CELL CARCINOMA, BRONCHIOLAR-ALVEOLAR TUMOR, TYPE A TUMOR, TYPE B TUMOR, INTERMEDIATE TYPE I TUMOR AND COMMON PULMONARY TUMOR OF THE MOUSE.

MALE 34 (1621/80)

LUNG

*** ALVEOLOGENIC CARCINOMA :
A MALIGNANT TUMOR OF THE LUNG TISSUE WITH SYNONYMS IN MICE FOR ADENOMA, CARCINOMA, ALVEOLOGENIC PAPILLARY CARCINOMA, PAPILLARY CYSTADENOMA, ADENOCARCINOMA, BRONCHIOLAR CELL CARCINOMA, BRONCHIOLAR-ALVEOLAR TUMOR, TYPE A TUMOR, TYPE B TUMOR, INTERMEDIATE TYPE I TUMOR AND COMMON PULMONARY TUMOR OF THE MOUSE.

LIVER

*** ADENOCARCINOMA :
MALIGNANT EPITHELIAL TUMOR SHOWING VARIOUS WELL DIFFERENTIATED MORPHOLOGICAL ASPECTS.

MALE 36 (1613/80)

BAYER AG BAYER AG BAYER AG

LUNG

*** ALVEOLOGENIC CARCINOMA :
A MALIGNANT TUMOR OF THE LUNG TISSUE WITH SYNONYMS IN MICE FOR ADENOMA, CARCINOMA, ALVEOLOGENIC PAPILLARY CARCINOMA, PAPILLARY CYSTADENOMA, ADENOCARCINOMA, BRONCHIOLAR CELL CARCINOMA, BRONCHIOLAR-ALVEOLAR TUMOR, TYPE A TUMOR, TYPE B TUMOR, INTERMEDIATE TYPE I TUMOR AND COMMON PULMONARY TUMOR OF THE MOUSE.

LIVER

*** ADENOCARCINOMA :
MALIGNANT EPITHELIAL TUMOR SHOWING VARIOUS WELL DIFFERENTIATED MORPHOLOGICAL ASPECTS.

MALE 38 (1007/80)

THYMUS

*** LYMPHOMA LYMPHOCYTIC :
THE NEOPLASM OF THE RETICULAR SYSTEM ORIGINATES FROM LYMPHOCYTES.

SPLEEN

*** LYMPHOMA LYMPHOCYTIC :
THE NEOPLASM OF THE RETICULAR SYSTEM ORIGINATES FROM LYMPHOCYTES.

MALE 39 (1616/80)

LUNG

*** ALVEOLOGENIC CARCINOMA :
A MALIGNANT TUMOR OF THE LUNG TISSUE WITH SYNONYMS IN MICE FOR ADENOMA, CARCINOMA, ALVEOLOGENIC PAPILLARY CARCINOMA, PAPILLARY CYSTADENOMA, ADENOCARCINOMA, BRONCHIOLAR CELL CARCINOMA, BRONCHIOLAR-ALVEOLAR TUMOR, TYPE A TUMOR, TYPE B TUMOR, INTERMEDIATE TYPE I TUMOR AND COMMON PULMONARY TUMOR OF THE MOUSE.

MALE 42 (1636/80)

LUNG

*** ALVEOLOGENIC CARCINOMA :
MULTIFOCAL
A MALIGNANT TUMOR OF THE LUNG TISSUE WITH SYNONYMS IN MICE FOR ADENOMA, CARCINOMA, ALVEOLOGENIC PAPILLARY CARCINOMA, PAPILLARY CYSTADENOMA, ADENOCARCINOMA, BRONCHIOLAR CELL CARCINOMA, BRONCHIOLAR-ALVEOLAR TUMOR, TYPE A TUMOR, TYPE B TUMOR, INTERMEDIATE TYPE I TUMOR AND COMMON PULMONARY TUMOR OF THE MOUSE.

PANCREAS

*** ISLET CELL ADENOMA :
THIS IS A BENIGN GLANDULAR TUMOR ARISING FROM THE ISLET CELLS.

SPLEEN

*** LYMPHOMA STEM CELLS :
THE NEOPLASM OF THE RETICULAR SYSTEM ORIGINATES FROM STEM CELLS.

MALE 43 (1639/80)

SPLEEN

*** LYMPHOMA LYMPHOCYTIC :
THE NEOPLASM OF THE RETICULAR SYSTEM ORIGINATES FROM LYMPHOCYTES.

MALE 44 (163n/80)

LIVER

*** CYSTADENOMA :
CYSTIC AND ADENOMATOUS CHANGE WITH CYSTIC HYPERPLASIA.

BAYER AG

MALE 47 (1632/80)

SPLEEN

*** LYMPHOMA STEM CELLS :
THE NEUPLASM OF THE RETICULAR SYSTEM ORIGINATES FROM STEM CELLS.

LYMPH NODE

*** LYMPHOMA STEM CELLS :
THE NEOPLASM OF THE RETICULAR SYSTEM ORIGINATES FROM STEM CELLS.

MALE 48 (1627/80)

LUNG

*** ALVEOLOGENIC CARCINOMA :
MULTIFOCAL
A MALIGNANT TUMOR OF THE LUNG TISSUE WITH SYNONYMS IN MICE FOR ADENOMA, CARCINOMA, ALVEOLOGENIC PAPILLARY CARCINOMA, PAPILLARY CYSTADENOMA, ADENOCARCINOMA, BRONCHIOLAR CELL CARCINOMA, BRONCHIOLAR-ALVEOLAR TUMOR, TYPE A TUMOR, TYPE B TUMOR, INTERMEDIATE TYPE I TUMOR AND COMMON PULMONARY TUMOR OF THE MOUSE.

SPLEEN

*** LYMPHOMA LYMPHOCYTIC :
THE NEOPLASM OF THE RETICULAR SYSTEM ORIGINATES FROM LYMPHOCYTES.

LYMPH NODE

*** LYMPHOMA LYMPHOCYTIC :
THE NEOPLASM OF THE RETICULAR SYSTEM ORIGINATES FROM LYMPHOCYTES.

MALE 49 (1609/80)

NMCT11 MALE 49 CONTINUED

LUNG

*** ALVEOLOGENIC CARCINOMA :
A MALIGNANT TUMOR OF THE LUNG TISSUE WITH SYNONYMS IN MICE FOR ADENOMA, CARCINOMA, ALVEOLOGENIC PAPILLARY CARCINOMA, PAPILLARY CYSTADENOMA, ADENOCARCINOMA, BRONCHIOLAR CELL CARCINOMA, BRONCHIOLAR-ALVEOLAR TUMOR, TYPE A TUMOR, TYPE B TUMOR, INTERMEDIATE TYPE I TUMOR AND COMMON PULMONARY TUMOR OF THE MOUSE.

LIVER

*** ADENOMA HEPATIC BENIGN :
DISTINCT NODULES COMPRESS THE ADJACENT LIVER PARENCHYMA, ARE CHARACTERIZED BY WELL DIFFERENTIATED HEPATOCYTES AND DO NOT SHOW PORTAL TRIADS.

SPLEEN

*** LYMPHOMA STEM CELLS :
THE NEOPLASM OF THE RETICULAR SYSTEM ORIGINATES FROM STEM CELLS.

LYMPH NODE

*** LYMPHOMA STEM CELLS :
THE NEOPLASM OF THE RETICULAR SYSTEM ORIGINATES FROM STEM CELLS.

MALE 50 (1631/80)

SPLEEN

*** LYMPHOMA LYMPHOCYTIC :
THE NEOPLASM OF THE RETICULAR SYSTEM ORIGINATES FROM LYMPHOCYTES.

BAYER AG

SMIT 1 CHRONIC TOXICITY STUDY IN MICE: SYSTEMATIC

HISTOPATHOLOGY: LIST OF TUMOR BEARERS

PRODUCT : XMG 6519 GROUP : 1
ROUTE : DIETARY
TIME : 105 WEEKS DOSE : 125 PPM
THIS GROUP COMPRISED : 11 MALES

MALE 107 (1496/80)

LUNG

*** ALVEOLOGENIC CARCINOMA :
MULTIFOCAL
A MALIGNANT TUMOR OF THE LUNG TISSUE WITH SYNONYMS IN MICE FOR ADENOMA, CARCINOMA, ALVEOLOGENIC PAPILLARY CARCINOMA, PAPILLARY CYSTADENOMA, ADENOCARCINOMA, BRONCHIOLAR CELL CARCINOMA, BRONCHIOLAR-ALVEOLAR TUMOR, TYPE A TUMOR, TYPE B TUMOR, INTERMEDIATE TYPE I TUMOR AND COMMON PULMONARY TUMOR OF THE MOUSE.

MALE 117 (1497/80)

ADRENALS

*** ADENOMA :
UNILATERAL
THIS IS BENIGN GLANDULAR EPITHELIAL TUMOR.

MALE 119 (1498/80)

LUNG

*** ALVEOLOGENIC CARCINOMA :
A MALIGNANT TUMOR OF THE LUNG TISSUE WITH SYNONYMS IN MICE FOR ADENOMA, CARCINOMA, ALVEOLOGENIC PAPILLARY CARCINOMA, PAPILLARY CYSTADENOMA, ADENOCARCINOMA, BRONCHIOLAR

SMIT 2 MALE 119 CONTINUED

LUNG CONTINUED

CELL CARCINOMA, BRONCHIOLAR-ALVEOLAR TUMOR, TYPE A TUMOR, TYPE B TUMOR, INTERMEDIATE TYPE I TUMOR AND COMMON PULMONARY TUMOR OF THE MOUSE.

MALE 123 (1499/80)

LUNG

*** ALVEOLOGENIC CARCINOMA :
A MALIGNANT TUMOR OF THE LUNG TISSUE WITH SYNONYMS IN MICE FOR ADENOMA, CARCINOMA, ALVEOLOGENIC PAPILLARY CARCINOMA, PAPILLARY CYSTADENOMA, ADENOCARCINOMA, BRONCHIOLAR CELL CARCINOMA, BRONCHIOLAR-ALVEOLAR TUMOR, TYPE A TUMOR, TYPE B TUMOR, INTERMEDIATE TYPE I TUMOR AND COMMON PULMONARY TUMOR OF THE MOUSE.

MALE 127 (1500/80)

ADRENALS

*** PHEOCHROMOCYTOMA :
UNILATERAL
THIS TUMOR IS COMPOSED OF POLYHEDRAL CELLS WHICH ARISE FROM THE CHROMAFFIN CELLS OF THE ADRENAL MEDULLA AND FORM LOBULES SEPARATED BY VASCULAR CONNECTIVE TISSUE SEPTA.

MALE 128 (1501/80)

LUNG

*** ALVEOLOGENIC CARCINOMA :
A MALIGNANT TUMOR OF THE LUNG TISSUE WITH SYNONYMS IN MICE FOR ADENOMA, CARCINOMA, ALVEOLOGENIC PAPILLARY CARCINOMA, PAPILLARY CYSTADENOMA, ADENOCARCINOMA, BRONCHIOLAR CELL CARCINOMA, BRONCHIOLAR-ALVEOLAR TUMOR, TYPE A TUMOR, TYPE B TUMOR, INTERMEDIATE

BAYER AG BAYER AG BAYER AG

LUNG CONTINUED
TYPE I TUMOR AND COMMON PULMONARY TUMOR OF THE MOUSE.

ADRENALS

*** ADENOMA :
UNILATERAL
THIS IS BENIGN GLANDULAR EPITHELIAL TUMOR.

TESTES

*** INTERSTITIAL CELL TUMOR :
UNILATERAL FOCAL
THIS BENIGN TUMOR IS COMPOSED OF LARGE EPITHELIAL CELLS WITH ABUNDANT ACIDOPHILIC CYTOPLASM.

MALE 141 (1502/80)

LUNG

*** ALVEOLOGENIC CARCINOMA :
A MALIGNANT TUMOR OF THE LUNG TISSUE WITH SYNONYMS IN MICE FOR ADENOMA, CARCINOMA, ALVEOLOGENIC PAPILLARY CARCINOMA, PAPILLARY CYSTADENOMA, ADENOCARCINOMA, BRONCHIOLAR CELL CARCINOMA, BRONCHIOLAR-ALVEOLAR TUMOR, TYPE A TUMOR, TYPE B TUMOR, INTERMEDIATE TYPE I TUMOR AND COMMON PULMONARY TUMOR OF THE MOUSE.

MALE 142 (1503/80)

LUNG

*** ALVEOLOGENIC CARCINOMA :
A MALIGNANT TUMOR OF THE LUNG TISSUE WITH SYNONYMS IN MICE FOR ADENOMA, CARCINOMA, ALVEOLOGENIC PAPILLARY CARCINOMA, PAPILLARY CYSTADENOMA, ADENOCARCINOMA, BRONCHIOLAR CELL CARCINOMA, BRONCHIOLAR-ALVEOLAR TUMOR, TYPE A TUMOR, TYPE B TUMOR, INTERMEDIATE TYPE I TUMOR AND COMMON PULMONARY TUMOR OF THE MOUSE.

MALE 149 (1505/60)

LUNG

*** ALVEOLOGENIC CARCINOMA :
A MALIGNANT TUMOR OF THE LUNG TISSUE WITH SYNONYMS IN MICE FOR ADENOMA, CARCINOMA, ALVEOLOGENIC PAPILLARY CARCINOMA, PAPILLARY CYSTADENOMA, ADENOCARCINOMA, BRONCHIOLAR CELL CARCINOMA, BRONCHIOLAR-ALVEOLAR TUMOR, TYPE A TUMOR, TYPE B TUMOR, INTERMEDIATE TYPE I TUMOR AND COMMON PULMONARY TUMOR OF THE MOUSE.

LIVER

*** ADENOMA HEPATIC BENIGN :
DISTINCT NODULES COMPRESS THE ADJACENT LIVER PARENCHYMA, ARE CHARACTERIZED BY WELL DIFFERENTIATED HEPATOCYTES AND DO NOT SHOW PORTAL TRIADS.

BAYER AG BAYER AG BAYER AG BAYER AG

NM1T 1 CHRONIC TOXICITY STUDY IN MICE: NONSYSTEMATIC

HISTOPATHOLOGY: LIST OF TUMOR BEARERS

PRODUCT : XMG 0519 GROUP : 1
ROUTE : DIETARY
TIME : 105 WEEKS DOSE : 125 PPM
THIS GROUP COMPRISED : 39 MALES

MALE 102 (1737/80)

LIVER

*** ADENOMA HEPATIC BENIGN :
SEVERE
DISTINCT NODULES COMPRESS THE ADJACENT LIVER PARENCHYMA, ARE CHARACTERIZED BY WELL DIFFERENTIATED HEPATOCYTES AND DO NOT SHOW PORTAL TRIADS.

ADRENALS

*** PHEOCHROMOCYTOMA :
THIS TUMOR IS COMPOSED OF POLYHEDRAL CELLS WHICH ARISE FROM THE CHROMAFFIN CELLS OF THE ADRENAL MEDULLA AND FORM LOBULES SEPARATED BY VASCULAR CONNECTIVE TISSUE SEPTA.

MALE 105 (1740/80)

LIVER

*** ADENOMA HEPATIC BENIGN :
MULTIFOCAL
DISTINCT NODULES COMPRESS THE ADJACENT LIVER PARENCHYMA, ARE CHARACTERIZED BY WELL DIFFERENTIATED HEPATOCYTES AND DO NOT SHOW PORTAL TRIADS.

MALE 106 (1706/80)

SPLEEN

*** LYMPHOMA LYMPHOCYTIC :

UNIT 2 MALE 106 CONTINUED

SPLEEN CONTINUED

THE NEOPLASM OF THE RETICULAR SYSTEM ORIGINATES FROM LYMPHOCYTES.

LYMPH NODE

*** LYMPHOMA LYMPHOCYTIC :
THE NEOPLASM OF THE RETICULAR SYSTEM ORIGINATES FROM LYMPHOCYTES.

MALE 111 (1701/80)

HEART

*** METASTASIS : (alveologenic carcinoma)
A SECONDARY MALIGNANT TUMOR DEVELOPED AWAY FROM THE INITIAL GROWTH.

LUNG

*** ALVEOLOGENIC CARCINOMA :
MULTIFOCAL
A MALIGNANT TUMOR OF THE LUNG TISSUE WITH SYNONYMS IN MICE FOR ADENOMA, CARCINOMA, ALVEOLOGENIC PAPILLARY CARCINOMA, PAPILLARY CYSTADENOMA, ADENOCARCINOMA, BRONCHIOLAR CELL CARCINOMA, BRONCHIOLAR-ALVEOLAR TUMOR, TYPE A TUMOR, TYPE B TUMOR, INTERMEDIATE TYPE I TUMOR AND COMMON PULMONARY TUMOR OF THE MOUSE.

KIDNEYS

*** METASTASIS : (alveologenic carcinoma)
UNILATERAL
A SECONDARY MALIGNANT TUMOR DEVELOPED AWAY FROM THE INITIAL GROWTH.

ADRENALS

*** ADENOMA :
UNILATERAL
THIS IS BENIGN GLANDULAR EPITHELIAL TUMOR.

MALE 112 (1731/80)

BAYER AG BAYER AG BAYER AG

LUNG

*** ALVEOLOGENIC CARCINOMA :
MULTIFOCAL
A MALIGNANT TUMOR OF THE LUNG TISSUE WITH SYNONYMS IN MICE FOR ADENOMA, CARCINOMA, ALVEOLOGENIC PAPILLARY CARCINOMA, PAPILLARY CYSTADENOMA, ADENOCARCINOMA, BRONCHIOLAR CELL CARCINOMA, BRONCHIOLAR-ALVEOLAR TUMOR, TYPE A TUMOR, TYPE B TUMOR, INTERMEDIATE TYPE I TUMOR AND COMMON PULMONARY TUMOR OF THE MOUSE.

MALE 114 (1726/80)

LUNG

*** ALVEOLOGENIC CARCINOMA :
A MALIGNANT TUMOR OF THE LUNG TISSUE WITH SYNONYMS IN MICE FOR ADENOMA, CARCINOMA, ALVEOLOGENIC PAPILLARY CARCINOMA, PAPILLARY CYSTADENOMA, ADENOCARCINOMA, BRONCHIOLAR CELL CARCINOMA, BRONCHIOLAR-ALVEOLAR TUMOR, TYPE A TUMOR, TYPE B TUMOR, INTERMEDIATE TYPE I TUMOR AND COMMON PULMONARY TUMOR OF THE MOUSE.

MALE 115 (1735/80)

LUNG

*** ALVEOLOGENIC CARCINOMA :
MULTIFOCAL
A MALIGNANT TUMOR OF THE LUNG TISSUE WITH SYNONYMS IN MICE FOR ADENOMA, CARCINOMA, ALVEOLOGENIC PAPILLARY CARCINOMA, PAPILLARY CYSTADENOMA, ADENOCARCINOMA, BRONCHIOLAR CELL CARCINOMA, BRONCHIOLAR-ALVEOLAR TUMOR, TYPE A TUMOR, TYPE B TUMOR, INTERMEDIATE TYPE I TUMOR AND COMMON PULMONARY TUMOR OF THE MOUSE.

MALE 116 (1725/80)

LYMPH NODE

*** LYMPHOMA LYMPHOCYTIC :
THE NEUPLASM OF THE RETICULAR SYSTEM ORIGINATES FROM LYMPHOCYTES.

MALE 120 (1704/80)

ADRENALS

*** ADENOMA :
THIS IS BENIGN GLANDULAR EPITHELIAL TUMOR.

MALE 121 (1700/80)

LUNG

*** ALVEOLOGENIC CARCINOMA :
MULTIFOCAL
A MALIGNANT TUMOR OF THE LUNG TISSUE WITH SYNONYMS IN MICE FOR ADENOMA, CARCINOMA, ALVEOLOGENIC PAPILLARY CARCINOMA, PAPILLARY CYSTADENOMA, ADENOCARCINOMA, BRONCHIOLAR CELL CARCINOMA, BRONCHIOLAR-ALVEOLAR TUMOR, TYPE A TUMOR, TYPE B TUMOR, INTERMEDIATE TYPE I TUMOR AND COMMON PULMONARY TUMOR OF THE MOUSE.

MALE 125 (1696/80)

BAYER AG

LIVER

*** ADENOMA HEPATIC BENIGN :
MULTIFOCAL
DISTINCT NODULES COMPRESS THE ADJACENT LIVER PARENCHYMA, ARE CHARACTERIZED BY WELL DIFFERENTIATED HEPATOCYTES AND DO NOT SHOW PORTAL TRIADS.

MALE 126 (1675/80)

LUNG

*** ALVEOLOGENIC CARCINOMA :
A MALIGNANT TUMOR OF THE LUNG TISSUE WITH SYNONYMS IN MICE FOR ADENOMA, CARCINOMA, ALVEOLOGENIC PAPILLARY CARCINOMA, PAPILLARY CYSTADENOMA, ADENOCARCINOMA, BRONCHIOLAR CELL CARCINOMA, BRONCHIOLAR-ALVEOLAR TUMOR, TYPE A TUMOR, TYPE B TUMOR, INTERMEDIATE TYPE I TUMOR AND COMMON PULMONARY TUMOR OF THE MOUSE.

MALE 129 (1694/80)

LUNG

*** ALVEOLOGENIC CARCINOMA :
A MALIGNANT TUMOR OF THE LUNG TISSUE WITH SYNONYMS IN MICE FOR ADENOMA, CARCINOMA, ALVEOLOGENIC PAPILLARY CARCINOMA, PAPILLARY CYSTADENOMA, ADENOCARCINOMA, BRONCHIOLAR CELL CARCINOMA, BRONCHIOLAR-ALVEOLAR TUMOR, TYPE A TUMOR, TYPE B TUMOR, INTERMEDIATE TYPE I TUMOR AND COMMON PULMONARY TUMOR OF THE MOUSE.

MALE 130 (1729/80)

SPLEEN

*** LYMPHOMA LYMPHOCYTIC :

NMIT 6 MALE 130 CONTINUED

SPLEEN CONTINUED

THE NEOPLASM OF THE RETICULAR SYSTEM ORIGINATES FROM LYMPHOCYTES.

MALE 131 (1730/00)

LUNG

*** ALVEOLOGENIC CARCINOMA :
A MALIGNANT TUMOR OF THE LUNG TISSUE WITH SYNONYMS IN MICE FOR ADENOMA, CARCINOMA, ALVEOLOGENIC PAPILLARY CARCINOMA, PAPILLARY CYSTADENOMA, ADENOCARCINOMA, BRONCHIOLAR CELL CARCINOMA, BRONCHIOLAR-ALVEOLAR TUMOR, TYPE A TUMOR, TYPE B TUMOR, INTERMEDIATE TYPE I TUMOR AND COMMON PULMONARY TUMOR OF THE MOUSE.

SPLEEN

*** LYMPHOMA LYMPHOCYTIC :
THE NEOPLASM OF THE RETICULAR SYSTEM ORIGINATES FROM LYMPHOCYTES.

MALE 133 (1679/80)

SPLEEN

*** LYMPHOMA STEM CELLS :
THE NEOPLASM OF THE RETICULAR SYSTEM ORIGINATES FROM STEM CELLS.

ADRENALS

*** ADENOMA :
BILATERAL
THIS IS BENIGN GLANDULAR EPITHELIAL TUMOR.

MALE 136 (1677/80)

BAYER AG BAYER AG BAYER AG

MALE 136 CONTINUED 586

FAT

*** LIPOMA :
THE BENIGN TUMOR IS COMPOSED OF NORMAL FAT CELLS WITH SOME VASCULAR FIBROUS STROMA.

MALE 137 (1678/80)

LUNG

*** ALVEOLOGENIC CARCINOMA :
MULTIFOCAL
A MALIGNANT TUMOR OF THE LUNG TISSUE WITH SYNONYMS IN MICE FOR ADENOMA, CARCINOMA, ALVEOLOGENIC PAPILLARY CARCINOMA, PAPILLARY CYSTADENOMA, ADENOCARCINOMA, BRONCHIOLAR CELL CARCINOMA, BRONCHIOLAR-ALVEOLAR TUMOR, TYPE A TUMOR, TYPE B TUMOR, INTERMEDIATE TYPE I TUMOR AND COMMON PULMONARY TUMOR OF THE MOUSE.

MALE 138 (1724/80)

ADRENALS

*** ADENOMA :
UNILATERAL
THIS IS BENIGN GLANDULAR EPITHELIAL TUMOR.

MALE 139 (1697/80)

THYMUS

*** LYMPHOMA LYMPHOCYTIC :
THE NEOPLASM OF THE RETICULAR SYSTEM ORIGINATES FROM LYMPHOCYTES.

MALE 140 (1739/80)

THYROIDS

*** ADENOMA :
UNILATERAL
THIS IS BENIGN GLANDULAR EPITHELIAL TUMOR.

MALE 147 (1702/80)

LUNG

*** ALVEOLOGENIC CARCINOMA :
MULTIFOCAL
A MALIGNANT TUMOR OF THE LUNG TISSUE WITH SYNONYMS IN MICE FOR ADENOMA, CARCINOMA, ALVEOLOGENIC PAPILLARY CARCINOMA, PAPILLARY CYSTADENOMA, ADENOCARCINOMA, BRONCHIOLAR CELL CARCINOMA, BRONCHIOLAR-ALVEOLAR TUMOR, TYPE A TUMOR, TYPE B TUMOR, INTERMEDIATE TYPE I TUMOR AND COMMON PULMONARY TUMOR OF THE MOUSE.

BAYER AG

SM2T 1 CHRONIC TOXICITY STUDY IN MICE: SYSTEMATIC

HISTOPATHOLOGY: LIST OF TUMOR BEARERS

PRODUCT : KNG 0519 GROUP : 2
ROUTE : DIETARY
TIME : 105 WEEKS DOSE : 500 PPM
THIS GROUP COMPRISED : 13 MALES

MALE 202 (1522/80)

TESTES

*** INTERSTITIAL CELL TUMOR :
BILATERAL
THIS BENIGN TUMOR IS COMPOSED OF LARGE EPITHELIAL CELLS WITH ABUNDANT ACIDOPHILIC CYTOPLASM.

MALE 206 (1524/80)

LYMPH NODE

*** LYMPHOMA LYMPHOCYTIC :
THE NEOPLASM OF THE RETICULAR SYSTEM ORIGINATES FROM LYMPHOCYTES.

MALE 215 (1525/80)

LIVER

*** ADENOMA HEPATIC BENIGN :
DISTINCT NODULES COMPRESS THE ADJACENT LIVER PARENCHYMA, ARE CHARACTERIZED BY WELL DIFFERENTIATED HEPATOCYTES AND DO NOT SHOW PORTAL TRIADS.

MALE 217 (1526/80)

LUNG

*** ALVEOLOGENIC CARCINOMA :
A MALIGNANT TUMOR OF THE LUNG TISSUE WITH SYNONYMS IN MICE FOR ADENOMA, CARCINOMA, ALVEOLOGENIC PAPILLARY CARCINOMA, PAPILLARY CYSTADENOMA, ADENOCARCINOMA, BRONCHIOLAR CELL CARCINOMA, BRONCHIOLAR-ALVEOLAR TUMOR, TYPE A TUMOR, TYPE B TUMOR, INTERMEDIATE TYPE I TUMOR AND COMMON PULMONARY TUMOR OF THE MOUSE.

MALE 218 (1527/80)

LUNG

*** ALVEOLOGENIC CARCINOMA :
A MALIGNANT TUMOR OF THE LUNG TISSUE WITH SYNONYMS IN MICE FOR ADENOMA, CARCINOMA, ALVEOLOGENIC PAPILLARY CARCINOMA, PAPILLARY CYSTADENOMA, ADENOCARCINOMA, BRONCHIOLAR CELL CARCINOMA, BRONCHIOLAR-ALVEOLAR TUMOR, TYPE A TUMOR, TYPE B TUMOR, INTERMEDIATE TYPE I TUMOR AND COMMON PULMONARY TUMOR OF THE MOUSE.

FEMUR

*** OSTEOMA :
THIS BENIGN WELL CIRCUMSCRIBED TUMOR IS COMPOSED OF WELL-DEVELOPED BONE.

MALE 226 (1529/80)

LIVER

*** ADENOMA HEPATIC BENIGN :
DISTINCT NODULES COMPRESS THE ADJACENT LIVER PARENCHYMA, ARE CHARACTERIZED BY WELL DIFFERENTIATED HEPATOCYTES AND DO

BAYER AG

SM2T 3 MALE 226 CONTINUED

LIVER CONTINUED
NOT SHOW PORTAL TRIADS.

MALE 230 (1531/80)

ADRENALS

*** ADENOMA :
UNILATERAL
THIS IS BENIGN GLANDULAR EPITHELIAL TUMOR.

MALE 233 (1532/80)

PANCREAS

*** ISLET CELL ADENOMA :
THIS IS A BENIGN GLANDULAR TUMOR ARISING FROM THE ISLET CELLS.

MALE 239 (1533/80)

ADRENALS

*** ADENOMA :
UNILATERAL
THIS IS BENIGN GLANDULAR EPITHELIAL TUMOR.

MALE 244 (1534/80)

LUNG

*** ALVEOLOGENIC CARCINOMA :
A MALIGNANT TUMOR OF THE LUNG TISSUE WITH
SYNONYMS IN MICE FOR ADENOMA, CARCINOMA,

SM2T 4 MALE 244 CONTINUED

LUNG CONTINUED

ALVEOLOGENIC PAPILLARY CARCINOMA, PAPILLARY CYSTADENOMA, ADENOCARCINOMA, BRONCHIOLAR CELL CARCINOMA, BRONCHIOLAR-ALVEOLAR TUMOR, TYPE A TUMOR, TYPE B TUMOR, INTERMEDIATE TYPE I TUMOR AND COMMON PULMONARY TUMOR OF THE MOUSE.

BAYER AG BAYER AG BAYER AG BAYER AG

NM2T 1 CHRONIC TOXICITY STUDY IN MICE: NONSYSTEMATIC

HISTOPATHOLOGY: LIST OF TUMOR BEARERS

PRODUCT : XWG 0519

GROUP : 2
ROUTE : DIETARY
DOSE : 500 PPM

TIME : 105 WEEKS
THIS GROUP COMPRISED : 36 MALES

MALE 201 (1779/80)

LUNG

*** ALVEOLOGENIC CARCINOMA :
MULTIFOCAL
A MALIGNANT TUMOR OF THE LUNG TISSUE WITH SYNONYMS IN MICE FOR ADENOMA, CARCINOMA, ALVEOLOGENIC PAPILLARY CARCINOMA, PAPILLARY CYSTADENOMA, ADENOCARCINOMA, BRONCHIOLAR CELL CARCINOMA, BRONCHIOLAR-ALVEOLAR TUMOR, TYPE A TUMOR, TYPE B TUMOR, INTERMEDIATE TYPE I TUMOR AND COMMON PULMONARY TUMOR OF THE MOUSE.

LIVER

*** ADENOMA HEPATIC BENIGN :
DISTINCT NODULES COMPRESS THE ADJACENT LIVER PARENCHYMA, ARE CHARACTERIZED BY WELL DIFFERENTIATED HEPATOCYTES AND DO NOT SHOW PORTAL TRIADS.

TESTES

*** INTERSTITIAL CELL TUMOR :
UNILATERAL
THIS BENIGN TUMOR IS COMPOSED OF LARGE EPITHELIAL CELLS WITH ABUNDANT ACIDOPHILIC CYTOPLASM.

MALE 203 (1774/80)

LUNG

*** ALVEOLOGENIC CARCINOMA :
MULTIFOCAL
A MALIGNANT TUMOR OF THE LUNG TISSUE WITH SYNONYMS IN MICE FOR ADENOMA, CARCINOMA, ALVEOLOGENIC PAPILLARY CARCINOMA, PAPILLARY CYSTADENOMA, ADENOCARCINOMA, BRONCHIOLAR

NMRT 2 MALE 203 CONTINUED

LUNG CONTINUED

CELL CARCINOMA, BRONCHIOLAR-ALVEOLAR TUMOR, TYPE A TUMOR, TYPE B TUMOR, INTERMEDIATE TYPE I TUMOR AND COMMON PULMONARY TUMOR OF THE MOUSE.

MALE 204 (1763/80)

SPLEEN

*** LYMPHOMA LYMPHOCYTIC :
THE NEOPLASM OF THE RETICULAR SYSTEM ORIGINATES FROM LYMPHOCYTES.

BONE

*** OSTEOMA :
THIS BENIGN WELL CIRCUMSCRIBED TUMOR IS COMPOSED OF WELL-DEVELOPED BONE.

MALE 208 (1771/80)

LIVER

*** ADENOMA HEPATIC BENIGN :
DISTINCT NODULES COMPRESS THE ADJACENT LIVER PARENCHYMA, ARE CHARACTERIZED BY WELL DIFFERENTIATED HEPATOCYTES AND DO NOT SHOW PORTAL TRIADS.

MALE 210 (1762/80)

LUNG

*** ALVEOLOGENIC CARCINOMA :
A MALIGNANT TUMOR OF THE LUNG TISSUE WITH SYNONYMS IN MICE FOR ADENOMA, CARCINOMA, ALVEOLOGENIC PAPILLARY CARCINOMA, PAPILLARY CYSTADENOMA, ADENOCARCINOMA, BRONCHIOLAR CELL CARCINOMA, BRONCHIOLAR-ALVEOLAR TUMOR, TYPE A TUMOR, TYPE B TUMOR, INTERMEDIATE TYPE I TUMOR AND COMMON PULMONARY TUMOR OF

BAYER AG BAYER AG BAYER AG BAYER AG

LUNG CONTINUED

THE MOUSE.

MALE 211 (1766/80)

SEMINAL VESICLES

*** MESENCHYMAL TUMOR :
MALIGNANT TUMOR DERIVED FROM UNDIFFERENTIATED COMPONENTS OF CONNECTIVE TISSUE.

MALE 212 (1778/80)

LUNG

*** ALVEOLOGENIC CARCINOMA :
A MALIGNANT TUMOR OF THE LUNG TISSUE WITH SYNONYMS IN MICE FOR ADENOMA, CARCINOMA, ALVEOLOGENIC PAPILLARY CARCINOMA, PAPILLARY CYSTADENOMA, ADENOCARCINOMA, BRONCHIOLAR CELL CARCINOMA, BRONCHIOLAR-ALVEOLAR TUMOR, TYPE A TUMOR, TYPE B TUMOR, INTERMEDIATE TYPE I TUMOR AND COMMON PULMONARY TUMOR OF THE MOUSE.

MALE 231 (1750/80)

LUNG

*** ALVEOLOGENIC CARCINOMA :
A MALIGNANT TUMOR OF THE LUNG TISSUE WITH SYNONYMS IN MICE FOR ADENOMA, CARCINOMA, ALVEOLOGENIC PAPILLARY CARCINOMA, PAPILLARY CYSTADENOMA, ADENOCARCINOMA, BRONCHIOLAR CELL CARCINOMA, BRONCHIOLAR-ALVEOLAR TUMOR, TYPE A TUMOR, TYPE B TUMOR, INTERMEDIATE TYPE I TUMOR AND COMMON PULMONARY TUMOR OF THE MOUSE.

NMRI 4 MALE 231 CONTINUED

SPLEEN

*** LYMPHOMA LYMPHOCYTIC :
THE NEOPLASM OF THE RETICULAR SYSTEM ORIGINATES FROM LYMPHOCYTES.

MALE 232 (1783/80)

LIVER

*** ADENOMA HEPATIC BENIGN :
DISTINCT NODULES COMPRESS THE ADJACENT LIVER PARENCHYMA, ARE CHARACTERIZED BY WELL DIFFERENTIATED HEPATOCYTES AND DO NOT SHOW PORTAL TRIADS.

MALE 234 (1764/80)

LUNG

*** ALVEOLOGENIC CARCINOMA :
MULTIFOCAL
A MALIGNANT TUMOR OF THE LUNG TISSUE WITH SYNONYMS IN MICE FOR ADENOMA, CARCINOMA, ALVEOLOGENIC PAPILLARY CARCINOMA, PAPILLARY CYSTADENOMA, ADENOCARCINOMA, BRONCHIOLAR CELL CARCINOMA, BRONCHIOLAR-ALVEOLAR TUMOR, TYPE A TUMOR, TYPE B TUMOR, INTERMEDIATE TYPE I TUMOR AND COMMON PULMONARY TUMOR OF THE MOUSE.

MALE 235 (1780/80)

LUNG

*** ALVEOLOGENIC CARCINOMA :
MULTIFOCAL
A MALIGNANT TUMOR OF THE LUNG TISSUE WITH SYNONYMS IN MICE FOR ADENOMA, CARCINOMA, ALVEOLOGENIC PAPILLARY CARCINOMA, PAPILLARY CYSTADENOMA, ADENOCARCINOMA, BRONCHIOLAR CELL CARCINOMA, BRONCHIOLAR-ALVEOLAR TUMOR,

BAYER AG

NMRT 5 MALE 235 CONTINUED

LUNG CONTINUED

TYPE A TUMOR, TYPE B TUMOR, INTERMEDIATE TYPE I TUMOR AND COMMON PULMONARY TUMOR OF THE MOUSE.

FEMUR

*** OSTEOMA :
THIS BENIGN WELL CIRCUMSCRIBED TUMOR IS COMPOSED OF WELL-DEVELOPED BONE.

MALE 237 (1760/80)

ADRENALS

*** ADENOMA :
UNILATERAL
THIS IS BENIGN GLANDULAR EPITHELIAL TUMOR.

MALE 243 (1772/80)

SPLEEN

*** LYMPHOMA LYMPHOCYTIC :
THE NEOPLASM OF THE RETICULAR SYSTEM ORIGINATES FROM LYMPHOCYTES.

MALE 246 (1768/80)

SPLEEN

*** LYMPHOMA LYMPHOCYTIC :
THE NEOPLASM OF THE RETICULAR SYSTEM ORIGINATES FROM LYMPHOCYTES.

MALE 249 (1754/60)

THYMUS

*** LYMPHOMA LYMPHOCYTIC :
THE NEOPLASM OF THE RETICULAR SYSTEM ORIGINATES FROM LYMPHOCYTES.

BAYER AG BAYER AG BAYER AG BAYER AG

SM3T 1 CHRONIC TOXICITY STUDY IN MICE: SYSTEMATIC

HISTOPATHOLOGY: LIST OF TUMOR BEARERS

PRODUCT : XnG 0519 GROUP : 3
ROUTE : DIETARY
TIME : 105 WEEKS DOSE : 2000 PPM
THIS GROUP COMPRISED : 17 MALES

MALE 306 (1552/80)

LUNG

*** ALVEOLOGENIC CARCINOMA :
A MALIGNANT TUMOR OF THE LUNG TISSUE WITH SYNONYMS IN MICE FOR ADENOMA, CARCINOMA, ALVEOLOGENIC PAPILLARY CARCINOMA, PAPILLARY CYSTADENOMA, ADENOCARCINOMA, BRONCHIOLAR CEL. CARCINOMA, BRONCHIOLAR-ALVEOLAR TUMOR, TYPE A TUMOR, TYPE B TUMOR, INTERMEDIATE TYPE I TUMOR AND COMMON PULMONARY TUMOR OF THE MOUSE.

LIVER

*** ADENOMA HEPATIC BENIGN :
DISTINCT NODULES COMPRESS THE ADJACENT LIVER PARENCHYMA, ARE CHARACTERIZED BY WELL DIFFERENTIATED HEPATOCYTES AND DO NOT SHOW PORTAL TRIADS.

MALE 308 (1553/80)

LUNG

*** ALVEOLOGENIC CARCINOMA :
MULTIFOCAL
A MALIGNANT TUMOR OF THE LUNG TISSUE WITH SYNONYMS IN MICE FOR ADENOMA, CARCINOMA, ALVEOLOGENIC PAPILLARY CARCINOMA, PAPILLARY CYSTADENOMA, ADENOCARCINOMA, BRONCHIOLAR CEL. CARCINOMA, BRONCHIOLAR-ALVEOLAR TUMOR, TYPE A TUMOR, TYPE B TUMOR, INTERMEDIATE TYPE I TUMOR AND COMMON PULMONARY TUMOR OF THE MOUSE.

ADRENALS

*** PHEOCHROMOCYTOMA :
UNILATERAL

SM3T 2 MALE 308 CONTINUED

ADRENALS CONTINUED

THIS TUMOR IS COMPOSED OF POLYHEDRAL CELLS WHICH ARISE FROM THE CHROMAFFIN CELLS OF THE ADRENAL MEDULLA AND FORM LOBULES SEPARATED BY VASCULAR CONNECTIVE TISSUE SEPTA.

MALE 310 (1554/80)

LUNG

*** ALVEOLOGENIC CARCINOMA :
A MALIGNANT TUMOR OF THE LUNG TISSUE WITH SYNONYMS IN MICE FOR ADENOMA, CARCINOMA, ALVEOLOGENIC PAPILLARY CARCINOMA, PAPILLARY CYSTADENOMA, ADENOCARCINOMA, BRONCHIOLAR CELL CARCINOMA, BRONCHIOLAR-ALVEOLAR TUMOR, TYPE A TUMOR, TYPE B TUMOR, INTERMEDIATE TYPE I TUMOR AND COMMON PULMONARY TUMOR OF THE MOUSE.

MALE 315 (1556/80)

LIVER

*** ADENOMA HEPATIC BENIGN :
DISTINCT NODULES COMPRESS THE ADJACENT LIVER PARENCHYMA, ARE CHARACTERIZED BY WELL DIFFERENTIATED HEPATOCYTES AND DO NOT SHOW PORTAL TRIADS.

ADRENALS

*** ADENOMA :
UNILATERAL
THIS IS BENIGN GLANDULAR EPITHELIAL TUMOR.

MALE 322 (1557/80)

BLADDER

*** CARCINOSARCOMA :
IRREGULAR NESTS OF EPITHELIAL CELLS ARE CLOSELY INTERMIXED WITH MALIGNANT SPINDLE CELLS.

BAYER AG BAYER AG BAYER AG

MALE 327 (1556/80)

SPLEEN

*** LYMPHOMA LYMPHOCYTIC :
THE NEOPLASM OF THE RETICULAR SYSTEM ORIGINATES FROM LYMPHOCYTES.

MALE 332 (1560/80)

LUNG

*** ALVEOLOGENIC CARCINOMA :
A MALIGNANT TUMOR OF THE LUNG TISSUE WITH SYNONYMS IN MICE FOR ADENOMA, CARCINOMA, ALVEOLOGENIC PAPILLARY CARCINOMA, PAPILLARY CYSTADENOMA, ADENOCARCINOMA, BRONCHIOLAR CELL CARCINOMA, BRONCHIOLAR-ALVEOLAR TUMOR, TYPE A TUMOR, TYPE B TUMOR, INTERMEDIATE TYPE I TUMOR AND COMMON PULMONARY TUMOR OF THE MOUSE.

MALE 334 (1561/80)

ADRENALS

*** ADENOMA :
UNILATERAL
THIS IS BENIGN GLANDULAR EPITHELIAL TUMOR.

MALE 335 (1562/80)

LUNG

*** ALVEOLOGENIC CARCINOMA :
A MALIGNANT TUMOR OF THE LUNG TISSUE WITH SYNONYMS IN MICE FOR ADENOMA, CARCINOMA, ALVEOLOGENIC PAPILLARY CARCINOMA, PAPILLARY CYSTADENOMA, ADENOCARCINOMA, BRONCHIOLAR CEL. CARCINOMA, BRONCHIOLAR-ALVEOLAR TUMOR, TYPE A TUMOR, TYPE B TUMOR, INTERMEDIATE TYPE I TUMOR AND COMMON PULMONARY TUMOR OF THE MOUSE.

MALE 336 (1563/80)

LUNG

*** ALVEOLOGENIC CARCINOMA :
A MALIGNANT TUMOR OF THE LUNG TISSUE WITH SYNONYMS IN MICE FOR ADENOMA, CARCINOMA, ALVEOLOGENIC PAPILLARY CARCINOMA, PAPILLARY CYSTADENOMA, ADENOCARCINOMA, BRONCHIOLAR CEL. CARCINOMA, BRONCHIOLAR-ALVEOLAR TUMOR, TYPE A TUMOR, TYPE B TUMOR, INTERMEDIATE TYPE I TUMOR AND COMMON PULMONARY TUMOR OF THE MOUSE.

ADRENALS

*** ADENOMA :
UNILATERAL
THIS IS BENIGN GLANDULAR EPITHELIAL TUMOR.

MALE 342 (1565/80)

LIVER

*** ADENOMA HEPATIC BENIGN :
DISTINCT NODULES COMPRESS THE ADJACENT LIVER PARENCHYMA, ARE CHARACTERIZED BY WELL DIFFERENTIATED HEPATOCYTES AND DO NOT SHOW PORTAL TRIADS.

SPLEEN

*** LYMPHOMA LYMPHOCYTIC :
THE NEOPLASM OF THE RETICULAR SYSTEM ORIGINATES FROM LYMPHOCYTES.

BAYER AG

SM3T 5

MALE 343 (1566/80)

LIVER

*** ADENOMA HEPATIC BENIGN :
DISTINCT NODULES COMPRESS THE ADJACENT LIVER PARENCHYMA,
ARE CHARACTERIZED BY WELL DIFFERENTIATED HEPATOCYTES AND DO
NOT SHOW PORTAL TRIADS.

MALE 345 (1567/80)

LIVER

*** ADENOMA HEPATIC BENIGN :
DISTINCT NODULES COMPRESS THE ADJACENT LIVER PARENCHYMA,
ARE CHARACTERIZED BY WELL DIFFERENTIATED HEPATOCYTES AND DO
NOT SHOW PORTAL TRIADS.

NM3T 1 CHRONIC TOXICITY STUDY IN MICE: NONSYSTEMATIC

HISTOPATHOLOGY: LIST OF TUMOR BEARERS

PRODUCT : KMG 0519

GROUP : 3
ROUTE : DIETARY
DOSE : 2000 PPM

TIME : 105 WEEKS
THIS GROUP COMPRISED : 33 MALES

MALE 301 (1849/80)

LUNG

*** ALVEOLOGENIC CARCINOMA :
A MALIGNANT TUMOR OF THE LUNG TISSUE WITH SYNONYMS IN MICE FOR ADENOMA, CARCINOMA, ALVEOLOGENIC PAPILLARY CARCINOMA, PAPILLARY CYSTADENOMA, ADENOCARCINOMA, BRONCHIOLAR CELL CARCINOMA, BRONCHIOLAR-ALVEOLAR TUMOR, TYPE A TUMOR, TYPE B TUMOR, INTERMEDIATE TYPE I TUMOR AND COMMON PULMONARY TUMOR OF THE MOUSE.

SPLEEN

*** LYMPHOMA LYMPHOLYTIC :
THE NEOPLASM OF THE RETICULAR SYSTEM ORIGINATES FROM LYMPHOCYTES.

LYMPH NODE

*** LYMPHOMA LYMPHOLYTIC :
THE NEOPLASM OF THE RETICULAR SYSTEM ORIGINATES FROM LYMPHOCYTES.

MALE 302 (1839/80)

LUNG

*** FIBROMA :
WITHIN THIS ENCAPSULATED SPINDLE CELL TUMOR THERE IS COLLAGEN FORMATION.

LIVER

*** ADENOMA HEPATIC BENIGN :
DISTINCT NODULES COMPRESS THE ADJACENT LIVER PARENCHYMA, ARE CHARACTERIZED BY WELL DIFFERENTIATED HEPATOCYTES AND DO

BAYER AG

LIVER CONTINUED

NOT SHOW PORTAL TRIADS.

MALE 309 (1836/60)

SPLEEN

*** LYMPHOMA GRANULOCYTIC :
THE NEOPLASM OF THE RETICULAR SYSTEM ORIGINATES FROM GRANULOCYTES.

MALE 313 (1848/60)

LUNG

*** ALVEOLOGENIC CARCINOMA :
MULTIFOCAL
A MALIGNANT TUMOR OF THE LUNG TISSUE WITH SYNONYMS IN MICE FOR ADENOMA, CARCINOMA, ALVEOLOGENIC PAPILLARY CARCINOMA, PAPILLARY CYSTADENOMA, ADENOCARCINOMA, BRONCHIOLAR CELL CARCINOMA, BRONCHIOLAR-ALVEOLAR TUMOR, TYPE A TUMOR, TYPE B TUMOR, INTERMEDIATE TYPE I TUMOR AND COMMON PULMONARY TUMOR OF THE MOUSE.

MALE 319 (1843/80)

LIVER

*** ADENOMA HEPATIC BENIGN :
DISTINCT NODULES COMPRESS THE ADJACENT LIVER PARENCHYMA, ARE CHARACTERIZED BY WELL DIFFERENTIATED HEPATOCYTES AND DO NOT SHOW PORTAL TRIADS.

MALE 320 (1833/80)

LUNG

*** ALVEOLOGENIC CARCINOMA :
MULTIFOCAL
A MALIGNANT TUMOR OF THE LUNG TISSUE WITH SYNONYMS IN MICE FOR ADENOMA, CARCINOMA, ALVEOLOGENIC PAPILLARY CARCINOMA, PAPILLARY CYSTADENOMA, ADENOCARCINOMA, BRONCHIOLAR CELL CARCINOMA, BRONCHIOLAR-ALVEOLAR TUMOR, TYPE A TUMOR, TYPE B TUMOR, INTERMEDIATE TYPE I TUMOR AND COMMON PULMONARY TUMOR OF THE MOUSE.

LIVER

*** ADENOMA HEPATIC BENIGN :
DISTINCT NODULES COMPRESS THE ADJACENT LIVER PARENCHYMA, ARE CHARACTERIZED BY WELL DIFFERENTIATED HEPATOCYTES AND DO NOT SHOW PORTAL TRIADS.

BLADDER

*** CARCINOSARCOMA :
IRREGULAR NESTS OF EPITHELIAL CELLS ARE CLOSELY INTERMIXED WITH MALIGNANT SPINDLE CELLS.

MALE 321 (1821/80)

THYMUS

*** LYMPHOMA LYMPHOCYTIC :
THE NEOPLASM OF THE RETICULAR SYSTEM ORIGINATES FROM LYMPHOCYTES.

SPLEEN

*** LYMPHOMA LYMPHOCYTIC :
THE NEOPLASM OF THE RETICULAR SYSTEM ORIGINATES FROM LYMPHOCYTES.

BAYER AG

MALE 323 (1837/80)

LUNG

*** ALVEOLOGENIC CARCINOMA :
MULTIFOCAL
A MALIGNANT TUMOR OF THE LUNG TISSUE WITH SYNONYMS IN MICE FOR ADENOMA, CARCINOMA, ALVEOLOGENIC PAPILLARY CARCINOMA, PAPILLARY CYSTADENOMA, ADENOCARCINOMA, BRONCHIOLAR CELL CARCINOMA, BRONCHIOLAR-ALVEOLAR TUMOR, TYPE A TUMOR, TYPE B TUMOR, INTERMEDIATE TYPE I TUMOR AND COMMON PULMONARY TUMOR OF THE MOUSE.

LIVER

*** ADENOCARCINOMA :
MALIGNANT EPITHELIAL TUMOR SHOWING VARIOUS WELL DIFFERENTIATED MORPHOLOGICAL ASPECTS.

MALE 324 (1831/80)

THYMUS

*** LYMPHOMA LYMPHOCYTIC :
THE NEOPLASM OF THE RETICULAR SYSTEM ORIGINATES FROM LYMPHOCYTES.

MALE 326 (1825/80)

LUNG

*** ALVEOLOGENIC CARCINOMA :
A MALIGNANT TUMOR OF THE LUNG TISSUE WITH SYNONYMS IN MICE FOR ADENOMA, CARCINOMA, ALVEOLOGENIC PAPILLARY CARCINOMA, PAPILLARY CYSTADENOMA, ADENOCARCINOMA, BRONCHIOLAR CELL CARCINOMA, BRONCHIOLAR-ALVEOLAR TUMOR, TYPE A TUMOR, TYPE B TUMOR, INTERMEDIATE TYPE I TUMOR AND COMMON PULMONARY TUMOR OF

NM3T 5 MALE 326 CONTINUED

LUNG CONTINUED

THE MOUSE.

MALE 329 (1829/60)

LUNG

*** ALVEOLOGENIC CARCINOMA :
A MALIGNANT TUMOR OF THE LUNG TISSUE WITH SYNONYMS IN MICE FOR ADENOMA, CARCINOMA, ALVEOLOGENIC PAPILLARY CARCINOMA, PAPILLARY CYSTADENOMA, ADENOCARCINOMA, BRONCHIOLAR CELL CARCINOMA, BRONCHIOLAR-ALVEOLAR TUMOR, TYPE A TUMOR, TYPE B TUMOR, INTERMEDIATE TYPE I TUMOR AND COMMON PULMONARY TUMOR OF THE MOUSE.

UNKNOWN TISSUE OR ANY OT

*** UNCLASSIFIED RCS :
THIS TUMOR ARISES FROM RETICULUM CELLS.

MALE 337 (1840/60)

LUNG

*** ALVEOLOGENIC CARCINOMA :
A MALIGNANT TUMOR OF THE LUNG TISSUE WITH SYNONYMS IN MICE FOR ADENOMA, CARCINOMA, ALVEOLOGENIC PAPILLARY CARCINOMA, PAPILLARY CYSTADENOMA, ADENOCARCINOMA, BRONCHIOLAR CELL CARCINOMA, BRONCHIOLAR-ALVEOLAR TUMOR, TYPE A TUMOR, TYPE B TUMOR, INTERMEDIATE TYPE I TUMOR AND COMMON PULMONARY TUMOR OF THE MOUSE.

MALE 339 (1847/60)

LUNG

*** ALVEOLOGENIC CARCINOMA :

BAYER AG BAYER AG BAYER AG

NM3T 6 MALE 339 CONTINUED

LUNG CONTINUED

A MALIGNANT TUMOR OF THE LUNG TISSUE WITH SYNONYMS IN MICE FOR ADENOMA, CARCINOMA, ALVEOLOGENIC PAPILLARY CARCINOMA, PAPILLARY CYSTADENOMA, ADENOCARCINOMA, BRONCHIOLAR CEL. CARCINOMA, BRONCHIOLAR-ALVEOLAR TUMOR, TYPE A TUMOR, TYPE B TUMOR, INTERMEDIATE TYPE I TUMOR AND COMMON PULMONARY TUMOR OF THE MOUSE.

MALE 340 (1619/80)

SPLEEN

*** LYMPHOMA STEM CELLS :
THE NEOPLASM OF THE RETICULAR SYSTEM ORIGINATES FROM STEM CELLS.

MALE 341 (1827/80)

SKIN

*** SQUAMOUS CELL CARCINOMA KERATINIZING :
IT IS A MALIGNANT EPITHELIAL TUMOR DEMONSTRATING KERATIN PRODUCTION.

MALE 344 (1824/80)

SPLEEN

*** LYMPHOMA STEM CELLS :
THE NEOPLASM OF THE RETICULAR SYSTEM ORIGINATES FROM STEM CELLS.

LYMPH NODE

*** LYMPHOMA STEM CELLS :
THE NEOPLASM OF THE RETICULAR SYSTEM ORIGINATES FROM STEM CELLS.

MALE 346 (1830/80)

SPLEEN

*** LYMPHOMA LYMPHOCYTIC :
THE NEOPLASM OF THE RETICULAR SYSTEM ORIGINATES FROM LYMPHOCYTES.

MALE 349 (1826/80)

BONE

*** OSTEOMA :
THIS BENIGN WELL CIRCUMSCRIBED TUMOR IS COMPOSED OF WELL-DEVELOPED BONE.

MALE 350 (1832/80)

SPLEEN

*** LYMPHOMA LYMPHOCYTIC :
THE NEOPLASM OF THE RETICULAR SYSTEM ORIGINATES FROM LYMPHOCYTES.

BAYER AG

SECT 1 CHRONIC TOXICITY STUDY IN MICE: SYSTEMATIC HISTOPATHOLOGY: LIST OF TUMOR BEARERS

PRODUCT : XWG 0519
TIME : 105 WEEKS
THIS GROUP COMPRISED : 16 FEMALES

GROUP : CONTROL
ROUTE : DIETARY
DOSE : 0 PPM

FEMALE 55 (1481/80)

LUNG

*** ALVEOLOGENIC CARCINOMA :
A MALIGNANT TUMOR OF THE LUNG TISSUE WITH SYNONYMS IN MICE FOR ADENOMA, CARCINOMA, ALVEOLOGENIC PAPILLARY CARCINOMA, PAPILLARY CYSTADENOMA, ADENOCARCINOMA, BRONCHIOLAR CELL CARCINOMA, BRONCHIOLAR-ALVEOLAR TUMOR, TYPE A TUMOR, TYPE B TUMOR, INTERMEDIATE TYPE I TUMOR AND COMMON PULMONARY TUMOR OF THE MOUSE.

OVARIES

*** LUTEOMA :
UNILATERAL
IT IS A BENIGN TUMOR COMPOSED OF CELLS RESEMBLING THOSE OF THE CORPUS LUTEUM.

FEMALE 57 (1482/80)

LUNG

*** ALVEOLOGENIC CARCINOMA :
A MALIGNANT TUMOR OF THE LUNG TISSUE WITH SYNONYMS IN MICE FOR ADENOMA, CARCINOMA, ALVEOLOGENIC PAPILLARY CARCINOMA, PAPILLARY CYSTADENOMA, ADENOCARCINOMA, BRONCHIOLAR CELL CARCINOMA, BRONCHIOLAR-ALVEOLAR TUMOR, TYPE A TUMOR, TYPE B TUMOR, INTERMEDIATE TYPE I TUMOR AND COMMON PULMONARY TUMOR OF THE MOUSE.

MAMMARY GLAND

*** ADENOCARCINOMA :
THE MAMMARY TUMOR IS COMPOSED OF SMALL ACINI OR TUBULES

SECT 2 FEMALE 57 CONTINUED

MAMMARY GLAND CONTINUED
LINED BY SINGLE LAYER OF CUBOIDAL CELLS WHICH MAY BE INFILTRATING/METASTASING.

FEMALE 66 (1483/80)

LUNG

*** ALVEOLOGENIC CARCINOMA :
A MALIGNANT TUMOR OF THE LUNG TISSUE WITH SYNONYMS IN MICE FOR ADENOMA, CARCINOMA, ALVEOLOGENIC PAPILLARY CARCINOMA, PAPILLARY CYSTADENOMA, ADENOCARCINOMA, BRONCHIOLAR CELL CARCINOMA, BRONCHIOLAR-ALVEOLAR TUMOR, TYPE A TUMOR, TYPE B TUMOR, INTERMEDIATE TYPE I TUMOR AND COMMON PULMONARY TUMOR OF THE MOUSE.

FEMALE 78 (1486/80)

BLADDER

*** PAPILLOMA :
A BENIGN GROWTH INTO THE LUMEN IS COMPOSED OF A VASCULAR FIBROUS CORE COVERED BY TRANSITIONAL EPITHELIUM.

MAMMARY GLAND

*** ADENOCARCINOMA :
THE MAMMARY TUMOR IS COMPOSED OF SMALL ACINI OR TUBULES LINED BY SINGLE LAYER OF CUBOIDAL CELLS WHICH MAY BE INFILTRATING/METASTASING.

FEMALE 81 (1487/80)

LUNG

*** ALVEOLOGENIC CARCINOMA :
MULTIFOCAL
A MALIGNANT TUMOR OF THE LUNG TISSUE WITH SYNONYMS IN MICE FOR ADENOMA, CARCINOMA,

BAYER AG

SECT 3 FEMALE 81 CONTINUED

LUNG CONTINUED

ALVEOLOGENIC PAPILLARY CARCINOMA, PAPILLARY CYSTADENOMA, ADENOCARCINOMA, BRONCHIOLAR CELL CARCINOMA, BRONCHIOLAR-ALVEOLAR TUMOR, TYPE A TUMOR, TYPE B TUMOR, INTERMEDIATE TYPE I TUMOR AND COMMON PULMONARY TUMOR OF THE MOUSE.

FEMALE 89 (1491/80)

LUNG

*** ALVEOLOGENIC CARCINOMA :
MULTIFOCAL
A MALIGNANT TUMOR OF THE LUNG TISSUE WITH SYNONYMS IN MICE FOR ADENOMA, CARCINOMA, ALVEOLOGENIC PAPILLARY CARCINOMA, PAPILLARY CYSTADENOMA, ADENOCARCINOMA, BRONCHIOLAR CELL CARCINOMA, BRONCHIOLAR-ALVEOLAR TUMOR, TYPE A TUMOR, TYPE B TUMOR, INTERMEDIATE TYPE I TUMOR AND COMMON PULMONARY TUMOR OF THE MOUSE.

THYMUS

*** LYMPHOMA LYMPHOCYTIC :
THE NEOPLASM OF THE RETICULAR SYSTEM ORIGINATES FROM LYMPHOCYTES.

FEMALE 92 (1492/80)

LUNG

*** ALVEOLOGENIC CARCINOMA :
MULTIFOCAL
A MALIGNANT TUMOR OF THE LUNG TISSUE WITH SYNONYMS IN MICE FOR ADENOMA, CARCINOMA, ALVEOLOGENIC PAPILLARY CARCINOMA, PAPILLARY CYSTADENOMA, ADENOCARCINOMA, BRONCHIOLAR CELL CARCINOMA, BRONCHIOLAR-ALVEOLAR TUMOR, TYPE A TUMOR, TYPE B TUMOR, INTERMEDIATE TYPE I TUMOR AND COMMON PULMONARY TUMOR OF THE MOUSE.

OVARIES

*** CYSTADENOMA :
UNILATERAL

CYSTIC AND ADENOMATOUS CHANGE WITH CYSTIC HYPERPLASIA.

NFCT 1 CHRONIC TOXICITY STUDY IN MICE: NONSYSTEMATIC

HISTOPATHOLOGY: LIST OF TUMOR BEARERS

PRODUCT : KWG 0519

GROUP : CONTROL
ROUTE : DIETARY
DOSE : 0 PPM

TIME : 105 WEEKS
THIS GROUP COMPRISED : 33 FEMALES

FEMALE 53 (1648/80)

SPLEEN

*** LYMPHOMA LYMPHOCYTIC :
THE NEOPLASM OF THE RETICULAR SYSTEM ORIGINATES FROM LYMPHOCYTES.

LYMPH NODE

*** LYMPHOMA LYMPHOCYTIC :
THE NEOPLASM OF THE RETICULAR SYSTEM ORIGINATES FROM LYMPHOCYTES.

FEMALE 56 (1654/80)

SPLEEN

*** LYMPHOMA LYMPHOCYTIC :
THE NEOPLASM OF THE RETICULAR SYSTEM ORIGINATES FROM LYMPHOCYTES.

LYMPH NODE

*** LYMPHOMA LYMPHOCYTIC :
THE NEOPLASM OF THE RETICULAR SYSTEM ORIGINATES FROM LYMPHOCYTES.

FEMALE 56 (1658/80)

BAYER AG

NECT 2 FEMALE 58 CONTINUED

THYMUS

*** LYMPHOMA LYMPHOCYTIC :
THE NEOPLASM OF THE RETICULAR SYSTEM ORIGINATES FROM LYMPHOCYTES.

FEMALE 59 (1657/80)

OVARIES

*** METASTASIS : (leiomyosacrcoma)
UNILATERAL
A SECONDARY MALIGNANT TUMOR DEVELOPED AWAY FROM THE INITIAL GROWTH.

CERVIX

*** LEIOMYOSARCOMA :
MALIGNANT TUMOR DERIVED FROM SMOOTH MUSCLE FIBERS.

FEMALE 60 (1670/80)

LIVER

*** ADENOCARCINOMA :
MALIGNANT EPITHELIAL TUMOR SHOWING VARIOUS WELL DIFFERENTIATED MORPHOLOGICAL ASPECTS.

FEMALE 62 (1655/80)

LYMPH NODE

*** LYMPHOMA LYMPHOCYTIC :
THE NEOPLASM OF THE RETICULAR SYSTEM ORIGINATES FROM LYMPHOCYTES.

NFCT 3

FEMALE 63 (1674/80)

UTERUS

*** ADENOCARCINOMA :
UNILATERAL
THE MALIGNANT TUMOR IS COMPOSED OF A DIVERSIFIED GROUP OF EPITHELIAL CELLS WITH GLANDULAR PATTERNS WICH MAY BE SOMETIMES CYSTIC.

FEMALE 64 (1669/80)

LUNG

*** ALVEOLOGENIC CARCINOMA :
A MALIGNANT TUMOR OF THE LUNG TISSUE WITH SYNONYMS IN MICE FOR ADENOMA, CARCINOMA, ALVEOLOGENIC PAPILLARY CARCINOMA, PAPILLARY CYSTADENOMA, ADENOCARCINOMA, BRONCHIOLAR CELL CARCINOMA, BRONCHIOLAR-ALVEOLAR TUMOR, TYPE A TUMOR, TYPE B TUMOR, INTERMEDIATE TYPE I TUMOR AND COMMON PULMONARY TUMOR OF THE MOUSE.

SPLEEN

*** LYMPHOMA LYMPHOCYTIC :
THE NEOPLASM OF THE RETICULAR SYSTEM ORIGINATES FROM LYMPHOCYTES.

LYMPH NODE

*** LYMPHOMA LYMPHOCYTIC :
THE NEOPLASM OF THE RETICULAR SYSTEM ORIGINATES FROM LYMPHOCYTES.

FEMALE 67 (1645/80)

SPLEEN

*** LYMPHOMA LYMPHOCYTIC :

BAYER AG

NFCT 4 FEMALE 67 CONTINUED

SPLEEN CONTINUED

THE NEOPLASM OF THE RETICULAR SYSTEM ORIGINATES FROM LYMPHOCYTES.

FEMALE 68 (1652/80)

THYMUS

*** LYMPHOMA LYMPHOCYTIC :
THE NEOPLASM OF THE RETICULAR SYSTEM ORIGINATES FROM LYMPHOCYTES.

FEMALE 69 (1659/80)

MESENTERY

*** METASTASIS : (**mesenchymal tumour**)
A SECONDARY MALIGNANT TUMOR DEVELOPED AWAY FROM THE INITIAL GROWTH.

BODY WALL

*** MESENCHYMAL TUMOR :
MALIGNANT TUMOR DERIVED FROM UNDIFFERENTIATED COMPONENTS OF CONNECTIVE TISSUE.

FEMALE 71 (1664/80)

SPLEEN

*** LYMPHOMA LYMPHOCYTIC :
THE NEOPLASM OF THE RETICULAR SYSTEM ORIGINATES FROM LYMPHOCYTES.

FEMALE 72 (1671/80)

NFCT 5 FEMALE 72 CONTINUED

SPLEEN

*** LYMPHOMA GRANULOCYTIC :
THE NEOPLASM OF THE RETICULAR SYSTEM ORIGINATES FROM GRANULOCYTES.

FEMALE 73 (1668/80)

UTERUS

*** MESENCHYMAL TUMOR :
MALIGNANT TUMOR DERIVED FROM UNDIFFERENTIATED COMPONENTS OF CONNECTIVE TISSUE.

FEMALE 77 (1644/80)

THYMUS

*** LYMPHOMA LYMPHOCYTIC :
THE NEOPLASM OF THE RETICULAR SYSTEM ORIGINATES FROM LYMPHOCYTES.

SPLEEN

*** LYMPHOMA LYMPHOCYTIC :
THE NEOPLASM OF THE RETICULAR SYSTEM ORIGINATES FROM LYMPHOCYTES.

FEMALE 79 (1667/80)

SPLEEN

*** LYMPHOMA GRANULOCYTIC :
THE NEOPLASM OF THE RETICULAR SYSTEM ORIGINATES FROM GRANULOCYTES.

MESENTERY

*** METASTASIS : **(histiocytic sarcoma)**
A SECONDARY MALIGNANT TUMOR DEVELOPED AWAY FROM THE INITIAL GROWTH.

BAYER AG

UTERUS

*** HISTIOCYTIC SARCOMA :
THIS TUMOR IS PRINCIPALLY COMPOSED OF HISTIOCYTE-LIKE CELLS. MULTINUCLEATED OR FIBROBLAST-LIKE CELLS CAN BE OBSERVED. MITOSES ARE FAIRLY FREQUENT.

FEMALE 80 (1679/80)

SPLEEN

*** LYMPHOMA LYMPHOCYTIC :
THE NEOPLASM OF THE RETICULAR SYSTEM ORIGINATES FROM LYMPHOCYTES.

LYMPH NODE

*** LYMPHOMA LYMPHOCYTIC :
THE NEOPLASM OF THE RETICULAR SYSTEM ORIGINATES FROM LYMPHOCYTES.

FEMALE 87 (1656/80)

SPLEEN

*** LYMPHOMA STEM CELLS :
THE NEOPLASM OF THE RETICULAR SYSTEM ORIGINATES FROM STEM CELLS.

FEMALE 88 (1647/80)

UTERUS

*** LEIOMYOSARCOMA :
MALIGNANT TUMOR DERIVED FROM SMOOTH MUSCLE FIBERS.

FEMALE 91 (1660/80)

LUNG

*** ALVEOLOGENIC CARCINOMA :
A MALIGNANT TUMOR OF THE LUNG TISSUE WITH SYNONYMS IN MICE FOR ADENOMA, CARCINOMA, ALVEOLOGENIC PAPILLARY CARCINOMA, PAPILLARY CYSTADENOMA, ADENOCARCINOMA, BRONCHIOLAR CELL CARCINOMA, BRONCHIOLAR-ALVEOLAR TUMOR, TYPE A TUMOR, TYPE B TUMOR, INTERMEDIATE TYPE I TUMOR AND COMMON PULMONARY TUMOR OF THE MOUSE.

LYMPH NODE

*** LYMPHOMA LYMPHOCYTIC :
THE NEOPLASM OF THE RETICULAR SYSTEM ORIGINATES FROM LYMPHOCYTES.

FEMALE 93 (1673/80)

LUNG

*** ALVEOLOGENIC CARCINOMA :
MULTIFOCAL
A MALIGNANT TUMOR OF THE LUNG TISSUE WITH SYNONYMS IN MICE FOR ADENOMA, CARCINOMA, ALVEOLOGENIC PAPILLARY CARCINOMA, PAPILLARY CYSTADENOMA, ADENOCARCINOMA, BRONCHIOLAR CELL CARCINOMA, BRONCHIOLAR-ALVEOLAR TUMOR, TYPE A TUMOR, TYPE B TUMOR, INTERMEDIATE TYPE I TUMOR AND COMMON PULMONARY TUMOR OF THE MOUSE.

FEMALE 94 (1061/80)

LUNG

*** ALVEOLOGENIC CARCINOMA :
A MALIGNANT TUMOR OF THE LUNG TISSUE WITH

BAYER AG

Vertraulich
Eigentum der Firma Bayer AG
Benutzung, Verwertung oder Weitergabe nur mit Einwilligung der Bayer AG gestattet

LUNG CONTINUED

SYNONYMS IN MICE FOR ADENOMA, CARCINOMA, ALVEOLOGENIC PAPILLARY CARCINOMA, PAPILLARY CYSTADENOMA, ADENOCARCINOMA, BRONCHIOLAR CELL CARCINOMA, BRONCHIOLAR-ALVEOLAR TUMOR, TYPE A TUMOR, TYPE B TUMOR, INTERMEDIATE TYPE I TUMOR AND COMMON PULMONARY TUMOR OF THE MOUSE.

SPLEEN

*** LYMPHOMA GRANULOCYTIC :
THE NEOPLASM OF THE RETICULAR SYSTEM ORIGINATES FROM GRANULOCYTES.

UTERUS

*** LEIOMYOSARCOMA :
MALIGNANT TUMOR DERIVED FROM SMOOTH MUSCLE FIBERS.

FEMALE 95 (1663/80)

SPLEEN

*** LYMPHOMA STEM CELLS :
THE NEOPLASM OF THE RETICULAR SYSTEM ORIGINATES FROM STEM CELLS.

UTERUS

*** LEIOMYOSARCOMA :
MALIGNANT TUMOR DERIVED FROM SMOOTH MUSCLE FIBERS.

FEMALE 97 (1662/80)

SPLEEN

*** LYMPHOMA STEM CELLS :
THE NEOPLASM OF THE RETICULAR SYSTEM ORIGINATES FROM STEM CELLS.

LYMPH NODE

*** LYMPHOMA STEM CELLS :
THE NEOPLASM OF THE RETICULAR SYSTEM ORIGINATES FROM STEM CELLS.

FEMALE 99 (1650/60)

FEMUR

*** OSTEOGENIC SARCOMA :
A MALIGNANT MESENCHYMAL TUMOR WITH ISLANDS OF OSTEOID AND BONE FORMATION IS FOUND.

SKULL

*** METASTASIS : (osteogenic sarcoma)
A SECONDARY MALIGNANT TUMOR DEVELOPED AWAY FROM THE INITIAL GROWTH.

BAYER AG BAYER AG BAYER AG BAYER AG

SF1T 1 CHRONIC TOXICITY STUDY IN MICE: SYSTEMATIC HISTOPATHOLOGY: LIST OF TUMOR BEARERS

PRODUCT : XMG 0519
TIME : 105 WEEKS
THIS GROUP COMPRISED : 16 FEMALES

GROUP : 1
ROUTE : DIETARY
DOSE : 125 PPM

FEMALE 158 (1506/80)

LUNG

*** ALVEOLOGENIC CARCINOMA :
A MALIGNANT TUMOR OF THE LUNG TISSUE WITH SYNONYMS IN MICE FOR ADENOMA, CARCINOMA, ALVEOLOGENIC PAPILLARY CARCINOMA, PAPILLARY CYSTADENOMA, ADENOCARCINOMA, BRONCHIOLAR CELL CARCINOMA, BRONCHIOLAR-ALVEOLAR TUMOR, TYPE A TUMOR, TYPE B TUMOR, INTERMEDIATE TYPE I TUMOR AND COMMON PULMONARY TUMOR OF THE MOUSE.

FEMALE 163 (1508/80)

LUNG

*** ALVEOLOGENIC CARCINOMA :
MULTIFOCAL
A MALIGNANT TUMOR OF THE LUNG TISSUE WITH SYNONYMS IN MICE FOR ADENOMA, CARCINOMA, ALVEOLOGENIC PAPILLARY CARCINOMA, PAPILLARY CYSTADENOMA, ADENOCARCINOMA, BRONCHIOLAR CELL CARCINOMA, BRONCHIOLAR-ALVEOLAR TUMOR, TYPE A TUMOR, TYPE B TUMOR, INTERMEDIATE TYPE I TUMOR AND COMMON PULMONARY TUMOR OF THE MOUSE.

FEMALE 171 (1512/80)

LUNG

*** ALVEOLOGENIC CARCINOMA :
MULTIFOCAL
A MALIGNANT TUMOR OF THE LUNG TISSUE WITH SYNONYMS IN MICE FOR ADENOMA, CARCINOMA, ALVEOLOGENIC PAPILLARY CARCINOMA, PAPILLARY CYSTADENOMA, ADENOCARCINOMA, BRONCHIOLAR CELL CARCINOMA, BRONCHIOLAR-ALVEOLAR TUMOR, TYPE A TUMOR, TYPE B TUMOR, INTERMEDIATE TYPE I TUMOR AND COMMON PULMONARY TUMOR OF THE MOUSE.

SPLEEN

*** LYMPHOMA LYMPHOLYTIC :
THE NEOPLASM OF THE RETICULAR SYSTEM ORIGINATES FROM LYMPHOCYTES.

BONE

*** OSTEOMA :
THIS BENIGN WELL CIRCUMSCRIBED TUMOR IS COMPOSED OF WELL-DEVELOPED BONE.

FEMALE 177 (1513/80)

LUNG

*** ALVEOLOGENIC CARCINOMA :
MULTIFOCAL
A MALIGNANT TUMOR OF THE LUNG TISSUE WITH SYNONYMS IN MICE FOR ADENOMA, CARCINOMA, ALVEOLOGENIC PAPILLARY CARCINOMA, PAPILLARY CYSTADENOMA, ADENOCARCINOMA, BRONCHIOLAR CELL CARCINOMA, BRONCHIOLAR-ALVEOLAR TUMOR, TYPE A TUMOR, TYPE B TUMOR, INTERMEDIATE TYPE I TUMOR AND COMMON PULMONARY TUMOR OF THE MOUSE.

FEMALE 179 (1515/80)

ADRENALS

*** ADENOMA :
UNILATERAL
THIS IS BENIGN GLANDULAR EPITHELIAL TUMOR.

BAYER AG BAYER AG BAYER AG BAYER AG

OVARIES

*** LUTEOMA :
UNILATERAL
IT IS A BENIGN TUMOR COMPOSED OF CELLS RESEMBLING THOSE OF THE CORPUS LUTEUM.

FEMALE 186 (1516/80)

LYMPH NODE

*** LYMPHOMA LYMPHOCYTIC :
THE NEOPLASM OF THE RETICULAR SYSTEM ORIGINATES FROM LYMPHOCYTES.

FEMALE 196 (1519/80)

LUNG

*** ALVEOLOGENIC CARCINOMA :
A MALIGNANT TUMOR OF THE LUNG TISSUE WITH SYNONYMS IN MICE FOR ADENOMA, CARCINOMA, ALVEOLOGENIC PAPILLARY CARCINOMA, PAPILLARY CYSTADENOMA, ADENOCARCINOMA, BRONCHIOLAR CELL CARCINOMA, BRONCHIOLAR-ALVEOLAR TUMOR, TYPE A TUMOR, TYPE B TUMOR, INTERMEDIATE TYPE I TUMOR AND COMMON PULMONARY TUMOR OF THE MOUSE.

SKELETAL MUSCLE

*** METASTASIS : (fibrosarcoma)
A SECONDARY MALIGNANT TUMOR DEVELOPED AWAY FROM THE INITIAL GROWTH.

SUBCUTANEOUS TISSUE

*** FIBROSARCOMA :
IN THIS MALIGNANT MESENCHIMAL TUMOR THE NEOPLASTIC CELLS SHOW MITOSES AND SLIGHT PLEOMORPHISM. FORMATION OF COLLAGEN IS NOTED.

SF1T 4

FEMALE 197 (1520/80)

OVARIES

*** LUTEOMA :
UNILATERAL MULTIFOCAL
IT IS A BENIGN TUMOR COMPOSED OF CELLS RESEMBLING THOSE OF THE CORPUS LUTEUM.

FEMALE 198 (1521/80)

LUNG

*** ALVEOLOGENIC CARCINOMA :
A MALIGNANT TUMOR OF THE LUNG TISSUE WITH SYNONYMS IN MICE FOR ADENOMA, CARCINOMA, ALVEOLOGENIC PAPILLARY CARCINOMA, PAPILLARY CYSTADENOMA, ADENOCARCINOMA, BRONCHIOLAR CELL CARCINOMA, BRONCHIOLAR-ALVEOLAR TUMOR, TYPE A TUMOR, TYPE B TUMOR, INTERMEDIATE TYPE I TUMOR AND COMMON PULMONARY TUMOR OF THE MOUSE.

SPLEEN

*** LYMPHOMA LYMPHOCYTIC :
THE NEOPLASM OF THE RETICULAR SYSTEM ORIGINATES FROM LYMPHOCYTES.

BAYER AG

NFIT 1 CHRONIC TOXICITY STUDY IN MICE: NONSYSTEMATIC

HISTOPATHOLOGY: LIST OF TUMOR BEARERS

PRODUCT : CHG 0519

GROUP : 1
ROUTE : DIETARY
DOSE : 125 PPM

TIME : 105 WEEKS
THIS GROUP COMPRISED : 33 FEMALES

FEMALE 151 (1721/80)

LUNG

*** ALVEOLOGENIC CARCINOMA :
A MALIGNANT TUMOR OF THE LUNG TISSUE WITH SYNONYMS IN MICE FOR ADENOMA, CARCINOMA, ALVEOLOGENIC PAPILLARY CARCINOMA, PAPILLARY CYSTADENOMA, ADENOCARCINOMA, BRONCHIOLAR CELL CARCINOMA, BRONCHIOLAR-ALVEOLAR TUMOR, TYPE A TUMOR, TYPE B TUMOR, INTERMEDIATE TYPE I TUMOR AND COMMON PULMONARY TUMOR OF THE MOUSE.

FEMALE 152 (1708/80)

LYMPH NODE

*** LYMPHOMA LYMPHOCYTIC :
THE NEOPLASM OF THE RETICULAR SYSTEM ORIGINATES FROM LYMPHOCYTES.

FEMALE 155 (1683/80)

ADRENALS

*** ADENOMA :
UNILATERAL
THIS IS BENIGN GLANDULAR EPITHELIAL TUMOR.

FEMALE 157 (1746/80)

LUNG

*** ALVEOLOGENIC CARCINOMA :
A MALIGNANT TUMOR OF THE LUNG TISSUE WITH SYNONYMS IN MICE FOR ADENOMA, CARCINOMA, ALVEOLOGENIC PAPILLARY CARCINOMA, PAPILLARY CYSTADENOMA, ADENOCARCINOMA, BRONCHIOLAR CELL CARCINOMA, BRONCHIOLAR-ALVEOLAR TUMOR, TYPE A TUMOR, TYPE B TUMOR, INTERMEDIATE TYPE I TUMOR AND COMMON PULMONARY TUMOR OF THE MOUSE.

FEMALE 159 (1690/80)

THYMUS

*** LYMPHOMA LYMPHOCYTIC :
THE NEOPLASM OF THE RETICULAR SYSTEM ORIGINATES FROM LYMPHOCYTES.

FEMALE 160 (1710/80)

THYMUS

*** LYMPHOMA LYMPHOCYTIC :
THE NEOPLASM OF THE RETICULAR SYSTEM ORIGINATES FROM LYMPHOCYTES.

FEMALE 162 (1720/80)

BAYER AG

SPLEEN

*** LYMPHOMA LYMPHOCYTIC :
THE NEOPLASM OF THE RETICULAR SYSTEM ORIGINATES FROM LYMPHOCYTES.

FEMALE 165 (1688/80)

SPLEEN

*** LYMPHOMA LYMPHOCYTIC :
THE NEOPLASM OF THE RETICULAR SYSTEM ORIGINATES FROM LYMPHOCYTES.

FEMALE 166 (1715/80)

SPLEEN

*** LYMPHOMA LYMPHOCYTIC :
THE NEOPLASM OF THE RETICULAR SYSTEM ORIGINATES FROM LYMPHOCYTES.

LYMPH NODE

*** LYMPHOMA LYMPHOCYTIC :
THE NEOPLASM OF THE RETICULAR SYSTEM ORIGINATES FROM LYMPHOCYTES.

FEMALE 167 (1742/80)

LUNG

*** ALVEOLOGENIC CARCINOMA :
MULTIFOCAL
A MALIGNANT TUMOR OF THE LUNG TISSUE WITH SYNONYMS IN MICE FOR ADENOMA, CARCINOMA, ALVEOLOGENIC PAPILLARY CARCINOMA, PAPILLARY CYSTADENOMA, ADENOCARCINOMA, BRONCHIOLAR CELL CARCINOMA, BRONCHIOLAR-ALVEOLAR TUMOR, TYPE A TUMOR, TYPE B TUMOR, INTERMEDIATE TYPE I TUMOR AND COMMON PULMONARY TUMOR OF

LUNG CONTINUED

THE MOUSE.

FEMALE 172 (1718/80)

UTERUS

*** LEIOMYOSARCOMA :
UNILATERAL
MALIGNANT TUMOR DERIVED FROM SMOOTH MUSCLE FIBERS.

FEMALE 173 (1712/80)

LUNG

*** ALVEOLOGENIC CARCINOMA :
A MALIGNANT TUMOR OF THE LUNG TISSUE WITH SYNONYMS IN MICE FOR ADENOMA, CARCINOMA, ALVEOLOGENIC PAPILLARY CARCINOMA, PAPILLARY CYSTADENOMA, ADENOCARCINOMA, BRONCHIOLAR CELL CARCINOMA, BRONCHIOLAR-ALVEOLAR TUMOR, TYPE A TUMOR, TYPE B TUMOR, INTERMEDIATE TYPE I TUMOR AND COMMON PULMONARY TUMOR OF THE MOUSE.

SPLEEN

*** LYMPHOMA LYMPHOCYTIC :
THE NEOPLASM OF THE RETICULAR SYSTEM ORIGINATES FROM LYMPHOCYTES.

FEMALE 175 (1713/80)

LUNG

*** ALVEOLOGENIC CARCINOMA :
A MALIGNANT TUMOR OF THE LUNG TISSUE WITH SYNONYMS IN MICE FOR ADENOMA, CARCINOMA, ALVEOLOGENIC PAPILLARY CARCINOMA, PAPILLARY CYSTADENOMA, ADENOCARCINOMA, BRONCHIOLAR CELL CARCINOMA, BRONCHIOLAR-ALVEOLAR TUMOR,

BAYER AG BAYER AG BAYER AG

LUNG CONTINUED

TYPE A TUMOR, TYPE B TUMOR, INTERMEDIATE TYPE I TUMOR AND COMMON PULMONARY TUMOR OF THE MOUSE.

SPLEEN

*** LYMPHOMA LYMPHOCYTIC :
THE NEOPLASM OF THE RETICULAR SYSTEM ORIGINATES FROM LYMPHOCYTES.

FEMALE 180 (1719/80)

LUNG

*** ALVEOLOGENIC CARCINOMA :
A MALIGNANT TUMOR OF THE LUNG TISSUE WITH SYNONYMS IN MICE FOR ADENOMA, CARCINOMA, ALVEOLOGENIC PAPILLARY CARCINOMA, PAPILLARY CYSTADENOMA, ADENOCARCINOMA, BRONCHIOLAR CELL CARCINOMA, BRONCHIOLAR-ALVEOLAR TUMOR, TYPE A TUMOR, TYPE B TUMOR, INTERMEDIATE TYPE I TUMOR AND COMMON PULMONARY TUMOR OF THE MOUSE.

FEMALE 182 (1685/80)

SPLEEN

*** LYMPHOMA LYMPHOCYTIC :
THE NEOPLASM OF THE RETICULAR SYSTEM ORIGINATES FROM LYMPHOCYTES.

FEMALE 183 (1709/80)

LYMPH NODE

*** LYMPHOMA LYMPHOCYTIC :
THE NEOPLASM OF THE RETICULAR SYSTEM ORIGINATES FROM LYMPHOCYTES.

FEMALE 185 (1722/80)

LUNG

*** ALVEOLOGENIC CARCINOMA :
MULTIFOCAL
A MALIGNANT TUMOR OF THE LUNG TISSUE WITH SYNONYMS IN MICE FOR ADENOMA, CARCINOMA, ALVEOLOGENIC PAPILLARY CARCINOMA, PAPILLARY CYSTADENOMA, ADENOCARCINOMA, BRONCHIOLAR CELL CARCINOMA, BRONCHIOLAR-ALVEOLAR TUMOR, TYPE A TUMOR, TYPE B TUMOR, INTERMEDIATE TYPE I TUMOR AND COMMON PULMONARY TUMOR OF THE MOUSE.

FEMALE 189 (1714/80)

LYMPH NODE

*** LYMPHOMA LYMPHOLYTIC :
THE NEOPLASM OF THE RETICULAR SYSTEM ORIGINATES FROM LYMPHOCYTES.

FEMALE 190 (1723/80)

LUNG

*** ALVEOLOGENIC CARCINOMA :
A MALIGNANT TUMOR OF THE LUNG TISSUE WITH SYNONYMS IN MICE FOR ADENOMA, CARCINOMA, ALVEOLOGENIC PAPILLARY CARCINOMA, PAPILLARY CYSTADENOMA, ADENOCARCINOMA, BRONCHIOLAR CELL CARCINOMA, BRONCHIOLAR-ALVEOLAR TUMOR, TYPE A TUMOR, TYPE B TUMOR, INTERMEDIATE TYPE I TUMOR AND COMMON PULMONARY TUMOR OF THE MOUSE.

BAYER AG

FEMALE 191 (1716/80)

SPLEEN

*** LYMPHOMA LYMPHOCYTIC :
THE NEOPLASM OF THE RETICULAR SYSTEM ORIGINATES FROM LYMPHOCYTES.

FEMALE 192 (1744/80)

CERVIX

*** KERATOACANTHOMA :
THERE IS A BENIGN TUMOR OF THE SQUAMOUS EPITHELIUM. CONSIDERABLE PRODUCTION OF KERATIN IS SEEN.

FEMALE 193 (1711/80)

SPLEEN

*** LYMPHOMA LYMPHOCYTIC :
THE NEOPLASM OF THE RETICULAR SYSTEM ORIGINATES FROM LYMPHOCYTES.

FEMALE 200 (1681/80)

THYMUS

*** LYMPHOMA LYMPHOCYTIC :
THE NEOPLASM OF THE RETICULAR SYSTEM ORIGINATES FROM LYMPHOCYTES.

SF2T 1 CHRONIC TOXICITY STUDY IN MICE: SYSTEMATIC HISTOPATHOLOGY: LIST OF TUMOR BEARERS

PRODUCT : KWG 0519 GROUP : 2
ROUTE : DIETARY
TIME : 105 WEEKS DOSE : 500 PPM
THIS GROUP COMPRISED : 17 FEMALES

FEMALE 258 (1536/80)

OVARIES

*** LUTEOMA :
UNILATERAL
IT IS A BENIGN TUMOR COMPOSED OF CELLS RESEMBLING THOSE OF THE CORPUS LUTEUM.

FEMALE 266 (1538/80)

LIVER

*** ADENOMA HEPATIC BENIGN :
DISTINCT NODULES COMPRESS THE ADJACENT LIVER PARENCHYMA, ARE CHARACTERIZED BY WELL DIFFERENTIATED HEPATOCYTES AND DO NOT SHOW PORTAL TRIADS.

SPLEEN

*** LYMPHOMA LYMPHOCYTIC :
THE NEOPLASM OF THE RETICULAR SYSTEM ORIGINATES FROM LYMPHOCYTES.

FEMALE 267 (1539/80)

LIVER

*** ANGIOSARCOMA :
MALIGNANT MESENCHYMAL TUMOR OF VASCULAR ORIGIN OR SHOWING VASCULAR DIFFERENTIATION.

BAYER AG BAYER AG BAYER AG

FEMALE 270 (1541/80)

LUNG

*** ALVEOLOGENIC CARCINOMA :
A MALIGNANT TUMOR OF THE LUNG TISSUE WITH SYNONYMS IN MICE FOR ADENOMA, CARCINOMA, ALVEOLOGENIC PAPILLARY CARCINOMA, PAPILLARY CYSTADENOMA, ADENOCARCINOMA, BRONCHIOLAR CELL CARCINOMA, BRONCHIOLAR-ALVEOLAR TUMOR, TYPE A TUMOR, TYPE B TUMOR, INTERMEDIATE TYPE I TUMOR AND COMMON PULMONARY TUMOR OF THE MOUSE.

FEMALE 271 (1542/80)

LIVER

*** ADENOMA HEPATIC BENIGN :
DISTINCT NODULES COMPRESS THE ADJACENT LIVER PARENCHYMA, ARE CHARACTERIZED BY WELL DIFFERENTIATED HEPATOCYTES AND DO NOT SHOW PORTAL TRIADS.

FEMALE 272 (1543/80)

UTERUS

*** LEIOMYOSARCOMA :
UNILATERAL
MALIGNANT TUMOR DERIVED FROM SMOOTH MUSCLE FIBERS.

FEMALE 279 (1546/80)

SF2T 3 FEMALE 279 CONTINUED

LUNG

*** ALVEOLOGENIC CARCINOMA :
A MALIGNANT TUMOR OF THE LUNG TISSUE WITH SYNONYMS IN MICE FOR ADENOMA, CARCINOMA, ALVEOLOGENIC PAPILLARY CARCINOMA, PAPILLARY CYSTADENOMA, ADENOCARCINOMA, BRONCHIOLAR CELL CARCINOMA, BRONCHIOLAR-ALVEOLAR TUMOR, TYPE A TUMOR, TYPE B TUMOR, INTERMEDIATE TYPE I TUMOR AND COMMON PULMONARY TUMOR OF THE MOUSE.

FEMALE 291 (1548/80)

SPLEEN

*** LYMPHOMA LYMPHOCYTIC :
THE NEOPLASM OF THE RETICULAR SYSTEM ORIGINATES FROM LYMPHOCYTES.

FEMALE 296 (1550/80)

LUNG

*** ALVEOLOGENIC CARCINOMA :
A MALIGNANT TUMOR OF THE LUNG TISSUE WITH SYNONYMS IN MICE FOR ADENOMA, CARCINOMA, ALVEOLOGENIC PAPILLARY CARCINOMA, PAPILLARY CYSTADENOMA, ADENOCARCINOMA, BRONCHIOLAR CELL CARCINOMA, BRONCHIOLAR-ALVEOLAR TUMOR, TYPE A TUMOR, TYPE B TUMOR, INTERMEDIATE TYPE I TUMOR AND COMMON PULMONARY TUMOR OF THE MOUSE.

OVARIES

*** LUTEOMA :
UNILATERAL
IT IS A BENIGN TUMOR COMPOSED OF CELLS RESEMBLING THOSE OF THE CORPUS LUTEUM.

BAYER AG

MF2T 1 CHRONIC TOXICITY STUDY IN MICE: NONSYSTEMATIC

HISTOPATHOLOGY: LIST OF TUMOR BEARERS

PRODUCT : XWG 0519

GROUP : 2
ROUTE : DIETARY
DOSE : 500 PPM

TIME : 105 WEEKS
THIS GROUP COMPRISED : 33 FEMALES

FEMALE 251 (1794/80)

SPLEEN

*** LYMPHOMA LYMPHOCYTIC :
THE NEOPLASM OF THE RETICULAR SYSTEM ORIGINATES FROM LYMPHOCYTES.

FEMALE 252 (1803/80)

LUNG

*** ALVEOLOGENIC CARCINOMA :
A MALIGNANT TUMOR OF THE LUNG TISSUE WITH SYNONYMS IN MICE FOR ADENOMA, CARCINOMA, ALVEOLOGENIC PAPILLARY CARCINOMA, PAPILLARY CYSTADENOMA, ADENOCARCINOMA, BRONCHIOLAR CELL CARCINOMA, BRONCHIOLAR-ALVEOLAR TUMOR, TYPE A TUMOR, TYPE B TUMOR, INTERMEDIATE TYPE I TUMOR AND COMMON PULMONARY TUMOR OF THE MOUSE.

SPLEEN

*** LYMPHOMA LYMPHOCYTIC :
THE NEOPLASM OF THE RETICULAR SYSTEM ORIGINATES FROM LYMPHOCYTES.

LYMPH NODE

*** LYMPHOMA LYMPHOCYTIC :
THE NEOPLASM OF THE RETICULAR SYSTEM ORIGINATES FROM LYMPHOCYTES.

FEMALE 254 (1808/80)

LUNG

*** ALVEOLOGENIC CARCINOMA :
MULTIFOCAL
A MALIGNANT TUMOR OF THE LUNG TISSUE WITH SYNONYMS IN MICE FOR ADENOMA, CARCINOMA, ALVEOLOGENIC PAPILLARY CARCINOMA, PAPILLARY CYSTADENOMA, ADENOCARCINOMA, BRONCHIOLAR CELL CARCINOMA, BRONCHIOLAR-ALVEOLAR TUMOR, TYPE A TUMOR, TYPE B TUMOR, INTERMEDIATE TYPE I TUMOR AND COMMON PULMONARY TUMOR OF THE MOUSE.

LYMPH NODE

*** LYMPHOMA LYMPHOCYTIC :
THE NEOPLASM OF THE RETICULAR SYSTEM ORIGINATES FROM LYMPHOCYTES.

FEMALE 255 (1799/80)

SPLEEN

*** LYMPHOMA LYMPHOCYTIC :
THE NEOPLASM OF THE RETICULAR SYSTEM ORIGINATES FROM LYMPHOCYTES.

LYMPH NODE

*** LYMPHOMA LYMPHOCYTIC :
THE NEOPLASM OF THE RETICULAR SYSTEM ORIGINATES FROM LYMPHOCYTES.

FEMALE 256 (1789/80)

THYMUS

*** LYMPHOMA LYMPHOCYTIC :
THE NEOPLASM OF THE RETICULAR SYSTEM ORIGINATES FROM

BAYER AG

NF2T 3 FEMALE 256 CONTINUED

THYMUS CONTINUED
LYMPHOCYTES.

FEMALE 257 (1805/80)

SPLEEN

*** LYMPHOMA LYMPHOCYTIC :
THE NEOPLASM OF THE RETICULAR SYSTEM ORIGINATES FROM LYMPHOCYTES.

FEMUR

*** OSTEOGENIC SARCOMA :
MULTIFOCAL
A MALIGNANT MESENCHYMAL TUMOR WITH ISLANDS OF OSTEOID AND BONE FORMATION IS FOUND.

LYMPH NODE

*** LYMPHOMA LYMPHOCYTIC :
THE NEOPLASM OF THE RETICULAR SYSTEM ORIGINATES FROM LYMPHOCYTES.

FEMALE 259 (1797/80)

SPLEEN

*** LYMPHOMA LYMPHOCYTIC :
THE NEOPLASM OF THE RETICULAR SYSTEM ORIGINATES FROM LYMPHOCYTES.

FEMALE 260 (1814/80)

LUNG

*** ALVEOLOGENIC CARCINOMA :
A MALIGNANT TUMOR OF THE LUNG TISSUE WITH SYNONYMS IN MICE FOR ADENOMA, CARCINOMA, ALVEOLOGENIC PAPILLARY CARCINOMA, PAPILLARY CYSTADENOMA, ADENOCARCINOMA, BRONCHIOLAR

LUNG CONTINUED

CELL CARCINOMA, BRONCHIOLAR-ALVEOLAR TUMOR, TYPE A TUMOR, TYPE B TUMOR, INTERMEDIATE TYPE I TUMOR AND COMMON PULMONARY TUMOR OF THE MOUSE.

LIVER

*** ADENOMA HEPATIC BENIGN :
MULTIFOCAL
DISTINCT NODULES COMPRESS THE ADJACENT LIVER PARENCHYMA, ARE CHARACTERIZED BY WELL DIFFERENTIATED HEPATOCYTES AND DO NOT SHOW PORTAL TRIADS.

SPLEEN

*** LYMPHOMA STEM CELLS :
THE NEOPLASM OF THE RETICULAR SYSTEM ORIGINATES FROM STEM CELLS.

FEMALE 261 (1806/80)

LYMPH NODE

*** LYMPHOMA LYMPHOCYTIC :
THE NEOPLASM OF THE RETICULAR SYSTEM ORIGINATES FROM LYMPHOCYTES.

FEMALE 262 (1791/80)

LUNG

*** ALVEOLOGENIC CARCINOMA :
A MALIGNANT TUMOR OF THE LUNG TISSUE WITH SYNONYMS IN MICE FOR ADENOMA, CARCINOMA, ALVEOLOGENIC PAPILLARY CARCINOMA, PAPILLARY CYSTADENOMA, ADENOCARCINOMA, BRONCHIOLAR CELL CARCINOMA, BRONCHIOLAR-ALVEOLAR TUMOR, TYPE A TUMOR, TYPE B TUMOR, INTERMEDIATE TYPE I TUMOR AND COMMON PULMONARY TUMOR OF THE MOUSE.

SPLEEN

*** LYMPHOMA STEM CELLS :
THE NEOPLASM OF THE RETICULAR SYSTEM ORIGINATES FROM STEM CELLS.

BAYER AG

FEMALE 264 (1807/80)

DIAPHRAGM

*** LEIOMYOSARCOMA :
MALIGNANT TUMOR DERIVED FROM SMOOTH MUSCLE FIBERS.

FEMALE 265 (1804/80)

LIVER

*** ADENOCARCINOMA :
MALIGNANT EPITHELIAL TUMOR SHOWING VARIOUS WELL DIFFERENTIATED MORPHOLOGICAL ASPECTS.

SPLEEN

*** LYMPHOMA LYMPHOCYTIC :
THE NEOPLASM OF THE RETICULAR SYSTEM ORIGINATES FROM LYMPHOCYTES.

FEMALE 269 (1800/80)

BONE

*** OSTEOMA :
THIS BENIGN WELL CIRCUMSCRIBED TUMOR IS COMPOSED OF WELL-DEVELOPED BONE.

FEMALE 274 (1785/80)

SPLEEN

*** LYMPHOMA LYMPHOCYTIC :

SPLEEN CONTINUED

THE NEOPLASM OF THE RETICULAR SYSTEM ORIGINATES FROM LYMPHOCYTES.

FEMALE 275 (1809/60)

LUNG

*** ALVEOLOGENIC CARCINOMA :
A MALIGNANT TUMOR OF THE LUNG TISSUE WITH SYNONYMS IN MICE FOR ADENOMA, CARCINOMA, ALVEOLOGENIC PAPILLARY CARCINOMA, PAPILLARY CYSTADENOMA, ADENOCARCINOMA, BRONCHIOLAR CELL CARCINOMA, BRONCHIOLAR-ALVEOLAR TUMOR, TYPE A TUMOR, TYPE B TUMOR, INTERMEDIATE TYPE I TUMOR AND COMMON PULMONARY TUMOR OF THE MOUSE.

FEMALE 277 (1816/60)

LUNG

*** ALVEOLOGENIC CARCINOMA :
A MALIGNANT TUMOR OF THE LUNG TISSUE WITH SYNONYMS IN MICE FOR ADENOMA, CARCINOMA, ALVEOLOGENIC PAPILLARY CARCINOMA, PAPILLARY CYSTADENOMA, ADENOCARCINOMA, BRONCHIOLAR CELL CARCINOMA, BRONCHIOLAR-ALVEOLAR TUMOR, TYPE A TUMOR, TYPE B TUMOR, INTERMEDIATE TYPE I TUMOR AND COMMON PULMONARY TUMOR OF THE MOUSE.

SPLEEN

*** LYMPHOMA LYMPHOCYTIC :
THE NEOPLASM OF THE RETICULAR SYSTEM ORIGINATES FROM LYMPHOCYTES.

FEMUR

*** OSTEOMA :
THIS BENIGN WELL CIRCUMSCRIBED TUMOR IS COMPOSED OF WELL-DEVELOPED BONE.

LYMPH NODE

*** LYMPHOMA LYMPHOCYTIC :
THE NEOPLASM OF THE RETICULAR SYSTEM ORIGINATES FROM

BAYER AG BAYER AG BAYER AG

LYMPH NODE CONTINUED
LYMPHOCYTES.

FEMALE 278 (1795/80)

SPLEEN

*** LYMPHOMA LYMPHOCYTIC :
THE NEOPLASM OF THE RETICULAR SYSTEM ORIGINATES FROM LYMPHOCYTES.

UTERUS

*** MESENCHYMAL TUMOR :
UNILATERAL
MALIGNANT TUMOR DERIVED FROM UNDIFFERENTIATED COMPONENTS OF CONNECTIVE TISSUE.

LYMPH NODE

*** LYMPHOMA LYMPHOCYTIC :
THE NEOPLASM OF THE RETICULAR SYSTEM ORIGINATES FROM LYMPHOCYTES.

FEMALE 282 (1790/80)

SPLEEN

*** LYMPHOMA GRANULOCYTIC :
THE NEOPLASM OF THE RETICULAR SYSTEM ORIGINATES FROM GRANULOCYTES.

FEMALE 284 (1815/80)

LUNG

*** ALVEOLOGENIC CARCINOMA :
MULTIFOCAL
A MALIGNANT TUMOR OF THE LUNG TISSUE WITH SYNONYMS IN MICE FOR ADENOMA, CARCINOMA, ALVEOLOGENIC PAPILLARY CARCINOMA, PAPILLARY

LUNG CONTINUED

CYSTADENOMA, ADENOCARCINOMA, BRONCHIOLAR CELL CARCINOMA, BRONCHIOLAR-ALVEOLAR TUMOR, TYPE A TUMOR, TYPE B TUMOR, INTERMEDIATE TYPE I TUMOR AND COMMON PULMONARY TUMOR OF THE MOUSE.

FEMALE 286 (1810/80)

PITUITARY

*** ADENOMA :
THIS IS BENIGN GLANDULAR EPITHELIAL TUMOR.

FEMALE 287 (1787/80)

LUNG

*** ALVEOLOGENIC CARCINOMA :
MULTIFOCAL
A MALIGNANT TUMOR OF THE LUNG TISSUE WITH SYNONYMS IN MICE FOR ADENOMA, CARCINOMA, ALVEOLOGENIC PAPILLARY CARCINOMA, PAPILLARY CYSTADENOMA, ADENOCARCINOMA, BRONCHIOLAR CELL CARCINOMA, BRONCHIOLAR-ALVEOLAR TUMOR, TYPE A TUMOR, TYPE B TUMOR, INTERMEDIATE TYPE I TUMOR AND COMMON PULMONARY TUMOR OF THE MOUSE.

SPLEEN

*** LYMPHOMA LYMPHOCYTIC :
THE NEOPLASM OF THE RETICULAR SYSTEM ORIGINATES FROM LYMPHOCYTES.

LYMPH NODE

*** LYMPHOMA LYMPHOCYTIC :
THE NEOPLASM OF THE RETICULAR SYSTEM ORIGINATES FROM LYMPHOCYTES.

FEMALE 288 (1812/80)

BAYER AG BAYER AG BAYER AG

LUNG

*** ALVEOLOGENIC CARCINOMA :
MULTIFOCAL
A MALIGNANT TUMOR OF THE LUNG TISSUE WITH SYNONYMS IN MICE FOR ADENOMA, CARCINOMA, ALVEOLOGENIC PAPILLARY CARCINOMA, PAPILLARY CYSTADENOMA, ADENOCARCINOMA, BRONCHIOLAR CELL CARCINOMA, BRONCHIOLAR-ALVEOLAR TUMOR, TYPE A TUMOR, TYPE B TUMOR, INTERMEDIATE TYPE I TUMOR AND COMMON PULMONARY TUMOR OF THE MOUSE.

SPLEEN

*** LYMPHOMA LYMPHOCYTIC :
THE NEOPLASM OF THE RETICULAR SYSTEM ORIGINATES FROM LYMPHOCYTES.

LYMPH NODE

*** LYMPHOMA LYMPHOCYTIC :
THE NEOPLASM OF THE RETICULAR SYSTEM ORIGINATES FROM LYMPHOCYTES.

FEMALE 289 (1811/80)

LIVER

*** ADENOMA HEPATIC BENIGN :
DISTINCT NODULES COMPRESS THE ADJACENT LIVER PARENCHYMA, ARE CHARACTERIZED BY WELL DIFFERENTIATED HEPATOCYTES AND DO NOT SHOW PORTAL TRIADS.

SPLEEN

*** LYMPHOMA LYMPHOCYTIC :
THE NEOPLASM OF THE RETICULAR SYSTEM ORIGINATES FROM LYMPHOCYTES.

LYMPH NODE

*** LYMPHOMA LYMPHOCYTIC :
THE NEOPLASM OF THE RETICULAR SYSTEM ORIGINATES FROM LYMPHOCYTES.

FEMALE 290 (1804/80)

LUNG

*** ALVEOLOGENIC CARCINOMA :
A MALIGNANT TUMOR OF THE LUNG TISSUE WITH SYNONYMS IN MICE FOR ADENOMA, CARCINOMA, ALVEOLOGENIC PAPILLARY CARCINOMA, PAPILLARY CYSTADENOMA, ADENOCARCINOMA, BRONCHIOLAR CELL CARCINOMA, BRONCHIOLAR-ALVEOLAR TUMOR, TYPE A TUMOR, TYPE B TUMOR, INTERMEDIATE TYPE I TUMOR AND COMMON PULMONARY TUMOR OF THE MOUSE.

THYMUS

*** THYMOMA :
TUMOR DEVELOPED IN THE THYMUS AND DERIVED FROM THE EPITHELIAL CELLS.

BONE

*** OSTEOMA :
THIS BENIGN WELL CIRCUMSCRIBED TUMOR IS COMPOSED OF WELL-DEVELOPED BONE.

FEMALE 292 (1801/80)

OVARIES

*** LUTEOMA :
UNILATERAL
IT IS A BENIGN TUMOR COMPOSED OF CELLS RESEMBLING THOSE OF THE CORPUS LUTEUM.

FEMALE 293 (1784/80)

THYMUS

*** LYMPHOMA LYMPHOCYTIC :
THE NEOPLASM OF THE RETICULAR SYSTEM ORIGINATES FROM LYMPHOCYTES.

FEMALE 294 (1796/80)

BAYER AG

SPLEEN

*** LYMPHOMA LYMPHOCYTIC :
THE NEOPLASM OF THE RETICULAR SYSTEM ORIGINATES FROM LYMPHOCYTES.

FEMALE 296 (1794/80)

LUNG

*** ALVEOLOGENIC CARCINOMA :
A MALIGNANT TUMOR OF THE LUNG TISSUE WITH SYNONYMS IN MICE FOR ADENOMA, CARCINOMA, ALVEOLOGENIC PAPILLARY CARCINOMA, PAPILLARY CYSTADENOMA, ADENOCARCINOMA, BRONCHIOLAR CELL CARCINOMA, BRONCHIOLAR-ALVEOLAR TUMOR, TYPE A TUMOR, TYPE B TUMOR, INTERMEDIATE TYPE I TUMOR AND COMMON PULMONARY TUMOR OF THE MOUSE.

LYMPH NODE

*** LYMPHOMA LYMPHOCYTIC :
THE NEOPLASM OF THE RETICULAR SYSTEM ORIGINATES FROM LYMPHOCYTES.

FEMALE 300 (1813/80)

LUNG

*** ALVEOLOGENIC CARCINOMA :
MULTIFOCAL
A MALIGNANT TUMOR OF THE LUNG TISSUE WITH SYNONYMS IN MICE FOR ADENOMA, CARCINOMA, ALVEOLOGENIC PAPILLARY CARCINOMA, PAPILLARY CYSTADENOMA, ADENOCARCINOMA, BRONCHIOLAR CELL CARCINOMA, BRONCHIOLAR-ALVEOLAR TUMOR, TYPE A TUMOR, TYPE B TUMOR, INTERMEDIATE TYPE I TUMOR AND COMMON PULMONARY TUMOR OF THE MOUSE.

SF3T 1 CHRONIC TOXICITY STUDY IN MICE: SYSTEMATIC HISTOPATHOLOGY: LIST OF TUMOR BEARERS

PRODUCT : KWG 0519 GROUP : 3
ROUTE : DIETARY
TIME : 105 WEEKS DOSE : 2000 PPM
THIS GROUP COMPRISED : 19 FEMALES

FEMALE 357 (1571/80)

UTERUS

*** MESENCHYMAL TUMOR :
CONTRALATERAL
MALIGNANT TUMOR DERIVED FROM UNDIFFERENTIATED COMPONENTS OF CONNECTIVE TISSUE.

FEMALE 360 (1573/80)

UTERUS

*** LEIOMYOSARCOMA :
UNILATERAL
MALIGNANT TUMOR DERIVED FROM SMOOTH MUSCLE FIBERS.

FEMALE 367 (1574/80)

LIVER

*** ADENOMA HEPATIC BENIGN :
DISTINCT NODULES COMPRESS THE ADJACENT LIVER PARENCHYMA, ARE CHARACTERIZED BY WELL DIFFERENTIATED HEPATOCYTES AND DO NOT SHOW PORTAL TRIADS.

BAYER AG

FEMALE 375 (1576/80)

LIVER

*** ADENOMA HEPATIC BENIGN :
DISTINCT NODULES COMPRESS THE ADJACENT LIVER PARENCHYMA, ARE CHARACTERIZED BY WELL DIFFERENTIATED HEPATOCYTES AND DO NOT SHOW PORTAL TRIADS.

FEMALE 377 (1577/80)

LIVER

*** ADENOMA HEPATIC BENIGN :
DISTINCT NODULES COMPRESS THE ADJACENT LIVER PARENCHYMA, ARE CHARACTERIZED BY WELL DIFFERENTIATED HEPATOCYTES AND DO NOT SHOW PORTAL TRIADS.

FEMALE 378 (1578/80)

LUNG

*** ALVEOLOGENIC CARCINOMA :
A MALIGNANT TUMOR OF THE LUNG TISSUE WITH SYNONYMS IN MICE FOR ADENOMA, CARCINOMA, ALVEOLOGENIC PAPILLARY CARCINOMA, PAPILLARY CYSTADENOMA, ADENOCARCINOMA, BRONCHIOLAR CELL CARCINOMA, BRONCHIOLAR-ALVEOLAR TUMOR, TYPE A TUMOR, TYPE B TUMOR, INTERMEDIATE TYPE I TUMOR AND COMMON PULMONARY TUMOR OF THE MOUSE.

FEMALE 383 (1580/80)

LUNG

*** ALVEOLOGENIC CARCINOMA :
MULTIFOCAL
A MALIGNANT TUMOR OF THE LUNG TISSUE WITH SYNONYMS IN MICE FOR ADENOMA, CARCINOMA, ALVEOLOGENIC PAPILLARY CARCINOMA, PAPILLARY CYSTADENOMA, ADENOCARCINOMA, BRONCHIOLAR CELL CARCINOMA, BRONCHIOLAR-ALVEOLAR TUMOR, TYPE A TUMOR, TYPE B TUMOR, INTERMEDIATE TYPE I TUMOR AND COMMON PULMONARY TUMOR OF THE MOUSE.

FEMALE 384 (1581/80)

LUNG

*** ALVEOLOGENIC CARCINOMA :
A MALIGNANT TUMOR OF THE LUNG TISSUE WITH SYNONYMS IN MICE FOR ADENOMA, CARCINOMA, ALVEOLOGENIC PAPILLARY CARCINOMA, PAPILLARY CYSTADENOMA, ADENOCARCINOMA, BRONCHIOLAR CELL CARCINOMA, BRONCHIOLAR-ALVEOLAR TUMOR, TYPE A TUMOR, TYPE B TUMOR, INTERMEDIATE TYPE I TUMOR AND COMMON PULMONARY TUMOR OF THE MOUSE.

FEMALE 388 (1582/80)

UTERUS

*** ADENOMA :
UNILATERAL
THIS IS BENIGN GLANDULAR EPITHELIAL TUMOR.

FEMALE 391 (1584/80)

LUNG

*** ALVEOLOGENIC CARCINOMA :
MULTIFOCAL

BAYER AG

LUNG CONTINUED

A MALIGNANT TUMOR OF THE LUNG TISSUE WITH SYNONYMS IN MICE FOR ADENOMA, CARCINOMA, ALVEOLOGENIC PAPILLARY CARCINOMA, PAPILLARY CYSTADENOMA, ADENOCARCINOMA, BRONCHIOLAR CELL CARCINOMA, BRONCHIOLAR-ALVEOLAR TUMOR, TYPE A TUMOR, TYPE B TUMOR, INTERMEDIATE TYPE I TUMOR AND COMMON PULMONARY TUMOR OF THE MOUSE.

FEMALE 398 (1585/80)

ADRENALS

*** PHEOCHROMOCYTOMA :
UNILATERAL

THIS TUMOR IS COMPOSED OF POLYHEDRAL CELLS WHICH ARISE FROM THE CHROMAFFIN CELLS OF THE ADRENAL MEDULLA AND FORM LOBULES SEPARATED BY VASCULAR CONNECTIVE TISSUE SEPTA.

FEMALE 399 (1602/80)

LUNG

*** ALVEOLOGENIC CARCINOMA :

A MALIGNANT TUMOR OF THE LUNG TISSUE WITH SYNONYMS IN MICE FOR ADENOMA, CARCINOMA, ALVEOLOGENIC PAPILLARY CARCINOMA, PAPILLARY CYSTADENOMA, ADENOCARCINOMA, BRONCHIOLAR CELL CARCINOMA, BRONCHIOLAR-ALVEOLAR TUMOR, TYPE A TUMOR, TYPE B TUMOR, INTERMEDIATE TYPE I TUMOR AND COMMON PULMONARY TUMOR OF THE MOUSE.

OVARIES

*** ARRHENOBLASTOMA :
BILATERAL

THIS TUMOR IS MAINLY COMPOSED OF IMMATURE GONADAL ELEMENTS OF THE MALE TYPE SUCH AS TUBULAR STRUCTURES SUGGESTING POORLY DEVELOPED SEMINIFEROUS TUBULES.

NF3T 1 CHRONIC TOXICITY STUDY IN MICE: NONSYSTEMATIC

HISTOPATHOLOGY: LIST OF TUMOR BEARERS

PRODUCT : KhG 0519

TIME : 105 WEEKS
THIS GROUP COMPRISED : 30 FEMALES

GROUP : 3
ROUTE : DIETARY
DOSE : 2000 PPM

FEMALE 352 (1850/80)

THYMUS

*** LYMPHOMA LYMPHOCYTIC :
THE NEOPLASM OF THE RETICULAR SYSTEM ORIGINATES FROM LYMPHOCYTES.

FEMALE 353 (1859/80)

SPLEEN

*** LYMPHOMA STEM CELLS :
THE NEOPLASM OF THE RETICULAR SYSTEM ORIGINATES FROM STEM CELLS.

BONE

*** OSTEOMA :
THIS BENIGN WELL CIRCUMSCRIBED TUMOR IS COMPOSED OF WELL-DEVELOPED BONE.

FEMALE 356 (1594/80)

ADRENALS

*** ADENOMA :
UNILATERAL
THIS IS BENIGN GLANDULAR EPITHELIAL TUMOR.

BAYER AG BAYER AG BAYER AG

FEMALE 361 (1656/00)

SPLEEN

*** LYMPHOMA LYMPHOCYTIC :
THE NEOPLASM OF THE RETICULAR SYSTEM ORIGINATES FROM LYMPHOCYTES.

LYMPH NODE

*** LYMPHOMA LYMPHOCYTIC :
THE NEOPLASM OF THE RETICULAR SYSTEM ORIGINATES FROM LYMPHOCYTES.

FEMALE 362 (1600/80)

SPLEEN

*** LYMPHOMA LYMPHOCYTIC :
THE NEOPLASM OF THE RETICULAR SYSTEM ORIGINATES FROM LYMPHOCYTES.

SKULL

*** OSTEOMA :
THIS BENIGN WELL CIRCUMSCRIBED TUMOR IS COMPOSED OF WELL-DEVELOPED BONE.

FEMALE 363 (1660/80)

THYMUS

*** LYMPHOMA LYMPHOCYTIC :
THE NEOPLASM OF THE RETICULAR SYSTEM ORIGINATES FROM LYMPHOCYTES.

SPLEEN

*** LYMPHOMA LYMPHOCYTIC :
THE NEOPLASM OF THE RETICULAR SYSTEM ORIGINATES FROM LYMPHOCYTES.

FEMALE 365 (1599/80)

LIVER

*** ADENOMA HEPATIC BENIGN :
UNILATERAL MULTIFOCAL
DISTINCT NODULES COMPRESS THE ADJACENT LIVER PARENCHYMA, ARE CHARACTERIZED BY WELL DIFFERENTIATED HEPATOCYTES AND DO NOT SHOW PORTAL TRIADS.

FEMALE 366 (1597/80)

SPLEEN

*** LYMPHOMA LYMPHOCYTIC :
THE NEOPLASM OF THE RETICULAR SYSTEM ORIGINATES FROM LYMPHOCYTES.

LYMPH NODE

*** LYMPHOMA LYMPHOCYTIC :
THE NEOPLASM OF THE RETICULAR SYSTEM ORIGINATES FROM LYMPHOCYTES.

FEMALE 369 (1858/80)

THYMUS

*** LYMPHOMA LYMPHOCYTIC :
THE NEOPLASM OF THE RETICULAR SYSTEM ORIGINATES FROM LYMPHOCYTES.

SPLEEN

*** LYMPHOMA LYMPHOCYTIC :
THE NEOPLASM OF THE RETICULAR SYSTEM ORIGINATES FROM LYMPHOCYTES.

BAYER AG

Vertraulich

Eigentum der Firma Bayer AG
Benutzung, Verwertung oder W
gabe nur mit Einwilligung der
Bayer AG gestattet

FEMALE 370 (1661/80)

SPLEEN

*** LYMPHOMA LYMPHOCYTIC :
THE NEOPLASM OF THE RETICULAR SYSTEM ORIGINATES FROM LYMPHOCYTES.

OVARIES

*** LUTEOMA :
UNILATERAL
IT IS A BENIGN TUMOR COMPOSED OF CELLS RESEMBLING THOSE OF THE CORPUS LUTEUM.

FEMALE 371 (1853/80)

THYMUS

*** LYMPHOMA LYMPHOCYTIC :
THE NEOPLASM OF THE RETICULAR SYSTEM ORIGINATES FROM LYMPHOCYTES.

OVARIES

*** LUTEOMA :
BILATERAL
IT IS A BENIGN TUMOR COMPOSED OF CELLS RESEMBLING THOSE OF THE CORPUS LUTEUM.

FEMALE 373 (1596/80)

LUNG

*** METASTASIS : (osteogenic sarcoma)
A SECONDARY MALIGNANT TUMOR DEVELOPED AWAY FROM THE INITIAL GROWTH.

SKELETAL MUSCLE

*** METASTASIS : (osteogenic sarcoma)

FEMALE 373 CONTINUED

SKELETAL MUSCLE CONTINUED

A SECONDARY MALIGNANT TUMOR DEVELOPED AWAY FROM THE INITIAL GROWTH.

FEMUR

*** OSTEOGENIC SARCOMA :
A MALIGNANT MESENCHYMAL TUMOR WITH ISLANDS OF OSTEOID AND BONE FORMATION IS FOUND.

FEMALE 374 (1587/80)

SPLEEN

*** LYMPHOMA LYMPHOCYTIC :
THE NEOPLASM OF THE RETICULAR SYSTEM ORIGINATES FROM LYMPHOCYTES.

RIGHT HIND EXTREMITY

*** METASTASIS : (osteogenic sarcoma)
A SECONDARY MALIGNANT TUMOR DEVELOPED AWAY FROM THE INITIAL GROWTH.

FEMUR

*** OSTEOGENIC SARCOMA :
A MALIGNANT MESENCHYMAL TUMOR WITH ISLANDS OF OSTEOID AND BONE FORMATION IS FOUND.

BODY CAVITY

*** METASTASIS :(osteogenic sarcoma)
A SECONDARY MALIGNANT TUMOR DEVELOPED AWAY FROM THE INITIAL GROWTH.

FEMALE 376 (1657/80)

LIVER

*** ADENOMA HEPATIC BENIGN :
DISTINCT NODULES COMPRESS THE ADJACENT LIVER PARENCHYMA, ARE CHARACTERIZED BY WELL DIFFERENTIATED HEPATOCYTES AND DO NOT SHOW PORTAL TRIADS.

BAYER AG

FEMALE 380 (1601/80)

SPLEEN

*** LYMPHOMA LYMPHOCYTIC :
THE NEOPLASM OF THE RETICULAR SYSTEM ORIGINATES FROM LYMPHOCYTES.

LYMPH NODE

*** LYMPHOMA LYMPHOCYTIC :
THE NEOPLASM OF THE RETICULAR SYSTEM ORIGINATES FROM LYMPHOCYTES.

FEMALE 381 (1594/80)

LIVER

*** ADENOMA HEPATIC BENIGN :
DISTINCT NODULES COMPRESS THE ADJACENT LIVER PARENCHYMA, ARE CHARACTERIZED BY WELL DIFFERENTIATED HEPATOCYTES AND DO NOT SHOW PORTAL TRIADS.

SPLEEN

*** LYMPHOMA LYMPHOCYTIC :
THE NEOPLASM OF THE RETICULAR SYSTEM ORIGINATES FROM LYMPHOCYTES.

FEMALE 382 (1586/80)

THYMUS

*** LYMPHOMA LYMPHOCYTIC :
THE NEOPLASM OF THE RETICULAR SYSTEM ORIGINATES FROM LYMPHOCYTES.

SPLEEN

*** LYMPHOMA LYMPHOCYTIC :
THE NEOPLASM OF THE RETICULAR SYSTEM ORIGINATES FROM

NF3T 7 FEMALE 382 CONTINUED

SPLEEN CONTINUED
LYMPHOCYTES.

ADRENALS

*** ADENOMA :
UNILATERAL
THIS IS BENIGN GLANDULAR EPITHELIAL TUMOR.

FEMALE 385 (1588/80)

SPLEEN

*** LYMPHOMA LYMPHOCYTIC :
THE NEOPLASM OF THE RETICULAR SYSTEM ORIGINATES FROM LYMPHOCYTES.

FEMALE 390 (1862/80)

SPLEEN

*** LYMPHOMA LYMPHOCYTIC :
THE NEOPLASM OF THE RETICULAR SYSTEM ORIGINATES FROM LYMPHOCYTES.

UTERUS

*** LEIOMYOSARCOMA :
MALIGNANT TUMOR DERIVED FROM SMOOTH MUSCLE FIBERS.

FEMALE 394 (1595/80)

LUNG

*** ALVEOLOGENIC CARCINOMA :
MULTIFOCAL
A MALIGNANT TUMOR OF THE LUNG TISSUE WITH SYNONYMS IN MICE FOR ADENOMA, CARCINOMA, ALVEOLOGENIC PAPILLARY CARCINOMA, PAPILLARY CYSTADENOMA, ADENOCARCINOMA, BRONCHIOLAR CELL CARCINOMA, BRONCHIOLAR-ALVEOLAR TUMOR,

BAYER AG

LUNG CONTINUED

TYPE A TUMOR, TYPE B TUMOR, INTERMEDIATE TYPE I TUMOR AND COMMON PULMONARY TUMOR OF THE MOUSE.

SPLEEN

*** LYMPHOMA LYMPHOCYTIC :
THE NEOPLASM OF THE RETICULAR SYSTEM ORIGINATES FROM LYMPHOCYTES.

FEMALE 395 (1589/80)

CERVIX

*** LEIOMYOSARCOMA :
MALIGNANT TUMOR DERIVED FROM SMOOTH MUSCLE FIBERS.

FEMALE 396 (1593/80)

SPLEEN

*** LYMPHOMA LYMPHOCYTIC :
THE NEOPLASM OF THE RETICULAR SYSTEM ORIGINATES FROM LYMPHOCYTES.

FEMALE 397 (1851/80)

SPLEEN

*** LYMPHOMA LYMPHOCYTIC :
THE NEOPLASM OF THE RETICULAR SYSTEM ORIGINATES FROM LYMPHOCYTES.

407
"Contains NO CBI"

CHRONIC DIETARY ADMINISTRATION OF KWG 0519 TO MICE FOR 105 WEEKS: HISTOPATHOLOGY

Report

for

Bayer AG
Wuppertal

V 64. 600-01

Final Report

by

Dr. S. C. Saxena
M.Sc., Ph.D.
Toxicologist and Experimental
Animal Pathologist

Dr. med.vet. H. Ehrd
Fachtierarzt für
Pathologie

BAYER AG

CONTENTS

	Page
Introduction	1
Tissues and Tissue Preparation	1
Salient Diagnostic Features	2
Histological Evaluation and Summary	5
Neoplastic Lesions	6
Non-Neoplastic Lesions	8
Table I Incidence of Tumour Bearers	9
Table II Incidence of Malignant, Non-Malignant or Both Types of Tumour Bearers	10
Table III Incidence of Lymphoma Bearing Animals	11
Table IV Group Incidence of Certain Lesions in Liver, Thyroids, Testes and Uterus	12
Appendix I: Summary Tables	01
Table 1 Tumorous Lesions: Systematic Males	02
Table 2 Tumorous Lesions: Non-Systematic Males	04
Table 3 Tumorous Lesions: Group Incidence Males	07

		Page
Table 4	Tumorous Lesions: Systematic Females	10
Table 5	Tumorous Lesions: Non-Systematic Females	12
Table 6	Tumorous Lesions: Group Incidence Females	15
Table 7	Non-Tumorous Lesions: Systematic Males	18
Table 8	Non-Tumorous Lesions: Non-Systematic Males	23
Table 9	Non-Tumorous Lesions: Group Incidence Males	31
Table 10	Non-Tumorous Lesions: Systematic Females	41
Table 11	Non-Tumorous Lesions: Non-Systematic Females	46
Table 12	Non-Tumorous Lesions: Group Incidence Females	54

Appendix II: Individual Histological Data 64

Control: Systematic Males 65

Mice No. : 5 22 33
13 24 35
16 26 40
19 31

: Non-systematic Males 77

Mice No :

1 8 15 25 34 42 48
2 9 17 27 36 43 49
3 10 18 28 37 44 50
4 11 20 29 38 45
6 12 21 30 39 46
7 14 23 32 41 47

(Individual data contd.)

	Page
Group I: Systematic Males	127
Mice No: 107, 110, 117, 119, 123, 127, 128, 141, 142, 148, 149	
: Non-systematic Males	141
Mice No: 101, 102, 103, 104, 105, 106, 108, 109, 111, 112, 113, 114, 115, 116, 118, 120, 121, 122, 124, 125, 126, 129, 130, 131, 132, 133, 134, 135, 136, 137, 138, 139, 140, 143, 144, 145, 146, 147, 150	
Group II: Systematic Males	188
Mice No: 202, 205, 206, 215, 217, 218, 219, 226, 228, 230, 233, 239, 244	

BAYER AG

(Individual data contd.)

Page

: Non-systematic Males 201

Mice No:

201	208	212	220	224	231	236	241	247
203	209	213	221	225	232	237	242	248
204	210	214	222	227	234	238	243	249
207	211	216	223	229	235	240	246	250

Group III: Systematic Males 245

Mice No:

306	315	332	338	348
308	322	334	342	
310	327	335	343	
312	331	336	345	

: Non-systematic Males 261

Mice No:

301	309	318	325	337	347
302	311	319	326	339	349
303	313	320	328	340	350
304	314	321	329	341	
305	316	323	330	344	
307	317	324	333	346	

(Individual data contd.)

Page

Control: Systematic Females 305

Mice No:

51	66	81	89
52	74	82	92
55	76	83	96
57	78	84	100

: Non-systematic Females 326

Mice No:

53	61	69	77	88	97
54	62	70	79	90	98
56	63	71	80	91	99
58	64	72	85	93	
59	67	73	86	94	
60	68	75	87	95	

Group I: Systematic Females 373

Mice No:

158	168	178	194
161	170	179	196
163	171	186	197
164	177	188	198

BAYER AG

(Individual data contd.)

Page

: Non-systematic Females 391

Mice No:

151	157	167	176	185	193
152	159	169	180	187	195
153	160	172	181	189	200
154	162	173	182	190	
155	165	174	183	191	
156	166	175	184	192	

Group II: Systematic Females 434

Mice No:

253	268	276	296
258	270	279	299
263	271	281	
266	272	291	
267	273	295	

: Non-systematic Females 453

Mice No:

251	259	269	282	288	297
252	260	274	283	289	298
254	261	275	284	290	300
255	262	277	285	292	
256	264	278	286	293	
257	265	280	287	294	

(Individual data concluded)

Group III: Systematic Females

Mice No:

351	367	379	391
354	368	383	398
357	375	384	399
359	377	388	400
360	378	389	

: Non-systematic Females 523

Mice No:

352	362	369	374	385	393
353	363	370	376	386	394
356	364	371	380	387	395
358	365	372	381	390	396
361	366	373	382	392	397

BAYER AG BAYER AG BAYER AG BAYER AG

Page

Appendix III: List of Animals Bearing Tumours 561

Control: Systematic Males 562

Malignant Tumour Bearers:
Mice No.: 24, 35
Non-malignant Tumour Bearers:
Mice No.: 22, 33
Both: Mice No. : 16, 31. 40

: Non-systematic Males 565

Malignant Tumour Bearers:
Mice No. 2, 3, 6, 7, 8, 12, 14, 18,
20, 21, 23, 29, 30, 32, 34,
36, 38, 39, 43, 47, 48, 50

Non-malignant Tumour Bearers:
Mice No. 15, 44
Both: Mice No. 11, 25, 27, 42, 49

Group I: Systematic Males 576

Malignant Tumour Bearers:
Mice No. 107, 119, 123, 141, 142

Non-malignant Tumour Bearers:
Mice No. 117, 127

Both: Mice No. 128, 149

: Non-systematic Males 580

Malignant Tumour Bearers:
Mice No. 106, 112, 114, 115, 147
116, 121, 126, 129
130, 131, 137, 139

Non-malignant Tumour Bearers:
Mice No. 102, 105, 120, 125
136, 138, 140

Both: Mice No. 111, 133

(Animals bearing tumours contd.)

	Page
Group II: Systematic Males	588
Malignant Tumour Bearers Mice No. 206, 217, 244	
Non-malignant Tumour Bearers: Mice No. 202, 215, 226, 230, 233, 239	
Both: Mice No. 218	
: Non-systematic Males	592
Malignant Tumour Bearers Mice No. 203, 210, 211, 212, 231, 234, 243, 246, 249	
Non-malignant Tumour Bearers Mice No. 208, 232, 237	
Both: Mice No. 201, 204, 235	
Group III: Systematic Males	598
Malignant Tumour Bearers: Mice No. 310, 322, 327, 332, 335	
Non-malignant Tumour Bearers: Mice No. 315, 334, 343, 345	
Both: Mice No. 306, 308, 336, 342	

BAYER AG

(Animals bearing tumours contd.)

Page

: Non-systematic Males 603

Malignant Tumour Bearers:

Mice No. 301, 309, 313, 321, 323,
324, 326, 329, 337, 339,
340, 341, 344, 346, 350

Non-malignant Tumour Bearers

Mice No. 302, 319, 349

Both: Mice No.: 320

Control: Systematic Females 610

Malignant Tumour Bearers:

Mice No.: 57, 66, 81, 89

Both: Mice No.: 55, 78, 92

: Non-Systematic Females 613

Malignant Tumour Bearers:

Mice No. 53 56 58 59
60 62 63 64
67 68 69 71
72 73 77 79
80 87 88 91
93 94 95 97
99

(Animals bearing tumours contd.)

Page

Group I: Systematic Females 622

Malignant Tumour Bearers:

Mice No.: 158 163 177 186
196 198

Non-malignant Tumour Bearers:

Mice No.: 179 197

Both: Mice No.: 171

: Non-systematic Females 626

Malignant Tumour Bearers:

Mice No.: 151 152 157 159
160 162 165 166
167 172 173 175
180 182 183 185
189 190 191 193
200

Non-malignant Tumour Bearers:

Mice No.: 155 192

BAYER AG

(Animals bearing tumours contd.)

Page

Group II: Systematic Females 633

Malignant Tumour Bearer:

Mice No. 267 270 272 279 291

Non-malignant Tumour Bearers:

Mice No. 258 271

Both: Mice No.: 266, 296

: Non-systematic Females 636

Malignant Tumour Bearers:

Mice No.: 251 252 254 255
256 257 259 261
262 264 265 274
275 278 282 284
287 288 293 294
298 300

Non-malignant Tumour Bearers:

Mice No.: 269 286 292

Both: Mice No. 260 277 289 290

(Animals bearing tumours concluded)

Page

Group III: Systematic Females 647

Malignant Tumour Bearers:

Mice No.: 357 360 378 383
384 391

Non-malignant Tumour Bearers:

Mice No.: 367 375 377 388
398

Both: Mice No. 399

: Non-systematic Females 651

Malignant Tumour Bearers:

Mice No.: 352 361 363 366
369 373 374 380
385 390 394 395
396 397

Non-malignant Tumour Bearers:

Mice No.: 358 365 376

Both: Mice No.:

353 362 370 371
381 382

BAYER AG BAYER AG BAYER AG BAYER AG

Abbreviations in Computer Printout

UNKNOWN TISSUE OR ANY OT
= Unkown tissue or any other

UNCLASSIFIED RCS
= Unclassified Reticulum Cell System

NOTE

Male mice 245 in the group II (non-systematic) has been excluded because it was placed by mistake in another group probably at autopsy.

Introduction

Following a chronic study after dietary administration of KWG 0519 for 105 weeks to groups of male and female mice, wet tissues preserved in formalin were received from the sponsor, Bayer A.G., Wuppertal, for processing and histopathological evaluation.

The histological examination of the tissues was carried out by two pathologists. One of the pathologists (SCS) examined the tissues histologically from all female groups and male groups I and II, while the other (HE) examined the male groups control and III. In order to ensure uniformity of nomenclature for this study the two pathologists exchanged their views, and later on SCS re-examined some organs (lungs, livers, kidneys, testes, adrenals and all tumours) from male groups control and III as well.

Tissues and Tissue Preparation

For all the groups the organs listed below were routinely processed and subjected to histological examination:

Heart	Spleen	Testes/Ovaries
Lung	Kidneys	Thyroids/Parathyroids
Liver	Bladder	Adrenals
Pancreas	Stomach	Pituitary
Brain	Skeletal muscle	Nerve
Femur/Marrow		

Other organs showing a pathological change either at autopsy or after fixation were also processed and histologically examined.

The tissues were accompanied by a detailed list of findings on animals which showed changes at autopsy.

While trimming the tissues care was taken to include both the abnormal and normal parts of the organs by reading the autopsy findings on each animal.

The tissues were routinely processed and embedded in paraplast, cut at 5 µ and stained with haematoxylin-eosin. Each slide was hand printed with the animal number as well as the pathology number.

Salient Diagnostic Features

The identification of some lesions was based on the following:

Lungs: All pulmonary tumours were classified as alveologenic carcinomas according to the definition given by Stewart et al. (Tumours of the respiratory tract; in Pathology of the Tumours in Laboratory Animals, Vol. II - Tumours of the Mouse, 1979, published by the International Agency for Research on Cancer, Lyon, France).

Kidneys: If progressive nephropathy of any grade was diagnosed no mention was made of mononuclear cells, interstitial nephritis, proteinaceous casts, tubular ectasia, cysts, fibrosis, etc. ... If progressive nephropathy was not present, other possibly present lesions were diagnosed, which were of minimal to moderate severity. However, if lithiasis, epithelial hyperplasia and dilatation of the renal pelvis were present, they were recorded irrespective of the presence or absence of any renal lesion.

Hyperplastic nodule(s): If the hyperplastic focus or foci was/were nodular in form, it was/they were called hyperplastic nodule(s). In liver, these nodules can also be pedunculated.

Adrenals: The cortical lesions were well circumscribed (1) focal hyperplasia showing eosinophilic cytoplasm with mostly small-size cells without pressure on the surrounding tissue; (2) if focally circumscribed hyperplasia exerted pressure and/or also effected capsule fromation, it was diagnosed as adenoma.

BAYER AG

Liver : If focus/foci of hepatic cells showed hyperplasia without any other structural change, this was called focal hyperplasia. The hyperplastic nodule(s) was/were nodular in form, contained normal liver parenchyma, and maintained the normal lobular architecture with central vein and portal areas.

If a single nodule in liver was present, it is printed under 'Hyperplastic nodule' in Tables 7-12; if there were several nodules in the liver, they have been printed under 'Hyperplastic nodules'. This is due to the two separate code numbers which are given to the data bank for 'nodule' and 'nodules'.

The differentiation between hepatic adenoma and hepatocellular carcinoma was based on cell cytology as described in Mouse Hepatic Neoplasia (edited by Butler and Newberne, 1975, Elsevier, London).

The hepatic adenoma(s) showed compression, capsule formation and the absence of portal triads.

Histological Evaluation

For histological evaluation of the data, each group was subdivided under the headings "Systematic" and "Non-Systematic" studies.

In each group the "Systematic Study" consisted of those animals which were sacrificed at the end of the experimental period (105 weeks), while the "Non-Systematic Study" consisted of those animals which died spontaneously or those killed in extremis during the study.

The computer printouts of the pathological data on individual animals are given on pages 64 to 560. The lesions observed are given in computer-summarized tables on pages 01 to 63. Tables giving group incidence of neoplastic and non-neoplastic lesions were also made by combining the incidences in the "Systematic" and "Non-Systematic" studies of each group. The list of animals bearing only tumours is on pages 561 to 658.

As regards the data on individual animals, only those organs have been described which showed a lesion when histologically examined. However, sometimes an organ showing a lesion at autopsy was found to be normal at histological examination; these organs are specifically listed as normal, both in the individual data as well as in the tables.

BAYER AG

The individual observations revealed a great number of lesions of senile origin, which are commonly observed in the ageing mice of this strain and were more or less evenly distributed among treated and control groups.

The following comments are made in summary:

A. Neoplastic Lesions

- If found in any organ, leukemic deposits and metastasis were not considered primary tumours and therefore an animal having them was not considered a multiple tumour bearer. If an animal had two tumours in different organs it was counted as multiple tumour bearer. An animal bearing one or more tumours in the same organ was counted as single tumour bearer. Animals bearing the same type of lymphoma in two different organs were considered single tumour bearers, since we consider lymphoma a single tumour of the lymphoreticular system.

- The incidence of single, multiple and total tumour bearers has been summarized in Table I for "Systematic" and "Non-Systematic Studies". In the "Systematic Study" the female group III showed a higher incidence of single tumour bearers. This higher incidence was not attributable to a single tumour type of a particular organ, but to the fact that various animals had diverse types of single tumours normally found in a given population of mice (single tumours of the lung in females 378, 383, 384, 391; liver in females 367, 375, 377; pheochromocytoma in female 398; and uterine tumour in females 357, 360, 388). On the other hand, in the "Non-systematic Study" **or in the** treatment group as a whole (group incidence), the incidence of single, multiple and total

tumour bearers in both the sexes was comparable to that in the controls; it is therefore considered that there was no evidence of tumorigenic potential after dietary administration of KWG 0519 to mice for 105 weeks.

- The incidence of malignant, non-malignant and both types of tumour bearers is given in Table II. Some animals which had both, a malignant and a non-malignant tumour, were classified in this table for 'both' types of tumours in question . In the "Non-systematic Study" a higher incidence of malignant tumour bearers is present in the male and female control groups, especially when compared to group III in the respective sexes.

  In the female control group, the group incidence for malignant tumours is higher and the group incidence for non-malignant tumours is lower in comparison to group III only. This data given in Table II therefore does not indicate a tumorigenic potential of KWG 0519 for the induction of either malignant or non-malignant tumours in mice after 105 weeks of dietary administration.

- The incidence of lymphoma per organ is given in Tables 1-6. It is not always possible to determine the primary site of lymphoma in mice since it spreads to other lymphoreticular organs. It is therefore more reasonable to analyse the incidence of each type of lymphoma per animal rather than per organ since an animal bearing the same type of lymphoma in two different organs is considered as a single tumour bearer. Table III shows the incidence of lymphoma-bearing animals. From the data presented in Table III it

can be seen that the incidence of any type of lymphoma was comparable across the groups. In fact, in the male control group in the Non-systematic Study the incidence of lymphocytic lymphoma was slightly higher than in the treatment male groups.

- All other neoplasms summarized in Table 1-6 do not indicate a treatment-related effect either for incidence, or for a tumour type new to this strain of mice.

B. Non-Neoplastic Lesions

- In the female group III a marginal increase in the group incidence of liver hyperplastic nodule(s) is possibly a treatment-related effect (Table IV). In male groups the incidence of liver nodule(s) is comparable but on combining the incidence of nodule(s) and hyperplasia, a marginal increase in the incidence (15) in the male group III can be seen in comparison to the incidence (10) in the male control group.

- There was an evident increase in the incidence of cystic thyroids in the male group III (Table IV). This lesion was characterized by the presence of cystic changes in the follicles or in some cases by coalescence of one or two follicles which had also undergone cystic changes.

- A slightly higher incidence of spermatocoele formation in the male group III and cystic endometrial hyperplasia in the uterus of the female groups I and III is considered an old age related chance finding in this population of mice because there is no evidence of dose related effect.

- All other lesions summarized in Tables 7-12 are those which are normally seen in this strain of mice of this age.

BAYER AG

TABLE I

CHRONIC TOXICITY STUDY IN MICE WITH KNG 0519

INCIDENCE OF TUMOR BEARERS

	MALES				FEMALES			
GROUP	CONTROL	I	II	III	CONTROL	I	II	III
SYSTEMATIC STUDY N =	11	11	13	17	16	16	17	19
SINGLE TUMOR BEARERS	4	7	9	8	2	5	7	11
MULTIPLE TUMOR BEARERS	3	2	1	5	5	4	2	1
TOTAL TUMOR BEARERS	7	9	10	13	7	9	9	12
NONSYSTEMATIC STUDY N =	39	39	36	33	33	33	33	30
SINGLE TUMOR BEARERS	18	18	11	14	20	21	16	14
MULTIPLE TUMOR BEARERS	11	4	4	5	5	2	13	9
TOTAL TUMOR BEARERS	29	22	15	19	25	23	29	23
GROUP INCIDENCE N =	50	50	49	50	49	49	50	49
SINGLE TUMOR BEARERS	22	25	20	22	22	26	23	25
MULTIPLE TUMOR BEARERS	14	6	5	10	10	6	15	10
TOTAL TUMOR BEARERS	36	31	25	32	32	32	38	35

BAYER AG

TABLE II. Incidence of Malignant, Non-malignant or Both Types of Tumour Bearers

Sex	Males				Females			
Group	C	I	II	III	C	I	II	III
Systematic N	11	11	13	17	16	16	17	19
maliganant	2	5	3	5	4	6	5	6
non-malignant	2	2	6	4	0	2	2	5
both	3	2	1	4	3	1	2	1
Non-Systematic N	39	39	36	33	33	33	33	30
malignant	22	13	9	15	25	21	22	14
non-malignant	2	7	3	3	0	2	3	3
both	5	2	3	1	0	0	4	6
Group-Incidence N	50	50	49	50	49	49	50	49
malignant	24	18	12	20	29	27	27	20
non-malignant	4	9	9	7	0	4	5	8
both	8	4	4	5	3	1	6	7

BAYER AG

TABLE III. Incidence of Lymphoma Bearing Animals

Sex	Males				Females			
Group	C	I	II	III	C	I	II	III
Systematic N	11	11	13	17	16	16	17	19
lymphocytic	0	0	1	2	1	3	2	0
granulocytic	0	0	0	0	0	0	0	0
stem cell	0	0	0	0	0	0	0	0
Non-systematic N	39	39	36	33	33	33	33	30
unclassified	0	0	0	1	0	0	0	0
thymoma	0	0	0	0	0	0	1	0
lymphocytic	11	5	5	5	11	14	18	17
granulocytic	0	0	0	1	3	0	1	0
stem cell	6	1	0	2	3	0	2	1
Group Incidence N	50	50	49	50	49	49	50	49
unclassified	0	0	0	1	0	0	0	0
thymoma	0	0	0	0	0	0	1	0
lymphocytic	11	5	6	7	12	17	20	17
granulocytic	0	0	0	1	3	0	1	0
stem cell	6	1	0	2	3	0	2	1
lymphoma any type/group	17	6	6	11 §	18	17	23 +	18

+ thymoma excluded being epithelial tumour

§ including unclassified

TABLE IV. Group Incidence of Certain Lesions in Liver, Thyroids, Testes and Uterus.

Sex		Males				Females			
Group		C	I	II	III	C	I	II	III
Liver	N	50	50	49	50	48	49	50	49
nodule(s)		8	6	9	10	2	1	1	7
hyperplasia		2	0	0	5	0	0	0	0
Thyroids	N	28	24	34	39	37	36	31	35
cysts		2	2	2	10	3	3	1	3
Testes	N	49	50	48	50				
spermatocoele		4	4	1	11				
Uterus	N					35	38	33	42
cystic endometrial hyperplasia						5	14	7	11

APPENDIX I

SUMMARY TABLES

BAYER AG BAYER AG BAYER AG BAYER AG

SMT. 1

CHRONIC TOXICITY STUDY IN MICE: SYSTEMATIC HISTOPATOLOGY

PRODUCT : KAG 0519
ROUTE : DIETARY

TIME : 105 WEEKS

FREQUENCY OF ALTERATIONS

TABLE 1 TUMOROUS LESIONS SYSTEMATIC - MALES

GROUP		CONTROL	I	II	III
DOSE IN PPM		0	125	500	2000
EXAMINED		11	11	13	17
BRAIN	EXAMINED	10	11	13	17
HEART	EXAMINED	11	11	13	17
LUNG	EXAMINED	11	11	13	17
ALVEOLOGENIC CARCINOMA :		5	7	3	6
STOMACH	EXAMINED	10	11	13	17
LIVER	EXAMINED	11	11	13	17
ADENOMA HEPATIC BENIGN :		2	1	2	5
PANCREAS	EXAMINED	9	11	12	17
ISLET CELL ADENOMA :		0	0	1	0
SPLEEN	EXAMINED	11	11	13	17
LYMPHOMA LYMPHOCYTIC :		0	0	0	2
BONE MARROW	EXAMINED	0	0	1	0
KIDNEYS	EXAMINED	11	11	13	17
BLADDER	EXAMINED	10	11	13	17
CARCINOSARCOMA :		0	0	0	1
PITUITARY	EXAMINED	9	6	10	10
THYROIDS	EXAMINED	5	2	10	13
ADRENALS	EXAMINED	7	10	13	16
ADENOMA :		3	2	2	3
PHEOCHROMOCYTOMA :		0	1	0	1
SKELETAL MUSCLE	EXAMINED	11	11	13	17
SCIATIC NERVE	EXAMINED	10	11	10	16

SNT. 2

MESENTERY	EXAMINED	1	0	1	0
TESTES	EXAMINED	11	11	12	17
INTERSTITIAL CELL TUMOR :		0	1	1	0
SEMINAL VESICLES	EXAMINED	2	1	1	1
FAT	EXAMINED	1	0	0	0
LIPOMA :		1	0	0	0
INTESTINE	EXAMINED	0	0	1	0
FEMUR	EXAMINED	10	11	13	16
OSTEOMA :		0	0	1	0
LYMPH NODE	EXAMINED	0	1	1	0
LYMPHOMA LYMPHOCYTIC :		0	0	1	0

BAYER AG BAYER AG BAYER AG BAYER AG

NMT. 1

CHRONIC TOXICITY STUDY IN MICE: NONSYSTEMATIC HISTOPATOLOGY

PRODUCT : KMG 0519
ROUTE : DIETARY

TIME : 105 WEEKS

FREQUENCY OF ALTERATIONS

TABLE 2 TUMOROUS LESIONS NONSYSTEMATIC - MALES

GROUP		CONTROL	I	II	III
DOSE IN PPM		0	125	500	2000
EXAMINED		39	39	36	33
BRAIN	EXAMINED	34	30	29	26
HEART	EXAMINED	39	39	36	33
METASTASIS :		0	1	0	0
TRACHEA	EXAMINED	1	0	0	0
LUNG	EXAMINED	38	39	36	32
FIBROMA :		0	0	0	1
ALVEOLOGENIC CARCINOMA :		15	10	7	8
SALIVARY GLAND	EXAMINED	0	2	1	0
STOMACH	EXAMINED	38	39	35	33
LIVER	EXAMINED	39	39	36	33
ADENOMA HEPATIC BENIGN :		3	3	3	3
ADENOCARCINOMA :		2	0	0	1
METASTASIS :		1	0	0	0
CYSTADENOMA :		1	0	0	0
PANCREAS	EXAMINED	37	36	32	33
ISLET CELL ADENOMA :		1	0	0	0
THYMUS	EXAMINED	3	1	1	2
LYMPHOMA LYMPHOCYTIC :		3	1	1	2
SPLEEN	EXAMINED	39	39	36	33
LYMPHOMA STEM CELLS :		5	1	0	2
LYMPHOMA LYMPHOCYTIC :		9	3	4	4
LYMPHOMA GRANULOCYTIC :		0	0	0	1

NMT. 2

BONE MARROW	EXAMINED	1	0	0	1
KIDNEYS	EXAMINED	39	39	36	33
METASTASIS :		0	1	0	0
BLADDER	EXAMINED	36	39	35	33
CARCINOSARCOMA :		0	0	0	1
PITUITARY	EXAMINED	20	23	19	12
THYROIDS	EXAMINED	23	22	26	26
ADENOMA :		0	1	0	0
ADRENALS	EXAMINED	39	38	34	31
ADENOMA :		0	4	1	0
PHEOCHROMOCYTOMA :		0	1	0	0
SKELETAL MUSCLE	EXAMINED	38	39	35	28
SKIN	EXAMINED	0	0	1	3
SQUAMOUS CELL CARCINOMA KERATI		0	0	0	1
SCIATIC NERVE	EXAMINED	35	34	28	26
BONE	EXAMINED	1	0	1	1
OSTEOMA :		1	0	1	1
MESENTERY	EXAMINED	4	2	0	2
FIBROMYXOMA :		1	0	0	0
TESTIS	EXAMINED	38	39	36	33
INTERSTITIAL CELL TUMOR :		1	0	1	0
PROSTATE	EXAMINED	0	0	1	0
SEMINAL VESICLES	EXAMINED	4	5	6	2
MESENCHYMAL TUMOR :		0	0	1	0
FAT	EXAMINED	0	2	0	0
LIPOMA :		0	1	0	0
PARATHYROIDS	EXAMINED	0	0	1	0
INTESTINE	EXAMINED	1	1	1	3
FEMUR	EXAMINED	35	38	34	28
OSTEOMA :		0	0	1	0

BAYER AG

UNIT: 3

06

LYMPH NODE	EXAMINED	8	2	1	2
LYMPHOMA STEM CELLS :		4	0	0	1
LYMPHOMA LYMPHOCYTIC :		3	2	0	1
UNKNOWN TISSUE OR ANY OT	EXAMINED	0	0	0	2
UNCLASSIFIED RCS :		0	0	0	1

INT. 1

CHRONIC TOXICITY STUDY IN MICE: GROUP INCIDENCE

HISTOPATOLOGY

PRODUCT : KWG 0519 TIME : 105 WEEKS
ROUTE : DIETARY

FREQUENCY OF ALTERATIONS

TABLE 3 TUMOROUS LESIONS
GROUP INCIDENCE - MALES

GROUP		CONTROL	I	II	III
DOSE IN PPM		0	125	500	2000
EXAMINED		50	50	49	50
BRAIN	EXAMINED	44	41	42	45
HEART	EXAMINED	50	50	49	50
METASTASIS :		0	1	0	0
TRACHEA	EXAMINED	1	0	0	0
LUNG	EXAMINED	49	50	49	49
FIBROMA :		0	0	0	1
ALVEOLOGENIC CARCINOMA :		20	17	10	14
SALIVARY GLAND	EXAMINED	0	2	1	0
STOMACH	EXAMINED	48	50	48	50
LIVER	EXAMINED	50	50	49	50
ADENOMA HEPATIC BENIGN :		5	4	5	8
ADENOCARCINOMA :		2	0	0	1
METASTASIS :		1	0	0	0
CYSTADENOMA :		1	0	0	0
PANCREAS	EXAMINED	46	47	44	50
ISLET CELL ADENOMA :		1	0	1	0
THYMUS	EXAMINED	3	1	1	2
LYMPHOMA LYMPHOCYTIC :		3	1	1	2
SPLEEN	EXAMINED	50	50	49	50
LYMPHOMA STEM CELLS :		5	1	0	2
LYMPHOMA LYMPHOCYTIC :		9	3	4	6
LYMPHOMA GRANULOCYTIC :		0	0	0	1

BAYER AG

IMT. 2

BONE MARROW	EXAMINED	1	0	1	1
KIDNEYS	EXAMINED	50	50	49	50
METASTASIS :		0	1	0	0
BLADDER	EXAMINED	46	50	48	50
CARCINOSARCOMA :		0	0	0	2
PITUITARY	EXAMINED	29	29	29	22
THYROIDS	EXAMINED	28	24	34	39
ADENOMA :		0	1	0	0
ADRENALS	EXAMINED	46	48	47	47
ADENOMA :		3	6	3	3
PHEOCHROMOCYTOMA :		0	2	0	1
SKELETAL MUSCLE	EXAMINED	49	50	48	45
SKIN	EXAMINED	0	0	1	3
SQUAMOUS CELL CARCINOMA KERATI		0	0	0	1
SCIATIC NERVE	EXAMINED	45	45	38	42
BONE	EXAMINED	1	0	1	1
OSTEOMA :		1	0	1	1
MESENTERY	EXAMINED	5	2	1	2
FIBROMYXOMA :		1	0	0	0
TESTES	EXAMINED	49	50	48	50
INTERSTITIAL CELL TUMOR :		1	1	2	0
PROSTATE	EXAMINED	0	0	1	0
SEMINAL VESICLES	EXAMINED	6	6	7	3
MESENCHYMAL TUMOR :		0	0	1	0
FAT	EXAMINED	1	2	0	0
LIPOMA :		1	1	0	0
PARATHYROIDS	EXAMINED	0	0	1	0
INTESTINE	EXAMINED	1	1	2	3
FEMUR	EXAMINED	45	49	47	44
OSTEOMA :		0	0	2	0

IM1. 3

LYMPH NODE	EXAMINED	8	3	2	2
LYMPHOMA STEM CELLS :		4	0	0	1
LYMPHOMA LYMPHOCYTIC :		3	2	1	1
UNKNOWN TISSUE OR ANY OT	EXAMINED	0	0	0	2
UNCLASSIFIED RCS :		0	0	0	

BAYER AG BAYER AG BAYER AG BAYER AG

SFT. 1

CHRONIC TOXICITY STUDY IN MICE: SYSTEMATIC HISTOPATOLOGY

PRODUCT : KWG 0519
ROUTE : DIETARY

TIME : 105 WEEKS

FREQUENCY OF ALTERATIONS

TABLE 4 TUMOROUS LESIONS SYSTEMATIC - FEMALES

GROUP		CONTROL	I	II	III
DOSE IN PPM		0	125	500	2000
EXAMINED		16	16	17	19
BRAIN	EXAMINED	16	16	17	19
HEART	EXAMINED	16	16	17	19
LUNG	EXAMINED	16	16	17	19
ALVEOLOGENIC CARCINOMA :		6	6	3	5
STOMACH	EXAMINED	16	16	17	18
LIVER	EXAMINED	16	16	17	19
ADENOMA HEPATIC BENIGN :		0	0	2	3
ANGIOSARCOMA :		0	0	1	0
PANCREAS	EXAMINED	15	16	17	19
THYMUS	EXAMINED	1	0	0	0
LYMPHOMA LYMPHOCYTIC :		1	0	0	0
SPLEEN	EXAMINED	16	16	17	19
LYMPHOMA LYMPHOCYTIC :		0	2	2	0
KIDNEYS	EXAMINED	16	16	17	19
BLADDER	EXAMINED	16	16	17	18
PAPILLOMA :		1	0	0	0
PITUITARY	EXAMINED	13	14	15	16
THYROIDS	EXAMINED	6	11	8	16
ADRENALS	EXAMINED	15	16	17	19
ADENOMA :		0	1	0	0
PHEOCHROMOCYTOMA :		0	0	0	1
SKELETAL MUSCLE	EXAMINED	15	16	17	19
METASTASIS :		0	1	0	0

SCIATIC NERVE	EXAMINED	13	16	14	14
BONE	EXAMINED	0	1	0	0
OSTEOMA :		0	1	0	0
MESENTERY	EXAMINED	4	2	2	1
MAMMARY GLAND	EXAMINED	2	0	0	0
ADENOCARCINOMA :		2	0	0	0
OVARIES	EXAMINED	16	16	16	19
LUTEOMA :		1	2	2	0
ARRHENOBLASTOMA :		0	0	0	1
CYSTADENOMA :		1	0	0	0
UTERUS	EXAMINED	11	16	14	18
ADENOMA :		0	0	0	1
LEIOMYOSARCOMA :		0	0	1	1
MESENCHYMAL TUMOR :		0	0	0	1
FEMUR	EXAMINED	15	16	17	18
LYMPH NODE	EXAMINED	0	1	1	0
LYMPHOMA LYMPHOCYTIC :		0	1	0	0
SUBCUTANEOUS TISSUE	EXAMINED	0	1	0	0
FIBROSARCOMA :		0	1	0	0

BAYER AG

NFT. 1 CHRONIC TOXICITY STUDY IN MICE: NONSYSTEMATIC HISTOPATOLOGY

PRODUCT : KNG 0519 TIME : 105 WEEKS
ROUTE : DIETARY

FREQUENCY OF ALTERATIONS

TABLE 5 TUMOROUS LESIONS NONSYSTEMATIC - FEMALES

GROUP		CONTROL	I	II	III
DOSE IN PPM		0	125	500	2000
EXAMINED		33	33	33	30
BRAIN	EXAMINED	32	28	28	29
HEART	EXAMINED	33	32	33	30
TRACHEA	EXAMINED	0	0	0	3
LUNG	EXAMINED	33	33	33	30
METASTASIS :		0	0	0	1
ALVEOLOGENIC CARCINOMA :		4	8	12	1
STOMACH	EXAMINED	33	33	33	30
DUODENUM	EXAMINED	1	1	1	0
LIVER	EXAMINED	32	33	33	30
ADENOMA HEPATIC BENIGN :		0	0	2	3
ADENOCARCINOMA :		1	0	1	0
PANCREAS	EXAMINED	33	33	31	29
THYMUS	EXAMINED	3	3	3	5
LYMPHOMA LYMPHOCYTIC :		3	3	2	5
THYMOMA :		0	0	1	0
SPLEEN	EXAMINED	33	33	33	29
LYMPHOMA STEM CELLS :		3	0	2	1
LYMPHOMA LYMPHOCYTIC :		7	8	13	15
LYMPHOMA GRANULOCYTIC :		3	0	1	0
KIDNEYS	EXAMINED	33	33	33	30
BLADDER	EXAMINED	33	33	32	30
PITUITARY	EXAMINED	23	26	20	21
ADENOMA :		0	0	1	0

THYROIDS	EXAMINED	31	25	23	19
ADRENALS	EXAMINED	33	33	32	28
ADENOMA :		0	1	0	2
SKELETAL MUSCLE	EXAMINED	32	31	31	27
METASTASIS :		0	0	0	0
SKIN	EXAMINED	0	0	2	1
SCIATIC NERVE	EXAMINED	30	28	29	24
BONE	EXAMINED	0	0	3	1
OSTEOMA :		0	0	2	1
MESENTERY	EXAMINED	12	8	11	4
METASTASIS :		2	0	0	0
MAMMARY GLAND	EXAMINED	0	1	0	0
OVARIES	EXAMINED	32	32	32	27
METASTASIS :		1	0	0	0
LUTEOMA :		0	0	1	2
UTERUS	EXAMINED	24	22	19	24
ADENOCARCINOMA :		1	0	0	0
HISTIOCYTIC SARCOMA :		1	0	0	0
LEIOMYOSARCOMA :		3	1	0	1
MESENCHYMAL TUMOR :		1	0	1	0
CEREBRUM	EXAMINED	0	1	0	0
CERVICAL LYMPH NODE	EXAMINED	1	0	0	1
FAR	EXAMINED	0	1	0	0
DIAPHRAGM	EXAMINED	0	0	2	0
LEIOMYOSARCOMA :		0	0	1	0
INTESTINE	EXAMINED	0	1	0	2
RIGHT HIND EXTREMITY	EXAMINED	0	0	0	1
METASTASIS :		0	0	0	1
FEMUR	EXAMINED	33	31	32	28
OSTEOGENIC SARCOMA :		1	0	1	2
OSTEOMA :		0	0	1	0

BAYER AG

SKULL	EXAMINED	1	0	0	1
METASTASIS :		1	0	0	0
OSTEOMA :		0	0	0	1
CERVIX	EXAMINED	1	1	0	1
KERATOACANTHOMA :		0	1	0	0
LEIOMYOSARCOMA :		1	0	0	1
BODY CAVITY	EXAMINED	0	0	0	1
METASTASIS :		0	0	0	1
LYMPH NODE	EXAMINED	8	4	12	3
LYMPHOMA STEM CELLS :		1	0	0	0
LYMPHOMA LYMPHOCYTIC :		6	4	11	3
ABDOMINAL CAVITY	EXAMINED	0	1	0	0
BODY WALL	EXAMINED	1	0	0	0
MESENCHYMAL TUMOR :		1	0	0	0

IFT. 1 CHRONIC TOXICITY STUDY IN MICE: GROUP INCIDENCE

HISTOPATOLOGY

PRODUCT : KWG 0519 TIME : 105 WEEKS
ROUTE : DIETARY

FREQUENCY OF ALTERATIONS

TABLE 6 TUMOROUS LESIONS
GROUP INCIDENCE - FEMALES

GROUP		CONTROL	I	II	III
DOSE IN PPM		0	125	500	2000
EXAMINED		49	49	50	49
BRAIN	EXAMINED	48	44	45	48
HEART	EXAMINED	49	48	50	49
TRACHEA	EXAMINED	0	0	0	3
LUNG	EXAMINED	49	49	50	49
METASTASIS :		0	0	0	1
ALVEOLOGENIC CARCINOMA :		10	14	15	6
STOMACH	EXAMINED	49	49	50	48
DUODENUM	EXAMINED	1	1	1	0
LIVER	EXAMINED	48	49	50	49
ADENOMA HEPATIC BENIGN :		0	0	4	6
ADENOCARCINOMA :		1	0	1	0
ANGIOSARCOMA :		0	0	1	0
PANCREAS	EXAMINED	48	49	48	48
THYMUS	EXAMINED	4	3	3	5
LYMPHOMA LYMPHOCYTIC :		4	3	2	5
THYMOMA :		0	0	1	0
SPLEEN	EXAMINED	49	49	50	48
LYMPHOMA STEM CELLS :		3	0	2	1
LYMPHOMA LYMPHOCYTIC :		7	10	15	15
LYMPHOMA GRANULOCYTIC :		3.	0	1	0
KIDNEYS	EXAMINED	49	49	50	49
BLADDER	EXAMINED	49	49	49	48
PAPILLOMA :		1	0	0	0

PITUITARY	EXAMINED	36	40	35	37
ADENOMA :		0	0	1	0
THYROIDS	EXAMINED	37	36	31	35
ADRENALS	EXAMINED	48	49	49	47
ADENOMA :		0	2	0	2
PHEOCHROMOCYTOMA :		0	0	0	1
SKELETAL MUSCLE	EXAMINED	47	47	48	46
METASTASIS :		0	1	0	1
SKIN	EXAMINED	0	0	2	1
SCIATIC NERVE	EXAMINED	43	44	42	38
BONE	EXAMINED	0	1	3	1
OSTEOMA :		0	1	2	1
MESENTERY	EXAMINED	16	10	13	5
METASTASIS :		2	0	0	0
MAMMARY GLAND	EXAMINED	2	1	0	0
ADENOCARCINOMA :		2	0	0	0
OVARIES	EXAMINED	48	48	49	46
METASTASIS :		1	0	0	0
LUTEOMA :		1	2	3	2
ARRHENOBLASTOMA :		0	0	0	1
CYSTADENOMA :		1	0	0	0
UTERUS	EXAMINED	35	38	33	42
ADENOCARCINOMA :		1	0	0	0
ADENOMA :		0	0	0	1
HISTIOCYTIC SARCOMA :		1	0	0	0
LEIOMYOSARCOMA :		3	1	1	2
MESENCHYMAL TUMOR :		1	0	1	1
CEREBRUM	EXAMINED	0	1	0	0
CERVICAL LYMPH NODE	EXAMINED	1	0	0	1
FAT	EXAMINED	0	1	0	0

IFT: 3

DIAPHRAGM	EXAMINED	0	0	2	0
LEIOMYOSARCOMA :		0	0	1	0
INTESTINE	EXAMINED	0	1	0	2
RIGHT HIND EXTREMITY	EXAMINED	0	0	0	1
METASTASIS :		0	0	0	1
FEMUR	EXAMINED	48	47	49	46
OSTEOGENIC SARCOMA :		1	0	1	2
OSTEOMA :		0	0	1	0
SKULL	EXAMINED	1	0	0	1
METASTASIS :		1	0	0	0
OSTEOMA :		0	0	0	1
CERVIX	EXAMINED	1	1	0	1
KERATOACANTHOMA :		0	1	0	0
LEIOMYOSARCOMA :		1	0	0	1
BODY CAVITY	EXAMINED	0	0	0	1
METASTASIS :		0	0	0	1
LYMPH NODE	EXAMINED	8	5	13	3
LYMPHOMA STEM CELLS :		1	0	0	0
LYMPHOMA LYMPHOCYTIC :		6	5	11	3
SUBCUTANEOUS TISSUE	EXAMINED	0	1	0	0
FIBROSARCOMA :		0	1	0	0
ABDOMINAL CAVITY	EXAMINED	0	1	0	0
BODY WALL	EXAMINED	1	0	0	0
MESENCHYMAL TUMOR :		1	0	0	0

BAYER AG

SHN. 1 CHRONIC TOXICITY STUDY IN MICE: SYSTEMATIC HISTOPATOLOGY

PRODUCT : KWG 0519 TIME : 105 WEEKS
ROUTE : DIETARY

FREQUENCY OF ALTERATIONS

TABLE 7 NONTUMOR. LESIONS SYSTEMATIC - MALES

GROUP		CONTROL	I	II	III
DOSE IN PPM		0	125	500	2000
EXAMINED		11	11	13	17
BRAIN.	EXAMINED	10	11	13	17
CALCIFICATION :		0	0	1	0
FAT VACUOLES :		0	0	1	0
GLIOSIS :		2	3	1	0
ABSENT :		1	0	0	0
HEART	EXAMINED	11	11	13	17
FIBROSIS :		3	0	0	0
INFLAMMATION CHRONIC :		3	0	0	1
LEUKEMIC DEPOSITS :		0	0	1	0
PERIARTERITIS :		0	1	0	0
VENTRICULAR DILATATION :		0	0	0	1
DEGENERATION MUSCULAR :		0	0	1	0
THICKENING ENDOCARDIUM :		1	0	0	0
LUNG	EXAMINED	11	11	13	17
HEMORRHAGE :		0	1	0	0
PNEUMONIA :		1	3	7	2
CONGESTION :		0	0	0	1
ATELECTASIS :		4	1	1	1
EMPHYSEMA :		0	1	1	0
MUCOID CYST :		0	0	0	1
LEUKEMIC DEPOSITS :		0	0	1	0
THICKENED ALVEOLAR WALLS :		0	0	2	0

SMN. 2

STOMACH	EXAMINED	10	11	13	17
INFLAMMATION CHRONIC :		2	1	2	0
PIGMENTATION :		0	0	0	1
ABSENT :		1	0	0	0
MUCOID CYST :		1	4	6	6
LIVER	EXAMINED	11	11	13	17
HYPERPLASIA :		0	0	0	3
INFARCT :		0	0	1	0
CALCIFICATION :		0	0	0	1
FAT VACUOLES :		0	2	3	0
HEMORRHAGE :		0	0	0	1
MONONUCLEAR CELLS :		1	0	0	3
PIGMENTATION :		1	0	0	0
HEMATOPOIESIS :		0	2	0	0
HYPERPLASTIC NODULE :		0	5	3	1
HYPERTROPHY :		0	0	1	1
VACUOLIZATION :		0	1	1	1
PERICHOLANGITIS		0	1	0	0
CYSTS :		0	0	0	1
LEUKEMIC DEPOSITS :		0	0	0	1
HYALINOSIS :		0	1	0	0
HEPATOCYTIC HYPERPIGMENTATION		0	0	0	3
HYPERPLASTIC NODULES :		4	0	0	4
HYPERPLASIA FOCAL :		0	0	0	1
NORMAL :		0	0	1	0
PANCREAS	EXAMINED	9	11	12	17
FIBROSIS :		0	0	0	1
INFLAMMATION CHRONIC :		0	1	0	1
ABSENT :		2	0	1	0
LEUKEMIC DEPOSITS :		0	0	1	0
FATTY CYST :		0	1	0	0
NORMAL :		2	1	2	4

BAYER AG BAYER AG BAYER AG

SMN. 3

SPLEEN	EXAMINED	11	11	13	17
FIBROSIS :		0	1	0	0
HYPERPLASIA LYMPHOID :		0	1	1	0
HEMORRHAGE :		0	1	0	0
PIGMENTATION :		0	0	0	1
HEMATOPOIESIS :		5	9	8	7
HYPERTROPHY :		0	0	1	0
NORMAL :		1	1	0	0
BONE MARROW	EXAMINED	0	0	1	0
APLASIA MYELOID :		0	0	1	0
KIDNEYS	EXAMINED	11	11	13	17
CALCIFICATION :		0	0	1	1
FIBROSIS :		0	3	0	0
HYDRONEPHROSIS :		0	1	0	2
CONGESTION :		0	1	0	0
TUBULOPATHY :		0	4	4	1
INTERSTITIAL NEPHRITIS :		9	3	5	10
CYSTS :		8	6	3	6
LEUKEMIC DEPOSITS :		0	0	1	2
ECTASIA VASCULAR :		0	1	0	0
DILATATION OF GLOMERULAR LOOPS		0	1	0	0
DILATATION OF RENAL PELVIS :		0	2	1	0
PROGRESSIVE NEPHROPATHY :		1	2	0	0
BLADDER	EXAMINED	10	11	13	17
HYPERPLASIA EPITHELIAL :		0	0	0	1
INFLAMMATION CHRONIC :		0	1	0	0
INFLAMMATION GRANULOMATOUS :		0	0	2	0
ABSENT :		1	0	0	0
COAGULUM :		0	0	0	1
LEUKEMIC DEPOSITS :		0	0	0	1
HYPERPLASIA PAPILLOMATOUS :		0	0	1	2
NORMAL :		0	1	0	0

PITUITARY	EXAMINED	9	6	10	10
UNREADABLE :		1	0	0	0
ABSENT :		2	5	3	7
CYSTS :		0	1	0	0
NORMAL :		0	0	1	0
THYROIDS	EXAMINED	5	2	10	13
ABSENT :		6	9	3	4
CYSTS :		0	0	0	5
NORMAL :		0	0	1	0
ADRENALS	EXAMINED	7	10	13	16
CALCIFICATION :		0	0	0	1
PIGMENTATION :		2	5	2	2
ABSENT :		4	1	0	1
LEUKEMIC DEPOSITS :		0	0	0	1
HYPERPLASIA OF THE GLOMERULAR		0	0	0	1
NORMAL :		0	0	1	0
SKELETAL MUSCLE	EXAMINED	11	11	13	17
ATROPHY :		0	1	0	0
VACUOLIZATION :		0	1	0	0
LEUKEMIC DEPOSITS :		0	0	1	0
SCIATIC NERVE	EXAMINED	10	11	10	16
ABSENT :		1	0	3	1
MESENTERY	EXAMINED	1	0	1	0
INFLAMMATION CHRONIC :		1	0	0	0
LEUKEMIC DEPOSITS :		0	0	1	0
TESTES	EXAMINED	11	11	12	17
ATROPHY SEMINIFEROUS :		3	5	5	3
AZOOSPERMIA :		0	0	1	0
CALCIFICATION :		4	0	1	7
INFLAMMATION CHRONIC :		0	1	0	0
PIGMENTATION :		1	0	0	0
SPERMATOCELE :		1	0	0	5
ABSENT :		0	0	1	0

BAYER AG

NORMAL :		0	1	0	0
SEMINAL VESICLES	EXAMINED	2	1	1	1
ATROPHY EPITHELIAL :		1	0	0	1
ECTASIA SIMPLE :		1	0	0	1
COAGULUM :		1	1	0	1
HEMORRAGIC CYST :		0	0	1	0
INFLAMMATION ACUTE GLANDULAR :		0	1	0	0
NORMAL :		1	0	0	0
FAT	EXAMINED	1	0	0	0
INTESTINE	EXAMINED	0	0	1	0
FEMUR	EXAMINED	10	11	13	16
ABSENT :		1	0	0	1
LYMPH NODE	EXAMINED	0	1	1	0
HYPERPLASIA LYMPHOID :		0	1	0	0

NMN. 1

CHRONIC TOXICITY STUDY IN MICE: NONSYSTEMATIC HISTOPATOLOGY

PRODUCT : KWG 0519 TIME : 105 WEEKS
ROUTE : DIETARY

FREQUENCY OF ALTERATIONS

TABLE 8 NONTUMOR. LESIONS NONSYSTEMATIC - MALES

GROUP		CONTROL	I	II	III
DOSE IN PPM		0	125	500	2000
EXAMINED		39	39	36	33
BRAIN	EXAMINED	34	30	29	28
AUTOLYSIS :		1	0	0	0
FAT VACUOLES :		0	4	4	0
GLIOSIS :		0	2	0	0
HEMORRHAGE :		0	0	0	1
HYDROCEPHALUS :		0	1	0	0
CONGESTION :		0	0	0	1
ABSENT :		5	9	7	5
VACUOLIZATION :		0	0	1	0
AUTOLYSIS PARTIAL :		4	0	0	3
MENINGITIS :		1	0	0	0
HEART	EXAMINED	39	39	36	33
AUTOLYSIS :		1	0	0	0
THROMBOSIS :		2	2	4	3
FAT VACUOLES :		0	0	1	0
FIBROSIS :		1	0	1	3
INFLAMMATION CHRONIC :		2	0	1	0
HEMORRHAGE :		1	0	0	0
MONONUCLEAR CELLS :		1	0	0	4
LEUKOCYTOSIS :		0	0	1	0
CONGESTION :		15	9	12	9
DILATED CHAMBER :		2	1	1	0
LEUKEMIC DEPOSITS :		2	1	1	1
AUTOLYSIS PARTIAL :		4	0	1	4
PERICARDITIS :		0	1	2	0

BAYER AG

TRACHEA	EXAMINED	1	0	0	0
LEUKEMIC DEPOSITS :		1	0	0	0
LUNG	EXAMINED	38	39	36	32
AUTOLYSIS :		2	0	2	0
THROMBOSIS :		0	0	2	0
EDEMA :		1	10	5	4
NECROSIS :		0	0	1	0
FIBROSIS :		0	0	1	0
BRONCHOPNEUMONIA :		0	1	2	0
HEMORRHAGE :		0	6	2	0
ADENOMATOSIS :		1	2	3	1
PLEURITIS :		1	0	0	0
PIGMENTATION :		1	0	0	0
PNEUMONIA :		9	11	17	3
LEUKOCYTOSIS :		0	0	1	0
CONGESTION :		5	12	16	12
ATELECTASIS :		2	2	0	1
EMPHYSEMA :		1	3	1	0
ABSENT :		1	0	0	1
LEUKEMIC DEPOSITS :		5	3	1	4
AUTOLYSIS PARTIAL :		4	3	3	6
ECTASIA VASCULAR :		0	1	1	0
THICKENED ALVEOLAR WALLS :		0	1	0	0
NORMAL :		0	2	0	0
SALIVARY GLAND	EXAMINED	0	2	1	0
CALCIFICATION :		0	1	0	0
INFLAMMATION CHRONIC :		0	0	1	0
NORMAL :		0	1	0	0
STOMACH	EXAMINED	38	39	35	33
AUTOLYSIS :		8	2	4	8
CALCIFICATION :		0	0	1	0
FIBROSIS :		0	0	1	0
INFLAMMATION CHRONIC :		0	0	1	0

INFLAMMATION CHRONIC :	2	1	0	0
HEMORRHAGE :	0	2	1	1
MONONUCLEAR CELLS :	1	0	0	2
UNREADABLE :	1	0	1	1
ABSENT :	1	0	1	1
CYSTS :	0	0	0	1
MUCOID CYST :	0	1	0	1
LEUKEMIC DEPOSITS :	4	1	1	0
AUTOLYSIS PARTIAL :	7	11	7	4
ECTASIA VASCULAR :	0	0	2	0
NORMAL :	1	3	3	3
LIVER EXAMINED	39	39	36	33
AUTOLYSIS :	4	2	1	3
INFARCT :	0	1	1	0
CALCIFICATION :	1	1	1	4
FAT VACUOLES :	0	5	1	0
NECROSIS :	2	0	0	1
FIBROSIS :	0	1	0	0
INFLAMMATION GRANULOMATOUS :	0	1	0	0
HEMORRHAGE :	0	3	1	2
MONONUCLEAR CELLS :	2	2	2	0
PIGMENTATION :	0	0	1	0
AMYLOID :	3	1	1	6
HEMATOPOIESIS :	0	1	0	0
CONGESTION :	3	4	6	4
HYPERPLASTIC NODULE :	1	0	4	2
VACUOLIZATION :	1	1	0	0
CYSTS :	0	1	0	0
LEUKEMIC DEPOSITS :	9	5	4	6
INFLAMMATION PORTAL :	0	0	0	1
AUTOLYSIS PARTIAL :	3	13	10	5
HYALINOSIS :	0	0	0	1
HEPATOCYTIC HYPERPIGMENTATION	4	0	0	6

BAYER AG BAYER AG BAYER AG

HEMORRAGIC CYST :		0	0	5	0
HYPERPLASTIC NODULES :		3	1	2	3
HYPERPLASIA FOCAL :		2	0	0	1
NORMAL :		2	2	2	1
PANCREAS	EXAMINED	37	36	32	33
AUTOLYSIS :		5	8	7	9
INFLAMMATION CHRONIC :		0	1	0	2
INFLAMMATION CHRONIC :		1	0	0	0
AMYLOID :		0	0	1	1
HYPERPLASIA ISLETS :		2	0	0	0
CONGESTION :		0	0	1	1
UNREADABLE :		2	0	0	0
ABSENT :		2	3	4	0
LEUKEMIC DEPOSITS :		4	2	0	2
AUTOLYSIS PARTIAL :		4	7	7	4
CYSTIC DYSPLASIA :		0	1	0	0
FATTY CYST :		0	2	0	0
THYMUS	EXAMINED	3	1	1	2
ABSENT :		1	1	0	0
AUTOLYSIS PARTIAL :		0	0	0	1
SPLEEN	EXAMINED	39	39	36	33
AUTOLYSIS :		2	5	7	3
EDEMA :		0	1	0	0
HYPERPLASIA LYMPHOID :		3	1	1	2
HEMORRHAGE :		1	1	0	0
PIGMENTATION :		3	0	0	2
AMYLOID :		0	0	1	1
HEMATOPOIESIS :		8	13	7	5
ATROPHY :		0	0	0	1
CONGESTION :		1	2	3	0
HYPERTROPHY :		0	0	0	1
AUTOLYSIS PARTIAL :		5	5	5	6
ECTASIA VASCULAR :		0	1	0	0

NMN. 5

HEMORRAGIC CYST :		1	0	0	0
HYPOPLASIA LYMPHOID :		0	0	0	1
NORMAL :		0	0	2	1
BONE MARROW	EXAMINED	1	0	0	1
HYPERPLASIA :		0	0	0	0
HYPERPLASIA MEGAKARYOCYTE :		1	0	0	0
KIDNEYS	EXAMINED	39	39	35	33
AUTOLYSIS :		2	0	2	2
CALCIFICATION :		2	1	2	2
NECROSIS :		0	1	0	0
FIBROSIS :		0	4	0	1
PYELITIS :		1	0	0	0
HYDRONEPHROSIS :		3	0	2	0
HEMORRHAGE :		1	0	0	0
AMYLOID :		0	0	0	2
CONGESTION :		2	1	3	3
TUBULOPATHY :		2	10	7	4
INTERSTITIAL NEPHRITIS :		17	7	4	12
CYSTS :		7	2	6	4
LEUKEMIC DEPOSITS :		9	2	1	5
PYELONEPHRITIS :		1	1	1	0
AUTOLYSIS PARTIAL :		4	9	10	6
DILATATION OF GLOMERULAR LOOPS		1	2	1	0
DILATATION OF RENAL PELVIS :		0	5	0	1
PROGRESSIVE NEPHROPATHY :		2	8	3	1
BLADDER	EXAMINED	36	39	35	33
HYPERPLASIA :		1	0	0	0
AUTOLYSIS :		8	2	5	8
NECROSIS :		0	0	0	2
INFLAMMATION CHRONIC :		1	0	2	1
HEMORRHAGE :		0	0	0	1
MONONUCLEAR CELLS :		0	0	0	2
ECTASIA SIMPLE :		0	4	0	1

BAYER AG

RMN. 6

HYPERTROPHY :		0	0	0	1
UNREADABLE :		0	0	0	2
ABSENT :		3	0	1	0
COAGULUM :		0	0	1	2
LEUKEMIC DEPOSITS :		5	2	0	1
AUTOLYSIS PARTIAL :		9	16	8	8
INFLAMMATION ACUTE GLANDULAR :		0	1	0	0
HYPERPLASIA PAPILLOMATOUS :		5	1	0	0
NORMAL :		0	1	2	0
PITUITARY	EXAMINED	20	23	19	12
AUTOLYSIS :		0	0	3	2
UNREADABLE :		1	0	0	2
ABSENT :		19	16	16	21
AUTOLYSIS PARTIAL :		2	1	0	0
NORMAL :		2	0	0	0
THYROIDS	EXAMINED	23	22	24	26
AUTOLYSIS :		1	1	2	3
ABSENT :		16	17	12	7
CYSTS :		2	2	2	5
LEUKEMIC DEPOSITS :		1	0	0	0
AUTOLYSIS PARTIAL :		2	6	7	4
ADRENALS	EXAMINED	39	38	34	31
AUTOLYSIS :		1	0	3	2
PIGMENT :		1	0	0	0
PIGMENTATION :		0	0	4	0
AMYLOID :		0	0	1	1
HYPERPLASTIC NODULE :		1	1	0	0
UNREADABLE :		1	0	0	1
ABSENT :		0	1	2	2
LEUKEMIC DEPOSITS :		5	0	0	2
AUTOLYSIS PARTIAL :		3	2	2	4
HEMORRAGIC CYST :		0	0	1	1
HYPERPLASIA OF THE GLOMERULAR		0	1	0	0

NORMAL :		0	1	0	1
SKELETAL MUSCLE	EXAMINED	38	39	35	28
AUTOLYSIS :		1	0	0	0
EDEMA :		0	0	0	1
CALCIFICATION :		0	1	0	0
MONONUCLEAR CELLS :		0	0	0	3
UNREADABLE :		1	0	0	0
ABSENT :		1	0	1	5
LEUKEMIC DEPOSITS :		3	0	0	1
AUTOLYSIS PARTIAL :		2	0	0	2
FATTY CYST :		0	0	2	0
SKIN	EXAMINED	0	0	1	3
NECROSIS :		0	0	0	1
INFLAMMATION CHRONIC :		0	0	1	1
MONONUCLEAR CELLS :		0	0	0	1
SCIATIC NERVE	EXAMINED	35	34	28	26
AUTOLYSIS :		1	0	0	0
UNREADABLE :		1	0	0	0
ABSENT :		4	5	7	6
LEUKEMIC DEPOSITS :		1	0	0	0
AUTOLYSIS PARTIAL :		2	0	0	1
BONE	EXAMINED	1	0	1	1
MESENTERY	EXAMINED	4	2	0	2
LEUKEMIC DEPOSITS :		3	2	0	2
TESTES	EXAMINED	38	39	36	33
ATROPHY SEMINIFEROUS :		6	3	1	2
AZOOSPERMIA :		0	0	1	0
AUTOLYSIS :		1	1	2	0
CALCIFICATION :		8	5	6	3
SPERMATOCELE :		3	4	1	6
ABSENT :		1	0	0	0
CYSTS :		0	0	1	0
LEUKEMIC DEPOSITS :		1	0	0	0

BAYER AG

AUTOLYSIS PARTIAL :		2	1	4	5
PROSTATE	EXAMINED	0	0	1	0
COAGULUM :		0	0	1	0
SEMINAL VESICLES	EXAMINED	4	5	6	2
ATROPHY EPITHELIAL :		4	0	0	2
CALCIFICATION :		0	1	0	0
HEMORRHAGE :		0	1	0	0
ECTASIA SIMPLE :		1	0	0	1
COAGULUM :		4	5	5	2
CYSTS :		0	0	1	0
AUTOLYSIS PARTIAL :		1	0	1	0
FAT	EXAMINED	0	2	0	0
LEUKEMIC DEPOSITS :		0	1	0	0
PARATHYROIDS	EXAMINED	0	0	1	0
INTESTINE	EXAMINED	1	1	1	3
AUTOLYSIS :		0	0	0	1
HEMORRHAGE :		0	0	0	1
AUTOLYSIS PARTIAL :		0	0	0	1
NORMAL :		1	1	0	1
FEMUR	EXAMINED	35	38	34	28
ABSENT :		3	1	0	4
AUTOLYSIS PARTIAL :		0	0	0	2
LYMPH NODE	EXAMINED	8	2	1	2
INFARCT :		0	1	0	0
HYPERPLASIA LYMPHOID :		1	0	0	0
AUTOLYSIS PARTIAL :		1	0	0	0
UNKNOWN TISSUE OR ANY OT	EXAMINED	0	0	0	2
UNREADABLE :		0	0	0	1
AUTOLYSIS PARTIAL :		0	0	0	1

INN. 1

CHRONIC TOXICITY STUDY IN MICE: GROUP INCIDENCE

HISTOPATOLOGY

PRODUCT : KWG 0519
ROUTE : DIETARY

TIME : 105 WEEKS

FREQUENCY OF ALTERATIONS

TABLE 9 NONTUMOR. LESIONS
GROUP INCIDENCE - MALES

GROUP		CONTROL	I	II	III
DOSE IN PPM		0	125	500	2000
EXAMINED		50	50	49	50
BRAIN	EXAMINED	44	41	42	45
AUTOLYSIS :		1	0	0	0
CALCIFICATION :		0	0	1	0
FAT VACUOLES :		0	4	5	0
GLIOSIS :		2	5	1	0
HEMORRHAGE :		0	0	0	1
HYDROCEPHALUS :		0	1	0	0
CONGESTION :		0	0	0	1
ABSENT :		6	9	7	5
VACUOLIZATION :		0	0	1	0
AUTOLYSIS PARTIAL :		4	0	0	3
MENINGITIS :		1	0	0	0
HEART	EXAMINED	50	50	49	50
AUTOLYSIS :		1	0	0	0
THROMBOSIS :		2	2	4	3
FAT VACUOLES :		0	0	1	0
FIBROSIS :		4	0	1	3
INFLAMMATION CHRONIC :		5	0	1	1
HEMORRHAGE :		1	0	0	0
MONONUCLEAR CELLS :		1	0	0	4
LEUKOCYTOSIS :		0	0	1	0
CONGESTION :		15	9	12	9
DILATED CHAMBER :		2	1	1	0
LEUKEMIC DEPOSITS :		2	1	2	1
AUTOLYSIS PARTIAL :		4	0	1	4

BAYER AG

577

"Contains NO CBI"

PAGE NO(S) _____

ADDITIONS OR CORRECTIONS

FOR NUMBERED REPORTS

REPORT NUMBER (8229I) HAS BEEN:

____ REVISED _____ PROOFED _____

✓ ADDENDUM ADDED I PROOFED _____

____ VOIDED (SAME AS: _____)

REASON FOR REVISION: additional histopathology data on liver

REASON FOR ADDING ADDENDUM: _____

OTHER: _____

FROM: S. R. Ryan

DATE: 7/28/87

RF #F-37 (2-20-87)
Supersedes: (8-23-77)

SUPPLEMENTAL SUBMISSION TO

EPA ACCESSION NUMBER 071467

"Contains NO CBI"

Study Title

KWG 0519
(Triadimenol, Baytan® active ingredient)

CHRONIC TOXICOLOGICAL STUDY ON MICE

(Feeding experiment over two years)

Data Requirement

Guideline 83-2

Author

Dr. E. Bomhard

Study Completion Date

April 29, 1982

S U P P L E M E N T A L S U B M I S S I O N

Performing Laboratory

BAYER AG
Institute of Toxicology
Wuppertal
Germany

Report No.: 10855

Laboratory Project ID

Report No. 82291

STATEMENT OF NO DATA CONFIDENTIALITY CLAIMS

No claim of confidentiality is made for any information contained in this study on the basis of its falling within the scope of FIFRA Section 10(d)(1)(A), (B), or (C).

Company MOBAY CORPORATION

Company Agent: Dr. J.H. Thyssen

Date: 7-29-87

Manager Corporate Toxicology
Title

J. H. Thyssen
Signature

GOOD LABORATORY PRACTICE STATEMENT

This study meets the requirements for 40 CFR Part 160

Submitter MOBAY CORPORATION

Sponsor AGRICULTURAL CHEMICALS DIVISION

Study Director for the Hurley director J. H. Thyssen

Study: KWG 0519 male mice

Dose: 0 ppm

Animal No.	Status	Liver diagnosis *
1	D	within normal limits
2	KM	within normal limits
3	D	necrosis hepatocytic hyperpigmentation hyperplastic nodule
4	D	hyperplastic nodule
5	FS	hyperplastic nodules: multifocal
6	KM	amyloid: severe and multifocal hyperplastic nodule
7	D	hyperplastic nodule hyperplasia focal
8	D	autolysis
9	D	within normal limits
10	KM	within normal limits
11	D	mononuclear cells: minimal and multifocal
12	D	leukemic deposits
13	FS	pigmentation
14	D	autolysis
15	D	necrosis: multifocal congestion
16	FS	adenoma hepatic benign hyperplastic nodules: multifocal
17	D	within normal limits
18	D	within normal limits
19	FS	within normal limits
20	D	within normal limits

*

KM = killed; D = died; FS = final sacrifice

21	D	leukemic deposits
22	FS	within normal limits
23	D	within normal limits
24	FS	within normal limits
25	D	adenoma hepatic benign metastasis of a malignant tumor
26	FS	within normal limits
27	FS	adenoma hepatic benign mononuclear cells: moderate amyloid: multifocal
28	D	within normal limits
29	D	congestion hepatocytic hyperpigmentation
30	D	leukemic deposits
31	FS	hyperplastic nodules: multifocal
32	D	within normal limits
33	FS	adenoma hepatic benign mononuclear cells hyperplastic nodules: multifocal
34	KM	calcification: severe and multifocal adenocarcinoma vacuolization hepatocytic hyperpigmentation
35	FS	within normal limits
36	D	adenocarcinoma autolysis partial
37	D	autolysis
38	D	leukemic deposits
39	D	autolysis partial within normal limits
40	FS	within normal limits
41	D	congestion: severe
42	D	leukemic deposits
43	KM	leukemic deposits
44	D	leukemic deposits cystadenoma autolysis partial

45	D	within normal limits
46	D	within normal limits
47	D	amyloid: multifocal leukemic deposits hyperplasia focal
48	D	leukemic deposits
49	D	adenoma hepatic benign leukemic deposits
50	D	autolysis

Study: KWG 0519 female mice

Dose: 0 ppm

Animal No.	Status	Liver diagnosis
51	FS	mononuclear cells: minimal and focal hepatocytic hyperpigmentation: minimal and focal
52	FS	mononuclear cells: minimal and focal hyperplastic nodule
53	D	leukemic deposits
54	D	congestion
55	FS	vacuolisation
56	D	leukemic deposits autolysis partial
57	FS	hypertrophy
58	D	hyperplastic nodule autolysis partial
59	D	hematopoiesis: severe congestion autolysis partial
60	D	infarct: multifocal adenocarcinoma congestion hemorrhagic cyst
61	KM	absent: no slide available
62	D	mononuclear cells: minimal and focal congestion hepatocytic hyperpigmentation: minimal and multifocal
63	KM	within normal limits
64	KM	leukemic deposits
65	D	not fixed due to autolysis
66	FS	fat vacuoles cysts
67	D	leukemic deposits autolysis partial

68	D	within normal limits
69	D	congestion
70	D	congestion: severe
71	D	mononuclear cells: minimal and multifocal
72	D	leukemic deposits
73	KM	within normal limits
74	FS	fat vacuoles mononuclear cells
75	D	autolysis
76	FS	vacuolization hepatocytic hyperpigmentation: minimal
77	D	autolysis
78	FS	mononuclear cells: minimal and focal vacuolization
79	D	leukemic deposits
80	D	leukemic deposits
81	FS	fat vacuoles: minimal
82	FS	within normal limits
83	FS	fat vacuoles: minimal
84	FS	fat vacuoles: minimal hepatocytic hyperpigmentation: minimal
85	D	congestion
86	KM	within normal limits
87	D	leukemic deposits autolysis partial
88	D	calcification: multifocal congestion
89	FS	vacuolization: minimal
90	D	autolysis
91	D	congestion
92	FS	vacuolization
93	D	mononuclear cells: autolysis partial

94	KM	leukemic deposits
95	D	congestion
96	FS	mononuclear cells: minimal and multifocal vacuolization hepatocytic hyperpigmentation: minimal
97	D	leukemic deposits
98	D	autolysis
99	KM	mononuclear cells: minimal and multifocal
100	FS	fat vacuoles: minimal mononuclear cells: minimal

Study: KWG 0519 male mice

Dose : 125 ppm

Animal No.	Status	Liver diagnosis	
101	D	within normal limits autolysis partial	
102	D	fat vacuoles: severe fibrosis: severe adenoma hepatic benign	
103	D	fat vacuoles: minimal and multifocal	
104	D	calcification fat vacuoles autolysis partial hyperplastic nodules: multifocal	
105	KM	~~adenoma hepatic: multifocal~~ hemorrhage: severe congestion: severe	Change to: "Adenoma hepatic benign: multifocal"
106	D	leukemic deposits	
107	FS	within normal limits	
108	D	within normal limits	
109	D	within normal limits autolysis partial	
110	FS	hyperplastic nodule	
111	D	within normal limits	
112	D	mononuclear cells: minimal and focal	
113	D	within normal limits	
114	D	within normal limits	
115	D	within normal limits autolysis partial	
116	D	amyloid: multifocal leukemic deposits	
117	FS	within normal limits	
118	D	congestion	
119	FS	hematopoiesis: severe	
120	D	congestion	

121	KM	within normal limits
122	D	cysts: moderate and multifocal autolysis partial
123	FS	fat vacuoles: severe hyperplastic nodule pericholangitis: moderate and multifocal
124	D	within normal limits autolysis partial
125	D	adenoma hepatic benign: multifocal autolysis partial
126	D	inflammation granulomatous: moderate and multifocal hematopoiesis: severe and multifocal
127	FS	vacuolization: miminal and multifocal
128	FS	within normal limits
129	D	congestion
130	D	leukemic deposits autolysis partial
131	D	fat vacuoles: severe leukemic deposits
132	D	fat vacuoles: minimal and multifocal
133	KM	infarct: severe leukemic deposits
134	D	within normal limits autolysis partial
135	D	within normal limits
136	KM	vacuolizataion: minimal and multifocal
137	D	hemorrhage: severe and multifocal mononuclear cells: severe and multifocal
138	D	within normal limits autolysis partial
139	D	within normal limits autolysis partial
140	D	within normal limits autolysis partial
141	FS	hyperplastic nodule hyalinosis: moderate
142	FS	hyperplastic nodule

143	D	autolysis
144	D	within normal limits
145	D	within normal limits autolysis partial
146	D	within normal limits
147	D	within normal limits
148	FS	hematopoiesis: moderate
149	FS	fat vacuoles: severe adenoma hepatic benign hyperplastic nodule
150	D	autolysis

Study: KWG 0519 female mice

Dose: 125 ppm

Animal No.	Status	Liver diagnosis
151	D	hemorrhage congestion autolysis partial
152	D	within normal limits
153	D	within normal limits autolysis partial
154	D	within normal limits
155	D	congestion
156	D	within normal limits autolysis partial
157	KM	mononuclear cells: minimal and multifocal vacuolization: minimal
158	FS	within normal limits
159	D	autolysis
160	D	congestion leukemic deposits autolysis partial
161	FS	mononuclear cells: minimal and focal
162	D	leukemic deposits
163	FS	within normal limits
164	FS	within normal limits
165	D	within normal limits autolysis partial
166	D	leukemic deposits
167	KM	within normal limits
168	FS	mononuclear: minimal and multifocal vacuolization: minimal
169	D	within normal limits
170	FS	within normal limits

171	FS	leukemic deposits
172	D	within normal limits
173	D	hypertrophy leukemic deposits
174	D	autolysis
175	KM	amyloid: multifocal
176	D	autolysis
177	FS	within normal limits
178	FS	within normal limits
179	FS	mononuclear cells: minimal and multifocal
180	KM	hyperplastic nodule
181	D	vacuolization: minimal
182	D	within normal limits autolysis partial
183	D	leukemic deposits
184	KM	congestion
185	KM	within normal limits
186	FS	mononuclear cells: minimal and multifocal
187	KM	within normal limits
188	FS	within normal limits erraneously enumerated as No. 181 on pages 383/384
189	D	congestion
190	KM	within normal limits
191	KM	leukemic deposits
192	D	mononuclear cells: minimal and multifocal
193	D	congestion
194	FS	within normal limits
195	D	within normal limits
196	FS	hypertrophy
197	D	congestion vacuolization
198	FS	leukemic deposits
199	D	not fixed due to ~~analysis~~ Change to "autolysis"
200	D	hyperplastic nodule

Study: KWG 0519 male mice

Dose : 500 ppm

Animal No.	Status	Liver diagnosis
201	KM	adenoma hepatic benign
202	FS	hyperplastic nodule
203	D	within normal limits autolysis partial
204	KM	leukemic deposits
205	FS	fat vacuoles: minimal and multifocal
206	FS	within normal limits
207	D	within normal limits
208	D	calcification: moderate and multifocal adenoma hepatic benign hemorrhage: moderate and focal autolysis partial
209	D	hemorrhagic cyst: moderate and multifocal autolysis partial
210	D	congestion
211	D	within normal limits autolysis partial
212	D	leukemic deposits
213	D	hyperplastic nodule autolysis partial
214	D	within normal limits
215	FS	infarct: severe fat vacuoles: severe adenoma hepatic benign
216	D	hemorrhagic cyst: severe and multifocal
217	FS	vacuolisation: minimal and multifocal
218	FS	fat vacuoles: moderate hyperplastic nodule

219	FS	hyperplastic nodule hypertrophy
220	D	fat vacuoles: moderate congestion hyperplastic nodule
221	D	hemorraghic cyst: severe autolysis partial
222	KM	amyloid: moderate
223	KM	within normal limits
224	D	within normal limits
225	D	congestion
226	FS	adenoma hepatic benign
227	D	within normal limits
228	FS	within normal limits
229	D	within normal limits autolysis partial
230	FS	within normal limits
231	D	leukemic deposits autolysis partial
232	D	infarct: multifocal adenoma hepatic benign
233	FS	within normal limits
234	D	within normal limits
235	D	hyperplastic nodule hemorrhagic cyst: severe and multifocal
236	KM	within normal limits
237	D	congestion
238	KM	hyperplastic nodule: focal
239	FS	within normal limits
240	D	autolysis
241	D	mononuclear cells: moderate and multifocal
242	D	within normal limits
243	D	leukemic deposits autolysis partial
244	FS	within normal limits

245		excluded due to misplacement
246	D	congestion leukemic deposits
247	D	hemorrhagic cyst: severe and multifocal autolysis partial
248	D	hyperplastic nodules: multifocal
249	D	congestion
250	D	mononuclear cells: minimal and multifocal pigmentation: moderate

Study: KWG 0519 female mice

Dose: 500 ppm

Animal No.	Status	Liver diagnosis
251	D	leukemic deposits
252	D	leukemic deposits autolysis partial
253	FS	within normal limits
254	D	autolysis partial
255	D	leukemic deposits
256	D	congestion
		vacuolization: minimal
257	D	leukemic deposits
258	FS	vacuolization: minimal
259	D	leukemic deposits autolysis partial
260	D	adenoma hepatic benign: multifocal congestion
261	D	necrosis hyperplastic nodule leukemic deposits
262	D	infarct: multifocal leukemic deposits
263	FS	mononuclear cells: minimal and focal
264	D	autolysis partial
265	D	infarct adenocarcinoma
266	FS	adenoma hepatic benign leukemic deposits
267	FS	pigmentation: moderate
268	FS	vacuolization: moderate

269	D	congestion
270	FS	vacuolization: minimale
271	FS	adenoma hepatic benign vacuolization
272	FS	within normal limits
273	FS	within normal limits
274	D	autolysis
275	D	infarct: severe and multifocal
276	FS	within normal limits
277	D	leukemic deposits
278	D	hypertrophy: multifocal leukemic deposits autolysis partial
279	FS	within normal limits
280	D	congestion
281	FS	within normal limits
282	D	mononuclear cells: minimal and multifocal congestion
283	D	congestion
284	D	vacuolization: minimal and multifocal
285	D	mononuclear cells: minimal and multifocal
286	D	congestion
287	D	leukemic deposits autolysis partial
288	D	leukemic deposits
289	D	adenoma hepatic benign
290	D	leukemic deposits
291	FS	within normal limits
292	D	mononuclear cells: minimal and multifocal
293	D	congestion
294	D	leukemic deposits autolysis partial
295	FS	vacuolization: minimal

296	FS	within normal limits
297	D	autolysis
298	D	leukemic deposits
299	FS	within normal limits
300	D	congestion

Study: KWQ 0519 male mice

Dose: 2000 ppm

Animal No.	Status	Liver diagnosis
301	D	leukemic deposits
302	D	calcification: moderate and multifocal adenoma hepatic benign
303	KM	congestion
304	KM	within normal limits
305	D	hyperplastic nodule
306	FS	hyperplasia: multifocal ~~leukemic deposits~~ Change to: "Adenoma: hepatic benign" vacuolization: severe and multifocal
307	KM	amyloid hyperplasia: focal
308	FS	hyperplasia: multifocal mononuclear cells hyperplastic nodules: multifocal
309	D	congestion leukemic deposits
310	FS	within normal limits hyperplasia: multifocal calcification: severe and multifocal mononuclear cells: multifocal hyperplastic nodules: multifocal
311	D	within normal limits
312	FS	within normal limits
313	D	hyperplastic nodule
314	D	autolysis
315	FS	adenoma hepatic benign hyperplastic nodules: multifocal
316	D	necrosis: minimal and multifocal hemorrhage: moderate and multifocal hepatocytic hyperpigmentation hyperplastic nodule
317	KM	amyloid: moderate and multifocal

318	D	congestion: severe
319	D	adenoma hepatic benign amyloid: moderate and multifocal
320	D	calcification: multifocal Add: "Adenoma hepatic benign" leukemic deposits "hepatocytic hyperpigmenta- hemorrhage: severe and multifocal tion" amyloid: multifocal
321	D	leukemic deposits autolysis partial
322	FS	within normal limits
323	KM	calcification: severe and multifocal adenocarcinoma amyloid: severe and multifocal hepatocytic hyperpigmentation hyperplastic nodule
324	D	calcification: multifocal hyperplastic nodule
325	D	autolysis partial metastasis
326	D	hepatocytic hyperpigmentation autolysis partial
327	FS	within normal limits
328	D	within normal limits
329	D	within normal limits autolysis partial
330	D	amyloid: severe and multifocal
331	FS	hyperplastic nodule
332	FS	cysts
333	D	within normal limits
334	FS	hypertrophy
335	FS	hepatocytic hyperpigmentation
336	FS	hyperplasia: focal
337	D	within normal limits
338	FS	hyperplastic nodule
339	D	within normal limits
340	D	within normal limits

341	D	within normal limits
342	FS	adenoma hepatic benign leukemic deposits hepatocytic hyperpigmentation
343	FS	adenoma hepatic benign mononuclear cells: severe hepatocytic hyperpigmentation
344	D	leukemic deposits
345	FS	adenoma hepatic benign hemorrhage
346	D	hyperplastic nodule leukemic deposits autolysis partial
347	D	imflammation portal: severe
348	FS	within normal limits
349	D	hepatocytic hyperpigmentation
350	D	leukemic deposits

Study: KWG 0519 female mice

Dose: 2000 ppm

Animal No.	Status	Liver diagnosis
351	FS	fat vacuoles mononuclear cells hyperplastic nodule hepatocytic hyperpigmentation
352	D	congestion
353	D	leukemic deposits
354	FS	within normal limits
355	D	not fixed due to autolysis
356	KM	mononuclear cells: minimal periarteritis
357	FS	within normal limits
358	D	hyperplastic nodule
359	FS	fat vacuoles: minimal
360	FS	mononuclear cells: minimal
361	D	leukemic deposits
362	D	leukemic deposits
363	D	leukemic deposits
364	D	congestion
365	D	adenoma hepatic benign: unilateral and multifocal mononuclear cells: moderate and multifocal
366	D	leukemic deposits
367	FS	adenoma hepatic benign
368	FS	within normal limits
369	D	leukemic deposits
370	D	leukemic deposits
371	D	congestion
372	D	congestion

373	KM	mononuclear cells: minimal and multifocal
374	D	leukemic deposits
375	FS	infarct thrombosis adenoma hepatic benign congestion
376	D	adenoma hepatic benign hyperplastic nodule cysts
377	FS	adenoma hepatic benign
378	FS	within normal limits
379	FS	hepatocytic hyperpigmentation
380	D	leukemic deposits
381	D	adenoma hepatic benign hyperplastic nodules: multifocal
382	D	leukemic deposits
383	FS	within normal limits
384	FS	within normal limits
385	D	leukemic deposits
386	KM	mononuclear cells: severe and multifocal congestion: severe
387	D	fat vacuoles
388	FS	mononuclear cells: minimal
389	FS	hyperplastic nodule
390	D	leukemic deposits
391	FS	mononuclear cells: minimal hyperplastic nodule hepatocytic hyperpigmentation
392	D	within normal limits autolysis partial
393	D	within normal limits
394	KM	leukemic deposits
395	D	hypertrophy autolysis
396	KM	leukemic deposits

397	D	leukemic deposits
398	FS	within normal limits
399	FS	fat vacuoles: minimal hepatocytic hyperpigmentation: minimal
400	FS	fat vacuoles: moderate cysts hepatocytic hyperpigmentation: minimal hyperplastic nodule

To

Drs Hixson / Thyssen

Incidences

Study: KGW 0519

male mice

Doses (ppm)	0	125	500	2000
LIVER				
Number examined	50	50	49	50
HYPERPLASIA	0	0	0	3
INFARCT	0	1	2	0
CALCIFICATION	1	1	1	5
FAT VACUOLES	0	7	4	0
NECROSIS	2	0	0	1
FIBROSIS	0	1	0	0
INFLAMMATION GRANULOMATOUS	0	1	0	0
HEMORRHAGE	0	3	1	3
MONONUCLEAR CELLS	3	2	2	3
PIGMENTATION	1	0	1	0
AMYLOID	3	1	1	6
HEMATOPOIESIS	0	3	0	0
CONGESTION	3	4	6	4
HYPERTROPHY	0	0	1	1
VACUOLIZATION	1	2	1	1
PERICHOLANGITIS	0	1	0	0
CYSTS	0	1	0	1
LEUKEMIC DEPOSITS	9	5	4	7
INFLAMMATION PORTAL	0	0	0	1
HYALINOSIS	0	1	0	1
HEPATOCYTIC HYPERPIGMENTATION	4	0	0	9
HEMORRAGIC CYST	0	0	5	0
HYPERPLASIA FOCAL	2	0	0	2
HYPERPLASTIC NODULE	1	5	7	3
HYPERPLASTIC NODULES	7	1	2	7
CYSTADENOMA	1	0	0	0
ADENOMA HEPATIC BENIGN	5	4	5	8
ADENOCARCINOMA	2	0	0	1

Incidences

Study: KGW 0519

female mice

Doses (ppm)	0	125	500	2000
LIVER				
Number examined	48	49	50	49
INFARCT	1	0	3	1
THROMBOSIS	0	0	0	1
CALCIFICATION	1	0	0	0
FAT VACUOLES	6	0	0	5
NECROSIS	0	0	1	0
HEMORRHAGE	0	1	0	0
MONONUCLEAR CELLS	10	6	4	8
PIGMENTATION	0	0	1	0
AMYLOID	0	1	0	0
HEMATOPOIESIS	1	0	0	0
CONGESTION	10	7	10	6
HYPERTROPHY	1	2	1	1
VACUOLIZATION	6	4	7	0
CYSTS	1	0	0	2
LEUKEMIC DEPOSITS	10	8	15	15
HEPATOCYTIC HYPERPIGMENTATION	5	0	0	5
PERIARTERITIS	0	0	0	1
HEMORRHAGIC CYST	1	0	0	0
HYPERPLASTIC NODULE	2	1	1	4
HYPERPLASTIC NODULES	0	0	0	3
ADENOMA HEPATIC BENIGN	0	0	4	6
ADENOCARCINOMA	1	0	1	0
ANGIOSARCOMA	0	0	1	0

"Contains NO CDI" 627

PAGE NO(S) _____

ADDITIONS OR CORRECTIONS

FOR NUMBERED REPORTS

REPORT NUMBER (82291) HAS BEEN:

____ REVISED _____ PROOFED _____

✓ ADDENDUM ADDED II PROOFED _____

____ VOIDED (SAME AS: _____)

REASON FOR REVISION: _____

REASON FOR ADDING ADDENDUM: Addition of Pathology Report

OTHER: _____

FROM: 3/31/88

DATE: S.R. Ryan

RF #F-37 (2-20-87)
Supersedes: (8-23-77)

PAGE NO(S) 31

ADDITIONS OR CORRECTIONS

FOR NUMBERED REPORTS

REPORT NUMBER (82291) HAS BEEN:

V REVISED Addendum II PROOFED _____

____ ADDENDUM ADDED _____ PROOFED _____

____ VOIDED (SAME AS: _____)

REASON FOR REVISION: Memo (Appendix I) attached to end of addendum II - Statistical evaluations

REASON FOR ADDING ADDENDUM: _____

OTHER: _____

FROM: 4-4-88

DATE: C. K. Young

RF #F-37 (2-20-87)
Supersedes: (8-23-77)

SUPPLEMENTAL SUBMISSION TO EPA ACCESSION NUMBER 071467

Study Title

KWG 0519

CHRONIC TOXICOLOGICAL STUDY ON MICE

EVALUATION OF LIVER TISSUES FROM FEMALE MICE PATHOLOGY REPORT

EHR FILE
WO 1508

Data Requirement

EPA Guideline 83-2

Shawn - see me & tell you what I did on this addendum II revision

Author

Dr. E. Bomhard

Study Completion Date

April 29, 1982

Performing Laboratory

Experimental Pathology Laboratories, Inc.
P.O. Box 12766
Research Triangle Park, NC 27709

BAYER AG
Institute of Toxicology
Federal Republic of Germany
Report No. 10855

Laboratory Project ID

Report No. 82291

EHRD INFORMATION RESOURCES CENTER
RECEIVED
MAR 2

Study Title

KWG 0519

CHRONIC TOXICOLOGICAL STUDY ON MICE

EVALUATION OF LIVER TISSUES FROM FEMALE MICE PATHOLOGY REPORT

EHR FILE
WO 1509

Data Requirement

EPA Guideline 83-2

Author

Dr. E. Bomhard

Study Completion Date

April 29, 1982

Performing Laboratory

Experimental Pathology Laboratories, Inc.
P.O. Box 12766
Research Triangle Park, NC 27709

BAYER AG
Institute of Toxicology
Federal Republic of Germany
Report No. 10855

Laboratory Project ID

Report No. 82291

EHRD INFORMATION RESOURCES CENTER
RECEIVED
MAR 2

STATEMENT OF NO DATA CONFIDENTIALITY CLAIMS

No claim of confidentiality is made for any information contained in this study on the basis of its falling within the scope of FIFRA Section 10(d)(1)(A), (B), or (C).

Company MOBAY CORPORATION

Company Agent: Dr. J.H. Thyssen

Date: 3-29-88

Director Corporate Toxicology
Title

J. H. Thyssen
Signature

GOOD LABORATORY PRACTICE STATEMENT

This study meets the requirements for 40 CFR Part 160

Submitter MOBAY CORPORATION

Sponsor AGRICULTURAL CHEMICALS DIVISION

Study Director for the study director J.K. Thyssen

(See also page 013)

EPL

EXPERIMENTAL PATHOLOGY LABORATORIES, INC.

CHRONIC TOXICOLOGICAL STUDY ON MICE
MOBAY REPORT NO. 82291/1508

EVALUATION OF LIVER TISSUES FROM FEMALE MICE

PATHOLOGY REPORT

Submitted to:

Mobay Corporation
Stilwell, Kansas 66085-9104

March 23, 1988

TABLE OF CONTENTS

	Page
Pathology Narrative	6
Summary Incidence Tables	14
Histopathology Incidence Tables	16

CHRONIC TOXICOLOGICAL STUDY ON MICE
MOBAY REPORT NO. 82291/1508

EVALUATION OF LIVER TISSUES FROM FEMALE MICE

PATHOLOGY SUMMARY

A Chronic Toxicological Study on Mice was conducted at Bayer AG and histopathology performed at Battelle-Institute. The results of this study were submitted to the Environmental Protection Agency (EPA) by the study sponsor. The EPA requested that the sponsor have the liver sections from all female mice in all groups be reexamined to be sure that the interpretations, evaluations and nomenclatures for the liver lesions are consistent with those presently used in the United States. This reevaluation was conducted by Dr. Jerry F. Hardisty, Experimental Pathology Laboratories, Inc., Research Triangle Park, North Carolina who prepared this narrative summary of the findings and report of the results for submission to the Environmental Protection Agency.

Hematoxylin and eosin stained sections of liver from female mice given KWG 0519 (BAYTAN) and liver sections from control female mice were received from Dr. Barry Stuart, Mobay Corporation, Stilwell, Kansas, and were examined microscopically by a pathologist at Experimental Pathology Laboratories, Inc.

The dose groups and reevaluation number of female mice with liver sections submitted for this study are listed as follows:

Dose/ppm	Number of Female Mice
0	46
125	49
500	50
2000	49

RESULTS

Histopathologic observations for individual animals are tabulated in the accompanying Histopathology Incidence Tables. The incidence of these observations are summarized for each group in the Summary Incidence Tables.

An increased number of primary hepatocellular neoplasms were observed in the liver of female mice given 500 ppm and 2000 ppm KWG 0519 (BAYTAN) as compared to female mice given 0 ppm or 125 ppm KWG 0519 (BAYTAN). Nonneoplastic changes which were increased only in the 2000 ppm dose group included Kupffer cell pigmentation and hepatocellular cytoplasmic vacuolization. The criteria used to classify the hepatocellular lesions in this

reevaluation were those currently used by the National Toxicology Program[1]. The incidence of these lesions are summarized as follows:

	Female			
	0 ppm	125 ppm	500 ppm	2000 ppm
LIVER (NO. EXAMINED)	(46)	(49)	(50)	(49)
Hepatocellular Carcinoma	1		2	3
Hepatocellular Adenoma		1	2	4
Hepatocellular Adenoma, Multiple			1	1
Kupffer Cell Pigmentation	17	18	16	32
Cytoplasmic Vacuolization	2	1		10

The hepatocellular adenomas were usually discrete lesions which compressed the adjacent parenchyma. They were composed of well differentiated cells which resembled normal hepatocytes, were usually eosinophilic, and were sometimes vacuolated. Within the hepatocellular adenomas there was an absence of the normal hepatic lobular architecture characterized by disorganized cords and lack of portal triads and central veins.

A diagnosis of hepatocellular carcinoma was made when there was a distinct trabecular or adenoid pattern present within the neoplasm. The hepatocellular carcinomas were generally larger and involved major portions of the liver lobes. Hepatocellular carcinomas were more irregular than hepatocellular adenomas and there was frequent extension into the surrounding normal parenchyma. The normal hepatic architecture was replaced by hepatocytes arranged in sheets or disorganized cords. The

trabecular pattern was characterized by liver cords which were thickened and arranged in linear or papillary patterns separated by dilated hepatic sinusoids.

Kupffer cell pigmentation consisted of an accumulation of intracytoplasmic yellow pigment in the phagocytic cells of the liver. It was not possible to specifically characterize the nature of the pigment observed in the sections evaluated. Intracytoplasmic vacuolization of hepatocytes was characterized by scattered accumulation of fat vacuoles within the cytoplasm of hepatocytes. Although the incidence of these nonneoplastic lesions were elevated in the 2000 ppm dose group as compared to the control, low- and mid-dose groups, there was little difference in the degree of severity of these changes among the four test groups.

A variety of other changes were observed during this evaluation. No treatment related differences were noted among the control and treated groups with respect to these changes. Neoplastic changes consisted of lymphoreticular neoplasms with hepatic involvement. Nonneoplastic changes which were observed included multifocal necrosis and extramedullary hematopoiesis in a few control and treated mice, amyloidosis occurring in one control mouse and fibrosis associated with chronic inflammation in one female mouse in the 500 ppm dose group. These lesions are spontaneously occurring changes which are occasionally observed in untreated mice of this strain and age.

Following the reevaluation of liver sections from this study, diagnoses made by the study pathologist and reviewing pathologist were compared. Although there were differences between the diagnoses made by the study pathologist and the observations included in this report, the findings of this review support the conclusions presented by the study pathologist. A comparison of the study pathologist's diagnoses and findings of this review for reported proliferative hepatocellular lesions is presented as follows:

0 ppm

Animal Number	Study Pathologist	Reviewing Pathologist
52	Hyperplastic Nodule	No Corresponding Diagnosis
58	Hyperplastic Nodule	No Corresponding Diagnosis
60	Adenocarcinoma	Hepatocellular Carcinoma

125 ppm

Animal Number	Study Pathologist	Reviewing Pathologist
160	No Corresponding Diagnosis	Hepatocellular Adenoma
180	Hyperplastic Nodule	Eosinophilic Cell Foci
200	Hyperplastic Nodule	No Corresponding Diagnosis

500 ppm

Animal Number	Study Pathologist	Reviewing Pathologist
260	Adenoma Hepatic Benign	Hepatocellular Adenoma, Multiple
261	Hyperplastic Nodule	No Corresponding Diagnosis
265	Adenocarcinoma	Hepatocellular Carcinoma
266	Adenoma Hepatic Benign	Hepatocellular Carcinoma
271	Adenoma Hepatic Benign	Hepatocellular Adenoma
289	Adenoma Hepatic Benign	Hepatocellular Adenoma

2000 ppm

Animal Number	Study Pathologist	Reviewing Pathologist
351	Hyperplastic Nodule	Hepatocellular Adenoma
358	Hyperplastic Nodule	No Corresponding Diagnosis
365	Adenoma Hepatic Benign	Hepatocellular Carcinoma
367	Adenoma Hepatic Benign	Hepatocellular Adenoma
375	Adenoma Hepatic Benign	Hepatocellular Carcinoma
376	Adenoma Hepatic Benign Hyperplastic Nodule	Hepatocellular Adenoma, Multiple
377	Adenoma Hepatic Benign	Hepatocellular Adenoma
381	Adenoma Hepatic Benign Hyperplastic Nodules, Multifocal	Hepatocellular Carcinoma
389	Hyperplastic Nodule	Hepatocellular Adenoma
391	Hyperplastic Nodule	Eosinophilic Cell Foci
400	Hyperplastic Nodule	Eosinophilic Cell Foci

CONCLUSIONS

The results of this reevaluation of liver sections from female mice given 0 ppm, 125 ppm, 500 ppm and 2000 ppm KWG 0519 (BAYTAN), in Chronic Toxicological Study in Mice, indicate that there was an increased incidence of primary hepatocellular neoplasms in the treated female mice given 500 ppm and 2000 ppm when compared to female mice given 0 ppm and 125 ppm KWG 0519 (BAYTAN). A slight increase in Kupffer cell pigmentation and hepatocellular cytoplasmic vacuolization was observed in female mice in the 2000 ppm dose group as compared to female mice in the

control, mid- and low- dose groups. No increase in hepatocellular neoplasia or nonneoplastic changes were observed in the 125 ppm dose group.

Jerry F. Hardisty, D.V.M.
JERRY F. HARDISTY, D.V.M.
Pathologist

March 03, 1988
DATE

REFERENCES

1. Maronpot, R.R., Haseman, J.K., Boorman, G.A., Eustis, S.E., Rao, G.N., and Huff, J.E. (1987) Liver Lesions in B6C3F1 Mice: The National Toxicology Program, Experience and Position. In: P.L. Chambers, D. Henscher and F. Oesch (Eds), Mouse Liver Tumors, Supplement 10, Springer-Verlag, pp 10-26.

EPL

EXPERIMENTAL PATHOLOGY LABORATORIES, INC.

QUALITY ASSURANCE

FINAL CERTIFICATION

Client Name Mobay Corporation — EPL Project Coordinator Dr. Hardisty

Client Study No. Mobay Report No. 82291/1508 — EPL Pathologist Dr. Hardisty

Species Mouse — EPL Project No. 276-001

Study Title Chronic Toxicological Study on Mice

Test Article KWG 0519 (BAYTAN)

The following phases of this study (marked by "X") were inspected by Experimental Pathology Laboratories Quality Assurance Unit. The dates of the inspections performed are as indicated below. All findings were reported to the EPL Project Coordinator and to Management.

(X)		Date
X	Part 1 of 6 - Project Sheet Preparation	#1 March 4, 1988 #2 March 14, 1988
N/A	Part 2 of 6 - Master Individual/Multiple Animal Worksheet	
N/A	Part 3 of 6 - Histology Setup	
N/A	Part 4 of 6 - Histology Completion	
X	Part 5 of 6 - Rough Draft Report	March 14, 1988
X	Part 6 of 6 - Final Report	March 23, 1988
	Other	

Diane J. Bissett
Quality Assurance

March 23, 1988
Date

000013

SUMMARY INCIDENCE TABLE

SUMMARY INCIDENCE TABLE

Mobay Report No. 82291/1508
Chronic Toxicological Study
on Mice
KWG 0519 (BAYTAN)
Female Mice

	0 ppm			125 ppm			500 ppm			2000 ppm		
	Scheduled Sacrifice	Moribund Sacrifice & Deaths	Total	Scheduled Sacrifice	Moribund Sacrifice & Deaths	Total	Scheduled Sacrifice	Moribund Sacrifice & Deaths	Total	Scheduled Sacrifice	Moribund Sacrifice & Deaths	Total
LIVER (NO. EXAMINED)	(16)	(30)	(46)	(15)	(34)	(49)	(17)	(33)	(50)	(19)	(30)	(49)
Hepatocellular Carcinoma		1	1				1	1	2	1	2	3
Hepatocellular Adenoma					1	1	1	1	2	4		4
Hepatocellular Adenoma, Multiple								1	1		1	1
Leukemic Infiltrate		7	7	2	6	8	1	14	15		13	13
Multifocal Mononuclear Cell Infiltrate	7	6	13	5	4	9	2	5	7	8	6	14
Kupffer Cell Pigmentation	10	7	17	6	12	18	7	9	16	17	15	32
Eosinophilic Cell Foci					1	1	1		1	2		2
Cytoplasmic Vacuolization	1	1	2		1	1				5	5	10
Multifocal Necrosis		2	2		1	1	1	2	3			
Extramedullary Hematopoiesis	2	2	4								1	1
Amyloidosis		1	1									
Fibrosis							1		1			

000015

HISTOPATHOLOGY INCIDENCE TABLES

HISTOPATHOLOGY INCIDENCE TABLE

0 ppm
Scheduled Sacrifice (FS)

Mobay Report No. 82291/1508
Chronic Toxicological Study
on Mice
KWG 0519 (BAYTAN)
Female Mice

ANIMAL NUMBER	51	52	55	57	66	74	76	78	81	82	83	84	89	92	96	100
LIVER			X								X					
Hepatocellular Carcinoma																
Hepatocellular Adenoma																
Hepatocellular Adenoma, Multiple																
Leukemic Infiltrate																
Multifocal Mononuclear Cell Infiltrate	1	1		1			1						1		1	1
Kupffer Cell Pigmentation	1	1		1			1		1	1		1		1	2	1
Eosinophilic Cell Foci																
Cytoplasmic Vacuolization					1											
Multifocal Necrosis																
Extramedullary Hematopoiesis						1		1								
Amyloidosis																
Fibrosis																

41000

EPL
Experimental Pathology Laboratories, Inc

Key P = Present
1 = Minimal
N = No Section
2 = Slight
A = Autolysis
3 = Moderate
X = Not Remarkable
4 = Moderately Severe High

HISTOPATHOLOGY INCIDENCE TABLE

0 ppm
Moribund/Deaths (D & KM)

Mobay Report No. 82291/1508
Chronic Toxicological Study
on Mice
KWG 0519 (BAYTAN)
Female Mice

ANIMAL NUMBER	53	54	56	58	59	60	61	62	63	64	65	67	68	69	70	71	72	73	75	77	79	80	85	86	87	88	90	91
LIVER		X	N	A	A		N		X		N	N			X			X	A	A			X	X			A	
Hepatocellular Carcinoma						P																						
Hepatocellular Adenoma																												
Hepatocellular Adenoma, Multiple																												
Leukemic Infiltrate	P									P											P	P			P			
Multifocal Mononuclear Cell																												
Infiltrate				1	2			1								1												
Kupffer Cell Pigmentation								1						1		2	1									3		1
Eosinophilic Cell Foci																												
Cytoplasmic Vacuolization																										2		
Multifocal Necrosis						2																						
Extramedullary Hematopoiesis													1				4											
Amyloidosis																												
Fibrosis				.																								

00018

EPL
Experimental Pathology Laboratories, Inc.

Key: P = Present; 1 = Minimal; 5 = Severe/High; N = No Section; 2 = Slight; I = Incomplete Section; A = Autolysis; 3 = Moderate; X = Not Remarkable; 4 = Moderately Severe High

HISTOPATHOLOGY INCIDENCE TABLE

0 ppm
Moribund/Deaths (D & KM)

Mobay Report No. 82291/1508
Chronic Toxicological Study
on Mice
KWG 0519 (BAYTAN)
Female Mice

ANIMAL NUMBER	93	94	95	97	98	99
LIVER			X		A	
Hepatocellular Carcinoma						
Hepatocellular Adenoma						
Hepatocellular Adenoma, Multiple						
Leukemic Infiltrate		P		P		
Multifocal Mononuclear Cell Infiltrate	2					1
Kupffer Cell Pigmentation	1					
Eosinophilic Cell Foci						
Cytoplasmic Vacuolization						
Multifocal Necrosis				2		
Extramedullary Hematopoiesis						
Amyloidosis	1					
Fibrosis						

000019

EPL
Experimental Pathology Laboratories, Inc

Key P = Present
1 = Minimal
5 = Severe/High
N = No Section
2 = Slight
I = Incomplete Section
A = Autolysis
3 = Moderate
X = Not Remarkable
4 = Moderately Severe High

HISTOPATHOLOGY INCIDENCE TABLE

125 ppm
Scheduled Sacrifice (FS)

Mobay Report No. 82291/1508
Chronic Toxicological Study
on Mice
KWG 0519 (BAYTAN)
Female Mice

ANIMAL NUMBER	158	161	163	164	168	170	171	177	178	179	186	188	194	196	198
LIVER	X		X						X			X	X	X	
Hepatocellular Carcinoma															
Hepatocellular Adenoma															
Hepatocellular Adenoma, Multiple															
Leukemic Infiltrate							P								P
Multifocal Mononuclear Cell Infiltrate		1			1	1				1	1				
Kupffer Cell Pigmentation		1		1		1		1		1	1				
Eosinophilic Cell Foci															
Cytoplasmic Vacuolization															
Multifocal Necrosis															
Extramedullary Hematopoiesis															
Amyloidosis															
Fibrosis															

020020

EPL
Experimental Pathology Laboratories, Inc.

Key: P = Present; 1 = Minimal; 5 = Severe/High; N = No Section; 2 = Slight; I = Incomplete Section; A = Autolysis; 3 = Moderate; X = Not Remarkable; 4 = Moderately Severe High

HISTOPATHOLOGY INCIDENCE TABLE

125 ppm
Moribund/Deaths (D & KM)

Mobay Report No. 82291/1508
Chronic Toxicological Study
on Mice
KWG 0519 (BAYTAN)
Female Mice

ANIMAL NUMBER	151	152	153	154	155	156	157	159	160	162	165	166	167	169	172	173	174	175	176	180	181	182	183	184	185	187	189	190
LIVER	X			X				A			A				X		A		A			A			X	X		X
Hepatocellular Carcinoma																												
Hepatocellular Adenoma									P																			
Hepatocellular Adenoma, Multiple																												
Leukemic Infiltrate									P	P		P				P							P					
Multifocal Mononuclear Cell Infiltrate							1											1		1								
Kupffer Cell Pigmentation		2	1		1	1	1						1	1							1			1			2	
Eosinophilic Cell Foci																				2								
Cytoplasmic Vacuolization																					2							
Multifocal Necrosis																		3										
Extramedullary Hematopoiesis																												
Amyloidosis																												
Fibrosis																												

120021

EPL
Experimental Pathology Laboratories, Inc.

Key: P = Present; 1 = Minimal; 5 = Severe/High; N = No Section; 2 = Slight; I = Incomplete Section; A = Autolysis; 3 = Moderate; X = Not Remarkable; 4 = Moderately Severe High

HISTOPATHOLOGY INCIDENCE TABLE

125 ppm
Moribund/Deaths (D & KM)

Mobay Report No. 82291/1508
Chronic Toxicological Study
on Mice
KWG 0519 (BAYTAN)
Female Mice

ANIMAL NUMBER	191	192	193	195	197	199	200
LIVER			X	X		N	A
Hepatocellular Carcinoma							
Hepatocellular Adenoma							
Hepatocellular Adenoma, Multiple							
Leukemic Infiltrate	P						
Multifocal Mononuclear Cell Infiltrate		1					
Kupffer Cell Pigmentation		1			1		
Eosinophilic Cell Foci							
Cytoplasmic Vacuolization							
Multifocal Necrosis							
Extramedullary Hematopoiesis							
Amyloidosis							
Fibrosis				.			

220000

EPL | Experimental Pathology Laboratories, Inc.

Key P = Present
1 = Minimal
N = No Section
2 = Slight
A = Autolysis
3 = Moderate
X = Not Remarkable
4 = Moderately Severe High

HISTOPATHOLOGY INCIDENCE TABLE

500 ppm
Scheduled Sacrifice (FS)

Mobay Report No. 82291/1508
Chronic Toxicological Study
on Mice
KWG 0519 (BAYTAN)
Female Mice

ANIMAL NUMBER	253	258	263	266	267	268	270	271	272	273	276	279	281	291	295	296	299
LIVER		X	X			X				X		X	X	X		X	
Hepatocellular Carcinoma				P													
Hepatocellular Adenoma								P									
Hepatocellular Adenoma, Multiple																	
Leukemic Infiltrate				P													
Multifocal Mononuclear Cell Infiltrate	1														1		
Kupffer Cell Pigmentation	1			1	3			1	1		1						1
Eosinophilic Cell Foci							1										
Cytoplasmic Vacuolization																	
Multifocal Necrosis					1												
Extramedullary Hematopoiesis																	
Amyloidosis																	
Fibrosis					3												

000023

EPL
Experimental Pathology Laboratories, Inc.

Key: P = Present
1 = Minimal
5 = Severe/High
N = No Section
2 = Slight
I = Incomplete Section
A = Autolysis
3 = Moderate
X = Not Remarkable
4 = Moderately Severe High

HISTOPATHOLOGY INCIDENCE TABLE

500 ppm
Moribund/Deaths (D & KM)

Mobay Report No. 82291/1508
Chronic Toxicological Study on Mice
KWG 0519 (BAYTAN)
Female Mice

ANIMAL NUMBER	251	252	254	255	256	257	259	260	261	262	264	265	269	274	275	277	278	280	282	283	284	285	286	287	288	289	290	292
LIVER			A				A				A			A			A	X		X							
Hepatocellular Carcinoma												P															
Hepatocellular Adenoma																										P	
Hepatocellular Adenoma, Multiple								P																			
Leukemic Infiltrate	P	P		P		P	P		P	P						P	P							P	P	P	P	
Multifocal Mononuclear Cell Infiltrate																			1		1	1	1					1
Kupffer Cell Pigmentation					1							1	1						1		2							1
Eosinophilic Cell Foci															4		2											
Cytoplasmic Vacuolization																												
Multifocal Necrosis																												
Extramedullary Hematopoiesis																												
Amyloidosis																												
Fibrosis																												

#20000

EPL
Experimental Pathology Laboratories, Inc

Key P = Present
1 = Minimal
5 = Severe/High
N = No Section
2 = Slight
I = Incomplete Section
A = Autolysis
3 = Moderate
X = Not Remarkable
4 = Moderately Severe High

HISTOPATHOLOGY INCIDENCE TABLE

500 ppm
Moribund/Deaths (D & KM)

Mobay Report No. 82291/1508
Chronic Toxicological Study
on Mice
KWG 0519 (BAYTAN)
Female Mice

ANIMAL NUMBER	293	294	297	298	300
LIVER	X		A		
Hepatocellular Carcinoma					
Hepatocellular Adenoma					
Hepatocellular Adenoma, Multiple					
Leukemic Infiltrate				P	
Multifocal Mononuclear Cell Infiltrate					
Kupffer Cell Pigmentation		2		2	1
Eosinophilic Cell Foci					
Cytoplasmic Vacuolization					
Multifocal Necrosis					
Extramedullary Hematopoiesis					
Amyloidosis					
Fibrosis					

000025

EPL Experimental Pathology Laboratories, Inc.

Key P = Present
1 = Minimal
5 = Severe/High
N = No Section
2 = Slight
I = Incomplete Section
A = Autolysis
3 = Moderate
X = Not Remarkable
4 = Moderately Severe High

HISTOPATHOLOGY INCIDENCE TABLE

2000 ppm
Scheduled Sacrifice (FS)

Mobay Report No. 82291/1508
Chronic Mouse Study
on Mice
KWG 0519 (BAYTAN)
Female Mice

ANIMAL NUMBER	351	354	357	359	360	367	368	375	377	378	379	383	384	388	389	391	398	399	400
LIVER																			
Hepatocellular Carcinoma								P											
Hepatocellular Adenoma	P					P			P						P				
Hepatocellular Adenoma, Multiple																			
Leukemic Infiltrate																			
Multifocal Mononuclear Cell Infiltrate	1		1	1	1		1				1			2		1			
Kupffer Cell Pigmentation	1	1	1	1	1	2	1		1	1	2	1	1	1		1	1	1	2
Eosinophilic Cell Foci																3			3
Cytoplasmic Vacuolization	2			2												1		1	2
Multifocal Necrosis																			
Extramedullary Hematopoiesis																			
Amyloidosis																			
Fibrosis																			

000026

EPL
Experimental Pathology Laboratories, Inc

Key: P = Present
1 = Minimal
5 = Severe/High
N = No Section
2 = Slight
I = Incomplete Section
A = Autolysis
3 = Moderate
X = Not Remarkable
4 = Moderately Severe High

HISTOPATHOLOGY INCIDENCE TABLE

2000 ppm
Moribund/Deaths (D & KM)

Mobay Report No. 82291/1508
Chronic Toxicological Study
on Mice
KWG 0519 (BAYTAN)
Female Mice

ANIMAL NUMBER	352	353	355	356	358	361	362	363	364	365	366	369	370	371	372	373	374	376	380	381	382	385	386	387	390	392	393	394
LIVER	X		N		A																					A	X	
Hepatocellular Carcinoma										P										P								
Hepatocellular Adenoma																												
Hepatocellular Adenoma, Multiple																		P										
Leukemic Infiltrate		P						P			P	P	P				P		P		P	P			P			P
Multifocal Mononuclear Cell Infiltrate						1	2			3				1		1							3					
Kupffer Cell Pigmentation				2			2		1	1				1	1	1				2	2	1	1	1		1		1
Eosinophilic Cell Foci																												
Cytoplasmic Vacuolization										1					1						2		1	2				
Multifocal Necrosis																												
Extramedullary Hematopoiesis				2																								
Amyloidosis																												
Fibrosis																												

220000

EPL
Experimental Pathology Laboratories, Inc.

Key: P = Present; 1 = Minimal; 5 = Severe/High; N = No Section; 2 = Slight; I = Incomplete Section; A = Autolysis; 3 = Moderate; X = Not Remarkable; 4 = Moderately Severe High

HISTOPATHOLOGY INCIDENCE TABLE

2000 ppm
Moribund/Deaths (D & KM)

Mobay Report No. 82291/1508
Chronic Toxicological Study
on Mice
KWG 0519 (BAYTAN)
Female Mice

ANIMAL NUMBER	395	396	397
LIVER	A		
Hepatocellular Carcinoma			
Hepatocellular Adenoma			
Hepatocellular Adenoma, Multiple			
Leukemic Infiltrate		P	P
Multifocal Mononuclear Cell Infiltrate			
Kupffer Cell Pigmentation		1	
Eosinophilic Cell Foci			
Cytoplasmic Vacuolization			
Multifocal Necrosis			
Extramedullary Hematopoiesis			
Amyloidosis			
Fibrosis			

82000

EPL
Experimental Pathology Laboratories, Inc.

Key: P = Present; 1 = Minimal; 5 = Severe/High; N = No Section; 2 = Slight; I = Incomplete Section; A = Autolysis; 3 = Moderate; X = Not Remarkable; 4 = Moderately Severe High

APPENDIX 1 to ADDENDUM 2

KWG 0519
STATISTICAL EVALUATION OF ORIGINAL AND PEER REVIEWED EXAMINATIONS
OF HEPATOCELLULAR PROLIFERATIVE LESIONS FROM FEMALE MICE OF ONCOGENICITY
STUDY OF BAYTAN

MOBAY CORPORATION **HEALTH, ENVIRONMENT & SAFETY DEPARTMENT**
CORPORATE TOXICOLOGY

DATE: March 23, 1988

TO: J. H. Thyssen

COPY: C. A. Halder
BAYTAN file

FROM: B. P. Stuart

ID: BPS32388

SUBJECT: Contracted (Experimental Pathology Laboratories, Inc.) Review Findings for Female Mice from a Chronic Toxicological Study on Mice Receiving KWG 0519 (BAYTAN)

The reviewing pathologist at EPL stated that "although there were differences between the diagnoses made by the study pathologist and the observations included in this report, the findings of this review support the conclusions presented by the study pathologist."

Statistical evaluation using Chi-Square and Fishers Exact Test (SAS Institute, Cary, North Carolina) provided a statistical comparison ($p \leq 0.05$ level) of the original and peer review of the hepatocellular proliferative lesions. A Chi-Square analysis of the overall distribution was used to determine if a significant difference was present. If this was the case, a one-tailed Fishers Exact Test was used to determine which level(s) was different from the control group.

Incidence of Hepatocellular Proliferative Lesions

Dietary Level	Nodular Hyperplasia		Adenoma		Carcinoma		Total	
	Bayer	EPL	Bayer	EPL	Bayer	EPL	Bayer	EPL
0	2	0	0	0	1	1	3	1
I (125 ppm)	2	0	0	1	0	0	2	1
II (500 ppm)	1	0	4	3	1	2	6	5
III (2000 ppm)	7	0	6*	5	0	3	12*	8*

* = Statistical significance ($p \leq 0.05$)

Statistical analysis demonstrated a significant difference in the overall distribution of total hepatocellular proliferative lesions between control mice and female mice receiving dietary BAYTAN in the original (Bayer) and reviewing (EPL) pathologists' data. Although there was no statistical difference in the incidence of hepatocellular carcinoma reported by Bayer or EPL, there was a statistical increase in the hepatocellular adenoma incidence reported by Bayer.

There was an increase observed by the original and reviewing pathologists in hepatocellular adenoma and total hepatocellular proliferative lesions between control mice and those receiving 500 ppm (level II) dietary BAYTAN. There was also a slight increase in hepatocellular carcinoma observed by the reviewing pathologist. These increased incidences were not statistically significant. Only hepatocellular adenomas observed by the original pathologist and total hepatocellular proliferative lesions observed by both the original and reviewing pathologists in 2000 ppm (level III) mice were statistically significantly different from the control animals. There were no significant differences between the incidence of hepatocellular proliferative lesions in control and 125 ppm (level I) mice evaluated by either Bayer or EPL.

In summary, there was no major difference between the original and reviewing pathologists' evaluations made of the hepatocellular proliferative lesions in female mice from this chronic toxicological study.

Barry P. Stuart

B. P. Stuart

PS

727 for # 1508

PAGE NO(S) _____

ADDITIONS OR CORRECTIONS

FOR NUMBERED REPORTS

REPORT NUMBER (82291) HAS BEEN:

____ REVISED _____ PROOFED _____

✓ ADDENDUM ADDED ~~II~~ III PROOFED _____

____ VOIDED (SAME AS: _____).

REASON FOR REVISION: _____

REASON FOR ADDING ADDENDUM: L. Kaliner's opinion on morphology & nomenclature regarding Canada Flasher 1761-C.

OTHER: _____

FROM: S. R. Ryan

DATE: 10-26-88

BEST COPY AVAILABLE

SUPPLEMENTAL SUBMISSION TO EPA MRID NO.: 00126259

Study Title

KWG 0519 (TRIADIMENOL)

CHRONIC TOXICOLOGICAL STUDY ON MICE

(FEEDING EXPERIMENT OVER TWO YEARS)

Data Requirement

EPA Guideline 83-1

Author

Dr. E. Bomhard

Dr. E. Loser

Study Completion Date

April 29, 1982

Performing Laboratory

BAYER AG
Institute of Toxicology
Friedrich-Ebert-Strasse 217-333
D-5600 Wuppertal 1
Federal Republic of Germany

Addendum to Report No. 10855

Laboratory Project ID

Report No. 82291

STATEMENT OF NO DATA CONFIDENTIALITY CLAIMS

No claim of confidentiality is made for any information contained in this study on the basis of its falling within the scope of FIFRA Section 10(d)(1)(A), (B), or (C).

Company MOBAY CORPORATION

Company Agent: Dr. J.H. Thyssen

Date: 10-26-88

Director Corporate Toxicology
Title

J.H. Thyssen
Signature

GOOD LABORATORY PRACTICE STATEMENT

This study was not done in compliance with the Good Laboratory Practice requirements for 40 CFR Part 160. This study was performed previous to Good Laboratory Practice requirements.

SUBMITTER

MOBAY CORPORATION

Dr. J.H. Thyssen J. H. Thyssen

Director Corporate Toxicology

Date 10-26-88

SPONSOR

AGRICULTURAL CHEMICALS DIVISION

Dr. J.H. Thyssen J. H. Thyssen

Director Corporate Toxicology

Date 10-26-88

STUDY DIRECTOR

Signature for the Study Dr. J. H. Thyssen

Date 10-26-88

Dr. G. Kaliner

cc: Dr. Luckhaus
Prof. Dr. Kimmerle
Prof. Dr. Schlueter

To: Dr. Machemer
Institute of Toxicology/Agriculture

Re: KWG 0519 - Chronic Mouse Study -
H & W Canada, Flasher 1761-C

Dear Dr. Machemer:

Attached, you will find my professional opinion on the following subjects:

1. The morphology of the carcinosarcomas of the urinary bladder diagnosed in 1982 by the pathologists Saxena and Ehard (Batelle-Institut e.V., Frankfurt am Main, FRG) in two male mice of the high dose group.

2. The nomenclature used by other pathologists for similar urinary bladder changes that are based on my own comparative reexaminations of original histological slide preparations from other chronic mouse studies.

Sincerely yours,
[signed]
G. Kaliner
Aug. 22, 1988

BAYTAN^{R} (KWG 0519) - Chronic Mouse Study (Bayer Report No. 10855) - Carcinosarcomas in the Urinary Bladder (H&W Canada, Flasher 1761-C).

Professional Opinion on the Morphology and Nomenclature of the Urinary Bladder Changes in Question, with 23 Figures in the Appendix.

Preface

The histopathological evaluation of this study was made in 1982 by the pathologists S. C. Saxena and H. Ehard, Batelle-Institut e.V., Frankfurt am Main, FRG. In the urinary bladder wall of two male mice (animals No. 320 and 322) of the high dose group (2000 ppm KWG 0519/kg body weight), they found changes that they termed "carcinosarcomas" and described as "irregular nests of epithelial cells [that] are closely intermixed with malignant spindle cells (pages 251 and 281 of the histopathology report). The mice were of the strain CF1/ W 74, bred by WINKELMANN, in Borchen, FRG (page 4 of Bayer Report No. 10855).

Because of a request for additional information by the Canadian registration authorities (Flasher 1761-C), Mobay would like "a more complete description of the tumor type" and supplementary data for this mouse strain.

Introduction

The following were provided to me: for the description of the carcinosarcomas in the urinary bladder of male mouse No. 320, one slide with two histological urinary bladder sections (sections of mediocre quality); and, for male mouse No. 322, one slide with six histological preparations of the bladder (sections of satisfactory quality). The sections are the originals that the pathologists Saxena and Ehard, Batelle-Institut e.V., Frankfurt am Main, FRG, used to make their diagnoses in 1982. The urinary bladders are stained with H&E.

Description

Mouse No. 320

The transitional epithelium is (artificially) detached from the lamina propria in places and is two to three cell layers thick on the average.

At one site between the lamina propria and muscularis, there is an elongated cell cluster (carcinosarcoma) that does not have a sharp boundary with the neighboring tissue and has no direct contact with the transitional epithelium. Two cell types can be distinguished in the carcinosarcoma. First, large cells, rich in cytoplasm, with vesicular nuclei of different sizes, to some extent bizarre. These cells occasionally resemble epithelioid cells and show no cell borders. They appear in the carcinosarcoma as circumscribed cell nests. The second -- contrasting -- cell type is that of spindle-shaped cells that sometimes resemble fibrocytes. There are multiple transitional forms between the two extremes. Lymphocytes, not only as small foci but also diffusely distributed, can be found in the carcinosarcoma. Small vessels -- some of them are capillaries -- and small foci of extravascular erythrocytes attract attention. Macrophages with yellow-brownish pigment (hemosiderin?) are observed occasionally. The carcinosarcoma has small necrotic foci that are not bounded by tumor cells arranged like palisades, as is the case for a histiocytic sarcoma.

The carcinosarcoma of mouse No. 322 is similarly constructed. It is spatially more extensive and, in contrast to that of animal 320, extends all the way to the serosa as a compact symplasm. Accordingly, it has completely displaced the musculature at this site. Whereas the epithelioid cell nests that are scattered in the lamina propria and some of which are isolated from the remaining carcinosarcomatous symplasm have no contact with the transitional epithelium, at other sites numerous cells similar to fibrocytes lie directly below the transitional epithelium, which is several cell layers thick in this region and is thus hyperplastic. At some places, the impression is obtained that the spindle-shaped cells that run at right angles to the bladder lumen are

the walls of capillaries that conduct erythrocytes and -- with transitional forms -- end in an epithelioid cell nest in the direction of the serosa. In addition, vessel-rich areas are present in the carcinosarcoma that consist of fibrocytes and smooth muscle fibers; the muscle fibers appear to originate from the blood vessels. At some places in the carcinosarcoma, macrophages that phagocytose erythrocytes are present.

Opinion

In the pathology reports on mouse studies available to me, I found the diagnosis "carcinosarcoma" for the urinary bladder only in the above-mentioned report.

However, Report No. 10810 concerning another 2-year study using CF1 mice (pathologists A.J.N. and C.M.W.) contains the information that "a (small) mesenchymal (cell) tumour is seen in the subepithelial tissues" of two male control mice, one male mouse of the low dose group, and one male mouse of the intermediate dose group. For one female mouse of the intermediate dose group, it is noted in the report that "a fibrosarcoma is seen in the subepithelial tissues."

In another report (No. 10103) concerning a 2-year study on CF1 mice (pathologist H.J.W.Ch.), it is stated that a tumor described as a "papillary carcinoma of transitional epithelium with varying degrees of differentiation and multifocal areas of necrosis" was found in only one animal, a male control mouse. The following are cited as nonneoplastic changes: on page C 39 for a male control mouse, "moderate epithelial hyperplasia. Marked hyperplasia of submucosal stromal cells"; on page C 227 for a male mouse of the intermediate dose group, "subepithelial transitional cell nest"; and on page C 369 for a female mouse of the high dose group, a "subepithelial cell nest causing polypous protrusion of epithelium."

In an additional report (No. 10038) concerning another 2-year study on CF1 mice (pathologist G.K.), a tumor was diagnosed that was regarded as a carcinoma in the urinary bladder of just one animal, a male control mouse.

As a supplement to the urinary bladder findings in CF1 mice, the following findings for NMRI mice are of interest as examples: in the report (No. 16329) concerning a 21-month study on NMRI mice (pathologist G.K.), it is stated that urinary bladder tumors were found only in male mice, namely in one control animal, in two mice of the intermediate dose group, and in three mice of the high dose group. The neoplasms were termed stromal tumors. They are described as subepithelial neoplasms that contain the following: cells arranged in the form of nests (some polymorphic cells, some epithelioid cells; but also spindle-shaped cells); occasional focal necroses; and, in places, an argyrophilic fiber network. The transitional epithelium (urothelium) located above the subepithelial tumor is hyperplastic. Here and there the tumor infiltrates the muscularis or projects like a polyp above the other mucosa.

In yet another report (No. 13961) concerning a 21-month study on NMRI mice (pathologist U.M.) it is stated that (small) transitional epithelial carcinomas were found in one male control animal and in two male mice of the low dose group. A spindle cell sarcoma was diagnosed in one male mouse of the high dose group.

From the brief descriptions of the urinary bladder tumors and the mentioned nonneoplastic changes that are contained in the reports by the various pathologists, it can be concluded that the lesions exhibit morphological similarities. Therefore, original histological slide preparations from two studies (Report No. 10810 -mesenchymal cell tumour-, Report No. 16329 -stromal tumor-) were microscopically reexamined and compared with the corresponding histological sections of the KWG 0519 chronic mouse study (Report No. 10855). As a result, it was found that the majority of tumors contained the morphological cell structures (e.g. epithelioid nests and spindle cells) described for the carcinosarcomas

by S. C. Saxena and H. Ehard. Occasional changes represented only structures in which the "irregular nest of epithelial cells" predominated.

In Report No. 10810, it is noted that a fibrosarcoma was found in the subepithelial tissue of one female of the intermediate dose group. This fibrosarcoma is composed of spindle-shaped cells, of small-lumen blood vessels from which spindle-shaped cells radiate, of transitional forms to epithelioid cells that are starting to form a cell nest, of cells that phagocytose erythrocytes, and of (hemosiderin) pigment. The epithelium (unfortunately, incompletely preserved) above the tumor is hyperplastic. Thus, this fibrosarcoma can be regarded as an (early?) manifestation of the neoplasm designated as carcinosarcomas by Saxena and Ehard.

Only a few references to this type of urinary bladder change are found in the literature:

M. Wood and G. M. Bonser ("Tumours of the urinary bladder" in "Pathology of Tumours in Laboratory Animals," ed. by V. S. Turusov, International Agency for Research on Cancer, Lyon, 1979) include in their article an illustration (Fig. 30) of a surgically treated mouse that is quite similar to the epithelioid cell nests described above. In the view of the authors of this report, the epithelial cell nests are consequences of the operative procedure on the urinary bladder (displaced epithelial cells during a pellet implantation). According to Wood and Bonser, the cell nests are not tumors.

The article by J. B. Jacobs et al. (J. B. Jacobs, S. M. Cohen, M. Arai, G. H. Friedell, O. Bulay, and H. K. Urman, "Chemically Induced Smooth Muscle Tumors of the Mouse Urinary Bladder," Cancer Research, 36:2396-2398, 1976) includes an illustration (Fig. 1) that shows cell nests that are roughly identical to those found in our mice. In their summary, the authors write that "occasional submucosal tumors of indeterminate origin and without definite connection to the overlying mucosa

have been reported in mice given various carcinogenic agents." Jacobs et al. used an electron microscope to examine cell nests like these that showed no invasion into the mucosa or muscularis and came to the conclusion that these submucosal tumors originate from smooth muscle fibers.

In summary, it can be stated that the changes designated as carcinosarcoma by Saxena and Ehard correspond to morphological variations that were found in mice of other studies but were named differently (mesenchymal cell tumour, fibrosarcoma, carcinoma, stromal tumor). Since they do not occur frequently, that which they have morphologically in common becomes evident only during a comparative examination of several cases. The changes were found both in control animals and in treated mice of different dose groups and were regarded as random occurrences. On the basis of the different nomenclature used, it can be concluded that examination using a light microscope cannot with certainty identify determinate cells of origin of these subserosal changes.

[signed and dated]
August 22, 1988
Dr. Georg Kaliner
Specialist in Veterinary Pathology

P.S. In regard to Report No. 13961 (pathologist U.M.):
After the above was typed, I was also able to reexamine the original histological slide preparations and sections made later of the three transitional epithelial carcinomas (1 male control mouse and two males of the low dose group) as well as the spindle cell sarcoma diagnosed in one male of the high dose group of this study. The morphology of these four changes is identical to those of the "carcinosarcomas," "mesenchymal (cell) tumours," "and the "stromal tumors."



Fig. 1 BAYTAN^{R} (KWG 0519). Carcinosarcoma in the urinary bladder of male mouse No. 320. The transitional epithelium has been detached from the bladder wall together with a part of the lamina propria. Epithelioid cell nest (arrow). H&E, approx. 40+



Fig. 2 Detail from the carcinosarcoma of mouse No. 320. Necrotic focus (arrow) surrounded by spindle-shaped cells. At the right, a small epithelioid cell nest. H&E, approx. 250+

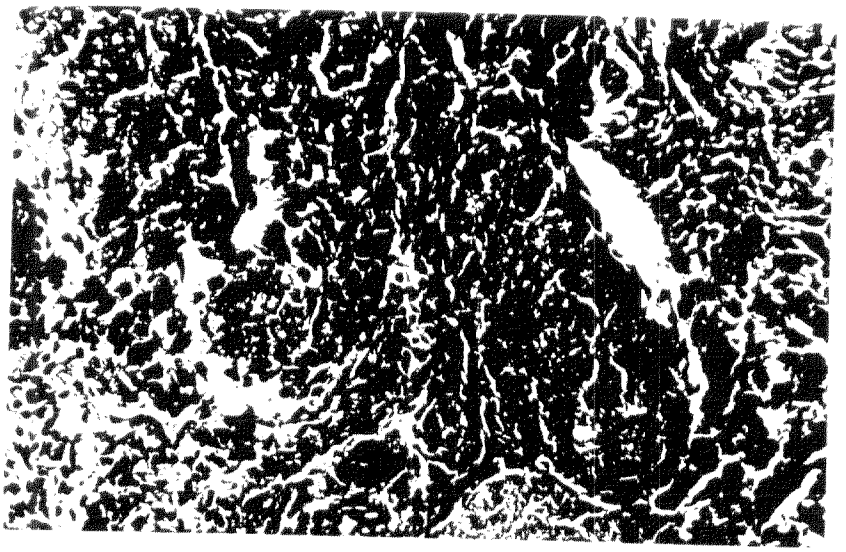

Fig. 3 Detail from the carcinosarcoma of mouse No. 320 with epithelioid and spindle-shaped cells. H&E, approx. 250+

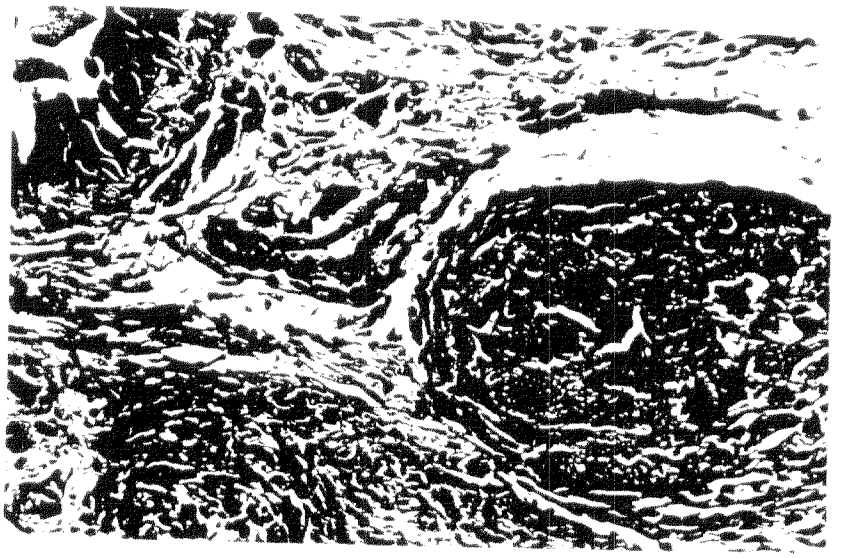

Fig. 4 Detail from the carcinosarcoma of mouse No. 320 with an epithelioid cell nest. At the upper left, the slightly hyperplastic urothelium can be seen. H&E, approx. 250+

Fig. 5 BAYTAN^{R} (KWG 0519). Section from the carcinosarcoma of male mouse No. 322. At the left (arrow), an isolated epithelioid cell next located in the lamina propria. H&E, approx. 40+

Fig. 6 Another section from the carcinosarcoma of mouse No. 322. The tumor has completely displaced the muscularis. The urothelium above the tumorous tissue is clearly hyperplastic in places. At lower left, an area that could suggest a spindle cell sarcoma, fibrosarcoma. H&E, approx. 40+

Fig. 7 Detail from the carcinosarcoma of mouse No. 322. Epithelioid cell nests and spindle-shaped cells. H&E, approx. 100+



Fig. 8 Detail from the carcinosarcoma of mouse No. 322. Spindle-shaped cells from the wall of a capillary (arrow) form an epithelioid cell nest in the direction of the serosa. At the left, hyperplastic urothelium. H&E, approx. 250+

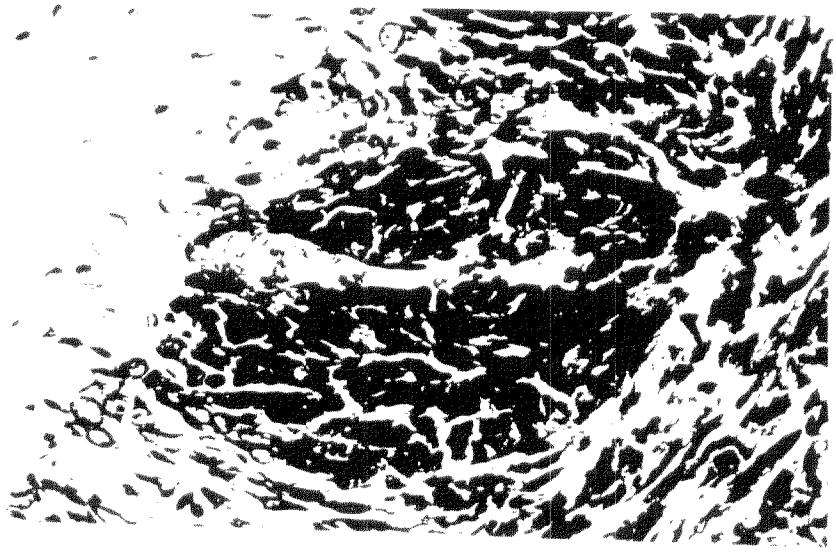

Fig. 9 Detail from the carcinosarcoma of mouse No. 322. Capillary surrounded by spindle-shaped cells. H&E, approx. 400+

Fig. 10 Detail from the carcinosarcoma of mouse No. 322. Two small epithelioid cell nests, into which spindle-shaped cells radiate. H&E, approx. 400+

Fig. 11 Report No. 10810. Male mouse No. 229, intermediate dose group. "A mesenchymal tumour is seen in the subepithelial tissues." Epithelioid cell nest, hyperemic blood vessel (arrow). The urothelium is autolytic and desquamated. H&E, approx. 100+

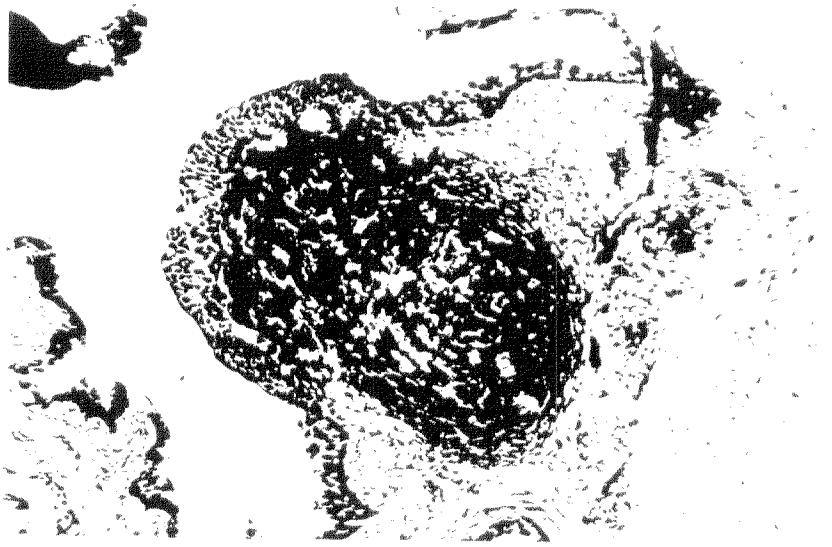

Fig. 12 Report No. 10810. Male mouse No. 149, low dose group. "A small mesenchymal cell tumour is seen in the subepithelial tissues." The cell nest causes the mucosa to protrude polyp-like into the bladder lumen. In the direction of the serosa, spindle-shaped cells can be seen that change into epithelioid cells. H&E, approx. 100+

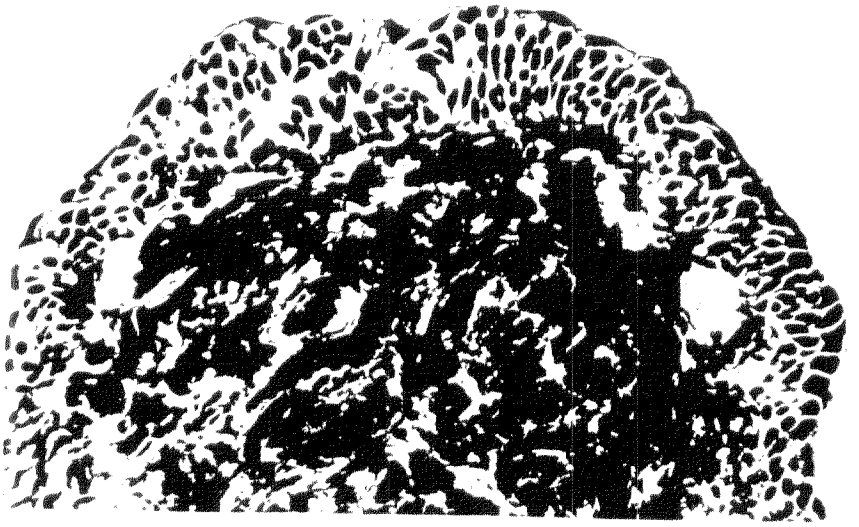

Fig. 13 Detail from the tumor of mouse No. 149. The cell nest is located below the hyperplastic urothelium. H&E, approx. 250+

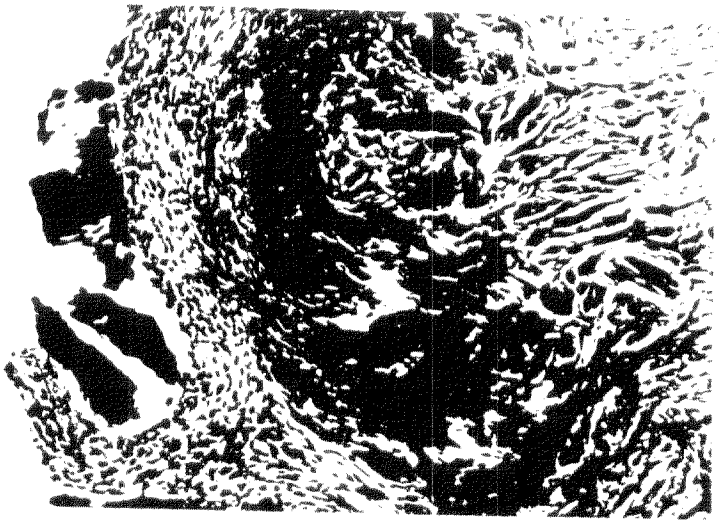

Fig. 14 Report No. 10810. Female mouse No. 272. "A fibrosarcoma is seen in the subepithelial tissues." The urothelium above this change is hyperplastic. H&E, approx. 100+

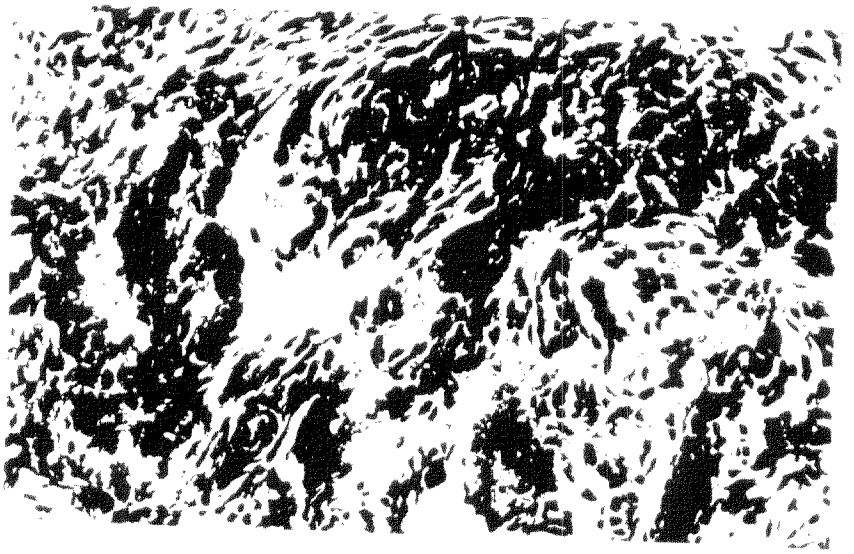

Fig. 15 Detail from the fibrosarcoma of mouse No. 272. In addition to blood vessels and spindle-shaped cells, structures can be identified that resemble incipient epithelioid cell nests. Compare with Fig. 6. H&E, approx. 250+

Fig. 16 Report No. 16389. Male mouse No. 68, control group. "Stromal tumor." The tumor has grown polyp-like into the bladder lumen. H&E, approx. 40+



Fig. 17 Detail from the tumor of mouse No. 68. The tumor contains polymorphic -- in some cases epithelioid -- cells with bizarre nuclei and spindle-shaped cells. The epithelium in the tubular structures (arrow) is cylindrical in places. H&E, approx. 100+

Fig. 18 Report No. 16329. Male mouse No. 189, intermediate dose group. "Stromal tumor" that has caused the mucosa to protrude polyp-like into the bladder lumen. H&E, approx. 40+

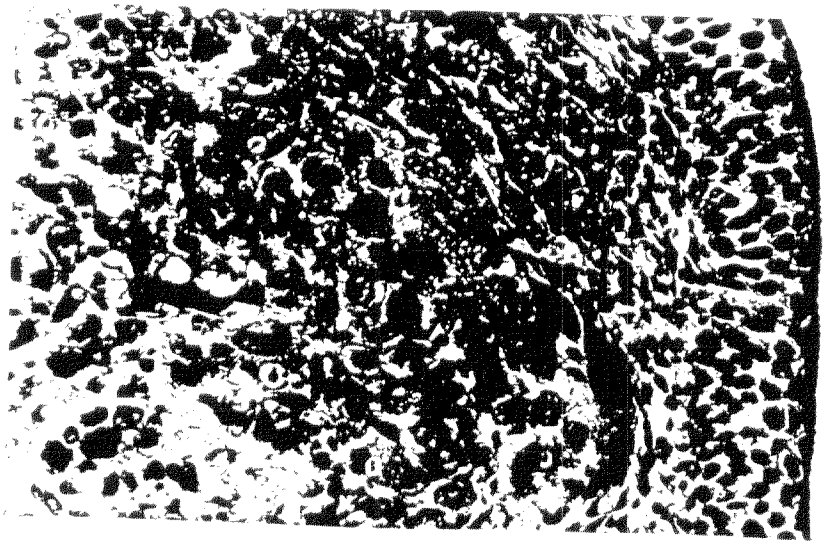

Fig. 19 Detail from the tumor of mouse No. 189. Spindle-shaped cells radiate into the epithelioid cell nest. The urothelium is hyperplastic. H&E, approx. 250+

Fig. 20 Report. No. 16329. Male mouse No. 234, high dose group. The subepithelial "stromal tumor" radiates into the muscularis. Compare Fig. 1. H&E, approx. 40+



Fig. 21 Detail from the tumor of mouse No. 234. Here also spindle-shaped cells radiate into the epithelioid cell nests. The urothelium is hyperplastic. H&E, approx. 100+

Fig. 22 Report No. 16329. Male mouse No. 242, high dose group. A "stromal tumor" located between lamina propria and muscularis. The urothelium is hyperplastic at this site. Compare Fig. 11. H&E, approx. 100+



Fig. 23 Detail from the tumor of mouse No. 242. Spindle-shaped cells and transitional forms; small necrotic focus (arrow). H&E, approx. 400+

88-T-150

Dr. G. Kaliner

cc Dr. Luckhaus
Prof. Dr. Kimmerle
Prof. Dr. Schlueter

Herrn Dr. Machemer
Institut f. Toxikologie / L

KWG 0519 - chronische Maeusestudie -
H & W Canada, Flasher 1761 - C

Lieber Herr Machemer,

als Anlage erhalten Sie meine fachliche Stellungnahme

1. zur Morphologie der 1982 von den Pathologen Saxena und Ehard (Batelle-Institut e.V./Frankfurt/Main) bei zwei maennlichen Maeusen der oberen Dosisgruppe diagnostizierten Carcinosarcome der Harnblase und

2. zu der von anderen Pathologen benutzten Nomenklatur gleicher Harnblasenveraenderungen, die auf eigenen vergleichenden Nachuntersuchungen der histologischen Originalpraeparate anderer chronischer Maeusestudien beruhen.

Mit freundlichem Gruss

J. Kaliner
22.8.88.

cinosarcom bezeichneten Veraenderungen mit morphologischen Variationen bei Maeusen anderer Studien ebenfalls gefunden, aber unterschiedlich bezeichnet wurden (mesenchymal cell tumour, fibrosarcoma, Carcinom, Stromatumor). Da sie nicht haeufig vorkommen, wird das morphologisch Gemeinsame erst bei einer vergleichenden Untersuchung mehrerer Faelle ersichtlich. Die Veraenderungen wurden sowohl bei Kontrolltieren als auch bei behandelten Maeusen unterschiedlicher Dosisgruppen gefunden und als Zufallsbefunde angesehen. Aufgrund der unterschiedlich verwendeten Nomenklatur ist zu schliessen, dass determinierte Ursprungszellen dieser subseroesen Veraenderungen lichtmikroskopisch nicht sicher zu bestimmen sind.

J. Kaliner
22.8.88.

Dr. Georg Kaliner
Fachtierarzt fuer Pathologie

PS. Zum Bericht Nr. 13961 (Pathologe U.M.)
Nach Fertigstellung des Schriftsatzes konnten auch die histologischen Originalpraeparate und Nachschnitte der drei Uebergangsepithelcarcinome (1 maennliches Kontrolltier und zwei maennliche Maeuse der unteren Dosisgruppe) sowie das bei einem maennlichen Tier der oberen Dosisgruppe dieser Studie diagnostizierte Spindelzellsarcom nachuntersucht werden. Die Morphologie dieser vier Veraenderungen ist identisch mit denen der "carcinosarcomas", "mesenchymal (cell) tumours" und den "Stromatumoren".

UNITED STATES ENVIRONMENTAL PROTECTION AGENCY
WASHINGTON, D.C. 20460

Donald W. Lamb, Ph.D.
Vice President, Product Safety & Regulatory Affairs
Miles, Inc.
Mobay Road
Pittsburgh, Pennsylvania 15205-97412

OFFICE OF
PREVENTION, PESTICIDES AND
TOXIC SUBSTANCES

MAR 30 1995

EPA acknowledges the receipt of information submitted by your organization under Section 8(e) of the Toxic Substances Control Act (TSCA). For your reference, copies of the first page(s) of your submission(s) are enclosed and display the TSCA §8(e) Document Control Number (e.g., 8EHQ-00-0000) assigned by EPA to your submission(s). Please cite the assigned 8(e) number when submitting follow-up or supplemental information and refer to the reverse side of this page for "EPA Information Requests".

All TSCA 8(e) submissions are placed in the public files unless confidentiality is claimed according to the procedures outlined in Part X of EPA's TSCA §8(e) policy statement (43 FR 11110, March 16, 1978). Confidential submissions received pursuant to the TSCA §8(e) Compliance Audit Program (CAP) should already contain information supporting confidentiality claims. This information is required and should be submitted if not done so previously. To substantiate claims, submit responses to the questions in the enclosure "Support Information for Confidentiality Claims". This same enclosure is used to support confidentiality claims for non-CAP submissions.

Please address any further correspondence with the Agency related to this TSCA 8(e) submission to:

Document Processing Center (7407)
Attn: TSCA Section 8(e) Coordinator
Office of Pollution Prevention and Toxics
U.S. Environmental Protection Agency
Washington, D.C. 20460-0001

EPA looks forward to continued cooperation with your organization in its ongoing efforts to evaluate and manage potential risks posed by chemicals to health and the environment.

Sincerely,

Terry R. O'Bryan

Terry R. O'Bryan
Risk Analysis Branch

Enclosure 12041A

Recycled/Recyclable
Printed with Soy/Canola Ink on paper that contains at least 50% recycled fiber

Triage of 8(e) Submissions

Date sent to triage: _____ NON-CAP (CAP)

Submission number: 12041A TSCA Inventory: Y N (D)

Study type (circle appropriate):

Group 1 - Dick Clements (1 copy total)

ECO AQUATO

Group 2 - Ernie Falke (1 copy total)

ATOX SBTOX SEN w/NEUR

Group 3 - Elizabeth Margosches (1 copy each)

STOX	(CTOX)	EPI	RTOX	GTOX
STOX/ONCO	CTOX/ONCO	IMMUNO	CYTO	NEUR

Other (FATE, EXPO, MET, etc.): _____

Notes:

THIS IS THE ORIGINAL 8(e) SUBMISSION; PLEASE REFILE AFTER TRIAGE DATABASE ENTRY

Only 1st part of study sent for triage.
Rest of study contains tables of raw data

For Contractor Use Only

entire document: 0 (1) 2 **pages** 1 **pages** 1, 4, 5

Notes:

Contractor reviewer : PR **Date:** 2/15/95

CECATS/TRIAGE TRACKING DBASE ENTRY FORM

CECATS DATA: Submission # 8EHQ- 0992 -12041 SEQ. A

TYPE: (INT.) SUPP FLWP

SUBMITTER NAME: Miles, Inc.

INFORMATION REQUESTED: FLWP DATE:
0501 NO INFO REQUESTED
0502 INFO REQUESTED (TECH)
0503 INFO REQUESTED (VOL ACTIONS)
0504 INFO REQUESTED (REPORTING RATIONALE)

DISPOSITION:
0639 REFER TO CHEMICAL SCREENING
(0678) CAP NOTICE

VOLUNTARY ACTIONS:
(0401) NO ACTION REPORTED
0402 STUDIES PLANNED/UNDERWAY
0403 NOTIFICATION OF WORKER/USER
0404 LABEL/MSDS CHANGES
0405 PROCESS/HANDLING CHANGES
0406 APP/USE DISCONTINUED
0407 PRODUCTION DISCONTINUED
0408 CONFIDENTIAL

SUB. DATE: 04/17/92 OTS DATE: 09/08/92 CSRAD DATE: 01/31/95

CHEMICAL NAME:
1H-1,2,4-triazole-1-ethanol, beta-(4-chlorophenoxy)-alpha-(1,1-dimethylethyl)-
Triadimenol

CAS#
55219-65-3
"
"

BEST COPY AVAILABLE

INFORMATION T		P F C
0201	ONCO (HUMAN)	01 02 04
(0202)	ONCO (ANIMAL)	01 (02) 04
0203	CELL TRANS (IN VITRO)	01 02 04
0204	MUTA (IN VITRO)	01 02 04
0205	MUTA (IN VIVO)	01 02 04
0206	REPRO/TERATO (HUMAN)	01 02 04
0207	REPRO/TERATO (ANIMAL)	01 02 04
0208	NEURO (HUMAN)	01 02 04
0209	NEURO (ANIMAL)	01 02 04
0210	ACUTE TOX. (HUMAN)	01 02 04
0211	CHR. TOX. (HUMAN)	01 02 04
0212	ACUTE TOX. (ANIMAL)	01 02 04
0213	SUB ACUTE TOX (ANIMAL)	01 02 04
0214	SUB CHRONIC TOX (ANIMAL)	01 02 04
(0215)	CHRONIC TOX (ANIMAL)	01 (02) 04

INFORMATION TYPE:		P F C
0216	EPI/CLIN	01 02 04
0217	HUMAN EXPOS (PROD CONTAM)	01 02 04
0218	HUMAN EXPOS (ACCIDENTAL)	01 02 04
0219	HUMAN EXPOS (MONITORING)	01 02 04
0220	ECO/AQUA TOX	01 02 04
0221	ENV. OCCC/REL/FATE	01 02 04
0222	EMER INCI OF ENV CONTAM	01 02 04
0223	RESPONSE REQEST DELAY	01 02 04
0224	PROD/COMP/CHEM ID	01 02 04
0225	REPORTING RATIONALE	01 02 04
0226	CONFIDENTIAL	01 02 04
0227	ALLERG (HUMAN)	01 02 04
0228	ALLERG (ANIMAL)	01 02 04
0239	METAB/PHARMACO (ANIMAL)	01 02 04
0240	METAB/PHARMACO (HUMAN)	01 02 04

INFORMATION TYPE:		P F C
0241	IMMUNO (ANIMAL)	01 02 04
0242	IMMUNO (HUMAN)	01 02 04
(0243)	CHEM/PHYS PROP	01 02 04
0244	CLASTO (IN VITRO)	01 02 04
0245	CLASTO (ANIMAL)	01 02 04
0246	CLASTO (HUMAN)	01 02 04
0247	DNA DAM/REPAIR	01 02 04
(0248)	PROD/USE/PROC	01 02 04
0251	MSDS	01 02 04
0299	OTHER	01 02 04

[redacted]

TRIAGE DATA:	NON-CBI INVENTORY	ONGOING REVIEW	SPECIES	TOXICOLOGICAL CONCERN:	USE:	PRODUCTION:
	YES	YES (DROP/REFER)	MUS	(LOW)	pesticide	
CAS SR	NO	NO (CONTINUE)		MED		
	(IN TERMINI)	REJ-T-R		HIGH		

COMMENTS: Mice received dietary concentrations of 0, 125, 500 and 2000 ppm for 24 months. Triadimenol - fungicide compound. There were no deaths and no signs of toxic effects. Liver damage & related increased tumor incidence were seen at the high dose. Hepatocellular adenomas and carcinomas were noted. The NOAEL was 125 ppm.

CECATS\TRIAGE TRACKING DBASE ENTRY FORM

CECATS DATA:
Submission # 8EHQ- 0992 -12041 SEQ. A

TYPE: INT. SUPP FLWP

SUBMITTER NAME: Miles, Inc.

INFORMATION REQUESTED: FLWP DATE:
0501 NO INFO REQUESTED
0502 INFO REQUESTED (TECH)
0503 INFO REQUESTED (VOL ACTIONS)
0504 INFO REQUESTED (REPORTING RATIONALE)

DISPOSITION:
0639 REFER TO CHEMICAL SCREENING
0678 CAP NOTICE

VOLUNTARY ACTIONS:
0401 NO ACTION REPORTED
0402 STUDIES PLANNED/UNDERWAY
0403 NOTIFICATION OF WORKER/OTHERS
0404 LABEL/MSDS CHANGES
0405 PROCESS/HANDLING CHANGES
0406 APP/USE DISCONTINUED
0407 PRODUCTION DISCONTINUED
0408 CONFIDENTIAL

SUB. DATE: 04/17/92 OTS DATE: 09/08/92 CSRAD DATE: 01/31/95

CHEMICAL NAME:
1H-1,2,4-triazole-1-ethanol, beta-(4-chlorophenoxy)-alpha-(1,1-dimethylethyl)-Triadimenol

CAS#
55219-65-3
"

INFORMATION TYPE:		P F C	INFORMATION TYPE:		P F C	INFORMATION TYPE:		P F C
0201	ONCO (HUMAN)	01 02 04	0216	EPI/CLIN	01 02 04	0241	IMMUNO (ANIMAL)	01 02 04
0202	ONCO (ANIMAL)	01 02 04	0217	HUMAN EXPOS (PROD CONTAM)	01 02 04	0242	IMMUNO (HUMAN)	01 02 04
0203	CELL TRANS (IN VITRO)	01 02 04	0218	HUMAN EXPOS (ACCIDENTAL)	01 02 04	0243	CHEM/PHYS PROP	01 02 04
0204	MUTA (IN VITRO)	01 02 04	0219	HUMAN EXPOS (MONITORING)	01 02 04	0244	CLASTO (IN VITRO)	01 02 04
0205	MUTA (IN VIVO)	01 02 04	0220	ECO/AQUA TOX	01 02 04	0245	CLASTO (ANIMAL)	01 02 04
0206	REPRO/TERATO (HUMAN)	01 02 04	0221	ENV. OCCC/REL/FATE	01 02 04	0246	CLASTO (HUMAN)	01 02 04
0207	REPRO/TERATO (ANIMAL)	01 02 04	0222	EMER INCI OF ENV CONTAM	01 02 04	0247	DNA DAM/REPAIR	01 02 04
0208	NEURO (HUMAN)	01 02 04	0223	RESPONSE REQEST DELAY	01 02 04	0248	PROD/USE/PROC	01 02 04
0209	NEURO (ANIMAL)	01 02 04	0224	PROD/COMP/CHEM ID	01 02 04	0251	MSDS	01 02 04
0210	ACUTE TOX. (HUMAN)	01 02 04	0225	REPORTING RATIONALE	01 02 04	0299	OTHER	01 02 04
0211	CHR. TOX. (HUMAN)	01 02 04	0226	CONFIDENTIAL	01 02 04			
0212	ACUTE TOX. (ANIMAL)	01 02 04	0227	ALLERG (HUMAN)	01 02 04			
0213	SUB ACUTE TOX (ANIMAL)	01 02 04	0228	ALLERG (ANIMAL)	01 02 04			
0214	SUB CHRONIC TOX (ANIMAL)	01 02 04	0239	METAB/PHARMACO (ANIMAL)	01 02 04			
0215	CHRONIC TOX (ANIMAL)	01 02 04	0240	METAB/PHARMACO (HUMAN)	01 02 04			

TOX/ONCO

TRIAGE DATA:	NON-CBI INVENTORY	ONGOING REVIEW	SPECIES	TOXICOLOGICAL CONCERN:	USE:	PRODUCTION:
	YES	YES (DROP/REFER)	MUS	LOW	pesticide	
CAS SR	NO	NO (CONTINUE)		MED		
	DETERMINE	REFER		HIGH		

COMMENTS

-CPSS-

> <ID NUMBER>
8(E)-12041A

> <TOX CONCERN>
L/L

> <COMMENT>
ONCOGENICITY IN MALE AND FEMALE SPF MICE IS OF LOW CONCERN. CHRONIC ORAL EXPOSURE TO 125, 500 AND 2000 PPM EACH FOR 24 MONTHS IN GROUPS OF MICE (50/SEX/GROUP) WERE ASSOCIATED WITH SLIGHTLY REDUCED WEIGHT GAIN AND INCREASED INCIDENCE OF HYPERPLASTIC LIVER NODULES IN MALES AND FEMALES, REACHING STATISTICAL SIGNIFICANCE IN FEMALES (P </= 0.05) OF A 2000 PPM REGIMEN. TIME OF ONSET, INCIDENCE RELATIVE TO DOSAGE AND MULTIPLICITY OF TUMORS DID NOT CONFIRM TREATMENT-INDUCED ONCOGENICITY.

CHRONIC ORAL TOXICITY IN MALE AND FEMALE SPF MICE IS OF LOW CONCERN. CHRONIC ORAL EXPOSURE TO 125, 500 AND 2000 PPM EACH FOR 24 MONTHS IN GROUPS OF MICE (50/SEX/GROUP) WERE ASSOCIATED WITH SLIGHTLY REDUCED WEIGHT GAIN (500, 2000 PPM), REDUCED PLASMA CHOLESTEROL AND TOTAL PROTEIN (2000 PPM), INCREASED PLASMA ENZYME (ALP, GOT AND CPT) ACTIVITY (M,2000 PPM; F,125-2000 PPM), INCREASED LIVER WEIGHTS (2000 PPM) AND INCREASED CYSTIC ANOMALIES OF THE THYROID IN MALES (2000 PPM). NO DOSAGE-RELATED SYSTEMIC TOXICITY WAS IDENTIFIED AND SURVIVAL RATES WERE NOT AFFECTED BY TREATMENT AT ANY DOSAGE LEVEL.

$$$$