Contains NO CBI

RHÔNE-POULENC

TOXICOLOGY DEPARTMENT
P.O. BOX 12014, 2 T.W. ALEXANDER DRIVE
RESEARCH TRIANGLE PARK, NC 27709
(919) 549-2000 TELEFAX (919) 549-8525
INTERNATIONAL TELEX NUMBER 4999378–ANSWERBACK APC RTP

92 OCT -7 AM 8:06

September 14, 1992

CERTIFIED MAIL
RETURN RECEIPT REQUESTED
P 640 082 560

8EHQ-92-12120
INIT
88920010358

Document Processing Center (TS-790)
Office of Toxic Substances
US Environmental Protection Agency
401 M Street, SW
Washington, DC 20460

Attn: Section 8(e) Coordinator (CAP Agreement)

RE: Report Submitted Pursuant to the TSCA Section 8(e) Compliance Audit Program

CAP ID No.: 8ECAP - 0004

Dear Sir/Madam:

On behalf of Rhône-Poulenc Inc. (RPI, CN 5266, Princeton, NJ 08543-5266) and its subsidiary Rhône-Poulenc Ag Company (RPAC), the attached study report is being submitted to the Environmental Protection Agency (EPA) pursuant to the Toxic Substances Control Act (TSCA) Section 8(e) Compliance Audit Program and the Agreement for a TSCA Section 8(e) Compliance Audit Program (CAP Agreement) executed by RPI and EPA.

The enclosed study report provides information on ioxynil. The CAS number assigned to this compound is 1689-83-4. The CAS name is 4-hydroxy-3,5-diiodobenzonitrile. This chemical was manufactured in Europe and imported by RPAC for pesticide research and development. We have never filed a pesticide application to EPA under the Federal Insecticide, Fungicide, and Rodenticide Act.

No claims of confidentiality are made for this submission. The title of the enclosed report is "Ioxynil: Acute Inhalation Toxicity in Rats 4-Hour Exposure". The following is a summary of the adverse effects observed in this study.

This study is being submitted under Section 8(e) because the 4 hour LC50 was 0.38 mg/l and thus, would be classified by EPA under TSCA Section 8(e) as extremely toxic. Abnormal breathing and brown staining were observed during exposure.

No previous TSCA Section 8(e) notices have been submitted on this chemical, but seven submissions will be made on ioxynil under the CAP. In total, RPI is submitting three copies of the enclosed report and this cover letter: an original and two copies.

RECEIVED 1/26/95

IOX-TP-85-0001

CONFIDENTIAL

M&B 204P/84563

IOXYNIL

ACUTE INHALATION TOXICITY

IN RATS

4-HOUR EXPOSURE

Addressee:

Mr. B. Ingham,
May and Baker Limited,
DAGENHAM,
Essex.
RM10 7XS

23 January 1985

Authors:

Graham C. Jackson,
Colin J. Hardy,
Pamela A. Mullins,
David J. Lewis.

Huntingdon Research Centre plc,
HUNTINGDON,
Cambridgeshire.

We the undersigned, hereby declare that the work was performed under our supervision according to the procedures herein described, and that this report provides a correct and faithful record of the results obtained.

Graham C. Jackson, B.A., L.R.S.C.,
Senior Scientific Officer,
Department of Inhalation Toxicology

Colin J. Hardy, B.Sc., Ph.D., M.I.Biol.,
Head of Industrial Chemicals Unit,
Department of Inhalation Toxicology

Pamela A. Mullins, B.Sc., Ph.D.,
Pathologist

David J. Lewis, B.Sc., Ph.D., M.I.Biol., M.R.C.Path.,
Senior Pathologist

Chirukandath Gopinath, B.V.Sc., M.V.Sc., Ph.D., M.R.C.Path.,
Director of Pathology

COMPLIANCE WITH GOOD LABORATORY PRACTICE STANDARDS

HRC Report No. M&B 204B/84563

To the best of our knowledge and belief the study described in this report was conducted in compliance with the following Good Laboratory Practice Standards:

United States Environmental Protection Agency, Title 40 Code of Federal Regulations Part 160, Federal Register, 29 November 1983.

Organisation for Economic Co-operation and Development, ISBN 92-64-12367-9, Paris 1982.

Japan Ministry of Agriculture, Forestry and Fisheries, 59 NohSan, Notification No. 3850, Agricultural Production Bureau, 10 August 1984.

C. J. Hardy

23.1.85

Colin J. Hardy, B.Sc., Ph.D., M.I.Biol.,
Study Director
Huntingdon Research Centre

QUALITY ASSURANCE AUDIT STATEMENT

HRC REPORT No. M+B 204B/84563

This report has been audited by HRC Quality Assurance Unit. It is considered to be an accurate description of the procedures and practices employed during the course of the study and an accurate presentation of the findings.

Kenneth W.G. Shillam, B.Sc., Ph.D., F.I.Biol.
Director, Quality Assurance

27.1.85

Audit notes

Short reports and some parts of other reports are audited completely. Large amounts of data are verified by means of sampling methods as described in British Standards Institution BS 6000, 6001 (1972) and US Military Standard 105D, the Acceptable Quality Level (the maximum percentage errors considered satisfactory as a process average) being 0.4.

Any computerised presentations which are the outcome of verified entry direct from the raw data and which are secure against manual alteration are not normally audited.

The findings of any investigations made by the sponsor and which are included in HRC reports are audited using the sponsor's report to HRC.

HRC

DATES OF QAU STUDY INSPECTIONS

HRC Report No. M+B 204B/84563

Inspections were made by the Quality Assurance Unit of the various phases of the study described in this Report. The dates on which inspections were made and the dates on which the findings were reported to the Study Director and to HRC Management are given below:

Phase of Study	Date of Inspection*	Date of Reporting
Protocol Review	-	10.4.84
Pre-experimental Period		
Experimental Period	5.4.84	10.4.84
"		
"		
"		
"		
"		
"		
"		
"		
"		
"		
"		
"		
"		
"		
"		
Post experimental Period		
Final Report Audit	-	22.1.85

K.W.G. Shillam 22.1.85
Director,
Quality Assurance Unit

*Week beginning. This has been adopted to avoid the presentation of excessive dates in instances of an inspection being conducted over several days.

Dates on which any 'process-based' inspections were made while the study was in progress are not included in the above listing.

CONTENTS

		Page	
SUMMARY	i	-	ii
INTRODUCTION		1	
MATERIALS AND METHODS			
Test substance		2	
Animals and maintenance		2	
Inhalation exposures		3	
Exposure system		3	
Procedure		4	
Chamber atmosphere analyses	4	-	5
Chamber air temperatures		5	
Relative humidity		5	
Observations	5	-	6
Terminal studies		6	
Estimation of the LC_{50} (4-hour) and standard error		6	
RESULTS			
Chamber atmosphere conditions			
Concentrations of ioxynil		7	
Particle size distribution		7	
Chamber air temperature		7	
Relative humidity		8	
Clinical observations			
Mortality		8	
Clinical signs	8	-	9
Bodyweight		9	
Food consumption		9	
Water consumption		9	
Terminal studies			
Lung weight to bodyweight ratio		10	
Estimation of the LC_{50} (4-hour) for ioxynil		10	
Macroscopic pathology		10	
Microscopic pathology		11	
FIGURES			
1. Wright dust generator		12	
2. Exposure system		13	

Page

TABLES

1.	Concentration of ioxynil in air		14	
2.	Particle size distribution of ioxynil	15	-	16
3.	Clinical signs during exposure		17	
4.	Clinical signs during observation period		18	
5.	Individual and group mean bodyweights (g)	19	-	23
6a.	Food consumption (g/rat) : male rats		24	
6b.	Food consumption (g/rat) : female rats		24	
7a.	Water consumption (g/rat) : male rats		25	
7b.	Water consumption (g/rat) : female rats		25	
8.	Lung weight to bodyweight ratios	26	-	28

APPENDICES

1.	Determination of ioxynil in air samples	29	-	30
2.	Pathological data relating to individual rats	31	-	75

Test substance: Ioxynil.

Test animals: Albino rats, HC/CFHB (Wistar). One control group and 4 test groups each of 5 male and 5 female rats.

Route of administration: By inhalation of a test atmosphere containing a respirable dust generated from the test substance.

Duration of exposure: 4 hours continuous exposure in a head only exposure system.

Observation period: 14 days post exposure.

Results

Concentration of ioxynil and mortality:

Ioxynil mg/l	Mortality Males	Females	Total
0.18	0/5	0/5	0/10
0.36	2/5	1/5	3/10
0.49	3/5	4/5	7/10
0.69	5/5	5/5	10/10

Clinical signs:

(a) During exposure

Abnormal breathing and brown staining around the snout were observed in a proportion of rats exposed to ioxynil.

(b) During the observation period

Brown staining around the snout or brown staining of the body fur were observed in a proportion of rats exposed to ioxynil. Abnormal breathing was observed, on the day following exposure, in 4/5 male rats and 5/5 female rats exposed to ioxynil at 0.18 mg/l (Group 7).

Bodyweights:	Small to moderate losses of bodyweight were observed on the day following exposure to ioxynil.
Food consumption:	Food consumption was reduced for 1 day in male rats and 1-2 days in female rats following exposure to ioxynil.
Water consumption:	Water consumption for female rats was increased for 2-3 days following exposure to ioxynil. Water consumption for male rats exposed at 0.49 mg/l (Group 10) was increased for 2 days.
Lung weight to bodyweight ratio:	Within normal limits for rats surviving exposure to ioxynil. High value (>0.8) for 50% of rats dying as a result of exposure.
LC_{50} (4-hour) for ioxynil:	0.38 mg/l of air. Standard error 0.044 mg/l.
Macroscopic pathology:	Lungs congested in rats that died as a result of exposure to ioxynil. Occasionally the lungs were of swollen appearance and/or fluid was found in the trachea.
Microscopic pathology:	There were no abnormalities attributable with certainty to exposure to ioxynil.

INTRODUCTION

The acute inhalation toxicity of ioxynil was assessed by exposing groups of rats to atmospheres containing ioxynil. Each group received a single 4-hour exposure to ioxynil at a concentration between 0.18 and 0.69 mg/l of air.

On completion of the study all data relating to the study, all preserved tissues and a copy of this report were lodged in the Huntingdon Research Centre Archives, Huntingdon, Cambridgeshire.

MATERIALS AND METHODS

Test substance

The test substance was a buff coloured powder identified as:

IOXYNIL Batch No. 070941.

The sample was supplied by the Sponsor and was received on 24 February 1984. The sample was stored at room temperature.

This substance is adequately stable for use in this study (Pesticide Manual 6th Edition p. 305).

Animals and maintenance

Twenty-five male and 25 female albino rats, HC/CFHB (Wistar), about 6 weeks and 8 weeks old respectively, were obtained from Hacking and Churchill Limited, Huntingdon, Cambridgeshire.

On the day of arrival the male rats weighed between 120 and 154 g and female rats weighed between 158 and 174 g. The rats were allocated to one of 5 groups, each of 5 male and 5 female rats and were identified individually by a number tattooed on the tail. The rats were housed 5 of like sex to a cage.

The cages were made of polypropylene (size 38 cm x 56 cm x 18 cm height) and had detachable wire mesh tops and floors. The cages were suspended on a movable rack. While in their cages all rats had free access to a measured excess amount of food (Spratt's Laboratory Diet 1) and tap water. Food and water supplied were analysed routinely to determine the levels of chemical or microbiological contaminants.

The rats remained in a holding room except for the 4-hour exposure and an overnight post exposure period when the rats were kept in a ventilated cabinet to allow dispersal of any residual test substance.

The mean daily maximum and minimum temperatures of the holding room over the periods of the study were:

Dates	Groups	Mean maximum	Mean minimum	Relative humidity
30/3/84 - 19/4/84	1 and 3	23°C (0.5)	21°C (0.6)	34% (4.5)
19/4/84 - 10/5/84	7 and 8	23°C (0.8)	21°C (0.6)	35% (3.5)
4/5/84 - 23/5/84	10	22°C (1.3)	20°C (0.9)	40% (6.3)

Figures in parentheses are the standard deviation of the mean

Inhalation exposures

Four groups of rats were exposed continuously for 4 hours each to a different concentration of ioxynil in air.

An additional group acting as a control received clean air only for 4 hours.

The group identification and dates of exposure were:

Group 1	(Control)	5 April 1984
Group 3	(Test)	6 April 1984
Group 7	(Test)	25 April 1984
Group 8	(Test)	26 April 1984
Group 10	(Test)	9 May 1984

Group 1 was also used as a control for a study with bromoxynil.

Exposure system

Dust generator

A Wright dust generator[1] was used to produce test atmospheres containing ioxynil.

The construction of the generator is shown in Figure 1.

The generator was designed to produce and maintain an atmosphere containing dust by suspending material scraped from the surface of a compressed powder in a stream of dry air.

The concentration of dust in the atmosphere may be varied by selecting different gear ratios for the generator mechanism.

Exposure chambers

The head-only exposure chambers were of cylindrical form (35.5 cm i.d., 38.5 cm height) and made of perspex. The chambers were fitted with a hemispherical perspex top giving an enclosed volume of approximately 50 litres. The rats were held for exposure in perspex restraining tubes (22 cm x 6 cm i.d.) which were attached at evenly spaced ports in the cylindrical section of the chamber, and were designed to allow only the snout to project into the chamber. Each rat was restrained in a forward position by an adjustable plastic stopper which also provided a seal for the tube.

The test atmosphere entered through a tube located at the base centre of the chamber and passed out through small holes in the lower edge of the cylindrical section. Each chamber was installed in a large fume cupboard exhausting to atmosphere through an absolute filter.

The exposure system is shown in Figure 2.

[1] Wright B. M. J. Sci. Inst. 27(1) p12 (1950)

Procedure

A sample of Ioxynil was packed into the container of the Wright dust generator using an hydraulic bench press to assist packing. Even density of the powder was achieved by packing the container in stages and applying a force of approximately 0.2 tons weight.

The dust generator was positioned on a stand below the exposure chamber and was connected using a polypropylene tube (15 cm x 1 cm i.d.) to the inlet port of the chamber. The top of the tube was approximately 5 cm above the base of the chamber.

A supply of clean dried compressed air was connected to the dust generator and the supply pressure was adjusted to give a flow rate of 15 litres per minute measured at the generator outlet tube. The total chamber air supply was derived from the air flow through the dust generator.

A group of rats to be exposed to ioxynil (5♂ and 5♀) were placed in restraining tubes. The tubes were attached at selected ports on the chamber and unused ports were sealed.

The powder container of the Wright dust generator was advanced manually until a trace of suspended dust was seen at the top of the inlet tube. The gearing on the generator was then engaged and the generator motor switched on to start the exposure. After a 12-minute equilibration period[1] the exposure was timed for 4 hours.

The generator was then switched off and the rats were removed from the restraining tubes. The rats were examined and returned to the holding cages.

The procedure was repeated for the other test groups. The control group was treated similarly but received clean air only for 4 hours.

Following exposure the rats were held overnight in a ventilated cabinet and then returned to the holding room for the remainder of the observation period.

(1) 12 minutes is the theoretical time required for the concentrations of aerosol to reach 90% of its final value under the conditions of exposure employed

Chamber atmosphere analyses

Five or six air samples were taken from the chamber during each exposure and analysed to determine the concentration of ioxynil.

The samples were drawn through a Whatman GF/A glass fibre filter, mounted in an open face filter holder, at a rate of 2 litres per minute. The volume of the air sample was measured with a wet type gas meter.

Two further air samples were taken using an Andersen mini sampler[1] and the material collected by each stage was analysed to determine the particle size distribution of ioxynil in the chamber atmosphere.

At a sampling rate of 1.4 litres per minute, the collection characteristics of the Andersen sampler are:

Stage 1 - Particles larger than 5.5 µm mean aerodynamic diameter (a.d.)
Stage 2 - Particles between 3.5 µm and 5.5 µm mean a.d.
Stage 3 - Particles between 2.0 µm and 3.5 µm mean a.d.
Stage 4 - Particles between 0.3 µm and 2.0 µm mean a.d.
Filter - Particles smaller than 0.3 µm a.d.

The method used to determine the amount of ioxynil in the air samples is described in Appendix 1.

Chamber air temperatures

The air temperature in the exposure chamber was measured with a mercury-in-glass thermometer and recorded at the start of the exposure and then at 30-minute intervals during the 4-hour exposure.

Relative humidity

The concentration of water vapour in the chamber air was monitored using an Analytical Development Co., Ltd., water vapour analyser, model 225, and recorded at 30-minute intervals.

The relative humidity was calculated from the recorded data for the water vapour content and temperature of the chamber air.

Observations

Clinical signs

The rats were observed continuously for signs of reaction to ioxynil exposure and at least twice daily throughout the observation period.

Bodyweight

All rats were weighed daily from the day of delivery to the Huntingdon Research Centre until the end of the observation period.

(1) Andersen 2000 Inc.,

Food and water consumption

The amount of food and water consumed by each cage of rats was measured daily from the day following arrival. The mean daily intake of food and water for each rat was calculated from the recorded data.

Terminal studies

At the end of the 14-day observation period the rats were anaesthetised by intraperitoneal injection of pentobarbitone sodium and killed by exsanguination.

The rats were subjected to a detailed macroscopic examination. The lungs were removed, dissected clear of surrounding tissue and weighed in order to calculate the lung weight to bodyweight ratio.

The lungs were infused with, and preserved in, buffered 10% formalin together with samples of the liver and kidneys for microscopic examination.

The formalin fixed tissues from the control and test groups in which the mortality was less than 100% were processed routinely and embedded in paraffin wax. 5 µm sections of the tissues were prepared, stained with haematoxylin and eosin and examined microscopically.

Estimation of the LC_{50} (4-hour) and standard error

The concentration of ioxynil likely to cause death in 50% of exposed rats within 14 days following a single 4-hour exposure was calculated by the log probit method of Miller and Tainter(1).

The standard error was calculated from the formula:

$$\text{SE of } LC_{50} = \frac{2s}{\sqrt{2N}}$$

where 2s is the estimated increment in concentration of the test substance between probits 4.0 and 6.0 corresponding to 16% and 84% mortality and N is the total number of rats in groups with mortality between 6.7% and 93.3%.

(1) Miller, L.C. and Tainter, M.L., Proc. Soc. Exp. Biol. Med. 57, (2), 1944, pp 261-264

CHAMBER ATMOSPHERE CONDITIONS

Concentration of ioxynil

The analysis results for the air samples taken during the exposures to ioxynil are shown in Table 1. The mean concentrations during exposure for each group was:

Group	Ioxynil (mg/l)	Standard deviation
3	0.69	0.109
7	0.18	0.009
8	0.36	0.019
10	0.49	0.047

The variations (100 x range of values/mean) were generally within acceptable limits (<30%). The larger variation in concentration during the exposure of Group 3 (0.69 mg/l) was due to a low analysis result for sample 5.

Particle size distribution

The results for the air samples taken for determination of the particle size distribution of ioxynil in the chamber air are given in Table 2.

The results show that between 27 and 41% of the ioxynil was of respirable size (<5.5 µm aerodynamic diameter).

Chamber air temperature

The mean chamber air temperatures, and the standard deviation of the means, during exposure of the groups were:

Group	Mean °C	Standard deviation
1 (Control)	24.0	0.11
3 (0.69 mg/l)	24.8	0.31
7 (0.18 mg/l)	24.1	0.96
8 (0.36 mg/l)	25.1	0.80
10 (0.50 mg/l)	23.6	0.39

There were no differences in temperature considered likely to have any effect on the results of the study.

Relative humidity

The mean relative humidities of the chamber air, and the standard deviation of the means, during the exposures were:

Group	Relative humidity %	Standard deviation
1 (Control)	52.7	3.60
3 (0.69 mg/l)	29.5	4.27
7 (0.18 mg/l)	28.4	2.80
8 (0.36 mg/l)	26.4	3.18
10 (0.50 mg/l)	23.3	2.75

CLINICAL OBSERVATIONS

Mortality

The mortality is summarised in the following table:

Group	Ioxynil in air mg/l	Mortality Number dead/number exposed Males	Females	Total
1	0	0/5	0/5	0/10
3	0.69	5/5	5/5	10/10
7	0.18	0/5	0/5	0/10
8	0.36	2/5	1/5	3/10
10	0.49	3/5	4/5	7/10

Time of deaths

Group 3 (0.69 mg/l): 4 males and 4 females died during exposure. 1 male died within 1 hour post exposure. 1 female died overnight following exposure.
Group 8 (0.36 mg/l): 1 female died during exposure. 1 male died within 1 hour post exposure. 1 male died overnight following exposure.
Group 10 (0.49 mg/l): 1 male died during exposure. 2 males and 2 females died overnight and were found dead on Day 1 of the observation period. 2 females died overnight and were found dead on Day 2 of the observation period.

Clinical signs

(a) During exposure

The incidence of clinical signs observed during exposure is shown in Table 3.

Due to the method of restraint few clinical signs are readily observed.

Abnormal breathing and brown staining around the snout were observed in a proportion of rats exposed to ioxynil.

(b) During the observation period

The incidence of clinical signs seen during the observation period is shown in Table 4. Column 0 of this table shows the observations made when the rats were removed from the restraining tubes.

Brown staining around the snout or brown staining of the body fur were observed in a proportion of rats exposed to ioxynil.

Abnormal breathing was observed in 4/5 male rats and 5/5 female rats on the day following exposure to ioxynil at 0.18 mg/l (Group 7).

Bodyweight

The individual and group mean bodyweights are shown in Table 5.

Small to moderate losses of bodyweight were observed on the day following exposure to ioxynil.

Subsequently weight gain for the surviving rats was similar to that for the control rats.

Food consumption

The food consumption data are presented in Tables 6a and 6b for male and female rats respectively.

Food consumption was reduced for 1 day in male rats and for 1-2 days in female rats following exposure to ioxynil.

Water consumption

The water consumption data are presented in Tables 7a and 7b for male and female rats respectively.

The water consumption for female rats was increased for 2-3 days following exposure to ioxynil. The water consumption for male rats exposed to ioxynil at 0.49 mg/l (Group 10) was slightly increased for 2 days following exposure.

TERMINAL STUDIES

Lung weight to bodyweight ratio

The lung weight to bodyweight ratio for individual rats is shown in Table 8.

The lung weight to bodyweight ratio was within normal limits for all rats surviving exposure to ioxynil.

High values (>0.8) due to increased lung weight were found for 50% of rats dying as a result of exposure to ioxynil.

Estimation of the LC_{50} (4-hour) for ioxynil

From the mortality data, for exposure levels of 0.18 to 0.69 mg/l, the LC_{50} (4-hour) for ioxynil in the form of an aerosol is established at 0.38 mg/l of air.

The standard error of the estimate is 0.044 mg/l.

Macroscopic pathology

The macroscopic pathology for individual rats is included in Appendix 2.

The following comments are made in summary:

The lungs were congested in the majority of rats that died following exposure to ioxynil.

The lungs of 5/7 rats that died following exposure to ioxynil at 0.49 mg/l (Group 10) had a swollen appearance and fluid was found in the trachea of 3 of these rats.

Areas of congestion were found in the lung of rat 215♂ surviving exposure to 0.18 mg/l (Group 7).

The macroscopic appearance of internal organs in all other rats was normal.

Microscopic pathology

Histopathological findings for individual rats are described in detail in Appendix 2.

The following comments are made in summary.

Lungs

The congestion seen in 2/3 decedent rats receiving 0.36 mg/l ioxynil, and the 7 decedent rats receiving 0.49 mg/l ioxynil, all of which died as a result of exposure to the aerosol, was probably of post mortem origin and of no toxicological significance.

Incidental findings of no toxicological significance

Lungs

Arterial medial calcification in rat 218♀ (0.18 mg/l).

Liver

Focus of hepatocyte necrosis with associated mixed inflammatory cells in rat 214♂ (0.18 mg/l);

vacuolation of centrilobular hepatocytes in rat 221♂ (decedent, 0.36 mg/l);

focus of inflammatory cells in rat 228♀ (0.36 mg/l).

Kidneys

Dilated/basophilic tubules with or without associated inflammatory cells/inflammation/fibrosis in 6/10 rats receiving air (Control), 6/10 rats receiving 0.18 mg/l, 6/10 rats (including 2 decedents) receiving 0.36 mg/l and 3/10 rats (including 2 decedents) receiving 0.49 mg/l;

focal mineralisation at the corticomedullary junction in rats 70♀ (air, Control), 227♀, 229♀, 228♀, 230♀ (0.36 mg/l), 226♀ (decedent, 0.36 mg/l) and 260♀ (decedent, 0.49 mg/l);

pyelitis with associated hyperplasia of transitional epithelium in rat 227♀ (0.36 mg/l).

FIGURE 1

Wright dust generator

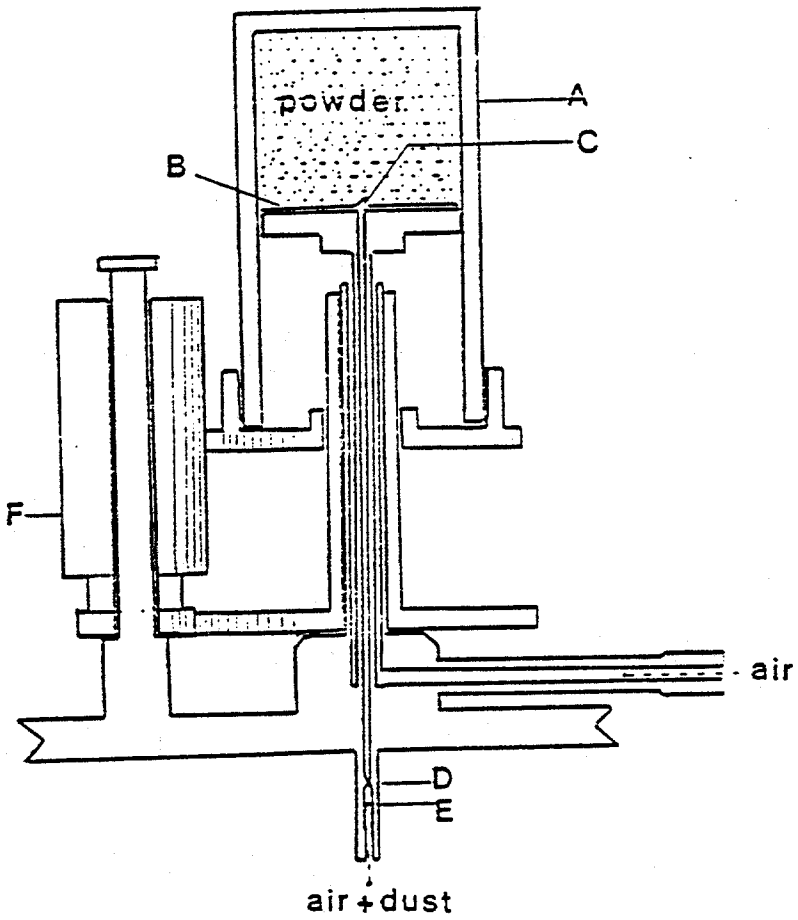

A Powder container
B Scraper blade
C Outlet tube
D Outlet nozzle
E Baffle plate
F Gear mechanism
(driven by a synchronous motor)

FIGURE 2

Exposure system

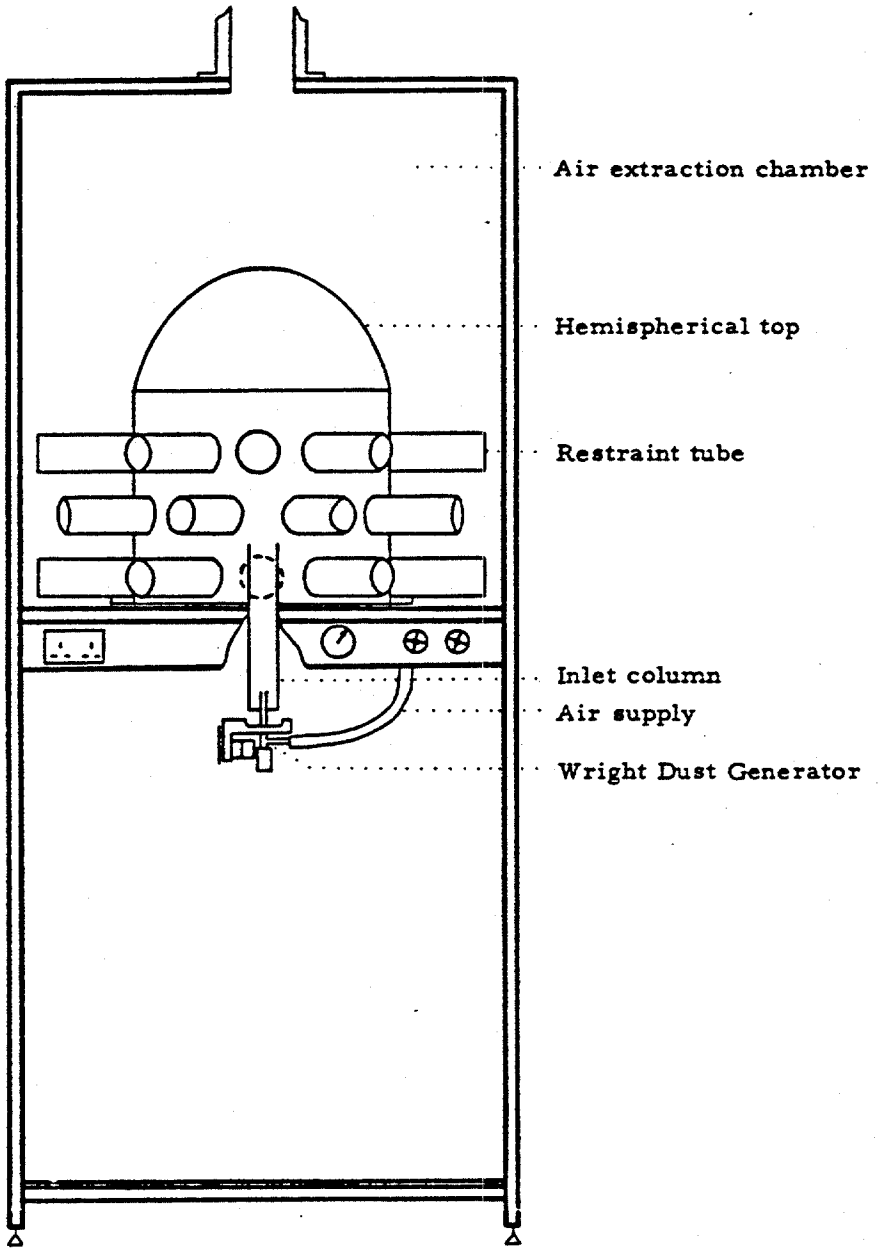

TABLE 1

Concentration of ioxynil in air samples

Group	Sample	Time taken	Ioxynil in air (mg/l)	Standard deviation
3	3.1	0h:25m	0.716	
	3.2	0h:57m	0.640	
	3.3	2h:06m	0.790	
	3.4	2h:49m	0.765	
	3.5	3h:52m	0.520	
		Mean	0.69	0.109
7	7.1	0h:30m	0.174	
	7.2	0h:55m	0.180	
	7.3	2h:03m	0.175	
	7.4	3h:00m	0.197	
	7.5	3h:39m	0.182	
		Mean	0.18	0.009
8	8.1	0h:29m	0.339	
	8.2	0h:54m	0.363	
	8.3	1h:53m	0.340	
	8.4	2h:58m	0.372	
	8.5	3h:53m	0.382	
		Mean	0.36	0.019
10	10.1	0h:30m	0.466	
	10.2	0h:54m	0.451	
	10.3	1h:50m	0.518	
	10.4	2h:59m	0.518	
	10.5	3h:45m	0.519	
		Mean	0.49	0.033

TABLE 2

Particle size distribution

Group	Sample	Time taken	Stage	Particle size range (µm)	Amount collected (mg)	% of total	% respirable
3	PSD 1	1h:36m	1	>5.5	2.823	68.02	
			2	3.5-5.5	1.071	25.81	
			3	2.0-3.5	0.221	5.33	
			4	0.3-2.0	0.011	0.27	
			Filter	<0.3	0.024	0.58	
				Totals	4.150	100.01	31.99
	PSD 2	3h:24m	1	>5.5	2.521	75.64	
			2	3.5-5.5	0.596	17.88	
			3	2.0-3.5	0.192	5.76	
			4	0.3-2.0	0.003	0.09	
			Filter	<0.3	0.021	0.63	
				Totals	3.333	100.00	24.36
7	PSD 1	1h:30m	1	>5.5	2.250	59.32	
			2	3.5-5.5	0.615	16.21	
			3	2.0-3.5	0.671	17.69	
			4	0.3-2.0	0.205	5.40	
			Filter	<0.3	0.052	1.37	
				Totals	3.793	99.99	40.67
	PSD 2	3h:20m	1	>5.5	2.594	59.62	
			2	3.5-5.5	0.932	21.42	
			3	2.0-3.5	0.633	14.55	
			4	0.3-2.0	0.156	3.59	
			Filter	<0.3	0.036	0.83	
				Totals	4.351	100.01	40.39

TABLE 2

(continued)

Group	Sample	Time taken	Stage	Particle size range (µm)	Amount collected (mg)	% of total	% respirable
8	PSD 1	1h:28m	1	>5.5	2.748	71.96	
			2	3.5-5.5	0.706	18.49	
			3	2.0-3.5	0.260	6.81	
			4	0.3-2.0	0.067	1.75	
			Filter	<0.3	0.038	1.00	
				Totals	3.819	100.01	28.05
	PSD 2	3h:21m	1	>5.5	3.112	74.10	
			2	3.5-5.5	0.719	17.12	
			3	2.0-3.5	0.296	7.05	
			4	0.3-2.0	0.047	1.12	
			Filter	<0.3	0.026	0.62	
				Totals	4.200	100.01	25.91
10	PSD 1	1h:22m	1	>5.5	3.985	68.14	
			2	3.5-5.5	1.419	24.26	
			3	2.0-3.5	0.362	6.19	
			4	0.3-2.0	0.054	0.92	
			Filter	<0.3	0.028	0.48	
				Totals	5.848	99.99	31.85
	PSD 2	3h:27m	1	>5.5	3.048	69.41	
			2	3.5-5.5	1.016	23.14	
			3	2.0-3.5	0.247	5.63	
			4	0.3-2.0	0.047	1.07	
			Filter	<0.3	0.033	0.75	
				Totals	4.391	100.00	30.59

TABLE 3

Clinical signs during exposure

Group	Signs	Number showing signs									
		Time in hours									
		0	0.25	0.5	1.0	1.5	2.0	2.5	3.0	3.5	4.0
1♂ (Control)	Normal appearance and behaviour	5	5	5	5	5	5	5	5	5	5
1♀ (Control)	Normal appearance and behaviour	5	5	5	5	5	5	5	5	5	5
3♂ (0.69 mg/l)	Abnormal respiratory pattern				4	5	5	5	4	1	1
	No signs visible	5	5	5	1						
3♀ (0.69 mg/l)	Abnormal rsepiratory pattern				5	5	5	5	5	3	1
	No signs visible	5	5	5							
7♂ (0.18 mg/l)	Abnormal respiratory pattern					3	5	5	5	5	5
	No signs visible	5	5	5	5	2					
	Brown staining around snout									1	3
7♀ (0.18 mg/l)	Abnormal respiratory pattern					2	5	5	5	5	5
	No signs visible	5	5	5	5	3					
	Brown staining around snout										1
8♂ (0.36 mg/l)	Abnormal respiratory pattern					1	3	5	5	5	5
	No signs visible	5	5	5	5	4	2				
	Brown staining around snout						1	1	1	1	1
8♀ (0.36 mg/l)	Abnormal respiratory pattern					2	3	5	5	5	4
	No signs visible	5	5	5	5	3	2				
	Brown staining around snout					1	2	2	2	2	3
	Dead										1
10♂ (0.49 mg/l)	Abnormal respiratory pattern					1	4	4	5	5	4
	Brown staining around snout			1	1	1	1	1	1	2	1
	No signs visible	5	5	4	4	4	1	1			
10♀ (0.49 mg/l)	Abnormal respiratory pattern					3	5	5	5	5	5
	Brown staining around snout				1	1	1	1	1	1	1
	No signs visible	5	5	5	4	1					

TABLE 4

Clinical signs during observation period

Group	Signs	Number showing signs														
		Day of observation period														
		0	1	2	3	4	5	6	7	8	9	10	11	12	13	14
1♂ (Control)	Normal appearance and behaviour	5	5	5	5	5	5	5	5	5	5	5	5	5	5	5
1♀ (Control)	Normal appearance and behaviour	5	5	5	5	5	5	5	5	5	5	5	5	5	5	5
3♂ (0.69 mg/l)	Normal appearance and behaviour															
	Lethargic	1														
	Test material on snout	1														
	White discharge from snout	1														
	Dead (total)	5*	5	5	5	5	5	5	5	5	5	5	5	5	5	5
3♀ (0.69 mg/l)	Normal appearance and behaviour															
	Lethargic	1														
	Test material on snout	1														
	White discharge from snout	1														
	Dead (total)	4*	5	5	5	5	5	5	5	5	5	5	5	5	5	5
7♂ (0.18 mg/l)	Normal appearance and behaviour						5	5	5	5	5	5	5	5	5	5
	Abnormal breathing	4	4													
	Brown staining around snout	5	5	5	5	5										
7♀ (0.18 mg/l)	Normal appearance behaviour						5	5	5	5	5	5	5	5	5	5
	Abnormal breathing	5	5													
	Brown staining around snout	4	4	4	5	5										
8♂ (0.36 mg/l)	Normal appearance and behaviour		5			3	3	3	3	3	3	3	3	3	3	3
	Abnormal breathing	4														
	Lethargic	1														
	Brown staining on fur			3	3											
	Dead (total)	1*	1	2	2	2	2	2	2	2	2	2	2	2	2	2
8♀ (0.36 mg/l)	Normal appearance and behaviour		4	4	4	4	4	4	4	4	4	4	4	4	4	4
	Abnormal breathing	4														
	Dead (total)	1	1	1	1	1	1	1	1	1	1	1	1	1	1	1
10♂ (0.49 mg/l)	Normal appearance and behaviour			2	2	2	2	2	2	2	2	2	2	2	2	2
	Abnormal breathing	4														
	Test material on fur		2													
	Brown staining around snout	1														
	Dead (total)	1*	3	3	3	3	3	3	3	3	3	3	3	3	3	3
10♀ (0.49 mg/l)	Abnormal breathing	5														
	Brown staining around snout	1														
	Brown staining on fur		3	1	1	1	1	1	1	1	1	1	1	1	1	1
	Cyanosis	1														
	Dead (total)		2	4	4	4	4	4	4	4	4	4	4	4	4	4

* Within 1 hour post exposure

TABLE 5

Individual and group mean bodyweights (g)

Group	Rat	Pre-exposure					Exposure	Day of observation period													
		-5	-4	-3	-2	-1	0	1	2	3	4	5	6	7	8	9	10	11	12	13	14
1♂ (Control)	61	145	155	162	174	183	194	194	204	212	220	230	238	248	252	266	274	280	288	294	300
	62	142	154	163	172	184	190	190	201	210	218	222	230	240	244	256	265	272	278	286	294
	63	150	160	170	180	190	198	198	210	220	228	238	242	254	260	274	284	294	300	309	320
	64	145	154	163	172	180	190	190	196	204	212	222	228	234	240	250	256	262	270	280	284
	65	148	159	165	174	179	190	190	202	208	212	220	232	236	240	250	258	264	269	274	280
	Mean	146	156	165	174	183	192	192	203	211	218	226	234	242	247	259	267	274	281	289	296
1♀ (Control)	66	179	181	184	186	186	193	193	197	202	204	208	208	212	216	220	220	228	228	230	232
	67	180	182	185	190	190	195	193	198	205	206	210	210	217	218	224	224	228	228	234	234
	68	178	176	180	183	182	186	185	189	194	190	192	200	204	200	212	210	211	210	216	220
	69	180	182	187	193	192	194	196	202	207	200	210	214	216	212	220	222	224	222	229	236
	70	185	187	192	194	195	198	197	201	205	206	208	208	212	210	214	218	220	220	226	226
	Mean	180	182	186	189	189	193	193	197	203	201	206	208	212	211	218	219	222	222	227	230

TABLE 5

(continued)

Group	Rat	Pre-exposure					Exposure	Day of observation period													
		-5	-4	-3	-2	-1	0	1	2	3	4	5	6	7	8	9	10	11	12	13	14
3♂ (0.69mg/l)	81	149	155	162	173	182	189														
	82	145	151	158	165	174	178														
	83	146	150	157	164	172	179														
	84	150	160	167	175	188	196														
	85	146	150	158	168	176	182														
	Mean	147	153	160	169	178	185														
3♀ (0.69 mg/l)	86	176	174	179	182	190	187														
	87	183	186	187	188	190	188														
	88	184	186	184	190	196	198														
	89	177	178	184	188	188	196														
	90	184	186	179	190	193	200														
	Mean	181	182	183	188	191	194														

TABLE 5

(continued)

Group	Rat	Pre-exposure					Exposure	Day of observation period													
		-5	-4	-3	-2	-1	0	1	2	3	4	5	6	7	8	9	10	11	12	13	14
7♂ (0.18 mg/1)	211	156	165	173	185	188	199	196	208	215	224	230	242	248	258	266	275	280	290	294	302
	212	152	161	170	180	188	199	194	206	216	224	232	240	248	254	262	271	278	286	289	295
	213	140	151	158	171	180	189	184	198	206	216	224	230	238	246	254	266	271	277	282	286
	214	155	166	173	186	194	204	200	212	220	230	238	246	256	266	274	290	297	304	310	318
	215	146	154	163	172	180	188	180	194	199	210	214	226	230	238	244	260	267	271	274	280
	Mean	150	159	167	179	186	196	191	204	211	221	228	237	244	252	260	272	279	286	290	296
7♀ (0.18 mg/1)	216	179	181	184	193	196	203	194	206	207	214	218	222	228	230	229	235	240	244	245	248
	217	180	185	187	192	196	199	194	198	200	206	206	210	212	218	219	225	230	228	222	228
	218	185	187	184	193	194	200	188	196	199	206	208	212	216	218	220	225	232	234	234	234
	219	175	182	180	187	190	194	184	194	194	200	198	200	206	216	206	210	217	220	216	217
	220	180	181	176	184	186	193	184	194	192	196	196	200	206	210	208	210	215	220	217	223
	Mean	180	183	182	190	192	198	189	198	198	204	205	209	214	218	216	221	227	229	227	230

TABLE 5

(continued)

Group	Rat	Pre-exposure					Exposure	Day of observation period													
		-5	-4	-3	-2	-1	0	1	2	3	4	5	6	7	8	9	10	11	12	13	14
8♂ (0.36 mg/l)	221	144	152	163	172	181	188	184	195	206	210	216	224	228	237	245	251	259	261	267	271
	222	151	160	172	182	189	196	188	200	210	218	224	230	240	245	255	265	271	274	280	283
	223	153	160	172	180	188	196	186	200	208	216	224	232	242	249	259	267	274	277	283	289
	224	151	158	170	178	189	198														
	225	142	152	164	174	186	196														
	Mean	148	156	168	177	187	195	186	198	208	215	221	229	237	244	253	261	268	271	277	281
8♀ (0.36 mg/l)	226	180	183	189	186	192	218	194	198	206	206	212	218	220	220	225	232	235	235	236	240
	227	176	177	186	190	196	198	194	194	202	208	210	218	218	218	224	229	232	229	234	234
	228	186	188	194	200	198	200	194	190	204	210	214	218	218	220	225	230	237	237	242	245
	229	180	183	190	194	200	204	194	198	206	208	210	210	218	220	226	230	233	233	237	238
	230	186	190	196	196	204	218														
	Mean	182	184	191	193	198	208	194	195	205	208	212	216	219	220	225	230	234	234	237	239

TABLE 5

(continued)

Group	Rat	Pre-exposure					Exposure	Day of observation period													
		-5	-4	-3	-2	-1	0	1	2	3	4	5	6	7	8	9	10	11	12	13	14
10♂ (0.49 mg/l)	251	144	152	163	174	181	190														
	252	148	160	172	180	185	192	184	186	202	208	214	225	234	240	247	255	260	268	275	281
	253	154	159	166	175	182	187														
	254	144	153	163	179	179	186	181	191	200	210	218	227	230	242	248	258	266	274	279	284
	255	142	150	164	172	178	184														
	Mean	146	155	166	176	181	188	183	189	201	209	216	226	232	241	248	257	263	271	277	283
10♀ (0.49 mg/l)	256	167	180	185	185	190	193	185													
	257	168	180	183	190	193	197	189	182	194	195	196	194	200	204	205	204	208	214	216	213
	258	170	185	191	190	196	198														
	259	170	184	189	186	194	197														
	260	170	180	187	187	189	189	182													
	Mean	169	182	187	188	192	195	185	182	194	195	196	194	200	204	205	204	208	214	216	213

TABLE 6a

Food consumption (g/rat) : male rats

Day of observation period	Group 1♂ (Control)	Group 3♂ (0.69 mg/l)	Group 7♂ (0.18 mg/l)	Group 8♂ (0.36 mg/l)	Group 10♂ (0.49 mg/l)
-5	23	22	23	22	22
-4	23	22	22	22	23
-3	23	22	23	24	23
-2	23	23	22	23	23
-1	24	22	22	23	23
1	17		16	13	16
2	23		24	24	24
3	24		22	24	24
4	24		24	22	24
5	22		22	22	23
6	24		23	22	25
7	24		23	23	23
8	23		24	22	27
9	25		25	24	27
10	25		26	22	27
11	25		26	24	27
12	25		25	24	28
13	23		26	23	25
14	25		26	22	25

TABLE 6b

Food consumption (g/rat) : female rats

Day of observation period	Group 1♀ (Control)	Group 3♀ (0.69 mg/l)	Group 7♀ (0.18 mg/l)	Group 8♀ (0.36 mg/l)	Group 10♀ (0.49 mg/l)
-5	20	22	21	20	22
-4	21	22	19	22	20
-3	19	22	19	20	21
-2	18	20	20	19	21
-1	19	20	18	19	21
1	15		12	12	10
2	19		19	19	13
3	20		19	23	24
4	18		20	21	21
5	19		18	21	19
6	18		19	22	14
7	18		20	21	16
8	18		18	19	20
9	17		17	21	21
10	18		18	19	15
11	18		20	20	19
12	17		19	20	22
13	18		18	22	20
14	18		19	19	35

TABLE 7a

Water consumption (g/rat) : male rats

Day of observation period	Group 1♂ (Control)	Group 3♂ (0.69 mg/l)	Group 7♂ (0.18 mg/l)	Group 8♂ (0.36 mg/l)	Group 10♂ (0.49 mg/l)
-5	24	23	25	23	19
-4	24	24	25	23	23
-3	26	25	34	24	20
-2	27	25	20	12	24
-1	29	25	27	25	24
1	27		27	27	34
2	30		35	31	36
3	29		29	26	27
4	30		29	25	26
5	29		30	25	26
6	28		29	24	26
7	16		30	25	24
8	40		29	24	28
9	28		29	24	26
10	17		28	25	26
11	30		30	24	27
12	29		29	23	27
13	30		28	26	25
14	30		28	24	26

TABLE 7b

Water consumption (g/rat) : female rats

Day of observation period	Group 1♀ (Control)	Group 3♀ (0.69 mg/l)	Group 7♀ (0.18 mg/l)	Group 8♀ (0.36 mg/l)	Group 10♀ (0.49 mg/l)
-5	24	24	23	23	22
-4	27	23	22	24	21
-3	25	28	31	23	22
-2	26	25	16	23	25
-1	25	25	22	23	25
1	25		27	39	45
2	26		29	45	77
3	29		27	31	40
4	28		25	27	25
5	29		22	29	22
6	27		24	25	17
7	12		25	24	32
8	40		24	23	27
9	26		20	22	35
10	26		24	25	19
11	27		25	26	27
12	31		24	21	27
13	30		20	26	22
14	29		24	23	24

TABLE 8

Lung weight to bodyweight ratios

Group	Rat	Lung weight (g)	Body-weight (g)	Lung to bodyweight ratio (LW/BW) x 100	
				Survivors	Decedents
1♂ (Control)	61	1.35	300	0.45	
	62	1.34	294	0.46	
	63	1.30	320	0.41	
	64	1.31	284	0.46	
	65	1.45	280	0.52	
			Mean	0.46	
			SD	0.039	
1♀ (Control)	66	0.90	232	0.39	
	67	1.09	234	0.47	
	68	1.00	220	0.45	
	69	1.08	236	0.46	
	70	1.09	226	0.48	
			Mean	0.45	
			SD	0.035	
3♂ (0.69 mg/l)	81	1.19	189		0.63
	82	1.24	178		0.70
	83	1.18	179		0.66
	84	1.49	196		0.76
	85	1.02	182		0.56
			Mean		0.66
			SD		0.075
3♀ (0.69 mg/l)	86	1.48	187		0.79
	87	1.53	188		0.81
	88	2.48	198		1.25
	89	1.58	196		0.81
	90	1.53	200		0.77
			Mean		0.89
			SD		0.204

TABLE 8

(continued)

Group	Rat	Lung weight (g)	Body-weight (g)	Lung to bodyweight ratio (LW/BW) x 100	
				Survivors	Decedents
7♂ (0.18 mg/l)	211	1.20	302	0.40	
	212	1.21	295	0.41	
	213	1.17	286	0.41	
	214	1.28	318	0.40	
	215	1.21	280	0.43	
			Mean	0.41	
			SD	0.012	
7♀ (0.18 mg/l)	216	0.96	248	0.39	
	217	1.04	228	0.46	
	218	0.98	234	0.42	
	219	1.12	217	0.52	
	220	1.04	223	0.47	
			Mean	0.45	
			SD	0.050	
8♂ (0.36 mg/l)	221	1.14	188		0.61
	222	1.02	271	0.38	
	223	1.21	283	0.43	
	224	1.21	289	0.42	
	225	2.22	196		1.13
			Mean	0.41	0.87
			SD	0.026	-
8♀ (0.36 mg/l)	226	1.27	218		0.58
	227	1.06	240	0.44	
	228	1.03	234	0.44	
	229	1.06	245	0.43	
	230	1.18	238	0.50	
			Mean	0.45	-
			SD	0.032	-

TABLE 8

(continued)

Group	Rat	Lung weight (g)	Body-weight (g)	Lung to bodyweight ratio (LW/BW) x 100	
				Survivors	Decedents
10♂ (0.49 mg/l)	251	1.73	190		0.91
	252	1.17	281	0.42	
	253	2.81	187		1.50
	254	1.20	284	0.42	
	255	2.21	184		1.20
			Mean	0.42	1.20
			SD	-	0.295
10♀ (0.49 mg/l)	256	1.60	185		0.86
	257	0.98	213	0.46	
	258	1.93	198		0.97
	259	2.72	197		1.38
	260	2.95	182		1.62
			Mean	-	1.21
			SD	-	0.355

APPENDICES

APPENDIX 1

Determination of ioxynil in air sample

1. Instrumentation and apparatus

Spectrophotometer:	Cecil - model CE 505.
Apparatus:	Volumetric flasks and pipettes.
	Extraction columns 110 mm x 5 mm i.d. Quartz cuvettes, 10 mm path length.

2. Reagents

Methanol:	'HPLC' grade, Fisons.
Ioxynil:	Supplied by Sponsor.

3. Preparation of sample solutions

The filters from the open face and Andersen samples were transferred to extraction columns and compacted with a glass rod. The columns were mounted above 25 ml volumetric flasks and the ioxynil was eluted with five 2-3 ml portions of methanol. The collected eluate was diluted to 20 ml with methanol.

The material collected on stages 1-4 of the Andersen sampler was washed off with methanol into volumetric flasks. The sample solutions were diluted with methanol to obtain solutions for spectrophotometry with expected concentrations of ioxynil of 6 µg/ml or less.

4. Analysis of solutions

The absorbance of the diluted sample solutions was measured at 286 nm against a methanol reference.

The concentration of ioxynil in the solutions was evaluated from a standard curve.

5. Standardisation

Approximately 100 mg of ioxynil was accurately weighed into a 100 ml volumetric flask, dissolved in methanol and diluted to volume with methanol. The solution was diluted to obtain standard solutions of ioxynil containing between 1.0 and 6.0 µg/ml.

The absorbance of each standard solution was measured at 286 nm against a methanol reference.

A standard curve was fitted to the absorbance readings by regression analysis.

APPENDIX 2

Pathological data relating to individual rats

Group:	1	3	7	8	10
Compound:	-			Ioxynil	
Level (mg/l):	Control	0.69	0.18	0.36	0.49

In the following pages, the macroscopic and microscopic abnormalities and variations from normality have been described in detail. Tissues not referred to were considered to be within normal limits. As a check that the tissues were examined histologically, the pathologist has entered a tick (✓) in the appropriate section of the tables on each page (H & E and special stained sections as per Experimental Procedure in the first column and additional sections, if any, in the second column). Tissues missing for any reason, and not examined by the pathologist are marked 0 in the first column of the table.

The abbreviations used in the tables are listed below:

Aorta
Trachea (Trach)
Heart
Lung
Thymus (Thym)
Lymph nodes - cervical and mesenteric (Ly N)
Liver
Liver - ORO stain (L fat)
Liver - PAS stain (L gly)
Gall bladder (Gal B)
Spleen (Spl)
Pancreas (Panc)
Kidney (Kid)
Kidney - ORO stain (K fat)
Kidney - PAS stain (K PAS)
Urinary bladder (Urin B)
Uterus (Uter)
Prostate (Prost)
Gonads (Gnds)
Thyroids (Thyr)
Parathyroids (Parath)
Adrenals (Adren)
Salivary gland (Sal G)
Oesophagus (Oes)
Stomach - glandular and non-glandular (Stom)
Duodenum (Duod)
Jejunum (Jej)
Ileum
Colon
Caecum (Caec)
Rectum (Rect)
Skin
Skeletal muscle (Sk M)
Mammary gland (Mam)
Tongue (Tong)
Eye
Optic nerve (Op N)
Cerebral cortex)
Thalamic nuclei)
Mid-brain) (Brain)
Cerebellum)
Medulla)
Pituitary (Pit)
Sciatic nerve (Sc N)
Spinal cord (Sp C)
Bone marrow - sternum (B Mar)
Marrow smear (Mar S)
Femur
Seminal vesicles (S Ves)
Masses - Abdominal (Abd)
Thoracic (Thor)
Subcutaneous (S/cut)
Cutaneous (Cut)

APPENDIX 2

(Pathology - continued)

Rat 61♂ - Terminal kill

Control

Macroscopic findings: No abnormalities detected.

Microscopic findings: No abnormalities detected in the tissues examined.

Aorta			Spl			Parath			Rect			Sp C			Mass		
Trach			Panc			Adren			Skin			B Mar			Abd		
Heart			Kid	✓		Sal G			Sk M			Mar S			Thor		
Lung	✓		K.fat			Oes			Mam			Femur			S/cut		
Thym			K.PAS			Stom			Tong			S Ves			Cut		
Ly N			Urin B			Duod			Eye								
Liver	✓		Uter			Jej			Op N						P.A. Hill		
L.fat			Prost			Ileum			Brain								
L.gly			Gnds			Colon			Pit						October '94		
Gal B			Thyr			Caec			Sc N								

(Pathology - continued)

Rat 62♂ - Terminal kill

Control

Macroscopic findings: No abnormalities detected.

Microscopic findings:

Kidneys: Multiple groups of dilated/basophilic tubules with associated interstitial inflammation/fibrosis.

Aorta			Spl			Parath			Rect			Sp C			Mass		
Trach			Panc			Adren			Skin			B Mar			Abd		
Heart			Kid	✓		Sal G			Sk M			Mar S			Thor		
Lung	✓		K.fat			Oes			Mam			Femur			S/cut		
Thym			K.PAS			Stom			Tong			S Ves			Cut		
Ly N			Urin B			Duod			Eye								
Liver	✓		Uter			Jej			Op N						P.A.Tull		
L.fat			Prost			Ileum			Brain								
L.gly			Gnds			Colon			Pit						Oct '84		
Gal B			Thyr			Caec			Sc N								

(Pathology - continued)

Rat 63♂ - Terminal kill

Control

Macroscopic findings: No abnormalities detected.

Microscopic findings:

Kidneys: A few groups of dilated/basophilic tubules with associated interstitial inflammatory cells.

Aorta			Spl			Parath			Rect			Sp C			Mass		
Trach			Panc			Adren			Skin			B Mar			Abd		
Heart			Kid	✓		Sal G			Sk M			Mar S			Thor		
Lung	✓		K.fat			Oes			Mam			Femur			S/cut		
Thym			K.PAS			Stom			Tong			S Ves			Cut		
Ly N			Urin B			Duod			Eye								
Liver	✓		Uter			Jej			Op N						P.A. Hall Oct 54		
L.fat			Prost			Ileum			Brain								
L.gly			Gnds			Colon			Pit								
Gal B			Thyr			Caec			Sc N								

(Pathology - continued)

Rat 64♂ - Terminal kill

Control

Macroscopic findings: No abnormalities detected.

Microscopic findings:

Kidneys: A few groups of dilated/basophilic tubules with associated interstitial inflammatory cells.

Aorta			Spl			Parath			Rect			Sp C			Mass		
Trach			Panc			Adren			Skin			B Mar			Abd		
Heart			Kid	✓		Sal G			Sk M			Mar S			Thor		
Lung	✓		K.fat			Oes			Mam			Femur			S/cut		
Thym			K.PAS			Stom			Tong			S Ves			Cut		
Ly N			Urin B			Duod			Eye								
Liver	✓		Uter			Jej			Op N								
L.fat			Prost			Ileum			Brain								
L.gly			Gnds			Colon			Pit								
Gal B			Thyr			Caec			Sc N								

APPENDIX 2

(Pathology - continued)

Rat 65♂ - Terminal kill

Control

Macroscopic findings: No abnormalities detected.

Microscopic findings:

Kidneys: A few groups of dilated/basophilic tubules with associated interstitial inflammatory cells.

Aorta			Spl			Parath			Rect			Sp C			Mass		
Trach			Panc			Adren			Skin			B Mar			Abd		
Heart			Kid	✓		Sal G			Sk M			Mar S			Thor		
Lung	✓		K.fat			Oes			Mam			Femur			S/cut		
Thym			K.PAS			Stom			Tong			S Ves			Cut		
Ly N			Urin B			Duod			Eye								
Liver	✓		Uter			Jej			Op N						P.A		
L.fat			Prost			Ileum			Brain								
L.gly			Gnds			Colon			Pit						Oct 84		
Gal B			Thyr			Caec			Sc N								

APPENDIX 2

(Pathology - continued)

Rat 66♀ - Terminal kill

Control

Macroscopic findings: No abnormalities detected.

Microscopic findings: No abnormalities detected in the tissues examined.

Aorta			Spl			Parath			Rect			Sp C			Mass		
Trach			Panc			Adren			Skin			B Mar			Abd		
Heart			Kid	✓		Sal G			Sk M			Mar S			Thor		
Lung	✓		K.fat			Oes			Mam			Femur			S/cut		
Thym			K.PAS			Stom			Tong			S Ves			Cut		
Ly N			Urin B			Duod			Eye								
Liver	✓		Uter			Jej			Op N						P.A. [illegible]		
L.fat			Prost			Ileum			Brain								
L.gly			Gnds			Colon			Pit						Oct '54		
Gal B			Thyr			Caec			Sc N								

APPENDIX 2

(Pathology - continued)

Rat 67♀ - Terminal kill

Control

Macroscopic findings: No abnormalities detected.

Microscopic findings: No abnormalities detected in the tissues examined.

Aorta			Spl			Parath			Rect			Sp C			Mass		
Trach			Panc			Adren			Skin			B Mar			Abd		
Heart			Kid	✓		Sal G			Sk M			Mar S			Thor		
Lung	✓		K.fat			Oes			Mam			Femur			S/cut		
Thym			K.PAS			Stom			Tong			S Ves			Cut		
Ly N			Urin B			Duod			Eye								
Liver	✓		Uter			Jej			Op N						PA Tell		
L.fat			Prost			Ileum			Brain								
L.gly			Gnds			Colon			Pit						Cor Sq		
Gal B			Thyr			Caec			Sc N								

(Pathology - continued)

Rat 68♀ - Terminal kill

Control

Macroscopic findings: No abnormalities detected.

Microscopic findings:

Kidneys: Occasional groups of basophilic cortical tubules.

Aorta			Spl			Parath			Rect			Sp C			Mass		
Trach			Panc			Adren			Skin			B Mar			Abd		
Heart			Kid	✓		Sal G			Sk M			Mar S			Thor		
Lung	✓		K.fat			Oes			Mam			Femur			S/cut		
Thym			K.PAS			Stom			Tong			S Ves			Cut		
Ly N			Urin B			Duod			Eye								
Liver	✓		Uter			Jej			Op N						P.A.H.		
L.fat			Prost			Ileum			Brain								
L.gly			Gnds			Colon			Pit								
Gal B			Thyr			Caec			Sc N						Oct '54		

APPENDIX 2

(Pathology - continued)

Rat 69♀ - Terminal kill

Control

Macroscopic findings: No abnormalities detected.

Microscopic findings: No abnormalities detected in the tissues examined.

Aorta			Spl			Parath			Rect			Sp C			Mass		
Trach			Panc			Adren			Skin			B Mar			Abd		
Heart			Kid	✓		Sal G			Sk M			Mar S			Thor		
Lung	✓		K.fat			Oes			Mam			Femur			S/cut		
Thym			K.PAS			Stom			Tong			S Ves			Cut		
Ly N			Urin B			Duod			Eye								
Liver	✓		Uter			Jej			Op N						PA Hill Oct '84		
L.fat			Prost			Ileum			Brain								
L.gly			Gnds			Colon			Pit								
Gal B			Thyr			Caec			Sc N								

(Pathology - continued)

Rat 70♀ - Terminal kill

Control

Macroscopic findings: No abnormalities detected.

Microscopic findings:

Kidneys: Bilateral minimal focal mineralisation at the corticomedullary junction. A few groups of basophilic cortical tubules, some with associated interstitial inflammatory cells.

Aorta			Spl			Parath			Rect			Sp C			Mass		
Trach			Panc			Adren			Skin			B Mar			Abd		
Heart			Kid	✓		Sal G			Sk M			Mar S			Thor		
Lung	✓		K.fat			Oes			Mam			Femur			S/cut		
Thym			K.PAS			Stom			Tong			S Ves			Cut		
Ly N			Urin B			Duod			Eye								
Liver	✓		Uter			Jej			Op N								
L.fat			Prost			Ileum			Brain								
L.gly			Gnds			Colon			Pit								
Gal B			Thyr			Caec			Sc N								

APPENDIX 2

(Pathology - continued)

0.69 mg/l Ioxynil

Rat 81♂ - Decedent

Macroscopic findings:

External appearance: Wet fur on head. Test material on snout.

Lungs: Congestion.

Microscopic findings: No tissues processed as per Experimental Procedure.

Rat 82♂ - Decedent

Macroscopic findings:

External appearance: Wet fur on head. Test material on snout.

Lungs: Congestion.

Microscopic findings: No tissues processed as per Experimental Procedure.

Rat 83♂ - Decedent

Macroscopic findings:

External appearance: Wet fur on head. Test material on snout.

Lungs: Congestion.

Microscopic findings: No tissues processed as per Experimental Procedure.

Rat 84♂ - Decedent

Macroscopic findings:

External appearance: Wet fur on head. Test material on snout.

Lungs: Congestion.

Microscopic findings: No tissues processed as per Experimental Procedure.

(Pathology - continued)

0.69 mg/l Ioxynil

Rat 85♂ - Decedent

Macroscopic findings:

External appearance:	Test material on snout. White discharge from snout.
Lungs:	Few red areas (up to 2 x 2 mm).
Microscopic findings:	No tissues processed as per Experimental Procedure.

(Pathology - continued)

0.69 mg/l Ioxynil

Rat 86♀ - Decedent

Macroscopic findings:

External appearance: Wet fur on head.
Test material on snout.

Lungs: Congestion.

Microscopic findings: No tissues processed as per Experimental Procedure.

Rat 87♀ - Decedent

Macroscopic findings:

External appearance: Wet fur on head.
Test material on snout.

Lungs: Congestion.

Microscopic findings: No tissues processed as per Experimental Procedure.

Rat 88♀ - Decedent

Macroscopic findings:

External appearance: Clear discharge from snout.

Lungs: Appear swollen.
Congestion.
Fluid in trachea.

Microscopic findings: No tissues processed as per Experimental Procedure.

Rat 89♀ - Decedent

Macroscopic findings:

External appearance: Wet fur on head.
Test material on snout.

Lungs: Congestion.

Microscopic findings: No tissues processed as per Experimental Procedure.

(Pathology - continued)

0.69 mg/l Ioxynil

Rat 90♀ - Decedent

Macroscopic findings:

External appearance:	Wet fur on head. Test material on snout.
Lungs:	Congestion.
Microscopic findings:	No tissues processed as per Experimental Procedure.

APPENDIX 2

(Pathology - continued)

Rat 211♂ - Terminal kill

0.18 mg/l Ioxynil

Macroscopic findings: No abnormalities detected.

Microscopic findings:

Kidneys: Occasional groups of basophilic cortical tubules, some with associated interstitial inflammatory cells.

Aorta			Spl			Parath			Rect			Sp C			Mass		
Trach			Panc			Adren			Skin			B Mar			Abd		
Heart			Kid	✓		Sal G			Sk M			Mar S			Thor		
Lung	✓		K.fat			Oes			Mam			Femur			S/cut		
Thym			K.PAS			Stom			Tong			S Ves			Cut		
Ly N			Urin B			Duod			Eye								
Liver	✓		Uter			Jej			Op N						P.A. Hall Oct '84		
L.fat			Prost			Ileum			Brain								
L.gly			Gnds			Colon			Pit								
Gal B			Thyr			Caec			Sc N								

APPENDIX 2

(Pathology - continued)

Rat 212♂ - Terminal kill

0.18 mg/l Ioxynil

Macroscopic findings: No abnormalities detected.

Microscopic findings:

Kidneys: A few groups of dilated/basophilic cortical tubules, some with associated interstitial inflammatory cells.

Aorta			Spl			Parath			Rect			Sp C			Mass		
Trach			Panc			Adren			Skin			B Mar			Abd		
Heart			Kid	✓		Sal G			Sk M			Mar S			Thor		
Lung	✓		K.fat			Oes			Mam			Femur			S/cut		
Thym			K.PAS			Stom			Tong			S Ves			Cut		
Ly N			Urin B			Duod			Eye								
Liver	✓		Uter			Jej			Op N								
L.fat			Prost			Ileum			Brain								
L.gly			Gnds			Colon			Pit								
Gal B			Thyr			Caec			Sc N								

F.A. Tull
Oct '84

APPENDIX 2

(Pathology - continued)

Rat 213♂ - Terminal kill

0.18 mg/l Ioxynil

Macroscopic findings: No abnormalities detected.

Microscopic findings: No abnormalities detected in the tissues examined.

Aorta			Spl			Parath			Rect			Sp C			Mass		
Trach			Panc			Adren			Skin			B Mar			Abd		
Heart			Kid	✓		Sal G			Sk M			Mar S			Thor		
Lung	✓		K.fat			Oes			Mam			Femur			S/cut		
Thym			K.PAS			Stom			Tong			S Ves			Cut		
Ly N			Urin B			Duod			Eye								
Liver	✓		Uter			Jej			Op N								
L.fat			Prost			Ileum			Brain						P.A. [illegible]		
L.gly			Gnds			Colon			Pit								
Gal B			Thyr			Caec			Sc N						Oct '84		

(Pathology - continued)

Rat 214♂ - Terminal kill

0.18 mg/l Ioxynil

Macroscopic findings: No abnormalities detected.

Microscopic findings:

Liver: Parenchymal focus of hepatocyte necrosis with associated mixed inflammatory cells.

Kidneys: Multiple groups of dilated/basophilic tubules with associated interstitial inflammatory cells.

Aorta			Spl			Parath			Rect			Sp C			Mass		
Trach			Panc			Adren			Skin			B Mar			Abd		
Heart			Kid	✓		Sal G			Sk M			Mar S			Thor		
Lung	✓		K.fat			Oes			Mam			Femur			S/cut		
Thym			K.PAS			Stom			Tong			S Ves			Cut		
Ly N			Urin B			Duod			Eye								
Liver	✓		Uter			Jej			Op N						P.A [illegible]		
L.fat			Prost			Ileum			Brain								
L.gly			Gnds			Colon			Pit								
Gal B			Thyr			Caec			Sc N						Oct 84		

(Pathology - continued)

Rat 215♂ - Terminal kill

0.18 mg/l Ioxynil

Macroscopic findings:

Lungs: Area of congestion affecting 25% of right middle lobe.

Microscopic findings:

Lungs: No abnormalities detected in the sections examined.

Aorta			Spl			Parath			Rect			Sp C			Mass		
Trach			Panc			Adren			Skin			B Mar			Abd		
Heart			Kid	✓		Sal G			Sk M			Mar S			Thor		
Lung	✓		K.fat			Oes			Mam			Femur			S/cut		
Thym			K.PAS			Stom			Tong			S Ves			Cut		
Ly N			Urin B			Duod			Eye								
Liver	✓		Uter			Jej			Op N								
L.fat			Prost			Ileum			Brain								
L.gly			Gnds			Colon			Pit								
Gal B			Thyr			Caec			Sc N								

F.A. [illegible] Oct '54

(Pathology - continued)

Rat 216♀ - Terminal kill

0.18 mg/l Ioxynil

Macroscopic findings: No abnormalities detected.

Microscopic findings:

Kidneys: Occasional groups of dilated/basophilic cortical tubules, some with associated interstitial inflammatory cells.

Aorta			Spl			Parath			Rect			Sp C			Mass		
Trach			Panc			Adren			Skin			B Mar			Abd		
Heart			Kid	✓		Sal G			Sk M			Mar S			Thor		
Lung	✓		K.fat			Oes			Mam			Femur			S/cut		
Thym			K.PAS			Stom			Tong			S Ves			Cut		
Ly N			Urin B			Duod			Eye								
Liver	✓		Uter			Jej			Op N						P.A.		
L.fat			Prost			Ileum			Brain								
L.gly			Gnds			Colon			Pit								
Gal B			Thyr			Caec			Sc N						Cat'sy		

APPENDIX 2

(Pathology - continued)

Rat 217♀ - Terminal kill

0.18 mg/l Ioxynil

Macroscopic findings: No abnormalities detected.

Microscopic findings: No abnormalities detected in the tissues examined.

Aorta			Spl			Parath			Rect			Sp C			Mass		
Trach			Panc			Adren			Skin			B Mar			Abd		
Heart			Kid	✓		Sal G			Sk M			Mar S			Thor		
Lung	✓		K.fat			Oes			Mam			Femur			S/cut		
Thym			K.PAS			Stom			Tong			S Ves			Cut		
Ly N			Urin B			Duod			Eye								
Liver	✓		Uter			Jej			Op N								
L.fat			Prost			Ileum			Brain								
L.gly			Gnds			Colon			Pit								
Gal B			Thyr			Caec			Sc N								

PA Miller
Oct '84

(Pathology - continued)

Rat 218♀ - Terminal kill

0.18 mg/l Ioxynil

Macroscopic findings: No abnormalities detected.

Microscopic findings:

Lungs: Focus of arterial medial calcification.

Kidneys: Occasional groups of basophilic cortical tubules, some with associated interstitial inflammatory cells.

Aorta			Spl			Parath			Rect			Sp C			Mass		
Trach			Panc			Adren			Skin			B Mar			Abd		
Heart			Kid	✓		Sal G			Sk M			Mar S			Thor		
Lung	✓		K.fat			Oes			Mam			Femur			S/cut		
Thym			K.PAS			Stom			Tong			S Ves			Cut		
Ly N			Urin B			Duod			Eye								
Liver	✓		Uter			Jej			Op N								
L.fat			Prost			Ileum			Brain						P.A. [illegible]		
L.gly			Gnds			Colon			Pit								
Gal B			Thyr			Caec			Sc N						Oct 84		

APPENDIX 2

(Pathology - continued)

Rat 219♀ - Terminal kill

0.18 mg/l Ioxynil

Macroscopic findings: No abnormalities detected.

Microscopic findings:

Kidneys: A few groups of basophilic cortical tubules, some with associated interstitial inflammatory cells.

Aorta			Spl			Parath			Rect			Sp C			Mass		
Trach			Panc			Adren			Skin			B Mar			Abd		
Heart			Kid	✓		Sal G			Sk M			Mar S			Thor		
Lung	✓		K.fat			Oes			Mam			Femur			S/cut		
Thym			K.PAS			Stom			Tong			S Ves			Cut		
Ly N			Urin B			Duod			Eye								
Liver	✓		Uter			Jej			Op N						P.A. Rull		
L.fat			Prost			Ileum			Brain						Oct 84		
L.gly			Gnds			Colon			Pit								
Gal B			Thyr			Caec			Sc N								

(Pathology - continued)

Rat 220♀ - Terminal kill

0.18 mg/l Ioxynil

Macroscopic findings: No abnormalities detected.

Microscopic findings: No abnormalities detected in the tissues examined.

Aorta			Spl			Parath			Rect			Sp C			Mass		
Trach			Panc			Adren			Skin			B Mar			Abd		
Heart			Kid	✓		Sal G			Sk M			Mar S			Thor		
Lung	✓		K.fat			Oes			Mam			Femur			S/cut		
Thym			K.PAS			Stom			Tong			S Ves			Cut		
Ly N			Urin B			Duod			Eye								
Liver	✓		Uter			Jej			Op N								
L.fat			Prost			Ileum			Brain								
L.gly			Gnds			Colon			Pit								
Gal B			Thyr			Caec			Sc N								

F.A. [illegible] Oct 84

APPENDIX 2

(Pathology - continued)

Rat 221♂ - Decedent

0.36 mg/l Ioxynil

Macroscopic findings:

External appearance: Wet fur on head.

Microscopic findings:

Liver: Minimal vacuolation of centrilobular hepatocytes.

Aorta			Spl			Parath			Rect			Sp C			Mass		
Trach			Panc			Adren			Skin			B Mar			Abd		
Heart			Kid	✓		Sal G			Sk M			Mar S			Thor		
Lung	✓		K.fat			Oes			Mam			Femur			S/cut		
Thym			K.PAS			Stom			Tong			S Ves			Cut		
Ly N			Urin B			Duod			Eye						-		
Liver	✓		Uter			Jej			Op N								
L.fat			Prost			Ileum			Brain								
L.gly			Gnds			Colon			Pit								
Gal B			Thyr			Caec			Sc N								

(Pathology - continued)

Rat 222♂ - Terminal kill

0.36 mg/l Ioxynil

Macroscopic findings: No abnormalities detected.

Microscopic findings: No abnormalities detected in the tissues examined.

Aorta			Spl			Parath			Rect			Sp C			Mass		
Trach			Panc			Adren			Skin			B Mar			Abd		
Heart			Kid	✓		Sal G			Sk M			Mar S			Thor		
Lung	✓		K.fat			Oes			Mam			Femur			S/cut		
Thym			K.PAS			Stom			Tong			S Ves			Cut		
Ly N			Urin B			Duod			Eye								
Liver	✓		Uter			Jej			Op N								
L.fat			Prost			Ileum			Brain								
L.gly			Gnds			Colon			Pit								
Gal B			Thyr			Caec			Sc N								

F.A. [illegible] Oct '84

APPENDIX 2

(Pathology - continued)

Rat 223♂ - Terminal kill

0.36 mg/l Ioxynil

Macroscopic findings: No abnormalities detected.

Microscopic findings:

Kidneys: Occasional groups of basophilic cortical tubules, some with associated interstitial inflammatory cells.

Aorta			Spl			Parath			Rect			Sp C			Mass		
Trach			Panc			Adren			Skin			B Mar			Abd		
Heart			Kid	✓		Sal G			Sk M			Mar S			Thor		
Lung	✓		K.fat			Oes			Mam			Femur			S/cut		
Thym			K.PAS			Stom			Tong			S Ves			Cut		
Ly N			Urin B			Duod			Eye								
Liver	✓		Uter			Jej			Op N						P.A.H.		
L.fat			Prost			Ileum			Brain								
L.gly			Gnds			Colon			Pit						Oct '84		
Gal B			Thyr			Caec			Sc N								

APPENDIX 2

(Pathology - continued)

Rat 224♂ - Terminal kill

0.36 mg/l Ioxynil

Macroscopic findings: No abnormalities detected.

Microscopic findings: No abnormalities detected in the tissues examined.

Aorta			Spl			Parath			Rect			Sp C			Mass		
Trach			Panc			Adren			Skin			B Mar			Abd		
Heart			Kid	✓		Sal G			Sk M			Mar S			Thor		
Lung	✓		K.fat			Oes			Mam			Femur			S/cut		
Thym			K.PAS			Stom			Tong			S Ves			Cut		
Ly N			Urin B			Duod			Eye								
Liver	✓		Uter			Jej			Op N								
L.fat			Prost			Ileum			Brain								
L.gly			Gnds			Colon			Pit								
Gal B			Thyr			Caec			Sc N								

[illegible]
Oct '84

APPENDIX 2

(Pathology - continued)

Rat 225♂ - Decedent

0.36 mg/l Ioxynil

Macroscopic findings:

External appearance:	Brown staining around snout.
Lungs:	Appear swollen. Brown fluid visible in trachea. Congestion.

Microscopic findings:

Lungs:	Autolysis. Congestion, probably post mortem.
Liver:	Autolysis.
Kidneys:	Autolysis. A few groups of basophilic cortical tubules with associated interstitial inflammatory cells.

Aorta			Spl			Parath			Rect			Sp C			Mass		
Trach			Panc			Adren			Skin			B Mar			Abd		
Heart			Kid	✓		Sal G			Sk M			Mar S			Thor		
Lung	✓		K.fat			Oes			Mam			Femur			S/cut		
Thym			K.PAS			Stom			Tong			S Ves			Cut		
Ly N			Urin B			Duod			Eye								
Liver	✓		Uter			Jej			Op N						P.A. [illegible]		
L.fat			Prost			Ileum			Brain								
L.gly			Gnds			Colon			Pit						Oct '84		
Gal B			Thyr			Caec			Sc N								

(Pathology - continued)

Rat 226♀ - Decedent

0.36 mg/l Ioxynil

Macroscopic findings:

External appearance: Wet fur on head.

Lungs: Congestion.

Microscopic findings:

Lungs: Congestion, probably post mortem.

Kidneys: Bilateral minimal focal mineralisation at the corticomedullary junction. Occasional groups of dilated/ basophilic cortical tubules, some with associated interstitial inflammatory cells.

Aorta			Spl			Parath			Rect			Sp C			Mass		
Trach			Panc			Adren			Skin			B Mar			Abd		
Heart			Kid	✓		Sal G			Sk M			Mar S			Thor		
Lung	✓		K.fat			Oes			Mam			Femur			S/cut		
Thym			K.PAS			Stom			Tong			S Ves			Cut		
Ly N			Urin B			Duod			Eye								
Liver	✓		Uter			Jej			Op N								
L.fat			Prost			Ileum			Brain						P.A Mull		
L.gly			Gnds			Colon			Pit								
Gal B			Thyr			Caec			Sc N						Oct '84		

(Pathology - continued)

Rat 227♀ - Terminal kill

0.36 mg/l Ioxynil

Macroscopic findings: No abnormalities detected.

Microscopic findings:

Kidneys: Bilateral moderate focal mineralisation at the corticomedullary junction. A few basophilic cortical tubules, some with associated interstitial inflammatory cells.
Bilateral minimal pyelitis with associated hyperplasia of transitional epithelium.

Aorta			Spl			Parath			Rect			Sp C			Mass		
Trach			Panc			Adren			Skin			B Mar			Abd		
Heart			Kid	✓		Sal G			Sk M			Mar S			Thor		
Lung	✓		K.fat			Oes			Mam			Femur			S/cut		
Thym			K.PAS			Stom			Tong			S Ves			Cut		
Ly N			Urin B			Duod			Eye								
Liver	✓		Uter			Jej			Op N								
L.fat			Prost			Ileum			Brain								
L.gly			Gnds			Colon			Pit								
Gal B			Thyr			Caec			Sc N								

(Pathology - continued)

Rat 228♀ - Terminal kill

0.36 mg/l Ioxynil

Macroscopic findings: No abnormalities detected.

Microscopic findings:

Liver: Parenchymal focus of inflammatory cells.

Kidneys: Unilateral minimal focal mineralisation at the corticomedullary junction.
A few groups of basophilic cortical tubules, some with associated interstitial inflammatory cells.

Aorta			Spl			Parath			Rect			Sp C			Mass		
Trach			Panc			Adren			Skin			B Mar			Abd		
Heart			Kid	✓		Sal G			Sk M			Mar S			Thor		
Lung	✓		K.fat			Oes			Mam			Femur			S/cut		
Thym			K.PAS			Stom			Tong			S Ves			Cut		
Ly N			Urin B			Duod			Eye								
Liver	✓		Uter			Jej			Op N						P.A. Hill		
L.fat			Prost			Ileum			Brain								
L.gly			Gnds			Colon			Pit								
Gal B			Thyr			Caec			Sc N						Oct '84		

APPENDIX 2

(Pathology - continued)

Rat 229♀ - Terminal kill

0.36 mg/l Ioxynil

Macroscopic findings: No abnormalities detected.

Microscopic findings:

Kidneys: Bilateral minimal focal mineralisation at the corticomedullary junction.

Aorta			Spl			Parath			Rect			Sp C			Mass		
Trach			Panc			Adren			Skin			B Mar			Abd		
Heart			Kid	✓		Sal G			Sk M			Mar S			Thor		
Lung	✓		K.fat			Oes			Mam			Femur			S/cut		
Thym			K.PAS			Stom			Tong			S Ves			Cut		
Ly N			Urin B			Duod			Eye								
Liver	✓		Uter			Jej			Op N								
L.fat			Prost			Ileum			Brain								
L.gly			Gnds			Colon			Pit								
Gal B			Thyr			Caec			Sc N								

(Pathology - continued)

Rat 230♀ - Terminal kill

0.36 mg/l Ioxynil

Macroscopic findings: No abnormalities detected.

Microscopic findings:

Kidneys: Unilateral minimal focal mineralisation at the corticomedullary junction.
A few groups of basophilic cortical tubules, some with associated interstitial inflammatory cells.

Aorta			Spl			Parath			Rect			Sp C			Mass		
Trach			Panc			Adren			Skin			B Mar			Abd		
Heart			Kid	✓		Sal G			Sk M			Mar S			Thor		
Lung	✓		K.fat			Oes			Mam			Femur			S/cut		
Thym			K.PAS			Stom			Tong			S Ves			Cut		
Ly N			Urin B			Duod			Eye								
Liver	✓		Uter			Jej			Op N								
L.fat			Prost			Ileum			Brain								
L.gly			Gnds			Colon			Pit								
Gal B			Thyr			Caec			Sc N								

APPENDIX 2

(Pathology - continued)

Rat 251♂ - Decedent

0.49 mg/l Ioxynil

Macroscopic findings:

External appearance: Wet fur around jaws.
Brown staining around snout.

Lungs: Congestion.

Microscopic findings:

Lungs: Congestion, probably post mortem.

Aorta			Spl			Parath			Rect			Sp C			Mass		
Trach			Panc			Adren			Skin			B Mar			Abd		
Heart			Kid	✓		Sal G			Sk M			Mar S			Thor		
Lung	✓		K.fat			Oes			Mam			Femur			S/cut		
Thym			K.PAS			Stom			Tong			S Ves			Cut		
Ly N			Urin B			Duod			Eye								
Liver	✓		Uter			Jej			Op N								
L.fat			Prost			Ileum			Brain						PA Nil		
L.gly			Gnds			Colon			Pit								
Gal B			Thyr			Caec			Sc N						Cer SG		

(Pathology - continued)

Rat 252♂ - Terminal kill

0.49 mg/l Ioxynil

Macroscopic findings: No abnormalities detected.

Microscopic findings:

Kidneys: Occasional groups of basophilic cortical tubules.

Aorta			Spl			Parath			Rect			Sp C			Mass		
Trach			Panc			Adren			Skin			B Mar			Abd		
Heart			Kid	✓		Sal G			Sk M			Mar S			Thor		
Lung	✓		K.fat			Oes			Mam			Femur			S/cut		
Thym			K.PAS			Stom			Tong			S Ves			Cut		
Ly N			Urin B			Duod			Eye								
Liver	✓		Uter			Jej			Op N								
L.fat			Prost			Ileum			Brain								
L.gly			Gnds			Colon			Pit								
Gal B			Thyr			Caec			Sc N								

PA Hill
Oct '84

APPENDIX 2

(Pathology - continued)

Rat 253♂ - Decedent

0.49 mg/l Ioxynil

Macroscopic findings:

External appearance: Red staining around snout and jaws.

Lungs: Appear swollen.
Congestion.
Clear fluid visible in the trachea.

Microscopic findings:

Lungs: Autolysis.
Congestion, probably post mortem.

Kidneys: Autolysis.
A few groups of basophilic cortical tubules, some with associated interstitial inflammatory cells.

Aorta			Spl			Parath			Rect			Sp C			Mass		
Trach			Panc			Adren			Skin			B Mar			Abd		
Heart			Kid	✓		Sal G			Sk M			Mar S			Thor		
Lung	✓		K.fat			Oes			Mam			Femur			S/cut		
Thym			K.PAS			Stom			Tong			S Ves			Cut		
Ly N			Urin B			Duod			Eye								
Liver	✓		Uter			Jej			Op N						P.A [illegible]		
L.fat			Prost			Ileum			Brain								
L.gly			Gnds			Colon			Pit								
Gal B			Thyr			Caec			Sc N						Oct 84		

(Pathology - continued)

Rat 254♂ - Terminal kill

0.49 mg/l Ioxynil

Macroscopic findings: No abnormalities detected.

Microscopic findings: No abnormalities detected in the tissues examined.

Aorta			Spl			Parath			Rect			Sp C			Mass		
Trach			Panc			Adren			Skin			B Mar			Abd		
Heart			Kid	✓		Sal G			Sk M			Mar S			Thor		
Lung	✓		K.fat			Oes			Mam			Femur			S/cut		
Thym			K.PAS			Stom			Tong			S Ves			Cut		
Ly N			Urin B			Duod			Eye								
Liver	✓		Uter			Jej			Op N								
L.fat			Prost			Ileum			Brain						P.A Tull		
L.gly			Gnds			Colon			Pit								
Gal B			Thyr			Caec			Sc N						Oct '84		

APPENDIX 2

(Pathology - continued)

Rat 255♂ - Decedent

0.49 mg/l Ioxynil

Macroscopic findings:

External appearance:	Wet fur around jaws.
Lungs:	Appear swollen. Congestion. Clear fluid visible in the trachea.

Microscopic findings:

Lungs:	Autolysis. Congestion, probably post mortem.
Liver:	Autolysis.
Kidneys:	Autolysis. Occasional groups of basophilic cortical tubules some with associated interstitial inflammatory cells.

Aorta			Spl			Parath			Rect			Sp C			Mass		
Trach			Panc			Adren			Skin			B Mar			Abd		
Heart			Kid	✓		Sal G			Sk M			Mar S			Thor		
Lung	✓		K.fat			Oes			Mam			Femur			S/cut		
Thym			K.PAS			Stom			Tong			S Ves			Cut		
Ly N			Urin B			Duod			Eye								
Liver	✓		Uter			Jej			Op N								
L.fat			Prost			Ileum			Brain								
L.gly			Gnds			Colon			Pit								
Gal B			Thyr			Caec			Sc N								

P.A. [illegible]
Oct '84

APPENDIX 2

(Pathology - continued)

Rat 256♀ - Decedent

0.49 mg/l Ioxynil

Macroscopic findings:

External appearance:	Soiled fur.
Lungs:	Appear swollen. Congestion.

Microscopic findings:

Lungs:	Autolysis. Congestion, probably post mortem.
Liver:	Autolysis.
Kidneys:	Autolysis.

Aorta			Spl			Parath			Rect			Sp C			Mass		
Trach			Panc			Adren			Skin			B Mar			Abd		
Heart			Kid	✓		Sal G			Sk M			Mar S			Thor		
Lung	✓		K.fat			Oes			Mam			Femur			S/cut		
Thym			K.PAS			Stom			Tong			S Ves			Cut		
Ly N			Urin B			Duod			Eye								
Liver	✓		Uter			Jej			Op N								
L.fat			Prost			Ileum			Brain						P.A Tull		
L.gly			Gnds			Colon			Pit								
Gal B			Thyr			Caec			Sc N						Oct '84		

APPENDIX 2

(Pathology - continued)

Rat 257♀ - Terminal kill

0.49 mg/l Ioxynil

Macroscopic findings:

External appearance: Minimal brown staining on head.

Microscopic findings: No abnormalities detected in the tissues examined.

Aorta			Spl			Parath			Rect			Sp C			Mass		
Trach			Panc			Adren			Skin			B Mar			Abd		
Heart			Kid	✓		Sal G			Sk M			Mar S			Thor		
Lung	✓		K.fat			Oes			Mam			Femur			S/cut		
Thym			K.PAS			Stom			Tong			S Ves			Cut		
Ly N			Urin B			Duod			Eye								
Liver	✓		Uter			Jej			Op N						P.A. [illegible]		
L.fat			Prost			Ileum			Brain								
L.gly			Gnds			Colon			Pit						Oct '84		
Gal B			Thyr			Caec			Sc N								

(Pathology - continued)

Rat 258♀ - Decedent

0.49 mg/l Ioxynil

Macroscopic findings:

External appearance: Dark brown staining around snout.

Lungs: Congestion.

Microscopic findings:

Lungs: Autolysis.
Congestion, probably post mortem.

Liver: Autolysis.

Kidneys: Autolysis.

Aorta			Spl			Parath			Rect			Sp C			Mass		
Trach			Panc			Adren			Skin			B Mar			Abd		
Heart			Kid	✓		Sal G			Sk M			Mar S			Thor		
Lung	✓		K.fat			Oes			Mam			Femur			S/cut		
Thym			K.PAS			Stom			Tong			S Ves			Cut		
Ly N			Urin B			Duod			Eye								
Liver	✓		Uter			Jej			Op N								
L.fat			Prost			Ileum			Brain						PA Rell		
L.gly			Gnds			Colon			Pit								
Gal B			Thyr			Caec			Sc N						Oct 84		

(Pathology - continued)

Rat 259♀ - Decedent

0.49 mg/l Ioxynil

Macroscopic findings:

Lungs: Appear swollen.
Congestion.
Pale brown fluid visible in the trachea.

Microscopic findings:

Lungs: Autolysis.
Congestion, probably post mortem.

Liver: Autolysis.

Kidneys: Autolysis.

Aorta			Spl			Parath			Rect			Sp C			Mass		
Trach			Panc			Adren			Skin			B Mar			Abd		
Heart			Kid	✓		Sal G			Sk M			Mar S			Thor		
Lung	✓		K.fat			Oes			Mam			Femur			S/cut		
Thym			K.PAS			Stom			Tong			S Ves			Cut		
Ly N			Urin B			Duod			Eye								
Liver	✓		Uter			Jej			Op N								
L.fat			Prost			Ileum			Brain								
L.gly			Gnds			Colon			Pit								
Gal B			Thyr			Caec			Sc N								

(Pathology - continued)

Rat 260♀ - Decedent

0.49 mg/l Ioxynil

Macroscopic findings:

External appearance: Wet fur under jaws.
Soiled fur.

Lungs: Appear swollen.
Congestion.

Microscopic findings:

Lungs: Congestion, probably post mortem.

Liver: Autolysis.

Kidneys: Autolysis.
Bilateral minimal focal mineralisation at the corticomedullary junction.

Aorta			Spl			Parath			Rect			Sp C			Mass		
Trach			Panc			Adren			Skin			B Mar			Abd		
Heart			Kid	✓		Sal G			Sk M			Mar S			Thor		
Lung	✓		K.fat			Oes			Mam			Femur			S/cut		
Thym			K.PAS			Stom			Tong			S Ves			Cut		
Ly N			Urin B			Duod			Eye								
Liver	✓		Uter			Jej			Op N								
L.fat			Prost			Ileum			Brain								
L.gly			Gnds			Colon			Pit								
Gal B			Thyr			Caec			Sc N								

Triage of 8(e) Submissions

Date sent to triage: MAY 0 9 1995

Submission number: 12120A

NON-CAP CAP

TSCA Inventory: Y N D

Study type (circle appropriate):

Group 1 - Dick Clements (1 copy total)

ECO AQUATO

Group 2 - Ernie Falke (1 copy total)

ATOX SBTOX SEN w/NEUR

Group 3 - Elizabeth Margosches (1 copy each)

STOX CTOX EPI RTOX GTOX

STOX/ONCO CTOX/ONCO IMMUNO CYTO NEUR

Other (FATE, EXPO, MET, etc.):

Notes:

THIS IS THE ORIGINAL 8(e) SUBMISSION; PLEASE REFILE AFTER TRIAGE DATABASE ENTRY

For Contractor Use Only

entire document: 0 1 2 pages 1, 2 pages 1, 2, TABS

Notes: 2-sided PDR

Contractor reviewer : Date: 4/26/95

CECATS\TRIAGE TRACKING DBASE ENTRY FORM

CECATS DATA:
Submission # 8EHQ- 1092-12120 SEQ. A

TYPE: (INT.) SUPP FLWP

SUBMITTER NAME: Rhone-Poulenc Inc.

INFORMATION REQUESTED: FLWP DATE:
0501 NO INFO REQUESTED
0502 INFO REQUESTED (TECH)
0503 INFO REQUESTED (VOL ACTIONS)
0504 INFO REQUESTED (REPORTING RATIONALE)

DISPOSITION:
(0639) REFER TO CHEMICAL SCREENING
(0678) CAP NOTICE

VOLUNTARY ACTIONS:
(0401) NO ACTION REPORTED
0402 STUDIES PLANNED/UNDERWAY
0403 NOTIFICATION OF WORKER/CITIZENS
0404 LABEL/MSDS CHANGES
0405 PROCESS/HANDLING CHANGES
0406 APP/USE DISCONTINUED
0407 PRODUCTION DISCONTINUED
0408 CONFIDENTIAL

SUB. DATE: 02/14/92 OTS DATE: 10/07/92 CSRAD DATE: 01/26/95

CHEMICAL NAME:
ioxynil
Nitrile, 4-hydroxy-3,5-diiodobenzo-

CAS#
1689-83-4
1689-83-4

INFORMATION TYPE:		P F C
0201	ONCO (HUMAN)	01 02 04
0202	ONCO (ANIMAL)	01 02 04
0203	CELL TRANS (IN VITRO)	01 02 04
0204	MUTA (IN VITRO)	01 02 04
0205	MUTA (IN VIVO)	01 02 04
0206	REPRO/TERATO (HUMAN)	01 02 04
0207	REPRO/TERATO (ANIMAL)	01 02 04
0208	NEURO (HUMAN)	01 02 04
0209	NEURO (ANIMAL)	01 02 04
0210	ACUTE TOX. (HUMAN)	01 02 04
0211	CHR. TOX. (HUMAN)	01 02 04
(0212)	ACUTE TOX. (ANIMAL)	01 02 04
0213	SUB ACUTE TOX (ANIMAL)	01 02 04
0214	SUB CHRONIC TOX (ANIMAL)	01 02 04
0215	CHRONIC TOX (ANIMAL)	01 02 04

INFORMATION TYPE:		P F C
0216	EPI/CLIN	01 02 04
0217	HUMAN EXPOS (PROD CONTAM)	01 02 04
0218	HUMAN EXPOS (ACCIDENTAL)	01 02 04
0219	HUMAN EXPOS (MONITORING)	01 02 04
0220	ECO/AQUA TOX	01 02 04
0221	ENV. OCCC/REL/FATE	01 02 04
0222	EMER INCI OF ENV CONTAM	01 02 04
0223	RESPONSE REQEST DELAY	01 02 04
(0224)	PROD/COMP/CHEM ID	01 02 04
0225	REPORTING RATIONALE	01 02 04
0226	CONFIDENTIAL	01 02 04
0227	ALLERG (HUMAN)	01 02 04
0228	ALLERG (ANIMAL)	01 02 04
0239	METAB/PHARMACO (ANIMAL)	01 02 04
0240	METAB/PHARMACO (HUMAN)	01 02 04

INFORMATION TYPE:		P F C
0241	IMMUNO (ANIMAL)	01 02 04
0242	IMMUNO (HUMAN)	01 02 04
(0243)	CHEM/PHYS PROP	01 02 04
0244	CLASTO (IN VITRO)	01 02 04
0245	CLASTO (ANIMAL)	01 02 04
0246	CLASTO (HUMAN)	01 02 04
0247	DNA DAM/REPAIR	01 02 04
(0248)	PROD/USE/PROC	01 02 04
0251	MSDS	01 02 04
0299	OTHER	01 02 04

TRIAGE DATE:	NON-CBI INVENTORY	ONGOING REVIEW	SPECIES	TOXICOLOGICAL CONCERN:	USE:	PRODUCTION:
	YES	YES (DROP/REFER)	RAT	LOW	R&D	
CAS SR	NO	NO (CONTINUE)		(MED)	Pesticide	
	(IN TERMINI)	REFER		HIGH		

ATOX

CONTACT:

-CPSS- 0927952113

0 0 0 0 0 0 0 0 0 0 0
> <ID NUMBER>
8(E)-12120A

> <TOX CONCERN>
M

> <COMMENT>
ACUTE INHALATION TOXICITY IN RATS IS MEDIUM CONCERN FOR A 4 HOUR EXPOSURE BASED ON AN LC50 OF 0.38 MG/L. DOSE (MG/L) AND MORTALITY: 0.18 (0/5 M, 0/5 F), 0.36 (2/5 M, 1/5 F), 0.49 (3/5 M, 4/5 F), AND 0.69 (5/5 M, 5/5 F). CLINICAL SIGNS INCLUDED ABNORMAL BREATHING AND BROWN STAINING AROUND SNOUT OR BODY FUR. PATHOLOGY EXAM OF DECEDENTS REVEALED CONGESTED LUNGS IN DECEDENTS AND OCCASIONALLY LUNGS WERE SWOLLEN IN APPEARANCE AND/OR FLUID WAS FOUND IN THE TRACHEA.

$$$$